

XIV. *An Account of an Appendix to the small Intestines of Birds.*

By James Macartney, Esq. F. R. S.

Read March 21, 1811.

EVERY author who has written upon the incubation of the egg, except LEVEILLE', has admitted the existence of a direct communication between the yolk bag and the small intestine of the chick, to which the name has been sometimes given of Ductus Vitello-intestinalis. It was likewise known to STENON, NEEDHAM, and MAÎTRE JAN, that this duct remains in the form of a small cœcum during life; but I do not find that any anatomist was acquainted with the great size that this part possesses in particular species, or its internal structure and uses in the adult bird.

I was led to examine this process more attentively than it had been by others, in consequence of meeting with it in the snipe, in which bird it surpasses in length the cœca of the great intestines.

The appendix has an uniform structure in all the birds I have inspected for it. There appear to be but two tunics; the external is the continuation of the peritonæum; the internal of the villous coat of the intestine. The inner surface of the intestines exhibits different appearances, according to the species. In some it furnishes fine villous processes, in others zig-zag or waving laminæ, which produce a texture to the naked eye, like that of twilled cloth; but whatever may be

MDCCCXI.

L I

the arrangement of the internal coat of the intestine, the appendix is constantly found to present a surface composed of small cells, similar to those assemblages of mucous follicles that are met with in different parts of the alimentary canal. I have not observed in any instance, that the appendix received the natural contents of the adjoining intestine, but have always found it filled with a mucous fluid, I therefore conclude that it performs the office of a mucous gland.

The magnitude and form of the appendix are not so determined as its structure. In the snipe, as already mentioned, it exceeds in length the cœca of the great intestines; its width also is equal to that portion of the gut, from which it arises; but it becomes smaller towards the extremity.

In the curlew I have found it of a very considerable size, although less in proportion to the intestine than in the snipe. It is wider in the middle than at its origin or termination.

In the woodcock it is nearly as capacious as in the curlew.

I have found it very slender, but above an inch long, in the black coot. In this bird the intestines are all long and slender, and the cœca of the great intestines singularly so.

The appendix in the swan and goose is rather larger than in birds generally, and ends in a point.

It is remarkably small in the heron.

In a great number of the passerine and gallinaceous birds that I have examined for the purpose, I have found it very small.

It is short also in the hawk.

The greater size which this process of the intestine preserves in the snipe, curlew, and woodcock, would seem to depend upon the mode of feeding and habits of those birds;

although I do not perceive in what manner this peculiarity of structure becomes useful to them.

The appendix in most birds retains the marks of its origin; thus the remnant of the yolk bag is commonly found attached to its free extremity, with which it still preserves a communication. This occurs particularly in the passerine tribe, and amongst the accipitres. In the nightingale the duct is so short, that it is scarcely visible; but the yolk bag remains during life about the size of a small pea, adhering to the intestine with which it communicates.

The preceding facts furnish a curious example of the œconomy of nature, in adapting an organ of foetal life to the exercise of a particular function in the full grown bird.

They likewise afford a proof that the yolk bag and intestine not only have communicated, but that they were originally continuous structures, a fact which has been lately denied by LEVEILLE'.

At a future period, I hope to lay before the Society, some observations upon the functions of the different parts of the egg during incubation, from which it will be found, that a communication between the yolk bag and intestines exists as a matter of necessity.

EXPLANATION OF THE FIGURES.

Fig. 1. Represents a considerable portion of the intestinal canal of the snipe, in order to show the relative size of the appendix in that bird.

- a.* Indicates the small intestine.
- b.* The great intestine, or rectum.
- c.* Is the appendix, on which may be seen, even upon the external surface, the marks of the cellular structure. At the extremity of the appendix, the remnant of the yolk bag may be perceived.
- d.* Shows the two cœca of the great intestine, which are shorter in this bird than the appendix.

Fig. 2. Is a short portion of the small intestine, with the appendix, in the curlew.

- a.* Is the intestine laid open, to exhibit the plicated, or twilled appearance of the villous coat which is a common structure in birds.
- b.* The appendix opened also, to expose the cellular surface internally.
- c.* Is the remnant of the yolk.

N. B. This figure represents the parts perhaps a little larger than natural, owing to the drawing being made from a preparation in spirits; but the proportion between the appendix and intestine are nevertheless correct.

Fig. 1.

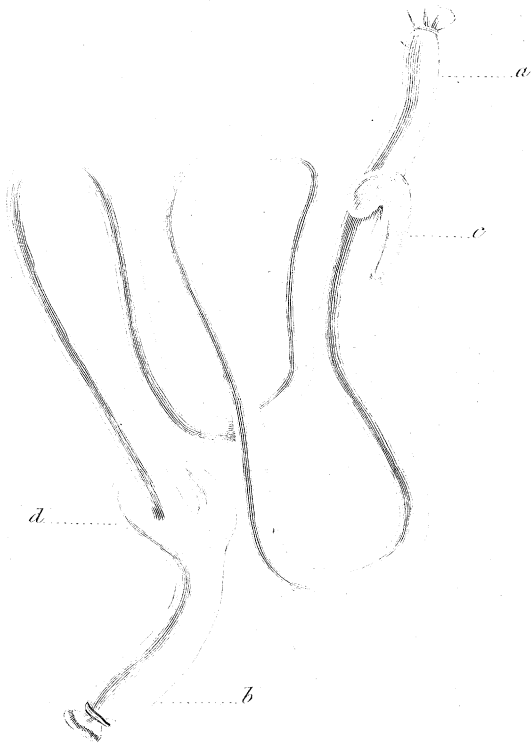


Fig. 2.

