

V. *A case of the human foetus found in the ovarium, of the size it usually acquires at the end of the fourth month.* By A. B. GRANVILLE, M. D. F. R. S. In a letter addressed to Sir EVERARD HOME, Bart., V. P. R. S.

Read January 13, 1820.

MY DEAR SIR,

HAVING met with a well defined case of a foetus in the human ovarium, which illustrates in a very satisfactory manner the explanation contained in your paper on the *corpora lutea*, respecting the mode in which the ovum is sometimes retained, and the embryo formed, within the cavity of the *corpus luteum*, I beg leave, through you, to communicate it to the Royal Society, that it may have a place amongst your observations on that subject.

To render it still more deserving of that honor, Mr. BAUER, to whom you and the public are so much indebted, has made drawings of the parts in a manner which, I may say, no one but himself could have executed.

A lady, aged 39 years, died on the 9th of last June, after having experienced various and severe sufferings, which, with the exception of a short period of apparent convalescence, had lasted from December the 12th, 1818, to the moment of her dissolution.

After death, the body was examined at the request of her friends. It presented nothing which, on a general inspection, might be said to indicate disease, except a considerable tumour,

soft and moveable, yet perfectly distinct, placed immediately above the region of the pubis, and a little to the left of the linea alba. My attention was, therefore, directed to the investigation of this point.

The integuments and muscular coverings of the abdomen being successively and carefully removed, a considerable quantity of fluid resembling blood, to the amount of several pounds, was discovered to fill every space which the viscera did not occupy. Many large coagula of pure blood lay here and there on the surface, and amongst the convolutions of the intestines; under the stomach; in the right hypochondrium principally; and in the cavity of the pelvis, where both the coagula and the fluid were in so large a quantity as completely to obscure from sight the internal parts of generation. Another obstacle to the view of these organs, even after the intestinal mass had been laid aside, was a tumour of the size of four times that of a hen's egg, partaking of the general black-reddish hue of all the surrounding parts.

A blood-vessel of the size of a large crow-quill, which penetrated the dense portion of the tumour, was traced upwards to the descending aorta, and was ascertained to be a branch of the left spermatic artery. A smaller and much shorter vessel, arising from the tumour, was also found to communicate with the spermatic vein; thus establishing a complete circulation to and from the parts. The inferior and left half portion of the tumour presented a surface consisting, in two or three places, of diaphanous membranes, through which a *fœtus* of about four months growth was readily discovered.

The fact of an extra-uterine conception being thus made out, I proceeded to detach the parts from the pelvis, and brought

them to that state of demonstration, which Mr. BAUER has so beautifully represented in the drawing (see Plate VI.)

The left ovarium (O) was the seat of the tumour, which, as it gradually enlarged, distended the coverings of that organ in the same progressive manner, in proportion to its own size, so as to remain, for a time, wholly enveloped by it.

As the fœtus however increased further, the ovarium burst in three different places (1. 2. 3) and thus the membranous sac forming the tumour, protruded partially into the cavity of the abdomen. During this destructive process, that part of the covering of the ovarium was also lacerated, over the inner surface of which the placenta (P) was engrafted, so as to tear the adhesions of the latter, thereby producing that sudden and fatal hemorrhage, which destroyed the life of the mother and the child, and filled the cavity of the abdomen with blood.

EXPLANATION OF PLATE VI.

The womb (A) had acquired considerable developement during the increase of the fœtus, so as nearly to have reached the size which it is known to attain when bearing the produce of conception. Its parietes (*a a*) were thickened in proportion; the orifice was closed, and transversely oblong, as I have generally found it to be in women who have borne children.* Several small prominent vesicles (*bb*) surrounded the internal orifice, and part of the neck of the uterus, within whose cavity (B) neither fluid, membrane, nor production of any description was found.

The right ovarium (C) was of a full size, and healthy, with

* The lady in question had been the mother of seven children. She had regularly menstruated up to December, when conception took place; and from that time there were occasional irregular discharges of a coloured fluid from the vagina.

a great number of the usual cells, containing fluid, distinctly visible; it was terminated by a long slender thread-like appendix (*cc*) of a tendinous nature, which connected it with the neighbouring viscera.

The Fallopian tube of the same side (*D*) was likewise healthy in its structure, but adhering to the lateral part of the *fundus uteri* by means of a short and tough band (*d*), (no doubt the result of inflammatory action), which seemed a prolongation of one of the *fimbriæ* of its floating extremity, so as to give to the tube that peculiar turn, which is so well expressed in the drawing.

The ligamenta rotunda (*EE*) seemed larger than usual, although healthy; and the peritoneal foldings, forming what are commonly called the large ligaments, offered not the slightest trace of disease. The latter were removed in the progress of the dissection, in order the better to exhibit the more important parts just described.

Both the Fallopian tubes were pervious only from their loose extremity inwards, to about half their length, and no farther; nor did any artifice carefully employed, enable me to discover the opening of the tubes into the womb.

The left Fallopian tube (*F*) was perfectly sound and loose, particularly at its fimbriated extremity, which had no connection whatever with the neighbouring tumour.

All the above anatomical and pathological features are accurately portrayed, and to their natural size, in the drawing, to which I beg to refer you and the Society, in order the better to comprehend my description.

It ought to be stated here, that one of my principal reasons for dissecting away the broad ligaments, was to ascertain

whether the peritoneal foldings, within which the ovarium is placed, rather than the membranes of the ovarium itself, formed the covering of the tumour. The dissection, and the drawing, prove that the latter was the case.

In order to supply as much information as possible, respecting a fact so curious and important in itself, the only one I believe on record, which offers such complete and authentic evidence of a perfect ovario-gestation, I thought it expedient to know the internal anatomy of the tumour, and readily acceded to Mr. BAUER's suggestion, of giving a second view of the case, which should represent as many of its important details as could be rightly ascertained. The result of this ulterior investigation, for which the preparation, after having been drawn in its original state, as seen by yourself, Mr. CLIFT, and others, was necessarily altered and cut into, for better demonstration, is given in a second drawing of Mr. BAUER, of the most accurate and finished execution.

I shall only give you an explanation of the references marked in that drawing, which speaks for itself.

EXPLANATION OF PLATE VII.

A. Amnion.

B. Chorion.

CCC. Placenta.

D. D. Fragments of the *corpus luteum* which surrounded the ovum, and was broken to pieces by the enlargement of the foetus.

EEEE. Ovarium.

F. Fallopian tube.

G. A portion of the omentum adhering to the ovarium.

MDCCCXX.

P

From the above explanation, and, on a mere reference to the plate, it appears evident,

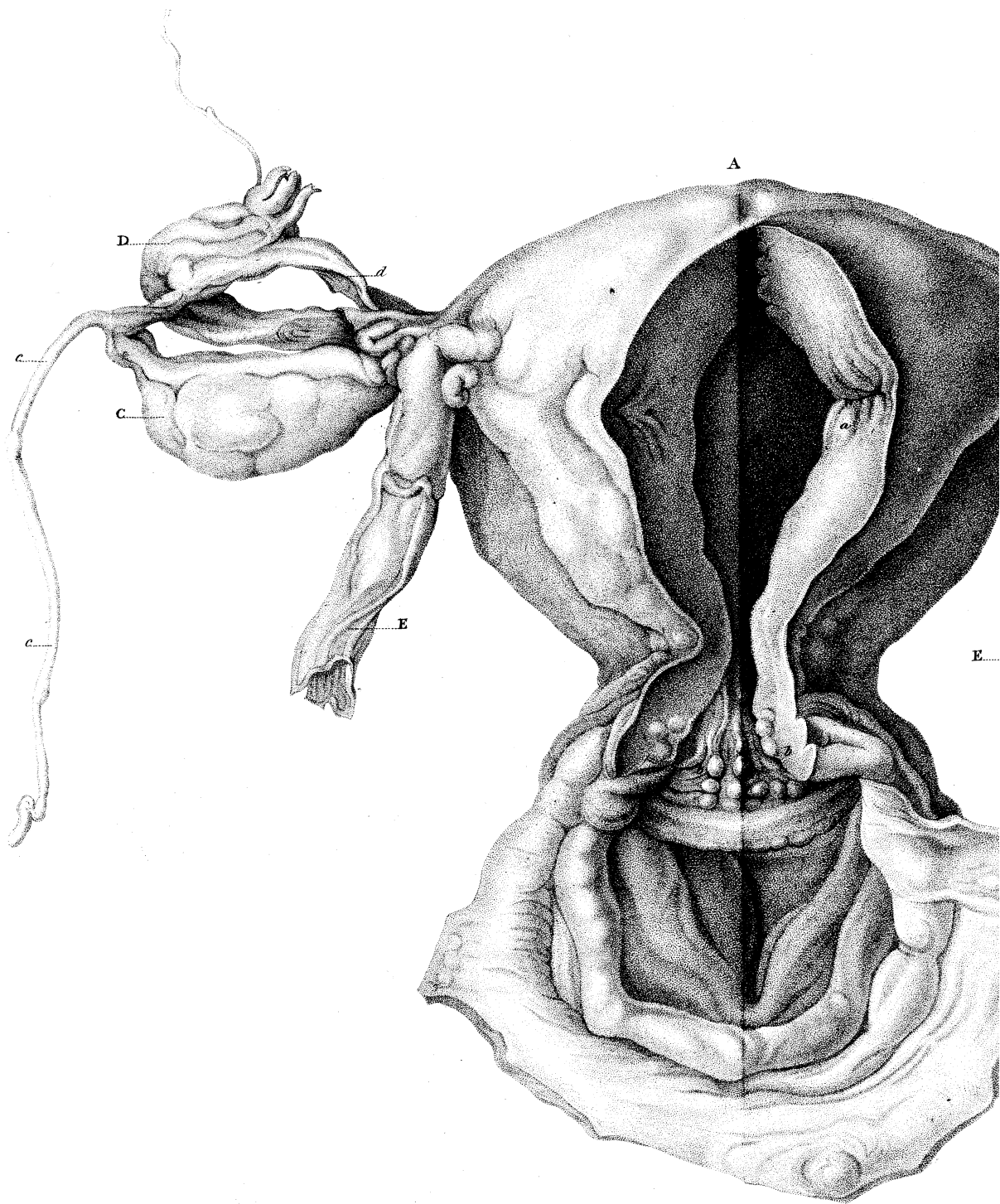
1st. That conception took place in the ovarium.

2dly. That the formation of the placenta and the development of the foetus, does not seem to have been different in this case, from what occurs within the womb under similar circumstances.

3dly. That the ovum was perfect, being formed of the placenta, and the two well known membranes quite distinct, without, however, the decidua of HUNTER.

4thly. That the *corpus luteum* does not follow, but precedes conception, as you have shown in the paper alluded to, since, in this case, considerable portions of the corpus luteum were still found adhering in part to the placenta. To all of which I may add, that the foetus, in every respect as perfect as a foetus of four months is known to be when borne in *utero*, was, in the present instance, contained in one of the outer and inferior cavities of the ovarium, within which it must have been completely inclosed, up to the period of the bursting of its covering; and that the fragments of the corpus luteum, together with the placenta, (which in this case was only half the size of what it should have been, though more vascular and spongy) adhered firmly, by means of short filaments, to the inner parietes of the cavity within which conception had taken place.

In examining the right ovarium, as well as that within which the foetus had been developed, several cells were found, as usual, containing fluid, which hardened into small white masses by the action of alcohol, and appeared to be what anatomists have called *ova*. But having summoned the



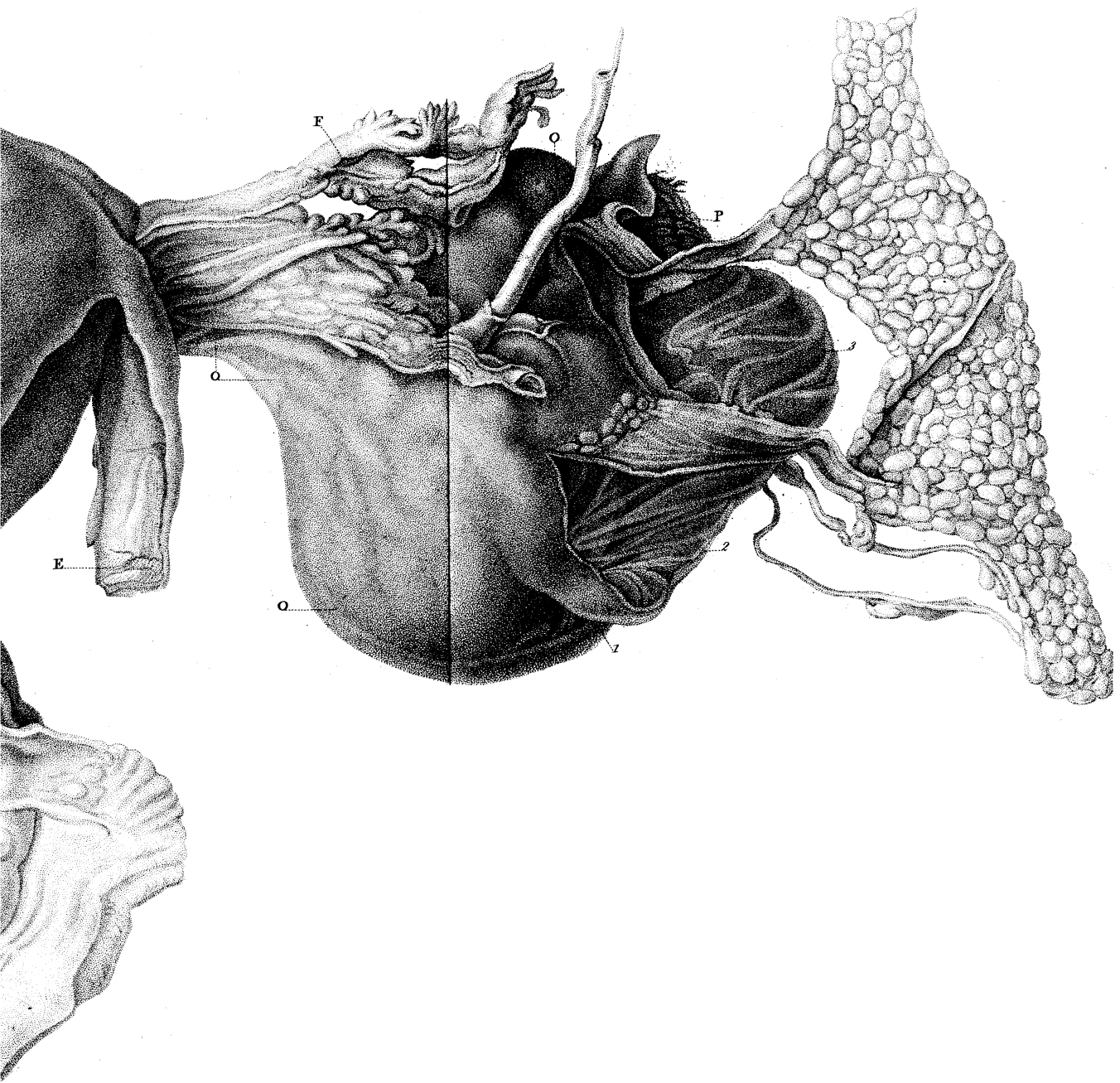



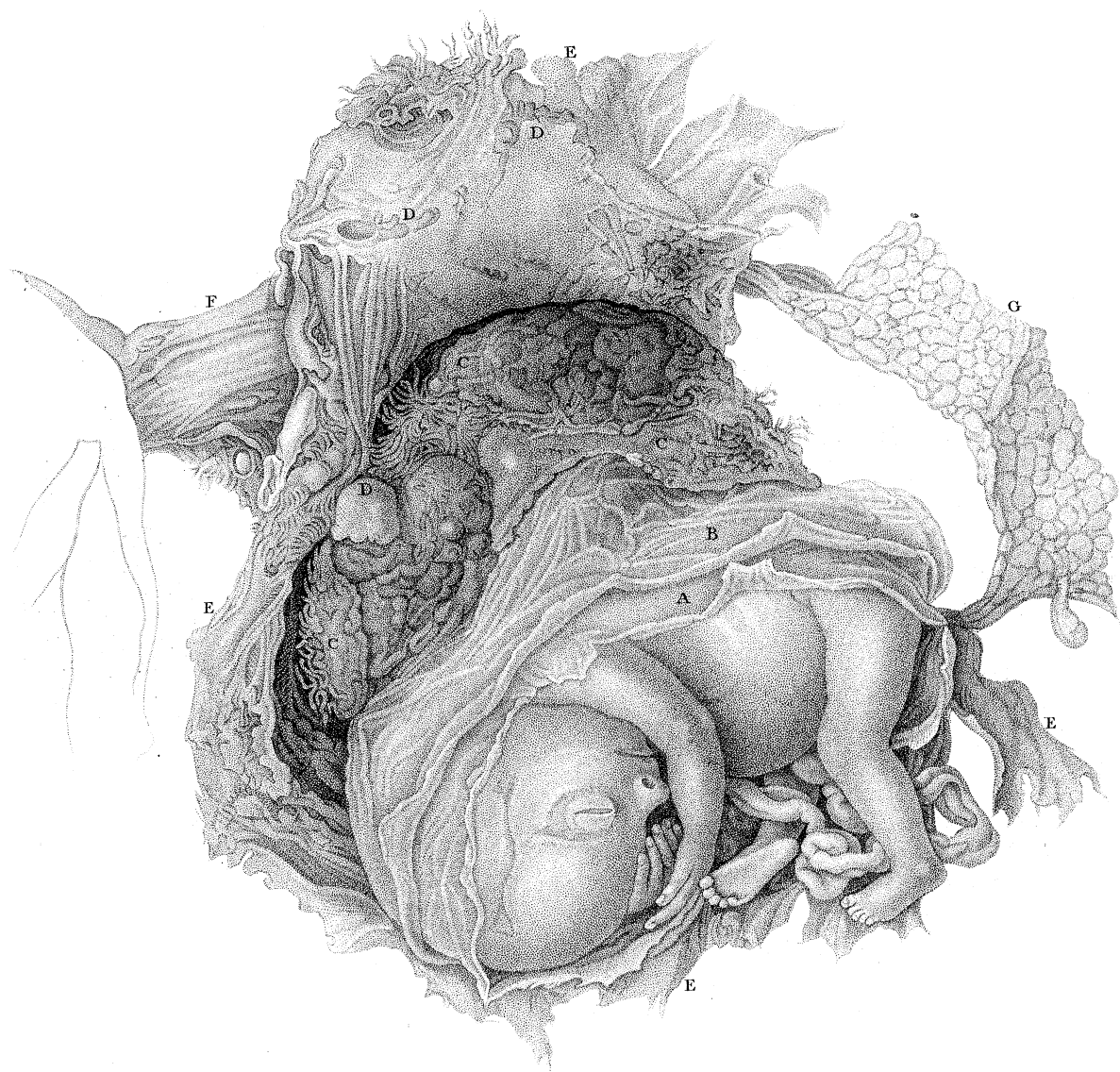


Fig. 1.

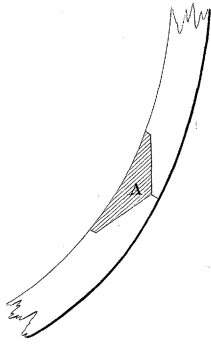


Fig. 2.


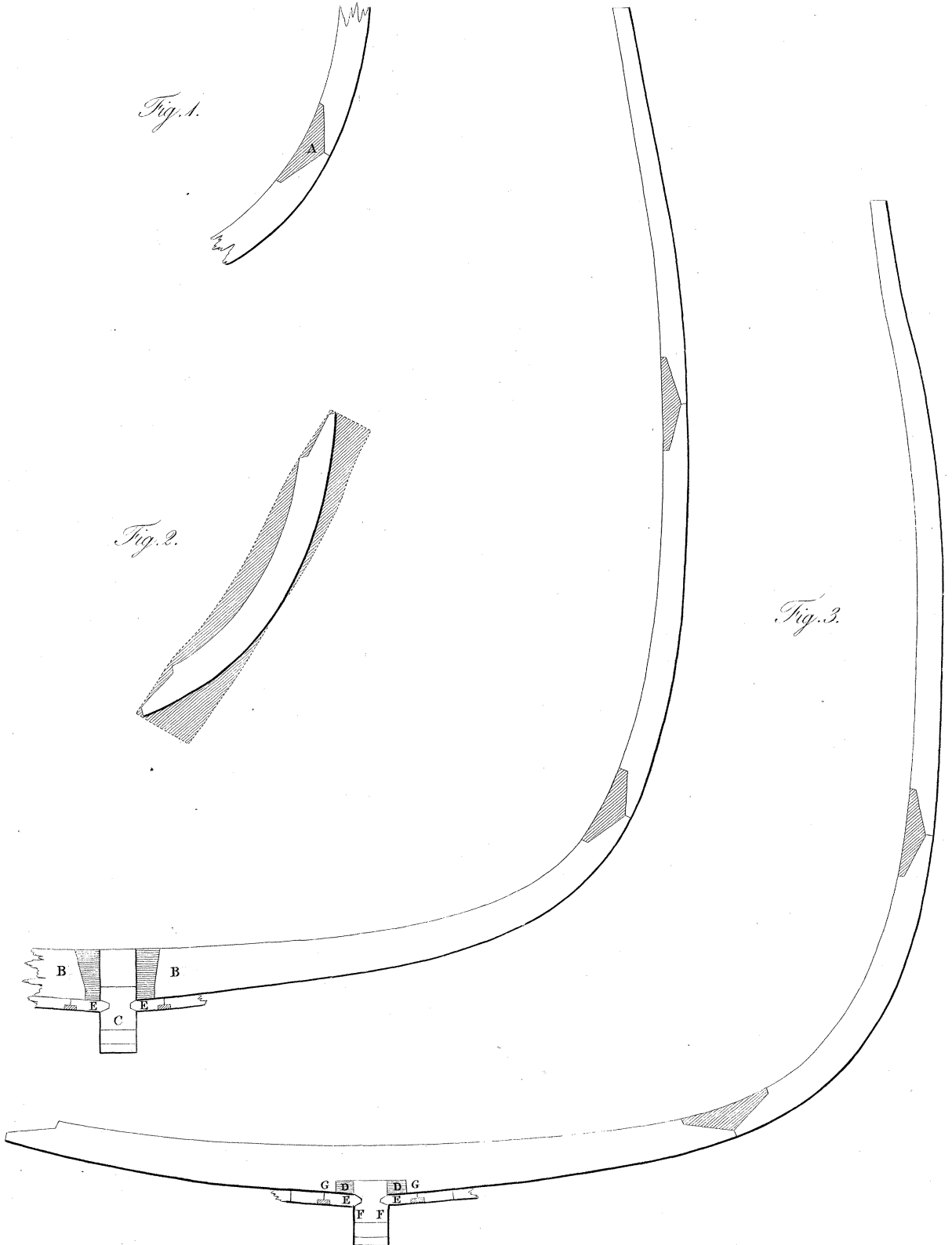


Fig. 3.



microscopical power of Mr. BAUER to my assistance, he has enabled me to give the following explanation, consistent with your doctrine, contained in the last volume of the Philosophical Transactions.

The small round, white, and opaque bodies found in the cells of the human ovarium, as well as in that of other animals in a healthy state, after they have been immersed for some time in alcohol, consist entirely of coagulable lymph, which is easily reduced, in water, to a mass of globules like those observed in *serum*; but in the present instance, the substance of which the coagula consisted, seemed very different, it being a very strong and tenacious mucus, not soluble in water, and which, when pressed, yielded a vast quantity of oil, without the slightest appearance of any globules; a phenomenon supposed to be the effect of previous disease. In the right ovarium there was a *corpus luteum* perfectly well preserved, not far from the cells, which did not contain any such opaque white bodies; while within two other cells equally near, and containing the coagula or white bodies above described, no traces of *corpora lutea* could be discovered. I abstain from all professional observations, this not being the place to enter into them.

I am, dear Sir,

yours most truly,

A. B. GRANVILLE.

Saville Row,
June, 1819.

