

IX. *On the Posterior Lobes of the Cerebrum of the Quadrumana.* By WILLIAM HENRY FLOWER, F.R.C.S., Assistant-Surgeon to, and Demonstrator of Anatomy at, the Middlesex Hospital. Communicated by Dr. SHARPEY, Sec. R.S.

Received November 20, 1861,—Read January 9, 1862.

TIEDEMANN states that the hippocampus minor is not found in the brain of Monkeys, or of any other animals which he had examined, but is peculiar to Man\*. In his figure of a horizontal section of the brain of *Simia nemestrina*, a part is described as “scrobiculus parvus loco cornu posterioris,” and the drawing corresponds with the description. Many writers on human anatomy have followed TIEDEMANN’S statement; thus CRUVEILHIER observes, “Du reste, l’ergot [hippocampus minor] de même que la cavité digitale [posterior cornu of the lateral ventricle] n’existe guères que chez l’homme, sans doute parce que l’homme seul présente un grand développement de la partie occipitale du cerveau†.”

More recently, the presence of a “posterior lobe” of the cerebrum, a “posterior horn of the lateral ventricle,” and a “hippocampus minor” have been affirmed by an eminent authority in this country, to be the distinguishing characteristics of the human brain‡.

On the other hand, according to CUVIER, “les ventricules antérieurs ou latéraux n’ont de cavité digitale que dans l’homme et dans les singes. Cette partie n’existe dans aucun autre mammifère. Sa présence dépend de celle des lobes postérieurs§.” M. SERRES, in his well-known work on the comparative anatomy of the brain, has the following passage:—“Le petit pied d’hippocampe, ou le relief de l’anse d’une anfractuosité dans la corne postérieure du grand ventricule, n’a encore été aperçu que dans l’homme; on l’efface en le dépliant par le procédé que l’on met en usage pour développer le grand ventricule latéral; je l’avais moi-même méconnu en procédant à sa recherche de cette manière. Je l’ai découvert au contraire chez les singes et les phoques, en pratiquant sur le lobe postérieur une section verticale au niveau du genou postérieur du corps calleux: on enlève de cette manière toute la cavité anciroïde, et en l’entr’ouvrant, en comprimant légèrement le lobe postérieur, on voit le petit pied d’hippocampe. Dans les cerveaux qui ont été durcis par l’alcool, on le met à découvert par cette section et

\* The passage in full is, “Pedes hippocampi minores vel ungues, vel calcaria avis, quæ a posteriore corporis callosi margine tanquam processus duo medullares proficiscuntur, inque fundo cornu posterioris plicas graciles et retroflexas formant, in cerebro Simiarum desunt, nec in cerebro aliorum a me examinerum mammalium occurrunt; homini ergo proprii sunt.”—*Icones Cerebri Simiarum et quorundam Mammalium rariorum*. Heidelberg, 1821, p. 51.

† Anatomie Descriptive. Paris, 1836, tome iv. p. 697.

‡ Professor OWEN, Proc. Linn. Soc. 1858, and Annals and Mag. of Nat. Hist. June 1861.

§ Leçons d’Anatomie Comparée (3rd edit.), tome iii. p. 103.

par le procédé ordinaire. Je l'ai maintenant sous les yeux, chez le papion (*Simia sphynx*), chez le rhésus, chez une autre espèce de macaque, et chez le mandrill (*S. maimon*)\*."

In LEURET'S 'Anatomie Comparée du Système Nerveux†' is an observation to the same effect; and in the continuation of the work by M. GRATIOLET, a passage occurs, which is so important in connexion with what has been written upon the subject by other authors, that I shall quote it in full‡:—

"Les ventricules latéraux s'enroulent, disons-nous sur les deux corps striés interven-triculaires. Celle de leurs extrémités, qui répond à la massue antérieure du corps strié, est la *corne antérieure* ou *frontale* du ventricule latéral. L'autre extrémité, enroulée comme le corps strié lui-même, répond à sa massue inférieure. Nous la nommons *corne inférieure* ou *sphénoïdale* du ventricule latéral. Tel est le ventricule dans la plupart des animaux mammifères. Mais dans l'*homme* et dans les *singes*, de la partie postérieure de l'arc du ventricule latéral se détache un prolongement un peu recourbé en dedans comme la corne d'un rhinoceros, ou comme une griffe. Ce prolongement est la *corne postérieure* ou *occipitale* du ventricule latéral. On le désigne encore sous le nom de *cavité ancyroïde*.

"Ce prolongement est fort remarquable; dans les *singes*, il a une grandeur énorme en égard à l'ensemble du ventricule latéral dont l'arc est fort petit. Dans l'*homme*, la prédominance passe à celui-ci. Cette observation est importante, parce qu'elle coïncide avec des observations faites sur la périphérie des hémisphères."

In a foot-note he adds, "Ce prolongement occipital du ventricule est particulier aux primates (*singes*) et à l'*homme*, et par conséquent, il caractérise fort bien le type d'organisation de ces êtres. Toutefois, il ne peut-être considéré comme un signe d'élévation, car il est beaucoup plus grand en égard à la partie enroulée du ventricule dans les *singes*, où son développement est énorme, que dans l'*homme*, où la partie enroulée l'emporte évidemment sur lui. Cette remarque est d'une haute importance, et fait voir que des dispositions, qui caractérisent un groupe élevé, ne peuvent toujours être choisies comme *critérium* des dispositions sériales à l'aide desquelles l'ensemble de ce groupe est zoologiquement conçu. Si l'on attachait à la considération de prolongement occipital une importance absolue, l'*homme* serait inférieur au *singe*. C'est une preuve entre mille que la faute dont les zoologistes doivent le mieux se garantir, c'est de prendre dans leurs raisonnements la partie pour le tout.

"On pourrait supposer, en considérant la grandeur des ventricules latéraux dans le fœtus, que cette grandeur de la cavité ancyroïde chez les *singes* résulte d'un arrêt de développement. Mais cette conclusion serait loin d'être exacte; en effet, aux lobes antérieurs qui, chez les *singes*, sont extrêmement réduits, correspond un ventricule très-réduit dans toutes ses parties, tandis que le lobe postérieur, malgré la grandeur de son ventricule, a un développement relatif énorme."

It was not until the greater number of the observations related in the following paper

\* Anatomie Comparée du Cerveau. Paris, 1826, tome ii. p. 470.

† Tome i. 1839, p. 402.

‡ Tome ii. 1857, p. 74.

were made, and the principal conclusions arrived at, that I met with this passage, which affords from an independent source a confirmation of their general accuracy, but at the same time leaves untouched the necessity for detailed descriptions of the condition of this portion of the brain in particular species. I also think it not improbable that renewed investigations into the development of the human brain may necessitate some modification in the conclusions contained in the last paragraph.

Some of the special monographs upon the brains of Quadrumana exhibit discrepancies almost equal to those existing in the more general statements upon the subject. Thus SCHROEDER VAN DER KOLK and VROLIK found in the Chimpanzee the "lateral ventricle distinguished from that of Man by the very defective proportions of the posterior cornu, wherein only a stripe is visible as an indication of a hippocampus minor\*," while in a memoir on the brain of the same animal by Mr. MARSHALL, these parts are shown to be as fully developed as in an average example in the human brain†. Dr. ROLLESTON has recently described and figured a well-marked posterior cornu and hippocampus minor in the Orang‡; and Mr. HUXLEY, in an admirable memoir to which I shall have occasion hereafter to refer, has given a full account of the structure of the posterior lobes in *Ateles*, a monkey of the Platyrrhine or New World group§.

Such being the present state of the literature of a subject which is evidently within the reach of ordinary observation, it will be seen that its full elucidation must be based upon an appeal to nature, and not to authority. Therefore, with a desire to contribute some reliable data to an interesting branch of anatomical science, I have taken the opportunity recently afforded by the examination of the brains of numerous examples belonging to three families of Quadrumana of making the following observations. The greater number of the specimens described are from animals which have died during the past summer in the Gardens of the Zoological Society. For their transmission into my hands while in that perfectly fresh condition so essential to the success of cerebral investigations, I am indebted to the attention of Mr. BARTLETT, the able Superintendent of the Society's Collection.

As other considerations besides those of a purely anatomical character have been supposed to be involved in inquiries of this nature, I must state at the outset that these have been undertaken without reference to any theory as to the transmutation of species, or origin of the human race; whatever inferences others may draw from the facts related, for my own part I see no reason to assign any special importance, in determining the value of such a theory, to the condition of the particular portion of the cerebral organization now under consideration, especially as the general close resemblance between the physical structure of Man and the Quadrumana has long been a matter of common observation.

As it is to the brain of Man that the comparisons instituted in this paper chiefly refer, it will be necessary in the first instance to call attention to certain points in the struc-

\* Nieuwe Verhandlingen der eerste Klasse van het Koningl. Nederlandsche Instituut. Amsterdam, 1849.

† Nat. Hist. Review, July 1861.

‡ Ibid. April 1861.

§ Proc. Zool. Soc., June 11, 1861.

ture of that organ; and I must premise that in all the ensuing descriptions the nomenclature used is the one proposed by Mr. HUXLEY\*, founded on that of M. GRATIOLET, to whom the merit of reducing to an intelligible and harmonious system the apparently confused and intricate surface-markings of the brain of the Primates is chiefly due†.

Plate II. fig. 1 is a sketch of the internal surface of the right hemisphere of the brain of an adult European. It has been carefully drawn from a specimen which had been prepared for the purpose, by injecting the carotid arteries with strong spirit, and hardening within the cranium, so that the general form and relative situation of the different parts have been accurately preserved. Five principal sulci are seen upon this face of the cerebral hemisphere. 1. The *calloso-marginal* (*i, i*), running lengthwise, parallel to, and between, the upper border of the corpus callosum and the superior margin of the hemisphere. 2. A nearly vertical fissure (*k, k*) placed about midway between the posterior end of the corpus callosum and the apex of the hemisphere. As it forms the line of demarcation between the parietal and occipital lobes, it has received the name of *occipito-parietal* ("scissure perpendiculaire interne" of GRATIOLET). 3. A deep and distinctly marked sulcus (*l, l*) commencing just below the posterior extremity of the corpus callosum, and running backwards and slightly upwards almost to the apex of the hemisphere, where it divides into an ascending and descending branch. This is the *calcarine* sulcus, so named from its relation to the part called, when seen from the interior of the ventricle, "calcar avis," or "hippocampus minor" ("anfractuosité de la cavité digitale," CRUVEILHIER; posterior portion of the "scissure des hippocampes," GRATIOLET). 4. The *dentate* sulcus, in which the small gyrus called "corpus dentatum" (corps godronné) is situated. This is the anterior portion of the "scissure des hippocampes" of GRATIOLET, and holds the same relation to the hippocampus major as the calcarine fissure does to the hippocampus minor. 5. A fissure (*n, n*) running more or less parallel to the last, but at a lower level, named from its connexion with the eminentia collateralis, the *collateral* sulcus. The relations of the last three sulci have been pointed out in detail by Mr. HUXLEY in the paper referred to.

The gyri on the inner surface have their boundaries defined by the above-named sulci, and are of a very simple character. They will be better understood by a reference to the figure, than by a verbal description. 17 is the marginal gyrus; 18 the callosal; 18' the quadrate lobule; 19 the uncinatè gyrus; 20 the dentate; and 25 the internal occipital lobule.

In the hemisphere of the hardened brain (Plate II. fig. 1) the space between the posterior edge of the corpus callosum and the extremity of the lobe was divided into four equal parts, and the sections indicated by the lines A, B, and C were made at the points thus determined. For accuracy of comparison, the same rule has been observed in all the sections of the Simian brains which follow. The figures A, B, and C represent the surface of such sections, and exhibit the distance to which the different sulci penetrate

\* On the Brain of *Ateles paniscus*, Proc. Zool. Soc. June 11, 1861.

† Mémoire sur les Plis Cérébraux de l'Homme et des Primates. Paris, 1854.

into the substance of the hemisphere. It must be observed that in the human brain there is some variation in this respect, but the average depth of the calcarine fissure is well illustrated in this example, as also the usual size of the posterior cornu. This cavity appears in section as a mere fissure curved round a delicate stratum of white substance, which covers internally the grey matter of the calcarine sulcus, and which constitutes the ventricular surface of the hippocampus minor. In section C no trace of the opening can be discovered.

Such is the appearance presented by this portion of the brain, in the highest state of perfection which that organ attains; a condition, however, always the least favourable for studying the morphological significance and true relations of its several parts. The original design, now obscured by special adaptive modifications, can only be traced either by observing the gradual evolution of the same parts from their most rudimentary condition, or by a comparison of similar structures in other animals of simpler organization.

By the first method we learn that while the hemispheres of the brain are mere sacs, and perfectly devoid of convolutions, the calcarine is one of the first of the sulci which appears on the surface (about the fifteenth week, according to TIEDEMANN), and coincident with it, an elevation is seen upon the interior of the ventricle, the future hippocampus minor. The eminence is, in fact, formed simply by an involution of the wall of the original ventricular cavity, and such portion of this cavity, situated in the posterior lobe, as has escaped being closed in by the growth of the surrounding cerebral substance, constitutes the posterior cornu. The variability of its extent in the human subject, and consequent apparent variability of the hippocampus minor, is well known\*. Little physiological importance can, however, be attached to the size of the latter as commonly estimated by the projection into the ventricle. The real amount of cortical or ganglionic neurine surrounding the calcarine sulcus can only be ascertained by an examination of the length, depth, and complexity of that sulcus, and remains unaltered whatever may be the extent to which the cavity of the ventricle is closed: just as the size and form of the corpus striatum would be unaffected by the absence or closure of the portion of the lateral ventricle which lies in contact with it. Such an examination, both in different individuals of the human race, and in the brains of various animals, may supply important data in future investigations concerning the functions of special portions of the grey matter on the surface of the cerebrum.

\* Many of the variations in the condition of these parts must be ascribed rather to pathological changes than to original conformation. Thus, in aged and debilitated subjects, the posterior cornu is often enlarged, and somewhat funnel-shaped, the calcarine projection being also more or less obliterated, a circumstance arising apparently from gravitation of the intra-ventricular fluid during long continuance of the recumbent posture. In atrophy of the cerebral substance, from whatever cause, attended by an increased size of the ventricular cavities, the change is usually most strikingly seen in the posterior cornu.

## Order QUADRUMANA.

Family 1. *Catarrhina*.

Orang-Utang (*Pithecus satyrus*).—The brain of a young female of this species, which died in the Gardens of the Zoological Society, May 1850, is preserved in the Museum of the Middlesex Hospital. Although this specimen has retained its form and general characters unusually well, I do not propose to give any detailed account of it, being unwilling to multiply the too numerous imperfect descriptions which already exist of the cerebral anatomy of this animal—imperfect inasmuch as they are mostly taken from specimens the form of which has been more or less altered by preservation in spirit. A general flattening of the cerebral mass, contraction of the hemispheres, with loss of characteristic outline, obliteration of distinction between white and grey substance, and adherence of contiguous walls of sulci and cavities, render such brains ill adapted for the successful study either of the external characters or internal structure.

The following points relating to the posterior lobes of the cerebrum are, however, to be noted in this specimen. On looking directly down upon the centre of the upper surface of the brain, no part of the cerebellum is visible, either laterally or posteriorly. When viewed from one side, the posterior lobes are seen to project exactly as far backwards as completely to cover the cerebellum, but not to extend beyond it. But an examination of the interior of the cranium from which the brain was taken, shows that the shrinking of the hemispheres has reduced their dimensions in this direction. It is therefore perfectly evident that the posterior lobes of the cerebrum, according to any definition taken from external characters, exist in a very well-developed condition, although not prolonged backwards to quite so great an extent as they usually are in the human brain.

To examine the interior, the upper portions of the hemispheres were removed to the level of the inferior surface of the corpus callosum, and then further portions were carefully dissected away so as to expose the lateral ventricles with their three cornua. The general form of the cavity presents almost the exact counterpart of that in the human subject. The posterior cornu extends as far backwards as an average example in Man, being  $\frac{5}{8}$ ths of an inch long, and its apex being but  $\frac{3}{8}$ ths of an inch ( $= \frac{1}{8}$ th of the entire length of the hemisphere) from the surface of the posterior lobe. The projection of the hippocampus minor bears comparison with a very well-developed specimen of this structure as met with in the human brain. Its length is  $\frac{5}{8}$ ths of an inch, its breadth at the base  $\frac{3}{16}$ ths of an inch. The eminentia collateralis is more prominent than in many human brains. The hippocampus major has no distinct digital marks, but the convex border of its expanded termination has a slightly nodulated appearance. There is a complete correspondence of form in the ventricles of the two hemispheres, the posterior cornu extending backwards to a similar extent in both.

As it seemed desirable to possess an exact means of estimating the length of the posterior lobes in different animals by a criterion derived from internal structure, I have

taken the most prominent part of the convex border of the hippocampus major as the limit between the antero-median and the posterior portions of the cerebrum. The former includes the anterior and middle cornua of the ventricle, the corpus striatum, thalamus opticus, and the hippocampus major; the latter, the posterior cornu and hippocampus minor, where these exist. In Man and the Quadrumana, the angle formed at the junction of the hippocampus major and minor readily indicates the exact spot on which to place the compasses (see Plate III. fig. 7). Such measurements should, if possible, be taken before the brain is removed from the cranial cavity. Let the length of the first part be called A, and that of the second B. In Man the average proportion in several examples of A to B is as 100 to 53. In this Orang's brain A measures exactly 2 inches, and B 1 inch, or as 100 to 50; so that the posterior lobe, as defined by internal structure, exhibits the same slight diminution upon that of the human brain, as was already estimated by the amount of covering of the cerebellum. It must be remembered, however, that this observation is taken from a spirit preparation.

*Presbytes leucoprymnus* (OTTO).—An adult female died in the Zoological Society's Gardens, August 20, 1861, and the brain was examined while in a perfectly fresh condition. The posterior lobes completely covered, and projected beyond, the cerebellum. The sulci on the internal face of the cerebral hemisphere (Plate II. fig. 2) bear a very close resemblance in general arrangement (though of course far less complex) to those of the human brain. The occipito-parietal (*k*, *k*) runs downwards and forwards, and almost meets the calcarine (*l*, *l*), the second internal annectent gyrus scarcely appearing on the surface. The calcarine sulcus differs from that, not only of Man, but of nearly all Apes, in extending to the extremity of the lobe, and even turning round to the outer surface, without dividing into branches. The three sections show that this sulcus penetrates more deeply into the substance of the hemisphere than in Man, but it is tolerably simple in its course, passing nearly directly inwards. The posterior cornu of the ventricle is distinctly open to within a very short distance of the hinder extremity of the lobe, and is of considerable vertical depth, being curled round the very prominent calcarine involution, or hippocampus minor.

In the left hemisphere a horizontal section was made, so as to expose the lateral ventricle (Plate III. fig. 5, *a*). The posterior cornu was seen, when opened from above, to take the same general course as in the brain of Man, viz. outwards, backwards, and finally somewhat inwards, but, owing to the depth of the calcarine fissure, and consequent great projection of the hippocampus minor, it is placed nearer to the external wall of the hemisphere than it is in Man. The measurements of the antero-median (A) and posterior (B) portions of the hemisphere are 1.5 inch and .7 inch—A to B as 100 to 47. The latter is therefore proportionally less than in the human brain.

*Cercopithecus*.—Several examples of this genus have come under examination, including *C. sabæus*, *C. ruber*, and *C. mona*, but a description of *C. pygerythrus* (F. Cuv.), the common Vervet Monkey, will suffice. In order to obtain a side view of the brain *in situ*, the right half of the cranium of an adult animal of this species was carefully



removed with the saw and bone forceps, then the dura mater was taken away, and the contents of the cranial cavity exposed. While still in an undisturbed condition, the extent to which the posterior lobes of the cerebrum projected beyond the cerebellum was ascertained to be fully  $\frac{1}{8}$ th of an inch. On comparing the form of the brain with that of the human subject, very great similarity is seen in the contour of the posterior half of the cerebrum, but the anterior lobes in the Monkey are much reduced, being narrowed almost to a point, flattened, and largely excavated in the orbital regions. Fig. 6 (Plate III.) is a profile view of this brain, and shows accurately the relative form and situation of the different parts while *in situ*, and the arrangement of the sulci upon the outer face of the hemisphere.

Fig. 3 (Plate II.) is a sketch of the convolutions of the inner face of the right hemisphere. The calcarine sulcus is very strongly marked, and describes a curve having the concavity upwards; it bifurcates as usual at the posterior end. The occipito-parietal sulcus, instead of running downwards and forwards as in Man and *Presbytes*, is directed somewhat backwards, and does not join the calcarine sulcus, but terminates at the upper margin of a prominent gyrus (the second internal annectent) which borders the last-named fissure superiorly. The sections show that the calcarine fissure extends to a greater depth than in any other genus (yet examined), and has a singular complexity of form, as there is concealed within it, and attached to its floor, a small but distinct gyrus (Plate II. fig. 3, and Plate III. fig. 7, 26). This convolution, which may be called from its position "calcarine," commences anteriorly by a slight elevation of the floor of the calcarine fissure, increases as it proceeds backwards, and comes to the surface where the sulcus turns up towards its termination; then, bounded superiorly by the lower branch of the sulcus, sweeps round the inferior border of the lobe, and becomes continuous with the infero-occipital gyrus of the outer side. It appears to be always present in *Cercopithecus*, *Macacus*, and *Cebus*, and probably in all the allied genera, but is absent in the highest and lowest members of the order. The consequence of the depth and complexity of the calcarine sulcus is that the involution of grey matter forming its walls is much increased, and bears a very large proportion to the mass of the lobe, and the cornu of the ventricle is thrown quite to the outer side of the hemisphere, being at its termination only separated by a thin stratum of white matter from the cortical layer of its external face. The walls of the cornu are in such close apposition that I have not been able to satisfy myself that it is in the adult *Cercopithecus* an actual cavity in the same sense as the remaining portion of the ventricle, especially as the staining of the lining membrane found in other parts rarely extends more than a quarter of an inch upon the surface of the hippocampus minor. But as fine sections of hardened brains show a line in which the cerebral substance is absent, having always the same definite extent, form, and direction,—as the slightest touch with the handle of the scalpel will separate the walls,—as in some genera it is undoubtedly as distinctly open as any other part of the cavity, and as it has been so considered by GRATIOLET, HUXLEY, and other competent observers, I have no hesitation in looking upon it as homologous to the posterior cornu



in Man. Whether it is an actual or potential cavity is, however, of very little consequence, as there can be no question that the portion of the brain answering to that which in Man is called hippocampus minor, attains in *Cercopithecus* a really prodigious development in comparison with the size of the cerebral hemisphere.

The proportionate length of the posterior lobe, as measured upon a section made while the base of the brain still remained within the cranium, slightly exceeds that of Man, being to the antero-median portion as 54 to 100.

*Macacus*.—The brains of *M. silenus*, *M. nemestrinus*, *M. cynomolgus*, *M. sinicus*, *M. radiatus*, and *M. erythræus* have all been examined. They resemble one another so closely that the latter (the Rhesus Monkey) alone need be described. The length of the posterior lobes, both as to the extent to which the cerebellum is covered, and as ascertained by internal measurement, is slightly inferior to that of *Cercopithecus*. The convolutions of the inner face of the hemisphere (Plate II. fig. 4) have the same general arrangement as in that genus. The calcarine sulcus does not extend to quite so great a depth, but it conceals within it, though on rather a smaller scale, a similar gyrus (Calcarine, No. 26 B, Plate II. fig. 4). In adult examples the walls of the posterior cornu adhere very closely, but in a new-born Rhesus they were distinctly separate almost to the very end of the lobe. In this specimen the hemispheres were so elongated backwards as to project by nearly one-fourth of their length beyond the cerebellum.

*Cynocephalus*.—GRATIOLET has demonstrated that the principal cerebral characteristic of this genus is the great development of the occipital lobes. In a nearly full-grown example of *C. porcarius*, I find that they project  $\frac{4}{10}$ ths of an inch beyond the cerebellum, or rather more than  $\frac{1}{3}$ th of the entire length of the hemisphere; proportionally more, therefore, than in Man. Measured internally, the proportion of the posterior to the antero-median portion of the cerebrum is as 57 to 100—greater than in any other of the Catarrhine Apes. The calcarine sulcus is very deep and complex, as in the last two genera, but the specimen did not reach my hands in time to give any drawings.

#### Family 2. *Platyrrhina*.

*Cebus apella*.—The brain of this species presents a different form from that of *Cercopithecus*, or any of the Old World Apes. The hemispheres are much elongated and compressed laterally, so as to give a regularly oval outline to the entire cerebrum when seen from above. The cerebellum, though large, is entirely covered, and the posterior lobes are of great proportional length, being to the antero-median as 59 to 100.

The sulci upon the inner face of the cerebral hemisphere are shown in Plate III. fig. 5. The calcarine fissure at its anterior extremity joins the dentate, so that the callosal gyrus is not actually continuous with the uncinata as in Man and most of the Quadrumana; but at the point of union the sulcus is extremely shallow, or, in other words, the band which connects the two above-named gyri does not quite reach the surface. At first the sulcus runs somewhat in a downward direction, but ultimately takes a considerable

sweep upwards. It penetrates deeply into the lobe, not quite to the same extent as in *Cercopithecus*, but is so disposed as to contain a similar convolution.

*Hapale jacchus*, the Common Marmoset.—In an adult specimen which died at the Zoological Society's Gardens, September 25, 1861, the brain was exposed *in situ* by clipping away different portions of the cranial bones, and the drawings (Plate III. figs. 8 & 9) made before its outline had been altered by removal from its bed in the skull. Seen from above, the two hemispheres form an elongated oval, slightly narrowed anteriorly. The olfactory lobes extend forwards beyond the cerebrum, but no part of the cerebellum is seen. The side view shows the elongation and flattening of the whole hemisphere, and the extent to which the posterior lobes project beyond the cerebellum. The orbital region of the anterior lobe is greatly excavated. The fissure of SYLVIIUS is well marked, but on separating its lips no distinct median lobe is seen, the only indication of it being a very slight elevation of the floor of the middle third of the fissure. The outer surface of the hemisphere is perfectly smooth and free from sulci, a faint depression only occupying the situation of the antero-temporal, the most persistent of all the sulci of the outer face in the Quadrumana.

The inner surface of the hemisphere (Plate III. fig. 10), quite smooth in its anterior and superior portions, presents, nevertheless, three distinctly marked sulci, the dentate (*m*), the collateral (*n*), and, occupying exactly the same situation as in the higher Primates, the calcarine sulcus (*l*). This is quite simple, not bifurcated at the end, or joined by any other fissure, and describes a curve with the convexity upwards. There is no trace either of the occipito-parietal or the callosomarginal sulcus. A section made at the middle of the posterior lobe (corresponding to the section B in the larger brains) shows that the calcarine fissure is of great depth and has a downward curve. The grey matter surrounding it occupies nearly the whole of the interior space of the lobe, forming a hippocampus minor of simple construction, but very great relative size. The very narrow stripe of medullary white matter between this involution and the external surface contains a distinctly marked crescentic opening, the section of the posterior cornu.

A horizontal section through the left hemisphere (Plate III. fig. 9) exhibits the great length of the posterior lobe as compared with the antero-median, viz. as 62 to 100. The posterior cornu in this view describes a regular curve, with the concavity inwards, and is seen to extend to within  $\frac{1}{10}$ th of an inch of the apex of the hemisphere. Its walls fell apart directly the section was made, and there appeared to be a distinct lining membrane, on which fine blood-vessels were seen to ramify.

The above description would apply almost equally well to the brain of *H. ædipus*, two examples of which have been dissected.

Thus, in the brain of these diminutive creatures and in that of Man, placed at opposite ends of an extensive series, and in many respects so widely removed from each other, are found certain well-marked common characters in the posterior lobes; and the principal distinction that we can draw between them, with respect to this portion of the brain, is, that in the Marmoset the whole lobe is more elongated, the calcarine fissure

more deeply cut, the hippocampus minor more prominent, and the posterior cornu patent to a greater extent.

As has been already pointed out, from an examination of vertical sections of skulls, it is among members of this family that the occipital region of the cerebrum attains its greatest, and also, as far as the Apes properly so called are concerned, its least development; the first in *Chrysothrix*, one of the lowest, and the last in *Mycetes*, the genus usually placed at the head of the family. It is remarkable, also, that among the Catarrhina, as estimated by the same means, the backward development of the cerebrum, in relation to the cerebellum, appears to coincide with the order in which these animals are zoologically arranged, being least among the anthropoid Apes, and attaining its maximum in the *Cynocephali*.

### Family 3. *Strepsirrhina*.

Most of the descriptions and figures of the brains of members of this family hitherto published are unsatisfactory. For example, that given by TIEDEMANN\* of *Lemur mongoz*, though evidently drawn with great accuracy and care, represents a brain the form of which has been considerably altered by hardening in spirit. The same objection applies, but even more strongly, to the delineations of the brain of *Stenops* given by VROLIK† and by SCHROEDER VAN DER KOLK‡. That of *Tarsius*, in the admirable memoir of BURMEISTER§, may perhaps be excepted.

Having, therefore, lately had an opportunity of dissecting a Lemur in a fresh condition, I have thought it desirable to give a new figure of the external characters of the brain. The view of the upper surface (Plate III. fig. 11) was drawn after the removal of the skull-cap, while the brain was still in the head; the other two (Plate III. figs. 12 & 13) immediately after it was taken out, and with the assistance of a cast of the interior of the cranium. After the brain had been a fortnight in spirit, the hemispheres had lost one-fifth of their length, together with their characteristic outline, and had left about half of the cerebellum uncovered.

*Lemur nigrifrons*, GEOFF. (*L. mongoz*, LINN.?).—After removing the upper portion of the skull by a horizontal incision, and then taking away the dura mater, the surface of the encephalon was exposed. The part brought into view consisted of the cerebral hemispheres, with a small portion of the olfactory lobes projecting in front, and of the cerebellum behind. The general outline of the two cerebral hemispheres presented an oval figure, very narrow in front and broad behind, where it was deeply indented in the middle line. On looking directly down upon the centre of this oval, the portion of the cerebellum visible was part of the upper surface of the superior vermis, chiefly exposed by the divergence of the posterior apices of the cerebral hemispheres, and a very narrow

\* *Op. cit.* tab. iv. figs. 1, 2, 3, 4.

† *Bijdrage tot de Anatomie van den Stenops Kuskang*. Leiden, 1841.

‡ *Nieuwe Verhand. der 1<sup>e</sup> Klasse v. h. Kon. Nederlandsche Inst.* 1843.

§ *Beiträge zur näheren Kenntniss der Gattung Tarsius*. Berlin, 1846.

border of each lateral lobe. The extreme projection was  $\cdot 15$  of an inch behind the cerebrum. In front the olfactory lobes extended  $\frac{1}{10}$ th of an inch beyond the cerebrum. The hemispheres were  $1\cdot65$  inch in length, and  $1\cdot3$  inch across their broadest part. On gently separating the edges of the longitudinal fissure, the corpus callosum was seen to cover completely the corpora quadrigemina; its length was  $\cdot85$  of an inch.

The brain was now removed. The general surface of the cerebrum is smooth, but marked with strongly defined, deeply cut, regular, and almost symmetrical sulci. The anterior or frontal lobes are attenuated, being flattened above, compressed laterally, and excavated below for the orbital plates. They are distinctly marked off from the temporal lobe by the fissure of SYLVIVS, which runs upwards and backwards to the parietal region, and has an abrupt and slightly bifurcated termination. The average depth of this fissure is nearly one-fourth of an inch, and on separating its lips, a small, smooth, but distinctly defined *insula* or median lobe of oval form was disclosed. This observation is important, as GRATIOLET says, "Le lobe central [*insula*] paraît particulier à l'homme et aux singes; peut-être voit-on quelque chose d'analogue dans les makis, mais on ne voit rien de semblable chez les autres mammifères." The temporal lobe is full and deep, and terminates posteriorly without any definite boundary in the posterior or occipital lobe. This last is shallow, and excavated on its under and inner surface for the cerebellum.

The sulci on the outer face of the hemisphere are—1. The fissure of SYLVIVS (*e*). 2. A well-marked longitudinal sulcus on the upper surface of the frontal lobe, inclining outwards posteriorly, probably corresponding with the infero-frontal (*a*). 3. A slight longitudinal indentation on the orbital surface of the same lobe. 4. A very distinct sulcus on the temporal lobe, parallel to, but extending rather higher than, the fissure of SYLVIVS, and curving forwards at its upper end (*f*): this is the antero-temporal (*scissure parallèle*). 5. A well-marked longitudinal sulcus on the upper surface of the parietal, and extending into the occipital lobe, marking off the upper limit of the angular gyrus. 6. A slight longitudinal indentation on the outer side of the occipital lobe. There is no trace of the temporo-occipital sulcus (*scissure perpendiculaire externe*), so well marked in the higher Apes, or of either of the parietal fissures; indeed the region on which they should be placed is very greatly reduced. In number, extent, and situation the sulci above described nearly correspond to those of *Callithrix moloch* (as figured by GRATIOLET), a Platyrrhine Ape about the same size as the Lemur.

Upon the internal face of the hemisphere (Plate III. fig. 14) are seen—1. The callosomarginal (*i*), distinct only in the middle third of the hemisphere. 2. A very deeply marked calcarine sulcus (*l, l*), extending from below the posterior end of the corpus callosum, backwards and slightly upwards, to near the extremity of the hemisphere, where it ends abruptly without bifurcation. 3. Joining this, almost at a right angle, is the occipitoparietal (*k*), which does not quite reach the upper margin of the hemisphere. 4. A slight indication of the collateral sulcus (*n*). 5. A well-marked dentate sulcus (*m*).

The olfactory bulbs are in size intermediate between those of the lower Apes and

those of the Carnivora. The corpora albicantia are represented by a single mass, which however is cleft posteriorly, indicating its separation into two portions. The corpora geniculata form distinct white nodules on the sides of the crura, but not visible until the edge of the temporal lobe is slightly lifted up. The pons is but little elevated. The medulla oblongata is very wide, and the tracts called corpora trapezoidea clearly marked out. The corpora quadrigemina resemble those of other Quadrumana, the anterior being larger and of more rounded form than the others. The cerebellum shows a marked inferiority to that of the true Monkeys. The median vermis, especially the inferior portion, is very large. The lateral vermis (flocculus) is also greatly developed, and forms the principal part of the lateral mass of the cerebellum. The body of the lobe is, however, not so much reduced as in the Carnivora.

To return to the cerebral hemispheres. A section was made through the right posterior lobe at the point B (Plate III. fig. 14). The calcarine sulcus is now seen to extend to about the middle of the section, but to be of the simplest form. The cortical layer which it carries with it (hippocampus minor) is bordered by a thin stratum of white substance, which is separated from the contiguous medullary cerebral matter, as in the other Quadrumana, by a fine crescentic line, indicating the presence of a posterior cornu of the lateral ventricle. In a horizontal section of the left hemisphere this cornu appeared as a mere fissure, with walls in close apposition, but traceable nearly to the termination of the hemisphere. In this view, the most marked difference between the parts displayed, and those of the ordinary Quadrumana, consisted in the comparative shortness of the posterior lobe, this being, as compared with the antero-median portion, only as 35 to 100.

None of the authors who have written upon the brains of the Lemuridæ, whose works I have been able to consult, describe a hippocampus minor. VROLIK expressly states that it is absent in *Stenops* ("L'éminence digitale, l'éminence collatérale de MECKEL manquent," *op. cit.* p. 79), and BURMEISTER alone mentions a posterior cornu to the ventricle in *Tarsius*, the only observation upon it being, that it is "very long." There can be no doubt, however, of the strict homology of the calcarine fissure, and its surrounding grey matter (hippocampus minor), in the Lemur, to that of the parts so described in Man and all the intermediate forms; and that in this low and almost aberrant member of the order, although of reduced length, corresponding with that of the hemisphere, it extends more deeply into, and bears a greater ratio to the surrounding mass of the lobe than it does either in Man or in the anthropoid Quadrumana.

The presence of the same parts is shown even more distinctly in the brain of a Galago (*Otolicmus*) preserved in the Museum of the Middlesex Hospital. The animal to which it belonged died in the Zoological Society's Gardens in 1852\*. While alive it was referred to *O. Garnettii* (OGILBY), but its dimensions did not agree with those of the type specimen of that species in the British Museum; its generic determination is, however, sufficient for the present purpose. For reasons given in the case of the Orang, I do not

\* See Proc. Zool. Soc., March 23, 1852, p. 73.

purpose to give a description of the external characters of this brain, but only an account of such parts of the internal structure as have special reference to the subject of this paper. A horizontal section of both hemispheres has been made at the level of the corpus callosum, and the lateral ventricles are laid open. Fig. 15 (Plate III.) represents this dissection. A broad and very distinct posterior cornu extends backwards almost to the extremity of the hemisphere. Its floor and inner wall are raised into a prominence, having distinctly the characters of the hippocampus minor as found in Man and the higher Quadrumana, and corresponding with the deeply marked calcarine sulcus on the inner face of the lobe. The form of the eminence is somewhat triangular, the apex being directed backwards; but its surface is convex, both from above downwards and in the antero-posterior direction, so that the axis of the cavity into which it projects, though directed generally backwards, has first an outward inclination, and finally turns somewhat inwards. The anterior or broad end of the eminence is concave, being adapted to the curved posterior margin of the hippocampus major, from which it is separated by a deep groove. The length of the hippocampus minor is one-fourth of an inch; its breadth at the base almost as much. The part of the outer wall of the ventricle which projects into the angle between the hippocampi may be compared with the "eminencia collateralis" of the human brain\*.

On comparing the posterior lobe in *Galago* with the same part in the true Apes, it is seen that there is, as in *Lemur*, a very marked reduction in length. This abbreviation is the more remarkable as there is no approach to it in the lowest of the Platyrrhine Monkeys. In the possession of a well-defined Sylvian fissure, a median lobe, and a calcarine sulcus, and in the general characters of the convolutions of the hemispheres, the brain of the Lemuridae follows precisely the same type as that upon which the brain of Man and the other Quadrumana is formed, and differs essentially from that of the Carnivora and all other orders of Mammalia. But while the gradations of the brains of this type are tolerably regular and unbroken between the largest and the smallest of the series (i. e. *Homo* and *Hapale*), the Lemurs do not continue in precisely the same line of degradation, but rather should be placed as a small subseries parallel to the lower part of the large series, and distinguished from it by the shortness of the posterior lobes, the large size of the olfactory bulbs, and the inferior condition of the cerebellum.

With regard to the general characters of the posterior lobes throughout the series, although the examination of all the forms is not yet complete, the facts which have already been brought together are sufficient to justify the following conclusions:—

\* A further examination of this specimen, and of the brains of some allied genera, leads me to doubt whether the above-described 'cavity' in the posterior lobe existed before dissection, the length of time that it had been in spirit having greatly facilitated this process. If it did not, it will justify the statement of the absence of the hippocampus minor by anatomists who have looked at this structure only in its relation to the posterior cornu, but at the same time will afford a further illustration of what I have endeavoured to show throughout this paper, viz. that the part of the brain to which this term has been applied can exist independently of the ventricular cavity.

1. That the posterior lobes, whether we understand by the term that portion of the cerebrum which lies over the cerebellum, or, taking our definition from internal structure, that part which is situated behind the hippocampus major, exist in all the Quadrumana, and are characterized in all by the presence of a deep longitudinal sulcus (calcarine) on their inner surface.

2. That the length of this part of the brain, in relation to that of the antero-median portion, varies in different members of the series, but is greater in many of the Apes than it is in Man, and attains its maximum in the smaller members of the family Platyrrhina.

3. That the depth and complexity of the characteristic involution of the cortical grey matter surrounding the calcarine sulcus (or, in other words, that part which, according to its homology with the structure so named in the human brain, must be called "hippocampus minor") is one of the most striking characteristics of the typical Simian brain, as it is greatest in *Cercopithecus*, *Macacus*, *Cynocephalus*, and *Cebus*, less in the anthropoid Apes, and least of all, in proportion to the mass of cerebral substance contained in the lobe, in Man.

## APPENDIX.

TABLE showing the comparative length of the posterior lobes of the cerebrum in certain Quadrumana, and other Mammalia, measured upon the plan described at p. 191.

	Actual length in inches.		Proportion.	
	Antero-median portion.	Posterior portion.	Antero-median portion.	Posterior portion.
Homo (average) .....	4·40	2·35	100	53
Pithecus satyrus .....	2·00	1·00	100	50
Presbytes leucopymnus .....	1·50	·70	100	47
Cercopithecus pygerythrus .....	1·65	·90	100	54
C. sabæus .....	1·65	·90	100	54
C. mona .....	1·20	·65	100	54
Macacus silenus .....	1·75	·95	100	54
M. erythræus.....	1·75	·90	100	52
Cynocephalus porcarius .....	2·20	1·25	100	57
Cebus apella .....	1·60	·95	100	59
Nyctipithecus felinus .....	1·20	·70	100	58
Hapale œdipus .....	·85	·50	100	59
H. jacchus .....	·80	·50	100	62
Lemur nigrifrons .....	1·00	·35	100	35
Stenops Javanicus.....	·90	·40	100	44
Otolienus —? .....	·85	·35	100	41
Pteropus Edwardsii .....	·79	·18	100	24
Erinaceus Europæus.....	·60	·07	100	11
Cercoleptes caudivolvulus.....	1·20	·40	100	33
Felis domesticus .....	1·20	·25	100	21
Canis familiaris .....	1·55	·55	100	35
Equus caballus .....	3·50	1·25	100	35
Sus scrofa .....	2·15	·55	100	25
Dicotyles torquatus .....	2·00	·40	100	20
Lepus cuniculus .....	1·00	·20	100	20



## EXPLANATION OF THE PLATES.

## PLATE II.

All the figures are of the natural size, except the first.

- Fig. 1. Inner face of the right cerebral hemisphere of human brain, reduced one-half in linear dimensions. A, B, C. Sections of the posterior lobe at the points indicated by the lines so lettered.
- Fig. 2. The same part of *Presbytes leucoprymnus*.
- Fig. 3. The same part of *Cercopithecus pygerythrus*.
- Fig. 4. The same part of *Macacus erythræus*.

## PLATE III.

- Fig. 5. The same part of *Cebus apella*.
- Fig. 5 a. Horizontal section of left hemisphere of *Presbytes leucoprymnus*. The transverse lines show the mode of estimating the length of the posterior portion of the brain (B) as compared with the antero-median (A).
- Fig. 6. Side view of the brain of *Cercopithecus pygerythrus*, showing the exact form when *in situ*. The outline is drawn from a cast of the interior of the cranium.
- Fig. 7. Horizontal section of the brain of the same animal. On the right side the middle and posterior cornua are completely opened, so as to exhibit the relative size and situation of the two hippocampi. In exposing the hippocampus minor to this extent, the limits of the cornu (as seen in the sections A, B, C, fig. 3) have not been exceeded; but as the walls are more or less adherent, this must be regarded partly as a dissection. On the left side the walls of the cornu remain undisturbed, part of the brain only having been cut away to expose the commencement of the hippocampus major.
- Fig. 8. Side view of the brain of *Hapale jacchus*.
- Fig. 9. Upper surface of the same brain, the left hemisphere in section.
- Fig. 10. Inner face of the right hemisphere of the same brain. B. Section of the posterior lobe.
- Fig. 11. Upper surface of the brain of *Lemur nigrifrons*.
- Fig. 12. Base of the same brain.
- Fig. 13. Side view of the same.
- Fig. 14. Inner face of the same. B. Section of the posterior lobe.
- Fig. 15. Horizontal section of the brain of *Galago*. On the right side the section is carried rather low, and the hippocampus minor cut through; on the left the whole surface of this structure is exposed by opening the posterior cornu from above. The form of the brain is somewhat altered by keeping in spirit.

*Nomenclature and lettering of all the Figures.*

## Gyri of the outer face:—

- |                              |                                |
|------------------------------|--------------------------------|
| 1. Infero-frontal.           | 8. Medio-temporal.             |
| 2. Medio-frontal.            | 9. Postero-temporal.           |
| 3. Supero-frontal.           | 10. Supero-occipital.          |
| 1'. Supra-orbital.           | 11. Medio-occipital.           |
| 4. Antero-parietal.          | 12. Infero-occipital.          |
| 5. Postero-parietal.         | 13. First external annectent.  |
| 5'. Postero-parietal lobule. | 14. Second external annectent. |
| 6. Angular.                  | 15. Third external annectent.  |
| 7. Antero-temporal.          | 16. Fourth external annectent. |

## Gyri of the inner face:—

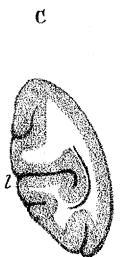
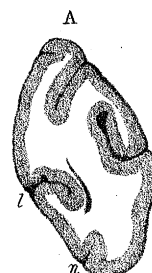
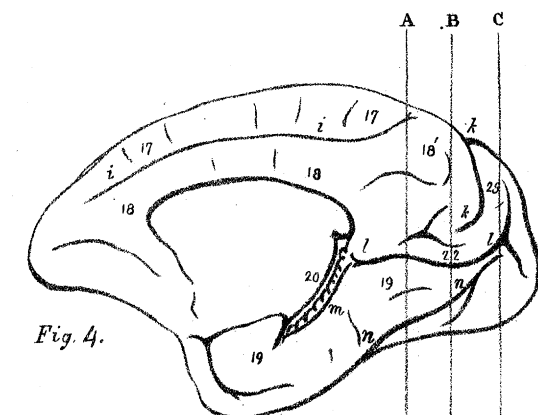
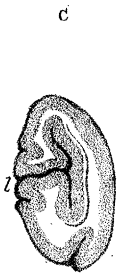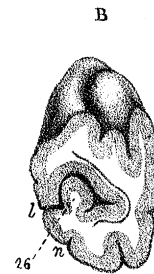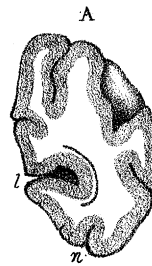
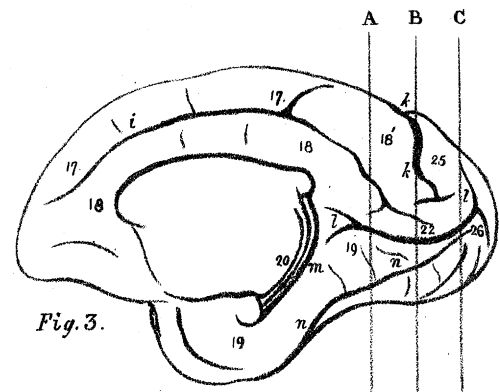
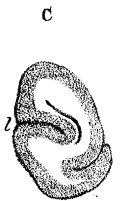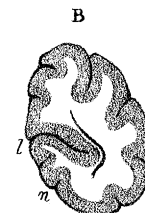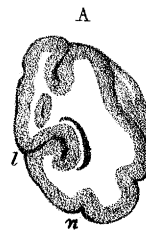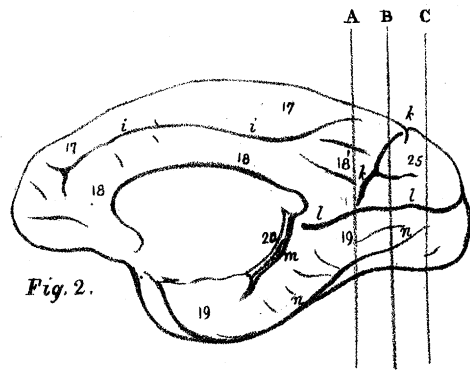
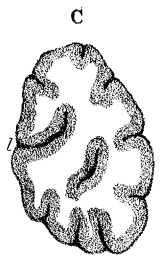
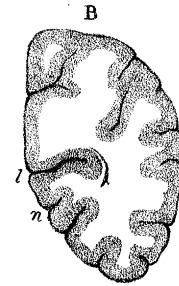
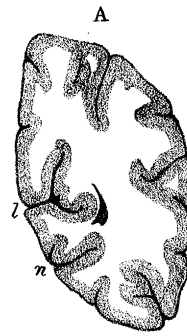
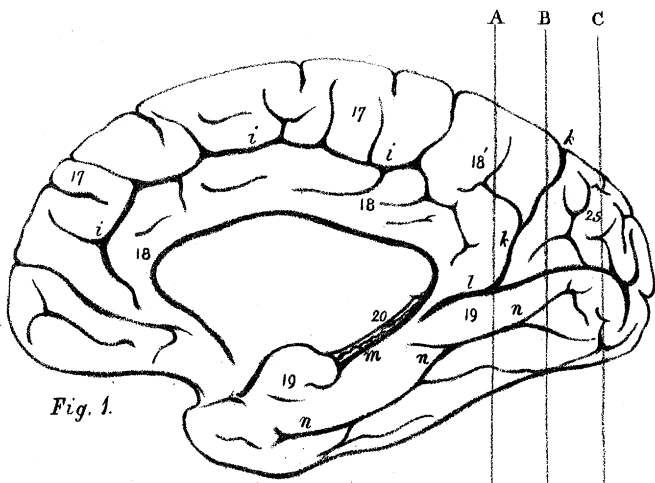
- |                       |                                |
|-----------------------|--------------------------------|
| 17. Marginal.         | 20. Dentate.                   |
| 18. Callosal.         | 21-24. Internal annectent.     |
| 18'. Quadrate lobule. | 25. Internal occipital lobule. |
| 19. Uncinate.         | 26. Calcarine.                 |

## Sulci of the outer face:—

- |                             |                              |
|-----------------------------|------------------------------|
| <i>a.</i> Infero-frontal.   | <i>e.</i> Sylvian.           |
| <i>b.</i> Supero-frontal.   | <i>f.</i> Antero-temporal.   |
| <i>c.</i> Antero-parietal.  | <i>g.</i> Postero-temporal.  |
| <i>d.</i> Postero-parietal. | <i>h.</i> Temporo-occipital. |

## Sulci of the inner face:—

- |                              |                       |
|------------------------------|-----------------------|
| <i>i.</i> Calloso-marginal.  | <i>n.</i> Collateral. |
| <i>k.</i> Occipito-parietal. | ** Hippocampus major. |
| <i>l.</i> Calcarine.         | * Hippocampus minor.  |
| <i>m.</i> Dentate.           |                       |



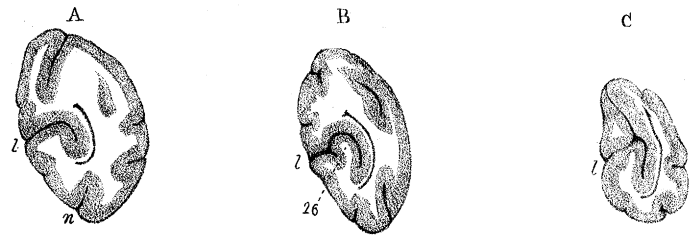
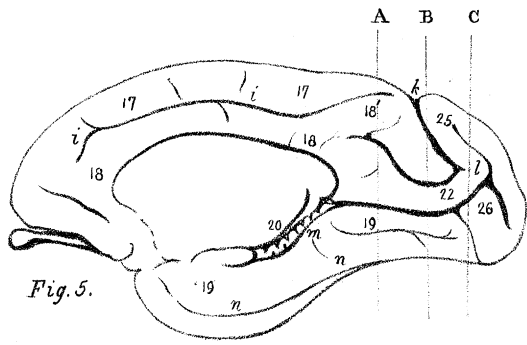


Fig. 7.

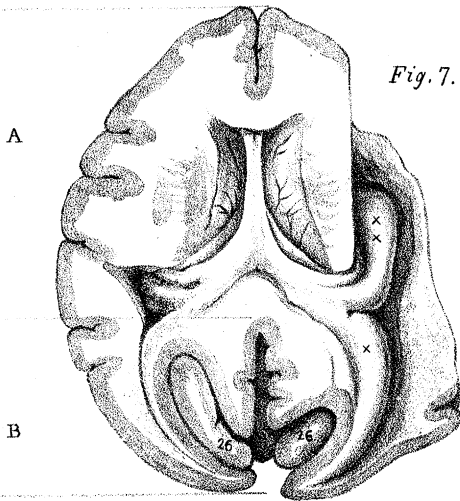


Fig. 6.

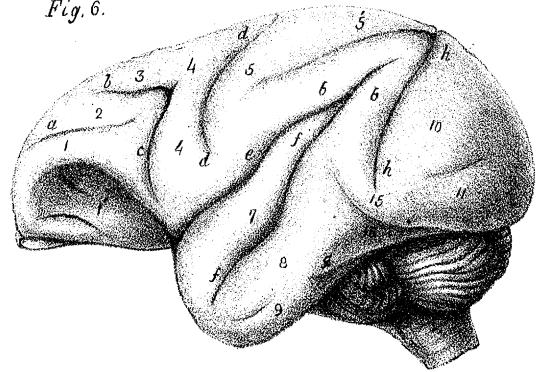


Fig. 8.

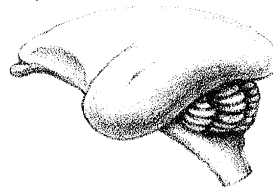


Fig. 10.

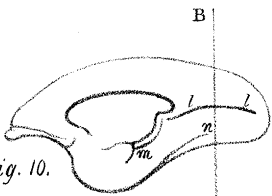
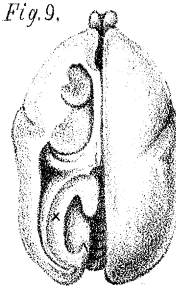


Fig. 9.



A

B

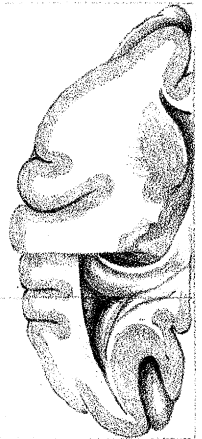


Fig. 5.<sup>a</sup>

Fig. 14.

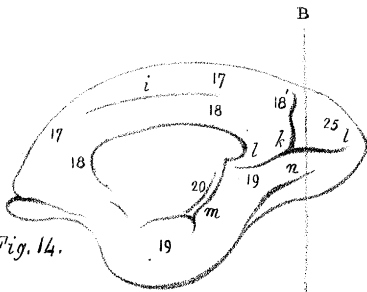


Fig. 11.

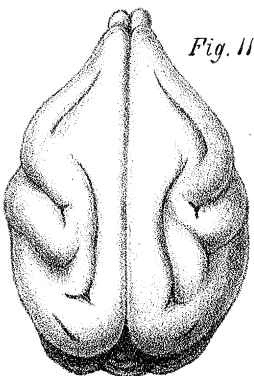


Fig. 12.

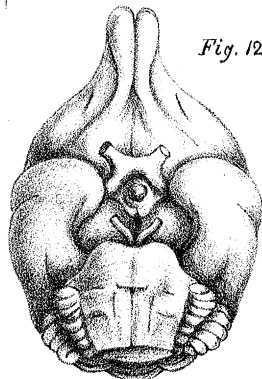


Fig. 13.

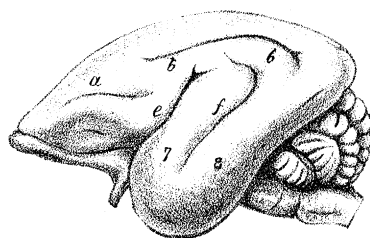


Fig. 15.

