

IX. *On the Structure and Development of the Skull in the Pig* (*Sus scrofa*).

By W. K. PARKER, F.R.S.

Received May 17,—Read June 19, 1873.

MY intention for some time past has been to follow up the Morphology of the Fish's skull by that of the Mammal; and as amongst the "Placentalia" the Guineapig (*Cavia aperea*) takes a very *low* place, it was chosen as the type to work out. I have been led to change my plan, however, and to take a *medium* type by an unexpected supply of materials kindly put into my hands, in November 1871, by my friend Mr. CHARLES STEWART; these were about seventy embryos of the Common Pig, a considerable number of which were barely two thirds of an inch in length, whilst others measured 6 inches in a straight line from the snout to the tuberosity of the ischium\*.

As the tissues in the earlier stages were only in a nascent condition, the greatest care has been taken to harden them for slicing into sections and for dissection from without inwards; and no labour has been spared in this matter the sections being made after the hardened embryos had been imbedded in solid paraffin. These extremely thin objects were coloured with an ammoniacal solution of carmine, and then transferred to slides, on which they were mounted in acid glycerine. The coarser sections of the larger embryos, to be used as opaque objects, were made without imbedding, after the specimens had been immersed in a dilute solution of nitric or muriatic acid, to which had been added some chromic acid†; in the former way I have been able to obtain views of the tissues of the earliest stage under a magnifying-power of as much as 600 diameters, although about 50 diameters has been found to be the most useful, showing, as such a lesser enlargement does, the various parts in relation to each other, and enabling the eye to follow the granular thickenings which are becoming differentiated into special tissues.

The study of this particular type of Mammalian skull has been facilitated by preparatory work in many other types of this Class, extending over a period of thirty-three years; but I have determined not to bring anything forward relating to special modifications until this more exhaustive piece of work has seen the light.

The first impulse in this direction was given me by an invaluable work which appeared long ago; I refer to W. CHESELDEN'S 'Anatomy of the Human Body' (London, 1722, 8vo). But my newer stand-point is from the 'Elements of Comparative Anatomy' (1864), by Professor HUXLEY (Lecture 7th to the end).

\* The actual length of these embryos, measured along the curved line of the spine to the end of the tail, is about one half more than is given by my practical and easier method of admeasurement.

† All the finer sections and preparations were made by my son, Mr. T. J. PARKER.

Since the older writer, no native anatomist has arisen more fitted to hold and to handle this difficult subject than the author of those "Lectures."

I shall follow up this matter from point to point in the same manner as that pursued in the papers already offered to the Society; and my endeavour is to link on paper to paper so that they may form an organic whole, the idea and purpose being the same in each, and the special mode of treatment the same.

In the present communication more *relative* anatomy has been given than in the former papers; I have to steer between the confusion arising from the display of too many parts, and the baldness of a mere account of skeletal structures.

If the nasal and auditory sense-capsules were as easy of elimination as the eyeball, the skull and face would present a much less complex problem; but they soon become part and parcel of a most intricate cranio-facial *unity*, and everywhere intrude themselves upon the observer.

A certain convenient subdivision of this especial piece of morphological work can be made; thus we have—

- 1st. The notochordal region of the skull.
- 2nd. The pronotochordal region of the same.
- 3rd. The facial arches.
- 4th. The sense-capsules.

The metamorphosis of the original and, as it were, *larval* parts here obtains its highest degree; the distance which has to be travelled by the morphologist between the starting-point and the goal may be conceived of if the primary form (Plate XXVIII. fig. 5) be compared with the finished condition of the skull (Plate XXXVI. fig. 4).

In observing the growth-changes that bring about this result, a large amount of *histological* labour is involved; in the present piece of work that part of the research has been taken pains with as much as if it had been intended to write upon the tissues, and not upon their massing and arrangement. The determination of *homologous* parts in this type, as compared with the elements that build up the skull of the Fish, the Frog, and the Bird, has not been by any means the most difficult part of my toil; they arrange themselves, and assume their own titles, in a very ready manner; for the difficulties of terminology will all melt away as soon as a sufficient number of types have been traced down to their embryonic "roots." Many parts will have to be re-named; but this will be easy work when the true reason for the change is made plain.

As the skeletal parts are all composed of the various kinds of "connective tissue," and as these kinds are intimately related to, and often pass insensibly into, one another, it is not easy to keep to a consistent terminology in describing them.

This class of tissues becomes hardened by bone-salts at very different *ages*; and in any homologous territory, if ossification is *late*, the tissue becomes hyaline cartilage first; in other types the like tract may become bony, whilst, as yet, the tissue is extremely soft and young: in intermediate conditions bone is formed in a tissue which is *indifferent*; it

looks like hyaline cartilage, but the cells are crowded, and it is formed into bone before the intercellular substance has time to appear\*.

In the Mammal, more than in any other type, the original parts are all the more completely transformed, in that the bony substance formed in the primordial cartilage becomes very large in relation to its first model; and, moreover, the "investing bones" formed in the subcutaneous web become very large indeed, as compared with the small granular territory, the soft model in which they first appeared.

Also in no other type do the primary facial rods become segmented, arrested, and metamorphosed to the same degree as in this the highest vertebrate Class.

*First Stage.—Embryo Pig,  $7\frac{1}{2}$  to 8 lines long.*

The primordial skeleton of the most highly specialized Mammal is as simple as that of the lowest brain-bearing Fish; the form of the foetal head (Plate XXVIII. fig. 1) may be aptly compared with that of the Fish and Frog (see my former papers on those types). In embryos  $7\frac{1}{2}$  lines in length the three brain-vesicles (C 1<sup>a</sup>, C 2, C 3) are hollow, the film of soft brain-substance merely lining the enclosing membranous cranium. The foremost of the vesicles has budded into the two rudimentary hemispheres above the primary sac, the "thalamencephalon" (Plate XXVIII. figs. 3 & 6, C 1, C 1<sup>a</sup>); yet at this stage the cutis does not cover the whole of the third vesicle (C 3) nor the whole of the auditory sac (*au.*). The head is bent over upon the thin-walled thorax, and the cervical region of the spinal chord is very outbent and swollen (fig. 1).

*The Visceral Clefts.*—After noticing the brain-vesicles and the three pairs of sense-capsules (*ol.*, *e.*, *au.*), the foundations of which are already well laid, the eye detects that peculiar dehiscence of the facial wall, the continuous face being cloven by the formation of a series of slits or cuts, which pass quite through the substance of the cheek and neck. By the older embryologists these are counted from behind the mouth; but in my last paper, especially, I have shown that the mouth itself is a great, double, completed cleft, and that there is a *secondary* cleft in front of it, the "palato-trabecular" or preoral cleft (*cl.* 1). But the "first postoral" is in reality the second cleft; this is the largest in the embryo pig, with the exception of the mouth. Behind this there are three others; and the first of these, the "second postoral," is the counterpart of the most anterior of those through which the *water-currents* pass in the osseous fish. Below and behind the clefts the fore limb is seen in rudiment. Here it will be seen that there is a deficiency in the *number* of clefts behind, as compared with the gill-bearing vertebrates (see papers on Frog and Salmon). Only the first "postoral" cleft is persistent and functional, the three behind soon closing in. I shall describe, anon, what becomes of the persistent clefts, that in front of and that behind the great mouth-cleft. Between the clefts are formed the arches; these facial bars have some resemblance to ribs, but are formed independently of axial parts, whereas the ribs are evident downgrowths from the vertebral portions of the "Somatomes."

\* See on this subject, "On the Connective Tissues," by A. ROLLETT, in STRICKER'S 'Human and Comparative Histology,' translated by H. POWER for the New Sydenham Society. London, 1870, pp. 47-146.

Where the facial arches most closely imitate ribs, as in the first and second postoral, the "capitulum" and the "tuberculum" are applied to a part to which they have no proper morphological relation—namely, to a sense-capsule. This is one of the many modifications the morphological elements are subjected to in the cephalic region.

The original pattern of the facial system of a vertebrate is simple in the extreme; the paired rods are accurately like each other, but their development is not quite synchronous; the *secondary* preoral pterygo-palatine (*p.pg.*) is overshadowed and slow in growth (see Plate XXVIII. fig. 2, where the arches are drawn as though the object were transparent)\*. The facial thickenings between the clefts which contain the arches may be seen with considerable clearness, especially in front (fig. 3); here in front of (above) the mouth towards the mid line we see the clubbed ends of the trabeculæ (*tr.*) roofed over by the nasal sacs. Below and somewhat behind these are the pterygo-palatine arches (*p.pg.*), in the thick outer wall of which the maxillaries and malars will be developed, and the pith of which will become, by early ossification, the palatine and pterygoid bones. Below the *inferior*, transverse, large mouth, the thickenings which contain the first and second postorals are seen—Meckelian and hyoid. The cleft which is formed between the trabecular and the pterygo-palatine bars is best seen in the side view (figs. 1 & 2, *cl.1*); it opens in the inner canthus of the eye. The two pairs of preoral rods will be best understood by reference to a palatal view of the skull with the postorals cut away (fig. 4), and to the diagrammatic view of the skull and face as seen from below (fig. 5). It is easy to see, by a reference to the palatal view (fig. 4), that we are now standing on the same level as the "Dipnoi" amongst the Fishes; the external nostril (*en.*) and the internal (*in.*) lie on the same plane; a free intervening growth of cartilage, binding the arches together, with no further metamorphosis of the parts, would produce a true parallel to the skull of those remarkable Fish. The sinuosities of the upturned palate (fig. 4), its plaits and its crevices, are easily understood by reference to the diagram (fig. 5).

*First Preoral Arch.*—The trabecular rods form together an elegantly lyriform structure; they already have begun their extensive "commissure," being parallel now in their fore half. Behind, they are like callipers, and the blades are at some distance from each other; their apices, sharpened off, seem to approach the fore end of the investing mass (*i.v.*); but a sectional view (fig. 6, *tr.cm., i.v.*) corrects this error, and shows that these diverse parts lie on a totally distinct plane and far from each other, a fact I pointed out long ago in my paper on the Frog (Phil. Trans. 1871, Plate III. p. 143). These trabecular blades embrace the pituitary body (*py.*); but their curve does not conform to its shape, and is altogether independent of it, being the proper "habit" or morphological *fashion* of the arch. After forming the elegant, pyriform, primordial pituitary space, the trabeculæ become thicker, narrower, and lie closely side by side; this is soon followed by fusion of their edges—the formation of the trabecular commissure (see Plate XXIX. fig. 4, *tr.cm.*). These two rods do not end as a straight bar, but in front

\* In my paper on the Frog (Phil. Trans. 1871, p. 148) the pterygo-palatine arcade is described as a secondary structure; in that on the Salmon (*ibid.* 1873, p. 109) it is spoken of as independent. *It is a secondary arch.*



are bent upon themselves, as the fingers in clutching; hence the transverse crevice seen in the palate between the inner nares (fig. 4, *i.n.c., tr.*). This retral growth of the trabecular "cornua" is not so pronounced in the Frog (Phil. Trans. 1871, Plate v.), but is equal to the Mammal in the Bird ("Fowl's Skull," Phil. Trans. 1869, Plate LXXXI. figs. 1 & 2, *tr.*). The median part of the upper lip, which is transverse and quite rudimentary in the youngest embryo (fig. 3, *u.l.*), has developed in a somewhat older specimen (fig. 4, *pn.*) into a pointed retral flap. This flap hides an azygous projection of the trabecular commissure, the "prenasal cartilage;" this axis of the premaxillaries is a part largely developed in Birds (see "Fowl's Skull," Plates LXXXI.—III. *pn.*), where it is first retral, then vertical, and then foreturned, so that it is the principal factor in the exaggerated prognathism of that Class. Outside this process the trabecular cornua are at present clubbed and bulbous (Plate XXVIII. figs. 3, 4, & 5, *c.tr.*); afterwards they each send backwards a recurrent rod\*. The general appearance of the trabeculæ, as seen from above, is shown in Plate XXIX. fig. 4; their varying thickness is displayed in sections (Plate XXIX. figs. 1, 2, 3, & 5, *tr.*).

*Second Preoral Arch.*—Even in the Osseous Fish I found the pterygo-palatine arch both *late* and feeble in its development; in the Frog it is a long time before it appears, and grows very slowly, and is never more than a long conjugational band between the trabecular and mandibular rod. In the Mammal, as in the Bird, this primarily feeble rod is ossified hurriedly, as it were, before the cells can acquire any intermediate substance (see "Fowl's Skull," Plate LXXXI. figs. 1, 6, & 11); yet in the present instance the bony plates that arise in and around these small sigmoid granular rods are some of the most complicated and the most massive in the whole head and face. Even through the palatal skin the hooked tops of the preoral arches can be seen (fig. 4); but whilst those of the trabeculæ grow *inwards*, those of the pterygo-palatine bars grow upwards and outwards, persistent in the "hamular process." The direction of the whole bar (Plate XXVIII. figs. 4 & 5, *p.pg.*) is downwards and forwards, and their extremities or "cornua" approach each other below the trabeculæ: they are at present far apart in this originally cleft palate (figs. 4 & 5); the fold of mucous membrane covering each on its inner side gradually grows towards its fellow, and they eventually meet and coalesce. The thick cushion outside each bar is the nidus in which the maxillary and malar are developed; and the whole maxillo-palatine mass is a mere process or outgrowth of the first (postoral) arch, and is not an independent morphological region. At present the arch is *subocular*; but it does not correspond to the subocular bar of the Tadpole ("Frog's Skull," Plate v.), which is formed by the extremely long pier of the mandibular arch, the arrested conjugational pterygo-palatine lying quite in front of the eyeball.

\* The distinctness of these rods from the surrounding tissues is purposely exaggerated in the accompanying illustrations, for they are imbedded in a gelatinous tissue rich with enclosed granules or young cells, whose protoplasmic substance takes up the carmine very freely; and the differentiation of these rods is at present a matter of degree, that part of the blastema which will become hyaline cartilage being the most compact and crowded with young cells; next to this the nascent perichondrium; and the most gelatinous part outside is the rudimentary condition of the loose stroma or areolar connective tissue.

In this stage a section of the head (affected as it is by the "mesocephalic flexure") which passes through the first cerebral vesicle and its upgrowth takes the pterygo-palatine rods almost from end to end, whilst the trabeculae are cut directly through (Plate XXIX. fig. 5, *tr.p.pg.*). Thus, as compared with the trabecular apices, the pterygo-palatines *descend* a little before they send upwards the apical hook.

*Third Arch, or First Postoral.*—This rod, like its immediate successor, is stout, sigmoid, and strongly inhooked above; it does not at present meet its fellow at the mid line. This is the primordial mandible, *mn.*; but it remains as the lower jaw for a very short time, and is not segmented into an upper and lower piece. There is a stage in all the oviparous Vertebrata in which this rod is free from segmentation; but, above the Lamprey, a pier and free arch are formed by subdivision of the bar. The tissue over it is thick, and in this overlying part the persistent mandible is formed (see Plate XXVIII. figs. 1, 4, & 6, and Plate XXIX. figs. 5 & 6, *mk.*).

The morphological changes that take place in the hooked and inbent apex are of the greatest interest; for now we arrive at the point where not only the hyoid arch is arrested and modified in relation to the outworks of the organ of hearing, but the mandible of the embryo is also suddenly given up to these secondary correlations. Considered in relation to their new function, the parts of the mandible of the mammal might, like those of the upper part of the hyoid arch, be included in the *stapedian* terminology\*.

The Meckelian rod itself is shown in the vertical section near its extremity (Plate XXVIII. fig. 6, *mk.*), and in the palatal view (fig. 4, *mk.*) near its apex; near its apex it is seen on the outside in the lateral view of the sliced head (Plate XXIX. fig. 6, *mk.*). But horizontal sections of the head are necessary to show the relation of the apex of this bar to the first postoral cleft, the rudimentary ear-drum cavity (see Plate XXIX. figs. 7, 8, 9, *mk.*). These sections show that this very expanded cleft is being divided into two spaces, one of which (the inner) becomes the tympanic cavity, and the other the "meatus auditorius externus." The septum or diaphragm is formed by the lining skin of the cleft growing outwards from the side of the ear-sac, and inwards from the outer face; this latter growth is the most intense, being pushed in by the ingrowth of the apex of the embryonic mandible, which, growing inwards and backwards, carries the lining skin of the cleft before it; thus the "membrana tympani" is formed. Looking at these figures, we see at once that the "manubrium mallei" is the hooked apex of the primordial mandibular arch, and that therefore it must correspond with the large bifaceted backwardly placed head of the Bird's quadrate bone"†.

The shoulder or tuberculum of this rib-like bar becomes the thick head of the

\* See "On the Representatives of the Malleus and the Incus of the Mammalia in the other Vertebrata," by Professor HUXLEY, Proc. Zool. Soc., May 27, 1869, pp. 391-407.

† I was under the impression that the "internal angular process" of the Bird's mandible ("Fowl's Skull," Plate LXXXI. fig. 13, *i.a.p.*) was the homologue of the manubrium mallei of the mammal; it is not; both it and the posterior process (*p.a.p.*) are outgrowths formed lower down, and correspond in nature to the "opercular knob" of the next or hyoid arch.

hammer; the solid rod itself develops for a while, but by the time of birth has shrunk into the feeble, pointed "processus gracilis."

*Fourth Arch, or Second Postoral.*—At present this arch is extremely like the one in front of it (Plate XXVIII. fig. 5, and Plate XXIX. figs. 5 & 6, *hy.*); but it is flatter, and the right and left bars meet more closely and at an obtuse angle; its shoulder, also, is more upturned. This arch has been cut through in the palatal vertical views (Plate XXVIII. figs. 4 & 6, *hy.*); but the form of its tuberculum and capitulum are best seen in the horizontal section (Plate XXIX. figs. 7–10, *hy.*), and its shoulder or tuberculum is exposed in the sliced head (Plate XXIX. fig. 6, *hy.*). In this latter figure it is seen that the shoulder stands out like that of a Bird's rib, the head or capitular portion thrusting itself as far inwards as it can on to the periotic wall. The *landmarks* exposed in this figure are the portio dura and the top of the jugular vein (Plate XXIX. fig. 6, *hy.*, 7<sup>a</sup>, *j.v.*). In figs. 7, 8, & 10 of the same, Plate, the horizontal sections show that the head of the hyoid growing towards the auditory mass is exactly like the head of the mandibular rod. The portio dura nerve is seen both at its entrance into and its exit from the facial wall in this figure, and it is of the utmost consequence to the morphologist as being a most safe landmark. In the outer lateral view it is seen escaping behind that part of the hyoid rod which becomes the "stylohyal" (Plate XXIX. fig. 6, *hy.*, 7<sup>a</sup>).

In one horizontal view (Plate XXIX. fig. 7, *hy.*, 7<sup>a</sup>) its whole *auditory* course is seen, on one side its entrance into the wall in front of the first postoral cleft, and its exit behind the hyoid in the other; the same thing is shown in Plate XXVIII. fig. 8, 7<sup>a</sup> (see also Plate XXIX. figs. 8–10, 7<sup>a</sup>). In most of these figures the head and neck of the hyoid are shown from *above* (Plate XXIX. figs. 7, 8) and from *below* (fig. 10, *hy.*); but in another seen from above (Plate XXIX. fig. 9) the section is through the rods a little lower down; and here we get a most instructive view, the shoulder evidently becoming dislocated from the neck, a process which will go on to complete separation of the parts.

*Fifth Arch, or Third Postoral.*—In this arch the Mammal has developed merely the counterpart of the "hypobranchial" segment of the first branchial arch; it is shown in a subhorizontal section *in situ* attached to the larynx (Plate XXIX. fig. 5, *th.h.*, *lx.*), and in the diagrammatic figure (Plate XXVIII. fig. 5, *th.h.*) is seen beneath the auditory sacs. In my paper on the Frog (Plate VII. p. 171) I showed how that the thyrohyals were the hypobranchial remnants of the first and second branchial arches developed backwards; those of the Mammal are therefore strictly homologous with those of the Frog, the latter being formed by retention of a part, which part is alone developed in the former.

Looking again at the five pairs of facial arches as a whole, we see that the only arch, at present, which has developed a conjugational keystone piece is the first or trabecular: this is the "prenasal rostrum" which figures so largely in my former paper on the Bird's Skull. No other keystone appears afterwards in the Pig, save in the last pair;

this becomes the "basihyal" of anthropotomy, but answers to the first "basibranchial of the Fish. These and the other "conjugations" will be shown in the more advanced stages.

*The Notochordal Region and Membranous Cranium.*—With the arrest of the somatic divisions in the cephalic region of the embryo, and the great modification of the nerves of common sensation and of motion, we have no certain guide as to how much or how little of the *spine* the notochordal region corresponds to. The notochord retreating, relatively, from the fore end of the investing mass and becoming in time the temporary axis of a single basal bone, the basioccipital, although it gives a *vertebral* character to its own territory, is yet placed by its altered conditions in a new category.

In my first stage I take the skull when it has been fully bent upon itself—the "mesocephalic flexure;" and at this time the large notochord (Plate XXVIII. fig. 6, *nc.*) bends suddenly upwards, and ends in a free blunted point, exactly opposite that infolding of the membranous cranium which partially severs the second from the third cerebral vesicle (C 2, C 3). The investing mass stops short of the apex of the notochord and lies *beneath* its plane. The relation of the two, as seen from above, is given in the horizontal view (Plate XXVIII. fig. 8), and as seen from below, diagrammatically, in fig. 5. The vertical section (Plate XXVIII. fig. 6) shows the notochord covered above with the membranous cranium (dura mater and cells of the *cutis*), and bearing in its hollow the medulla oblongata (*m.ob.*) and the vesicular cerebellum (C 3). The three structures here seen *behind* the pituitary body (*py.*) form the primordial "posterior clinoid wall;" and the rounded mass of delicate gelatinous stroma which lies above these three parts, in the *hilus* of the kidney-shaped third cerebral vesicle, is the "third or median trabecula" of RATHKE—a structure quite temporary, as that excellent author averred, and of no morphological import\*.

Only in the basal region is there at present any developed hyaline cartilage (Plate XXVIII. figs. 5, 6, 8, and Plate XXIX. figs. 4 & 7, *i.v.*), although it does appear in large tracts afterwards infero-laterally, and even *above* also in the occipital region. At present all but the notochordal region of the cranium is a very soft and delicate membrane, inclosing the large blebs into which the great neural axis has developed. Afterwards this membrane will in certain parts split up into three strata—the dura mater within, the granular territories in which the "investing bones" develop will lie on the outside, and in the middle the hyaline cartilage of the occipital and sphenoidal regions. At present the skin is represented, but not thickened into distinguishable dermis, over the third vesicle (Plate XXVIII. figs. 1, 2, & 6, C 3); afterwards this vesicle will be entirely enringed behind, in the manner of a vertebra, the middle layer of the membrane chondrifying directly upwards from the investing mass. But in the basi-sphenoidal region only as much cartilage as was primarily related to the free end of the notochord (namely, the "postclinoid wall") has any remnant in it comparable to a

\* RATHKE erred in supposing the "paired rafters," or symmetrical trabeculae, to be outgrowths of the investing mass of the notochord.

vertebral structure; and the whole basisphenoidal territory, small as it is in the Pig, is very *compound*, having its origin in the two apices of the investing mass, in the apices and posterior end of the commissure of the trabecular rods, in a chondrified part of the cranial wall (related to the investing mass merely by coalescence at its postero-inferior angle), and, lastly, in a *secondary* growth of cartilage beneath the pituitary body. This last growth of cartilage is found in Sharks and Batrachians, but not in Teleostean Fishes nor in Lizards and Birds.

The basisphenoidal territory may be understood by drawing one imaginary line across the end of the trabecular commissure (Plate XXIX. fig. 4, *tr.cm.*), and a second across the apices of the investing mass, leaving a short tract in front of the posterior line; the figure itself ends at this second line.

The cranial wall in the anterior sphenoidal region is altogether soft and gelatinous at present (Plate XXIX. fig. 5, a section through the primary cerebral vesicle, thalamencephalon, and its two outgrowths, the *hemispheres*); beneath this part the trabecular bands are now fairly differentiated (*tr.*), and these form the lower half of the *compound* presphenoid, as we shall soon see. These are the three proper cranial regions, corresponding to the cerebral vesicles, but not in any proper morphological sense answering to the divisions of the body, the somatomes; no other segment can be found, for the immense outgrowths of the first cerebral vesicle lie upon the nasal roofs.

Even the posterior sphenoid loses what little relation it had to the notochord, which is absorbed by the basioccipital, and is largely formed by borrowing substance from the first facial arch; but the anterior sphenoid is a mere chondrification of the middle layer of the membranous cranium, the two wings mutually sending downwards an azygous plate which coalesces with the common crest of the trabecular bars.

*The Sense-capsules.*—The extent of the olfactory region is at present very small; afterwards the whole labyrinth takes up three fourths of the cranio-facial length. The squarish septum (Plate XXVIII. fig. 6, *s.n.*) looks almost directly downwards beneath the first cerebral vesicle, and the double roof of the labyrinth has the relation of an eave to the cerebral roof. The most projecting kidney-shaped part of the nasal roof is the “ala nasi;” and both lateral and front views of the embryonic head show how this is, as it were, grafted on to the upper surface of the down-bent trabecular bars. A great difficulty is got rid of here, which has cost me much trouble; for the alæ nasi are not formed out of the substance of the trabeculæ, nor can they be considered, in the adult, merely the front and portico of the roof of the nasal labyrinth; they completely coalesce with the trabecular knuckles; and the rooting, ossified snout of the adult Pig is of a compound nature, principally, however, formed of the genuflection of the first visceral arch.

The passage from the outer to the inner nostril (Plate XXVIII. fig. 4, *e.n.*, *i.n.*) is already tortuous (Plate XXVIII. fig. 7, a vertical section *beyond* the septum nasi); for already the mucous membrane has been thrown into baggy folds, into which soft outgrowths of the roof are entering, afterwards to become a labyrinth of cartilaginous

coils. The bilobate mass directly above the trabecular horn (*al.tb.*, *i.tb.*, *c.tr.*) has its anterior lobe developed into the curious "alinasal turbinals" immediately within the snout, whilst its hinder lobe becomes the long "inferior turbinal." The swelling below the down-turned roof is the rudiment of the "nasal turbinal," scarcely developed in the adult of this type; and the mass which lies beneath the rudiment of the olfactory crus (1) becomes the upper and middle turbinal (one mass in the Pig) and the true olfactory region. Vertical sections\* show, most instructively, what could in nowise have been guessed at—namely, that the nasal labyrinth has its skeletal parts formed by the approximation and coalescence of two imperfect cylinders open freely below, and by these receiving at their junction below the ascending crest formed by the conjugated trabeculæ (Plate XXIX. figs. 1–3, *al.s.*, *al.e.*, *tr.*). When these trabecular bands continue flat (as in the embryo, Plate XXIX. figs. 1 & 2, *tr.*), then we have, as in the Frog and the Crow, a cartilaginous floor to the nasal passages (see memoir on "Frog's Skull," Plate VII. fig. 6, and Plate x. fig. 3, *s.n.l.*; and also Proc. Roy. Micr. Soc., Oct. 2, 1872, p. 224, pl. 38. fig. 1, *s.n.*). In most Mammals, and in Birds not belonging to the Passerine group, the trabeculæ narrow in to form the rounded thickened base of the whole "ethmo-presphenoidal bar;" this process is seen to be beginning in the section through the posterior part of the nasal region (Plate XXIX. fig. 3, *tr.*). The section through the inner nares (Plate XXIX. fig. 3, *i.n.*) also shows the back wall of each nasal passage (*p.n.w.*). These large rounded spaces are seen to have the rudiments of the last of the middle turbinal coils already continuous with the end wall. These posterior walls correspond to the end of each "sphenoidal sinus;" this is therefore the presphenoidal region, and *behind* the mesoethmoid; and the pyriform openings above were made through the front of the cranium and through the fore end of the cerebral hemispheres, where they bud-off the olfactory crus (see also Plate XXVIII. fig. 6, C 1<sup>a</sup>, *ol.*). This same section has cut through the first cleft (first preoral or lacrymal passage) on its way to the nasal passage. The anterior extremity of the, as yet, soft palato-pterygoid rod (*p.pg.*) is here cut through, where it passes below the inner nostril (*i.n.*). The space between the rudimentary olfactory crus and the budding upper turbinal (Plate XXVIII. fig. 6, *ol.*, *s.n.*) is composed, at present, of an almost structureless gelatinous stroma; it is slow to form those cartilaginous bands afterwards, which, creeping between the olfactory filaments, form the cribriform plate—a *secondary* morphological structure almost entirely peculiar to the Mammalian skull.

The eyeball only affects the skull from without, by modifying the facial and cranial structures to form its safe recess or orbit; but the *earball* is constructed after the fashion of the old cottage *oven*, being built into the side walls of the skull, bulging out on the outside, and having its *nerve-mouth* projecting also within.

In my last paper, on the Salmon's skull, I was able to show the infolding of the

\* These *vertical* sections of the nasal region were made by the same slicing as the *horizontal* sections of the head further back: this depended upon the hooked shape of the head at this stage; the razor passed at right angles to the nasal roof, but parallel to the notochord.

dermal layer to form the ear-sac, the cavity of which was wide open on the outer surface. In this piece of work "it was my hap to light upon" embryos the youngest of which were filming over this primordial "aqueduct;" the skin (*cutis*) is incomplete over the top (Plate XXVIII. figs. 1 & 2, *au.*), but the passage itself, leading into the rudimentary labyrinth, is closed by a gelatinous plug. The periotic walls come as near to cartilage, in their commenced solidification, as the investing mass and facial arches, and the outline of the sacs can be fairly made out. Their general form can be seen by referring to the horizontal views (Plate XXVIII. figs. 5 & 8, and Plate XXIX. fig. 7, *au.*); but they are well outlined on the external surface (Plate XXVIII. figs. 1 & 2, *au.*), and they are seen to be tuberoso bodies, having a straightish inner margin, a sublobular outer margin, and their broadest end behind. They are separated by the breadth of the investing mass with its enclosed notochord, and this tract is narrowest in front. When the upper face is slightly pared off (Plate XXIX. fig. 6, *au.*), the opening of the aqueductus vestibuli is shown; but this is best seen in a horizontal section, viewed from below (Plate XXIX. fig. 10), where it is seen imbedded in the periotic wall inside the "tegmen tympani" (*t.ty.*); a little behind it is seen the portio dura, which forms by its boring the "aqueductus Fallopii." In the same figure the opposite side of the section was made lower down, so that the roof of the tympanum (tegmen) is cut away, and the tympanic cavity cut through, exposing the head of the second postoral arch and the "aqueductus" just above its entrance into the cavity of the ear-sac\*.

The reader will observe that this passage has the appearance of being double; I could not, however, find more than one perforation. This opening into the auditory sac, which is large in my first and second stages in the Frog, has closed in the third stage ("Frog's Skull," Plates III. & IV. *au.*); in the Salmon ("Salmon's Skull," Plate v.) it has not closed in "fry" of the first summer.

As for the cavity of the ear-sac, it is at present very rudimentary; the canals are but beginning to bud out from the postero-superior region, and the cochlea is perfectly ornithic (compare Plate XXVIII. fig. 8, *cl.*, and Plate XXIX. fig. 7, *cl.*, with "Fowl's Skull," Plate LXXXII. fig. 1, *cl.*).

The sections show the larger nerves and vessels, which serve as excellent landmarks, especially the trigeminal, the portio dura, the glosso-pharyngeal, the vagus, and the hypoglossal nerves (5, 7<sup>a</sup>, 8, 8<sup>a</sup>, 9). The three last nerves all pass through soft stroma in the angle between the auditory sac and the investing mass; the large vessels also ("basilar artery" and "internal carotid") all lie, as dense ensheathed masses of young blood-corpuscles, in the most diffuent stroma, the fluidness and instability of which makes it an admirable "soil" for these fast-growing countless "roots." Before passing to the next stage I must again refer the reader to the diagrammatic figure (Plate XXVIII. fig. 5), that he may compare it with what I have already described in the embryos of the Fowl, Frog, and Osseous Fish at a similar stage. With the vantage-ground of this

\* I have not been able to determine what relation this primary opening bears to the "aqueductus cochleæ," or whether it is related to it at all.



simple platform it will be easy to follow the metamorphosis of the primordial parts, even in the Mammal, where such changes are most of all displayed, and to compare and harmonize them with the lesser degrees of transformation to be seen in Fowl, Frog, and Fish.

*Second Stage.—Embryo Pig, 1 inch long.*

Most of my illustrations of the complete embryonic skull will be made from a somewhat more advanced stage than this; but this second stage is of great importance in illustrating the morphology of the facial arches and auditory sacs\*.

In this embryo *chondrification* has fairly set in, although the cells of the hyaline cartilage are still close together, quite as close as in the nidus of the vomer in the next stage, or the tissue in which the rostrum of the parasphenoid is developed in the embryo bird ("Fowl's Skull," Second Stage, Plate LXXXI. fig. 7, *r.st.*). *Ossification* has commenced also, and can just be seen in the nidus of the vomer, maxillary, and dentary; this last is the forwardest of the bony plates (Plate XXX. fig. 2, *d.*). Beginning at the snout we see that the alæ nasi have chondrified, and that the retral trabecular horns (Plate XXX. fig. 1, *al.n.*, *c.tr.*) have coalesced with them: the little papular prenasal cartilage (*p.n.*) is well seen in this *front* view; beneath this, a little further back, the stroma becomes dense on each side and forms the premaxillary territories, and is ready to ossify. In the deepest and widest part of the ethmoidal region, a vertical section of which (Plate XXX. fig. 2) shows the commenced ingrowing of the proper turbinal folds, we see now that the descending nasal roofs and the ascending trabecular crests have all coalesced together to form the large mesoethmoid (*m.eth.*). A long scoop-shaped territory lies immediately under the trabecular base of this septum, and this granular tract is undergoing endostosis; it is forming the vomer (*v.*). Far on each side, above a rudimentary tooth-pulp, is a faint trace of the maxillary (*mx.*). In this "schizognathous" stage the root of the tongue is seen at no great distance from the freely exposed vomerine region, and the oral cavity (*m.*) has here steep sides, in the walls of which the primary palatal bars (*p.pg.*) are seen as compressed granular plates. On each side, below an inferior tooth-rudiment (*t.*), a large mass of nascent cartilage is seen, having a kidney-shaped section; and inside this a round rod of cartilage is seen, converging towards its fellow of the other side as it passes forwards. If my observations had ended here, the thick slab of granular tissue, with its incurved edges, would have merely been noticed as the proper dentary territory or nidus of the mammalian mandible; it is more than this, as the next two stages will show: the "rod" is MECKEL's cartilage (*mk.*), the shaft of the first postoral arch. The dentary bone itself appears in this section, and is of a rich rose-colour in the preparation, one stained with carmine; the tissue around the osseous deposit is becoming *colourless*, like MECKEL's rod, for the carmine scarcely tints the cartilage. The other postoral bars are shown in this section; the "cornu minor"

\* From a large number of exquisite sections of this stage I have only made the six illustrations here given; for what the rest show is better seen in a somewhat more advanced stage, the morphological level being essentially the same.

(*c.hy.*) is cut through near its junction with the long stylohyal, and the "cornu major" (*br. 1*) is shown in its whole extent on each side; whilst between we have the basal piece (*b.br.*), not, truly, a basihyal, but answering to the first basibranchial of the Fish. The larynx (*lx.*) is below and behind them, and behind it is the œsophagus (*œ.*).

Another section (Plate XXX. fig. 3), taken further back than the last, shows the sphenoidal, auditory, and occipital regions as seen from above. The differentiation of parts has gone on very rapidly, whilst the embryo has merely become longer by one half, and the difficulties in the way of interpretation are largely removed.

In front the "anterior clinoid wall" (*a.cl.*) is seen to be symmetrically divided at the mid line; this is the junction of the trabeculæ at the end of their long commissure, in front of the outbent blades which pass around the pituitary region. The pituitary cup is deep, wide, narrow above, and has a crescentic form, the concavity of which looks forwards. Between this actual cavity and the free ascending ends of the notochord and investing mass there is a large amount of gelatinous tissue, through which the wavy internal carotids (*i.c.*) pass, converging and again diverging. The gelatinous tract, the base of the so-called "middle trabecula" (see Plate XXVIII. fig. 6, *m.tr.*), is widest close to the ear-sacs, and narrows to the edge of the pituitary pit; on each side of it is seen a bulbous mass, the Gasserian ganglion (5). On each side of the extremity of the notochord and investing mass are seen the well-defined ear-sacs, which are here cut through in their cochlear region; the *coils* are now well developed. On the left side the section is *behind* and *below* that shown on the right, where the "malleus" or head of the first postoral is cut through, the shaft of the second arch, and the "meatus externus" and outer ear. Part of a similar section, taken lower down (fig. 4), displays the orbito-sphenoids in section (with their upper part cut away); and where they have coalesced with the trabecular commissure, there the optic nerves (2) are crossing. The alisphenoids (*al.s.*) are sections seen in their whole extent, but not their connexion with the basisphenoid, the notochordal region of which is displayed, backwards to where the basioccipital territory begins.

At a lower level closely packed cells are developing into cartilage, which will form a secondary floor to the pituitary body, the *seat* of the "sella turcica;" then the posterior sphenoid will be morphologically complete. The connexion of the two great postoral bars with the auditory capsule will be better understood by two more sectional views similar to the large figure (Plate XXX. fig. 3), but of more limited extent and more highly magnified: all these figures are made from the *antero-inferior* aspect of the up-tilted basis cranii, the sections, which in the nasal region were *vertical* (figs. 1 & 2), being *horizontal* behind. Such a section (Plate XXX. fig. 5) through the outer ear or concha (*ca.*) and head of the first postoral bar shows how curiously incurved this capitular portion is, and how that its apex is developed into an orbicular part, like that on the apex of the next bar. The shoulder, which articulates with the upper part of the next bar, is very bulbous, and at the root of the neck a conical boss is sent outward; the shoulder is the head of the malleus, the boss is the process for attachment of the

tensor tympani muscle, and the rest of the neck with the rounded head is the "manubrium mallei" (*mb.*). The dark jagged space is the tympanic cavity, a development of the first postoral cleft, and which runs forwards into the mouth-cleft as the Eustachian tube. Now it is easy to see how the membrana tympani is formed; for the inhooked apex of the mandibular rod, creeping like a tendril toward the auditory sac, necessarily carries with it the lining membrane of the cleft wrapped over its head. The shaft is not shown here, because it has been severed with the fore part of the shoulder or "tubercular" portion.

On the left side of the larger figure (Plate XXX. fig. 3) the fellow of this is seen, but cut away further backward. Below the "manubrium" is seen the shaft of the next arch (now to be called stylohyal); its direction is downwards and forwards to the root of the tongue; a good distance must be supposed between this and the section through the ceratohyal already described (Plate XXX. fig. 2, *c.hy.*).

The outer ear or concha (*ca.*) is fast passing into cartilage; it is curiously folded upon itself, and runs round the external orifice of the cleft; it is much modified already from its Batrachian and Plagiostomous prototypes, the "annulus tympanicus" of the former, the "principal opercular" of the latter. The interest attached to the vegetative gemmation of the membrana tympani is more than rivalled in the metamorphic changes that take place in the succeeding arch and in the neighbouring territory of the ear-sac. In the first stage we saw that the simply oval primordial ear-pouch was developing into a lobular form, and that there were three bulgings on the outer side of the sac (Plate XXVIII. figs. 5 & 8, *au.*). The middle of these, by a process of gemmation, has freed itself to a great extent from the wall of the ear-capsule, thus forming a "fenestra" in that wall, which, however, is closed by the separated nodule of cartilage. This twin bud (Plate XXX. fig. 6, *st.*) (it has two papular elevations which look forward and outward from its free surface) is covered externally by delicate indifferent tissue, ready to become cartilage. Being in the posterior wall of the first postoral cleft, the second arch (hyoid), whilst sending its orbicular head inwards, does not become infolded in the mucous membrane lining the cleft, but is free to creep, tendrilwise, to the surface of the ear-sac; this it does, and conjugation takes place between its orbicular "capitulum" and the freed auditory bud. But in the first stage we saw that a curious kind of segmentation was taking place through the shoulder of the second postoral bar (Plate XXIX. fig. 9, *hy.*); now that process is much more complete, and the simple bar has undergone a process the exact counterpart of that by which the blade of the *orange-leaf* articulates with its petiole: whilst this has been going on, a rounded "tuberculum," distinct as that in the rib of a bird, has been developed on the detached upper segment (Plate XXX. fig. 6, *s.c.i.*); this is the "short crus of the incus;" the *neck* growing towards the ear-sac is the "long crus" (*l.c.i.*); its expanded, conjugating end the nidus of the "os orbiculare;" the *half-shoulder* above is the body of the incus, which articulates with the shoulder of the arch in front (Plate XXX. fig. 3, *i., m.*); and the bigeminal segment of the auditory sac is the young stapes (*st.*). The other half of the shoulder, or tubercular

part of the rod, is continuous with the long descending part of the arch (see Plate XXX. fig. 9, *st.h.*); it is the head of the stylohyal. Here we see that the second postoral arch grafts its capitular portion on to the auditory segment, and splits its tubercular portion into two new condyles, one of which, covered by the squamosal on the outside, articulates with the tegmen tympani; whilst the other, retreating very sensibly, *coalesces* with the ear-sac further backwards and downwards, close in front of the exit of the portio dura nerve. In the figure these parts are continuous; but the continuity is kept up at present by *new cells*, and these younger cells are all soft indifferent tissue as yet; their morphological differentiation will be explained in the next stage\*.

Behind the stylohyal and some distance outside the promontory (*pr.*), the portio dura nerve ( $7^a$ ) is seen in section, an excellent land-mark for the stylohyal; further backward the compound 8th nerve ( $8^a$ ,  $8^b$ ) is seen in the "foramen lacerum posterius" (*f.l.p.*); the hypoglossal (9) is enclosed in the upgrowing exoccipital cartilage (Plate XXX. figs. 3, 9, *e.o.*).

The relation of the auditory sac to the exoccipital (*e.o.*) is shown in fig. 7; the whole arch of the horizontal canal is seen shining through the cartilage, and its ampulla is obscured by the fibres of the portio mollis nerve ( $7^b$ ); the Gasserian ganglion, and the compound 8th nerve are also severed ( $5$ ,  $8^a$ ,  $8^b$ ).

*Third Stage.—Embryo Pig,  $1\frac{1}{3}$  inch in length.*

Those metamorphic processes which were rapidly proceeding in the last stage have become very complete in this, where the embryo is one third longer: this stage must be copiously illustrated and described at length, as it is the best stepping-stone between the early simple and the later transformed conditions. The sections now to be described are a series from the end of the snout to the occipital region. Parallel to each other, yet they do not keep the same *vertical* relation to the embryonic head, but become almost horizontal sections of the occipital region: the whole head at this stage is about equal in size to a horse-bean.

The first of these slices is through the end of the snout (Plate XXXI. fig. 1), and shows the coalescence of the alinasal cartilages with the backwardly bent trabecular cornua (*al.n.*, *c.tr.*). The next (fig. 2) is through the foremost part of the septum nasi (*s.n.*) and valvular fold of the nostril—rudiment of alinasal turbinal (*al.tb.*): a more enlarged view of the lower half of the septum (fig.  $2^a$ ) shows the large and massive trabecular cornua, and the prenasal part of the trabecular commissure between them. In the next (figs. 3 &  $3^a$ ) the cornua are now seen to be *retral*, for here they are becoming separate from the "prenasal;" still the base of the septum nasi as well as their

\* I have studied the development of this *interhyal* tract in the Batrachia Anura and Ophidia, where it never even chondrifies; in the Eel (*Anguilla*), where it is very small and indistinct as cartilage, and fades into a mere ligament; in the Osseous Fish (*Salmo salar*) and the Ganoid (*Accipenser sturio*), where it becomes an ossified rod of cartilage; and in the embryo of *Linota cannabina*, where it chondrifies after a time and *fuses together again* the incus and stylo-hyal.

own direction is backwards. Further back (fig. 4) the septum is increasing in height, and the retral processes of the trabecular horns are now much smaller; these slender laminae I propose to call the "recurrent cartilages"\*.

In the *fifth* and *sixth* sections (figs. 5, 6, 6<sup>a</sup>) there is no longer any distinction between the rudimentary prenasal cartilage and the completely fused portion of the trabecular bar, the lower part of the septum nasi; but as this bud-like wedge of cartilage (see Second Stage, Plate XXX. fig. 1, *p.n.*) never becomes vertical, having its apex downwards as in the Chelonians, still less protruded forwards as in its large counterpart in the Bird, the bony plates that appear as its splints are not *superior* as in the Bird, nor *anterior* as in the Chelonian, but *inferior*. These plates are the premaxillaries, which appear in the Mammal below the snout (see also CALLENDER, Philosophical Transactions, 1869, p. 166, Plate XIV. fig. 6, *c*, for its inferior position in Man). Yet in the Mammal the premaxillaries are related, as splints, more to the retral trabecular cornua themselves than to the arrested azygous cartilage impacted between them. So much of the alinasal cartilages as are depicted in the enlarged figure (fig. 6<sup>a</sup>, *al.n.*) is a separate segment—the "appendix alæ nasi." The next section (fig. 7) is behind the first third of the septum nasi, where the rudiments of the "hard palate" begin in front, the lips of which appear now on each of the padded bases of the septum, but are here far apart. The long cushion-like valvular mass in which the aliseptal folds (*al.s.*) end and dilate is the early form of the inferior turbinal, which is not so sharply separate from the alinasal turbinal (*al.tb.*) as in the Bird. A sharp process of mucous membrane is seen above this on each side, where the aliseptal cartilages bend inward; this is the rudiment of the "nasal turbinal" (see HUXLEY, 'Elem. Comp. Anat.' p. 248), which is but feebly developed in the Pig. In the thick mass which envelops the base of the septum two flat straps of cartilage are seen in section; these are the "recurrent laminae" (*r.c.c.*), and they are continued in this stage back to that part of the septum which, ossifying earlier than that in front, gets the name of "perpendicular ethmoid" (see fig. 11). On each side of the lower palatal lip there is a rudimentary tooth-pulp shown in section; and above this, up to the nasal roof, the tissue is marked off from the skin and subcutaneous tissue; this is the granular nidus for the posterior margin of the premaxillary and the anterior margin of the maxillary. The detached piece of this section (fig. 7<sup>a</sup>) is the fore end of the lower jaw with tooth-pulps appearing, and with a curious result of the great prognathism of the type, namely, complete fusion of the ends of the primordial mandibular rods—"MECKEL's cartilages (*mk.c.*)." A section made near the middle of the septum (fig. 8), although answering on the whole to the 7th, shows the tip of the vomer (*v.*) and a very near approach of the lips of the hard palate, and, below (fig. 8<sup>a</sup>), the convergence of the mandibular rods and the fore end of a bony tract outside them; this is the dentary (*d.*); the tongue (*tg.*) is here cut across.

The *ninth* section (fig. 9) takes in part of the frontal wall, with the foremost part of

\* The "recurrent cartilages" are of great morphological importance; in future communications I hope to show their form and meaning in the Ophidians and in Birds, "Passerines," "Hemipods," the *Rhea*, &c.

the membranous cranium; here we shall see the "recurrent laminae" (*rc.c.*) on each side of the vomer (*v.*), and a still nearer approach of the edges of the under palatal floor. The *tenth* section (fig. 10) is through the most projecting part of the hemispheres, but in front of the olfactory crus; here, above the inferior turbinal, folds of cartilage are appearing in the roof, the foremost part of the upper turbinal (*u.tb.*). Here the septum, now to be called the perpendicular ethmoid (*p.e.*), is at its highest, and we are now behind the recurrent processes of cartilage. At this part the palatal bands meet each other, and in them a new bony centre has appeared, the maxillary (*mx.p.*); like the premaxillary, it begins below. The next section (fig. 11) is through the widening ethmoidal region and the partly separated olfactory crura (1), as well as through the hemispheres (*C 1<sup>a</sup>*). The *twelfth* section (fig. 12) is through the cavity of the hemisphere, which is being cut off from that of the olfactory crus (1): it is immediately in front of the eye, the anterior (inner) canthus being cut through. This section is of great interest; here we are behind the aliethmoidal cartilages above, and the olfactory bulbs rest upon the soft mat through which their fibres root down into the nasal cavity. The walls, both outer and middle, reach further backward than the roof of the nasal sac; and in the middle wall we see the ribbed condition caused by thickening at the junction of the trabecular crests with the double keel sent down by the nasal alæ. Here the middle turbinal arises above the inturned nasal wall which ends the inferior turbinal (*m.tb.*, *i.tb.*). This section is behind the new maxillary centre, but shows a large tooth-rudiment on each side of the conjugating palatal flaps; the antagonist teeth appear in rudiment below on each side of the severed tongue (*tg.*), above the growing dentary (*d.*), whilst inside the dentary is the Meckelian rod (*mk.*).

The next section (fig. 13) is through the anterior third of the eyeballs (*e.*) and the middle of the hemispheres (*C 1<sup>a</sup>*), and *behind* the perpendicular ethmoid; here the rest of the septum is almost, if not entirely, of trabecular origin; the section is in front of the junction of the orbito-sphenoidal cartilages (*o.s.*) with the basal median part. But if the mesoethmoid is dying out here, the nasal wall (*n.w.*) continues much further backward, bordering the greater part of the so-called presphenoid (*p.s.*). We are now behind the upper and lower turbinal regions, and here the "middle turbinal" (*m.tb.*) is near its extremity; one interspace is cut through. This narrow, subcranial, presphenoidal part of the nasal labyrinth, running so far backwards parallel with the trabecular plate, is the "sphenoidal sinus;" and if any osseous centres were to form in the wall of this narrow region, they would be, as in Man, the "bones of Bertin," the hindermost of the ossifications of the olfactory sacs. Bound strongly beneath the basifacial wall is the granular nidus of the vomer (*v.*), kidney-shaped in section; and beneath it the posterior nares are imperfectly floored in this the region of the palatal bone (*pa.*), which is a centre just commencing in granular indifferent tissue less solid and clear than that of the vomer. Below the mouth this section differs from the last in that the dentary (*d.*) is thicker and lies closer to the mandibular rod (*mk.*).

The *fourteenth* section (figs. 14 & 14<sup>a</sup>) is through the middle of the eyeball, and

gives us the first intimation of the frontal (*f.*) outside the orbito-sphenoid (*o.s.*). The end of the middle turbinal is seen from behind in the sphenoidal sinus (*sp.s.*); at this part the nidus of the vomer is most solid, and comes nearest to hyaline cartilage (fig. 14<sup>a</sup>, *v.*), a state of things first pointed out to me by my friend Mr. CHAS. STEWART.

The proper territories of each investing bone in the Pig evidently only want *time* that they might all become true cartilage; ossification sets in too soon for the formation of the intercellular substance, but each tract, before ossification, is a true morphological element or organ, as much so as the cartilaginous "operculars" and "branchiostegals" of a Shark or the "labial cartilages" of a Myxinoid. In illustration of these remarks I have now to mention a fact new both to Professor HUXLEY and myself, namely, that the substance which ossifies to become the dentary (figs. 14 & 14<sup>a</sup>, *d.*) becomes for the most part very typical solid colourless cartilage, as much so as MECKEL'S cartilage, which it invests: I shall show this more fully in the next stage.

The *fifteenth* section (Plate XXXII. fig. 1) is through the fore edge of the optic foramen; and here we see the nasal wall (*n.w.*) closing in upon the presphenoid (*p.s.*), and joining the end of the sphenoidal sinuses. Part of each optic nerve (2) is seen in this section, and for that reason the orbito-sphenoid appears distant from the median cartilage below; its continuity is seen in the vertical section (Plate XXXIII. fig. 4). Here the frontal (*f.*) is growing down towards the orbit, to which it will form a ceiling.

The *sixteenth* section (Plate XXXII. fig. 2) is through the largest part of the hemispheres and the underlying thalamencephalon; the eye is cut through near its posterior canthus, and the optic chiasma is severed (2). This section is through the lowest part of the presphenoid, which is still invested below by the vomer (*v.*); and opposite the section of the hindermost part of the ascending palatine plate we see the fore part of the cartilaginous "external pterygoid plates" (*e.pg.*). The orbito-sphenoids (*o.s.*) are here at their greatest size, creeping far up the cranial wall and protecting the swelling hemispheres; the section through the dentary (*d.*) is close in front of the "coronoid process."

The *seventeenth* section (Plate XXXII. fig. 3) is through the large orbito-sphenoidal leaves, where they join the presphenoid behind the optic foramen (see also Plate XXXIII. fig. 4, *o.s.*, *ps.*, 2). This is the last section which shows the vomer (*v.*), and here the razor passed through the soft, faintly ossified "internal pterygoid plate"—pterygoid proper. The fore-turned external pterygoid plates (*e.pg.*) are here thick massive cartilages; and here, also, both the primary (*mk.*) and secondary (*ar.*) elements of the mandible are composed entirely of hyaline cartilage; this part of the permanent lower jaw is the coronoid and fore part of the articular regions. This section through the posterior part of the palato-pterygoid bar is of great interest, as it gives the direction taken by the apex of the second facial bar, namely upwards and outwards, although the *upward* bend is less in the Pig than in many Mammals; it has its fullest development in that small Ruminant, *Tragululus javanicus*.

In the *eighteenth* section the basisphenoid and its alæ (Plate XXXII. fig. 4, *b.s.*,



*al.s.*) are cut through obliquely, so as to show only the *floor* part of the latter; and the cartilage beneath the pituitary body is made to appear thicker than it is in reality (see Plate XXXIII. figs. 2 & 3, *py.*). On each side of the pituitary body the internal carotids are seen passing to the "circle of WILLIS," and outside these the Gasserian ganglia. Overlapping the whole are the orbito-sphenoids (*o.s.*); and on each side of the flaps of the soft palate (*s.pa.*) MECKEL'S cartilages are severed; and lower down the ceratohyals (*c.hy.*), thyrohyals (*t.hy.*), and larynx (*lx.*) are shown.

The *nineteenth* section (Plate XXXII. fig. 5) is drawn a little more than half across, and on a larger scale. The curve of the cranio-facial axis makes this and the succeeding section very oblique; and in this figure the basilar artery (*b.a.*) is tilted to show the bulbous end of the notochord (*nc.*): this thickish section is viewed from behind. The notochord ends now in the region of the future "spheno-occipital synchondrosis;" this narrow part of the basilar plate or investing mass is subcarinate. The razor has passed through the cochlea (*cl.*) parallel to the plane of its coils; over this part of the auditory sac, which is scooped above at the side, lies the great Gasserian ganglion (5); and inside and above this the fore edge of the large superoccipital lamina (*s.o.*) is seen, severed close to the edge, so that there is here a discontinuity between it and the ear-sac, the reason of which is shown in the *inner* lateral view (Plate XXXIII. fig. 3, *au.*, *s.o.*), where a large rounded notch is seen in front of the occipital cartilage, bulged out at this part by the lateral sinus. At some little distance from the cochlea the first postoral (now a veritable "malleus") is severed through its head, neck, and shoulders; the *head* is now flattened: this section shows the thin edge of this manubrium, the thicker part being cut through in the next section (fig. 6, *mb.*). This view (fig. 5, *m.t.*) well shows the imbedding of the manubrium in the membrana tympani, and the inner and outer regions of the first postoral cleft, thus divided by the head of the bar.

The *twentieth* section (Plate XXXII. fig. 6) is a little oblique from side to side; it is thus practically double; the left hand shows parts in front of those displayed on the right. Here, on the left, the manubrium mallei (*mb.*) is cut through at its thickest, posterior part, and its solid shoulder (*ml.*) is seen, the part which articulates with the incus. The incus (*i.*) is seen on the right side, hiding the manubrium partly, and having its "short crus" cut away: the figure shows the *back* of the thickish section. On the right side the section is behind the notch on the base of the fore edge of the superoccipital (*s.o.*). Below and outside the tympanic cavity (*t.c.*) the stylohyal (*st.h.*) is seen in oblique section as it passes downwards and forwards, and mesiad of this there is the large jugular vein (*j.v.*) with a coiled radicle. The notochord (*nc.*) is very clearly seen in the substance of the basioccipital cartilage. On the right side the stapelial bud is seen projecting from the auditory capsule just above the section of the promontory (*st.*, *pr.*), and to this the orbicular "capitulum" of the second postoral is applying itself limpet-like. The *twenty-first* section (fig. 7) is from behind the left side of the last (reversed), and shows on the whole what is displayed on the right; in both (figs. 6 & 7) we see the opening of the "aqueduct of the vestibule," and in this the "aqueduct of Fallopius" containing the

portio dura (7<sup>a</sup>), and mesiad of the jugular vein the glossopharyngeal nerve (8<sup>a</sup>) is cut through; outside the nerve, and below the stylohyal (*st.h.*), a part of the exoccipital (*e.o.*) appears. A similar section to the other side is also shown as a front view (fig. 8); and here the relation of the portio dura (7<sup>a</sup>) to the hyoid arch is well seen. This figure does not show the incus, which is removed to display a new segment (*i.hy.*) that has arisen, the counterpart of the Sauropsidian "infrastapedial" (H.) and of the so-called "stylohyal" of the Fish (Cuv.); here it will be called the "interhyal" (P.), as it really wants a proper name. In the second stage (Plate XXX. fig. 6) I have displayed the relation of the segmenting second arch to the very Batrachian stapes (see "Frog's Skull," Plate VII. figs. 12-16, *st.*); and on the same Plate (fig. 8) I have put for comparison the state of things in the third stage; both are *front* views, and the apex of the stapes is towards the eye. The bigeminal papulae on the younger stapes are now connected by a bridge of cartilage, and the lateral dimples are the *foot-hole* of the little stirrup.

The round head of the short crus of the incus is seen articulating with the tegmen tympani (Plate XXX. fig. 8, *t.ty., i.*); and *below* and *behind* it is the clavate head of the stylohyal, which is ready to coalesce with the periotic cartilage at the junction of the epiotic and opisthotic regions (see Plate XXXVI. fig. 2, *i., st.h., op., ep.*). The descent of the dislocated hinder half of the shoulder of this second arch is not so great as in the Osseous Fish ("Salmon's Skull," Plate VI. fig. 2), but it is considerable; and this is a true third stage, as may be seen by comparing fig. 9, *hy.*, in Plate XXIX. with figs. 6 & 8, Plate XXX. The binding, intervening band of new indifferent tissue which has grown in the gap of these divided parts has acquired a hardening nucleus of new cartilage, exactly as we see it in Ganoid and Osseous Fishes, e. g. *Accipenser*, *Anguilla*, *Salmo*. The portio dura (7<sup>a</sup>) is seen passing down its aqueduct behind these segments, and the upturned, inbent, long crus or neck of the rib-like bar ends in an elegant sucker-shaped disk, its capitulum or apex\*.

On the same Plate the postoral arches of the third stage are shown in a side view (Plate XXX. fig. 9); and a comparison of the undivided mandibular bar with the displaced fragments of the hyoid will make things plain to the mind. The apices of the two bars come very near together; but whilst the first hooks backwards, downwards, and inwards, it does not graft itself upon the auditory sac; nor does its shoulder send backwards a secondary pedicle so distinct as the "short crus of the incus." Moreover the shaft of the bar on the first arch keeps on its way normally, as in the early embryo; but in the second arch this part has been segmented off, and displaced backwards and downwards, catching in its descent at the *neck* and *head* of the arch, but travelling still further in more advanced stages, until it rests and combines with the postero-inferior angle of the auditory mass. In the new web which grows between the two segments comes the secondary "interhyal" segment; this, however, loses all its first relations, and finally

\* In both these figures, put together for comparison, the parts of the second arch are coloured, and those of the auditory capsule are plain, for the sake of distinction, that the *eye* may learn to separate the "stapes" from the segments of the hyoid arch.

coalesces with the neck of the projecting stapes (Plate XXXVI. figs. 2 & 3, *i.hy., st.*), and is half lost, at last, in the tendon of the "stapedius" muscle. The "cornu minor" (*c.hy.*) of Man is here seen (Plate XXX. fig. 9, *c.hy.*) below, articulating with the keystone of the arrested third postoral. This lesser horn answers to the "hypohyal" (P.) of the Osseous Fish. The *twenty-second* section, a front view (Plate XXXIII. fig. 1), is through the three semicircular canals; the anterior canal (its arch) is above, near the superoccipital cartilage (*a.sc., s.o.*), whilst the horizontal canal (*h.s.c.*) is laid bare at its crown and where its non-ampullar end enters the vestibule (*vb.*). The posterior canal has the base of its ampulla laid open, and half the arch is seen shining through the cartilage; the lateral cerebellar recess (*l.c.r.*) is seen above the aqueductus vestibuli (*aq.v.*). The space between the auditory mass and the basi- and exoccipitals is the posterior foramen lacerum (*f.l.p.*; see also fig. 3); the basilar artery lies on the basioccipital, and the notochord is within it (*b.o., b.a., nc.*).

From a series of sections taken horizontally in the nasal region, but which were cut through the investing mass at a right angle, or nearly so, I have selected two as of most importance in this demonstration. The first of these (Plate XXXII. fig. 9) is a front view, and shows the left mandibular rod coming forwards and downwards, its manubrium being buried in the tissue behind. The portio mollis (*7<sup>b</sup>*) is seen lying at the entrance of the meatus internus. The anterior (superior) canal (*a.s.c.*) is cut through near its ampulla, and the cochlea (*cl.*) is divided at right angles to the plane of its coils.

On the other side (left of the figure, right side of the head) the portio mollis (*7<sup>b</sup>*) is seen streaming into the labyrinth, and the portio dura (*7<sup>a</sup>*) is cut through close to the tegmen tympani (*t.ty.*). The crown of the anterior canal is here cut through, and the horizontal canal near its ampulla; here the "tegmen" is seen at its high anterior part, and the "short crus" of the incus lies in front of its descending portion, where the overlying horizontal canal dips before it turns inwards to enter the vestibule. The "long crus" of the incus (*i.*) is shown hooking upwards, and expanding into its orbicular portion on the stapes (*st.*), the apex of which has been cut away, exposing the hole. The head of the stylohyal (*st.h.*) is cut through, and in the angle between it and the long crus there is a large pisiform "interhyal" (*i.h.y.*). The basioccipital has an irregularly pentagonal section, shows the notochord in its centre, and is very distinct from the auditory mass: this distinction is very clear and persistent in the Mammalia.

The plane from which the last section was taken being sliced again, yielded what I have depicted in fig. 10: this is a *back* view, and the left side of the figure corresponds to the left side of the head. On the right side the occipital arch (*s.o.*) appears almost to its crown; on the left its fore edge is just missed.

The left side of this figure corresponds very nearly to the left of the last, but the razor has passed close behind the auditory nerve and through the promontory, where its cartilage passes as a narrow band between the fenestræ (*f. ovalis* and *f. rotunda*), a tract which receives osseous matter from the "opisthotic" centre. Here the base of the stapes is towards the eye, and half of it is seen through the cochlear wall (promontory): the rest is as in the last figure.

But the section of the right side, just a degree further back, is most instructive. The large superoccipital cartilage is seen embracing and walling in the great sinus (*s.o.*, *l.s.*), and the periotic mass is severed at the junction of the anterior and posterior canals, so that the tube opened here is the "common canal" (*c.c.*). The posterior non-ampullar half of the horizontal canal (*h.s.c.*) is opened over the hinder part of the tegmen tympani. The promontory is cut through at the fenestra rotunda (*pr.*, *f.r.*), and outside this is seen the head of the stylohyal; all this long sinuous rod (*st.h.*) is exposed, and also the short ceratohyal (*c.hy.*) at its base, where it is seen articulating with the three rudiments of the next arch (base and larger cornua of hyoid of Man).

Reconstruction of the skull at this third stage from the foregoing materials will be rendered easier by light obtained from longitudinally vertical sections (Plate XXXIII. figs. 2 & 3). In these the first is made, in the facial region, a little to the left of the mid line, so as to give the left face of the septum of the nose; in the next (fig. 3) the septum is cut away, and the left face of the right turbinals exposed. In the first (fig. 2), the brain is sketched in outline *in situ*; in fig. 3 it has been removed to display the inner wall of the cranium. The notochord (*nc.*) has retired from the posterior clinoid wall, and has been buried in cartilage; it still lies, however, nearest the upper surface of the investing mass. This may be compared with the like view in the first stage (Plate XXVIII. fig. 6). There the basifacial axis scarcely made a right angle with the basicranial; here these parts meet at an angle larger by one half: there the notochord mounted above the investing mass; here it has retired, and lies below the clinoid wall. The gelatinous space called by RATHKE the "middle trabecula" is gone, and the reduplicated lining membrane of the cranium has formed the "tentorium cerebelli" (fig. 2, *t.cb.*). The huge expansion of the hemispheres (*C1<sup>a</sup>*) has hidden the middle vesicle (*C2*), as seen from the outside. Behind the large cerebellum (*C3*) the occipital cartilage (*s.o.*) is seen in section; and below the rounded margin of the basioccipital (*b.o.*) is shown, the tract becoming thinner forwards, and then much thicker close to the pituitary body (*py.*); it ends above in the overlapping "posterior clinoid wall" (*p.cl.*). The pituitary depression is not saddle-like, but is a deep cup, floored by a good plate of cartilage. The anterior clinoid wall (*a.cl.*) is rounded, and belongs to the presphenoid; the depression in front of it is for the optic chiasma. The median plate rises gently in front of the optic depression, and this higher part for a short distance belongs to the anterior sphenoidal territory: it is formed principally by the trabecular commissure and crests. The rest of the plate belongs to the perpendicular ethmoid and septum nasi; the latter is the longest region and the former the highest. The lateral ethmoid (*al.e.*) is scarcely seen in this view (fig. 2). Below the pituitary body the Eustachian opening (*eu.*) is seen, in the root of the tongue the ceratohyal (*tg.*, *c.hy.*), and in the substance of the lower jaw the commissure of MECKEL's cartilages (*mk.*).

These things and some others are seen in the next figure (fig. 3). Outside the foramen magnum (*f.m.*) is seen the occipital condyle (*o.c.*); in front of this the "anterior

condyloid foramen" (9), and then the "foramen lacerum posterius" (8). Crest-like, above the foramen magnum and auditory mass, is the superoccipital cartilage (*s.o.*), ending in front in a sinuous manner, being notched and bulged out by the lateral sinus (*l.c.*). The ear-sac (*au.*) is an ovoidal flattened body, lying obliquely outwards and backwards, with its bored and scooped face on the inner side. The blind recess under the arch of the anterior canal is for the cerebellar process; the antero-inferior spaces are for the compound seventh nerve; the meatus internus has a small cartilaginous bridge in front of it, which passes upwards inside the canal for the portio dura. Between the ear-sac and the small thick alisphenoid (*al.s.*), there is a large shallow fossa for the Gasserian ganglion (5), and the space for the main part of the fifth nerve is merely the great chink between these two parts—the alisphenoid and the ear-sac. Hence in the Pig we see no "foramen ovale," and the "f. rotundum" has no distinctness from the chink between the orbito- and alisphenoids. Most of the alisphenoid is spent in forming the large "external pterygoid process," and its cranial part is small; here it is not the "ala major," as in Man. On the other hand, the "alæ minores" of Man are represented in the Pig by huge wings of cartilage, that spread themselves from the nasal to the auditory regions. This reversal in size of the anterior and posterior wings is like what we see in the Lizard, &c.,—unlike the Bird's skull in this respect, where the orbito-sphenoids are aborted, the alisphenoids huge. As in the Lizard, the Mammalian orbito-sphenoid has a postneural band, which encloses the optic nerve (2) in a complete foramen: this is well developed in the Pig (Plate XXX. fig. 3, *o.s.* 2). In front of the optic nerve the base of this orbital wing is continuous with the trabecular commissure for some extent; the greater part of the so-called presphenoid is, however, trabecular in nature. The olfactory roof and wall extends backwards behind the septum, which graduates into the presphenoid; thus a large rounded notch exists on each side, and the roof of the true olfactory region and floor of the rhinencephalon is soft; through this delicate tissue the olfactory filaments root downwards to the rudimentary upper and middle turbinal septa (*u.tb.*, *m.tb.*). Between the nerve-fibrils cartilage is beginning to appear, and thus a cribriform plate will be formed of secondary cartilage (fig. 3, *cr.p.*). In front of the upper turbinal a rudimentary "nasal turbinal" (*n.tb.*) is formed by bending inwards of the aliseptal cartilage. Lower down this cartilage turns inwards, and develops into the inferior or *anterior* turbinal (*i.tb.*), attached to which in front is the small alinasal turbinal (*al.tb.*).

*Fourth Stage.—Embryo of the Pig, from 2 inches 4 lines to 2 inches 6 lines in length.*

From dissections and sections of embryos not larger than the grub of the honey-bee in the first, we come in this stage to specimens as large as a mouse.

This is an excellent stage for morphological comparison, as the skull may well be placed side by side with that of the adult Osseous and Ganoid Fish, Amphibian and Reptile, and with that of the ripe chick of the Common Fowl. It also corresponds very closely in development with an early stage of the skull of *Balaena japonica*, Lac., excel-

lently illustrated by the late Dr. ESCHRICHT ("Ni Tavler til Oplysning af Hvaldyrenes Bygning, udferte til utrykte Foredrag af afdede Etatsraad Dr. D. F. ESCHRICHT:" Copenhagen, 1869. Edited by Professor REINHARDT, plate ii. figs. 1-3).

The well-marked granular territories that at first invested the primordial skull and face are now largely ossified, and these ossifications are massive in relation to so small a skull. As in the strong-legged "Herbivora" generally, and in the "Aves præcoces," the development before birth and before hatching is very rapid, so that they are strong and in good liking at their first appearance. Moreover, the primordial parts are undergoing endostosis at many points, and from this time the bony metamorphosis takes place very rapidly. If this skull (Plate XXXIV. figs. 1-7) be compared with that of the Bird ("Fowl's Skull," Plate LXXXIV.-LXXXVII.), it will be seen that the premaxillaries (*px.*) do not reach to the end of the snout, instead of projecting beyond it, and they do not send a nasal process between the nasal bones up to the frontal. Here, in the Mammal, the maxillary is by far the largest bone, and, with the linking malar and zygomatic spur of the squamosal, forms a strong subocular arch, one pier of which is formed by the maxillary and reaches near to the nostril, whilst the other pier is formed by the supratemporal and stretches over the auditory capsule to the occiput (Plate XXXIV. fig. 1, *mx., j., z.sq.*). This sigmoid, trilobate temporal (squamosal) bone, besides creeping over the infero-lateral wall of the cranium by its squamous part, clamping the outer wall of the ear-capsule by a long falcate process, and perfecting the great facial yoke (zygoma), also takes in a new relation; it articulates with a well-differentiated *secondary* mandible (*d*). This is distinctively Mammalian; for in the highest Sauropsida (the Bird) the primordial and secondary mandibles have an equal development, and are permanently combined as the free arch of the mandible, the large "pier" of which is merely the hugely developed head, neck, and shoulder of the first mandibular rod. In this stage of the Mammalian skull we catch the equivalence of these primary and investing parts; but the new hinge is formed already, and the primary bar, now at its highest relative development, shows no sign of segmentation into a pier (quadrate) and a free arch (articulo-Meckelian). By the time of birth, the whole of the large succulent rod of cartilage which runs along the inside of the lower jaw (fig. 7, *d., mk., m.*) and coalesces largely with its fellow in front will have shrunk up into a delicate fibrous band, leaving a small bony style (processus gracilis) to the arrested upper part of the rod\*. A bony ring is growing round both the preoral and the first postoral clefts; these are the lacrymal (*l.*) and the tympanic (*ty.*); the first of these has an outer facial development, and is not hidden in the orbit as in Man. The nasal, frontal, and parietal bones (*n., f., p.*) form a regular double series; they are only equivalent to the *inner layer* of the scutes seen in the same region in Ganoid Fishes; yet they are very thick, the thickness depending upon the free development of connective (indifferent) tissue between the cutis and the primordial skull. The fontanelles are still wide open; but

\* In the figure (Plate XXXIV. fig. 7, *d.mk.*) the primary rod is cut through, and the mandible detached from its new hinge these parts will be described more in detail from the figures of sections.

the lower edge of the frontal has sent inwards from its eave a plate which reaches the orbito-sphenoid—the orbital plate. The agreements and the differences seen by comparing the Ornithic and Mammalian skulls are made very evident if this palatal view (Plate XXXIV. fig. 2) be put side by side with the figure of this region in the Ostrich's embryo ("Ostrich's Skull," Phil. Trans. 1866, Plate VII. fig. 4); at this stage the conformity is more remarkable than the difference.

The dental (*d.px.*) part of the pig's premaxillary is broad and filled with tooth-sacs, which deeply groove it; the palatal processes (*pp.x.*) are slender. The approximating maxillaries (*mx.*) do not hide the vomer (*v.*); they are grooved by vessels down the middle of their palatine plate, whilst their dentary portion is hollow and shell-like, containing as it does large growing tooth-germs. The palatines (*pa.*) are *ornithic*, scarcely showing so much of the "hard palate" as a Green Turtle (*Chelone mydas*). The pterygoids (*pg.*) are thin in their ascending part, and are clubbed hooks below; they and the palatines both articulate with the great conjugational "basipterygoid," which here, as in the Ophidia, mainly arises from the alisphenoid; it is, however, formed of true cartilage, as in all the Sauropsida in which it occurs. This part, the "external pterygoid plate" (*e.pg.*), is a pronotochordal secondary structure; it arises at its root from the side of the apex of the trabecula. These apices of this first pair of bars do not project outwards and backwards in the Pig as in the Kitten, nor does the "basitemporal" appear here in rudiment as the "lingula sphenoidalis;" both these, the process and the bone, are exquisitely and most instructively displayed in the Guinea-pig (*Cavia aperea*). The ring on which the tympanic diaphragm is stretched (*ty.*) is at present U-shaped, with its crura pointing backwards, and the larger on the outer and *upper* side; this crus has a flat flange which looks upwards. The vomer has the same relative size as in the embryos of the Ostrich and the Whale ("Ostrich's Skull," Plate VII. fig. 4, *v.* and ESCHRICHT "On the Cetacea," plate ii. fig. 2, *V.*).

In the endoskeletal parts we have to deal with two tissues at once, hyaline cartilage and bone, principally endosteal at present, although rapidly gaining the surface and beginning to affect the perichondrium; I shall describe it first in the dissections and then in the sections. In the side view (Plate XXXIV. fig. 1) the tracts that are hardening in the arch of the occiput are shown; and of these there are five, namely the superoccipital and *two pairs* of exoccipitals (see also fig. 3). Moreover the superoccipital is double, as may be seen in a younger specimen (fig. 4, *s.o.*), but the two patches run into each other in a day or so. The ossification of the exoccipital is remarkable; for within the substance of the massive condyle an epiphysial centre appears, quite distinct at first from the large rambling growth above (figs. 1 & 3, *e.o.*); these two points soon coalesce. The basioccipital (*b.o.*) is best studied in a sectional view (fig. 5), but its form is seen from above and below (figs. 6 & 2); it is spearhead-shaped in outline and thick as to substance; it is fast obliterating the notochord. The newer cartilage which underfloors the pituitary body is rapidly ossifying as basisphenoid (fig. 5, *b.s.*); the form of this centre is seen from below in fig. 2: this is the only bone at present in the posterior



sphenoid. The real harmony between the outstanding bars on each side this bone and the basipterygoid spurs of the Lizard and Ostrich is here clearly shown; whilst the "external pterygoid plate" was only studied in Man (where it is said to be merely a periosteal outgrowth of the "ala major"), its homology with the "Sauropsidan" bar could not be determined; here it is a direct cartilaginous outgrowth of both *base* and *wing*, and its basal origin is from the side of the trabecular apex. Here it articulates with both palatine and pterygoid, being so huge and developed to so great an extent laterally; there (see "Ostrich's Skull," Plate VII. fig. 4, *pg.*, *a.p.*) the pterygoid is wedged in bodily between the basipterygoid spur and the palatine; it is in that memoir called the "anterior pterygoid process" (*a.p.*), and by Professor HUXLEY "basipterygoid" ("On the Classification of Birds," Proc. Zool. Soc. April 11th, 1867, p. 418). There is no special ossification in the confluent trabecular base beneath the orbito-sphenoids (figs. 2 & 5, *p.s.*), and these large wings have no centre over and behind the optic foramen, as in Man (figs. 1, 5, 6, *o.s.*, 2); from these only the whole mass will be leavened. These wings have now coalesced with the lateral ethmoid (*al.e.*) in front, and overlap the auditory capsule (*au.*) behind, exactly as in ESCHRICHT's figure of the embryo of *Balaena japonica* (*op. cit.* plate ii. figs. 1 & 2, *k,mG*). The orbito-sphenoids are now at their highest degree of development (see in third stage, Plate XXXIII. fig. 3, *o.s.*, and in the sixth, Plate XXXV. figs. 1, 3, 4, *o.s.*). In front of these orbito-sphenoidal nuclei there is no endosteal deposit, nor is there any for some time to come in the ear-sacs (*au.*). The bird's-eye view (fig. 6) shows how far, as in the Bird, the great septum of the nasal sacs ("mesoethmoid," continuous perpendicular plate, and septum nasi) continues backward beyond the primary roof (here compare fig. 6 with primordial struthious skull, *op. cit.* Plate VII. fig. 1, *al.e., cr.g., o.s.*). The cribriform plate is now sufficiently advanced on each side of the retral septum of the sacs to be fairly understood; it is a delicate comb-shaped lamina of *secondary* cartilage, with four long "teeth" growing inwards and forwards from its margin or "back;" the long interspaces admit the olfactory filaments. The common outer band does not fill in all the space which forms the floor to these huge rhinencephalic fossæ, but, as in the embryo of the Ostrich and Fowl ("Fowl's Skull," Plate LXXXI. fig. 4, *eth.*), the septum is continued backwards to the verge of the anterior sphenoid, and here, in the Pig, ends in a club-shaped manner.

Between the anterior edge of the orbito-sphenoid (*o.s.*) and the back of the comb-like lamina (figs. 5 & 6, *cr.l.*) there is a considerable membranous space. The bulgings in the olfactory roof (*al.e., al.s.*) are caused, behind, by the upper and middle turbinals, now increasing in complexity, and further forwards by the inferior turbinals. Behind the postneural commissure of the orbito-sphenoid (figs. 5 & 6, *o.s.*) the alisphenoids are obscurely seen (*al.s.*), overshadowed and obscured by the so-called "alæ minores." They have no foramina in their substance, but the cranial nerves root down in front of and behind them; on the upper view the whole of the alæ and the floor of the "sella turcica" are far from the eye, the posterior clinoid wall (*p.cl.*), the end of the investing mass, cropping up high into the cranial cavity. The ear-sacs are seen from without,

within, above, and below (figs. 1, 2, 5, 6, *au.*), but as a mass they are not much changed from the last stage.

In the sectional view (fig. 5) the Eustachian tube (*eu.*) is seen below the basisphenoid (*b.s.*); below the soft palate the ceratohyal (*c.hy.*) is cut through, and along the inside of the lower jaw the primary mandible is seen. This is better shown when dissected out (fig. 7); and now its malleal end is ossified (this part is cut through in fig. 1), whilst, below, the Meckelian commissure is severed, the bars uniting along their anterior fourth. I can only find one osseous centre here in the mandible, the dentary (*d.*); this is found in the rapidly chondrifying nidus, which, like a huge "inferior labial," obliquely overlaps the primary mandible; in Man, according to CALLENDER, there is an osseous centre at the *chin* in MECKEL'S cartilage, and a second splint (splenial) on the inner face of the dentary (see Phil. Trans. 1869, Plate XIII. figs. 6 & 7, p. 170).

A few of the many sections prepared of this stage will now be described, and they will thoroughly explain the structure of the parts which have above been described mainly from *dissections*.

The *first* is through the snout (Plate XXXIV. fig. 8), and shows the arched cartilages, united together in front, which were formed by fusion of the *alæ nasi* with the overbent trabecular horns.

The *second* (Plate XXXIV. fig. 9) is through the *alæ nasi* (*al.n.*), fore part of septum (*s.n.*), alinasal turbinal (*al.tb.*); and the masses with trilobate outline below are the recurrent trabecular horns (*rc.c.*).

The *third* section (Plate XXXIV. fig. 10) shows a curious triradiate cartilage separated from the "*alæ nasi*;" this is the "appendix" (*a.al.n.*); here the trabecular cornua are becoming slenderer.

The *fourth* (Plate XXXIV. fig. 11) shows the same parts further back; here the recurrent process has become a smallish band lying flat on each side of the base of the septum, which is now becoming high, but has not commenced the inferior turbinal fold. The four-winged section, on each side, below the septum and recurrent cartilages is the severed premaxillary (*px.*, see also fig 2).

The *fifth* (Plate XXXIV. fig. 12) is through the middle of the inferior turbinal (*i.tb.*); the pedate section here shows the upper limb coiled on itself, but not the lower at present. The recurrent laminae of the trabecular horns are running even past this point backwards; they are here vertical, and in close relation with the nidus of the scoop-shaped vomer (*v.*)\*. In this section the outer stratum of granular tissue overlying the nasal canals is now ossified as the nasal bones (*n.*), and the mass of tissue overlying the pterygo-palatine bar has become the maxillary (*mx.*), with its deep dental groove and pulps and its palatine plate.

The *sixth* (Plate XXXIII. fig. 4) section is through the solid anterior third of the

\* The relation of these recurrent developments of the trabecular horns to the splints that belong to the first facial arch is of intense interest; I am working out this subject in various groups; it is most complicated in Passerine Birds, "*Ægithognathæ*" (H.). They are evidently formed by the fusion of a "labial" with each trabecular horn. If we add to this the "appendix *alæ nasi*" and the secondary mandible, we get *three pairs* of suctorial cartilages in an ordinary Mammal.

frontals (*f.*), the true olfactory region, and the zygomatic process of the maxillary (*z.mx.*); above this is the overlapping malar or jugal (*j.*) The thick frontal slabs send inwards and downwards an "orbital plate," which clamps the ethmoidal wall; this wall is seen to be separated by a very large space from the fore top of the septum or perpendicular ethmoid (*p.e.*), on each side of which lie the olfactory crura (1), and above these the fore part of the hemispheres (*C 1<sup>a</sup>*). Here we see that the comb-like floor of the olfactory crura (Plate XXXIV. figs. 5, 6, *cr.p.*) is connected with, and is the top of, a system of cartilaginous ingrowths, the upper and middle turbinals (*u.tb.*, *m.tb.*), which, by repeated splitting, as it were, or rather by a process of foliation, is becoming more complex day by day. This section is through the most solid part of the vomer (*v.*), where it is squared below to rest upon the "hard palate" over its median suture; here the palatines are cut through their fore part, where they are thin bony scoops, protecting the outside of the posterior nostril passage. Large tooth-pulps (*t.p.*) are seen above and below, and the lower are in relation to a large dentary groove, the outer wall of which is very massive and the inner a smaller rod: both of these sections are parts of a continuous dentary (*d.*); below the inner bony bar is the Meckelian rod (*mk.*), on each side of the base of the tongue (*tg.*).

The *seventh* section (Plate XXXIII. fig. 5) is through the fore part of the eyeballs (*e.*) and the sphenoidal sinuses (*sp.s.*), the hinder part of the backwardly projected nasal labyrinth. At this point the septum, "perpendicular ethmoid," ends; and the pyriform section seen here, at the posterior end of the large "rhinencephalic fossæ" (see Plate XXXIV. fig. 6, *ol.*, *cr.p.*), is no longer indebted to the inturned nasal roofs for its height, which is due to the upgrowth of the trabecular crests\*. This section is through the most solid part of the palatines (*pa.*), and their interior edge is thickening and growing inwards ready to form their part of the hard palate. Only the malar (*j.*) is seen on the side and below, and mesiad of it is the coronoid process of the lower jaw (*cr.*). MECKEL'S cartilage (*mk.*) is now high up the inside of the jaw, which is here mainly composed of solid hyaline cartilage, the inner cells of which are rapidly proliferating as "osteoblasts." In the root of the tongue (*tg.*) the ceratohyals are seen articulating with the basi- and thyrohyals (*c.hy.*, *b.hy.*, *th.h.*), now one piece of cartilage.

The *eighth* section (Plate XXXIII. fig. 6) is one of the most instructive; it severs the orbito-sphenoids (*o.s.*) where they pass into the presphenoidal trabecular wall close at the back of the sphenoidal sinuses (see also in third stage, Plate XXXII. fig. 1). This is the high part immediately in front of the optic foramina (Plate XXXIV. figs. 1, 5, 6, <sub>2</sub>). The orbito-sphenoids are overlapped above by the frontals (*f.*), and the presphenoid has the end of the vomer (*v.*) beneath it. Here the thin ascending plate of the pterygoid, and its thick "hamular" part, is cut through; the osseous matter is scarcely continuous in the ascending part, and every now and then a separate "mesopterygoid" is developed.

\* If the reader wishes to see an exact counterpart of this structure displayed in the second facial arch or "palato-ptyergoid," it is ready at hand in the skull of the Pelican, where both the preoral arches form a long and solid "commis sure," from which a high crest ascends.

The fore part of the curious thick leaf of cartilage which grows out of the ali- and basisphenoid is here cut through; it is the conjugating process between the first and second preoral arches. Here the zygomatic process of the squamosal (*z.sq.*) overlaps the jugal (*j.*), and here the cartilaginous part of the lower jaw is nearly at its thickest; in the root of the tongue the stylohyals are severed at their junction with the ceratohyals (*c.hy.*).

The *ninth* section (Plate XXXIII. fig. 7) has been made through the orbito-sphenoid (*o.s.*) close in front of the osseous nucleus (see Plate XXXIV. fig. 6, *o.s.*); it has passed down through the low part of the presphenoid, where it is crossed by the optic nerve, and where its territory ends and that of the basisphenoid (*b.s.*) begins.

Hence in this figure we have the alisphenoids (*al.s.*) cut through beneath the orbital wings. At this point the hooked coronoid process is severed at its apex (*cr.*); and outside this is the "squamosal" (*sq.*), with its articular cartilage and "meniscus." Below these the articular and angular part of the lower jaw is shown; it is one mass of hyaline cartilage. MECKEL'S cartilage and the stylohyal are also cut through.

Part of this section is shown from the *right* side (Plate XXXIII. fig. 8), magnified twice as much. Here the three cartilages that form the mandibular hinge are all secondary, and, like the outer ear, suggest a reversion to the labial and opercular cartilages of the Shark.

The *tenth* section (Plate XXXIII. fig. 9) is through the malleal portion of the first preoral arch (*ml.*), the front of the tegmen tympani (*t.ty.*), the long, overlapping, posterior angle of the orbito-sphenoid (*o.s.*), the cochlea (*cl.*), the stylohyal (*st.h.*), and the "occipito-sphenoidal synchondrosis" with its enclosed notochord (*b.o., nc.*).

The *eleventh* section (Plate XXXIII. fig. 10) displays the ampulla of the anterior canal (*a.sc.*), the general cavity of the labyrinth (*vb., cl.*), and the tegmen tympani (*t.ty.*), with a bony eave formed by the squamosal (*sq.*) and roofing over the body of the incus (*i.*). The incus is seen turning up its "long crus" and spreading its *orbicular* apex over the top of the stapes (*st.*), which has been cut through from top to bottom, exposing the *foot-hole*. Below the stapes is the cartilaginous wall of the promontory (*pr.*), and outside this is a continuation of the tympanic cavity, in the outer wall of which is the stylohyal (*ty., st.h.*).

#### *Fifth Stage.—Embryo Pig, 3 inches long.*

This is merely introduced to show the ossification of the "alisphenoids" (Plate XXXIII. fig. 11, *al.s.*), which had not begun in the last, whilst in the next they are one solid mass of bone with the basisphenoid (*b.s.*). Here it will be seen that the posterior sphenoid is much simpler in the Pig than in Man; in the Sheep at this stage I find it simpler still, not being able to discover any median centre; but the two alisphenoids are to be seen becoming pointed below, and growing towards each other; here, then, there appears to be no median piece, and thus the postsphenoid is like the anterior region, in which the orbito-sphenoids themselves fill in the mid region with bone. The contrary takes place in the Rodents; and especially in the Guineapig (*Cavia aperea*)

are the sphenoidal structures complex. As in other Rodents, there is a large presphenoid as well as a basisphenoid; the alisphenoids are ossified from two centres on each side; long "lingular" pedicles are formed by the apices of the trabeculæ, and to these are articulated a pair of long, outstretched falcate bones, the evident counterparts of the "basitemporals" of the Bird. In this animal also the "external pterygoid processes" are *basipterygoids*, and the small pterygoid bone is attached to their apex. Even in the Ruminants these spurs are *basal* in their origin. (For the development of the human sphenoid, see HUXLEY, 'Elem. Comp. Anat.' p. 144.)

*Sixth Stage.—Embryo Pigs, 6 inches long, measured from snout to ischium.*

The head in this stage equals in size that of a Squirrel, but its bones are much more dense. The roof-bones (Plate XXXV. figs. 1–3) are now applied to each other edge to edge by sutures, and in certain places overlapping as squamæ. The "anterior fontanelle" (*fo.*) is still open, but is much lessened; the parietal and occipital bones now form a good "lambdoidal suture." The nasals, frontals, parietals, squamosals, lacrymals, premaxillaries, maxillaries, and malars (*n., f., p., sq., l., px., mx., j.*) are all so far formed as to require but little change of size to fit them for their adult relationships. The palatal region (Plate XXXV. fig. 2) shows a great development of the secondary floor or "hard palate," the palatines themselves being now tied together at the mid line below. The ossification of the cartilaginous skull has advanced greatly; the superoccipital is a large, strong shell of bone, and it is at present separated by a larger tract of cartilage from the exoccipitals than in the last stage (*s.o., e.o.*). The latter have now only one centre, for the epiphysis formed primarily in the substance of the condyle has coalesced with the outer deposit; this is now creeping far down into the substance of the long twisted paroccipital process (*p.oc.*). The basioccipital (*b.o.*) now reaches from the foramen magnum to the spheno-occipital synchondrosis; and in front of it (fig. 2) the basisphenoid is now a thick mass of bone (see also fig. 3, *b.o., b.s.*). The presphenoidal region is hidden below by the vomer (fig. 2, *v.*), but in the section (fig. 3, *p.s.*) it is seen to be largely unossified. The alisphenoids (figs. 3 & 4, *al.s.*) are solidly anchylosed to the median piece; they are larger relatively to the orbito-sphenoids, but are still inferior in size and in place; they largely owe their size, laterally, to the external pterygoid processes (*e.pg.*), for their cranial region is small. The whole orbital wing is much more contracted, relatively (figs. 1, 3, 4, *o.s.*); it has become detached from the ethmoid, and is some distance from the auditory mass. The two centres are completely anchylosed at the mid line, and quite encircling the optic passages (2); below (fig. 3), they are forming the presphenoid.

The remainder of the facial axis and nasal septum is one sheet of solid cartilage; and so also is the complex nasal labyrinth, now much more complex in its turbinal growths and cribriform plate (*u.tb., cr.p.*).

From the intimate impaction of the auditory mass into the sides of the cranium, its osseous centres have caused much confusion; this has, however, been greatest in the

Oviparous Vertebrata, where the fusion of the periotic capsule with the skull proper is the greatest. Here, in the Pig, the bony deposits are formed much as in Man (see HUXLEY, 'Elem. Comp. Anat.' pp. 147-156). A description such as that quoted above serves almost equally well for both types. Looking at the inner face of the capsule (figs. 3 & 4), we see a creeping endosteal patch, which surrounds the "meatus internus," runs under the fore part or apex of the cochlea, and has found its way supero-posteriorly to the junction of the anterior and posterior canals (*a.sc.*, *p.sc.*). Seen from the outside (fig. 5, *pro.*) the same bony tract is seen above and in front of the "fenestra ovalis" (*f.ov.*), below which it forms a sudden hook-like bend, which turns forwards, passing into the tract seen on the inside of the cochlea: this is the "prootic" ossification.

On the inside (fig. 3) a small hook of bone is seen in front of the "foramen lacerum posterius" (8); this is a spur sent round the back of the capsule *from the outside*, and the plate of which it is a process is seen from that aspect (fig. 5, *op.*) covering the most bulbous part of the cochlea, the "promontory" (*pr.*). This is the "opisthotic bone;" it sends forwards and downwards a long hook, which binds behind the hook of the prootic, beneath the apex of the cochlea. Another process of the opisthotic runs between the fenestra ovalis and fenestra rotunda (*f.ov.*, *f.r.*) close in front of the head of the styloid cartilage (*st.h.*). Above the head of the styloid, and below the hinder end of the tegmen tympani, a smaller spatulate scute has appeared; this is the mastoid proper, or "epiotic." Behind this little bone the auditory mass is much contracted in the Pig, this part of the capsule being strongly clamped by the squamosal and impinged upon by the exoccipital (*e.o.*), where it gives off its "paroccipital process" (*p.oc.*). The "epiotic" centre will, moreover, ossify the true mastoid region; although it arises in a more forward position, it is less than that of Man (see HUXLEY, *op. cit.* p. 154, fig. 61, *ep.o.*). In the vertical section (fig. 11) the prootic and opisthotic centres are cut through, each at two places, the first (*pro.*) above the stapes (*st.*) and inside the cochlea (*cl.*), and the opisthotic appears below the stapes and in the substance of the promontory (*pr.*). On the outside the semicircular canals are seen (*a.sc.*, *h.sc.*, *p.sc.*) imbedded in solid cartilage. The structures of the "middle ear" have now acquired their almost full metamorphosis; these are enclosed in a large imperfect ring of bone, the tympanic (figs. 1 & 2, *ty.*). This bone is now becoming very thick, and its breadth has greatly increased; but as yet there is no bony meatus stretching outwards beyond the membrana tympani (*m.t.*). It will be seen in the lower view that there is an additional bone clinging to the inner edge of the tympanic; this wedge and two smaller ossicles which I shall describe in the next stage are the feeble counterparts of the auditory "bullæ" of the "Felidæ" and their congeners\*.

\* On the subject of the auditory "bullæ" of the Carnivora, see Professor W. H. FLOWER's very valuable paper "On the Value of the Characters of the Base of the Cranium in the Classification of the Carnivora" &c., Proc. Zool. Soc., Jan. 14, 1869, p. 4. Whilst Professor HUXLEY's 'Elements' was going through the press, I showed him the bulla of the new-born Lion's whelp, a thin spoon-like lamina of true hyaline cartilage growing outwards from the inferior edge of the opisthotic region. Soon after this, Professor ROLLESTON presented me

In the Pig the bullar ossifications are found in a very soft stroma of connective tissue, and not in thin cartilage; yet that stroma is connected with the outer and lower edge of the opisthotic and prootic regions; it is the membranous floor of this huge air-cell.

The "os bullæ" already developed is seen in section, in its fore part (fig. 11, *o.b.*), a little in front of the auditory capsule, at the edge of the lower limb of the tympanic (*ty.*). The parts of the facial system of cartilages entering into the structure of the middle ear are shown in figs. 1 & 12; the "manubrium mallei" (fig. 1, *mb.*) is now ossified, and so also is the incus (figs. 12, *i.*). The lingual part of the hyoid arch is continued upwards to the epiotic region (figs. 1 & 5, *st.h.*), and behind this flattened rod the portio dura nerve is seen escaping.

The little ceratohyal (*c.hy.*) turns backward to articulate with the basal piece, to which also is attached the thyrohyals (fig. 1, *b.h.*, *t.hy.*); the latter three parts belong to the "third postoral arch."

The ossification of the lower jaw (fig. 1, *d.*) is almost complete, the unossified cartilage being principally condylar.

A series of sections selected from a large number now remain to be described; they will more fully illustrate this stage.

The *first* of these (Plate XXXV. fig. 6) is through the anterior third of the "inferior turbinal;" the pedate lower edge of the "aliseptal" cartilage here is seen to be coiled inwards above and below, the common back of the two coils lying towards the septum (*i.tb.*, *s.n.*). The sudden inbend of the aliseptal lamina higher up is the rudimentary "nasal turbinal" (*n.tb.*); below the septum is the vomer (*v.*), and below this the palatine processes of the premaxillaries are seen (*p.px.*). The nasals (*n.*), the side of the premaxillaries, and maxillaries (*px.*, *mx.*) show very thick in the section. On each side of the vomer the "recurrent apices of the trabecular horns" are still present (*rc.c.*).

The *second* section (fig. 7) is through the complex upper and middle turbinal regions (*u.tb.*, *m.tb.*) and the high part of the perpendicular ethmoid (*p.e.*). The olfactory crura (1) are also cut through as they lie on the cribriform plate (*cr.p.*). This widest part of the true olfactory region is roofed in by very massive frontals (*f.*); the thin lower edge of these bones is the orbital plate. The vomer (*v.*) is here very deep; on each side of it the posterior nares are cut through, and these are protected by the long scoop-shaped processes of the palatines (*pa.*). A part of the maxillary is seen on each side of a large molar tooth with its pulp; and above, the outer piece of bone is the jugal (*j.*).

The *third* section (fig. 8) is through the low part of the perpendicular ethmoid and the end of the cribriform plate, where it overlies the middle turbinal (*m.tb.*) only. The palatines (*pa.*) are here at their fullest development, their scooped portion underlying the end of the nasal wall (*n.w.*), and their subvertical plate sending inwards the palatal part of the hard palate.

---

with the head of a new-born Hyrax; and in this I found a large bulla, ossified separately from the true tympanic "annulus," and evidently formed in a shell of true cartilage.



The *fourth* section (fig. 9) instructs us how the olfactory labyrinth ends, as the sphenoidal sinus, on each side of the presphenoid; and it is seen that the fore edge of the orbito-sphenoids wall in this region, and underprop the thin descending orbital plate of the thick arching frontals (*o.s.*, *f.*). On each side is the eye-socket, and below the presphenoid is the thin part of the vomer (*v.*); the palatines (*pa.*) are here cut through behind the hard palate, and opposite them a section of the malar bone and lower jaw is shown (*j.*, *d.*).

The *fifth* section (fig. 10) brings a number of bones into view; the presphenoidal (trabecular) cartilage is rapidly ossifying from the coalesced orbito-sphenoidal centres (*o.s.*, *p.s.*); beneath this is the vomer (*v.*); and on each side, protecting the hinder nostrils, we see the thin part of the palatine and pterygoid (*pa.*, *pg.*); outside these is the fore-bent wing of bone known as the "external pterygoid plate" (*e.pg.*).

The *sixth* section (fig. 11) is through the postero-external part of the external pterygoid (*e.pg.*); it binds strongly against the inner face of the articular ("glenoid") part of the many-spurred squamosal (*sq.*). Here the basisphenoid is cut through behind the "wings," and the internal carotids mount up here to reach the "circle of WILLIS;" here the two limbs of the tympanic, the "os bullæ," and the stylohyal (*ty.*, *o.b.*, *st.h.*) are cut through. The "glenoid hinge" is here with its meniscus, and the articular region of the lower jaw is still largely cartilaginous beyond the head of the articular surface.

The *seventh* section (fig. 12) is through the lower edge of the parietal (*p.*), and also through the upper and lower edges of the squamosal (*sq.*) above, where it binds upon the mastoid region, and below, where it flanks the long paroccipital process (*p.oc.*). The extremity of the sinuous, creeping tympanic cavity is here seen (*ty.*), and outside it the stylohyal and tympanic (*st.h.*, *ty.*) are severed; below these is a section of the paroccipital spur. Over the incus (*i.*) the horizontal canal is seen, and below the stylohyal the portio dura (*7<sup>a</sup>*). Inside the upper and outer portion of the rambling prootic centre the portio mollis (*7<sup>b</sup>*) is seen streaming in; the inner face of the cochlea has the prootic in its edge, and the outer and lower the opisthotic (*pro.*, *op.*). The basioccipital (*b.o.*) is seen to have a subcrescentic form in section, and the cartilage at the edges of this elegant "basilar plate" will have its outer edge ossified by the exoccipitals.

#### *Seventh Stage.—New-born Pigs.*

Since the last stage the skull has almost doubled its length, and the process of ossification has gone on very rapidly; moreover the form of the entire skull has become much more specialized.

Wishing to limit the illustrations to this paper, I have given but few figures of the preparations made for my own research; but the head at this stage is most easily obtained by those interested in these studies. Moreover the semi-adult condition of the skull, prior to any extensive ankylosis, will be fully illustrated. Besides the finish given to the general form of the skull by the now complete investing bones, the endoskeletal parts are well ossified. The whole of the occipital arch and its paroccipital processes,

and the anterior and posterior sphenoids, are now thoroughly hardened. The "sphenoccipital synchondrosis" is of small extent, very thin, and a scarcely thicker tract of cartilage remains between the posterior and anterior sphenoids; yet these are each a single bone at this stage. The perpendicular ethmoid and septum nasi are still unossified; but the inferior turbinals are almost completely, and the "lateral masses" partially, converted into endosteal bone. The cribriform plate is soft, and so is the snout (Plate XXXVI. fig. 1); but this latter is everywhere burrowed with vessels prior to hardening.

Beneath the skull we see a most compact building together of the palatal, pterygoid, external pterygoid, and tympanic bony pieces; the thick, clubbed "hamular process" of the internal pterygoid is fixed as an undersetter to the solid nut-like tympanic, and dints it as an inturned horn dints the frontal in certain varieties of the Cow; this, however, is only a temporary state of things, and is quite recovered from in the lengthening head and face.

No "interparietals" have been found, adding two bones to the growing superoccipital, as seen in Man; this part, the superoccipital, is now a nearly vertical wall, the parietals finishing the roof above. The lower jaw is well ossified, and is now entirely free from the arrested primordial bar, MECKEL'S cartilage. The three periotic centres have completely ossified the auditory mass, "petrosal" and "mastoid" (Plate XXXVI. fig. 2); and a small bilobate ossicle has appeared in the attached (confluent) head of the stylohyal (*st.h.*). Further down another centre has appeared in the middle of the long rib-like bar, taking up nearly the middle third. The upper piece of bone (formed from two nuclei in the Lamb, and apparently also in the Pig) is called by Professor FLOWER\* the "tympano-hyal," a term it may be well to retain. The rudimentary stylohyal of Man is ossified from the upper centre; for "a centre of ossification appears in the styloid cartilage, and extending upwards and downwards, gives rise to the pyramid and styloid process" (HUXLEY, 'Elem.' p. 160). Hence it will be seen that the tympano-hyal and the *upper* styloid bone are identical; both these bones are largely developed in the Osseous Fish, the so-called "epi- and "ceratohyals;" they occupy the great flat "cornu," at the base of which the short ceratohyal proper, with its two bony centres, is articulated. The unciform ceratohyal ("cornu minor") of the Pig is strongly attached by fibrous tissue to the transverse basal piece (Plate XXXVI. fig. 2, *c.h.*), now coalesced with its own rudimentary arch, the "cornua majora" of Man; these pieces are ossified proximally (fig. 2, *th.h.*), and these centres correspond with the first pair of hypobranchials of the Osseous Fish, the median part answering to the first basibranchial. The "stylo-mastoid foramen" (fig. 2, *s.m.f.*, 7<sup>a</sup>) is seen transmitting the portio dura nerve; and this sends upwards and forwards the "chorda tympani" (7<sup>a</sup>), to which is attached the smallest of the three "ossa bullæ" (*o.b'*); the middle-sized piece is seen in front of the stylohyal (*o.b''*). The rest of the drum-walls being removed and the squamosal, the outer face of the periotic mass shows the three semicircular canals

\* In his valuable little work 'On the Osteology of the Mammalia,' 1870, p. 173.

above (*a.sc.*, *h.sc.*, *p.sc.*) and the cochlea below (*cl.*). The hollowed tegmen tympani (*t.ty.*) has in its hinder recess the head of the incus (*i.*); the recess ends in a round cup-like facet for the short crus of the incus, with its down-turned rounded head; the "acetabulum" for this head is finished, externally, by the squamosal, part of which, having become adherent, is shown in the figure. Below this wall-chamber for the incus is the fenestra ovalis with the enclosed stapes (*f.ov.*, *st.*); the long axis of the oval space and oval base of the stapes is upwards and forwards. The inturned hook of the long crus of the incus is now coupled to the neat head of the stapes by means of an intermediate bone, the "os orbiculare" (*o.ob.*), a special centre developed in the *primary head* of the second postoral bar, which, limpet-like, applied itself to that periotic "bud" which became the stapes, by a process similar to that which detaches the axillary buds in *Lilium tigrinum*. In this figure the malleus is not given; it is shown in fig. 3 (*ml.*). The processus gracilis (*p.gr.*) is reduced to a style, ending in fibrous tissue; the manubrium (*mb.*) is flat and slightly arcuate; the "head," articulated with the incus, is elegantly notched for this purpose, and fits on to the incus by a synovial joint, the miniature of that by which the tibia fits on to the astragalus in this same animal. Between the head and the manubrium the bone is thin, and is scooped externally; the head sends inward a rounded process (*i.p.m.*), and the manubrium sends backwards an angular snag; this latter is for the attachment of the "tensor tympani" muscle. The little *secondary* nucleus of cartilage which we saw developed between the dislocated incus and stylohyal (Plate XXX. figs. 8 & 9, *i.hy.*) is now attached to the neck of the stapes by its broad outer end, whilst its bluntly pointed distal end is buried in the fibres of the tendon of the "stapedius" muscle (*st.m.*). This is the *last* effect of the high degree of metamorphosis exhibited by the second postoral bar of the Mammal. The fore edge of the exoccipital, with its paroccipital spur (fig. 2, *e.o.*, *p.oc.*), is strongly clamped upon the auditory capsule; this is also made still stronger by the large posterior flange of the overgrowing squamosal, not shown in this figure.

The under surface of the snout is also given at this stage, to show the complete coalescence of the alæ nasi with the recurved trabecular horns, and their continuation backwards as the "recurrent laminae" (*rc.c.*), also the alinasal external segment or "appendix." The solid fore end of the snout, already full of small blood-vessels, is ready to become the snout-bone for *rooting*; this bone is formed in the ossified knees of the trabeculae: the stunted, recurved prenasal cartilage is now undistinguishable from the base of the septum nasi, formed by the complete coalescence of a large tract of the trabecular bars, the long commissure of the foremost facial arch.

*Eighth Stage.—The Skull of a Pig 6 months old.*

This makes a more convenient *last* stage than the adult, as here are still in existence the greater number of the sutural landmarks, so soon to be largely obliterated, whilst the change in general form is rather of interest to the zoologist than to the morphologist. The long angular skull (Plate XXXVI. fig. 4, and Plate XXXVII. figs. 1 & 2)

is an irregular pyramid, with two equal and two unequal sides and an oblique base. A complete contrast in outward form to the human skull, that of the Pig is straightest of all the types; it is very angular and strongly built, but its bone-tissue is inferior in density to that of the Sheep, being intermediate in this respect between the bone of a Ruminant and that of a Cetacean. The flat top of the skull, with its orbits flush with the top, indicate the semiaquatic habits of its owner; and the immense depth and squareness of the base of the pyramid is correlative to the high neck and strong shoulders of this type: *leverage* is suggested by every ridge and every snag. Coming back to the morphology of the matter, I may remark that the long straight nasals (Plate XXXVII. fig. 1, *n.*) overlap the snout in front, and only show their edge in the side view. They are articulated by suture along their outer edge with the upper edge of the long premaxillary wedge (*px.*), and for a less extent with the maxillary (*mx.*); they terminate in a transverse line half an inch behind their *maxillary* suture. The frontals (*f.*) together form a somewhat pentagonal plate, divided along the mid line by the sagittal suture. The anterior third is deeply grooved, the grooves issuing from the "infraorbital foramen;" the posterior half of their outer margin is thick, and somewhat raised as the superorbital ridge. There is a large orbital plate (Plate XXXVII. fig. 1) which is bounded behind above by the short arrested postorbital process, and lower down and within by the orbito-sphenoid (*o.s.*). The upper surface of the parietals (*p.*) is of short extent, and divided by the continuation of the sagittal suture; they are greatly pinched in to form the large temporal fossa (*t.f.*); and behind they are somewhat impinged upon by the large superoccipital wall (*s.o.*).

The premaxillaries (Plate XXXVI. fig. 4, and Plate XXXVII. fig. 1, *px.*) have a large facial and a lesser palatine region, the palatine spurs (*p.px.*) being slender and compressed. The huge maxillary (*mx.*), besides forming most of the fore face and the anterior root of the zygoma, by its last tooth-socket (a large pupiform cavity), binds behind upon the external pterygoid plate and descending extremity of the palatine (Plate XXXVII. fig. 1, *mx., pa., e.pg.*). Below (see Plate XXXVI. fig. 4, *mx.*) it forms three fourths of the elegant grooved and ribbed hard palate; the double "posterior palatine foramen" (*p.p.f.*) is partly in this bone and partly in the palatine. The median suture of the hard palate (Plate XXXVI. fig. 4) is two thirds the length of the skull and face. The palatine bones (*pa.*) by their primary ascending plate articulate with the vomer, and send forwards a long scoop-like process beneath the lateral ethmoids. After forming the elegant end of the hard palate they grow downwards as a thick boss, which articulates with the maxillary and external pterygoid process on the outside, and with the internal pterygoid plate on the inside. This latter bone, the "pterygoid" proper (*pg.*), is very thin in its ascending part; and on the right side the uppermost squamous part is a separate piece, the mesopterygoid (Plate XXXVI. fig. 4, *ms.pg.*), a bone not commonly distinct in the Mammalia; yet in my collection it occurs in the Fox (*Canis vulpes*), and is subdistinct in the Hedgehog (*Erinaceus europæus*); here, in the Pig, it is a small triangular scale. The inferior part of the pterygoid is thicker and is subfalcate, the

hooked portion ("hamular process") being the *apex* of the pterygo-palatine arch. The top of the pterygoid, behind the mesopterygoid, has already coalesced with the posterior sphenoid at the root of the "ala," and externally also it is almost completely confluent with the "external plate" (*e.pg.*).

The thin dentate end of the vomer (Plate XXXVI. fig. 4, *v.*) ends at the same transverse line with the mesopterygoids, whilst in front it reaches the fore margin of the premaxillaries within a barleycorn's length. The vomerine plate broadens a little to sit on and articulate with the upturned and dovetailed edge of the palatine plate of the palatine bones, and also with the longer "harmony suture" of the maxillaries; its groove for the trabecular subseptal beam is rather deep. The complex nasal labyrinth is well ossified, but the septum between the inferior turbinals, supplied by the fifth nerve, is still soft. Beneath the large lacrymal, the "lamina papyracea" of the ectoethmoid is just seen beside the pupiform socket of the developing last molar tooth.

The lacrymal (Plate XXXVII. fig. 1, *l.*) is a notable bone on the outer cheek, with an upper and a lower canal; it is deeply scooped where it articulates antorbitally with the orbital plate of the frontal (Plate XXXVII. fig. 1, *l., f.*); it forms part of the anterior root of the zygoma, and is nearly equally developed both within and without the orbit.

The malar or jugal (*j.*) is a massive bar of bone, strongly set in at the front of the orbit between the lacrymal and maxillary (Plate XXXVII. fig. 1, *j., l., m.*). It is saddle-backed in its front thicker part, and its hinder half suddenly becomes only as thick as in front, so that the squamosal may yoke on to it; its lower surface is arcuate, its inner surface scooped, and its outer surface convex: almost an inch of space intervenes between the highest part of the malar and the descending postorbital spur of the frontal. The proper temporal bone, fitting scale-like to the temporal region of the skull, over the hinder edge of the frontal and the lower part of the parietal, is properly called the squamosal (*sq.*). This temporal part turns suddenly outwards to catch the pyriform condyle of the lower jaw, and then runs forwards and rides on the upper edge of the malar, stopping behind the concave portion of that bone. This zygomatic process of the squamosal rises sharp above the transverse "glenoid" bridge, which is scooped above and below, has a convex transverse part in front, and an angular scooping behind: this part is clothed with articular cartilage, and the mandibular condyle rides freely *under* and *up* it, a meniscus intervening.

There is an acute ridge which runs obliquely up to the upper third of the superoccipital (Plate XXXVII. fig. 1, *sq., s.o.*); this rising wall closes in the deep temporal fossa. This ridge of bone, running downwards also, binds strongly upon and coalesces with the rough rounded uplooking mouth of the "meatus auditorius externus" (*m.e.*). Below this part the squamosal splits into two narrow rough leaves; the hinder of these is the "posttympanic process," and the front leaf is the "postglenoidal." The latter binds upon the side of the tympanic (*ty.*), the former runs down the fore edge of the paroccipital (paramastoid) process (*p.oc.*), and scoops its upper third. In front of the

glenoid facet the squamosal is strongly sutured to the alisphenoid (*al.s.*) and to its great expanded wing (*e.pg.*). Together, the zygomatic elements make a strong, deep, and convex arch on each side, which starts rather sharply upwards.

The tympanic (*ty.*), now like a large *filbert* in form and size, although snaggy and ridged below, is principally a mass of square-chambered diploë. It has a small cavity, to the produced edge of which the membrana tympani is attached; and its former "crura" have met, run upwards, and formed the curious, ascending, coral-like meatus.

The flange of the anterior crus is now a squamous process beneath the squamosal, and close to the inner edge of the glenoidal cartilage. As there are no proper "foramina ovalia" in the posterior sphenoid, so there is a continuous "foramen lacerum" round the tympanic, and between it and the basis cranii (Plate XXXVI. fig. 4, *f.l.p.*). Looking through these large chinks we can see a small part of the periotic mass, which is very separate from the surrounding parts. The great occipital plane (Plate XXXVII. fig. 2, *s.o.*, *e.o.*, *b.o.*) is scooped above (*s.o.*), and then the bone bends forwards, wedging itself in between the parietals: the upper element is alate above, and then narrows in and rests obliquely upon the exoccipitals (*e.o.*), forming the keystone of the archway for the medulla spinalis, the foramen magnum (*f.m.*). The arch again expands its sides, the exoccipitals spreading out behind and over the mastoids, which further outwards are plastered over by the "posttympanic processes" of the squamosal. These lateral pieces run downwards as the long paramastoid, or, more correctly, *paroccipital* spurs; whilst their middle region juts out, and forms the diverging, semioval, subpedunculate articular condyles (*oc.c.*). Inside the paroccipital process there is a considerable foramen for the hypoglossal nerve (Plate XXXVI. fig. 4, *9*). In front of the paroccipital process there is a canal, bounded on the outside by the posttympanic spur of the squamosal, and on the inside by the unciform tympanic. Looking up this canal we see that its inner half is occupied by a rod of bone, thickest below, where it is flat, the continuing cartilage being macerated off. This rod is the apex of the stylohyal—"tymano-hyal" (FLOWER), and the open tube is the canal for the portio dura; its mouth is the "stylo-mastoid foramen."

The basioccipital (Plate XXXVI. fig. 4, *b.o.*) is a pentagonal lozenge of bone, joining the sides of its own arch by suture, and separated from the next basal piece (*b.s.*) by a narrow synchondrosis. This basioccipital plate is mammillate at the sides below, and subcarinate mesially: it is the *notochordal* bone. Next in front is the basisphenoid (Plate XXXVI. fig. 4, *b.s.*), now merely the basal part of an inverted arch of bone, the "posterior sphenoid." The narrow cartilaginous tract between this and the bar in front is hidden below by the end of the vomer, and by a sharp ridge which grows mesiad from each alisphenoid (Plate XXXVI. fig. 4, *al.s.*, *b.s.*, *v.*). The orbito-sphenoids have met below, ossifying the underlying trabecular bar, which part is ensheathed by the vomer. These large wings can be seen in the posterior part of the orbit around and above the optic foramen (Plate XXXVII. fig. 1, *o.s.*, *2*), and also from behind through the foramen magnum (Plate XXXVII. fig. 2, *o.s.*, *2*). The change which has taken

place in the little auditory ossicles is too small to require special notice. The mandibular rami (Plate XXXVII. fig. 3) are quite distinct from each other at present: they are large deep bones, with a small notch between the coronoid and articular regions; the latter is somewhat pyriform, with the narrow end inwards; the angular region is flat, with a round outline and a thick rugose edge.

*Ninth Stage.—The Skull in Adult Pigs.*

The further changes that take place in the Pig's skull are mainly increase of size and extensive ankylosis. Besides referring the reader to the actual object, I may mention that a short and useful account of this type of cranium will be found in Professor FLOWER'S work, 'An Introduction to the Osteology of the Mammalia,' 1870, p. 172, and also in Professor HUXLEY'S 'Anatomy of the Vertebrated Animals,' 1871, p. 368.

SUMMARY.

The most important results of the present investigation may be stated as follows:—

1. In a pig embryo, in which the length of the body did not exceed two thirds of an inch, and four postoral clefts were present, the cranio-facial skeleton was found to consist of:—

(a) the notochord, terminating by a rounded end immediately behind the pituitary body.

(b) On each side of the notochord, but below it, a cartilaginous plate, which in front ends by a rounded extremity on a level with the notochord, whilst behind it widens out and ends at the free lower margin of the occipital foramen. These two plates, taken together, constitute the "investing mass" of RATHKE. In this stage they send up no prolongations around the occipital foramen; in other words, the rudiment of the basi-occipital exists, but not that of the exoccipital nor superoccipital.

(c) The large oval auditory capsules lie on each side of the anterior half of the investing mass, with which they are but imperfectly united: there is no indication of the stapes at this stage.

(d) The *trabecular* or first pair of preoral visceral arches enclose a lyre-shaped pituitary space; they are closely applied together in front of this space, and, coalescing, give rise to an azygous prænasal rostrum: they are distinct from one another and the investing mass.

(e) The *pterygo-palatine* or second pair of visceral arches lie in the maxillo-palatine processes, and are therefore subocular in position. Each is a sigmoid bar of nascent cartilage, the incurved anterior end of which lies behind the interior nasal aperture, while the posterior extremity is curved outwards at about the level of the angle of the mouth. The pterygo-palatine cartilages are perfectly free and distinct from the first preoral and the first *postoral* arch, although developed in a process of the latter, and are therefore *secondary* arches.

(f) The *mandibular* or first pair of postoral visceral arches are stout cartilaginous rods of cartilage, which lie in the first visceral arch behind the mouth. The ventral or

distal ends of these arches are not yet in contact; the dorsal or proximal end of each is somewhat pointed and sharply incurved, pushing inwards the membrane which closes the first visceral cleft and is the rudiment of the *membrana tympani*.

(g) The *hyoid* or second pair of postoral arches are in this stage extremely similar to the first pair, with which they are parallel. They are stout sigmoid rods of cartilage, which are separated at their distal ends, present an incurved process at their opposite extremities, and are not segmented.

(h) The *thyrohyal* or third postoral arches, which correspond with the first branchial of branchiate Vertebrata, are represented by two short cartilaginous rods which lie on each side of the larynx.

(i) The olfactory sacs are surrounded by a cartilaginous capsule, which has coalesced below with the trabecula of its side; while, within, the mucous membrane lining the capsule presents elevations which indicate the position of the future turbinal outgrowths of the capsule.

In this stage the posterior nares are situated at the anterior part of the oral cavity, as in the Amphibia; and the roof of the mouth is formed by the floor of the skull, the palatal plates of the maxillæ and palatine bones being foreshadowed by mere folds. The outer end of the cleft between the trabecula and the secondary preoral arch appears to be the rudiment of the lacrymal duct, while its inner end is the hinder nasal aperture. The gape of the mouth is the cleft between the second preoral and the first postoral arch. The auditory passage, representing the Eustachian tube, tympanum, and external auditory meatus, is the cleft between the first and second postoral arches. The proximal end of the mandibular arch, therefore, lies in the front wall of the auditory passage, and the hyoid in its hinder wall.

2. In an embryo pig, an inch in length, (a) the notochord is still visible; (b) the investing mass, the halves of which are completely confluent, has become thoroughly chondrified, and is continued upwards at each side of the occipital foramen to form an arch over it.

(c) The auditory capsules are still distinct from the investing mass, and a plug on the outer cartilaginous wall of each has become marked off as the stapes.

(d) The hinder ends of the trabecular arches have coalesced in front of the pituitary body, but they are not yet confluent with the investing mass.

(e) The pterygo-palatine rods have increased in size; they have not become hyaline cartilage, but are beginning to ossify in their centre.

(f) In the mandibular arch the proximal end has become somewhat bulbous, and is recognizable as the head of the malleus, whilst the incurved process, still more prominent than before, is the *manubrium mallei*. The rest of the arch is MECKEL's cartilage; outside this a mass of tissue appears, which is converted into cartilage, rapidly ossifies, and eventually becomes the ramus of the mandible.

(g) The proximal end of the hyoidean arch, similarly enlarging and articulating with the corresponding part of the mandibular arch, becomes the incus, the incurved process



attaching itself to the outer surface of the stapes and becoming the long process of the incus. The incus, thus formed out of the proximal end of the hyoidean arch, becomes separated from the rest of the arch by conversion of part of the arch into fibrous tissue, and the moving downwards and backwards of the proper hyoid portion of the arch. A nodule of cartilage left in the fibrous connecting band becomes a styloform "interhyal" cartilage, while the proximal end of the detached arch becomes the stylohyal.

(*h*) The thyrohyals have merely increased in size and density; they closely embrace the larynx by their upper ends.

(*i*) The olfactory capsules are well chondrified, and their descending inner edges have coalesced with each other and with the trabeculæ below to form the great median septum: the turbinal outgrowths are apparent.

In this stage the alisphenoids and orbito-sphenoids appear as chondrifications of the walls of the skull, quite independent of the investing mass and the trabeculæ.

The floor of the pituitary space chondrifies independently of the trabeculæ and the moieties of the investing mass, but serves to unite these four cartilaginous tracts.

3. In an embryo pig  $1\frac{1}{3}$  inch in length, (*a*, *b*, *c*) the primordial cranium is completely constituted as a cartilaginous whole, formed by the coalescence of the investing mass and its exoccipital and superoccipital prolongations, the modified trabeculæ, the sub-pituitary cartilage, the auditory capsules, the alisphenoidal and orbito-sphenoidal cartilages, and the olfactory capsules. The notochord is still to be seen extending in the middle line from the hinder wall of the pituitary fossa (now the clinoids of the sella turcica) to the posterior edge of the occipital region.

(*d*) The trabecular arches form the sides of the sella turcica, the presphenoid, and the base of the septum between the olfactory capsules; in front, where they form the azygous prenasal or "basitrabecular" element, they are developed backwards as "recurrent bands," elongations of the free recurved cornua.

(*e*) The pterygo-palatine arches, still increasing in size, but not chondrifying, now rapidly ossify; they are half-coiled laminæ bounding the posterior nasal passages.

(*f*) The mandibular arches and the rudimental ramus have become solid cartilage, and the latter is ossifying as the dentary; the distal part of each mandibular rod unites with its fellow for some distance.

(*g*) The hyoid arches are now more fully segmented as incus, with its orbicular head, interhyal, stylohyal, and ceratohyal.

(*h*) The thyrohyals are merely larger and denser.

(*i*) The olfactory capsules have now the turbinal outgrowths all marked out as alinasal, nasal, upper, middle, and lower turbinals.

4. In pigs of larger size the form and proportions of all the parts of the cranium become greatly altered, and ossification takes place on an extensive scale, but no new structure is added.

5. It follows from these facts that the mammalian skull, in an early embryonic condition, is strictly conformable with that of an Osseous Fish, a Frog, or a Bird at a like period of development, consisting as it does of:—

(a) A cartilaginous basicranial plate embracing the notochord, and stopping, like it, behind the pituitary body.

(b) Paired cartilaginous arches, of which two are preoral, while the rest are postoral.

(c) A pair of cartilaginous auditory capsules.

(d) A pair of cartilaginous nasal capsules.

Further, that in the Mammalia, as in the other Vertebrata the development of the skull of which has been examined, the basicranial plate grows up as an arch over the occipital region of the skull, and coalesces with the auditory capsules, laterally, to give rise to the primordial skeleton of the occipital, periotic, and basisphenoidal regions of the skull. The trabeculae become fused together, and, uniting with the olfactory capsules, give rise to the presphenoidal and ethmoidal parts of the cranium; and the moieties of the skull thus resulting from the metamorphosis of totally different morphological elements become united to give rise to the primordial cranium.

As in the Salmon and Fowl, the second pair of preoral arches give rise to the pterygo-palatine apparatus; in the Frog this arch is late in appearance, and is never distinct from the trabecular and mandibular bars, serving as a conjugational band between them. The mandibular arch, which in the Salmon becomes converted into MECKEL'S cartilage, the os articulare, the os quadratum, and the os metapterygoideum, in the Frog into MECKEL'S cartilage and the quadrate cartilage (which early becomes confluent with the periotic capsule), in the Bird into MECKEL'S cartilage, the os articulare, and the os quadratum (which articulates movably with the periotic capsule), in the Pig is metamorphosed into the malleus, which is loosely connected with the tegmen tympani, an outgrowth of the periotic capsule.

MECKEL'S cartilage persists in the Fish and the Amphibia, but disappears early in the Bird, and still earlier in the Mammal. The permanent ossifications formed outside the primary mandible are all membrane-bones in Fish, Frog, and Fowl, but in the Mammal (exceptionally) the ramus has a cartilaginous foundation. In the Fish the hyoidean arch becomes closely united with the mandibular, and then segmented into the hyomandibular, the stylohyal, ceratohyal, and hypohyal—the hyomandibular or proximal segment articulating with the outer wall of the periotic, and many of the segments becoming dislocated.

In the Frog the hyoid also becomes segmented into three pieces. The middle segment becomes the suprastapedial (hyomandibular) with its extrastapedial process, and, extending inwards as mediostapedial, articulates with the stapes, developed by segmentation from the outer wall of the auditory capsule, the proximal part, or interstapedial, intervening. The stylohyal is dislocated and becomes connected with the auditory capsule below the stapes (opisthotic region).

In the Bird the hyoidean arch remains distinct from the mandibular; whilst in its primordial condition it coalesces by its incurved apex with the auditory capsule in front of the promontory, before the stapedial plug is segmented. It then chondrifies as three distinct cartilages—an incudal, a stylohyal, and, distally, a ceratohyal. The stapes becomes free from the auditory capsule, but remains united with the cartilaginous part

of the incus (mediostapedial); the ascending part is largely fibrous (suprastapedial), and the part loosely attached to the mandibular arch is the elongated extrastapedial. The short stylohyal afterwards coalesces with the body of the upper or incudal segment by an aftergrowth of cartilage (the "interhyal" tract); a long membranous space intervenes between it and the glossal piece (ceratohyal). Thus the "columella" of the Bird is formed of three hyoidean and one periotic segment.

In the Pig the hyoidean arch is distinct, but articulates closely with the mandibular; its upper segment (hyomandibular) is converted into the incus, and becomes connected with the stapes, its disciform apex being ossified as the "os orbiculare." The stylohyal is dislocated and coalesces with the opisthotic region of the auditory capsule.

The views which have hitherto been entertained respecting the mode of development of the *ossicula auditus* of the Mammalia fall under four heads:—

1. According to REICHERT\*, the malleus and incus both result from the metamorphosis of the cartilaginous skeleton of the mandibular arch, while the stapes proceeds from an after segment of the hyoidean arch, which becomes separated and imbedded in the outer wall of the auditory capsule.

The latest writer on the subject, SEMMER†, supports REICHERT'S views in the main, but is not quite sure about the origin of the stapes.

2. GÜNTHER‡ holds that not only the malleus and the incus, but the stapes as well, are the product of the metamorphosis of the skeleton of the mandibular arch.

3. MAGITOT and ROBIN§, on the other hand, maintain that the malleus only takes its origin from the skeleton of the mandibular arch. They consider the incus and stapes to arise independently, but do not expressly refer them to the skeleton of the second postoral visceral arch.

4. Professor HUXLEY||, arguing from the anatomy of the mandibular and hyoidean arches in the lower Vertebrata, has put forward the view that the malleus of the Mammalia is the product of the metamorphosis of the proximal end of the cartilaginous skeleton of the mandibular arch, while the incus proceeds from the proximal end of the hyoidean arch, and is the homologue of the "suprastapedial" of the *Sauropsida*. He expresses no opinion respecting the origin of the stapes.

\* "Ueber die Visceralbogen der Wirbelthiere," MÜLLER'S Archiv, 1837.

† Untersuchungen über die Entwicklung der Meckel'schen Knorpels und seiner Nachbargebilde. Dorpat, 1872.

‡ Beobachtungen über die Entwicklung des Gehörorgans bei Menschen und höheren Säugethieren. Leipzig, 1842.

§ "Mémoire sur un organe transitoire de la oie fœtale désigné dans le nom cartilage de MECKEL," Annales des Sciences Naturelles, sér. 4, i., xviii. 1862.

|| "On the Representatives of the Malleus and the Incus of the Mammalia in the other Vertebrata," Proceedings of the Zoological Society, 1869.

## EXPLANATION OF ABBREVIATIONS.

<i>a.a.n.</i> appendix alæ nasi.	<i>i.c.</i> internal carotid artery.
<i>a.cl.</i> anterior clinoid wall.	<i>i.hy.</i> interhyal.
<i>al.e.</i> aliethmoid.	<i>i.n.</i> inner nostril.
<i>al.n.</i> alinasal.	<i>i.p.m.</i> internal process of malleus.
<i>al.s.</i> alisphenoid.	<i>i.tb.</i> inferior turbinal.
<i>al.tb.</i> alinasal turbinal.	<i>iv.</i> investing mass.
<i>aq.v.</i> aqueduct of the vestibule.	<i>j.</i> jugal.
<i>a.sc.</i> anterior semicircular canal.	<i>j.v.</i> jugular vein.
<i>a.ty.</i> annulus tympanicus.	<i>l.</i> lacrymal.
<i>au.</i> auditory sac.	<i>l.c.i.</i> long crus of incus.
<i>b.a.</i> basilar artery.	<i>l.c.r.</i> lateral cerebellar recess.
<i>b.br.</i> basibranchial.	<i>l.l.</i> lower lip.
<i>b.h.</i> , <i>b.hy.</i> basihyal.	<i>lp.</i> lip.
<i>b.o.</i> basioccipital.	<i>l.s.</i> lateral sinus.
<i>b.s.</i> basisphenoid.	<i>l.v.</i> larynx.
<i>b.tr.</i> basitrabecula.	<i>m.</i> mouth.
<i>c.a.</i> concha auris.	<i>mb.</i> manubrium mallei.
<i>c.c.</i> common (auditory) canal.	<i>mc.</i> meniscus.
<i>c.h.</i> , <i>c.hy.</i> ceratohyal.	<i>m.e.</i> meatus externus.
<i>cl.</i> cochlea.	<i>m.eth.</i> mesethmoid.
<i>cl.</i> 1, 2, &c. 1st, 2nd, and following visceral clefts*.	<i>mk.</i> MECKEL's cartilage.
<i>cr.</i> coronoid process of mandible.	<i>mk.c.</i> Meckelian commissure.
<i>ct.</i> cutis.	<i>ml.</i> malleus.
<i>c.tr.</i> cornua trabeculæ.	<i>mn.</i> mandible.
<i>C</i> 1. thalamencephalon.	<i>m.n.</i> middle nostril.
<i>C</i> 1 <sup>a</sup> . hemisphere.	<i>m.ob.</i> medulla oblongata.
<i>C</i> 2. 2nd cerebral vesicle.	<i>ms.pg.</i> mesopterygoid.
<i>C</i> 3. 3rd cerebral vesicle.	<i>m.tb.</i> middle turbinal.
<i>d.</i> dentary.	<i>m.tr.</i> middle trabecula.
<i>d.pa.</i> dentary part of premaxillary.	<i>m.ty.</i> membrana tympani.
<i>e.</i> eyeball.	<i>mx.</i> maxillary.
<i>ep.</i> epiotic.	<i>mx.p.</i> maxillo-palatine.
<i>e.n.</i> external nostril.	<i>n.</i> nasal.
<i>e.o.</i> exoccipital.	<i>n.w.</i> nasal wall.
<i>e.pg.</i> external pterygoid plate.	<i>o.b.</i> os bullæ.
<i>eu.</i> Eustachian tube.	<i>occ.</i> occipital condyle.
<i>f.</i> frontal.	<i>œ.</i> œsophagus.
<i>f.l.p.</i> foramen lacerum posterius.	<i>ol.</i> olfactory sac.
<i>f.m.</i> foramen magnum.	<i>o.ob.</i> os orbiculare.
<i>f.ov.</i> fenestra ovalis.	<i>os.</i> orbito-sphenoid.
<i>f.r.</i> fenestra rotunda.	<i>o.v.</i> ophthalmic vein.
<i>h.br.</i> hypobranchial.	<i>p.</i> parietal.
<i>h.sc.</i> horizontal semicircular canal.	<i>pa.</i> palatine.
<i>hy.</i> hyoid.	<i>p.e.</i> perpendicular ethmoid.

\* These may be counted from the lacrymal or first preoral, or from the tympanic or first postoral.

*pg.* pterygoid.  
*p.gr.* processus gracilis.  
*p.n.* prenasal cartilage.  
*p.n.w.* posterior nasal wall.  
*p.oc.* paroccipital.  
*p.p.f.* posterior palatine foramen.  
*p.pg.* palato-ptyergoid.  
*p.p.* palatine floor of palatine.  
*p.px.* palatal part of premaxillary.  
*pr.* promontory.  
*pro.* prootic.  
*ps.* presphenoid.  
*p.sc.* posterior semicircular canal.  
*py.* pituitary body.  
*re.c.* recurrent cartilages.  
*s.c.i.* short crus of incus.  
*s.m.f.* stylo-mastoid foramen.  
*s.n.* septum nasi.  
*so.* supero-occipital.  
*s.pa.* soft palate.  
*sp.s.* sphenoidal sinus.  
*sq.* squamosal.  
*s.t.* sella turcica.  
*st.* stapes.  
*st.h.* stylohyal.  
*st.m.* stapedius muscle.

*t.c.* tympanic cavity.  
*t.cb.* tentorium cerebelli.  
*t.f.* temporal fossa.  
*tg.* tongue.  
*th.h.* thyrohyal.  
*t.p.* tooth-pulp.  
*tr.* trabecula.  
*tr.cm.* trabecular commissure.  
*t.ty.* tegmen tympani.  
*ty.* tympanic.  
*u.l.* upper lip.  
*u.tb.* upper turbinal.  
*v.* vomer.  
*vb.* vestibule.  
*z.ma.* zygomatic process of maxillary.  
*z.sq.* zygomatic process of squamosal.  
 1. olfactory nerve.  
 2. optic nerve.  
 5<sup>a</sup>. ophthalmic nerve.  
 5<sup>b</sup>. main part of 5th nerve.  
 7<sup>a</sup>. portio dura.  
 7<sup>a'</sup>. chorda tympani.  
 7<sup>b</sup>. portio mollis.  
 8<sup>a</sup>. glossopharyngeal.  
 8<sup>b</sup>. vagus.  
 9. hypoglossal.

## DESCRIPTION OF THE PLATES.

## PLATE XXVIII.

*First Stage.*—*Embryo Pig,  $\frac{2}{3}$  inch in length.*

- Fig. 1. Side view of upper part of embryo.  $\times 7$  diameters.  
 Fig. 2. A plan of the same, with facial arches.  $\times 7$  diameters.  
 Fig. 3. A front view of the same.  $\times 7$  diameters.  
 Fig. 4. A palatal view of the same, with the mandible and lower face removed.  $\times 15$  diameters.  
 Fig. 5. A plan of the skull and face, seen from below.  $\times 10$  diameters.  
 Fig. 6. A vertical section of the head.  $\times 10$  diameters.  
 Fig. 7. Part of the same, with median part of nasal region removed.  $\times 20$  diameters.  
 Fig. 8. Upper view of a horizontal section of the head.  $\times 10$  diameters.

## PLATE XXIX.

- Fig. 1. Transversely vertical section of the nose, in front.  $\times 12$  diameters.  
 Fig. 2. A similar section through the middle of the nasal region.  $\times 12$  diameters.  
 Fig. 3. Another section through the posterior nasal region.  $\times 12$  diameters.

- Fig. 4. Horizontal section below the cranial cavity, exposing first arch, notochord, and investing mass.  $\times 10$  diameters.
- Fig. 5. A subhorizontal section through the eyes and root of tongue.  $\times 10$  diameters.
- Fig. 6. Part of the head, with outer part of cheek pared away.  $\times 12$  diameters.
- Fig. 7. A section made through the plane of the hinder part of cranium.  $\times 12$  diameters.
- Fig. 8. Part of same section.  $\times 20$  diameters.
- Fig. 9. A similar section.  $\times 26$  diameters.
- Fig. 10. Another subhorizontal section through the top of the first postoral cleft.  $\times 20$  diameters.

## PLATE XXX.

*Second Stage.—Embryo Pig, 1 inch long.*

- Fig. 1. Section across the end of the snout.  $\times 10$  diameters.
- Fig. 2. Section through ethmoid region, root of tongue, and larynx.  $\times 12$  diameters.
- Fig. 3. Section nearly in plane of the notochordal region, front view.  $\times 10$  diameters.
- Fig. 4. A similar section, lower down.  $\times 10$  diameters.
- Fig. 5. Part of a similar section through apex of mandibular arch, front view.  $\times 15$  diameters.
- Fig. 6. A similar section through apex of next arch, front view.  $\times 15$  diameters.
- Fig. 7. Another similar section through periotic capsule in plane of horizontal canal.  $\times 10$  diameters.

*Third Stage.—Embryo Pig,  $1\frac{1}{3}$  inch long.*

- Fig. 8. Part of a section through top of second postoral arch, corresponding with fig. 6 of second stage, front view.  $\times 15$  diameters.
- Fig. 9. Side view of the three postoral arches.  $\times 15$  diameters.

## PLATE XXXI.

*Third Stage (continued).*

- Fig. 1. 1st section through nasal region.  $\times 7\frac{1}{2}$  diameters.
- Fig. 2. 2nd section of same.  $\times 7\frac{1}{2}$  diameters.
- Fig. 2<sup>a</sup>. Part of fig. 2.  $\times 22\frac{1}{2}$  diameters.
- Fig. 3. 3rd section of same.  $\times 7\frac{1}{2}$  diameters.
- Fig. 3<sup>a</sup>. Part of same section.  $\times 22\frac{1}{2}$  diameters.
- Fig. 4. 4th section of same.  $\times 7\frac{1}{2}$  diameters.
- Fig. 5. 5th section of same.  $\times 7\frac{1}{2}$  diameters.
- Fig. 6. 6th section of same.  $\times 7\frac{1}{2}$  diameters.
- Fig. 6<sup>a</sup>. Part of fig. 6.  $\times 20$  diameters.
- Fig. 7. 7th section of nasal region.  $\times 7\frac{1}{2}$  diameters.
- Fig. 7<sup>a</sup>. Mandibular portion of same section.  $\times 7\frac{1}{2}$  diameters.

- Fig. 8. 8th section of same.  $\times 7\frac{1}{2}$  diameters.  
 Fig. 8<sup>a</sup>. Mandibular portion of same section.  $\times 7\frac{1}{2}$  diameters.  
 Fig. 9. 9th section of nasal region.  $\times 7\frac{1}{2}$  diameters.  
 Fig. 10. 10th section of same.  $\times 7\frac{1}{2}$  diameters.  
 Fig. 11. 11th section of same.  $\times 7\frac{1}{2}$  diameters.  
 Fig. 12. 12th section of same.  $\times 7\frac{1}{2}$  diameters.  
 Fig. 13. 13th section of same, head.  $\times 7\frac{1}{2}$  diameters.  
 Fig. 14. 14th section of same, head.  $\times 7\frac{1}{2}$  diameters.  
 Fig. 14<sup>a</sup>. Part of fig. 14.  $\times 14$  diameters.

## PLATE XXXII.

*Third Stage (continued).*

- Fig. 1. 15th section of same, head.  $\times 7$  diameters.  
 Fig. 2. 16th section of same, head.  $\times 7$  diameters.  
 Fig. 3. 17th section of same, head.  $\times 7$  diameters.  
 Fig. 4. 18th section of same, head.  $\times 7$  diameters.  
 Fig. 5. 19th section of same (part back view).  $\times 14$  diameters.  
 Fig. 6. 20th section of same, head (back view).  $\times 10$  diameters.  
 Fig. 7. 21st section of same (part back view).  $\times 14$  diameters.  
 Fig. 8. 21st part of section (front view).  $\times 14$  diameters.  
 Fig. 9. Hinder part of a section taken *horizontally* through the nasal region (front view).  
 $\times 10$  diameters.  
 Fig. 10. A similar section of same taken further backwards and lower down (back view).  
 $\times 10$  diameters.

## PLATE XXXIII.

*Third Stage (continued).*

- Fig. 1. 22nd section of the same head (part seen from the front).  $\times 14$  diameters.  
 Fig. 2. Vertical section of head.  $\times 5$  diameters.  
 Fig. 3. The same, with brain and septum nasi removed.  $\times 5$  diameters.

*Fourth Stage.—Embryo Pig,  $2\frac{1}{2}$  inches long.*

- Fig. 4. Vertically transverse section through fore part of brain.  $\times 5$  diameters.  
 Fig. 5. A similar section through fore part of orbit (part).  $\times 5$  diameters.  
 Fig. 6. A like section through hind part of orbit (part).  $\times 5$  diameters.  
 Fig. 7. A similar section through sphenoid (part).  $\times 5$  diameters.  
 Fig. 8. Part of same section (right side).  $\times 14$  diameters.  
 Fig. 9. A similar section through the fore part of auditory sac.  $\times 7$  diameters.  
 Fig. 10. Another section through hinder part of same.  $\times 14$  diameters.

*Fifth Stage.—Embryo Pig, 3 inches long.*

- Fig. 11. Section through posterior sphenoid.  $\times 3\frac{1}{2}$  diameters.

## PLATE XXXIV.

*Fourth Stage (continued).*

- Fig. 1. Side view of skull.  $\times 3\frac{1}{2}$  diameters.  
 Fig. 2. Lower view of same.  $\times 3\frac{1}{2}$  diameters.  
 Fig. 3. End view of same.  $\times 3\frac{1}{2}$  diameters.  
 Fig. 4. Upper occipital region of a somewhat younger embryo.  $\times 3\frac{1}{2}$  diameters.  
 Fig. 5. Section of skull (vertical).  $\times 3\frac{1}{2}$  diameters.  
 Fig. 6. Bird's-eye view of primordial skull.  $\times 3\frac{1}{2}$  diameters.  
 Fig. 7. Inner view of compound mandible.  $\times 3\frac{1}{2}$  diameters.  
 Fig. 8. 1st section through nasal region.  $\times 7$  diameters.  
 Fig. 9. 2nd section of same part.  $\times 7$  diameters.  
 Fig. 10. 3rd section through nose.  $\times 7$  diameters.  
 Fig. 11. 4th section of same.  $\times 7$  diameters.  
 Fig. 12. 5th section through inferior turbinal.  $\times 7$  diameters.

## PLATE XXXV.

*Sixth Stage.—Embryo Pig, 6 inches long.*

- Fig. 1. Side view of skull.  $\times 1\frac{1}{2}$  diameter.  
 Fig. 2. Lower view of same.  $\times 1\frac{1}{2}$  diameter.  
 Fig. 3. Vertical section of same.  $\times 1\frac{1}{2}$  diameter.  
 Fig. 4. Bird's-eye view of primordial skull.  $\times 1\frac{1}{2}$  diameter.  
 Fig. 5. Outer view of occipital and auditory regions.  $\times 2$  diameters.  
 Fig. 6. Transversely vertical section through inferior turbinals.  $\times 3$  diameters.  
 Fig. 7. Another through ethmoids.  $\times 3$  diameters.  
 Fig. 8. Part of section through hinder part of nasal labyrinth.  $\times 3$  diameters.  
 Fig. 9. Section through orbits.  $\times 2$  diameters.  
 Fig. 10. Part of section through anterior sphenoid.  $\times 3$  diameters.  
 Fig. 11. Section through hinge of lower jaw.  $\times 2$  diameters.  
 Fig. 12. Section through petrotic mass and basioccipital.  $\times 3$  diameters.

## PLATE XXXVI.

*Seventh Stage.—Pig at birth.*

- Fig. 1. Under view of snout-cartilages.  $\times 5$  diameters.  
 Fig. 2. Auditory capsule, hyoid, and occiput.  $\times 3\frac{1}{2}$  diameters.  
 Fig. 3. Auditory chain of bones.  $\times 5$  diameters.

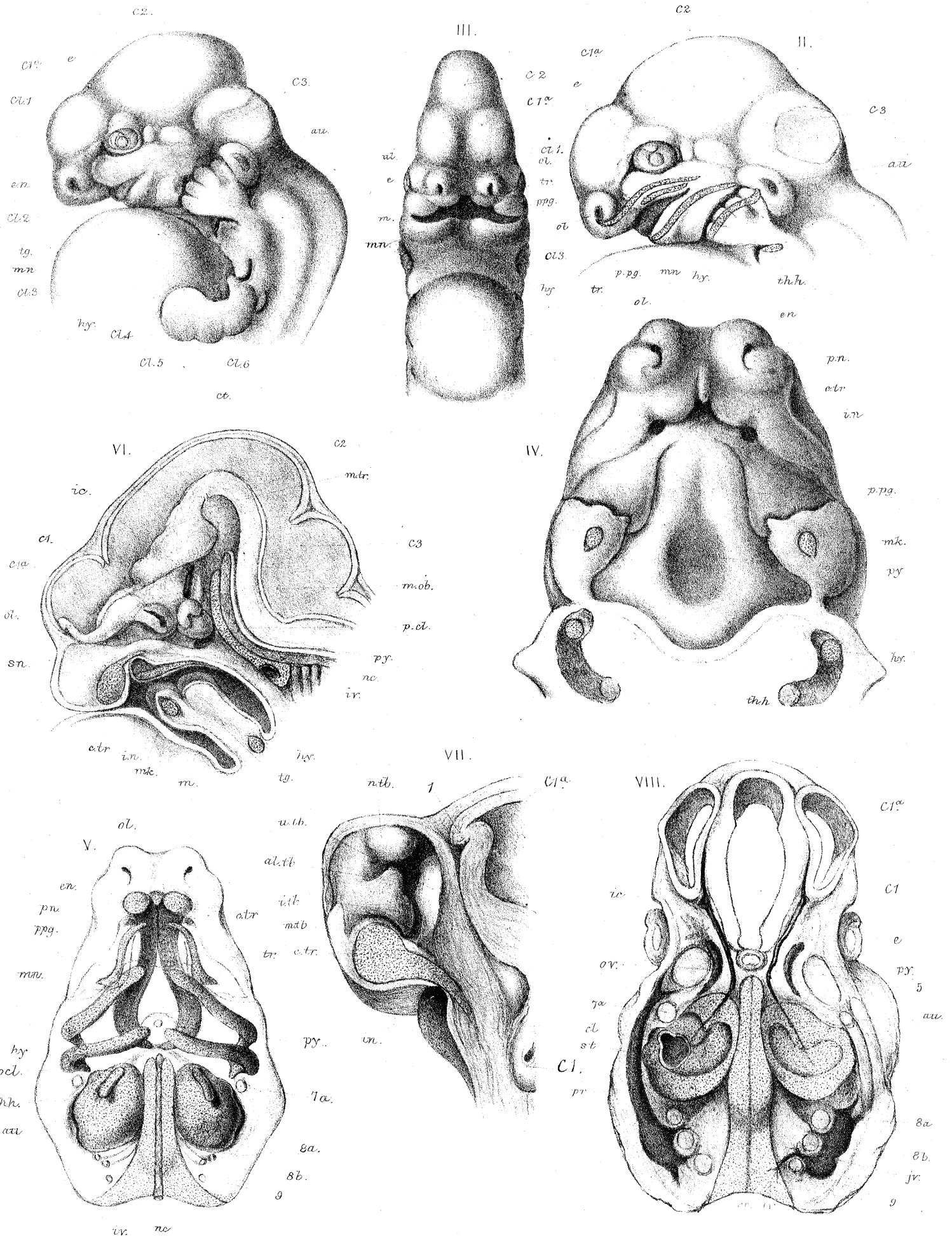
*Eighth Stage.—Pig, 6 months old.*

- Fig. 4. Lower view of skull. Natural size.

## PLATE XXXVII.

- Fig. 1. Side view of same. Natural size.  
 Fig. 2. End view of same. Natural size.  
 Fig. 3. Side view of lower jaw. Natural size.

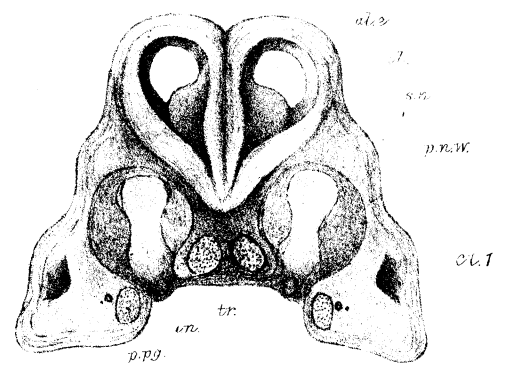
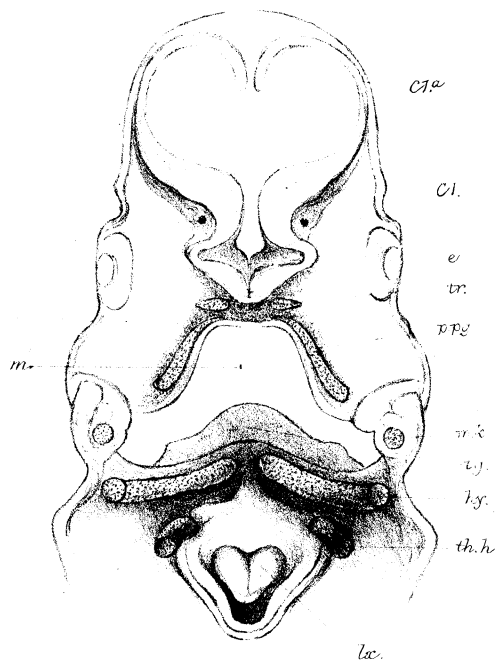
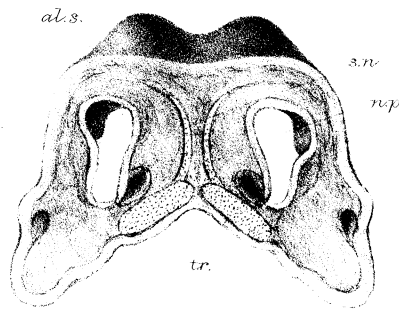




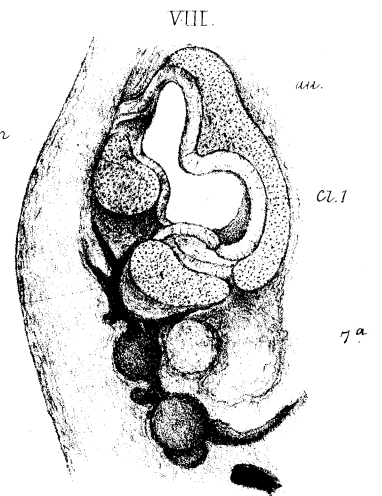
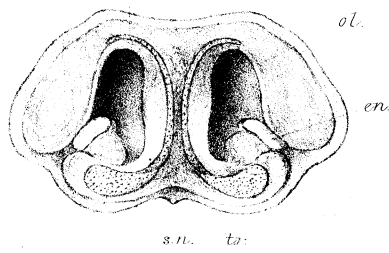
II.

V.

III.



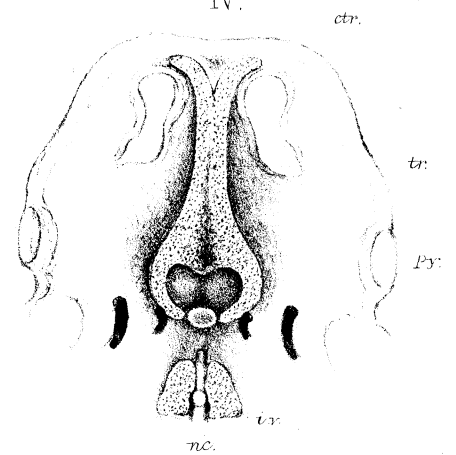
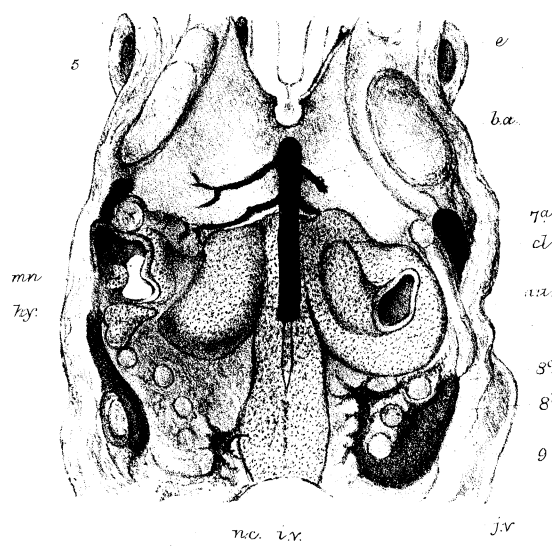
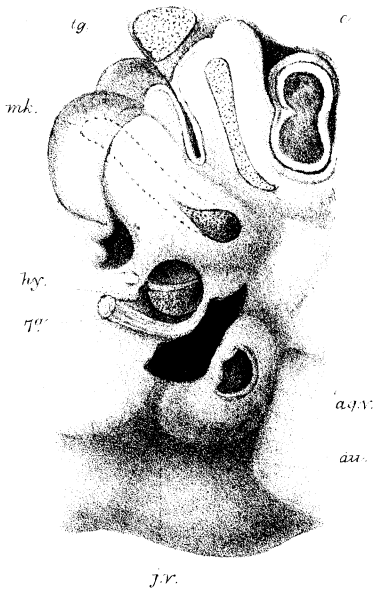
I.



VI.

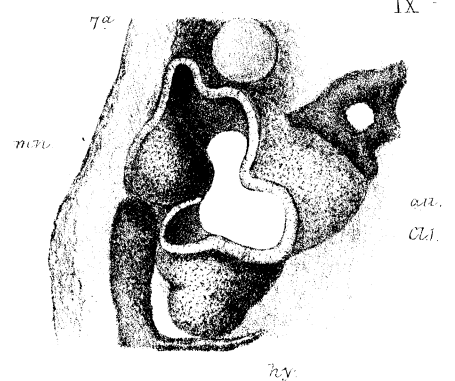
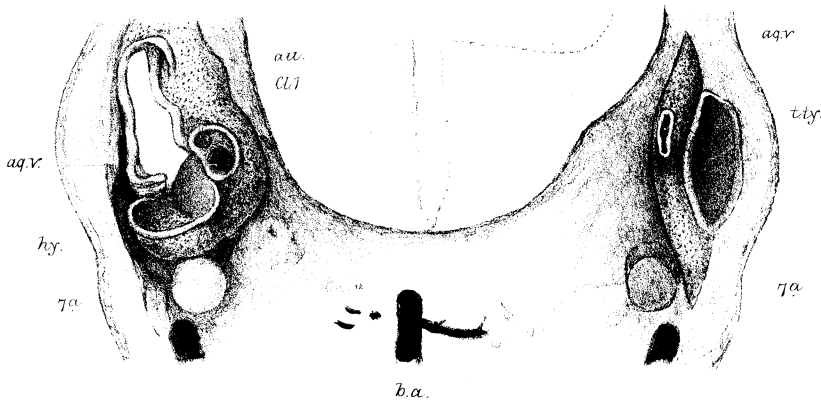
VII.

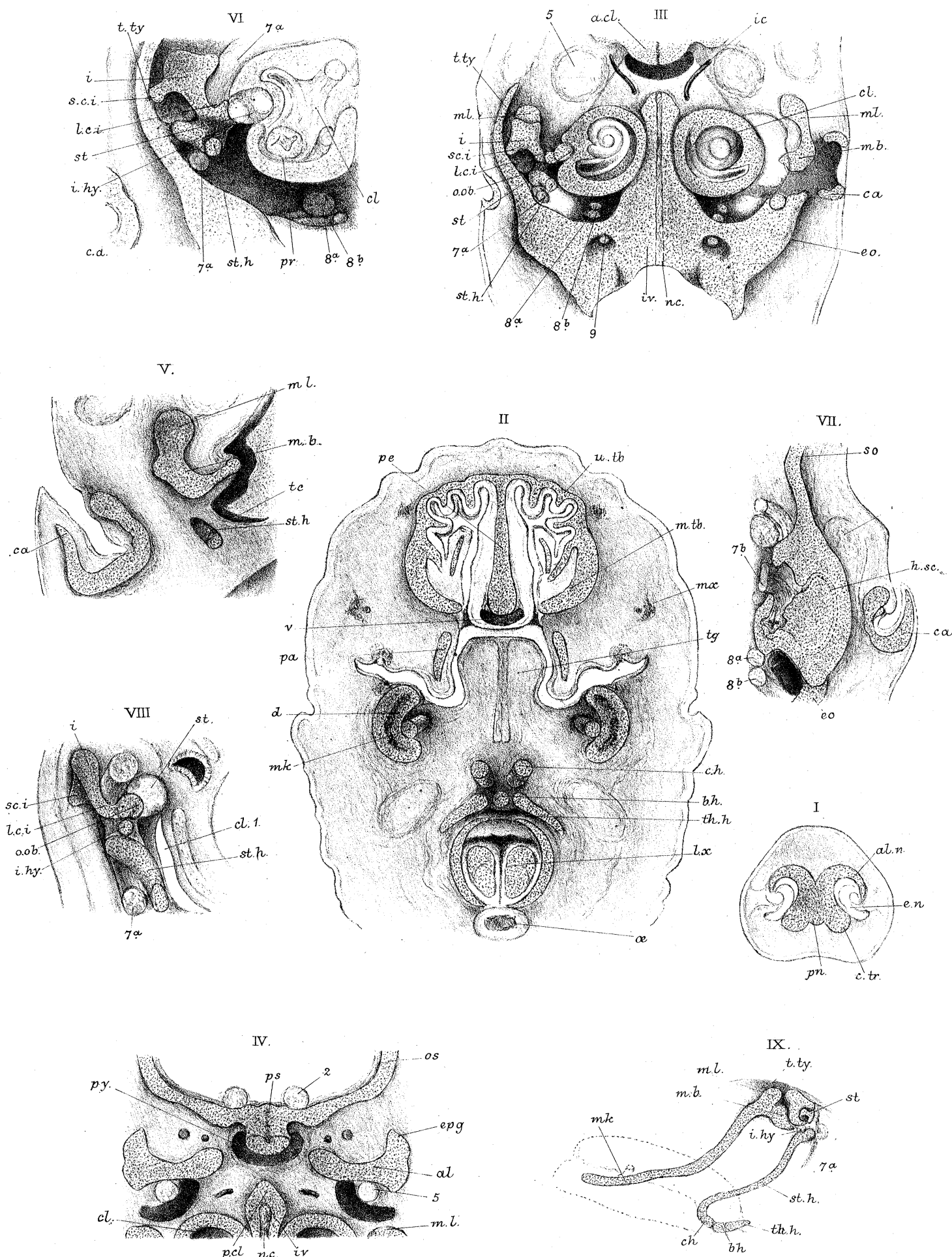
IV.



X.

IX.

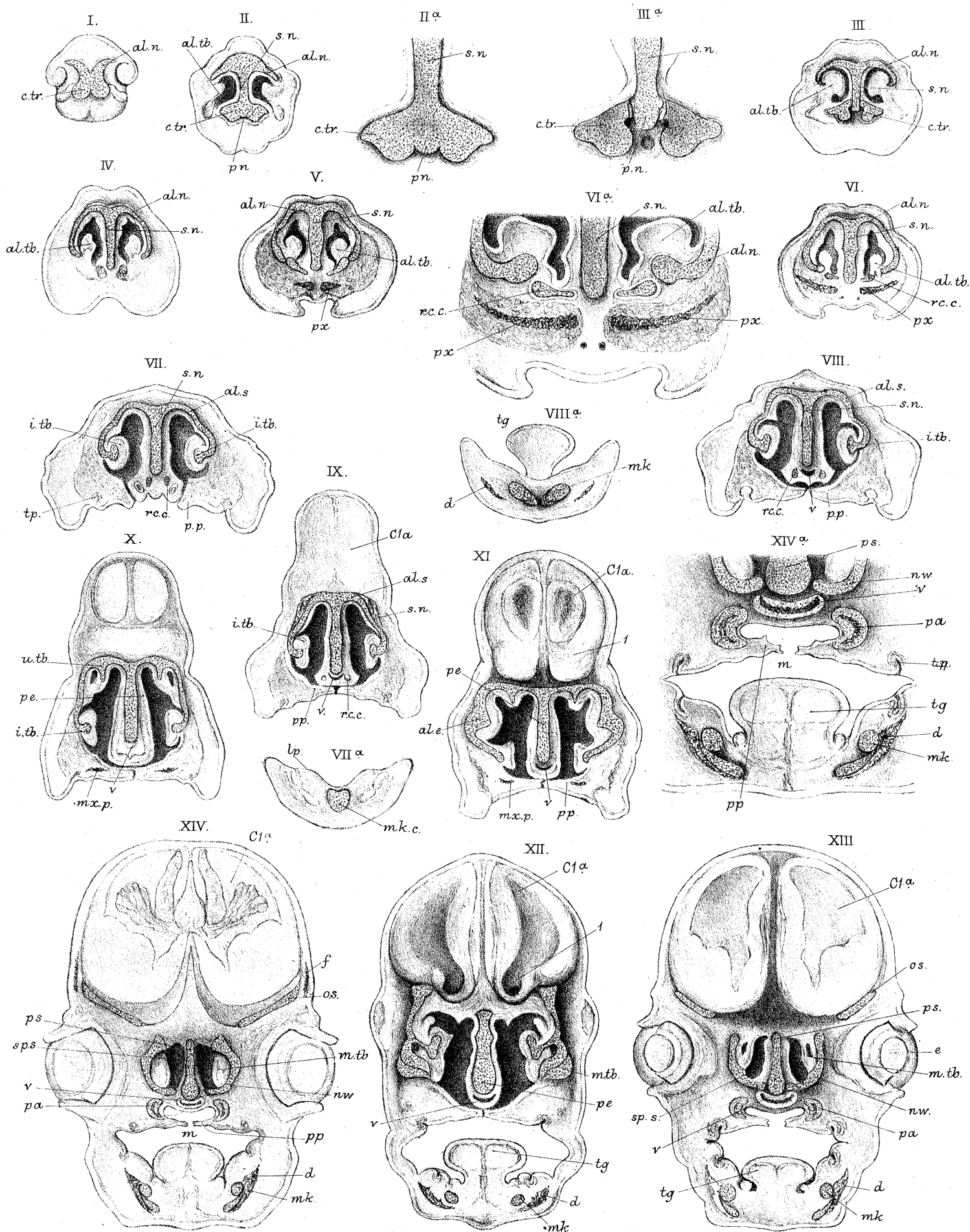




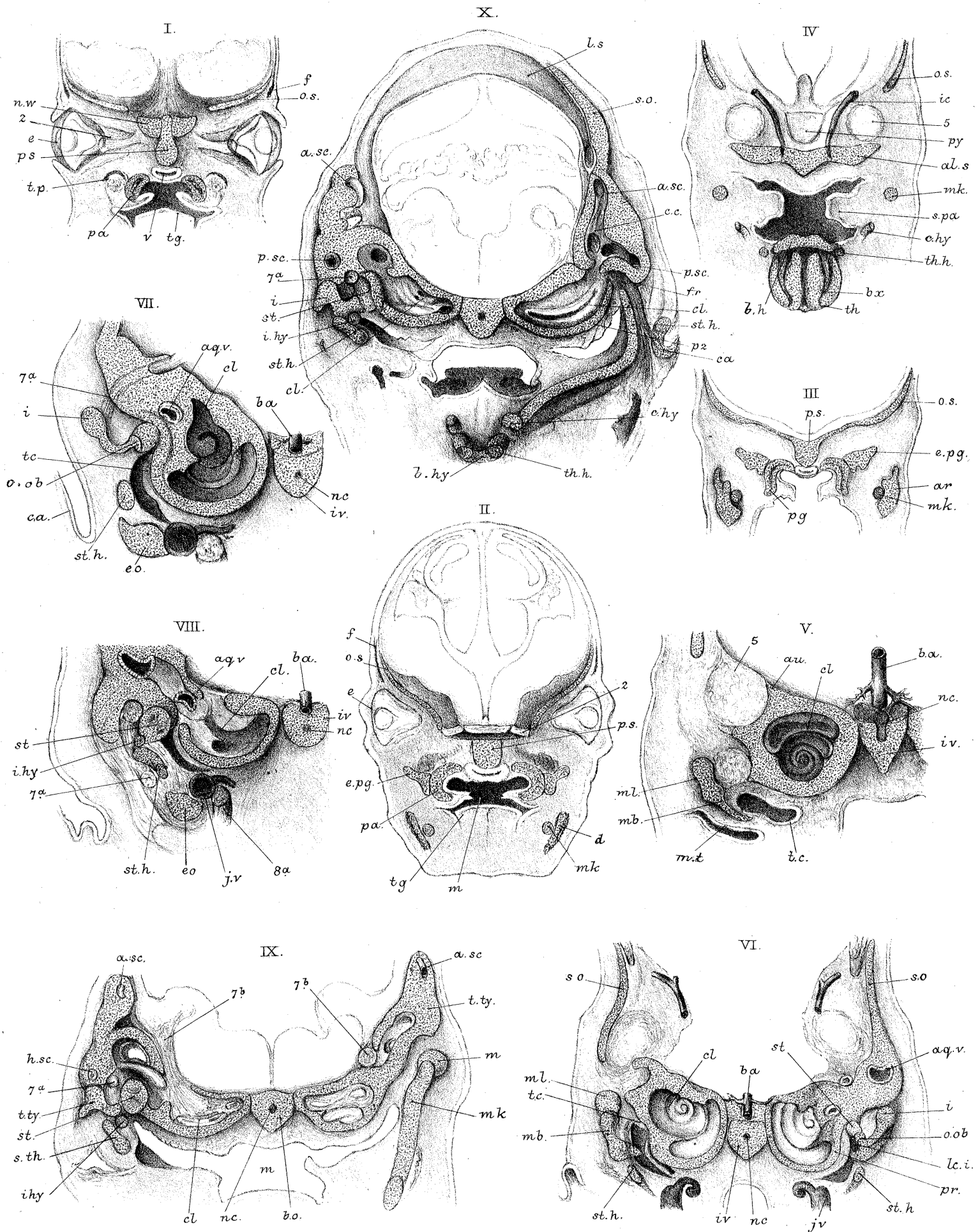
W.K.P. del. ad. nat. Geo. West lith.

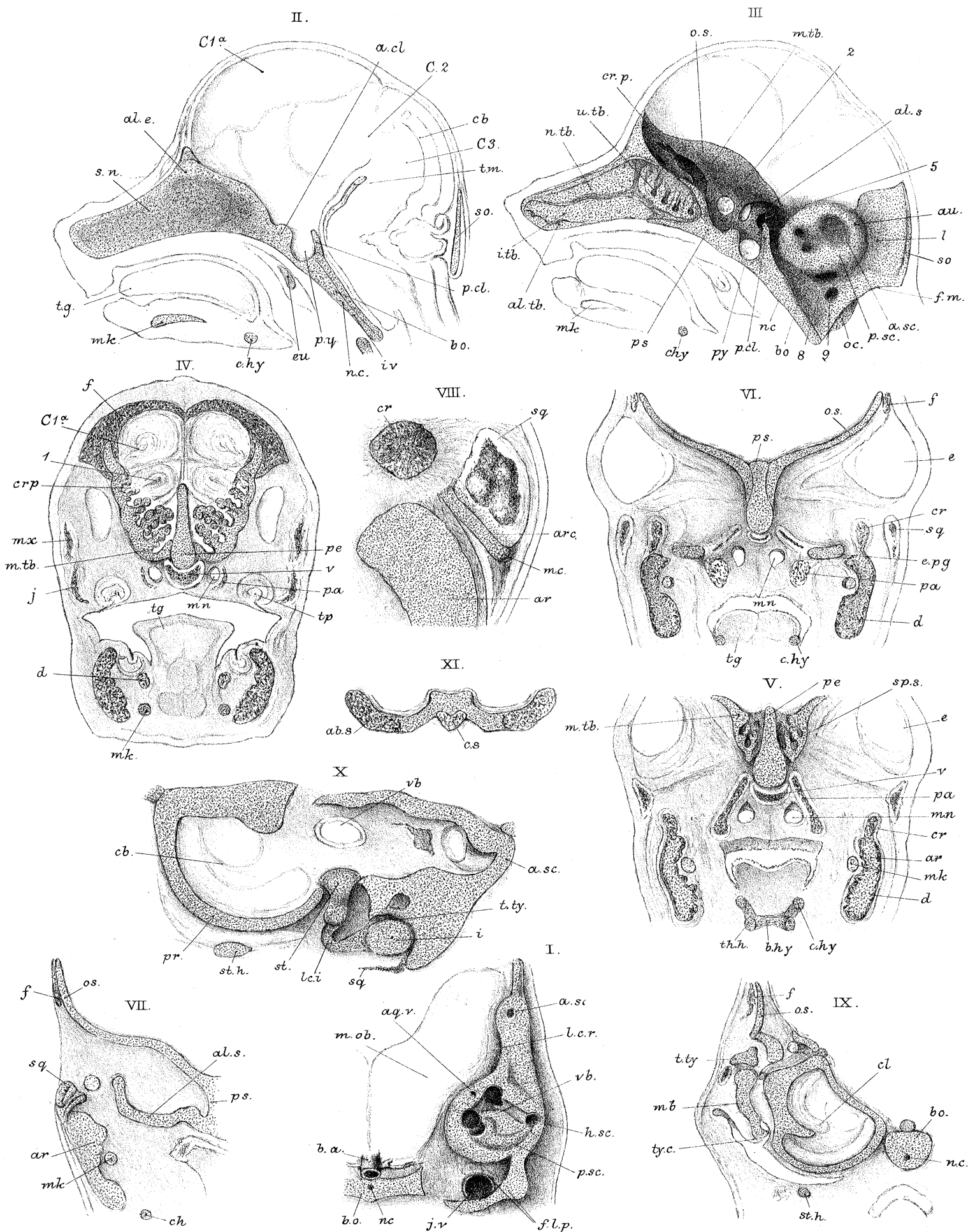
W. West & Co. imp.

Pig's Skull.  
Figs 1-7. 2<sup>nd</sup> Stage. Figs 8, 9. 3<sup>rd</sup> Stage.

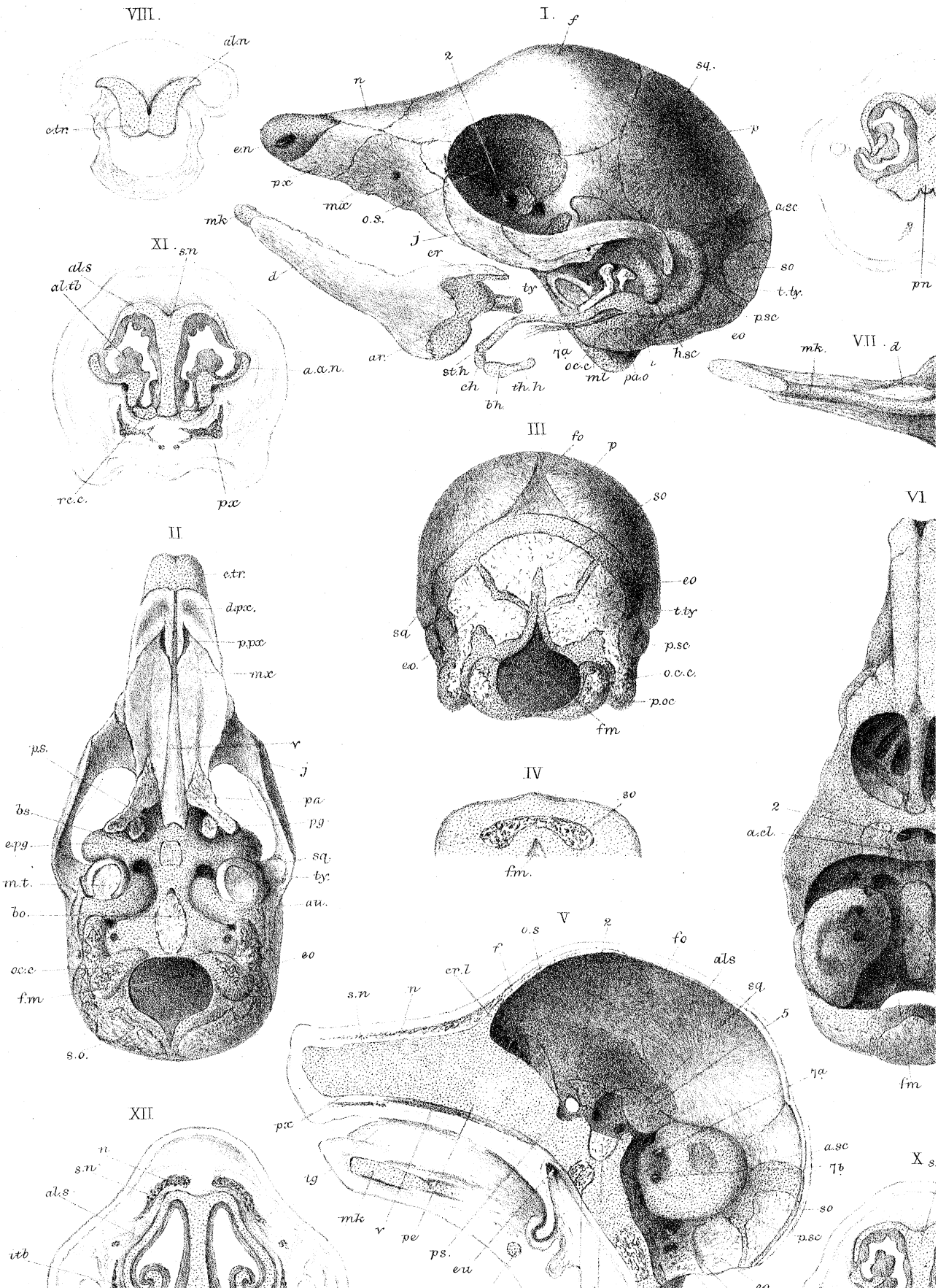


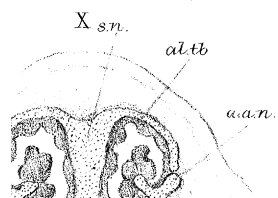
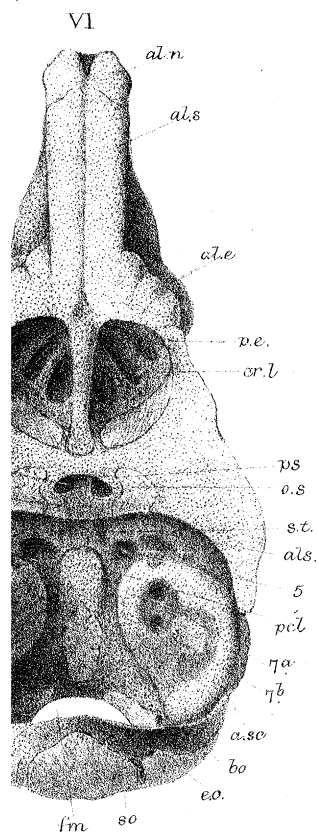
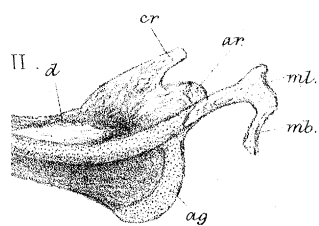
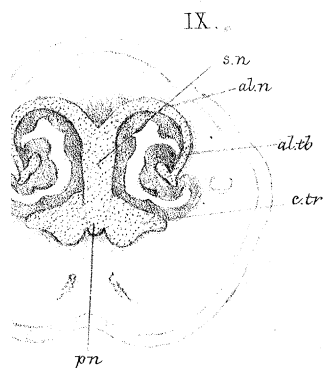




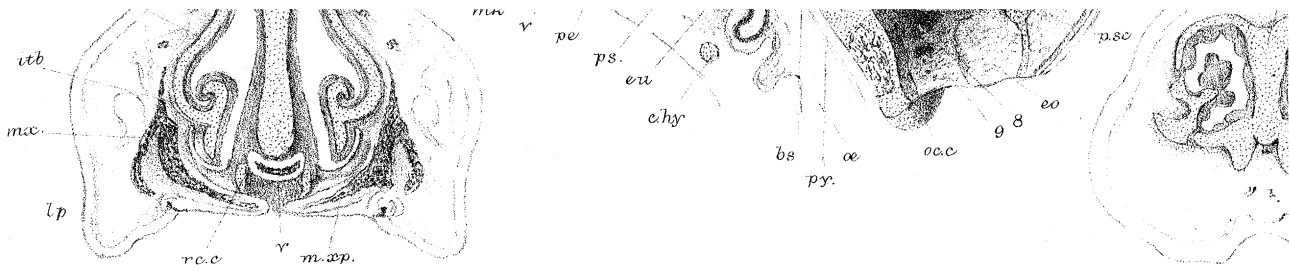


Pig's Skull.  
Figs. 1-3, 3<sup>rd</sup> Stage. Figs. 4-10, 4<sup>th</sup> Stage. Fig. 11. 5<sup>th</sup> Stage.



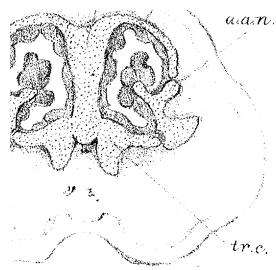




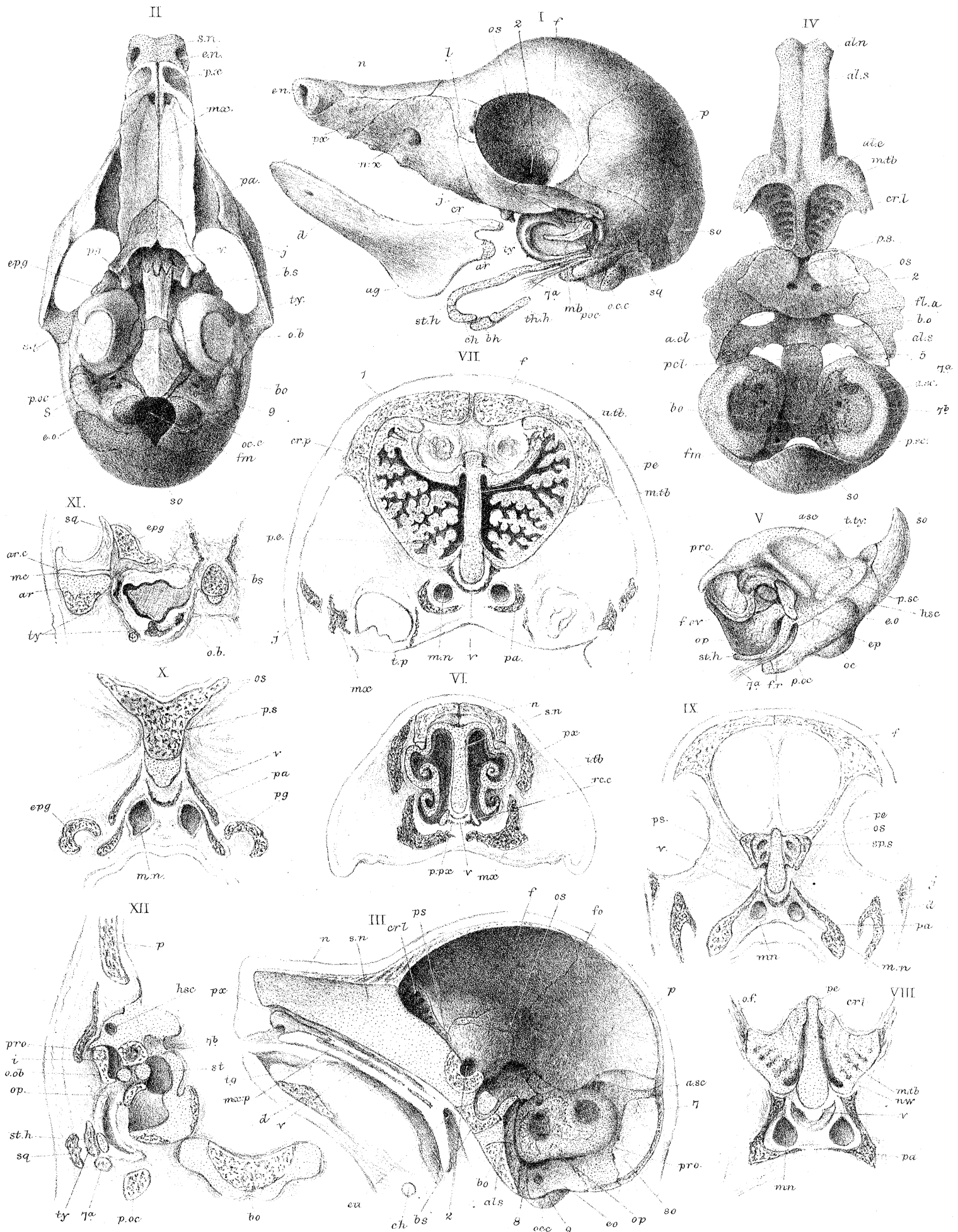


Pig's Skull. 4<sup>th</sup> Stage.

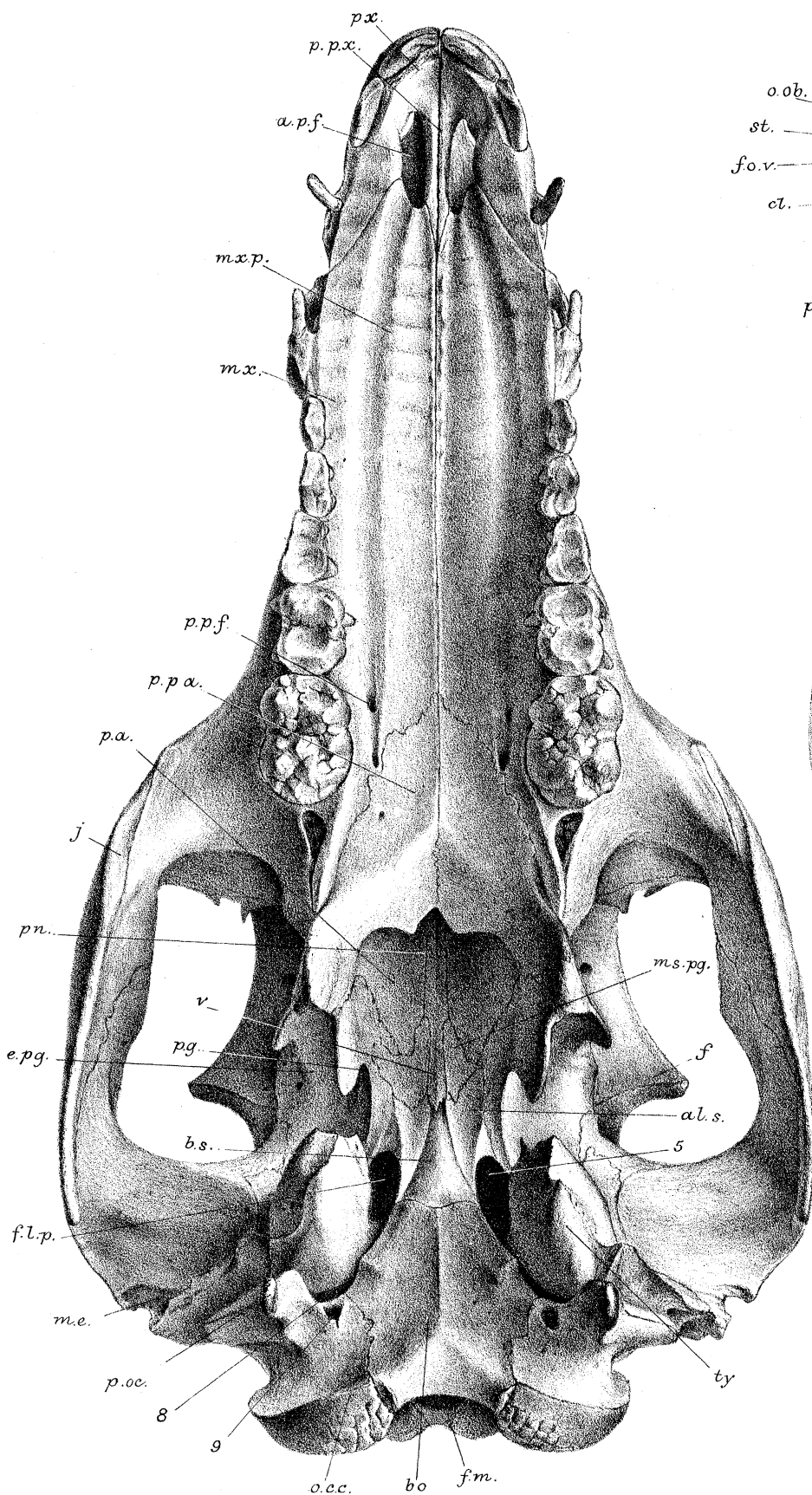
W.K.P. del ad nat. G. West lith.



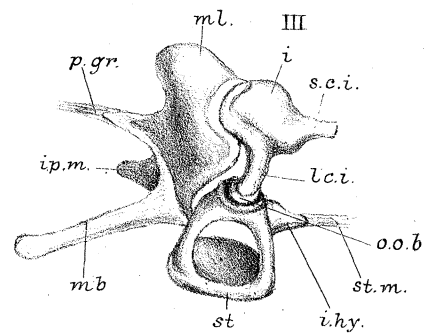
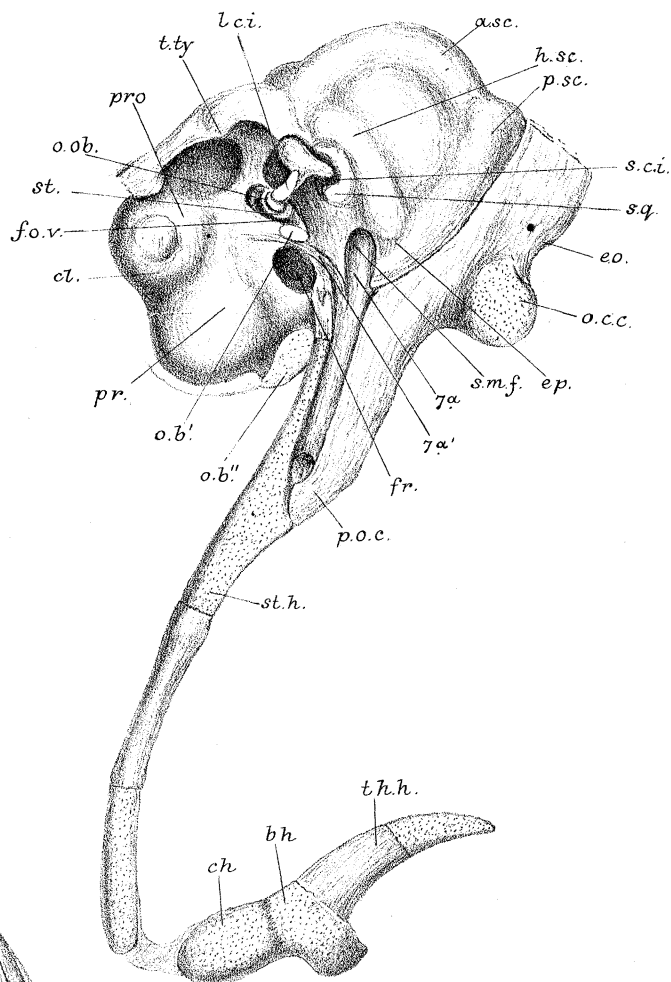
W. West & Co. imp.



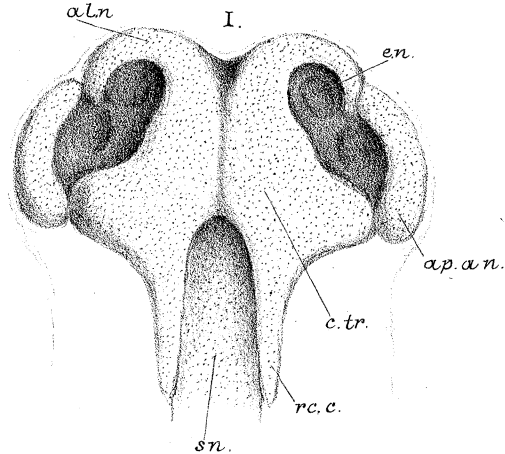
IV.

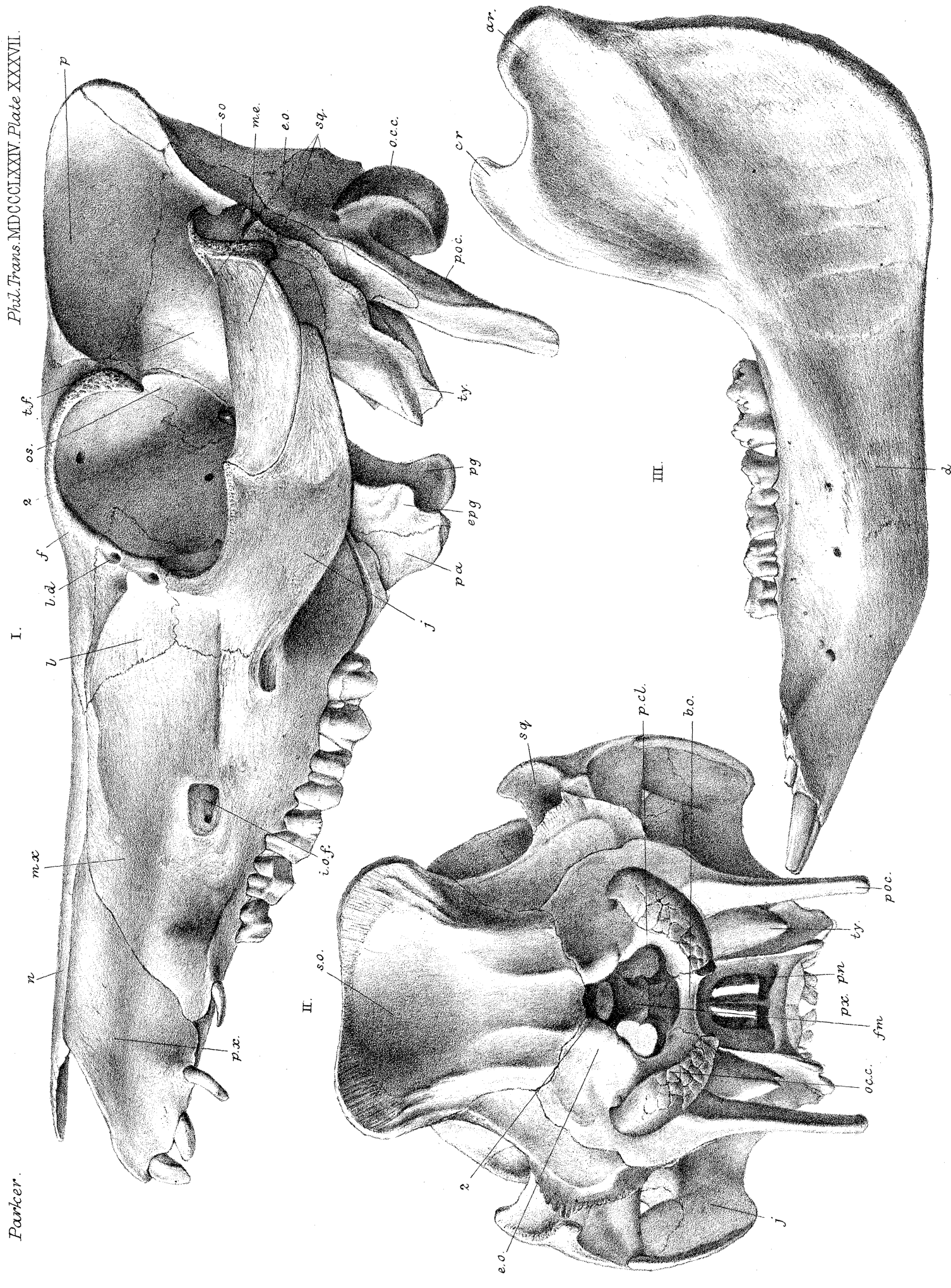


II.



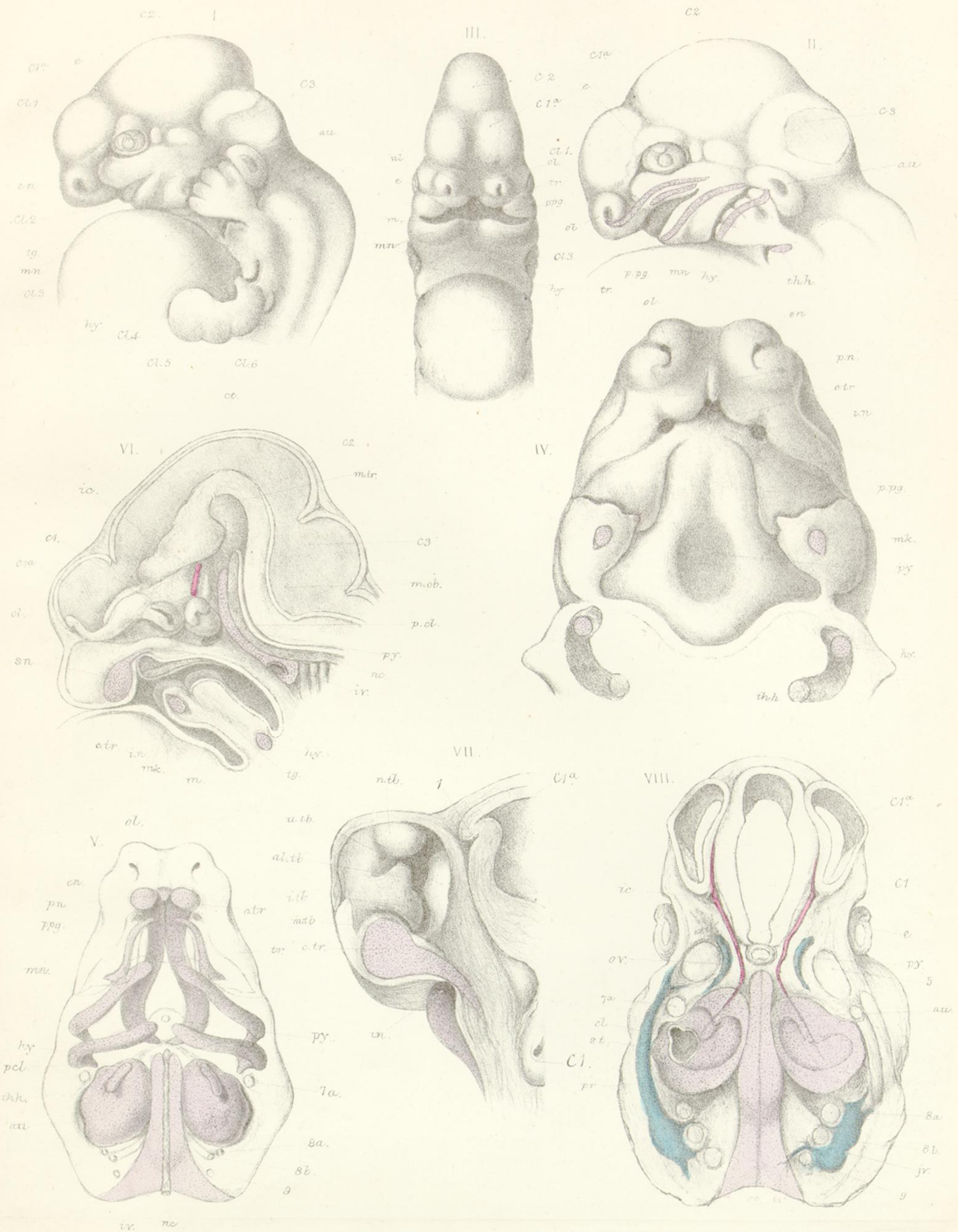
I.





Fig's Skull. 8<sup>th</sup> Stage.





Fig's Skull, 1<sup>st</sup> Stage.

# PLATE XXVIII.

*First Stage.—Embryo Pig,  $\frac{2}{3}$  inch in length.*

Fig. 1. Side view of upper part of embryo.  $\times 7$  diameters.

Fig. 2. A plan of the same, with facial arches.  $\times 7$  diameters.

Fig. 3. A front view of the same.  $\times 7$  diameters.

Fig. 4. A palatal view of the same, with the mandible and lower face removed.  $\times 15$  diameters.

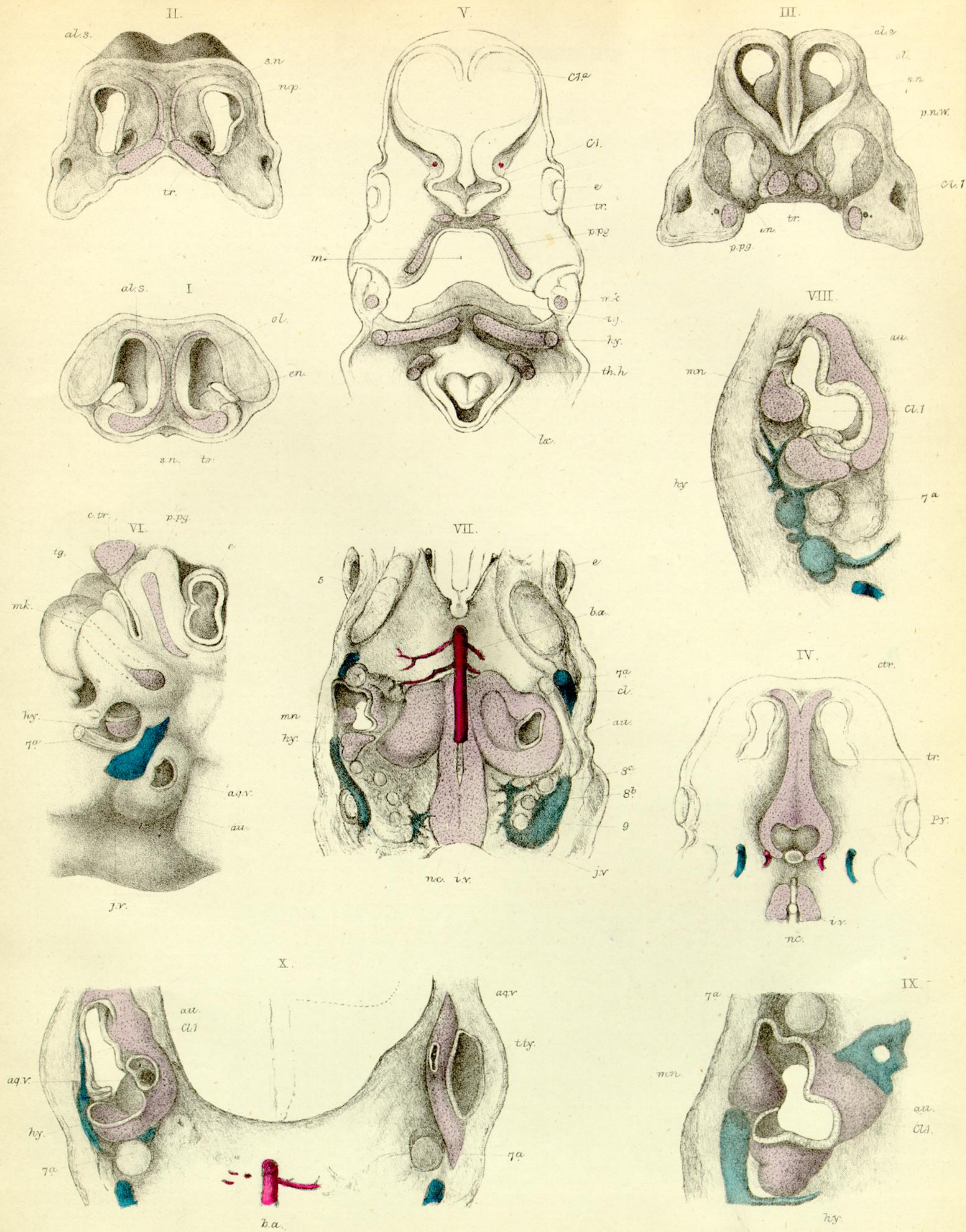
Fig. 5. A plan of the skull and face, seen from below.  $\times 10$  diameters.

Fig. 6. A vertical section of the head.  $\times 10$  diameters.

Fig. 7. Part of the same, with median part of nasal region removed.  $\times 20$  diameters.

Fig. 8. Upper view of a horizontal section of the head.  $\times 10$  diameters.



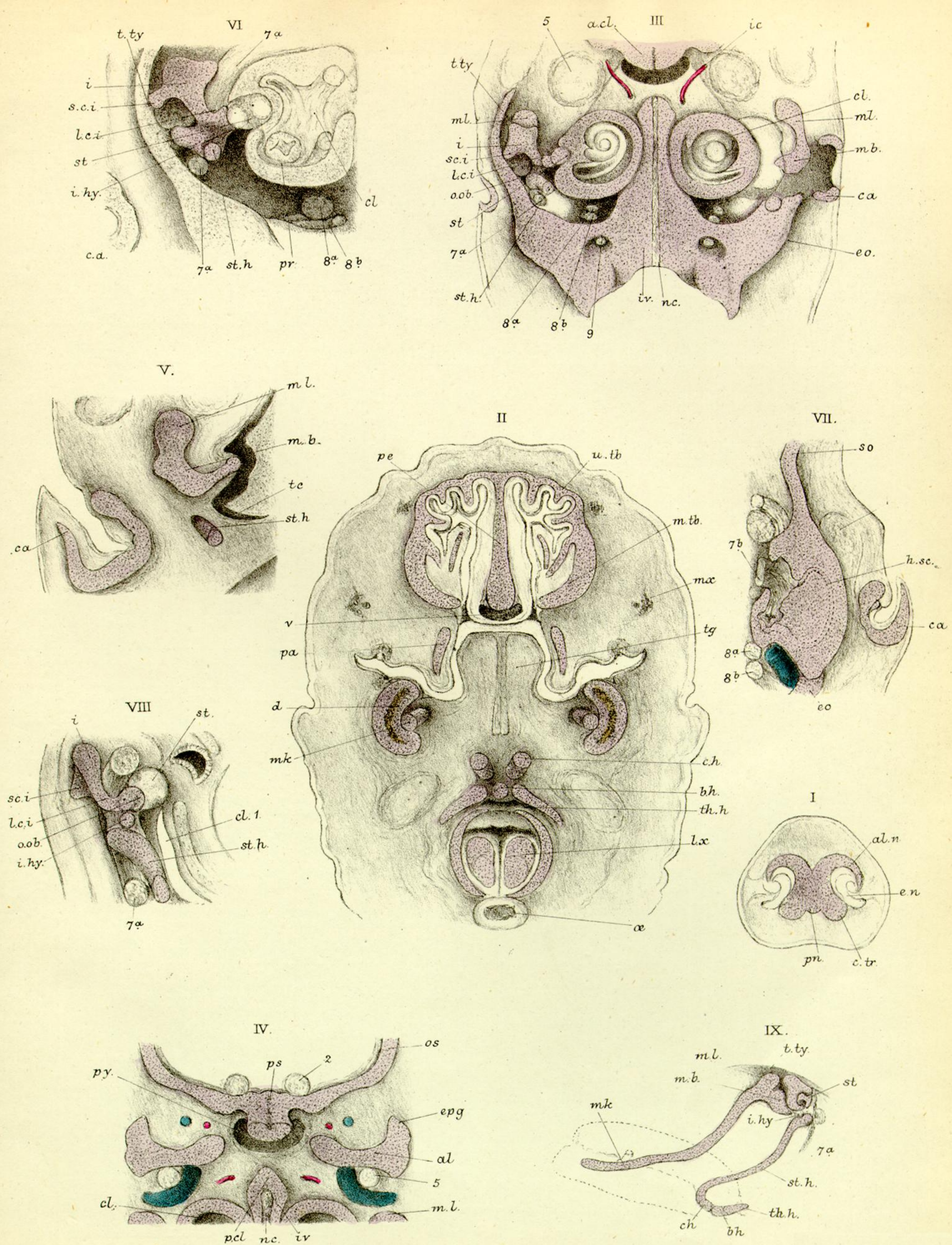


Fig's Skull 1<sup>st</sup> Stage.

## PLATE XXIX.

- Fig. 1. Transversely vertical section of the nose, in front.  $\times 12$  diameters.  
 Fig. 2. A similar section through the middle of the nasal region.  $\times 12$  diameters.  
 Fig. 3. Another section through the posterior nasal region.  $\times 12$  diameters.  
 Fig. 4. Horizontal section below the cranial cavity, exposing first arch, notochord, and investing mass.  $\times 10$  diameters.  
 Fig. 5. A subhorizontal section through the eyes and root of tongue.  $\times 10$  diameters.  
 Fig. 6. Part of the head, with outer part of cheek pared away.  $\times 12$  diameters.  
 Fig. 7. A section made through the plane of the hinder part of cranium.  $\times 12$  diameters.  
 Fig. 8. Part of same section.  $\times 20$  diameters.  
 Fig. 9. A similar section.  $\times 26$  diameters.  
 Fig. 10. Another subhorizontal section through the top of the first postoral cleft.  $\times 20$  diameters.





Pig's Skull.  
Figs 1-7. 2<sup>nd</sup> Stage. Figs 8, 9. 3<sup>rd</sup> Stage.

## PLATE XXX.

### Second Stage.—Embryo Pig, 1 inch long.

- Fig. 1. Section across the end of the snout.  $\times 10$  diameters.  
 Fig. 2. Section through ethmoid region, root of tongue, and larynx.  $\times 12$  diameters.  
 Fig. 3. Section nearly in plane of the notochordal region, front view.  $\times 10$  diameters.  
 Fig. 4. A similar section, lower down.  $\times 10$  diameters.  
 Fig. 5. Part of a similar section through apex of mandibular arch, front view.  $\times 15$  diameters.  
 Fig. 6. A similar section through apex of next arch, front view.  $\times 15$  diameters.  
 Fig. 7. Another similar section through periotic capsule in plane of horizontal canal.  $\times 10$  diameters.

### Third Stage.—Embryo Pig, $1\frac{1}{3}$ inch long.

- Fig. 8. Part of a section through top of second postoral arch, corresponding with fig. 6 of second stage, front view.  $\times 15$  diameters.  
 Fig. 9. Side view of the three postoral arches.  $\times 15$  diameters.









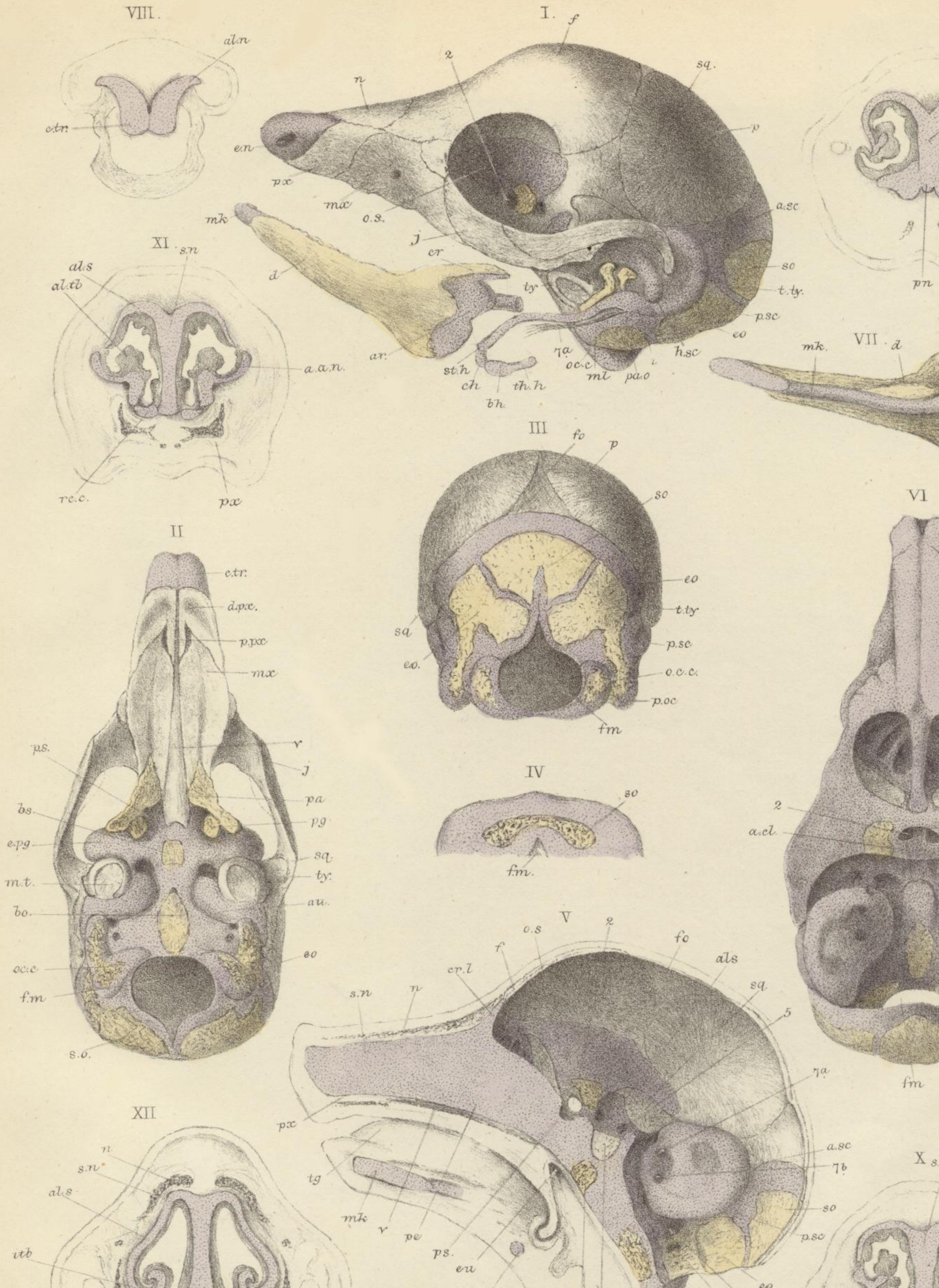




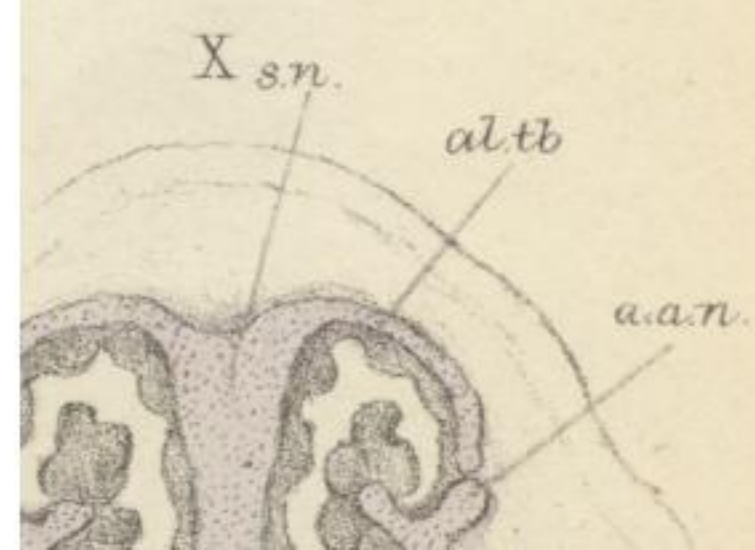
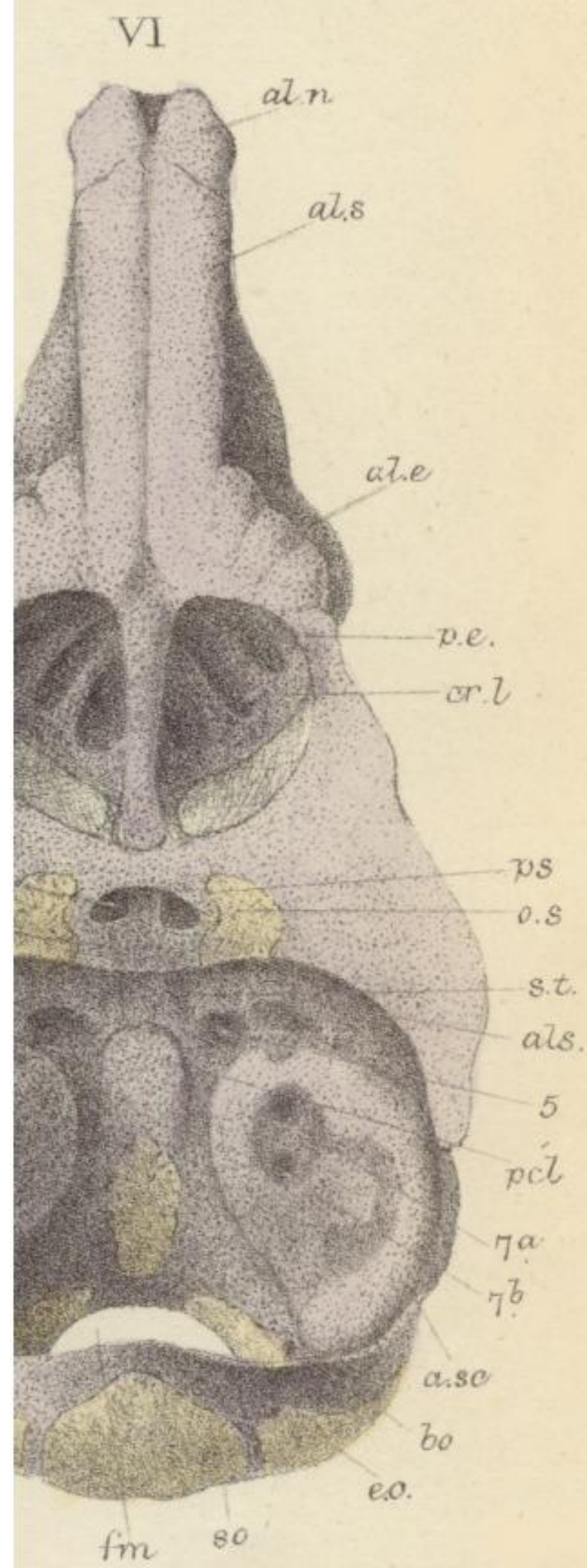
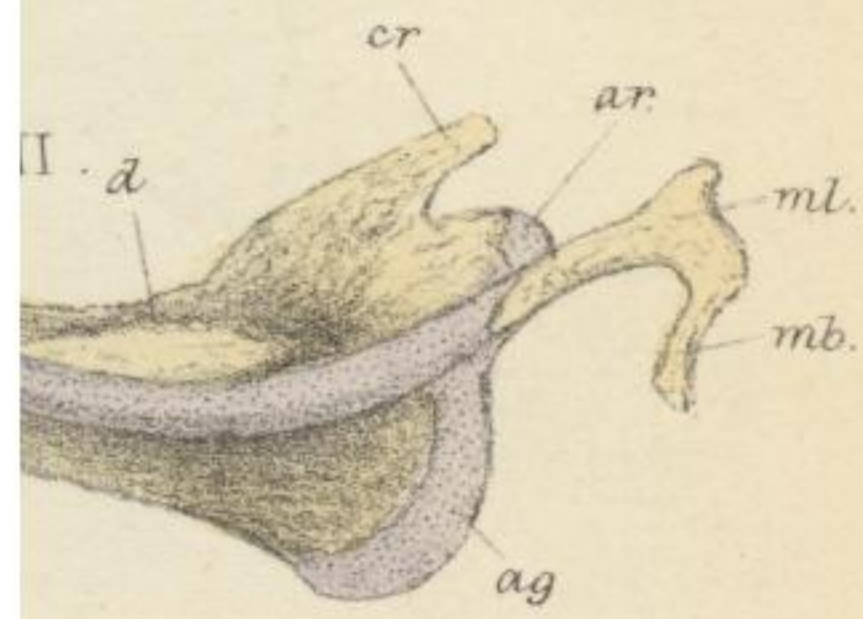
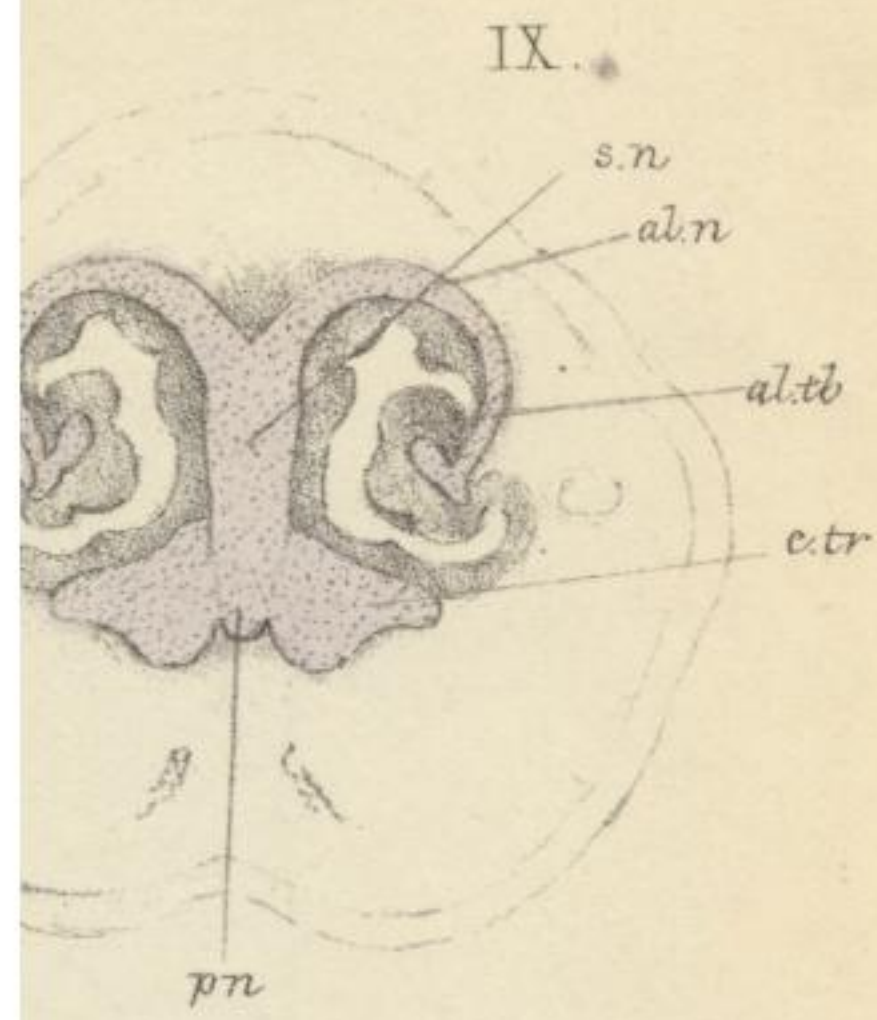











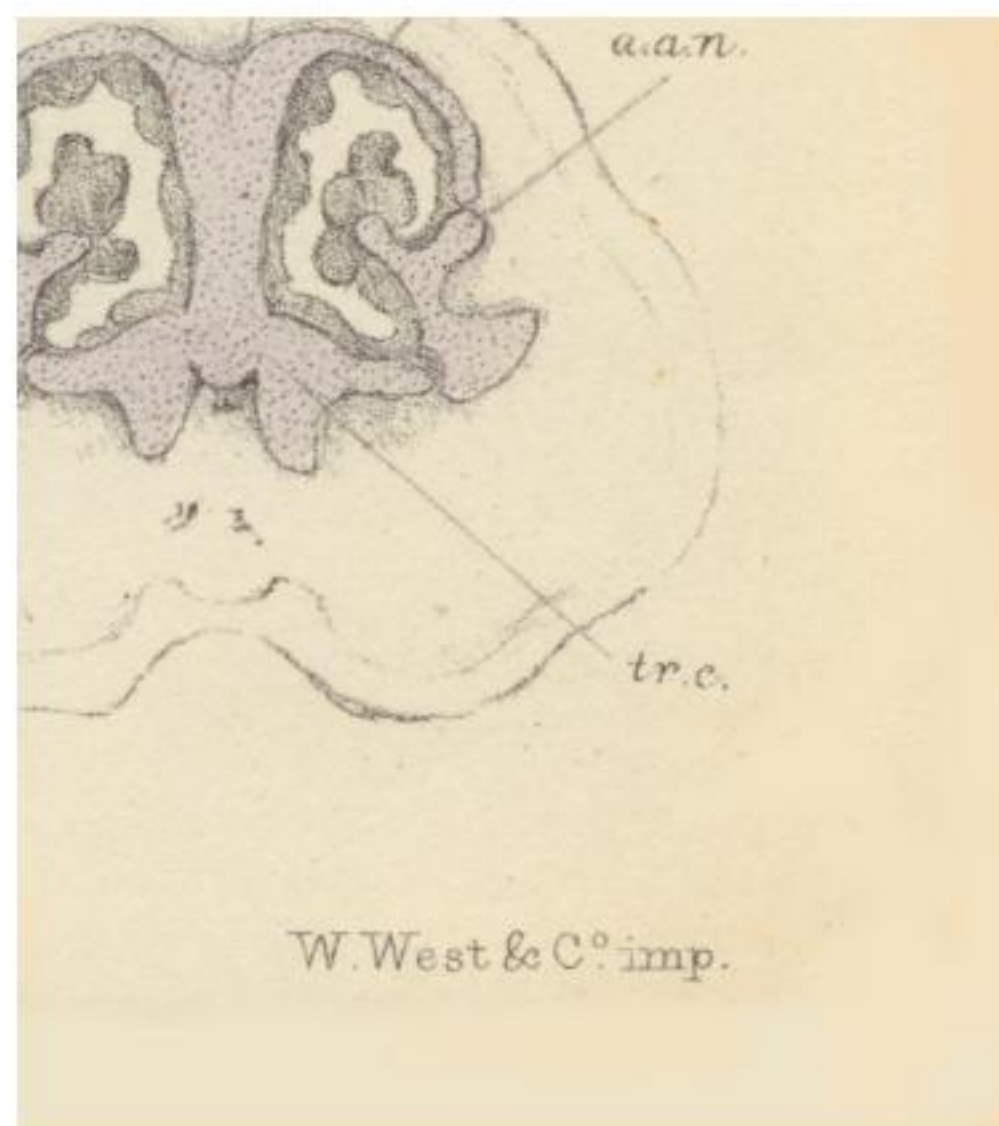




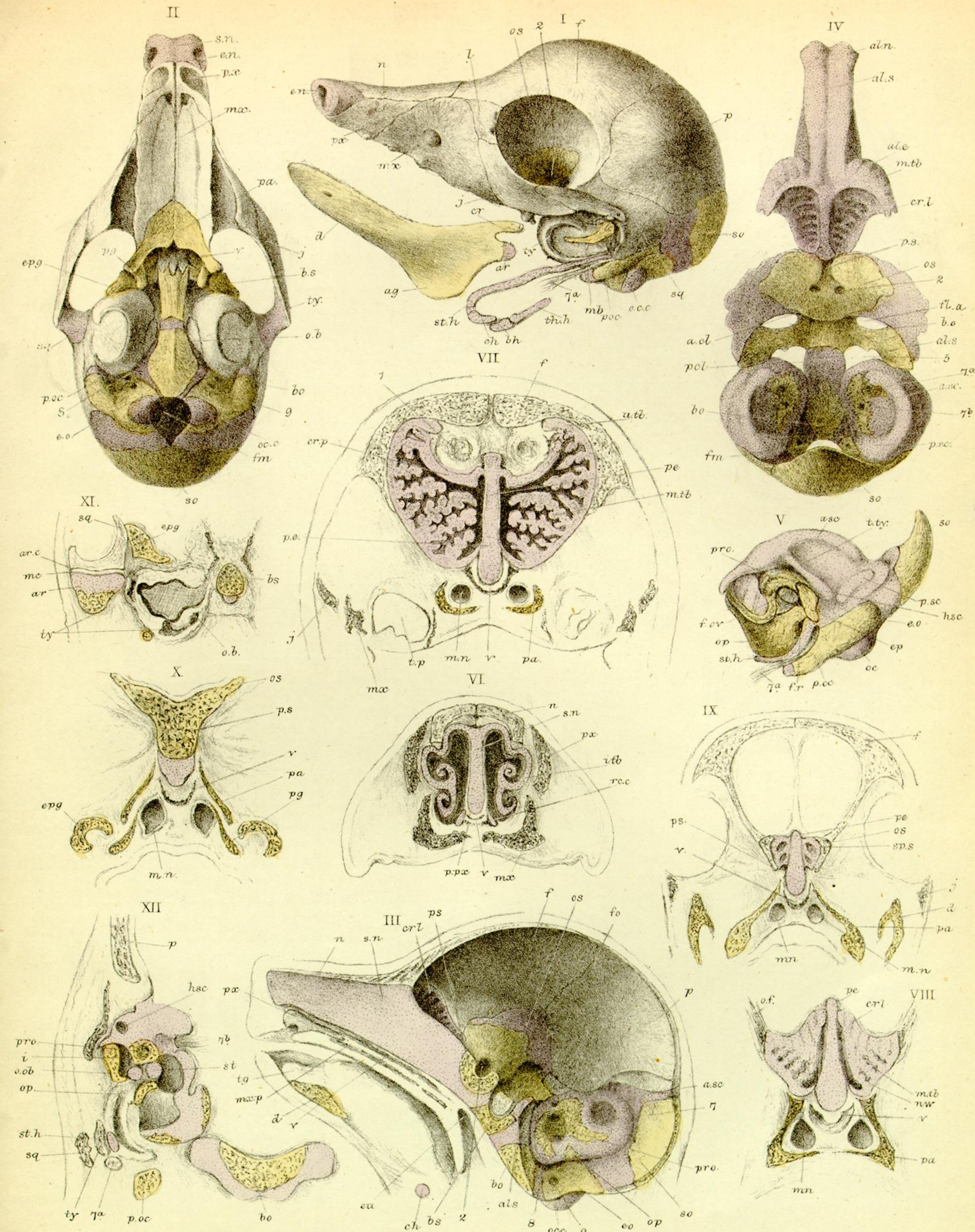


W.K.P. del ad nat. G. West lith.

Pig's Skull. 4<sup>th</sup> Stage.







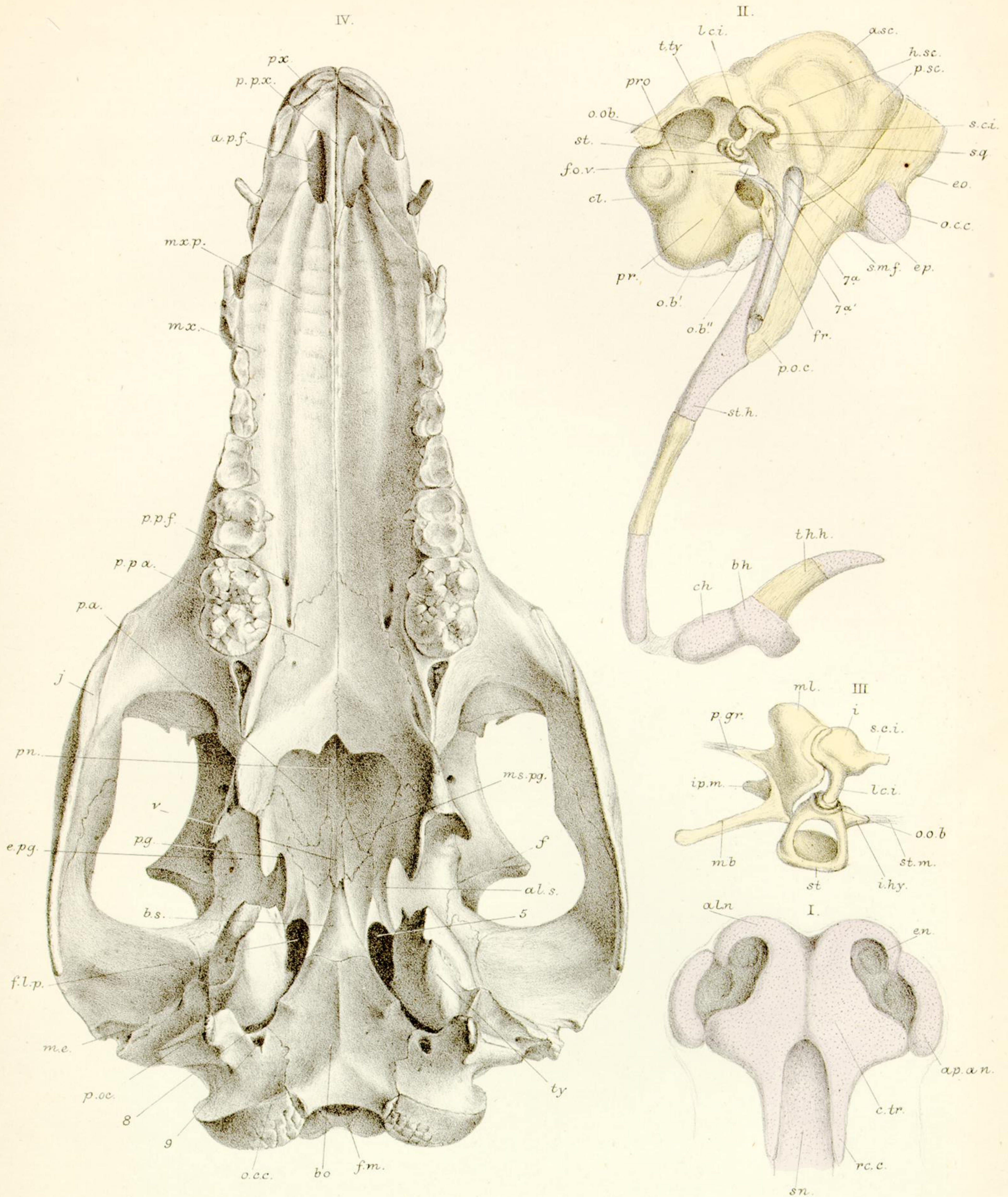
Pig's Skull. 6<sup>th</sup> Stage.

PLATE XXXV.

*Sixth Stage.—Embryo Pig, 6 inches long.*

- Fig. 1. Side view of skull.  $\times 1\frac{1}{2}$  diameter.
- Fig. 2. Lower view of same.  $\times 1\frac{1}{2}$  diameter.
- Fig. 3. Vertical section of same.  $\times 1\frac{1}{2}$  diameter.
- Fig. 4. Bird's-eye view of primordial skull.  $\times 1\frac{1}{2}$  diameter.
- Fig. 5. Outer view of occipital and auditory regions.  $\times 2$  diameters.
- Fig. 6. Transversely vertical section through inferior turbinals.  $\times 3$  diameters.
- Fig. 7. Another through ethmoids.  $\times 3$  diameters.
- Fig. 8. Part of section through hinder part of nasal labyrinth.  $\times 3$  diameters.
- Fig. 9. Section through orbits.  $\times 2$  diameters.
- Fig. 10. Part of section through anterior sphenoid.  $\times 3$  diameters.
- Fig. 11. Section through hinge of lower jaw.  $\times 2$  diameters.
- Fig. 12. Section through periotic mass and basioccipital.  $\times 3$  diameters.





Pig's Skull, 7<sup>th</sup> & 8<sup>th</sup> Stages.

## PLATE XXXVI.

*Seventh Stage.—Pig at birth.*

Fig. 1. Under view of snout-cartilages.  $\times 5$  diameters.

Fig. 2. Auditory capsule, hyoid, and occiput.  $\times 3\frac{1}{2}$  diameters.

Fig. 3. Auditory chain of bones.  $\times 5$  diameters.

*Eighth Stage.—Pig, 6 months old.*

Fig. 4. Lower view of skull. Natural size.