

XVIII. *The Minute Anatomy of the Alimentary Canal.* By HERBERT WATNEY, M.A.,  
M.D., *Demonstrator of Microscopical Anatomy at St. George's Hospital.* Commu-  
nicated by Dr. KLEIN, F.R.S.

Received December 16, 1875,—Read January 27, 1876.

TABLE OF CONTENTS.

CHAPTER I.	Page	CHAPTER II.	Page
The Minute Anatomy of the Mucous Membrane of the Intestine, and the Method of Fat- absorption.		The Minute Anatomy of the Mucous Membrane of the Pyloric end of the Stomach.	
Preliminary statement of the result of this re- search .....	452	History of the subject .....	469
History of the subject .....	452	The general structure of the mucous mem- brane .....	470
Methods employed.....	458	The epithelium covering the pyloric end of the stomach .....	471
The epithelium, and the reticulum and lymph- corpuscles among the epithelial cells .....	459	Germination of the epithelium.....	471
Membrana propria, of the villi, and of the pro- cesses of the mucous membrane of the large intestine .....	461	The connective-tissue reticulum among the columnar epithelium .....	473
The membrana of LIEBERKÜHN's crypts .....	462	The character of the membrana propria .....	474
The disposition and termination of the muscles in the processes of the mucous membrane of the rabbit's colon .....	462	The muscle-endings in the plicæ villosæ and the perivascular spaces .....	474
The disposition of the muscle-bundles and the muscle-endings in the villi .....	463	The proper gland-tubes of the pyloric end of the stomach.....	475
Structure and relations of the blood-vessels of the mucosa .....	464		
The character and relations of the chyle-vessels of the villi.....	465	CHAPTER. III.	
The tissue composing the mucosa .....	465	The Minute Anatomy of the Mucous Membrane at the point of transition between the Stomach and Intestine.....	476
Fat-absorption by the reticulum among the epithelial cells .....	467		
Fat-absorption by the reticulum of the villi ..	469	Explanation of the Plates.....	479
		References.....	486

THE following is an account of a research undertaken in the laboratory of the Brown Institution in July 1873, under the direction of Dr. KLEIN, and carried on there under his direction until October 1874. During the last year it has been continued in the physiological laboratory of St. George's Hospital.

## CHAPTER I.

## THE MINUTE ANATOMY OF THE MUCOUS MEMBRANE OF THE INTESTINE, AND THE METHOD OF FAT-ABSORPTION.

In this chapter I propose first to state very briefly the result of my researches on the structure of the intestine and the method of fat-absorption ; secondly, to relate the history of these subjects ; and, finally, to give a detailed account of this research.

## PRELIMINARY STATEMENT.

*The mucous membrane of the intestine is pervaded everywhere by a reticulum similar to, and continuous with, that found in the follicles of PEYER'S patches. This reticulum is situated among all the other elements which are contained in its meshes. This is true of the epithelial cells, the muscle-fibres, the cells of the parenchyma, and of the endothelial plates of the membrana propria, of the blood-vessels, and lymphatics.*

*It is by this reticulum that the fat is absorbed, and by this reticulum that the fat finds its way into the lymphatic vessels, and probably also into the blood-vessels.*

## HISTORY.

ASSELIUS (1628) ascribed open mouths to the chyle-vessels of the intestine.

LIEBERKÜHN (1)\*, HEWSON (2), and CRUIKSHANK (3) believed that the central canal of the villus opened on the surface. LIEBERKÜHN thought he saw one opening from the ampulla or widened end of the chyle-vessel. HEWSON conceived that the villi have a network of lacteals, and that the orifices of the lacteals are on the extremities of the villi. He considered it probable that the villi were erected "in order to make the small absorbents stand rigidly open;" and he thought that in this way the fluid (chyle) may be conveyed to the first pair of valves. CRUIKSHANK saw "in some hundred villi the trunk of a lacteal forming or beginning by radiated branches. The orifices of these radii were very distinct on the surface of the villus, as well as the radii themselves. The radii passing into the trunk of the lacteal were full of a white fluid. There was but one trunk in each villus."

RUDOLPHI (4), 1802, examined the villi of many animals ; he denied the existence of openings of the chyle-vessel on the surface ; he imagined that the chyle-vessels took their rise by a network within the villi.

FOHMAN (5), 1827, injected the lymphatics of fish with quicksilver. He found that no mercury escaped into the intestine, and concluded that the lymphatics end blindly.

After this there was a long contest as to the origin of the chyle-vessel and method of fat-absorption. We may distinguish three different opinions. The first was that the chyle-vessel arose from a network of lymph-capillaries: KRAUSE (6), GOODSIR (7), E. H. WEBER (8), NUHN (9), ZENKER (10). A second opinion maintained that the fat pressed through the villus, not in definite preformed ways, but among the parenchyma: FRERICHS (11), DONDEERS (12), FUNKE (13), DÖNITZ (14). A third opinion was held by other observers, who maintained that the chyle-vessels are closed ; they gave no opinion

\* See the References, p. 486.

as to the manner in which fat traversed the villus: HENLE (15), SCHWANN (16), DONDEES (12), KÖLLIKER (44), and BRUCH (18). DONDEES further spoke of the chyle-vessels as possessing a membrane.

HENLE (15), 1837, showed that the intestine is covered by a layer of epithelium.

GOODSIR (7), 1842, first noticed that the epithelial cells apparently contain fat-granules. He did not, however, lay any stress on the fact, but supposed that certain "vesicles" close to the membrane have the property of absorbing, and that the epithelium is cast off previous to absorption. This author saw the *membrana propria* clearly, and considered that the nuclei situated in it at regular distances were the germinal spots from which the epithelium is reproduced.

LACAUCHIE (19), 1843, first noticed the movements of the villi, and attributed them to a system of muscles. He considered each villus to be a system of sucking- and forcing-pumps (*aspirantes et foulantes*).

GRUBY and DELAFOND (20), 1842 and 1843, found chyle in the epithelial cells, and thought that each epithelial cell must be considered an organ specially charged to receive raw chyle, and convert it to a homogeneous chyle, and to transmit the liquid thus made. Each epithelial cell is provided with a cavity whose external opening is sometimes gaping and at other times more or less exactly shut. They found that on the surface of the epithelium of the villi of the dog vibratile bodies exist, whose function may be to displace, when necessary, the raw chyle in contact with the epithelium. They independently discovered the movements of the villi.

E. H. WEBER (8) noticed that the chyle-vessels were filled with chyle, although the mucosa was clothed with its epithelium; and no one after this seems to have doubted that the fat found its way through the epithelium, if we except ERDMANN (34). WEBER speaks of a second layer of cells which are round, some of which are filled with an opaque white fluid and some with a transparent fluid. He considered that the epithelium underwent a change in form in the act of absorption.

FRERICHS (11), 1848, found that the granules of fat, which are of considerable size in the stomach, become finer in the intestine, this change being of a mechanical nature, probably caused by the action of bile, the pancreatic fluid, and the fluid of the intestine; he found that the fat thus finely divided presses gradually through the substance of the villus.

FUNKE (21), 1853, in his Atlas, gave a representation of the branched chyle-vessels (see fig. i. Taf. viii.).

FUNKE (13) afterwards (1855) spoke of the chyle-capillaries as being due to the fat pressing in everywhere in the tissue of the villus. He denied the existence of pre-formed ways.

BRUCH (18), 1853, said that the fat enters the epithelial cells as little drops, which unite to form larger ones. He spoke of fat-absorption by the blood-vessels, and considered all the so-called branched chyle-vessels to be really blood-capillaries containing molecular fat; he included in that FUNKE's fig. i. Taf. viii.

VIRCHOW (22), 1853, noticed a white substance in the veins of the villi. He considered the whole parenchyma of the villus to be full of fat during absorption.

VIRCHOW (23), 1857, noticed that the epithelial cells of the gall-bladder are filled with fat, the fat lying in parallel rows in the epithelial cells.

BRÜCKE (24), 1851 and (25) 1853, repeated and confirmed the researches of LACAUCHIE, and of GRUBY and DELAFOND, concerning the contractility of the villi. BRÜCKE further showed that that contractility is due to bands of longitudinal muscle-fibres running up to the points of the villi; and, further, that these muscles are only processes from the muscularis mucosæ\*. This author supposed that each epithelial cell is open at its distal and proximal ends, that the fat encounters (at the entrance to the cells) a plug of mucous consistence, and that the central canal is not a vessel but only a space between the tissue.

DONDERS (12), 1853 and 1856, denied the existence of openings at the ends of the epithelial cells. He thought that the fat goes through the villus in a cloud-like form.

MOLESCHOTT and MARFELS (26), 1854, maintained BRÜCKE's opinion of the epithelial cells being open at their free extremities. They found that in frogs mammalian blood and in mammals pigment-granules penetrate the epithelium.

DONDERS, WITTICH (27), and HOLLANDER (28) obtained negative results on repeating the experiments of MOLESCHOTT and MARFELS.

KÖLLIKER (29) spoke in the most positive terms of the epithelial cells being closed at their free extremities; further, KÖLLIKER and FUNKE (30), 1855, showed that the "basal border" of the epithelium is striated. KÖLLIKER thought that the basal seam is penetrated by little pores through which the fat passes.

BRETTAUER and STEINACH (31), 1857, showed that the seam is sometimes composed of little rods.

There was much discussion, which may be found in the literature of the subject, on the character of the seam, its thickness in fat-absorption, and the manner in which fat penetrated it; and subsequently there was great dispute about the origin and significance of the goblet-cells. Neither of these questions will be entered upon in this paper.

TODD and BOWMAN (32), 1856, described a basement membrane in the villi as a single layer of homogeneous membrane.

This question of the existence of a basement membrane is nearly as important as the similar one of the occurrence of a membrane belonging to the chyle-vessels; for if there be a membrane, the views of HEIDENHAIN and all his followers must fall to the ground, unless we accept a basement membrane in the sense of KÖLLIKER. The following authors assert that there is a basement membrane:—GOODSIR (7), DONDERS (12), TODD and BOWMAN (32), EBERTH (33), DÖNITZ (14), ERDMANN (34), and DEBOVE (35).

BILLROTH (36), 1858, supposed that the epithelium of the frog's intestine has an intimate connexion with the connective-tissue corpuscles.

\* The muscularis mucosæ had been previously described by MIDDELDORFF in a paper on BRUNNER's glands (1846).



HEIDENHAIN (37), 1858, put forward a definite theory of fat-absorption, namely, that the epithelial cells are in connexion with the branched cells of the parenchyma, that there is a direct transition of these cells into real chyle-vessels, and that these structures are preformed ways which the fat traverses. He gave drawings of nucleated epithelial cells ending in processes, the processes containing a second nucleus, and filled with fat (fig. iv.). HEIDENHAIN figured branched cells of the parenchyma connected with one another by processes (fig. vi.). In chromic acid, however, he found the cells were round and surrounded by a framework (fig. viii.).

This theory of the connexion of the epithelial cells with the connective-tissue corpuscles was afterwards supported by WIEGANDT (38), BALOGH (39), ARNSTEIN (40), EIMER (41), and THANHOFFER (57); but it was denied by RINDFLEISCH (42), LIPSKY (43), KÖLLIKER (44), VERNON (45), and BASCH (46). The connexion was necessarily denied by those who assumed an unbroken *membrana propria*, as DÖNITZ (14) and ERDMANN (34).

WIEGANDT (38), 1860, noticed the long processes attached to the epithelium of the frog's intestine; he could not find connective-tissue corpuscles with processes. WIEGANDT, however, considered HEIDENHAIN'S view to be probably correct for the epithelium of the frog.

BALOGH (39), 1860, described processes in the epithelium of the rabbit's intestine.

EBERTH (33), 1864, isolated the basement membrane which covers the villi. He found that the membrane has holes or gaps in it, and is attached to the blood-vessels (figs. i. & ii.). He described the *membrana propria* of LIEBERKÜHN'S crypts as a structureless membrane, with oval nuclei imbedded in it. EBERTH figured short processes to some of the epithelial cells (fig. ix.).

DÖNITZ (14), 1864, spoke of the fat coming in in the form of a cloud, and said that the epithelial cells with processes are artificial products. This author denied the presence of star-like or branching connective-tissue corpuscles in the mucosa; and maintained that the epithelium is separated from the parenchyma by a glass-like membrane containing no visible pores.

BASSLINGER (47), 1858, found that in birds the lymphatic follicles are not sharply bordered, but that the follicular tissue may be found in the base of the villi, or even extending to their apices.

HIS (48), 1862, showed that the tissue of the mucosa, including the villi, consists of a more or less close network of fine connective-tissue trabeculæ, or branched cells, which form a framework attached to the blood-vessels; in the meshes of the framework lymph-corpuscles are found. He called this tissue "adenoid." HIS further showed that lymphoid follicles are not formations of a peculiar kind, but are richer collections of adenoid substance. He gave a drawing of the tissue of a villus which had been brushed, in which the reticulum is clearly seen (see HIS, fig. iv.).

TEICHMAN (49), 1861, by his beautiful injections, showed the disposition of the chyle-vessels in the villi. He asserted that the chyle-vessels are closed.

RECKLINGHAUSEN (50), 1862, on the contrary, found that the material which he

injected into the lymphatics of the villi left the vessel and passed into the stroma of the villus (see Taf. iii. fig. ii.). He showed that the walls of the chyle-vessels are lined by an endothelium. RECKLINGHAUSEN thought there was a Saftcanalsystem in the villi, although he allowed that there is a gradual transition from follicular tissue (adenoid tissue, HIS) to the Saftcanalsystem.

HIS (51) and AUERBACH (52) confirmed RECKLINGHAUSEN's observation of the existence of an endothelial covering to the chyle-vessels. HIS maintained with TEICHMAN that the injection does not leave the chyle-vessels. Notwithstanding these researches, three observers, FLES (53), BASCH (54), and ZAWARYKIN (56), declared that in its upper part the central vessel has no definite membrane.

BASCH (54), 1865, found no difference between the cells of the villus and those lining the chyle-vessel. He injected from the lymphatics, and not only filled the central canal of the villus, but his injection penetrated the stroma of the villus in lines, forming a regular network.

LETZERICH (55), 1866 and 1867, described certain structures among the epithelial cells, which in the *normal* state are the sole absorbents of fat; these structures ("vacuoles") are connected with a system of canals, and the canals with the central vessel. In *pathological* states the epithelial cells contain fat. When not in action the vacuoles are closed, and are seen as star-shaped bodies between the epithelium. EIMER and other observers pointed out that the vacuoles are "goblet-cells."

KÖLLIKER (44), 1867, confirmed EBERTH's researches as to the basement membrane. He held, however, that the border seam is nothing but a thickened outer layer of the connective tissue, corresponding to the border layer of the "follicular glands." KÖLLIKER considered it probable that the fat passes through the pores of the epithelial cells; and stated that the paths by which the fat travels in the tissue of the villus are unknown to anatomists.

ERDMANN (34), 1867, found that the epithelium is separated from the stroma of the villus by an unbroken membrane. This membrane sends processes, on the one hand, around the epithelial cells (as a cement substance), and, on the other hand, in the stroma of the villus (as connective-tissue trabeculæ)\*. These trabeculæ enclose the connective-tissue corpuscles. The corpuscles of the villus are not star-like, but round; the fat travels by the cement substance between the epithelial cells.

EIMER (41), 1869, tried to demonstrate HEIDENHAIN's theory. He gave drawings of the connexions of the epithelial cells with the tissue of the villus from sections of a hardened intestine of a frog†. EIMER further gave drawings of fat-particles in the processes of the branched connective-tissue corpuscles of the submucosa of the frog's intes-

\* FLES (1865) considered that the intercellular substance between the epithelial cells is in direct communication with the connective-tissue of the villus.

† Almost all the attempts to establish the connexions of the epithelial cells and the connective-tissue corpuscles have been made from preparations of the frog's intestine; and this is the more remarkable from the fact that the epithelial cells in that animal are very long and narrow, and that it is somewhat difficult to show their connexions.

tine. These corpuscles are attached to the lymphatic vessels (figs. ix. & xiii.). This author found, during absorption, fat-particles in the circular muscular layer of the intestine. He figured fat-particles between the epithelial cells (fig. xx.). EIMER further considered that in mammals the epithelial cells are connected with the tissue of the villus.

ZAWARYKIN (56), 1869, obtained a natural injection of the paths which the chyle traverses by injecting albumen and Berlin blue into a loop of the intestine in the living animal. He found that the blue mass goes by the borders of the cells; these borders end in processes which communicate with the membrane of the villus. He found the substance of the villus coloured as it is represented by BASCH (54), *i. e.* he found a network of blue lines surrounding the lymph-corpuscles. ZAWARYKIN thought the blue lines correspond to the cleavage-spaces in the ground substance of the villus.

BASCH (46), 1870, described the villus as composed of trabeculæ and cells of the parenchyma; the trabeculæ contain connective-tissue corpuscles. The fat goes by ways within the trabeculæ which possibly are preformed. BASCH's drawings give very thick trabeculæ, containing cells (see his fig. vii.). He denied a constant connexion of the epithelium with the tissue of the villus. BASCH noticed the fat between the epithelial cells, but he conceived that it was due to regurgitation from the villus.

DEBOVE (35), 1872, showed by the use of nitrate of silver that there is everywhere in immediate proximity to the epithelium an endothelial membrane similar to that of the chyle-vessels.

THANHOFFER (57), 1874, found that the epithelial cells in the frog's intestine are open, that the cell-substance, in the form of hair-like processes, may protrude above the cells. This was seen when the nerve-centres were injured. These hair-like processes show lively movements, and aid in fat-absorption. He found star-like connective-tissue corpuscles attached to the epithelium.

*Bibliography of the small Cells among the Epithelium.*

EBERTH (58), 1861, found in the intestine of a duck groups of epithelial cells containing two to four nuclei, the nuclei lying one above the other.

RINDFLEISCH (42), 1861, found round elements among the deeper layers of the epithelial cells.

EBERTH (33), 1864, saw young cells among the intestinal epithelium; at times they were arranged in rows between the epithelial cells. He also saw citron-shaped cells. EBERTH was unable to determine whether these cells are young epithelial cells or not: he considered that some of them are elements which have wandered from the mucosa.

ARNSTEIN (40), 1867, found lymph-corpuscles between and within the individual epithelial cells; he found them also within the goblet-cells. He considered that these lymph-corpuscles have wandered from the mucosa.

FRIES (59), 1867, noticed the round cells among the intestinal epithelium.

EIMER (60), 1867, injected colouring-matter into the lymph-sac of a frog. He found coloured lymph-corpuscles in the goblet-cells and in the mucosa.

LIPSKY (43), 1867, noticed small round cells in the epithelium covering PEYER'S patches.

VERSON (45), 1870, also mentions the occurrence of rounded cells between the attached extremities of the epithelial cells over PEYER'S patches.

#### METHODS EMPLOYED.

##### *Hardening in Chromic Acid.*

The intestine or stomach of a recently killed animal was washed as soon as possible in one tenth per cent. chromic acid, or in one per cent. bichromate of potash, and then immediately transferred to chromic acid. After the chromic acid, it was placed in forty-six per cent. spirit and finally preserved in spirit of the strength of ninety-two per cent. (ordinary methylated spirit). To obtain a very firm tissue it was left from seven to ten days in one fifth per cent. chromic acid, and then from two to five days in the weaker spirit, before being transferred to the stronger.

To obtain sections which would show the lymph-corpuscles clearly differentiated from the other tissues, the stomach and intestine were hardened only four days in one sixth per cent. chromic acid, and then four days in the weak spirit, finally being placed in the strong.

##### *Hardening in Chloride of Gold and Chromic Acid.*

After washing the tissue in one tenth per cent. chromic acid, it was placed in one half per cent. gold chloride for four hours, and then in one sixth per cent. chromic acid from four to eight days, afterwards in the weak spirit one to two days, and finally removed to the strong.

##### *To obtain the Intestine of an Animal during the Absorption of Fat.*

Milk, or milk and cream, were given the animals to drink; or the cream was injected into the intestine (the latter was the plan pursued with hedgehogs), the animal in either case being killed one or two hours afterwards.

##### *Osmic-acid Staining.*

The following modification of BASCH'S (46) method was employed:—The ligature intestine was placed in warm MÜLLER'S fluid for twenty-four hours, and at the end of that time small portions were washed in one tenth per cent. osmic acid, and then placed in one to one half per cent. osmic acid for twenty-four hours; they were further hardened in one sixth per cent. chromic acid for six or eight days, left in weak spirit for two days, and afterwards transferred to the strong spirit. The latter was saturated with fat (oil and wax), so that the spirit might not dissolve the fat of the preparations.

##### *Staining of Specimens.*

The specimens (with the exception of some which were treated by osmic acid) were

stained in a solution of hæmatoxylin. They were left in a strong solution from six to twelve, or even thirty hours. The solution of hæmatoxylin was made in accordance with the receipt given by Dr. KLEIN in the 'Quarterly Journal,' Oct. 1873.

#### STRUCTURE OF THE MUCOUS MEMBRANE OF THE INTESTINE.

##### *The Epithelium, and the Reticulum and Lymph-Corpuscles among the Epithelial Cells.*

On viewing a section of the vermiform process of the rabbit, many small round cells will be noticed among the epithelium covering the apices of the lymphatic follicles. These cells are exactly similar to those in the follicles. They may be situated among the epithelium, as if that tissue were to some extent infiltrated by them; or they may have possession of at least the lower half of the space which ought to be occupied by the epithelium, as in Plate 39. figs. 1 & 2, where they are seen as two or more layers above the basement membrane, the epithelium being apparently eaten away at its lower extremity by the round cells. If the section be a favourable one, and very deeply stained, it will be seen that processes from the dark line on which the epithelium appears to rest run up between the epithelial cells; and where this is the case the epithelium which covers the follicle contains a tissue similar to that found within the follicles. (Identical appearances are met with in the epithelium covering the follicles of the tonsil\*.) Thus we find that the epithelium contains a tissue consisting of a reticulum containing in its meshes lymph-corpuscles.

If, now, sections of the epithelium covering the villi or the villus-like processes of the large intestine be examined in any animal, it will easily be seen that the epithelium contains lymph-corpuscles similar to those in the follicles (see fig. 13). It is specially easy to demonstrate this fact in the intestine of the rabbit and sheep. In preparations treated by chromic acid and stained in hæmatoxylin, these cells are seen to consist of a small zone of unstained protoplasm surrounding a very deeply stained spherical nucleus. *In the following pages I intend to apply the term "lymph-corpuscles" only to these cells.*

Again, if the villi of a recently killed rabbit be examined (either in the fresh state, in saline solution of three quarters per cent., with the addition of weak acetic acid, or after having remained in one per cent. bichromate of potash from two to six days), it is easy to show that the lymph-corpuscles are scattered everywhere among the intestinal epithelium; and it is equally easy to show, if the epithelial cells be separated from one another by teasing, that the lymph-corpuscles are not found within the epithelial cells, but lie between them. Thus ARNSTEIN (40) was mistaken in supposing that these corpuscles were ever contained within the epithelium†.

\* HENLE long ago noticed that the epithelium which covers much developed "agminated glands" of the conjunctiva is thinner from an infiltration of the gland-substance ('Eingeweidelehre,' 1862).

† Some observers have described Psorospermia as existing within the epithelial cells (KLEBS, VIRCHOW'S 'Archiv,' Bd. xvi.). There is considerable difficulty in deciding the exact relations in tissue so abnormal as that where Psorospermia are present in any great number; but there is no evidence in my preparations of

If the epithelium which has lain in weak bichromate of potash is teased (and it is best to select the intestine of the rabbit, as in that animal the epithelial cells are more easily separated), the idea that they have processes will soon be refuted. They are seen to be somewhat conical, the lower smaller end being slightly broadened at its termination, as was first shown by BILLROTH (36). Attached to them are shreds of the reticulum\*, which always separate with the epithelial cells from the rest of the mucosa. In these preparations rarely, if ever, will an epithelial cell with two nuclei be found: the lymph-corpuscles attached to individual cells may give that impression, but in such a case, by pressing on the cover-glass, and so rolling over the epithelial cells, the attached corpuscles will be seen indenting the wall (see fig. 3). This indentation of the wall has been shown in the drawings of EBERTH (33) (fig. viii. *a* and *b*) and ARNSTEIN (40).

The epithelial cells are closed: perhaps the easiest way to show this is to add weak acetic acid to epithelium of a freshly killed animal, examined in saline solution. If the action be pushed far enough (*i. e.* until the cells are almost transparent and the nuclei very much marked) the well-known seam will be pushed up in the form of a segment of a circle, as has been shown by so many observers, or it may be raised up *en masse*.

Sections of frog's intestine show great differences in the length of the epithelial cells in the same animal; and, as a rule, the epithelium in the rectum is longer than that of the upper parts of the intestine. Any good section will show epithelial cells with processes nearly, if not quite, as long as those figured by HEIDENHAIN (37) and others (see Plate 42. fig. 34, of the epithelium of the stomach of the frog). Considerable differences of length will also be met with in the epithelial cells of the intestine of mammals, partly due to the presence of structures which will be discussed hereafter, under the title of "*Epithelial Buds*" (see Plate 39. fig. 13), and partly due to the fact that the epithelium covering the upper surface of the villi and the upper surfaces of the processes in the large intestine is much shorter, as a rule, than elsewhere.

On examining the projections of the mucous membrane in a section of the vermiform process of the rabbit, fine, almost thread-like processes from the dark line on which the epithelium rests may be seen running among the epithelial cells. This dark line (see figs. 9 and 13, *r*), as we shall see afterwards, is due to the sectional view of the connective-tissue reticulum, which lies surrounding the epithelial cells, and on which they rest.

Again, if sections of villi or folds of the mucosa be examined where the epithelial cells have been cut horizontally near their base (see Plate 40. fig. 4), the polygonal areas of the epithelial cells are seen, and between them very deeply stained bodies (fig. 4, *r*), which

---

rabbit's intestine (see Plate 39. fig. 1) for concluding that they are ever contained in the epithelial cells; but, on the contrary, they are probably situated between the cells, the latter being pressed to one side by the invading Psorospermia.

\* This reticulum will shortly be discussed.

rarely show a nucleus. These bodies, by their processes, form a continuous network (or reticulum), the epithelial cells being contained in the meshes.

This reticulum stains very deeply in gold or hæmatoxylin; and in oblique sections it can be demonstrated that the dark line which is present below the epithelium in vertical sections is due to the presence of these bodies, *i. e.* of the reticulum.

The same structures will be observed in a cross section of the epithelial cells of a LIEBERKÜHN'S crypt (see Plate 39. fig. 5, where the reticulum is seen to send processes horizontally round the epithelial cells as well as downwards to join with the reticulum of the mucosa). Thus the bodies forming the dark line are anatomically continuous with the reticulum of the mucosa, and are the uppermost layer of that reticulum. This can also be well seen in an oblique section of a villus, where we can similarly trace the continuity of the reticulum which surrounds the epithelial cells with the reticulum of the substance of the villus.

There is, however, a difference between the reticulum which is found among the epithelial cells and that which elsewhere pervades the mucous membrane, inasmuch as the nodes of the reticulum surrounding the epithelial cells are very broad, and the reticulum itself is very delicate, and this gives the appearance of small cells with branching processes (see Plate 40. fig. 4).

*Membrana Propria, of the Villi, and of the processes of the Mucous Membrane of the Large Intestine.*

For a long time I conceived that the dark line below the epithelium was the membrana (*r.* figs. 10 & 13, Plate 39); this was found not to be the case. In the colon large cells were seen to be situated below the dark line (see fig. 10); but there was no evidence in these preparations that they formed a membrane. On examining, however, some sections of the villi of a monkey, which were denuded of their epithelium, it was noticed that the villi are bordered by large cells with oval nuclei, that these cells are placed more or less closely together, and have somewhat the character of endothelial plates. In places these cells were found to form a membrane; this was seen if the cells were separated from the mucosa and viewed from above (see Plate 40. fig. 6). We notice in the figure that some of the capillary blood-vessels are attached to the membrane; this is always found to be the case. And we further notice that the membrane has gaps or holes in it. We can show that these gaps or holes are not artificial products, if we compare the section with others prepared and stained in exactly the same manner (see figs. 6, 7, 8). Fig. 7 shows the membrana of a LIEBERKÜHN'S crypt; fig. 8 gives the appearances of two alveoli of the mammary gland: neither in fig. 7 nor in fig. 8 is there any indication of holes in the membrane.

In these preparations of villi, devoid of epithelium and bordered by large cells, the dark line which is generally seen at the base of the epithelial cells can nowhere be found; and this teaches us that the reticulum forming the dark line at the base of the epithelium always breaks off with the epithelial cells, that its connexions with the epithelial cells are much more intimate than with the rest of the villus.

On examining villi which have lain three or four days in weak bichromate of potash, if the epithelium be removed, we see the cells forming the membrana (as in fig. 9). If the tissue is then stained in strong hæmatoxylin for some hours and afterwards teased, the membrane with its attached blood-vessels can be isolated, and we obtain similar appearances to those in fig. 6, which was drawn from a section of a hardened villus.

It has been mentioned that the blood-vessels are always attached to the membrana; the reason for this will be evident by referring to fig. 13 (*e*), where it is seen that the cells forming the membrana are not altogether flat plates, but partially surround the blood-vessels and form a kind of adventitia to them.

In examining sections of the villi of the following animals, a membrana propria, very similar to that of fig. 6, is seen—*i. e.* in the sheep, rabbit, rat, hedgehog, dog, cat, and frog.

#### *The Membrana of LIEBERKÜHN'S Crypt.*

If in sections this membrane be completely isolated from the surrounding structures and viewed from above, it is seen to be a structureless membrane with nuclei imbedded in it at regular intervals (see Plate 40. fig. 7).

On viewing an *oblique* section of a LIEBERKÜHN'S crypt, however (see Plate 39. fig. 5), the membrane is seen to be composed of large cells, the reticulum (*r*) resting on these cells (*e*), and sending processes between them. The cells have all the characters of an endothelium, and (as is the case with the membrana of the villi) the endothelial plates are really contained in the meshes of the reticulum.

#### *The disposition and terminations of the Muscles in the processes of the Mucous Membrane of the Rabbit's Colon.*

On viewing a slightly oblique section of one of the processes of the mucous membrane of a rabbit's colon (see Plate 39. fig. 10), we recognize the epithelium, the dark line below it, and the separate large cells of the membrana, as oval or roundish bodies; we observe also bands of muscle running up between the LIEBERKÜHN'S crypts, and separating into individual fibres. Many of these fibres will be seen apparently to end in the large cells below the epithelium (*m*, fig. 10); others will be found to end in connective-tissue processes, which are also seemingly attached to the cells of the membrana (*m'*, fig. 10). At first sight we are tempted to conclude that the muscles end in these cells; this is, however, not the case. In order to understand the relations of the muscle-fibres to the surrounding tissues, they must be studied in cross sections. This will best be done in sections at right angles to the muscularis mucosa (see fig. 12). Here we find certain points of resemblance to the transverse sections of the epithelial cells. Thus small branched bodies are seen which are attached to one another by their processes, the muscle-fibres being contained in their meshes. Is this appearance, then, due again to a reticulum? and, if so, can this reticulum be shown to be in anatomical continuity with that of the mucosa? Both these questions are answered by observing sections in which the



muscularis mucosa is cut obliquely to the direction of its fibres; we there find that the reticulum surrounding the fibres is continuous with that of the rest of the mucous membrane. The same thing may be noticed in cross sections of those fibres which are found in immediate contact with the chyle-vessel. Thus each muscle-fibre is ensheathed in a reticulum; and it is by this reticulum that the muscle-bands running up towards the surface are attached to the cells forming the membrana, or, more correctly, to the reticulum surrounding the cells forming the membrane. The method of their attachment to these large endothelial cells is well shown in fig. 11, where the ensheathing tissue (*r*) is seen to envelop one of the cells of the membrana (*e*). *The reader will notice that the reticulum must be considered not only as a network of threads, but as forming, to some extent, membranous investments.* Thus the muscle-fibres have membranous coverings, which are continuous with and are really part of the reticulum; and the same may be said of the endothelial plates of the membrana.

*The Disposition of the Muscle-bundles and the Muscle-endings in the villi.*

In those villi of the monkey, hedgehog, or rat where there is only one chyle-vessel, the muscle-bundles run by its side, giving off individual fibres towards the side of the villus; and finally they either run straight on and end by being attached to the membrana at the apex of the villus (see fig. 13), or they may be arched slightly over the vessel, and then they will be attached to the membrana at a point on the opposite side of the villus. In the monkey the involuntary muscles form a membrane at least half-way round the chyle-vessel, and it is doubtful whether they do not entirely surround it; but of this I am not sure, as I have no good horizontal sections. This membrane, which is composed of a single layer of fibres dovetailing into one another, is in contiguity with the endothelium\*.

In the hedgehog the muscle-bands contain very few fibres, generally only two or three, so that only a small portion of the wall of the chyle-vessel is in contact with muscle-fibre.

In the rat the bands are reduced to the smallest dimensions, sometimes even to rows of single muscle-fibres slightly overlapping at their ends.

In the broad villi, as those at the commencement of the duodenum, in the dog and cat, and in the villi of the sheep, there are many bands running up the villi, which branch, anastomose, and finally end by being attached to the membrana†. I have one preparation of the sheep's intestine where one of the uppermost anastomosing bands, running nearly parallel to the surface epithelium, gives the appearance of a transverse band of muscles.

\* It is difficult at first sight to understand how fat can pass through this membrane to the chyle-vessel; we have, however, seen that each muscle-fibre is surrounded by the reticulum, and it will be further shown that the fat travels by that reticulum.

† KÖLLIKER (61) noticed that in the broad villi of the commencement of the duodenum and jejunum the muscle-bands are spread out like a membrane, and run from the base of the villus to the top.

From what has been explained before of the relation of the connective-tissue reticulum to the individual muscle-fibres, it will be easy to understand that the reticulum surrounding the bundle of fibres is attached to the reticulum of the mucosa, each fibre having here, as in the colon, its own ending: if the fibres end near the membrana, they may be apparently attached to the large cells composing it.

*Structure and Relations of the Blood-vessels of the Mucosa.*

These vessels have an adventitia—that is to say, in sections showing the longitudinal course of the vessel, threads are seen attaching the vessel to the reticulum of the mucosa (see Plate 40. figs. 15, 17, and 18). There is, however, considerable difference in the arrangement of this adventitia as regards the arteries and veins.

First, as regards the arteries. In those places where the minute arteries have a distinct and continuous layer of involuntary muscle-fibres\*, as in the commencement of the duodenum in some animals (*i. e.* in the dog, rat, and hedgehog), the reticulum passes between and surrounds the involuntary muscle-fibres (see fig. 15). Whether the reticulum penetrates between the endothelial plates of the artery, I have been unable to discover.

In other parts of the mucosa we find arteries without a continuous layer of muscle-fibres—that is to say, the muscles are situated at some distance from one another; where that is the case, the reticulum surrounds the vessel much as it does in the former case (compare figs. 16 & 15).

A somewhat similar appearance to that in fig. 16 would no doubt be given by a longitudinal section of an artery in which the muscle-fibres were situated principally above or below the vessel, as in such a section most of the fibres would be cut near their ends; the fibres would then look like clear rings, and would show no trace of nucleus. That this explanation is, however, not suitable is proved by sections which are thick enough to show the whole vessel: by focusing up and down in these sections, we can assure ourselves that there is no continuous layer of involuntary muscle-fibres surrounding the artery, and that there are only a few fibres at rare intervals; and in such a preparation, on accurately focusing the lumen of the vessel, we obtain an appearance similar to fig. 16.

In the minute arteries of many villi there are no involuntary muscle-fibres at all; we shall, however, often be able to recognize the arterial character of these vessels by the marked adventitia.

Secondly, as regards the relations of the adventitia to the veins.

In the veins the adventitia is not so distinctly seen as a separate membrane; it can, however, be shown to exist, and an adventitia is present here in the same sense that an adventitia may be said to surround the involuntary muscle-fibres. See fig. 18, where in places the reticulum surrounding the vessel is seen, and compare figs. 17 & 18.

\* DONDERS (12) noticed ring-shaped nuclei around the arteries in the villi.

Not only does the reticulum surround the endothelium, *but we can also show that it penetrates between the individual endothelial cells.* This is seen if we examine a longitudinal section of a broad vein, and view the inner surface of the vessel from above: see Plate 40. fig. 19, where we find a delicate reticulum between the individual cells. Nor must we be surprised that the reticulum is very delicate, as it has been shown that membranes, when viewed from the surface and separated from the rest of the tissue, show no trace of the reticulum (see figs. 6 & 7), although in oblique sections of these membranes *in situ* (as in Plate 39. fig. 5), as we have seen, it is quite easy to demonstrate a reticulum among the separate endothelial cells.

It has already been mentioned that the cells of the membrana propria partially surround the superficial capillaries.

### *The Character and Relations of the Chyle-vessels of the Villi.*

In the cylindrical villi the central canal is somewhat club-shaped, the lower end being much narrowed. The villi of the hedgehog are best adapted to demonstrate the chyle-vessels in sections, as in that animal they are very large, and are not surrounded by many involuntary muscle-fibres.

The walls of the chyle-vessels are composed of endothelial plates. The relation of the reticulum to the chyle-vessels is almost exactly similar to its relation to the veins; *i. e.*, in longitudinal sections of the vessel, threads are seen attached to the wall, which are continuous with the reticulum of the mucosa (see Plate 41. fig. 22), whereas, on viewing the vessel from above, there is seen to be a delicate reticulum penetrating between the endothelial plates (see fig. 20).

If the chyle-vessel be cut rather obliquely, as in fig. 21, we notice that the reticulum surrounding the cells of the mucosa is continuous with that which envelops the endothelial plates. This specimen was drawn from a villus situated above BRUNNER'S glands in the dog: it will be seen that in the upper part of the chyle-vessel the cells of the villus and the endothelial plates of the chyle-vessel are continuous.

In sections of the cylindrical villi, if the cells of the tissue have been accidentally removed, threads of the connective-tissue reticulum are seen attaching the upper widened end of the chyle-vessel to the membrana (see Plate 39. fig. 14).

### *The Tissue composing the Mucosa.*

The mucous membrane contains no fibrous tissue. Probably the involuntary muscle fibres, with their intervening threads of reticulum, have been mistaken for it.

The mucosa is everywhere composed of a reticulum and of cells held in its meshes. Wherever the intestine contains lymphatic follicles, it can be shown that the reticulum of the follicles is continuous with that of the rest of the mucosa; and there are many places in the mucosa where the cells contained in the meshes of the reticulum are only lymph-corpuscles.

What, then, is the tissue of a villus? Is it the same as that of the rest of the mucosa, as is often assumed? And is the tissue of the mucosa the same as that found in a follicle

of a PEYER'S patch? It is very important to be clear on this point, as it is certain that fat-absorption cannot be properly understood unless we perfectly understand the structure of the villi, a fact which has been much lost sight of. The difference between the tissue of the villus on the one hand and of a follicle of a PEYER'S patch on the other, is not to be found in the reticulum (which is identical or very similar), but in the cells contained in that reticulum.

In the lymphatic follicles, and in parts of the mucosa, the cells are entirely lymph-corpuscles\*. In the villi, though lymph-corpuscles are always present and may be almost the chief constituent (as in the sheep), or an important constituent (as in the rabbit), yet in some animals they are few in number (as in the dog and cat), or even rare (as in the monkey), in this situation.

What, then, is the character of the cells of the villi? They are polygonal cells composed of a very pale protoplasm with an oval nucleus. These cells differ from lymph-corpuscles:—first, in size, they are more than twice as large; secondly, they differ in having a large zone of protoplasm around the nucleus; and thirdly, they differ in regard to their nuclei, which are oval and stain very lightly, as contrasted with the spherical deeply staining nuclei of the lymph-corpuscles. Let the reader compare the two kinds of cells in fig. 13 (Plate 39). Nevertheless, as can be seen in fig. 21 (Plate 41), the cells of the upper part of the villus are larger than those near the base; and it is no doubt true that there is every transitional form between the lymph-corpuscles of a lymphatic follicle and the cells of the upper part of the villus.

These cells of the villi are seen in sections to be arranged almost like an endothelium (see figs. 21 & 22); and in the upper part of the villus they are very similar to the endothelial cells of the membrana propria, of the veins, and of the chyle-vessel. See fig. 13, where the cells of the villus are not to be distinguished from those of the membrana propria; and see fig. 19, where there is great similarity between the endothelial cells of the vein and the cells of the villus. We have already noticed in fig. 21 that in the upper part of the villus the endothelial cells of the chyle-vessel and the cells of the villus are continuous and similar.

We have seen above that the mucosa is composed of a reticulum containing cells in its meshes; these cells are (*a*) lymph-corpuscles and (*b*) large flat cells similar to endothelial cells: the latter may therefore be considered to be connective-tissue corpuscles. We have further seen that there is a gradual transition from the one kind of cell to the other.

It has now been demonstrated that there is everywhere a reticulum holding all the elements of the mucous membrane in its meshes; and if this account of the minute anatomy of the mucosa be correct, fat-absorption can only take place by means of the reticulum, or by the cells, or through both. Though my researches on fat-absorption have not been numerous, yet, as they show the fat to be in a reticulum, and as that reticulum is attached to the muscles and to the chyle-vessels in exactly the same way

\* I have already defined the cells which are spoken of in this paper as lymph-corpuscles. See page 459.

as I have shown that the reticulum is attached in preparations hardened in chromic acid, I conceive them to be sufficiently convincing.

*Fat-absorption by the Reticulum among the Epithelial Cells.*

To obtain preparations showing the fat between the epithelial cells, an animal was killed during the absorption of fat, and the intestine hardened in osmic acid, according to the methods given above; small portions of the mucous membrane were teased. The teased preparations were then treated with a dilute solution of caustic potash, until the tissue became much more transparent; they were then placed in glycerine. If, in such a preparation, a horizontal view of separated epithelial cells be examined, it is seen that fat-granules are arranged in lines between the cells, the epithelium being free from fat-particles (see Plate 41. fig. 23).

In examining sections of an intestine hardened as above, if we view the epithelium where it has been cut transversely, we have appearances very similar to those we have just described, *i. e.* the fat-granules are arranged in lines between the epithelial cells. If in the section the epithelium be cut vertically, although there are distinct lines of fat-granules between the cells, yet, as a rule, the appearances are not so satisfactory, as the cells appear to contain particles of fat.

Examination of teased preparations will show isolated epithelial cells apparently filled with fat, as has been figured and described by so many observers. It must, however, be remembered that the reticulum always breaks off with the epithelium, and that it is difficult to decide whether the fat which we see apparently in the epithelial cells is lying in them or in the shreds of reticulum attached to them; by pressing on the cover-glass and rolling over these isolated epithelial cells, the fat is generally seen to be arranged in lines along their borders.

*From the foregoing observations I have concluded that there is proof that the fat travels by the reticulum between the epithelial cells, but that there is no decisive evidence that fat-granules are absorbed by the epithelial cells.*

This reticulum has been seen and described by a great number of observers under various names. It has been seen in the most different epithelia; it has been shown to be capable of absorbing various substances; and there are some observations which prove that injections have penetrated into it.

Thus, REICH (109), PFLÜGER (62), HEIDENHAIN (110), LANGERHANS (63), GIANUZZI (64), BOLL (65), SAVIOTTI (66), EWALD (67), EBNER (68), LEYDIG (69), and LATSCHENBERGER (70), have seen it in the salivary glands or pancreas; while it was described as nervous tissue by REICH (109) and PFLÜGER (62), or as connective-tissue by BOLL (65), it was injected and considered to be intercellular salivary capillaries by GIANUZZI (64), LANGERHANS (63), SAVIOTTI (66), BOLL (71), and EWALD (67); LEYDIG (69) and LATSCHENBERGER (70) thought that there were only intercellular spaces between the cells; HEIDENHAIN (110) concluded that this tissue was a continuation of the cell-membrane; EBNER (68)

deemed it to be a cuticular formation which was probably connected to the *membrana propria*.

SCHWALBE (72) noticed the tissue in BRUNNER's glands; he spoke of it as secretion-capillaries with a coagulation of their contents.

Similarly GIANUZZI and FALASCHI (73) described interepithelial secretion-capillaries in the mammary gland.

This tissue was seen in the "*rete Malpighii*" of the skin as small branched bodies, staining deeply with gold: these bodies are probably connected with nerves: CHRSCHTSCHONOWITSCH (74), PODCOPAËW (75), and ELIN (76). This connexion was not made out by LANGERHANS (77), EBERTH (78), and EIMER (79).

This tissue was described in the intestine by FLES (53), ERDMANN (34), and ZAWARYKIN (56). FLES and ERDMANN considered it to be cement substance, and probably connected with the connective-tissue reticulum of the villus; while ZAWARYKIN spoke of it as the borders of the epithelial cells; ERDMANN and ZAWARYKIN noticed that absorption took place by this tissue.

Possibly this tissue was seen in the serous membranes by ÆDMANSSON (80) and DYBKOVSKI (81), who described openings between the endothelium of the serous membranes.

This tissue was described and figured by KLEIN (82) in the serous membranes, as pseudostomatous tissue. KLEIN considered this tissue to be of the greatest importance in absorption.

Probably it is this tissue which was seen in the lymphatic vessels, and described as stomata by HIS (51) and RECKLINGHAUSEN (83), and as stigmata by ARNOLD (84).

The same tissue was seen in the epithelium of the alveoli of the lung, and in the epithelium of the bronchi, by SIKORSKY (85), KLEIN (86), WITTICH (87), and KÜTTNER (88). KLEIN has figured it as intraepithelial nucleated branched cells in connexion with the connective-tissue corpuscles of the mucosa, the latter being in anatomical continuity with the lymphatic vessels.

Finally, it has been seen and described as cement-substance by ARNOLD (89) in epithelium of the tongue and palate of the frog.

Injections have been forced into it from the blood-vessels by CARTER (90) in many places, as in the palate of the frog and in the reticulum of the lymph-follicles of the intestine, in the epithelia of the skin and mucous membranes, and between the involuntary muscle-fibres of the arteries. By ARNOLD (89) also injections have been forced into it in many places; and by THOMA (91) a precipitation was obtained in it (in the living animal) by a natural injection.

Injections have also been forced into it from the lymphatics, by KOWALEWSKY (92) in the lymphatic glands, by DYBKOVSKI (81) in the pleura, and by BASCH (54) in the tissue of the villus.

This tissue has been found to absorb coloured fluid in recently killed animals, WITTICH (87), and in living animals, ZAWARYKIN (56), SIKORSKY (85), and KÜTTNER (88). ZAWARYKIN and KÜTTNER, in making experiments on the absorption of coloured fluids,

found that lines between the endothelial cells of the lymphatic vessel are marked out by the colouring-matter.

*Fat-absorption by the Reticulum of the Villi.*

A glance at figs. 24 & 25 (Plate 41) will give the appearances I have now to describe: these preparations are from the intestine of the hedgehog. The similarity of the reticulum (filled with small fat-granules) to that which is seen in preparations treated by chromic acid is obvious (compare figs. 21 & 22 with figs. 24 & 25). There is only one difference, and that is due to the different reagents. The reticulum is always broader in preparations which have been hardened in MÜLLER'S fluid and osmic acid, than it is in those preparations hardened in chromic acid or alcohol (see figs. 41 & 39, Plate 43).

*In conclusion, we find that the fat travels by the reticulum which is found everywhere among the other elements of the mucosa.*

I can confirm those observers who have asserted that LIEBERKÜHN'S glands absorb. There is, however, much less absorption from these glands than from the surfaces of the villi.

What are the forces causing absorption? No doubt the emptying of the chyle-vessel by the muscles surrounding it, and the subsequent erection of the villi, tend to promote absorption. Probably, however, absorption is not the purely mechanical process of particles of fat being pressed through a soft semifluid mass (the reticulum); on the contrary, it is more probable that the reticulum takes an active part in the process\*.

## CHAPTER II.

### THE MINUTE ANATOMY OF THE MUCOUS MEMBRANE OF THE PYLORIC END OF THE STOMACH.

#### HISTORY.

TODD and BOWMAN (32) first showed the great difference between the glands near the pylorus and those of the rest of the stomach. They found that the epithelial cells of the surface are continued into wide cylindrical tubes, which end in very short and diminutive tubes lined with a "subcolumnar" epithelium.

This difference between the glands of the pylorus and those of the rest of the stomach was confirmed by DONDERS (12) and KÖLLIKER (93).

KÖLLIKER (61) found bands of muscles from the muscularis mucosa running between the glands even into the plicæ villosæ.

KLEIN (94) explained the manner in which the bands of muscle in the lower part of the mucosa decussate, "forming a kind of pocket" . . . "embracing the several tubes." He found that some of the fibres "extend as far as the epithelium."

EBSTEIN (95) first accurately described the character of the cells of the proper gland-

\* BUSK and HUXLEY, in a note to the translation of the Manual of Human Anatomy by A. KÖLLIKER, 1854, said, "We should rather compare the manner in which fat enters a villus to that in which the ingesta enter an *Actinophrys*."

tubes, and he also described the changes occurring in digestion. This paper will be referred to again.

LOVÉN (96) discovered lymph-vessels in the mucosa of the stomach extending into the plicæ villosæ.

RABE (97) noticed that, in the horse, the glands are of uneven length, and that this gives the mucosa a somewhat wavy surface.

*The general structure of the Mucous Membrane.*

If we harden the pyloric end of the stomach of a dog in chromic acid and examine the surface with the naked eye, the mucosa, with the exception of a few large folds, presents a somewhat smooth surface. On examining this apparently smooth surface more carefully with the aid of a simple lens, we shall find that it is formed of a number of minute elevations and depressions. The principal elevations are parallel to the transverse axis of the stomach; but they communicate by short branches running in the longitudinal direction, and thus they form a network of irregularly shaped meshes\*. On making a longitudinal vertical section of the pylorus, these elevations are seen to be rounded, and give the mucous surface a wavy aspect.

We notice, in the section, that the upper part of the stomach-tubes which open on the summit of these elevations is straight, and that the plicæ villosæ between the tubes are straight and long; whereas the tubes which open into the depressions are shorter and wider, and their sides are folded (see fig. 26, Plate 42, where we find alternations of long straight tubes and of short tubes); and these appearances are very like those which EBSTEIN (95) has given in his fig. iv. and fig. iii. as representations of the stomach of a dog in stages of sponge feeding and of vegetable feeding respectively.

These wave-like elevations of the mucous membrane of the stomach with the accompanying differences in the length of the tubes are seen in dogs killed in all stages of digestion and hunger, and they are therefore to be considered a constant feature of the dog's stomach.

This feature is, however, not always well marked, if the stomach has been hardened in alcohol; and it was completely absent in the stomach (hardened in alcohol) of a dog which had been fed on sponge after the manner of SPALLANZANI and EBSTEIN (95).

It has been found that, as a rule, the mucosa is more contracted in digestion than in hunger; this is also true of the plicæ villosæ, which are more expanded in sections made from the hardened stomach of an animal killed while fasting, than in sections made from an animal killed during digestion.

The wave-like elevations of the surface of the pyloric end of the stomach are well marked in those animals which have very compound glands and much convoluted gland-tubes, as in the dog and horse. In the monkey, rabbit, and hedgehog these foldings of the surface are much less marked. In the rat the tubes are of even length, and the surface of the stomach is quite smooth.

\* KÖLLIKER (44) has described a network of folds on the surface of the pylorus.



If we examine a vertical section of the pylorus, we notice that the epithelium of the surface is continued downwards into wide cylindrical tubes (*d*, fig. 26, Plate 42). These tubes divide, at their lower extremity, into two short branches, and into each of these short divisions two or three small branching twisted tubes (*ct*, fig. 26) open from below. That part (*d*) of the stomach gland-tubes which is lined by cylindrical epithelium will be called the duct. The smaller tubes (*ct*) will be called the proper glands or coiled tubes.

*The Epithelium covering the Pyloric end of the Stomach.*

TODD and BOWMAN (32) thought that when the cells have arrived at maturity the granular contents escape "by a dehiscence or opening of the wall at that part," "leaving the transparent husk with its nucleus subsisting for some time longer." The clear structureless mucus which occupies the cells and covers the surface "seems to be altered contents" of the cells.

F. E. SCHULZE (98) spoke of the cells as being open above; he showed that by the action of some fluids the contents of the upper part of the cells swell to a very voluminous mass.

EBSTEIN (95) thought that the cylindrical epithelium has closed ends; that in digestion these cells, owing to extreme mucous metamorphosis, burst, and are then open above.

I have found that in certain stages of secretion these cells are open; but if the animal has been kept some time without food, the substance of the cell is definitely bordered. This can be demonstrated by examination of the stomach of a recently killed rabbit which has been kept twenty-four hours without food. The stomach is to be placed in five per cent. salt solution for one hour, and then examined in saline solution of three quarters per cent. We shall then see that the epithelium is closed. On adding weak acetic acid, all the cells pour out a large quantity of semifluid substance and become goblet-cells. I must therefore agree with TODD and BOWMAN (32) and EBSTEIN (95) in considering the cells to be closed; but differ from F. E. SCHULZE (98) and BLEYER (99), who hold that they are always open.

*Germination of the Epithelium.*

Almost all the phenomena which will be described under this heading are equally true for the epithelium of the intestine. They will be described in connexion with the stomach, because I first noticed the method of increase in the epithelium of the *plicæ villosæ*, and because the accompanying drawings have been made chiefly from that region.

(A) If the stomach has been stained in gold and hardened in chromic acid, *many of the epithelial cells covering the surface will be found to contain nuclei in a state of division* (see fig. 27, Plate 42)\*. It is noticed that the division does not seem to take place according to any strict law, as some of the nuclei are divided transversely, some longitudinally, and some obliquely.

\* This preparation is from the colon of the rabbit; the appearances are very similar to those in the stomach.

(B) In preparations hardened in chromic acid, *small cells are found at the base of the epithelium*. This fact was described by TODD and BOWMAN (32), who seem to have thought that a second layer was always present. F. E. SCHULZE (98) (Taf. x. fig. vi.), EBSTEIN (95) (fig. i.), and BLEYER (99) have also described small cells at the base of the epithelium.

These cells are of two kinds:—first, lymph-corpuses similar to those which have been described among the epithelial cells of the intestine (see fig. 28, Plate 42); and secondly, rounded or conical cells which are only found at the base of the epithelium (see figs. 29 and 32)\*. These latter cells have a faintly granular protoplasm, and contain spherical nuclei which are not readily stained by hæmatoxylin. These cells may therefore be distinguished from the lymph-corpuses, which have been already described as consisting of a small clear zone of protoplasm surrounding a very deeply stained spherical nucleus (compare fig. 28 and fig. 29).

(C) In similar preparations *we find short broad epithelial cells*, showing a faintly staining cell-substance containing a large pale nucleus, which may be divided (see fig. 30).

(D) And, finally, we see *groups of epithelial cells composed of two or three, or even more, cells arranged very much like a bud* (see figs. 13, 31, 33, where it will be seen that the base of the group of cells projects slightly into the mucosa). These groups of cells are the structures which I propose to call “epithelial buds.”

The same features are seen in the small round or conical cells of figs. 29 & 32, and in the short broad cells of fig. 30, and in the epithelial buds of fig. 33. These features are a spherical nucleus, as opposed to the oval nucleus of ordinary epithelium, and a faintly granular protoplasm of the cells, which is not easily stained by hæmatoxylin.

Now it seems to me reasonable to form the following conclusions from the appearances described at (A), (B), (C), (D):—that the epithelial cells divide; that the small rounded cells of figs. 29 and 32 are the products of their division; that these small cells, increasing in size and rising up among the older cells, push them to one side, and form the short broad cells as represented by fig. 30; and that these short broad cells, by division, form the bud-like structures of figs. 31 & 33. The view that the buds are caused by division is favoured by the appearance of the epithelial cells next to the bud-like groups. They are always compressed together, are deeply stained in hæmatoxylin, and contain a considerable amount of mucus.

\* Fig. 29 is drawn from a preparation which had been stained in hæmatoxylin; the upper part of the cells is seen to be intensely stained, and in the original preparation was of a deep blue colour. The cells are open and contain mucus. It is the mucus which has been stained so readily. That mucus is very readily stained a blue colour by hæmatoxylin, has been shown by me in a short note to the Royal Society (Proceedings, vol. xxii. p. 293). I have there described the different manner in which the cells of the mucous glands of the tongue are acted on by staining fluids, in states of inanition and secretion. Specimens stained first in hæmatoxylin and then in carmine showed that during inanition the cells contain mucus, and their contents are more easily stained by hæmatoxylin than by carmine; whereas during secretion the carmine will stain the cell substance more readily than hæmatoxylin; any mucus in the ducts of the glands is, however, stained an intensely blue colour.

The bud-like groups are sometimes found of considerable size, and, when this is the case, they call to mind the foldings of the epithelium, which have been described in the intestine by DONDERS (12) and KÖLLIKER, and figured by TODD and BOWMAN\*; they have also been figured by EBSTEIN† in the stomach. These buds are found, however, not only on the sides of the villus-like processes of the stomach, but also on the flattened surfaces of those processes; and they are seen among the epithelium covering the sides of the villi of the intestine, or on the sides of the plicæ villosæ, where there is no apparent folding of the epithelium. If, however, the short plicæ villosæ (in the depressions between the wave-like elevations of the stomach) be examined (see fig. 26, Plate 42), the epithelium is seen to be in folds, giving the appearance of large buds. Whether we have here one of the plicæ villosæ, temporarily shortened by the contraction of its muscles, with a consequent folding of the epithelium, or whether we have some more permanent process associated with repair, I have no evidence on which to decide.

These bud-like structures are found in great numbers in young animals, and at first it seemed possible that these buds were the means whereby the epithelium increases in growing animals; and possibly it may be so, as REMAK (100) has observed in the intestine the increase of epithelium by longitudinal division. These buds may, however, be seen in the epithelium of animals which have attained their full maturity, as was proved by sections made from the stomachs of five dogs, of the ages of two years and upwards. I consider, therefore, that these bud-like structures are concerned in the repair of the epithelium, and that this repair is constantly needed during the life of the animal.

The foregoing results were obtained from a great number of observations, and were chiefly made from sections of the stomach of the dog. I have, however, one preparation from the pyloric end of the frog's stomach (Plate 42. fig. 34), which may possibly be explained by the view that DONDERS (12) and KÖLLIKER (93) took of the regeneration of the epithelial cells—*i. e.* “that the cylindrical cells of the intestine not unfrequently burst at their apices, and allow a part of their contents (mucus) and their nucleus to pass out; a second, previously formed cell-nucleus then serves for the regeneration of these cells; . . . these are the cells designated by GRUBY and DELAFOND ‘epithelium capitatum,’ *i. e.* goblet-cells.”

#### *The Connective-tissue Reticulum among the Columnar Epithelium.*

This reticulum is, in its character, exactly like that which has been already described among the epithelium of the intestine, and can be best seen among the epithelium of the ducts (see fig. 35, Plate 43). It is much harder to demonstrate its occurrence among the epithelium of the surface of the plicæ villosæ; and though it does exist even among that epithelium, it is very fine and delicate, and does not appear to reach the surface. There is, however, an intercellular substance uniting the upper surfaces of the epithelial cells, which differs very materially from the connective-tissue reticulum, in the fact that it does not stain at all in hæmatoxylin.

\* *Loc. cit.* fig. 159.

† *Loc. cit.* fig. iii.

*The Character of the Membrana Propria.*

The membrana propria of the surface of the villus-like processes is formed of endothelial cells. In section they are seen as oval or rounded cells; on surface view they appear as polygonal plates. I have never been able to separate the membrana from the rest of the mucosa. The membrana of the ducts, when seen from the surface and completely isolated from the surrounding structures, is exactly like that of LIEBERKÜHN's crypts, namely, a structureless membrane, with oval nuclei imbedded in it at intervals.

*The Muscle-endings in the Plicæ Villosæ and the Perivascular Spaces.*

In specimens hardened in chromic acid, the muscles arising from the muscularis mucosæ are seen passing up between the glands and entering the plicæ villosæ. If these villus-like processes of the mucous membrane are very narrow, two bundles of muscular fibres will be seen, one on each side of a central clear space, and in contiguity with it. The muscle bands running up to the tops of the plicæ villosæ and spreading out, end by being attached to the membrana; some of the fibres may cross above the clear space, or pass to the side of it to be attached to the membrana of the other side of the villus-like process; the mode of their attachment is exactly like that which has been already described in the colon of the rabbit (compare fig. 36, Plate 43, with fig. 10, Plate 39).

The clear space enclosed by the muscle bands is seen to contain a blood-vessel, and is formed of endothelial plates.

The blood-vessels in the narrower plicæ villosæ run vertically, but, at times, they bend horizontally. If in the section they bend towards the observer, the blood-vessel is seen to be surrounded by a clear ring (perivascular space). In the broad villus-like processes where the blood-vessels run in a direction parallel with the surface, the upper wall of the perivascular space is formed by the membrana propria: thus we have here an arrangement somewhat similar to that described by BOLL (71) and LEYDIG (69) in the salivary glands, and by LUDWIG and TOMSA (101) in the testicle, namely, a blood-vessel enclosed in a perivascular space, one wall of which is formed by the membrana propria, the membrane supporting a secreting epithelium.

These perivascular spaces are probably the same as those lymph-vessels of the stomach which have been injected by Professor LOVÉN (96) by the method of puncture (*loc. cit.* figs. iv. & x.).

In the broad villi great numbers of muscle-fibres are always present; and fig. 36 shows how they form membranous layers, which lie in contiguity with the endothelial plates of the perivascular membrane. This arrangement reminds us at once of the relation of the muscle-fibres to the walls of the chyle-vessels of the villi in the monkey. The action of the muscles on the plicæ villosæ will be twofold: when they contract they will shorten the villi, and further they will cause them to become smaller in their transverse diameter. This follows from the disposition of the bands of muscle: they expand in a fan-like manner in the upper part of the villi, some of the fibres crossing over to be attached to the other side.

*The proper Gland-tubes of the Pyloric end of the Stomach.*

These tubes contain a different epithelium to that in the ducts, as EBSTEIN (95) first pointed out. He described the character of the epithelium of these glands in animals killed while fasting and also during digestion; he found that in the former case the cells are composed of a transparent, faintly granular cell-substance, the nuclei being situated at the base of the cells (*loc. cit.* fig. ii.); in the latter case the cells become cloudy with granules, are shrunken, and are deeply stained by carmine or anilin; and EBSTEIN has figured (figs. iii. & iv.) the nuclei as spherical in form.

If, in a vertical section of the stomach, we examine a part of one of the coiled tubes running vertically, and view the tube from the outside, we notice between the epithelial cells a fine reticulum, similar to, but much finer than any we have seen before (see fig. 37, Plate 43). The nuclei of the epithelial cells are seen from this point of view as circular bodies, and are stained very slightly by hæmatoxylin, the cell-substance hardly being stained at all; the reticulum is deeply stained. If in the section we find a tube which has been cut transversely (so that the epithelium is cut vertically), we notice the separate epithelial cells resting apparently on the basement membrane, and we find a dark line at the base of each cell (see fig. 38, *a*). To what is the dark line due? No doubt, in some measure, to the nuclei; and we should expect the flat circular nuclei when seen from the side (that is to say, when the light has to pass through their long diameter) to intercept the light more than when viewed from above or below. But that the dark line is due to something else than the nuclei, is easily seen where the cells are placed rather obliquely to the line of the section (see fig. 38, *b*). Here we can partly see the nuclei, and yet the dark lines are present. In sections which have cut the epithelial cells more obliquely, we find that the dark line is partly formed by the connective-tissue reticulum (see fig. 39). It has been already mentioned incidentally in Chapter I. that the reticulum is more marked in specimens which have been hardened in MÜLLER'S fluid and osmic acid than in those which have been hardened in chromic acid (let the reader compare figs. 39 & 41).

This reticulum has been seen by SCHWALBE (72), who spoke of it as a network of canals, a layer of granular cell-substance being found between the membrana and the polygonal network; he also found the nuclei not within the meshes of the network of canals, but lying over one of the meshes (*loc. cit.* fig. xiii.).

It has been mentioned above that EBSTEIN (95) has figured the nuclei of these cells as spherical in form in animals killed during digestion. I have examined a great many dogs in various stages of digestion, hardening their stomachs in chromic acid, and, with very few exceptions, the nuclei have been found as flattened disks, lying at the bottom of the cells, as in fig. 38. Sometimes, it is true, the nuclei are seen to be spherical, as in figs. 39 & 40; but this never occurs over any considerable tract of the stomach. I can, however, confirm EBSTEIN'S statement that the cells are more granular and stain more readily during digestion than during inanition. In tissue which has been washed in one tenth per cent. chromic acid and immediately placed in alcohol, I have equally failed to find the nuclei as spheres in the cells of animals killed during digestion.

Besides these two forms of nuclei, a third is sometimes met with (see Plate 43. fig. 40, *b*). There appears to be here some process of vacuolation of the nucleus; and this form is possibly an intermediate state between the disk-like and the spherical form of nucleus. Cells with nuclei in a state of vacuolation are not very frequently met with. They have been only found in animals killed during digestion.

The membrana of the coiled tubes is exactly similar to that of the ducts of the tubes or that of LIEBERKÜHN'S glands.

I must leave to another paper any complete description of fat-absorption in the stomach, only observing that in sucking animals the epithelium covering the surface is seen apparently completely filled with fat. This fact was noticed by BRUCH (102) and KÖLLIKER (103). In fully developed animals no fat can be observed in the epithelium covering the surfaces of the plicæ villosæ; but the epithelium of the ducts and of the coiled tubes appears cloudy with fat, and this is much marked in animals whose stomachs contain bile. It is not intended by the foregoing remarks to give any opinion as to the method of fat-absorption in the stomach.

The occurrence of lymphoid follicles in the mucosa will be discussed in the next chapter.

### CHAPTER III.

#### THE MINUTE ANATOMY OF THE MUCOUS MEMBRANE AT THE POINT OF TRANSITION BETWEEN THE STOMACH AND INTESTINE.

In the following Chapter the anatomical continuity of BRUNNER'S glands with the coiled tubes of the stomach will be described. But before proceeding to the relation of the facts a short account of the history of the subject will be given.

BRUCH (104), 1849, spoke of racemose or acinous glands of the pylorus, which pass into the acinous glands of the duodenum (BRUNNER'S glands).

ECKER (105), 1852, said that the racemose glands of the portio pylorica form an obvious transition to BRUNNER'S glands.

This fact was either overlooked or denied until

COBELLI (106), 1864, found, in the pyloric end of the stomach of man, branched mucous glands and acinous glands. The acinous glands are arranged in rows or little heaps radiating from the pylorus. At the commencement of the intestine the glands of BRUNNER were found in the submucosa and in the mucosa; the muscularis mucosæ at this point is very incomplete; further down the intestine there is a definite muscularis mucosæ, and the glands of BRUNNER are only found in the submucosa. From these observations the acinous glands of the portio pylorica may be "considered as a continuation" of BRUNNER'S glands. In the rabbit and dog only mucous glands were found in the pyloric end of the stomach. In the cat and in the *Mustela putorius* acinous glands occur in the pyloric end of the stomach. In all animals there exists a short tract where the glands of LIEBERKÜHN are wanting, and where BRUNNER'S glands are

placed both in the submucosa and in the mucosa. Follicles were found at the commencement of the duodenum in the dog and cat.

SCHLEMMER (107), 1869, showed that BRUNNER's glands are tubular.

SCHWALBE (72), 1871, confirmed SCHLEMMER, and proved the great similarity between the epithelial cells of the tubes of the pylorus and those of BRUNNER's glands. He said that the cells of BRUNNER's glands are like those of the stomach-glands in active secretion.

HEIDENHAIN (108), 1871, agreed with SCHWALBE as to the tubular character of BRUNNER's glands, and their great analogy to the stomach-glands of the pylorus.

If the point of union of the stomach and intestine in the dog be examined with the naked eye, lymphoid follicles are seen to be present in varying number. In some dogs they are so numerous that they form a ring of about half an inch in breadth at the commencement of the intestine, the surface being almost completely covered by them.

In sections made at right angles to the plane of union of the stomach and intestine, it will be seen that the character of the epithelium of the surface changes quite suddenly. This change in the character of the epithelium indicates the point of transition between the stomach and intestine. In specimens hardened in chromic acid and stained in hæmatoxylin, we see on one side the regularly arranged cylindrical epithelium of the stomach, which in its upper part is clear and almost unstained; on the other we find the granular epithelium of the intestine, with goblet-cells at intervals. This change of epithelium is found not only on the surface but in the tubes, so that at this point the glands of LIEBERKÜHN may be said to commence. There is, therefore, no gradual change, but suddenly the ducts of the stomach-tubes leave off, and the LIEBERKÜHN's glands begin. This opinion is confirmed by preparations hardened in osmic acid, where it can plainly be seen that the ducts of BRUNNER's glands do not open into the crypts of LIEBERKÜHN, but run up between them, as has been represented in the figure.

In viewing the section made at right angles to the plane of union, we notice that the stomach-glands near the point of union are slightly different to those of the rest of the portio pylorica, the proper glands (coiled tubes) are more branched and convoluted, and the ducts are somewhat shorter. It will be further noticed that the coiled tubes are found penetrating (or even to some degree extending below) the muscularis mucosa. At about the point of union between the stomach and intestine, the coiled tubes will be found to break through the muscularis mucosa to a greater degree; and at the commencement of the intestine we shall find that there are as many of these tubes in the submucosa as in the mucous membrane. At this point the muscularis mucosa is generally rather indefinite, as it splits up, and portions of it run among the lobes of the coiled tubes. These tubes, from their situation, must now be called BRUNNER's glands. On examining the section still further down the intestine, but few coiled tubes will be found above the still somewhat irregular muscularis mucosa; while below it, BRUNNER's glands are more regularly arranged in the form of separate lobes. Still further in the section we find a continuous muscularis mucosa with numerous LIEBERKÜHN's crypts

reaching down to it, while BRUNNER's glands consist of smaller lobes entirely below the muscularis mucosa. Finally, the lobes are smaller and more isolated, and then cease.

In the mucosa, as has been already stated, lymph-follicles are found in varying number. They may form almost a continuous chain. The follicles are almost always situated above the line of the muscularis mucosa; occasionally, however, lymphoid tissue is met with in the submucosa, but it is very rare.

A considerable number of animals were examined, in different stages of digestion and inanition, to determine whether the follicles are always present. They were always present to some degree, but they appeared to be more numerous in those animals which had been kept for some time previously on a minimum of food, or had been kept without food for two or three days. Lymphoid follicles were occasionally present in the pyloric end of the stomach. The stomachs of over forty dogs were examined, and in the greater number no follicles were noticed. Whenever in any animal these follicles were present in great numbers at the point of union of the stomach and intestine, they were also present in the stomach. The follicles in the pyloric end of the stomach are very rarely found below the line of the muscularis mucosa.

Near the point of transition between the stomach and intestine the plicæ villosæ are very short and broad, and the commencing villi are equally short and broad. But while there is thus a gradual change, from the villus-like processes of the stomach to the short villi of the commencement of the intestine, the change in the tissue is sudden. This has already been described, so far as the epithelium is concerned, but it is also true of the stroma of the mucosa. Thus, at the point of union of the stomach and intestine, we may find two elevations of the mucous membrane, one of which is covered by an epithelium, and contains a tissue similar to that found in the plicæ villosæ; the other is covered by an epithelium, and contains a tissue similar to that found in the villi.

I have examined other animals besides the dog, for the purpose of ascertaining if it be generally true that BRUNNER's glands are anatomically continuous with the coiled tubes of the stomach.

The intestine and stomach of the horse have given perhaps the most certain proof that this is the case. In that animal the glands of the stomach are much branched, a great many coiled tubes leading into one duct. At the commencement of the intestine the coiled tubes do not, as in the dog and most other animals, become much increased in number, but pass very gradually into BRUNNER's glands. The proper tissue of the mucosa at the commencement of the intestine is very thin, and consists of minute villi and very short LIEBERKÜHN's crypts. Further down the intestine the proper tissue of the mucous membrane increases in depth, and that part of BRUNNER's glands which is situated above the line of the muscularis mucosa is diminished; finally, BRUNNER's glands are only found in the submucosa. These changes are so gradual in this animal that it is very easy to trace the different steps.

In the cat the same arrangement prevails as in the dog, and there are only slight differences in the hedgehog and rabbit.



In the rat BRUNNER'S glands begin very suddenly and are very much convoluted, while the stomach-tubes at the pylorus are short and straight. There seemed to be a difference between the epithelium of the lower part of the tubes of the pylorus and that of BRUNNER'S glands. This difference was not met with in any other animal. In the rat I was therefore unable to trace the continuity of the stomach-tubes with BRUNNER'S glands.

In the monkey the coiled tubes of the stomach gradually breaking through the muscularis mucosa become continuous with BRUNNER'S glands. There are, however, certain peculiarities in the intestine of the monkey, as small valvulæ conniventes are found from its commencement. BRUNNER'S glands are principally grouped in the submucosa of the valvulæ. In this animal the glands are so much separated that in sections it can be seen that they are not acinous, but are composed of compound tubes.

In man, sections were made from two cases obtained from the post-mortem room of persons dying after accident. It was found that the tubes of the stomach at the point of union with the intestine are placed obliquely to the line of the muscularis mucosa; they penetrate that membrane and become continuous with BRUNNER'S glands, as has been seen to be the case in other animals.

Numerous lymphoid follicles were found at the point of union of the stomach and intestine in man, and they were found in that situation to some extent in all the animals which were examined.

This lymphoid tissue has been shown to occur in very varying amount at this point of the alimentary canal in the dog, the mucosa being sometimes almost free from it, and at other times composed in a great measure of lymphatic follicles. This latter condition was found to be the case in dogs which were kept on a very low diet. I wish to lay particular stress on these facts, as this great excess of lymphatic tissue may in itself constitute a pathological condition, and may be connected with some of those pathological changes so frequently met with in this part of the alimentary canal.

#### EXPLANATION OF PLATES 39-43.

The outlines of many of the preparations were drawn with an OBERHAEUSER'S Camera Lucida: in such cases the lens used with the Camera Lucida and the approximate magnification are given. The ocular and objective which were used in completing the drawings are also given.

The preparations from which these drawings are made were hardened in chromic acid and alcohol, except where the contrary is expressly stated in the following explanations.

Fig. 1. HARTNACK ocular III., objective 9,  $\times 550$ .

Vertical section of part of a lymphatic follicle from the vermiform process

of a rabbit. The psorospermia and lymph-corpuscles are seen to have invaded the epithelium.

*Ps.* Psorospermia.

*Ep.* Epithelium.

*lc.* Lymph-corpuscles.

Fig. 2. Camera Lucida: obj. 7,  $\times 450$ . The drawing was completed by means of oc. III., obj. 9.

Vertical section of part of a lymphatic follicle from the vermiform process of a rabbit.

*lc.* Lymph-corpuscles.

Fig. 3. Oc. III., obj. 9,  $\times 550$ .

Epithelial cell with two attached lymph-corpuscles, from the small intestine of a rabbit. Teased preparation which had lain twenty-four hours in one per cent. bichromate of potash, and was then treated with dilute acetic acid.

Fig. 4. Camera Lucida: obj. 8,  $\times 600$ —oc. III., obj. 11 immersion.

Transverse section of epithelial cells of the surface of a villus, from the small intestine of a rabbit. The tissue had been stained in gold chloride and hardened in chromic acid.

The reticulum (*r*) is seen to surround the epithelial cells.

Fig. 5. Camera Lucida: obj. 8,  $\times 600$ —oc. III., obj. 9.

Oblique section of a LIEBERKÜHN'S crypt, from the small intestine of a sheep.

*r.* Reticulum.

*Ep.* Epithelium.

*e.* Endothelial cells.

*lc.* Lymph-corpuscles.

The reticulum (*r*) is seen to send processes around the epithelial cell (*Ep*), and between the endothelial cells (*e*) of the membrana propria.

Fig. 6. Camera Lucida: obj. 8,  $\times 600$ —oc. III., obj. 9.

The membrana propria of the villus with the attached blood-vessels, from a section of the small intestine of a monkey. The membrane is seen to be composed of cells; it has holes or gaps in it.

Fig. 7. Camera Lucida: obj. 5,  $\times 300$ —oc. III., obj. 7.

Membrana propria of the ducts of the stomach-tubes, from a section of a dog's stomach. The appearances presented by the membrana propria of LIEBERKÜHN'S crypts are exactly similar.

Fig. 8. Camera Lucida: obj. 5,  $\times 300$ —oc. III., obj. 8.

Two alveoli of the mammary gland, from a section of a mammary gland of a cat. The cells have been almost entirely shaken out of the membrana.

*Gc.* Remaining gland-cells.

The walls of the alveoli are composed of a framework of branching cells, united by a structureless membrane.

Fig. 9. Camera Lucida: obj. 5,  $\times 300$ —oc. III., obj. 7.

Villus of the small intestine of a rabbit: teased preparation. The intestine had lain four days previously in half per cent. bichromate of potash.

The large cells composing the membrana propria are seen bordering the villus.

*v.* Blood-vessel.

Fig. 10. Camera Lucida: obj. 8,  $\times 600$ —oc. III., obj. 11 immersion.

Section of one of the villus-like processes of a rabbit's colon. The epithelium is only drawn diagrammatically.

*v.* Blood-vessel cut transversely.

*r.* Dark line at the base of the epithelium formed by the reticulum surrounding the epithelial cells.

*m.* The muscle-fibres. They are seen apparently ending in the round or oval cells of the membrana propria.

Fig. 11. Camera Lucida: obj. 7,  $\times 450$ —oc. III., obj. 8.

Section of one of the villus-like processes of a rabbit's colon.

*m.* A muscle-fibre.

*r.* Reticulum.

*e.* Endothelial cells of the membrana propria.

Fig. 12. Camera Lucida: obj. 5,  $\times 300$ —oc. III., obj. 8.

Cross section of the muscularis mucosæ, from the rectum of a sheep.

The reticulum is seen to surround the individual fibres.

Fig. 13. Oc. III., obj. 8,  $\times 400$ .

Section of a villus, from the small intestine of a monkey.

*m.* A band of involuntary muscle-fibres. The connective-tissue reticulum surrounding the individual fibres is attached to the membrana propria.

*Ep.* Epithelium. The epithelial cells are seen to be of different lengths.

*r.* Dark line at the base of the epithelial cells caused by the reticulum.

*lc.* Lymph-corpuscle.

*e.* Endothelial cells of the membrana.

*v.* Blood-vessels.

The great similarity of the cells of the villus to the cells composing the membrana is seen.

Fig. 14. Oc. III., obj. 9,  $\times 550$ .

Section of the upper part of a villus, from the small intestine of a monkey.

*m.* Muscle-fibres.

*l.* Central chyle-vessel.

*v.* Blood-vessels.

Fig. 15. Camera Lucida: obj. 8,  $\times 600$ —oc. III., obj. 9.

Artery, from a vertical section of a villus from the small intestine of a hedgehog.

The reticulum is seen as a dark line surrounding the individual muscle-fibres.

*c.* Cells of the villus.

Fig. 16. Camera Lucida: obj. 8,  $\times 600$ —oc. III., obj. 9.

Artery, from a vertical section of a villus from the small intestine of a hedgehog.

The muscle-fibres surrounding the vessel only occur at rare intervals. The reticulum (*r*) is seen as a dark line surrounding the individual fibres, and, where these muscle-fibres are wanting, the reticulum forms an adventitia to the vessel.

The elongated nuclei of the endothelial cells are seen.

Fig. 17. Camera Lucida: obj. 8,  $\times 600$ —oc. III., obj. 9.

Vessel, probably an artery, from a section of a villus of the duodenum of a rat.

The reticulum forms an adventitia to the vessel.

Fig. 18. Camera Lucida: obj. 8,  $\times 600$ —oc. III., obj. 9.

Vein, from a section of a villus of the duodenum of a rabbit. The reticulum forms an adventitia to the vessel, and passes between the cells of the villus.

Fig. 19. Camera Lucida: obj. 7,  $\times 450$ —oc. III., obj. 9.

Vertical section of the lower part of a villus, from the small intestine of a monkey, showing a large vein.

*me.* Section of the membrana propria.

*v.* Capillary blood-vessel.

*r.* Reticulum.

The endothelial cells of the vein are seen to be surrounded by a very delicate reticulum.

There is great similarity between the cells of the villus and the endothelium of the vein.

Fig. 20. Camera Lucida: obj. 5,  $\times 300$ —oc. III., obj. 8.

Section of a narrow villus, from the duodenum of a rat.

*ep.* Surface of the epithelium.

*v.* Capillary blood-vessels.

A reticulum is seen between the endothelial cells of the chyle-vessel (*l*).

Fig. 21. Camera Lucida: obj. 7,  $\times 450$ —oc. III., obj. 9.

Section of a villus, from the commencement of the duodenum of a dog.

*l.* The central chyle-vessel.

*m.* Bands of involuntary muscle-fibres.

*lc.* Lymph-corpuscle.

*v.* Blood-vessels.

In the upper part of the chyle-vessel, the reticulum surrounding the cells of the villus is seen to be continued between the endothelial cells of the chyle-vessel.

The cells of the upper part of the villus are larger than those in the lower part.

In the lower part of the figure the reticulum can be traced from the chyle-vessel to the border of the villus.

Fig. 22. Camera Lucida: obj. 7,  $\times 450$ —oc. III., obj. 9.

Section of the lower part of a villus, from the small intestine of a hedgehog.

*l.* Central chyle-vessel, containing a little granular matter.

*m.* A small band of muscles; they are in contiguity with the wall of the chyle-vessel.

The reticulum is attached to the wall of the chyle-vessel, and passes between the cells of the villus.

Figs. 23, 24, & 25. From the villi of a hedgehog killed during absorption of fat. The intestine was hardened in osmic acid.

Fig. 23. Oc. III., obj. 11 immersion,  $\times 850$ .

Surface view of epithelium, teased, and treated with caustic potash.

The fat is seen as small black particles between the epithelial cells. The clear spaces are the openings of goblet-cells.

Fig. 24. Camera Lucida: obj. 8,  $\times 600$ —oc. III., obj. 9.

Section of a villus. The fat is seen as small black granules in a reticulum.

Fig. 25. Camera Lucida: obj. 7,  $\times 450$ —oc. III., obj. 8.

Section of the lower part of a villus.

*l.* Chyle-vessel.

In the upper part of the figure the fat-particles in the chyle-vessel have run together.

The fat-particles are seen in the reticulum of the villus.

Fig. 26. Oc. III., obj. 2,  $\times 45$ .

Vertical section of the pyloric end of the stomach of a dog.

*mm.* Muscularis mucosæ.

*d.* Duct of the tubes.

*ct.* Proper glands, or coiled tubes.

Some of the plicæ villosæ (*p*) are seen to be shorter than the others; the epithelium on the sides of the shorter ones is folded.

Fig. 27. Camera Lucida: obj. 5,  $\times 300$ —oc. III., obj. 7.

Epithelium covering one of the villus-like processes of a rabbit's colon.

The intestine had been stained in gold and hardened in chromic acid.

The nuclei of the epithelial cells are seen to be divided transversely, obliquely, and vertically.

Fig. 28. Oc. III., obj. 7,  $\times 300$ .

Section of one of the plicæ villosæ from the stomach of a dog. The animal was killed two hours after food.

*lc.* Lymph-corpuscles.

Fig. 29. Camera Lucida: obj. 7,  $\times 450$ —oc. III., obj. 8.

Epithelial cells covering one of the plicæ villosæ, from a section of the stomach of a dog.

The mucus in the upper part of the epithelial cells is very deeply stained.

At the base of the epithelium numerous small round or conical cells are seen.

Fig. 30. Camera Lucida: obj. 5,  $\times 300$ —oc. III., obj. 8.

Epithelium covering the plicæ villosæ: from a section of the stomach of a dog.

The stomach had been stained in gold and hardened in chromic acid.

*b.* Broad cells with nuclei in a state of division.

Fig. 31. Camera Lucida: obj. 5,  $\times 300$ —oc. III., obj. 8.

Epithelium covering the plicæ villosæ: from a section of the stomach of a dog, showing a small bud-like group of cells.

Fig. 32. Camera Lucida: obj. 5,  $\times 300$ —oc. III., obj. 8.

Oblique section of epithelium covering the plicæ villosæ: from the stomach of a dog.

*b.* Pale cells with spherical nuclei.

Fig. 33. Camera Lucida: obj. 5,  $\times 300$ —oc. III., obj. 8.

Section of a short villus-like process: from the stomach of a dog, showing the "epithelial buds."

The nuclei of the cells composing the bud-like groups are spherical, and are less stained than those of the neighbouring cells.

Fig. 34. Camera Lucida: obj. 5,  $\times 300$ —oc. III., obj. 8.

Two of the villus-like processes of the pyloric end of the stomach of a frog (*Rana esculenta*). Only part of the figure is filled in.

*v.* Blood-vessels at the summits of the processes.

On the left side of the figure the great length of the epithelial cells is seen.

Fig. 35. Camera Lucida: obj. 8,  $\times 600$ —oc. III., obj. 11 immersion.

Slightly oblique section of the epithelium of the ducts of the stomach-tubes: from the stomach of a dog.

The reticulum is seen to surround the epithelial cells.

Fig. 36. Camera Lucida: obj. 8,  $\times 600$ —oc. III., obj. 11 immersion.

Vertical section of the upper part of one of the plicæ villosæ, from the stomach of a dog.

The epithelium is diagrammatic.

A clear space is seen to contain a blood-vessel (*v*).

The upper wall of the clear space is formed by the endothelial cells (*e*) of the membrana propria.

*e'*. Endothelial cells forming the lower wall of the perivascular space.

*m*. The muscle-fibres: in the lower part of the figure they form a membranous covering to the endothelial cells.

One of the muscles ends by being apparently attached to an endothelial cell (*e*). Compare fig. 10.

Fig. 37. Camera Lucida: obj. 5,  $\times 300$ —oc. III., obj. 8.

Surface view of one of the terminal alveoli of the proper gland-tubes, from the pyloric end of the stomach of a dog; the animal was killed two hours after meat food.

A delicate reticulum is seen surrounding the epithelial cells.

Fig. 38. Camera Lucida: obj. 5,  $\times 300$ —oc. III., obj. 8.

Cross section of one of the terminal alveoli of the proper gland-tubes, from the pyloric end of the stomach of a dog; the animal was killed while fasting.

*me*. Membrana propria.

*a*. The faintly granular gland-cells with a dark line at their base.

*b*. The epithelial cells are cut obliquely; the nuclei are partly seen to the inner side of the dark line.

Fig. 39. Camera Lucida: obj. 5,  $\times 300$ —oc. III., obj. 8.

Oblique section of one of the terminal alveoli of the proper gland-tubes; from the pyloric end of the stomach of a dog; the animal was killed two hours after meat food.

*me*. Membrana propria.

The nuclei and the reticulum are both clearly seen.

Fig. 40. Camera Lucida: obj. 5,  $\times 300$ —oc. III., obj. 8.

Vertical section of epithelial cells of one of the terminal alveoli of the proper gland-tubes, from the pyloric end of the stomach of a dog killed five hours after meat food.

*b*. Two cells whose nuclei are in a state of vacuolation; the other cells have spherical nuclei.

Fig. 41. Camera Lucida: obj. 5,  $\times 300$ —oc. III., obj. 8.

Section of one of the terminal alveoli of the proper gland-tubes, from the pyloric end of the stomach of a dog. The stomach had been hardened in osmic acid and subsequently in chromic acid.

The reticulum has a double outline, and is much broader than in fig. 37 or fig. 38.

Fig. 42. Camera Lucida: obj. 8,  $\times 600$  nearly—oc. III., obj. 9.

Vertical section of the upper part of one of the plicæ villosæ; from the stomach of a dog.

The epithelium is drawn diagrammatically.

*v.* Blood-vessel.

*m.* Muscle-fibres.

*e.* Endothelial cells.

The disposition of the muscle-fibres and the perivascular spaces are well seen.

Fig. 43.  $\times 20$  times nearly. Vertical longitudinal section of the point of transition of the stomach and intestine of a dog. This drawing was made from two specimens, and is therefore slightly diagrammatic.

*M.* Part of the muscular wall.

*SM.* Submucosa.

*mm.* Muscularis mucosa.

*lc.* Lymphatic follicles.

The coiled tubes are seen to break through the line of the muscularis mucosa and become continuous with the glands lying in the submucosa (BRUNNER's glands).

The ducts of two lobes of BRUNNER's glands are seen between the crypts of LIEBERKÜHN.—I have to thank my friend Mr. HOPE, of St. George's Hospital, for this drawing.

#### REFERENCES\*.

1. LIEBERKÜHN. *De fabrica et actione villorum.* Amstelod, 1745.
2. HEWSON. *The works of.* Printed by the Sydenham Society, 1846.
3. CRUIKSHANK. *The Anatomy of Absorbing Vessels.* London, 1790.
4. RUDOLPHI. *Abhandlungen* Berlin, 1802.
5. FOHMAN. *Das Saugadersystem der Wirbelthiere.* Heidelberg, 1827.
6. KRAUSE. *Müller's Archiv*, 1837.
7. GOODSIR. *Edinburgh Philosophical Journal*, No. 33. 1842.
8. E. H. WEBER. *Müller's Archiv*, 1847. And *Berichte der Königl. Sächs. Gesellschaft.* Leipzig, Hft. vii.
9. NUHN. *Unters. und Beobacht. a. d. Gebiete der Anatomie.* Heidelberg, 1849.
10. ZENKER. *Zeitschrift für wissenschaftliche Zoologie.* Band vi. 1855.
11. FRERICHS. *Handwörterbuch der Physiologie*, von Dr. WAGNER. Artikel: Verdauung. Band iii. 1846.
12. DONDEES. *Physiologie* Deutch von Theil. Band i. 1856.
13. FUNKE. *Zeitschrift für wissenschaftliche Zoologie.* Band vi. 1855.
14. DÖNITZ. *Archiv f. Anat. und Physiologie.* 1864.
15. HENLE. *Müller's Archiv*, 1838. And *Symbolæ ad anatomiam villorum intestinalium.* 1837. Berol.
16. SCHWANN. *Müller's Physiol.* i.
17. BRUCH. *Zeitschrift für wissenschaftliche Zoologie.* Band iv. 1853.
18. LACAUCHE. *Comptes Rendus*, 1843.

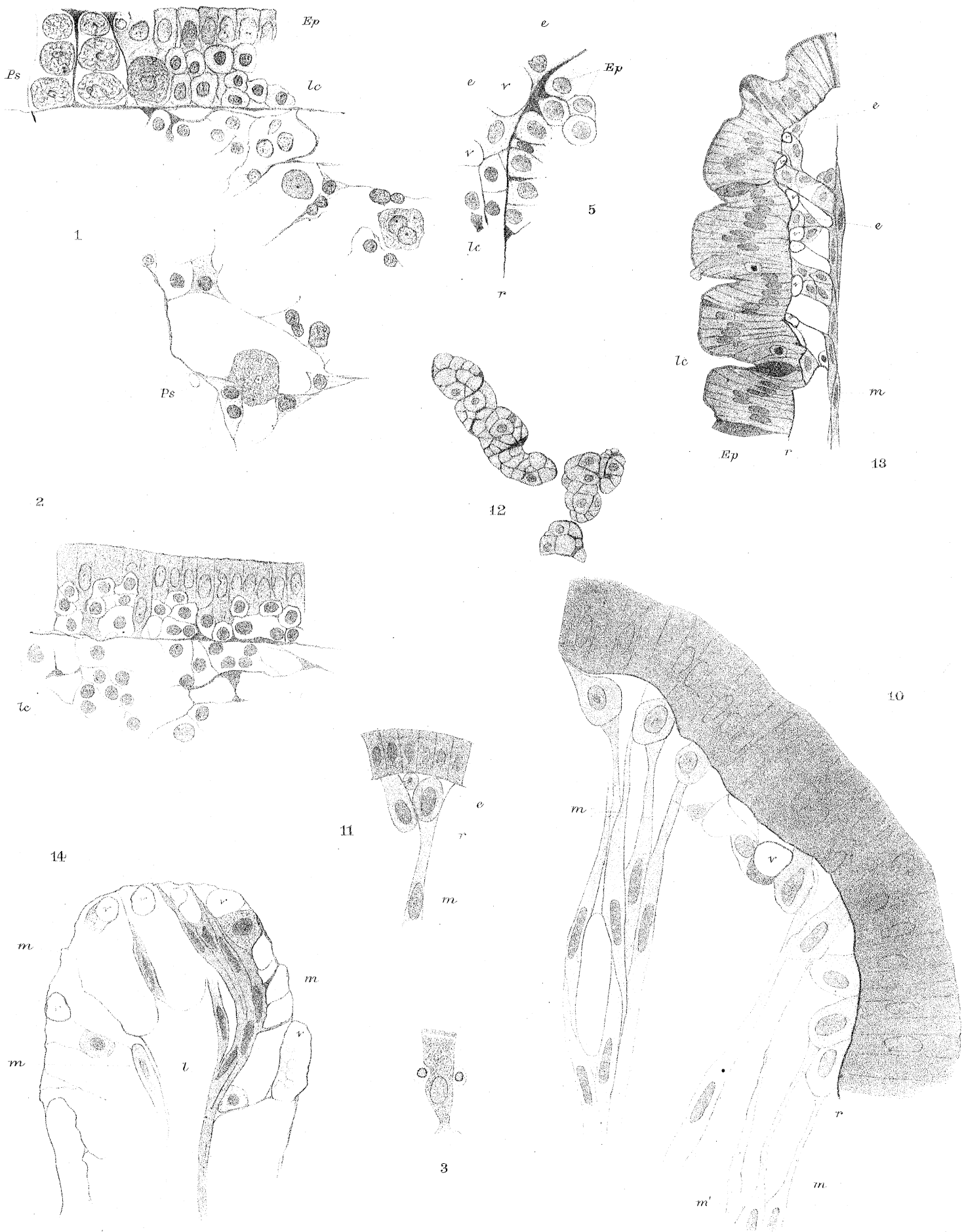
---

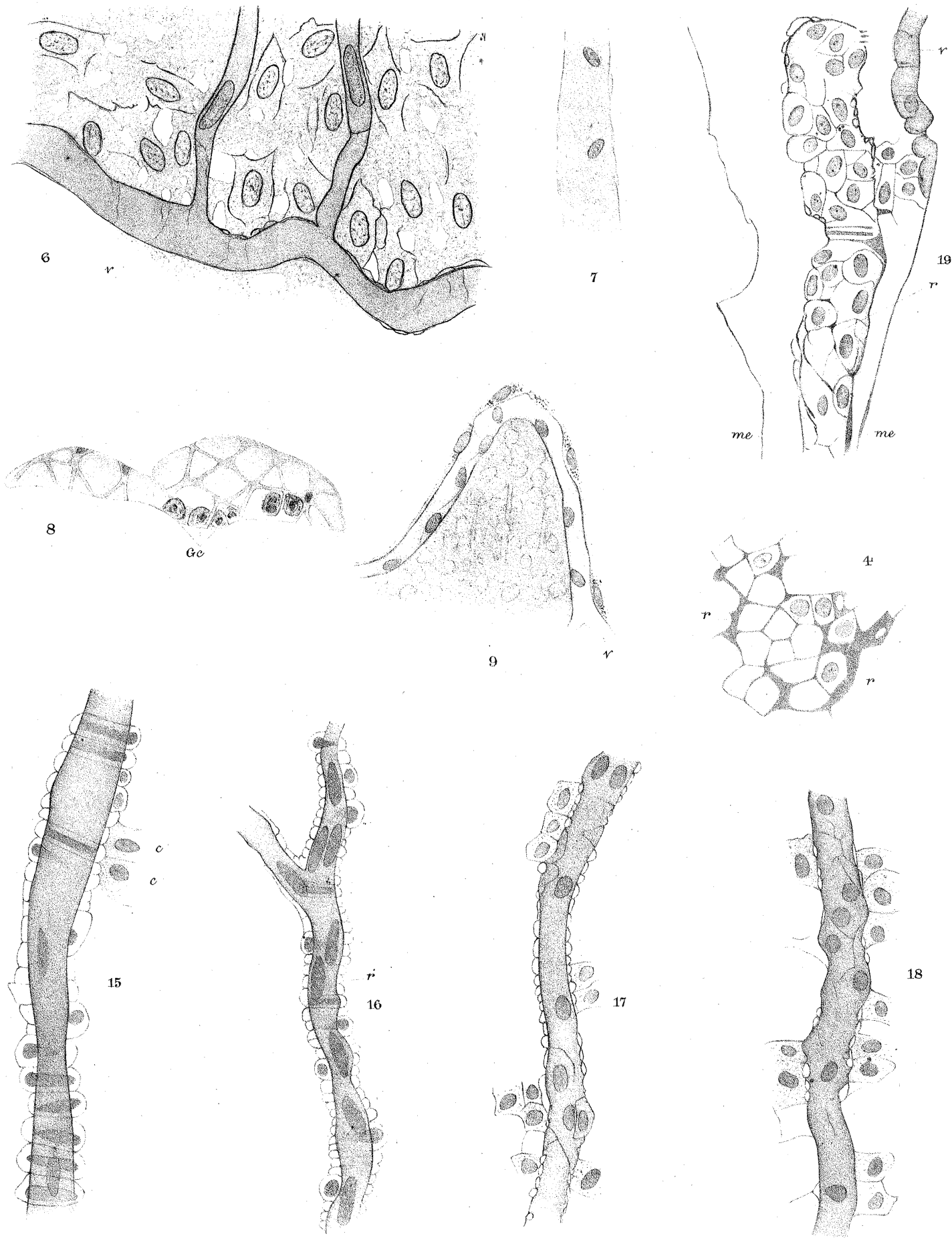
\* The memoirs of the following authors I have been unable to obtain; it was therefore necessary to quote them from other papers:—ASSELIUS, MOLESCHOTT and MARFELS, ERDMAN, WIEGANDT, FLES, LATSCHENBERGER, LANGERHANS, REICH.

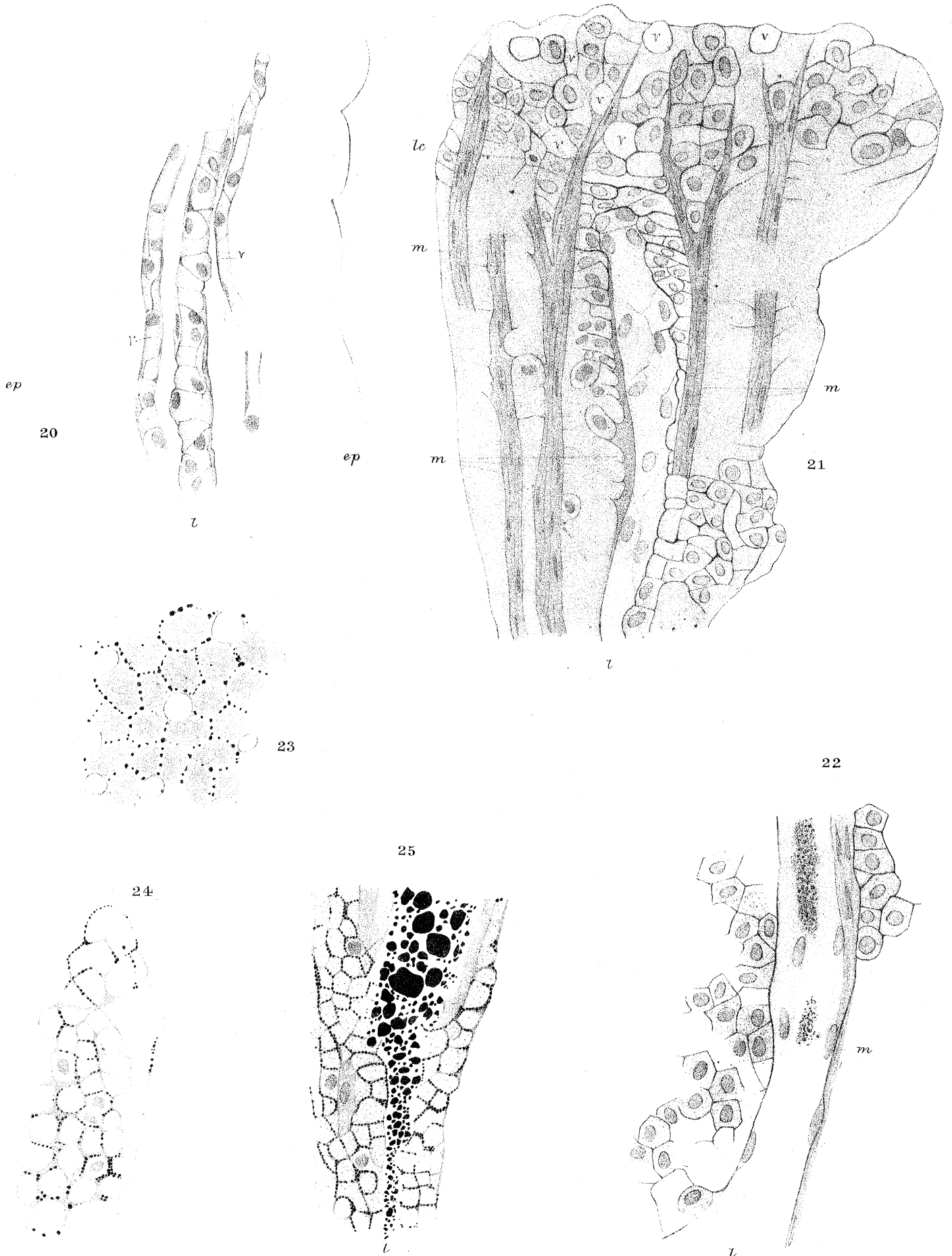

20. GRUBY and DELAFOND. *Comptes Rendus*, 1843.
21. FUNKE. *Atlas*. Leipzig, 1853.
22. VIRCHOW. *Würz. Verhand.* Band iv. 1853.
23. VIRCHOW. *VIRCHOW'S ARCHIV*, Band xi. 1857.
24. BRÜCKE. *Sitzungsber. d. Wiener k. Akad.* 1851.
25. BRÜCKE. *Denkschriften der Wiener k. Akad.* Band vi. 1853.
26. MOLESCHOTT and MARFELS. *Wiener med. Wochenschr.* 1854.
27. WITTICH. *Virchow's Archiv*, Band xi. 1857.
28. HOLLANDER. *Virchow's Archiv*, Band xi. 1857.
29. KÖLLIKER. *Würz. Verhandl.* Band vi. 1855.
30. FUNKE. *Zeitschrift für wissenschaftliche Zoologie*, Band vii.
31. BRETTAUER and STEINACH. *Sitzungsber. d. Wiener k. Akad.* Band xxiii. 1857.
32. TODD and BOWMAN. *The Physiological Anatomy and Physiology of Man.* 1856.
33. EBERTH. *Würz. nat. Zeitsch.* Band v. 1864.
34. ERDMANN. *Beobachtungen über die Resorptionswege in der Schleimhaut des Dünndarms.* Inaug. Dissert. Dorpat, 1867.
35. DEBOVE. *Comptes Rendus*, 1872; and *Archives de Physiologie*, 1874.
36. BILLROTH. *Müller's Archiv*, 1858.
37. HEIDENHAIN. *Moleschott's Unters.* Band iv. 1858.
38. WIEGANDT. *Unters. über das Dünndarm-Epithelium.* Inaug. Dissert., 1860.
39. BALOGH. *Moleschott's Unters.* Band vii. 1860.
40. ARNSTEIN. *Virchow's Archiv*, Band xxxix. 1867.
41. EIMER. *Virchow's Archiv*, Band xlviii. 1869.
42. RINDFLEISCH. *Virchow's Archiv*, Band xxii. 1861.
43. LIPSKY. *Sitzungsber. d. Wiener k. Akad.* Band lv. 1867.
44. KÖLLIKER. *Gewebelehre*; fünfte Aufl. 1867.
45. VERNON. *Stricker's Manual of Histology.* Translation by Dr. POWER. Vol. i. 1870.
46. BASCH. *Sitzungsber. d. Wiener k. Akad.* Band lxii. 1870.
47. BASSLINGER. *Sitzungsber. d. Wiener k. Akad.* Band xiii. 1854. And *Zeitschrift für wiss. Zool.* Band ix. 1858.
48. HIS. *Zeitschrift für wissenschaftliche Zoologie*, Band xi. 1862.
49. TEICHMAN. *Das Saugadersystem*, 1861.
50. RECKLINGHAUSEN. *Die Lymphgefäße &c.* Berlin, 1862.
51. HIS. *Zeitschrift für wissenschaftliche Zoologie*, Band xiii. 1863.
52. AUERBACH. *Virchow's Archiv*, Band xxxiii.
53. FLES. *Onderzoekingen over de histologische Zamenstelling des vlokjes van het darmkanaal.* M. Hand. t. d. Stelselm outleedkunde v. d. Mensch. 2 Auf. 1865.
54. BASCH. *Sitzungsber. d. Wiener k. Akad.* Band li. 1865.
55. LETZTERICH. *Virchow's Archiv*, Band xxxvii. and xxxix. 1866 and 1867.
56. ZAWARYKIN. *Mémoires de l'Académie de St. Pétersbourg*, T. xiv. 1869.
57. THANHOFFER. *Pflüger's Archiv*, Band viii. 1874.
58. EBERTH. *Virchow's Archiv*, Band xxi. 1861.
59. FRIES. *Virchow's Archiv*, Band xl. 1867.
60. EIMER. *Virchow's Archiv*, Band xl. 1867.
61. KÖLLIKER. *Würz. Verhandlungen*, Band iv. 1853.
62. PFLÜGER. *Archiv f. mikr. Anat.* Band v. 1869. *Stricker's Manual of Histology.* Translation by Dr. POWER. Vol. i. 1870.
63. LANGERHANS. *Beiträge zur mikroskopischen Anatomie der Bauchspeicheldrüse.* Inaug. Dissert. Berlin, 1869.

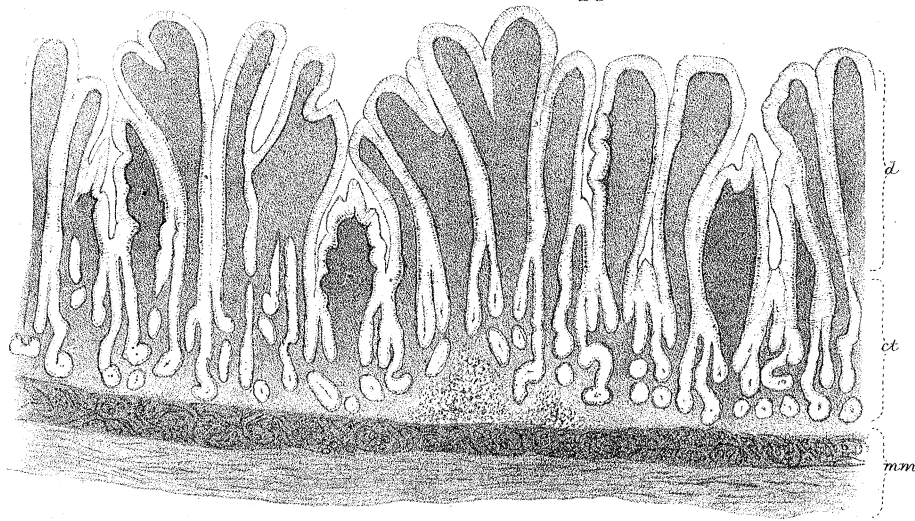
64. GIANUZZI. Comptes Rendus, Tom. lviii. 1869.
65. BOLL. Archiv f. mikr. Anat. Band iv. & v. 1868 and 1869.
66. SAVIOTTI. Archiv f. mikr. Anat. Band v. 1869.
67. EWALD. Beiträge zur Histologie der Speicheldrüsen. Inaug. Dissert. Berlin, 1870.
68. VON EBNER. Die acinösen Drüsen der Zunge. Graz, 1873.
69. LEYDIG. Archiv f. mikr. Anat. Band ix. 1873.
70. LATSCHENBERGER. Sitzungsber. d. Wiener k. Akad. Band lxv. 1872.
71. BOLL. Beiträge zur mikr. Anat. der acinösen Drüsen. Berlin, 1869.
72. SCHWALBE. Archiv f. mikr. Anat. Band viii. 1871.
73. GIANUZZI and FALASCHI. Comptes Rendus, lxx. 1870.
74. CHRSCITSCHONOWITSCH. Sitzungsber. d. Wiener k. Akad. 1871.
75. PODCOPAËW. Archiv f. mikr. Anat. Band v. 1869.
76. ELIN. Archiv f. mikr. Anat. Band vii. 1871.
77. LANGERHANS. Virchow's Archiv, Band xlv.
78. EBERTH. Archiv f. mikr. Anat. Band vi. 1870.
79. EIMER. Archiv f. mikr. Anat. Band viii. 1871.
80. EDMANSSON. Virchow's Archiv, Band xxviii.
81. DYBKOVSKI. Berichte d. s. Gesellschaft z. Leipzig, Sitz. 1865.
82. KLEIN. The Anatomy of the Lymphatic System. Part i. 1873.
83. RECKLINGHAUSEN. Stricker's Manual of Histology. Translation by Dr. POWER. Vol. i. 1870.
84. ARNOLD. Virchow's Archiv, Band lxii. 1875.
85. SIKORSKY. Centralblatt f. medicin. Wiss. No. 52, 1870.
86. KLEIN. The Anatomy of the Lymphatic System. Part ii. 1875.
87. WITTICH. Centralblatt f. medicin. Wiss. No. 58, 1874.
88. KÜTNER. Centralblatt f. medicin. Wiss. No. 41, 1875.
89. ARNOLD. Virchow's Archiv, Band lxiv. 1875.
90. CARTER. Proceedings of the Royal Society, April 1864.
91. THOMA. Virchow's Archiv, Band lxiv. 1875.
92. KOWALEWSKY. Sitzungsber. d. Wiener k. Akad. Band xlix.
93. KÖLLIKER. Manual of Human microscopic Anatomy. 1860
94. KLEIN. Stricker's Manual of Histology. Translation by Dr. POWER. Vol. i. 1870.
95. EBSTEIN. Archiv f. mikr. Anat. Band vi. 1870.
96. LOVÉN. Nord. med. Archiv, Band v. 1873.
97. RABE. Magazin für die gesammte Thierheilkunde. Berlin, 1874.
98. SCHULZE. Archiv f. mikr. Anat. Band iii. 1867.
99. BLEYER. Magenepithel und Magendrüsen der Batrachier. Inaug. Dissert. Königsberg, 1874.
100. REMAK. Untersuchungen über die Entwicklung der Wirbelthiere.
101. LUDWIG and TOMSA. Sitzungsber. d. Wiener k. Akad. Band xlvi. 1862.
102. BRUCH. Zeitschrift für wissenschaftliche Zoologie, Band iv. 1853.
103. KÖLLIKER. Würz. Verhandlungen, Band vii. 1856.
104. BRUCH. Zeitschrift für rationelle Medicin, Band viii. 1849.
105. ECKER. Zeitschrift für rationelle Medicin, Band ii. second series, 1852.
106. COBELL. Sitzungsber. d. Wiener k. Akad. Band L. 1864.
107. SCHLEMMER. Sitzungsber. d. Wiener k. Akad. Band lx. 1869.
108. HEIDENHAIN. Archiv für mikr. Anat. Band viii. 1871.
109. REICH. Disquis. Micr. de finibus nervorum in gland. saliv. Wrat. 1864.
110. HEIDENHAIN. Studien.



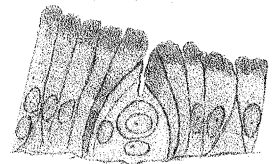
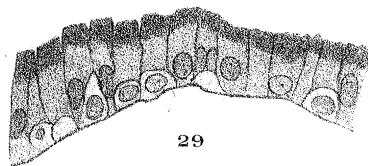
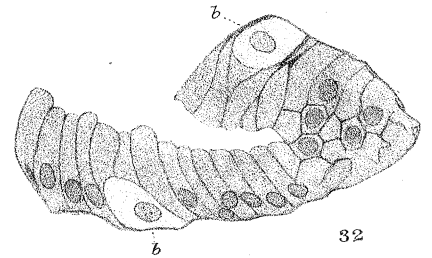
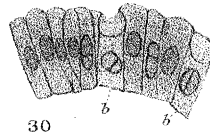
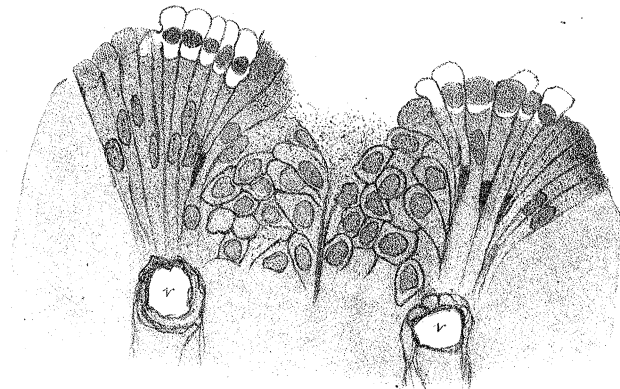
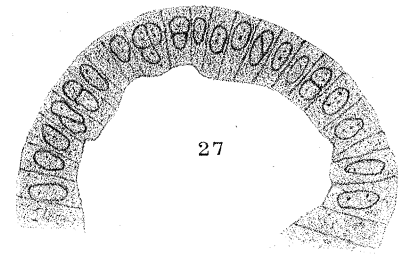
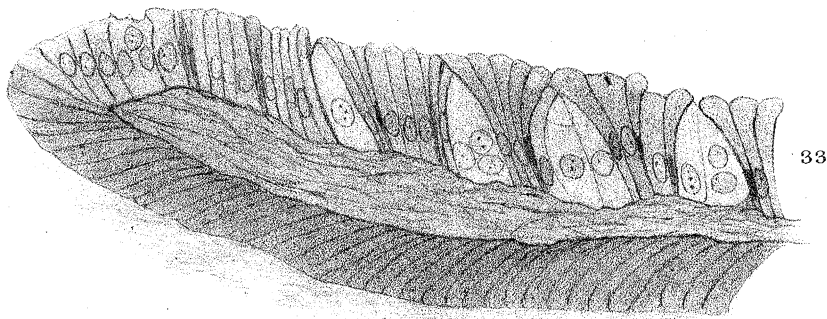
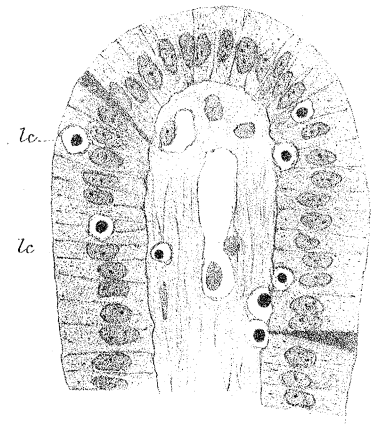




26



28



34

30

b

b

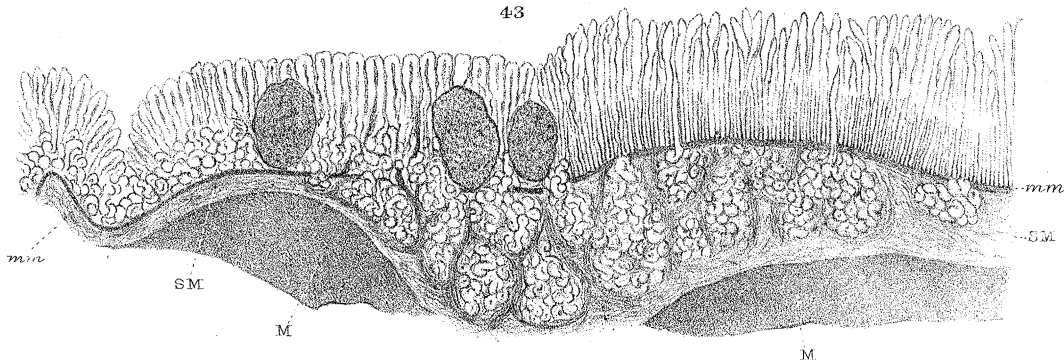
32

b

29

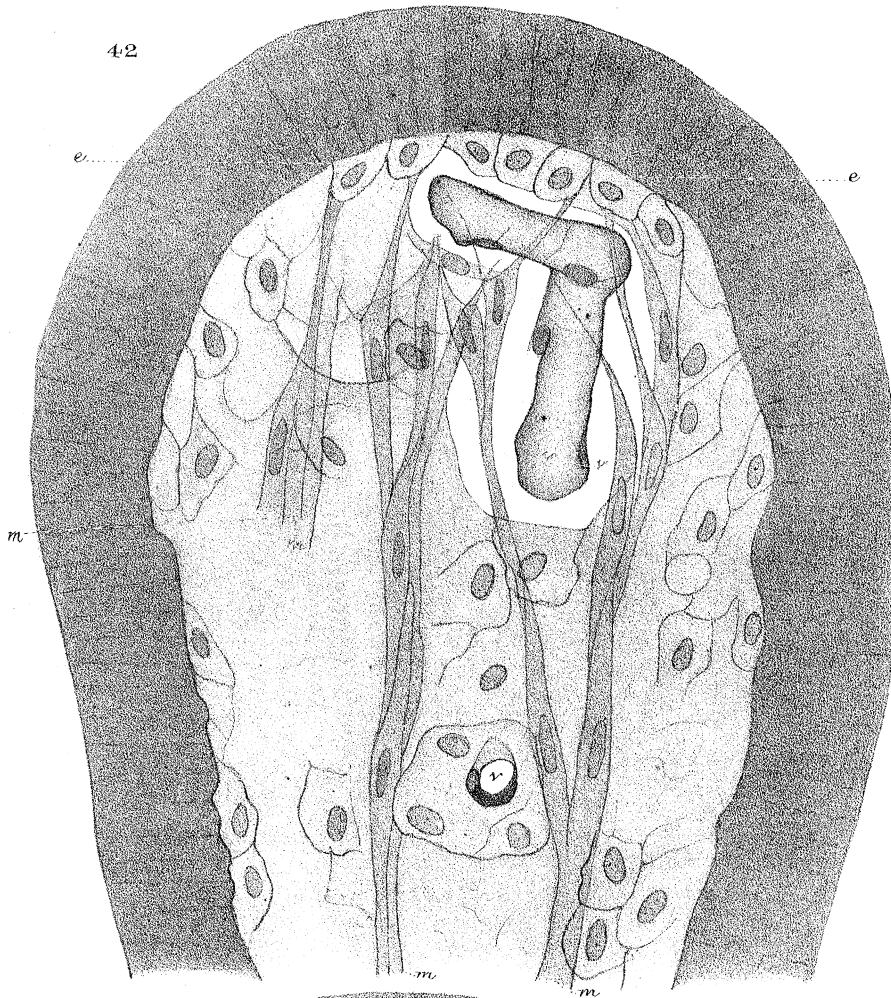
31

43

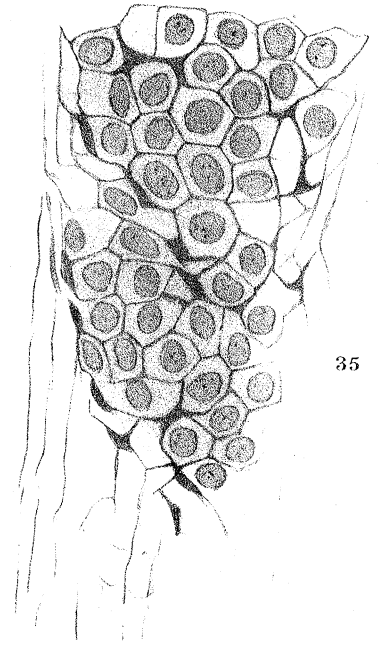




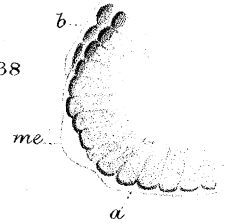
42



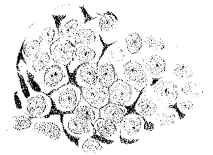
35



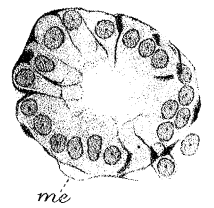
38



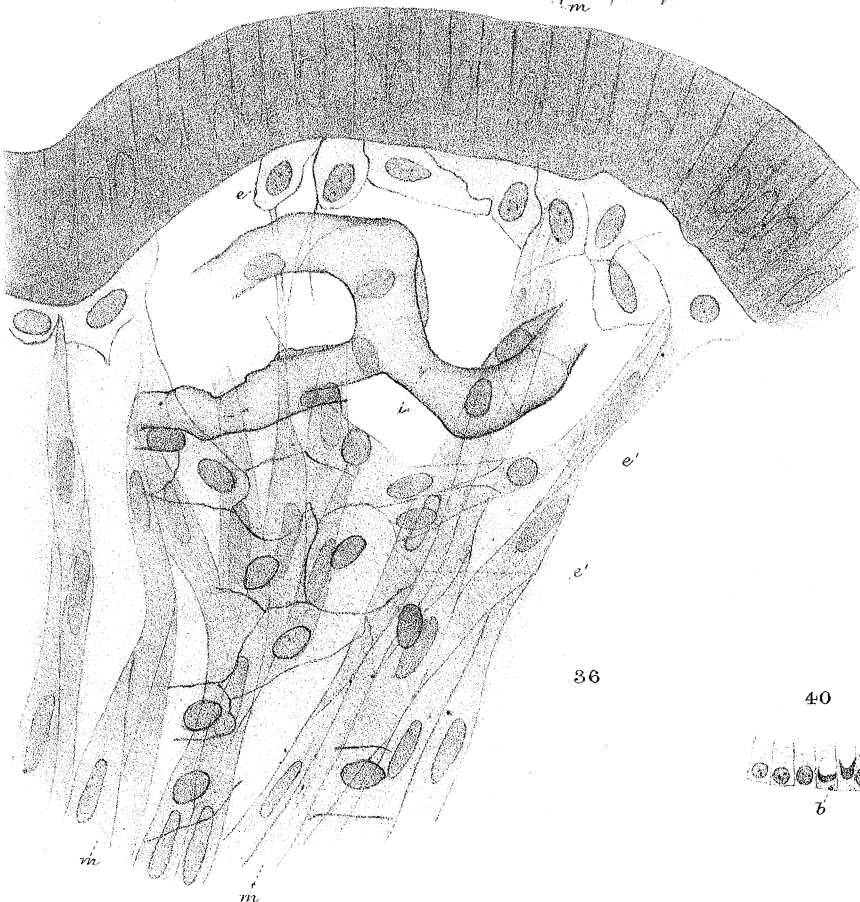
37



39



36



40



41

