

XIII. *Researches on the Minute Structure of the Thyroid Gland.*

By E. CRESSWELL BABER, *M.B. Lond.*

Communicated by E. KLEIN, *M.D., F.R.S.*

Received November 25, 1880,—Read January 6, 1881.

[PLATES 68–69.]

CONTENTS.

	Page
Introduction	577
Bibliography	578
Macroscopic appearances	578
Methods employed	580
Microscopic appearances	582
I. Vesicles	582
II. Epithelium, reticulum, and basement membrane.....	585
III. Contents of vesicles	589
IV. Parenchyma	596
V. Lymphatics and their contents	597
VI. Blood-vessels	600
VII. Undeveloped portions	600
General conclusions	602
Explanation of the plates	604

INTRODUCTION.

THE following research is a continuation of that previously communicated to the Society on the “Minute Anatomy of the Thyroid Gland of the Dog,” and published in the Philosophical Transactions for 1876 (Vol. 166, Part II.). It is based on a histological examination of the thyroid gland in the following vertebrate animals:—

I. *Mammalia*. Dog, Cat, Horse, Rabbit, Ox, Sheep, Seal.

II. *Aves*. Pigeon, Fowl, Rook.

III. *Reptilia*. Tortoise.

IV. *Amphibia*. Frog.

V. *Pisces*. Skate, Conger Eel.

(Altogether the glands of more than sixty animals have been examined in this research.)

My examination of the human thyroid gland is unfortunately not sufficiently com-

MDCCCLXXXI.

4 F

plete to allow of its being included in this communication, partly owing to its great delicacy of structure, and partly to the difficulty of obtaining this gland perfectly fresh, a condition which is absolutely necessary in order to examine its minute anatomy. I shall therefore merely refer to this gland incidentally on one or two points in the course of the paper.

BIBLIOGRAPHY.

The following are the chief publications to which it will be necessary to refer in the present communication :—

LEYDIG : ‘Lehrbuch der Histologie.’ 1857. .

HENLE : ‘Handbuch der Systematischen Anatomie des Menschen,’ vol. ii. 1866.

KÖLLIKER : ‘Handbuch der Gewebelehre.’ 5th edition, 1867.

PEREMESCHKO : “Ein Beitrag zum Bau der Schilddrüse.” Zeitschrift für Wissenschaftliche Zoologie, xvii. 1867.

ROLLESTON : ‘Forms of Animal Life.’ 1870.

VIRCHOW : ‘Pathologie des Tumeurs.’ French translation. Lect. 22, vol. iii. 1871.

W. MÜLLER : Jenaische Zeitschrift für Medizin und Naturwissenschaft, vi. 1871.

VERSON : Article “Thyroid Gland,” in STRICKER’S ‘Human and Comparative Histology.’ Sydenham Society’s translation, by H. POWER, vol. i. 1871.

P. A. BOÉCHAT : ‘Recherches sur la Structure Normale du Corps Thyroïde.’ Thèse. Paris, 1873.

FREY : ‘Histology and Histo-Chemistry.’ 4th edition, translated by BARKER. 1874.

BABER : “Contributions to the Minute Anatomy of the Thyroid Gland of the Dog.” Philosophical Transactions of the Royal Society, Vol. 166, Part II. 1876.

O. ZEISS : ‘Mikroskopische Untersuchungen über den Bau der Schilddrüse.’ Inaugural Dissertation. Strassburg, 1877.

HUXLEY and MARTIN : ‘Practical Biology.’ 4th edition, 1877.

KLEIN : “Observations on the Structure of Cells and Nuclei.” Quarterly Journal of Microscopical Science, vol. xviii., new series. 1878.

MACROSCOPIC APPEARANCES.

Before entering on the histology of the gland, it may be well to mention the following points in regard to its macroscopic anatomy which have been noted in this research (compare SIMON, “On the Comparative Anatomy of the Thyroid Gland,” Phil. Trans., 1844; and OWEN, ‘Anatomy and Physiology of the Vertebrata,’ vol. i., 1866) :—

Mammalia.—In some of these (such as the Dog, Sheep, &c.) the gland consists of two distinct halves, situate one on either side of the windpipe. In other instances the two lateral halves are united across the median line. For example, on injecting one lobe of the thyroid of a Rabbit (11 weeks old) by the method of puncture, what

appeared to be a broad band of small lymphatics became injected, running across the trachea to the lower part of the opposite lobe. Sections of this connecting band, examined microscopically, showed that it contained a considerable quantity of gland-tissue, and was therefore a true isthmus. In the Kitten, on injecting one gland by the puncture method with Berlin blue solution, what was apparently a large lymphatic vessel became filled, running across the trachea to the lower part of the opposite gland. This probably also formed a delicate isthmus of gland-tissue, connecting the two lobes.

Aves.—In the Birds examined (Fowl, Rook, Pigeon) the thyroid gland was composed of two small round or elongated bodies, situate in the upper part of the thorax, and in close connection with the jugular vein and carotid artery on either side.

Reptilia.—In the Tortoise the gland is single, and forms a yellowish, rounded, somewhat flattened organ, situate just above the base of the heart, between the right and left aorta.

Amphibia.—*Frog.* The following extracts will show that observers are by no means unanimous in regard to the position and character of the thyroid gland in this animal.

LEYDIG (*op. cit.*, p. 376) says that the thyroid gland of tail-less Batrachians (Frogs and Toads) usually consists of only three large vesicles, provided with a fine capillary network and isolated from one another, whose contents are neither clear fluid nor colloid, but a finely granular and partly fatty substance. ROLLESTON (*op. cit.*, pp. 184, 185) describes and figures the thyroid glands as placed just internally to the jugular veins. HUXLEY and MARTIN (*op. cit.*, p. 181), on the contrary, state that “the thyroid gland appears to be represented by two or more oval bodies, which are found attached to the lingual vessels, and between the aortic and pulmo-cutaneous trunks.” W. MÜLLER (*op. cit.*, p. 438) found that in young Frogs the thyroid lay on the two sides of the body of the hyoid bone, close in front of the point of attachment of the *cornua thyreoidea*. It was surrounded on all sides by muscles, and possessed a thin connective-tissue capsule, from which the vessels with their connective-tissue adventitia stretched into the interior. The gland substance consisted entirely of closed vesicles, with a delicate membrana propria and a single layer of cubical epithelium without pigment, and a central cavity containing a transparent colourless fluid, without any structural elements.

For some time I was unable to find in the Frog any body corresponding histologically to the thyroid gland, but subsequently, by following W. MÜLLER's directions as just quoted, I discovered it in transverse sections of the head. My observations show that in the Frog there are two bodies presenting the structure of the thyroid gland. They are situate, one on either side, on the ventral surface of the hyoid cartilage (or bone), being usually, but not always, in direct contact with this structure. They are found either between the hyoid cartilage and the hyoglossus muscles, or else immediately to the outer side of these muscles, on a level just anterior to the

point of their convergence. In quite small Frogs the thyroid gland appears in transverse sections as a somewhat flattened body, lying on the ventral surface of the hyoid cartilage, partly between it and the hyoglossus muscle. In rather larger Frogs it presents in transverse section a somewhat triangular outline (see Plate 68, fig. 1, 1, 1), the base being applied to the ventral surface of the cartilage (Plate 68, fig. 1, 1) and the apex projecting forwards by the side of the hyoglossus muscle. In still larger Frogs transverse sections show that the gland often extends forwards, but its development on the two sides appears to be irregular and unsymmetrical. In Frogs of full size it may, however, still be found flattened and extending very slightly forwards.

I may here mention that the structure of this gland resembles that of the thyroids of other animals. It consists of numerous vesicles separated by a stroma of connective tissue, the whole being surrounded by a capsule of similar character. The vesicles are lined by a single layer of cubical or slightly columnar epithelial cells, which are devoid of dark pigment. It will be seen that the results of these observations on the Frog agree on the whole with those of W. MÜLLER.

Pisces.—In the Skate, as far as I have seen, the gland is single (with the exception of a few detached vesicles) and forms a yellow flattened, lobulated body, occupying the median line at the bifurcation of the branchial artery.* Anteriorly it sometimes presents a narrow process of gland-tissue running forwards, and behind it is limited by the bifurcation of the branchial artery. The vesicles of the gland, of various sizes, are distinctly visible to the naked eye. In the Conger Eel the gland occupies a similar position and forms a reddish flattened body.

METHODS EMPLOYED.

Methods of Injection.

I. The gland of a freshly-killed animal was injected *in situ* with a solution of Berlin blue by the method of puncture. The gland being hardened first in a mixture of equal parts of methylated spirit and water, and afterwards in methylated spirit, and sections mounted in dammar or balsam in the usual way.

II. The fresh gland was injected in a similar manner with $\frac{1}{8}$ per cent. solution of nitrate of silver in water and hardened as before.

III. The fresh gland was injected *in situ* by the method of puncture with $\frac{1}{8}$ per cent. solution of osmic acid in water. The gland being removed was cut up into small pieces, and these placed in solutions of the same acid ranging in strength from $\frac{1}{20}$ to 1 per cent. for periods ranging from 1 to 24 hours. The gland being subsequently placed in alcohol and sections mounted in glycerine or in dammar.

* HANDFIELD JONES (quoted by OWEN, *loc. cit.*) has observed in the Skate a second body of similar structure situated some distance behind this. I have not observed this second gland, but cannot deny its existence.

IV. In the Tortoise a double injection of the gland was made by filling the blood-vessels from the aorta with GERLACH's carmine mass, and after about 20 minutes injecting the lymphatics of the gland *in situ* by the method of puncture with Berlin-blue solution—the latter, however, did not run very well.

In several animals also the blood-vessels only were injected with a solution of Berlin blue.

Methods of Hardening.

The method employed in by far the larger number of cases was that of placing portions of the fresh gland (injected or uninjected) into a mixture of equal parts of methylated spirit and water for a period varying from a few days to a couple of weeks (or longer), and afterwards into pure methylated spirit until sufficiently hard for cutting, the hardening being sometimes completed by immersion in absolute alcohol, although this is not necessary. Sections of the hardened gland were then stained with hæmatoxylin or picrocarminate of ammonia and mounted in dammar or balsam. The following methods were serviceable for showing special points in the structure of the gland (which will be referred to subsequently).

I. Thyroid of Sheep or Tortoise hardened in a $\frac{1}{2}$ to 1 per cent. solution of chromic acid for 17 to 25 hours and subsequently in alcohol, for showing the intercellular reticulum.

II. Thyroid of Tortoise hardened in MÜLLER's fluid for four days, stained with hæmatoxylin and mounted in glycerine, for showing the layer of connective tissue on the epithelial wall.

The following methods gave specimens which were either inferior, showing nothing fresh, or else were entirely useless:—(a) Immersion in a saturated solution of picric acid for 18 hours, afterwards in a strong solution of gum for 18 hours, and, finally, in methylated spirit. This method was only tried in the Ox, in which animal, it is only fair to state, the results obtained by other methods were very disappointing. (b) Solution of monochromate of ammonia ($2\frac{1}{2}$ and 5 per cent.), subsequent hardening in spirit. (c) Immersion for two days in a mixture of two parts of chromic-acid solution ($\frac{1}{6}$ per cent.), and one part of methylated spirit, afterwards in alcohol. The three methods recommended by KLEIN (*loc. cit.*) for showing intra-nuclear and intra-cellular reticulum were tried with the results mentioned below.

The general histology of the gland is certainly best shown in specimens hardened *in alcohol only*, although the facility with which the minute structure of this organ can be examined varies greatly in different animals, and also probably at different times in the same animal (*vide infra*, p. 586). BOÉCHAT (*op. cit.*, p. 13) also found hardening in alcohol the most successful method. The thyroid gland of no animal, as far as my experience goes, surpasses that of the Dog in the facility it presents for microscopic examination.

MICROSCOPIC APPEARANCES.

Speaking generally, the only points in regard to the histology of the thyroid gland, on which recent authors appear to be unanimous, are, that it consists of "cavities" lined by a single layer of epithelium and held together by a more or less dense stroma of connective tissue. Further, that numerous blood-vessels and lymphatics, also nerves, are found in the stroma, and that the whole organ is surrounded by a capsule of connective tissue, which is continuous with the stroma in its interior. On other points, such as the shape of these "cavities" (vesicles), the character of their epithelium, the nature of the contents of the vesicles, &c., the opinions of authors are at variance. In considering these subjects in order, it will be convenient to discuss them under the following heads.

I. *Vesicles.*

Literature.—The majority of observers (*e.g.*, HENLE, KÖLLIKER, VERNON, FREY, and LEYDIG) have described the vesicles of the thyroid gland as consisting of closed globular bodies; not communicating with one another. VIRCHOW, and more recently BOÉCHAT and ZEISS, however, believe that this is not the case, but that the supposed closed globular bodies form a system of branched cavities in the gland. VIRCHOW (*op. cit.*, p. 201) finds that the apparently vesicular bodies are in multiple connection with one another. BOÉCHAT (*op. cit.*, p. 43) considers that all the cavities of the thyroid gland communicate with one another. ZEISS (*op. cit.*, p. 14) does not go to this length, but maintains that in the thyroid gland of young Children, of the Calf, of young Dogs and Sheep, a not insignificant part of the parenchyma is made up of branched cavities (branched tubes); but whether these all communicate with one another, and whether completely closed vesicles also occur, he leaves undecided. Both BOÉCHAT and ZEISS endeavoured to prove the existence of these branched cavities by injections by the method of puncture, but without success. Their failure they attribute to the injecting fluid entering the large spaces of the lymphatics or blood-vessels in preference to the branched cavities, which, as ZEISS points out, are filled partly with an easily coagulable, albuminous fluid and partly with the viscid colloid material. Although this observer has traced the epithelial layer running from one vesicle to another, he has never observed tubes passing from one lobule of the gland to another. ZEISS demonstrated these tubes by floating them out in a solution of common salt from small portions of the fresh gland of young animals, also after maceration in iodised serum or in dilute MÜLLER'S fluid. Circular, oval, conical, or pyramidal cavities were thus obtained together with long tubes, sometimes extending "right across the field of the microscope, having a narrow, wide, or irregular lumen, which divide and branch, and are provided at intervals with lateral protuberances or constrictions." He considers that the tubes, so plainly seen by isolation or maceration, are rendered invisible in sections by the circumstance that they interlace so freely in all directions that in a section they must

always be cut across. W. MÜLLER (*loc. cit.*), who appears to agree with the majority of observers in considering that in the fully developed state the vesicles are closed globular bodies, describes an earlier stage (in the development of the gland) in which, before the formation of vesicles the gland consists of a network of cylindrical tubes, at first irregular, but afterwards becoming more regular in character. They are composed of a very fine envelope of connective tissue, and are filled in the interior with short cylindrical epithelial cells, placed radially on the envelope. The tubes are separated by processes of the mesoblast, which have grown inwards from the connective tissue surrounding the gland. The tubes are at first *solid*, but are subsequently provided with a central lumen. After the lumen in the interior of the tubes has become more marked, the separation of different segments of the tubes takes place by the growth into them laterally of processes of the mesoblast, which results in the formation of gland-vesicles. The same observer finds that in the human thyroid the shape of the vesicles varies much from the fifth month of embryonic life to the age of three years. From this period to puberty the changes occurring are, he considers, that the number of glandular deposits continues to diminish and the follicles increase in size, by the accumulation of secretion, which shows a great tendency to become thickened, and they approach the spherical shape. PEREMESCHKO (*op. cit.*, p. 283) found the vesicles in young embryos regularly round; in mature embryos mostly of irregularly polygonal form; in young animals very seldom of regular round form, and still more rarely so in adult animals. In the latter the vesicles have, he says, the most different forms; they are almost always polygonally round or polygonally oval.

Observations.

My own observations on this subject may be summarised as follows :—

Dog.—In the gland of young Dogs (aged five weeks and three months respectively*) I have observed that the gland-vesicles are very much branched and present numerous hollow ramifications (see Plate 68, figs. 2 and 3). In order to see these well in sections of hardened glands it is necessary that the sections should be *thick*, and then by careful focussing, the vesicles with their usual contents can be traced ramifying both upwards and downwards, and laterally in all directions. In the glands of numerous other Dogs of different ages I have ascertained with equal certainty that the vesicles present very few, if any, ramifications. When the vesicles present these branches, the intervals between them form the inflexions projecting into the interior of the vesicles, which have been already described by VERNON (*op. cit.*, p. 371) and myself (*op. cit.*, p. 560). I have examined fresh portions of the glands of young Sheep in salt solution and in MÜLLER'S fluid (according to the method recommended by ZEISS for floating out the tubes), but have obtained no appearances that might not be produced by the much-branched vesicles just described in the thyroid glands of young Dogs. In fact, there can be no doubt that these are the same structures as those which ZEISS

* The ages of most of the Dogs mentioned in this paper were only approximately ascertained.

obtained by flotation. Our observations also agree, inasmuch as ZEISS observed these tubes in the glands of *young* animals: at least he makes no statement to the effect that they have been found in the glands of adult animals. From the fact of their complete, or almost entire, absence in the glands of adult Dogs, I regard these much-branched vesicles merely as forming a stage in the growth of the organ, and consider that in its fully developed state the gland-vesicles form cavities more or less spherical in shape, which are very rarely, if at all, branched, or, in other words, in communication with one another. The presence of branched vesicles in a gland probably indicates that the number of vesicles is being increased by the growth into the vesicles already present of involutions of their walls, together with processes of the inter-vesicular tissue. PEREMESCHKO (*loc. cit.*) figures this division of the gland vesicles both in the embryo and adult Rabbit. He considers it probable that the division of vesicles takes place after intra-uterine life. W. MÜLLER is also of opinion, from an examination of the gland at different ages in Man, that completely-formed follicles (vesicles) undergo segmentation by the growth into them of processes of the mesoblast. I shall have occasion to refer to W. MÜLLER's observations on the early stage in the development of the gland in speaking of the "undeveloped portions."

The above conclusions refer to the thyroid gland of the Dog, as it is in this animal that I have chiefly studied the shape of the vesicles.

In the thyroid gland of Birds (Rook, Fowl, Pigeon), as far as I have seen, the vesicles are, as a rule, small and very rarely branched. In the last-named bird (Pigeon) the larger vesicles are usually found near the surface of the gland.

In the Tortoise the vesicles are sometimes, but not usually, branched.

In the thyroid gland of full-sized Frogs the vesicles are usually large. In smaller Frogs their size is generally less. They are occasionally branched.

The gland-vesicles of the Conger Eel are often of large size and more or less branched. In the Skate the vesicles are also often large, and branched ones are sometimes seen.

In all these animals the exact age was unascertained.

Whilst, therefore, branched vesicles may occur in the thyroid gland of adult animals, they do not, as far as I have seen, communicate with one another to any extent—a conclusion which, it appears to me, is strongly corroborated by the fact that in the course of a large number of interstitial injections in the glands of different animals I have never succeeded in injecting any system of branched tubes. I cannot think with ZEISS that the viscid contents of the vesicles would have the effect of preventing the injecting fluid from entering them, when we know that the viscid contents of the lymphatics has no such effect.

The exact shape of the vesicles is of course of minor importance. My chief object in drawing attention to this point has been to show that in the adult state the vesicles form *closed cavities*, and do not consist of a system of tubes traversing the substance of the gland as BOÉCHAT suggests.

In this connection it may be well to mention the following appearance which I have observed in the thyroid gland of several Conger Eels :—In the walls of the vesicles, which in this animal are often of considerable size in proportion to the whole organ, small vesicles are seen, as shown in Plate 68, fig. 4. These secondary vesicles (Plate 68, fig. 4, 3, 3) are provided with an epithelial wall, and with contents similar to the primary vesicles. From the fact that by their growth they have evidently flattened out to a greater or less degree the epithelium separating them from the cavity of the primary vesicle, it is probable that the two layers of epithelium separating the cavity of the small, from that of the large vesicle sometimes give way, allowing the contents of the two vesicles to mix. At the same time others of these small vesicles probably grow outwards becoming independent structures (Plate 68, fig. 4, 5, 5). It is possible that some of these small vesicles may be curved branches of a large one which are cut across in the section.

II. *Epithelium, Reticulum, and Basement Membrane.*

The wall of the vesicle is composed of a layer of epithelial cells, and also, according to some observers, of a basement membrane and reticulum.

Results of previous observations.

Epithelium.—Recent observers are not yet in accord in regard to the shape of the epithelial cells. VERNON (*loc. cit.*) describes the epithelial cells as higher than broad. BOÉCHAT, on the contrary (*op. cit.*, p. 20), considers that in the normal state their breadth exceeds their height. PEREMESCHKO (*op. cit.*, p. 281) is of opinion that in all animals, without exception, they are cylindrical, “but where the vesicles are enlarged, as in old animals, the epithelial cells present the most *bizarre* forms, which without doubt results from the mechanical pressure.” ZEISS (*op. cit.*, p. 20) finds their shape in the Sheep and Calf highly cylindrical; in Man and in the Rat, shortly cylindrical; in the Cat, Dog, and Rabbit, cubical. He insists that the normal shape of these cells is not flattened but cylindrical. He also states that he has never found cubical and cylindrical cells in immediate proximity, but has not uncommonly seen vesicles with cylindrical cells next to those containing a cubical epithelium. Processes attached to the base of the epithelial cell have been observed by PEREMESCHKO and ZEISS. PEREMESCHKO noticed that the surface of the cell turned towards the cavity of the vesicle (summit of the cell) has a bright margin. ZEISS confirms this observation (on fresh cells examined in saline solution), and describes the bright margin as a cuticula.

Reticulum.—ZEISS (*op. cit.*, p. 23) has observed between the epithelial cells a fine reticulum, similar to that described by VON EBNER and SCHWALBE in other glands provided with a cylindrical epithelium. He describes it as a network of delicate rods on the two surfaces of the epithelium with fine processes, or lamellæ, extending between the epithelial cells. In osmic and chromic acid preparations it presents

branched stellate figures, occasionally provided with nuclei having an indistinct contour. The reticulum extends on both aspects slightly beyond the level of the epithelium. He also describes in a profile view narrow rod-like structures between the cubical or columnar epithelial cells, resembling the club-shaped cells ("Keulenzellen") described by SCHWALBE in BRUNNER's glands of the Dog.

Basement membrane.—KÖLLIKER, HENLE, and VERNON have described a very fine homogeneous membrane (*membrana propria*) lying outside the epithelial cells. W. MÜLLER also found a thin *membrana propria* in the vesicles of Man, Fowl, and Pig. FREY has been unable to see this membrane. PEREMESCHKO (*op. cit.*, p. 281), although he denies having seen a *membrana propria*, concludes that the cavities of the vesicles are formed by the epithelial cells, which are situated directly on the surrounding connective tissue, which forms a homogeneous, membranous limiting layer ("Grenzschicht"). BOÉCHAT also denies its existence, and considers that the epithelial cells are in direct contact with the endothelium of the lymphatics at a great number of points. The two walls (the endothelium and epithelium) are, he considers, separated at certain points by the bands of connective tissue which form the framework of the gland, and by capillary blood-vessels which ramify between them (p. 39). ZEISS (*op. cit.*, p. 15) has not been able to find any *membrana propria* of the above description, nor any structure resembling the "Drüsenkörbe" of BOLL. He has always observed between the endothelium of the lymphatics and the epithelium of the vesicles a very fine layer of connective tissue, in which he thinks that the capillaries ramify (p. 44).

Observations.

Epithelium.—The discrepancy of opinion of different observers in regard to the shape of the epithelial cells is, I think, attributable to three chief causes:—

1. The varying shape of these cells in different animals.
2. The different re-agents employed in examining and hardening the organ.
3. The state of functional activity of the gland at the time of removal.

With regard to re-agents I have chiefly examined these cells in specimens hardened in the usual way in alcohol—others, however, have been examined after being hardened with other re-agents, or in the fresh state. When it is found, however, that in the glands of the same species of animal prepared by *a similar method*, the appearance of the epithelial cells differs considerably, one is forced, I think, to admit the third factor above mentioned. Making due allowance for the two last-named elements of uncertainty, I have found that the general character of these cells in different animals is as follows:—

In the Dog, Cat, Kitten, Rabbit, Sheep, Rook, Pigeon, and Frog the epithelial cells are cubical or slightly columnar. In the Seal and Tortoise they are distinctly columnar. In the Horse, Skate, and Conger Eel they are highly columnar in shape.

The general tendency, therefore, of these cells throughout the vertebrate series, as

far as examined, appears to be to the columnar form—their exact height varying in different animals.

A double line of demarcation is often seen on the summits of the epithelial cells (e.g., in the Tortoise). This doubtless corresponds with the cuticula described by ZEISS (*vide supra*, p. 585) and with the appearance of a membrane lining the summits of the epithelial cells which I described in the Dog (*op. cit.*, p. 560).

On examining with a moderately high power (VÉRICK, obj. 8) a transverse section of the wall of the vesicles in several animals, the appearance of a fine parallel striation has been observed in the epithelial cells running in the long axis of the cell, and extending for a greater or less distance from its summit (or free extremity) towards the base. Examination with a higher power (such as ZEISS, obj. F) does not, however, render this striation more plain, and I have not found it sufficiently distinct to be drawn. Thinking that this appearance was perhaps produced by intracellular fibrils such as KLEIN has described (*op. cit.*, p. 327), I treated portions of the thyroid gland of the Tortoise according to the three different methods recommended by the author of that paper (*ibid.*, pp. 319, 321, and 327), but without being able to see the intracellular reticulum distinctly. It must be borne in mind, however, that these cells are much smaller than those on which KLEIN made his observations.

Plate 68, fig. 8, shows an appearance probably connected with this striation. It is taken from the thyroid of a Kitten, injected by the method of puncture with silver, hardened in alcohol, and stained with hæmatoxylin. In addition to endothelial markings of the lymphatic, which are clearly seen (1, 1), on altering the focus the epithelial cells are seen studded with a quantity of dots and short lines, also stained with the silver, which I can only explain by supposing that the ends of intracellular fibrils have become stained by the silver, and are seen either endways or somewhat obliquely. The figure which PEREMESCHKO gives (*op. cit.*, Plate 16, fig. 1) of a profile view of the processes at the base of the epithelial cells, showing minute dots arranged in parallel rows running in the longitudinal axis of the cells, suggests the idea that it is these structures which produce the appearance of dots and lines, stained with silver, just described, and also possibly that of the intracellular striation. My own observations on the existence or non-existence of processes at the base of the epithelial cells have not led to any definite results.

Reticulum.—On viewing from the surface the epithelium of the vesicle in the thyroid gland of the Tortoise hardened in chromic acid, a delicate network is seen running between the individual epithelial cells, which stains darkly with hæmatoxylin. (See Plate 68, fig. 5. In this figure the epithelial cells present in the meshes of the reticulum are not represented.) This reticulum, which is probably formed by coagulated intercellular substance, is seen to be thickened at intervals. When viewed somewhat obliquely the meshes of the reticulum appear to be made up of delicate lamellæ running between the epithelial cells, although it is difficult to speak with certainty on this point. In spirit, and in osmic acid preparations, this reticulum is also observed

in a surface view. In a profile view of the epithelium of the Tortoise (hardened in alcohol) there are seen at intervals amongst the epithelial cells, narrower cells with much elongated nuclei, which latter take the hæmatoxylin stain more darkly than the nuclei of the epithelial cells. On examining these cells carefully they are found to be expanded somewhat like a fan at their summits, and also sometimes at the base, although the latter is not always the case. Probably these are more or less branched cells, which are situated in the swollen parts of the reticulum above-mentioned. The reticulum as well as the *club-shaped cells* just described are very plainly seen in the thyroid glands of the Conger Eel and Skate. Plate 68, fig. 6, gives a surface view of the epithelium as seen in a section of the thyroid of the Conger Eel, hardened in spirit. Amongst the epithelial cells in this figure are seen the branched or stellate nuclei of the club-shaped cells. In this animal, as well as in the Skate, the club-shaped cells are often seen in great numbers in a profile view of the epithelium. It is a common thing to see two of these cells in close approximation to each other, almost suggesting the appearance of stomata opening into the cavity of the vesicle. That these cells however bear an important part in the absorption from, or secretion into, the cavity of the vesicle is, I think, probable, although I am unable to speak more definitely on this point. In the Conger Eel the expanded summits of the club-shaped cells may often be observed projecting slightly beyond the surface of the epithelial layer.

The reticulum is also seen in the thyroid gland of Mammals, such as the Sheep and Kitten.

Basement membrane.—In a double-injected gland of the Tortoise in which the blood-vessels were injected with carmine-gelatine and the lymphatics with Berlin-blue solution, I have found that the arteries are surrounded more or less completely by their accompanying lymphatics; the capillaries, on the contrary, run between the epithelium of the vesicles and the smallest ramifications of the lymphatics, which in this animal are found between almost all individual vesicles. This relation of the lymphatics to the capillaries and arteries can be easily seen in uninjected sections of the same gland, also in those in which the lymphatics only are injected by the puncture-method. Plate 68, fig. 9, exhibits this relation of the minute lymphatics to the capillaries in the thyroid of the Tortoise. It represents a transverse section of the walls of two adjacent vesicles with the intervesicular structures. 2, 2 are the cavities of the two vesicles, 1, 1 their epithelial walls. In the centre is seen the small lymphatic (3, 3), and between this and the epithelium on each side the capillaries (4, 4, 4). As the ramifications of the capillaries are much more minute than those of the lymphatics, spaces are frequently left between the capillaries in which the endothelial wall of the lymphatic is *not* separated from the epithelium by a blood-vessel, and at these points the epithelial cells appear usually somewhat elongated. Two of such points are seen in the figure (Plate 68, fig. 9). In osmic acid preparations of the Tortoise, where the wall of a vesicle happens to be cut obliquely, lying outside the epithelium, is seen the nucleated membrane formed by the endothelial cells of the

lymphatics, and on this are observed fine wavy striæ, which are evidently due to a delicate layer of connective tissue interposed between the endothelium and epithelium in which the capillary blood-vessels ramify (see Plate 68, fig. 7). Judging from the appearance presented by this layer of connective tissue when examined from the surface, it is probable that it forms a continuous layer even at points where the lymphatics are not separated from the epithelium by capillaries, although in vertical sections I have not been able to trace this layer at these points. I have not observed any other form of basement membrane, nor have I been able to detect by maceration in MÜLLER's fluid, any basement membrane resembling the "Drüsenkörbe" described by BOLL.

III. *Contents of Vesicles.*

Literature.—FREY and PEREMESCHKO describe the contents of the vesicles *in the embryo* as consisting of a finely granular substance in which cells and nuclei are embedded. PEREMESCHKO figures these cells and says that they differ from the epithelial cells by their round shape and *smaller* nuclei. He finds that in larger embryos vesicles filled with colloid masses are met with here and there. In young animals the greater part of the vesicles are filled with this mass, and finally in adult animals it is very rare to meet with vesicles without colloid.

KÖLLIKER speaks of the contents of the vesicles in the healthy human thyroid gland as a clear, yellowish, somewhat tenacious fluid containing a large amount of albumen. BOÉCHAT alludes to the cavities as being first partly filled with a fluid of viscid appearance in which float granules in more or less abundance. ZEISS describes the small vesicles as being first filled with a clear fluid, soluble in water, which is related to albuminous substances in its chemical behaviour, and considers that it is not essentially different from the colloid masses, which often accompany, and subsequently replace it entirely. Numerous ill-defined, granular disintegrating cells, remains of protoplasm and nuclei, are present in it, also fat granules, cholesterine and octohedral crystals of oxalate of lime.

Almost all observers allude to these contents of the vesicles being subsequently replaced partly or entirely by a substance to which the term of *colloid* is applied.

Colloid substance.—With slight variations this body is described as a homogeneous, transparent, more or less yellow substance (VIRCHOW, FREY, KÖLLIKER, BOÉCHAT), viscid in character (VIRCHOW, KÖLLIKER, BOÉCHAT), and completely filling the vesicles in the adult state (FREY). PEREMESCHKO finds that it usually fills the whole vesicle, but that in other cases it appears as smaller or larger transparent drops adhering to the wall of the vesicle; in still other cases it appears as smaller or larger transparent granules (sago-grains, ECKER) suspended in a finely granular mass. Amongst these granules (according to PEREMESCHKO) are found occasionally, even in adult animals, the above-named cells, and stages of transformation of these into the transparent colloid granules may be observed.

Under the microscope the colloid substance is either quite amorphous and homogeneous, or amorphous and slightly granular (VIRCHOW), or it encloses cells, or débris of cells, and granules (VIRCHOW, KÖLLIKER).

BOÉCHAT describes the appearance it presents when coagulated by re-agents, namely, that of hard masses of rounded shape with regular or jagged borders.

ZEISS observed true colloid masses in the smaller follicles, appearing in specimens prepared in MÜLLER'S fluid as homogeneous, round, bean or egg-shaped masses, which are rarely granular, with a peculiar bluish or yellow tint, and often consisting of concentric layers. He found that these are at first suspended in the clear fluid, but soon accumulate layer upon layer on their surface, until they completely fill the vesicle.

The *colloid substance* is considered by HENLE and KÖLLIKER as pathological in character, whilst BOÉCHAT and PEREMESCHKO regard it as a physiological product. ZEISS, although agreeing with the last-named observer in having found it present in all Mammals examined, expresses no opinion either way. LEYDIG has also found it present in bony Fishes, Sharks and Rays, in Reptiles and Birds, and on that account he is *not* inclined to regard it as a pathological product when occurring in man.

Observations.

The following are the chief constituents of the contents of the vesicles which have been observed. They are considered entirely *from a morphological point of view*, and are described as they appear in specimens which have been *hardened in alcohol*, unless the contrary is stated. (Some of the specimens had been previously injected with Berlin blue or with nitrate of silver.)

- (a) *Homogeneous or granular material* ("Colloid").
- (b) *Red blood-corpuscles.*
- (c) *Colourless blood-corpuscles.*
- (d) *Rounded masses*, which stain darkly with hæmatoxylin or of a bright yellow colour with picrocarminate of ammonia.
- (e) *Crystals and Pigment.*

(a) *Homogeneous or granular material.*—*Dog.*—It will be convenient to describe first more fully the appearance of this substance in the Dog, and afterwards to mention its characters in other animals. In my previous paper (*op. cit.*, p. 560) I described in the vesicles of the Dog's thyroid gland a peculiar material, which in hardened specimens shrinks away from the walls of the vesicle and forms a solid mass in the centre. In sections stained in picrocarminate of ammonia it appears as a finely granular substance, and stains of a more or less bright yellow hue. In specimens coloured with hæmatoxylin, on the other hand, it presents the appearance of an opaque, grey, or greyish-violet mass which is generally uniform, but sometimes finely granular in appearance. This substance was present in all the Dogs (10 animals) examined in

the present research. In the youngest Dog examined (5 weeks old) the vesicles were almost filled with a granular material, with smooth outline, which assumed a grey tint on staining with hæmatoxylin. In the remaining Dogs the quantity present varied very much. At one time the vesicles appeared completely filled with it, whereas at another time it formed a shrunken mass only occupying a small portion of the cavity. The intensity with which this material took the hæmatoxylin or picrocarminate stain also varied much in different glands. It may be conjectured that this variation in the amount present corresponded to different states of functional activity of the gland.

A substance apparently similar was found in greater or less quantity in the thyroids of all the other Mammals examined. It varied however greatly in amount.

Birds.—A similar substance was observed in the thyroid glands of the Fowl and Pigeon. The thyroid glands of two Rooks were examined; in one of these Birds the vesicles in both glands were found almost filled with a homogeneous material staining more or less with hæmatoxylin. In the second Rook, on the other hand, a very few vesicles contained this material, the great majority of them appearing either empty or much compressed.

In the thyroids of all the Tortoises examined (14) the vesicles were found almost or entirely filled with this homogeneous material.

In the Frog an apparently similar homogeneous material was invariably present. Its outline was usually much indented.

Fishes.—In the Conger Eel the vesicles contained a homogeneous material, often with indented edges. In hæmatoxylin specimens sometimes, whilst this material presented a yellow colour, its central portion, to a greater or less extent, was of a bright violet tint. Rounded masses staining more or less with hæmatoxylin were often found in the vesicles.

In the Skate in one instance the vesicles contained a comparatively small quantity of homogeneous material, which was much shrunk and contained numerous clear round spaces. In other glands the contents of the vesicles consisted of coarsely granular masses or of globules of various sizes.

From the description just given there can be no doubt, I think, that, in adult animals at least, the homogeneous or granular material corresponds with the "colloid substance" of authors, and from its almost universal occurrence in the gland-vesicles of adult animals, I have no hesitation in regarding it as a *normal* product of the organ.

When this homogeneous material shrinks away from the walls of the vesicle its outline often presents an indented appearance, as if beset with pellucid drops (see Plate 68, figs. 10 and 11, taken from the Tortoise, and Plate 68, fig. 4, from the Conger Eel). These have been considered as drops of colloïd adhering to the walls of the vesicle (see above—PEREMESCHKO). For my own part I regard this appearance merely as the result of contraction of the viscid material (colloid) contained in the

vesicle, which probably takes place in the following manner:—The vesicle being full of the viscid material is placed in the fresh state into alcohol. This coagulates the viscid material and causes it to shrink. When this takes place, however, it is necessary either that the walls of the vesicles should fall in, or that the space left between the epithelial wall and the coagulated content should be filled with some other fluid. It is probable that a clear fluid exudes from the epithelial cells in the form of a drop from each cell, producing the indentations above mentioned. This will also explain the occurrence of a pellucid appearance around the *large round cells* found in the viscid material in the Tortoise, which will be described further on (see Plate 68, fig. 11). For in the latter case when the viscid material contracts, fluid probably exudes from the large round cells, and as it escapes equally all round, in the case of one of these cells lying singly, the pellucid appearance is more or less spherical in shape, as shown in the figure.

I have seen no sign of this homogeneous substance consisting of “concentric layers,” or of its accumulating “layer upon layer,” as described by ZEISS.

(b) *Red blood-corpuscles*.—Red blood-corpuscles are not uncommonly seen in the vesicles of the thyroid gland. They have been observed in the glands of Dogs (whose age ranged from 5 weeks to 7 or 8 years), in the glands of several Tortoises, and in the Conger Eel. The blood-corpuscles, which from their being situate *in* the homogeneous material (colloid) above described had beyond all doubt entered the vesicles *during life*, are sometimes few in number, but at other times they *completely fill the vesicle*. They either appear collected (or fused) into a ball in the centre, or are scattered throughout the contents of the vesicle (see Plate 68, fig. 10, from the Tortoise). They are also frequently met with arranged in a layer close to the epithelial cells (see Plate 68, fig. 12, from the Dog). The corpuscles are observed *in different stages of disintegration and decolorisation*. In some instances in the thyroid gland of the Dog the epithelial wall of a vesicle containing red blood-corpuscles was seen to be studded with a quantity of *minute yellow granules*, no doubt due to the absorption of the colouring matter of the escaped red blood-corpuscles by the epithelial cells or inter-cellular reticulum. (Plate 69, fig. 13, 2, 2, & 3, shows these granules in the epithelial wall of two vesicles containing red blood-corpuscles.) Colourless blood-corpuscles are sometimes observed in the cavity of the vesicles mixed with the coloured ones.

In the ten Dogs examined, whose age varied from 5 weeks to 12 years, one or more vesicles containing red blood-corpuscles were found, with one exception, in *all* instances either in one or both glands. (These glands were all *uninjected*.) The exception was that of a Dog (female, aged 12 years) in which appearances rendered it very probable that there had been an escape of red blood-corpuscles, but this could not be ascertained for certain.

In one gland of a Dog from this series (female, aged 7 or 8 years) *a very large proportion of the vesicles* contained red blood-corpuscles in greater or less number (see

Plate 68, fig. 12). The opposite gland of this Dog also contained numerous vesicles with red blood-corpuscles. In the gland of another Dog (male, nearly 2 years old) numerous vesicles containing red blood-corpuscles were also present. (In these two Dogs the red blood-corpuscles were more disintegrated and less distinct than in many others, but from a study of the changes which the red blood-corpuscles undergo in the vesicles, I think there can be no doubt of these being of this nature.) From these observations it appears that *in the Dog, at least, an escape of red blood-corpuscles is almost constantly taking place into a greater or less number of vesicles.* As only a few sections from each gland were examined, it is obvious that the number of vesicles containing red blood-corpuscles in all probability greatly exceeded that actually observed. The frequency of the escape of red blood-corpuscles into the vesicles of the Dog, together with its occurrence in the glands of such different animals as the Tortoise and Conger Eel, I think, renders it *very probable that the passage of red blood-corpuscles into the vesicles is a normal occurrence in the thyroid gland.*

In the thyroid gland of a Seal (*Phoca vitulina*) which I obtained through the kindness of the late Professor A. H. GARROD, F.R.S., the epithelium of *almost all* the vesicles contained numerous dark red granules, which on close examination appeared to be minute crystals. Arguing from the appearance above-described in the epithelium of the Dog, I attributed these to the absorption of colouring matter from blood effused into the cavity of the vesicles. Subsequently also on careful examination I found that *a large proportion, in some parts certainly the majority, of the vesicles* contained structures which were very probably red blood-corpuscles, but, perhaps owing to the gland not being quite fresh, they could not be certainly identified with these. In the thyroid gland of the Rook, also, in one instance, yellow granules, some of considerable size, were seen in the epithelial wall of *almost all the vesicles of both glands* (see Plate 69, fig. 14), and yellow masses were found in the cavities of some of the vesicles which I was inclined to consider as fused red blood-corpuscles. A careful examination of these glands led me to believe that in this Bird *an extensive hæmorrhage* had taken place into the vesicles, and that the Bird was killed just as the colouring matter of the blood was being reabsorbed.

It is possible, of course, that the glands of the Rook and the Seal just mentioned, as well as those of the two Dogs (in which an extensive escape of red blood-corpuscles was observed), may be pathological in character, in which case considerable interest would also obviously attach to them. These observations, however, I think at least render it *very probable that normally, under certain circumstances, an escape of red blood-corpuscles takes place into a large proportion of the vesicles of the thyroid gland;* they certainly encourage to further research in this direction with a view, if possible, of throwing light on the function of the organ.

The blood which thus escapes into the vesicles contributes, no doubt, *to a large extent* to the formation of the "colloid" material which they contain, and it seems highly probable that this escape of red blood-corpuscles into the vesicles, with their

subsequent disintegration, has an important bearing both on the physiology and pathology of the gland.*

I may mention that vesicles containing many red blood-corpuscles have also been observed in the thyroid gland of Man (male aged 4 years, and adult Man).

The red blood-corpuscles in the vesicles have probably hitherto escaped detection in the physiological state of the gland, owing to the rapidity with which they become melted down, as it were, and thus rendered invisible. From the fact also that the red blood-corpuscles in the *vessels* in these specimens often present no distinct structural characters, it is quite possible that red blood-corpuscles may be present in the *vesicles* at the time of death, although they are not distinguishable as such in sections of the hardened gland.

Although the following applies to a pathological state of the gland it is interesting, as showing that what I have described in the *normal* state has been already observed in abnormal conditions. In speaking of *vascular goitre* ("Gefässkropf") KÖLLIKER (*op. cit.*, p. 482) says that in this disease, besides a hyperæmic condition, there are numerous aneurysmal dilatations of the small blood-vessels which ECKER regards as arteries and coarse capillaries. By the bursting of these dilatations apoplectic vesicles of different sizes are formed, which may become modified in various manners by the blood undergoing different changes, &c.

(c) *Colourless blood-corpuscles*.—On examining a section of the thyroid gland of the Tortoise, it is common to find in a large proportion of the vesicles, situate in the homogeneous material, a greater or less number of *large round cells* (see Plate 68, fig. 11). These cells when perfect are round in shape, and present a granular cell-substance. They are each provided with a single, round, or oval-shaped nucleus. Both the cells and nuclei are *larger* than those of the epithelium of the vesicle. In this respect they differ from the cells described in the vesicles by PERMESCHKO (*vide supra*, p. 589). Their number in each vesicle often appears to be considerable, for in a section, which of course only includes a portion of the contents of a vesicle, it is not uncommon to find half-a-dozen or more of them. As they have been found in greater or less number in all the glands of the Tortoise, which have been sufficiently well prepared, I conclude that their presence in the cavities of the gland-vesicles is a normal phenomenon in this animal.

It was first thought that these cells might be parenchymatous cells, such as I have

* Amongst other suggestions which occur to one in this connexion, it is impossible to avoid conjecturing, whether rightly or wrongly, that the *anæmia* which so commonly accompanies certain forms of enlargement of the thyroid gland (*goitre*) may be due to an excessive destruction of red blood-corpuscles in the manner above-described [see, for instance, ERICHSEN, 'Science and Art of Surgery,' 5th ed., vol. ii., p. 297: "There is a remarkable connexion between tumors of the thyroid gland of this kind (simple hypertrophy) and a general anæmic condition of the system. In London nothing is more common to find than a certain degree of bronchocele in pale and bloodless women and girls; indeed, so frequent is the coincidence that it is impossible not to regard it in the light of cause and effect"].

already described as passing into the vesicles of the Dog's thyroid gland ; but from a comparison of them with the fresh blood of the Tortoise, and from the occurrence of very similar cells in the blood-vessels in sections of the hardened gland of the same animal, I think there can be no doubt that they are *colourless blood-corpuscles*. It is scarcely necessary to mention that these cells can be easily distinguished from any *post-mortem* falling in of the epithelial cells ; moreover, in these specimens the epithelium was usually intact. In specimens prepared in osmic acid these cells come out very clearly, and their cell-substance presents a coarsely-granular appearance.

Some of these Tortoises were killed by decapitation, after a ligature had been tightly tied round the neck, but the method of killing could have had no effect in causing the escape of these cells, for they were found equally in those killed by simple decapitation without ligature. The appearances observed also left no doubt that they had entered the vesicles during the life of the animal.

A few large nucleated cells have been observed in the vesicles of the thyroid gland of the Rook, which were probably colourless blood-corpuscles.

In one thyroid gland of a Dog (aged 9 weeks), many vesicles contained a quantity of cells with granular cell-substance and indistinct outline, both in their cavity and in the substance of the epithelial wall. The nuclei of these cells were smaller, and stained more deeply with hæmatoxylin than those of the epithelial cells. These cells, which I conclude were colourless blood-corpuscles, I am inclined to regard as a pathological appearance, as they were only seen in part of one gland of this Puppy. Their occurrence in the vesicles cannot therefore be compared with the migration of colourless corpuscles into the vesicles of the Tortoise, which from its being constantly present is doubtless a normal phenomenon.

It appears, therefore, that a *migration of colourless blood-corpuscles into the vesicles is a physiological occurrence in the thyroid gland of the Tortoise, but that it may also occur in other animals.*

(d) *Rounded masses*, embedded in the homogeneous material, have been observed in various animals. These are usually homogeneous in character, with smooth, or sometimes jagged outline, and stain darkly with hæmatoxylin (more so than the surrounding homogeneous substance), or of a bright yellow colour with picrocarminate of ammonia. They have been observed in the thyroids of Dog, Rook, Fowl, Pigeon, Conger Eel, and Skate. In the latter they sometimes presented the following appearance. The central portion was deeply stained with hæmatoxylin, whilst the periphery remained almost colourless. Whether these are pathological in character or not, and what relation they bear to the homogeneous contents of the vesicle, I am unable to say.

(e) *Crystals* were found in the homogeneous material in the gland-vesicles of the Tortoise and Rook, the latter being the bird in which it was concluded (as above-described, p. 593) that hæmorrhage had taken place into almost all the vesicles. The crystals in this case were present in considerable numbers.

Pigment.—Masses of brown pigment-granules were frequently seen in the homogeneous material in the thyroid glands of the Frog. They are probably the result of an escape of red blood-corpuscles into the vesicles, but this point could not be ascertained for certain. Numerous brown pigment granules were also sometimes seen in the homogeneous material in the vesicles of the Conger Eel.

IV. *Parenchyma.*

In my previous paper on this subject (*op. cit.*, p. 563) I described and figured, as normal structures in the thyroid gland of the Dog, some large round cells provided with a single oval-shaped nucleus, to which I applied the term "parenchymatous cells." From the different appearances they present and their different positions in regard to the wall of the vesicle, I concluded that a migration of these cells takes place into the cavity of the vesicles by displacement and compression of the epithelial cells.

ZEISS (the only observer, as far as I am aware, who has since written on the subject) has been unable to observe any such migration of cells into the vesicles. In order to see these cells well, it is of course necessary that the sections should be very thin.

To the description of these cells in the Dog, as given in the above paper, I have little to add. I have since also observed them in the glands of young Dogs (aged 5 and 9 weeks respectively). Whilst still maintaining the view that these cells migrate into the cavity of the vesicles, I think it is quite possible that some of them may originate between the epithelium of a vesicle and the capillaries, and from thence pass by compression or separation of the epithelial cells into the vesicle.

In the thyroid gland of the Cat, parenchymatous cells are also present in considerable numbers, although not nearly so numerous as in the Dog. They resemble very much those seen in the latter animal, and appear to migrate into the vesicles in a similar manner. A few cells, apparently of similar character, have also been seen in the thyroid of the Rabbit.

In the thyroid of the Pigeon large groups are frequently seen, consisting of cells, which are larger than the adjacent epithelial cells (see Plate 69, fig. 15). They are round or oval in shape, and are provided each with a single spherical or oval-shaped nucleus. They resemble very much the parenchymatous cells seen in the Dog; but whether they, like them, migrate into the vesicles I am unable to say, as I have not observed any of them in the substance of the epithelial walls.

Round cells were sometimes seen in the epithelium of the Skate, but the nature of these could not be ascertained. In the Conger Eel groups of cells somewhat rounded in form were found amongst the cylindrical epithelial cells, but in all probability these were connected with the origin of the small vesicles in the walls of larger ones, as above described.

V. *Lymphatics and their contents.*

Literature.—Lymphatics.—I have already described (*op. cit.*, p. 559) and figured in the thyroid gland of the Dog a dense system of lymphatics consisting of lymphatic vessels, spaces, and canals, traversing the gland in all directions. In opposition to FREY (quoted by HENLE, *loc. cit.**), who I supposed was the last observer who had then studied these structures, I laid stress on their not ending in blind extremities, as described by that author, and on their being much more numerous than he supposed. After the publication of my observations I became aware that in 1873 P. A. BOÉCHAT (*op. cit.*) had described a very similar network of lymphatics in this organ. BOÉCHAT (p. 39) found that the lymphatics of the thyroid gland of the Dog form a vast hollow network, contained in the stroma of connective-tissue, which serves as framework of the organ. The network is formed of lymphatic sinuses, which communicate with one another largely. In its meshes are contained the thyroid cavities (vesicles) whose walls are at many points adherent to those of the lymphatics. He studied them in specimens injected with nitrate of silver and with Prussian blue. PEREMESCHKO (*op. cit.*) had also described in the thyroid of the Dog a rich network of lymphatics, which surrounds small groups of vesicles; also large lymphatic canals, which frequently surround the arteries like sheaths, and under the capsule a network of lymphatic spaces ("Gänge").

Since the appearance of my paper ZEISS (*op. cit.*, 1877) has given a description of these vessels, which agrees on the whole with that given by BOÉCHAT and myself. He finds that the lymphatics form wide cavernous canals, which are not confined to the larger septa, but also as minute clefts (always lined by the same endothelium) encircle the follicles separately or in small groups of two, four, or six. As regards the endothelium, he finds its cells elongated and with wavy borders, the margins of neighbouring cells either fitting accurately into one another or else leaving between them small round or oval areas of cement-substance, which become more darkly stained than the gelatine (employed with the nitrate of silver in injecting) and project somewhat above the level of the endothelial cells. The lymphatic spaces frequently surround the arteries and veins for considerable distances.

Contents of lymphatics.—In my former paper (p. 562) I described the appearances presented by the contents of the lymphatics, namely, that of a homogeneous or granular mass, and argued in favour of its being during life of a viscid consistence. I also drew attention to the close resemblance (amounting, as I considered, to morphological identity) between the coagulated contents of the lymphatics and those of the vesicles, and urged its importance as tending to show that the material which is formed in the vesicles is carried off by the lymphatics. ZEISS has also noticed the coagulability of the contents of the lymphatics, but whilst admitting that they stain in similar

* I have not been able to obtain the original article of FREY in the "Vierteljahrsschrift der Naturforschenden Gesellschaft in Zürich," viii., i., 1863.

manner with colouring agents, he points out that the contents of the lymphatics show an entire absence of the phenomena of contraction observed in the contents of the vesicles.

Observations.

Mammalia.—A system of lymphatics, resembling in its general characters that described in the Dog, has been observed in the thyroid glands of other animals (*e.g.*, Kitten, Horse, Rabbit) by means of injections by the method of puncture. The extent of distribution of the network and the minuteness of its ramifications appear to vary in different animals.

The homogeneous or granular contents of the lymphatics have been observed in the same vessels in the thyroids of other animals (*e.g.*, Horse, Sheep). This material occurs both in injected and in uninjected specimens. The quantity varies much in different glands of the same species of animal, it being sometimes present in large quantities and at other times being apparently entirely absent. With a view of ascertaining whether the occurrence of this material in the lymphatics was peculiar to either sex, or to any particular age, I examined the thyroids of Dogs of various ages in both sexes, but, as might be expected, without any definite result. It appeared to be present or absent regardless of the sex or age of the animal. The margins of the coagulated content of the lymphatics undoubtedly do not present the indented appearance seen in the vesicular contents, but this is, I imagine, simply due to the absence of epithelial cells, from which drops of clear fluid could exude (see above, pages 591 and 592).

Aves.—In the thyroid gland of Birds, on the contrary, *I have been unable to inject any system of lymphatics*. My observations on this point are as follows:—On injecting the thyroid gland of a Pigeon by the method of puncture with Berlin blue, it swells up, and the injection is seen running *in the jugular vein* with which the gland is in close apposition. (It will be remembered that on injecting the Dog's thyroid gland in a similar manner, the injection was seen emerging from the gland *in lymphatic vessels*, which ran to neighbouring lymphatic glands.) Examination of sections of the Pigeon's gland, thus injected, shows that the injecting fluid has entered vessels containing red blood-corpuscles. The same vessels become filled on injecting in like manner with a solution of nitrate of silver. To ascertain whether by the puncture-method the blood-vessels really become injected, another gland was injected with Berlin blue from the lower part of the carotid artery, the artery at the same time being secured above the gland. In this case, in which the injection had entered the capillaries and veins, it was evident that these were the same system of vessels that had been injected by the method of puncture. It may therefore be stated that on repeated injections of the thyroid gland of the Pigeon, both with Berlin blue and with nitrate of silver, by the method of puncture, *I have been unable to inject any system of lymphatic vessels, but have always found the injection in the blood-vessels of the gland*. The *blood-vessels* of the thyroid gland of the Pigeon also present the following pecu-

liarities:—The capillaries, as usual, form a network running between the individual gland-vesicles, but in proportion to the size of the vesicles they do not appear so minute or to have such complicated ramifications as in the case of other animals (*e.g.*, Sheep or Tortoise), but resemble more in their distribution the lymphatics in some of the Mammalia (see Plate 69, fig. 17). The veins frequently surround either partially or entirely the arteries which they accompany (see Plate 69, fig. 18). Immediately under the surface of the capsule numerous large veins are seen, and in the fibrous capsule itself layers of red blood-corpuscles have been observed, which appear to be contained in blood-vessels communicating with the veins in the interior.

In a preliminary communication presented to the Society on this subject (Proc. Royal Society, No. 185, 1878), I mentioned that once or twice I had noticed in the large veins on the surface of the gland (under the capsule) in addition to red blood-corpuscles, and perhaps coloured injection, a greater or less quantity of a material of homogeneous aspect, presenting an appearance similar to the material seen in the vesicles, also to that described above in the lymphatics of the Dog. I do not, however, attach any importance to this, as the contents of the blood-vessels in the Dog, when coagulated, also sometimes present this homogeneous aspect.

In the thyroid gland of the Rook no system of lymphatics becomes injected by the method of puncture, but the blood-vessels, presenting an appearance very similar to those in the Pigeon, become filled.

Reptilia.—In the thyroid gland of the Tortoise a network of lymphatics can be injected by the method of puncture, of which the smaller ramifications run between almost all individual vesicles. In specimens injected with nitrate of silver the lymphatics are seen to be lined by a layer of endothelium, of which the cells are usually elongated and have a sinuous outline. The areas, stained dark with nitrate of silver (as described by ZEISS; see above, p. 595), are well seen in this animal (see Plate 69, fig. 16). They vary much in size and shape, and often appear to have a double contour. Usually, though not always, they are situate on the boundary line separating two endothelial cells. In the Tortoise the lymphatics have not usually any visible contents, but they sometimes contain a granular material which stains scarcely at all with hæmatoxylin.

Pisces.—In the thyroid gland of both Skate and Conger Eel an extensive system of vessels lined with endothelium becomes injected by the method of puncture. (A considerable portion of the injection, however, also passes into the meshes of the connective-tissue.) Being doubtful as to whether the vessels thus injected were of lymphatic or blood-vascular character, I injected the thyroid gland of a large Conger Eel with solution of Berlin blue from the blood-vessels (dorsal aorta and efferent branchial trunks); and from a comparison of the vessels injected in this case with those filled on injection by the puncture-method, I have been led to the conclusion that in the thyroid gland of the Conger Eel at least, as far as my observations extend, *there is no evidence of any system of lymphatic vessels.* Large veins, filled with red

blood-corpuscles, are frequently seen in this thyroid gland amongst the vesicles, and between these veins and the epithelial wall of the vesicles capillaries often ramify.

VI. *Blood-vessels.*

Literature.—The great richness of the thyroid gland in blood-vessels and the abundance of its capillaries, which form extensive ramifications on the surface of the vesicles, are generally acknowledged.

ZEISS (*op. cit.*, p. 34) describes, in specimens in which the blood-vessels are injected with Berlin blue, knotty dilatations forming dark blue drops situate laterally on the capillaries, or similar structures forming apparently the blind end of a capillary. He observed these in the Rabbit, Cat, and Rat, and says he was unable to observe these peculiar bulging or drop-like dilatations in uninjected specimens, although he speaks elsewhere of the capillaries in uninjected specimens being wedged in between the epithelial cells, and forming small projections towards the epithelial layer. ZEISS considers that the presence in such great numbers of these nodules or dilatations on the capillaries may retard to a considerable extent the flow of blood through the vessels of the gland, thereby favouring any secretion from, or absorption into, the blood-vessels, which may take place either in connection with the vesicles or with the lymphatics. Neither BOÉCHAT nor PEREMESCHKO make any mention of these dilatations, and in the figure which the latter observer gives of the blood-vessels no sign of them is visible.

Observations.—In the thyroid gland of the Tortoise I have frequently observed, in transverse sections of the epithelial walls of the vesicles (in uninjected specimens), projections of the capillaries between the epithelial cells, towards the interior of the vesicles. I have endeavoured repeatedly to show these by injections of the blood-vessels of the gland in this animal, but without much success, owing to a shrinking of the epithelial cells. It appears very probable that it is through these projections of the capillaries that the escape of blood-corpuscles (red or colourless) takes place into the cavity of the vesicles. In fact, in one specimen I could see in a vesicle, close to one of the capillary projections, some red and colourless blood-corpuscles which had apparently just escaped from a blood-vessel through this channel. Some peculiarities of the blood-vessels in the thyroid glands of Birds have been alluded to under the head of lymphatics (*vide supra*, p. 598), and those of the Conger Eel have also been referred to above (p. 599).

The relation of both large and capillary blood-vessels to the lymphatics has been discussed in considering the basement membrane (*vide supra*, p. 588).

VII. *Undeveloped portions.*

In the thyroid gland of the Dog bodies of considerable size are frequently seen, which differ entirely in structure from the rest of the gland (see Plate 69, fig. 19). They are rounded or flattened in shape, usually situate on the surface of the organ, and

possess the following structure (see Plate 69, fig. 20). They consist of a solid mass of more or less *cylindrical rows of cells* (Plate 69, fig. 20 1, 1, 1) which are much convoluted and interlace in all directions. Between them run capillary blood-vessels and also probably some lymphatics. These "cylinders" are composed of cells resembling epithelial cells, columnar or cubical in shape, those on the surface of the cylinder, next to the capillaries, being arranged at right angles to those vessels (Plate 69, fig. 20, 3). Each cell is provided with a nucleus usually oval in shape. In very few, if in any, of these cylinders have I been able to detect any central canal. In Dogs aged three months and upwards I have usually observed these "undeveloped portions" as distinct bodies, not continuous with the normal gland-tissue, but separated from it by layers of connective tissue, and frequently lying in depressions on the surface of the gland (see Plate 69, fig. 19). They appear to be portions of gland whose development has become arrested at an early stage, and there was in these Dogs, usually, no evidence to show that these bodies were undergoing any further development. Exceptions to this, however, occur; for example, in a male Dog (aged nearly 2 years) an "undeveloped portion" was found which was not distinctly separated from the rest of the gland-tissue, and contained well-formed vesicles showing that it was undergoing further development.

In the Kitten similar undeveloped portions are seen, which are sometimes observed to be continuous with the ordinary gland-tissue. In this case a formation of vesicles from the cylinders of cells appears to be taking place by the growth into them laterally of processes of connective-tissue with blood-vessels, and by their excavation into vesicles. In the Kitten the cylinders are less convoluted than in the Dog, and throughout the gland the fully-formed vesicles frequently appear grouped in rows, which have a more or less parallel arrangement.

"Undeveloped portions" have also been observed in the thyroid glands of the Sheep, Seal, and Rook. In the Seal there was a large quantity of fibrous tissue between the cylinders, as well as between the vesicles in the ordinary gland-tissue.

Somewhat similar, but much shorter, cylinders of cells have been seen in the thyroid gland of the Pigeon scattered throughout the gland.

There can be no doubt that these bodies are portions of the gland of which the development has progressed no further than the stage described by W. MÜLLER (*vide supra*, p. 583), in which the gland consists of a network of cylindrical tubes, at first irregular, but afterwards becoming more regular in character; the tubes (according to MÜLLER) being composed of short cylindrical epithelial cells, placed radially on the surface of the envelope and being at first *solid*, but subsequently provided with a lumen. I have also observed these cylinders in the thyroid glands of foetal Pigs (measuring about $2\frac{1}{4}$ inches in length). The occurrence of these undeveloped portions continuous with the ordinary gland-tissue in the thyroids of *young* animals of course merely indicates that a formation of gland-tissue is taking place in the manner described by W. MÜLLER.

In the thyroid gland of the Dog, however, it is remarkable that although these bodies are of frequent occurrence, there is, usually, in Dogs aged three months and upwards no evidence to show that they are undergoing further development. It is an interesting question whether the undeveloped portions, which are distinct from the gland, may not under certain circumstances become developed into true gland-tissue, and either give rise to the isolated lobes mentioned by various authors, or simply cause an increase in size of the gland itself.

Masses of *lymphoid tissue* have been observed in the thyroid glands of Kitten and Pigeon.

GENERAL CONCLUSIONS.

1. In the Frog, in opposition to the statements of several observers, the thyroid gland forms two small bodies situate, one on either side, on the ventral surface of the hyoid cartilage (or bone) usually but not always in direct contact with this structure. They are placed either between the hyoid cartilage and the hyoglossus muscles, or else immediately to the outer side of the latter, just anterior to the point of their convergence.

2. In the thyroid gland of adult animals the *vesicles* form closed cavities which are not in communication with one another to any extent. Branched vesicles, which may be present in the glands of adult animals, probably merely indicate that an increase in the number of vesicles is taking place by the growth into them of involutions of their walls. In the Conger Eel small vesicles are frequently observed in the walls of larger ones, into which they appear sometimes to burst by causing a flattening of the epithelial walls.

3. Whilst the shape of the *epithelial cells* varies much in different animals, the general tendency of these cells throughout the Vertebrate series, as far as examined, is to the columnar form.

A delicate *reticulum* (as described by ZEISS) is found amongst the epithelial cells of the vesicles. In a profile view of the epithelium *club-shaped cells* are also often seen, which are probably more or less branched cells situate in the swollen parts of the reticulum.

The only form of *basement membrane* observed has been a delicate layer of connective tissue between the epithelium and the endothelium of the lymphatics in which the blood-vessels ramify.

4. The following are the chief *contents of the vesicles* which have been observed in the microscopical examination of specimens hardened in alcohol.

(a) *Homogeneous or granular material* ("colloid substance" of authors) has been observed with slight variations in all classes of the Vertebrata, and is undoubtedly a normal product of the organ.

(b) *Red blood-corpuscles* are frequently found in the vesicles in greater or less number and in various stages of disintegration and decolorisation.

In the epithelial wall of vesicles containing red blood-corpuscles, granules of yellow

pigment are sometimes seen, which appear to be due to the absorption by the epithelial cells or reticulum of the colouring matter of the effused blood. Observations on the Dog lead to the inference that in this animal *an escape of red blood-corpuscles is almost constantly taking place into a greater or less number of vesicles*, and its occurrence in other animals also (Man, Tortoise, Conger Eel) renders it *very probable that the passage of coloured blood-corpuscles into the vesicles is a normal occurrence in the thyroid gland*. Further observations (Dog, Rook, Seal) also render it very probable that *normally under certain circumstances an escape of red blood-corpuscles takes place into a large proportion of the vesicles of the thyroid gland*. The blood thus effused contributes to a large extent to the formation of the "colloid" substance, and probably has an important bearing on the physiology and pathology of the organ.

(c) *Colourless blood-corpuscles* are frequently found in the homogeneous material in the gland-vesicles of the Tortoise. A migration of colourless corpuscles into the vesicles is a *normal* occurrence in the Tortoise, but it may also take place in other animals.

(d) *Rounded masses*, staining darkly with hæmatoxylin or of a bright yellow colour with picrocarminate of ammonia, are seen in the vesicles of many animals. *Crystals* sometimes occur in the gland vesicles (Tortoise and Rook) and brown pigment granules have been observed in the colloid material in the vesicles (Frog and Conger Eel).

5. *Parenchymatous cells*, already described in the Dog, also occur in the glands of young Dogs and in less numbers in the Cat, in which animal they appear to migrate into the vesicles in the same manner as in the Dog. Large groups of round or oval-shaped cells, provided with a single nucleus, frequently occur in the thyroid gland of the Pigeon.

6. A network of *lymphatics* resembling in its general characters that previously described in the Dog, though differing apparently in the extent of its ramifications, is also seen in some other Mammals. The homogeneous or granular contents of the lymphatics in the Dog occur in both injected and in uninjected specimens and in very variable quantity; the amount being apparently independent of the sex or age of the animal.

In the thyroid gland of Birds (Pigeon) no system of lymphatics is injected by the method of puncture, but the injecting fluid enters the blood-vessels of the gland, escaping by the jugular vein.

The thyroid gland of the Tortoise contains a network of lymphatics, of which the smaller ramifications run between almost all individual vesicles. The endothelium of these lymphatics presents well marked areas of irregular size and shape, stained darkly with nitrate of silver. In the thyroid gland of the Conger Eel no evidence of a system of lymphatics was obtained by injections.

7. The *arteries* are ensheathed more or less completely in their accompanying lymphatics (Dog, Tortoise); the *capillaries*, on the contrary, run between the epithelium of the vesicles and the smallest ramifications of the lymphatics (Tortoise) leaving

intervals between them, where the lymphatic is not separated from the epithelium by blood-vessels. Projections of the capillaries between the epithelial cells towards the cavity of the vesicles occur frequently in the Tortoise. In the Pigeon the inter-vesicular ramifications of the blood-vessels are not so complicated or minute as in other animals (Sheep, Tortoise) but resemble more the distribution of lymphatics in some Mammals. The veins, in the Pigeon, frequently surround either partially or entirely the arteries which they accompany.

8. Bodies consisting of portions of the gland of which the development has proceeded no further than the stage of convoluted "cylinders of cells" described by W. MÜLLER are frequently seen in the thyroid gland. The cylinders are composed of cubical or columnar cells, resembling epithelial cells, those on the surface of the cylinder being arranged at right angles to the capillaries, which ramify between the cylinders. In Dogs aged three months and upwards these "undeveloped portions" usually form distinct bodies separated by layers of connective tissue from the rest of the gland. In young animals, such as the Kitten, they are often continuous with the ordinary gland-tissue into which they are evidently developing.

In conclusion, I wish to offer my best thanks to Dr. KLEIN for his direction in this research, which has extended over a period of several years.

EXPLANATION OF THE PLATES.

PLATE 68.

Fig. 1. Transverse section of a portion of the neck of a moderate sized Frog, on a level immediately anterior to the convergence of the hyoglossus muscles. (VÉRIK's obj. O, oc. I. All the lenses employed in these drawings were VÉRIK's, except an obj. F of ZEISS.)

1. Hyoid cartilage.
- 2, 2. Thyroid glands, situate directly on the ventral surface of the hyoid cartilage.
3. Hyoglossus muscles seen in transverse section.

Fig. 2. Outline of a branched vesicle from a longitudinal section of the thyroid gland of a Puppy (aged 5 weeks) hardened in alcohol. The section from which this was taken was purposely very thick, and the different portions of the vesicle, which are situate on different planes, can only be brought into view by repeatedly altering the focus. The epithelium is semi-diagrammatic. (Obj. F, oc. I.)

Fig. 3. From a transverse section of the thyroid gland of a Dog (aged 3 months) hardened in alcohol. Showing the outline of a branched gland-vesicle. This body appears at first sight to be composed of three distinct vesicles, but on focussing the continuity of these three can be traced at 1, 1. (Obj. 6, oc. I.)

Fig. 4. Transverse section of a portion of the wall of a large gland-vesicle from the thyroid gland of a Conger Eel, hardened in alcohol and stained with hæmatoxylin. (Obj. 6, oc. I., tube half drawn out.)

1. Cavity of the large vesicle.
- 2, 2. Its epithelial wall, of which the cells are represented semi-diagrammatically.
- 3, 3. Small vesicles, which are situate in the epithelial wall of the large vesicle and are separated by much flattened epithelial cells from the cavity of the latter.
4. Another vesicle, separated by cells less flattened from the cavity of the large vesicle.
- 5, 5. Vesicles distinctly outside the wall of the large vesicle, which appear to be growing outwards.

The homogeneous contents of the small vesicles are seen with their jagged outlines. The vesicles represented in this drawing are not all quite on the same level.

Fig. 5. From a section of the thyroid gland of the Tortoise, hardened in a 1 per cent. solution of chromic acid (17 hours) and subsequently in diluted and in strong alcohol, and stained with hæmatoxylin. The intercellular reticulum is seen from the surface, but the intervening epithelial cells are not represented. (Obj. F, oc. I.)

Fig. 6. From a section of the thyroid gland of the Conger Eel, hardened in alcohol and stained with hæmatoxylin, giving a surface view of the epithelial cells amongst which are seen the branched nuclei of the club-shaped cells. They are probably connected with the intercellular reticulum. (Obj. 6, oc. I., tube half drawn out.)

Fig. 7. From a section of the thyroid gland of the Tortoise prepared as follows: injected by the method of puncture with $\frac{1}{8}$ th per cent. solution of osmic acid, hardened in a 1 per cent. solution of the same acid for five hours, and subsequently in alcohol, mounted in glycerine. It shows (at 1) the epithelial wall of a vesicle cut obliquely, beyond which there projects (at 2) a membrane having delicate wavy striæ on it. (Obj. F, oc. I.)

Fig. 8. From a longitudinal section of the thyroid gland of a Kitten injected with nitrate of silver by the method of puncture, hardened in alcohol and stained with hæmatoxylin. The drawing represents a portion of the wall of a vesicle seen from the surface. By focussing from the interior of the vesicle, three layers can be distinguished. First, the oval-shaped nuclei, at regular intervals, stained with hæmatoxylin; secondly, a layer of dots and short striæ, stained with nitrate of silver, only represented in the centre of the drawing; and thirdly, the outlines of the endothelial cells of a lymphatic, also stained with silver (1, 1). (Obj. F, oc. II.)

Fig. 9. From a section of the thyroid gland of the Tortoise (injected with Berlin

blue by the method of puncture, but the injection had not penetrated into this branch of the lymphatics), hardened in alcohol and stained with hæmatoxylin, showing a portion of the walls of two adjacent vesicles with the intervening structures seen in transverse section. (Obj. F, oc. I.)

- 1, 1. Epithelial walls of two vesicles.
- 2, 2. Cavities of ditto.
- 3, 3. Small branch of lymphatic running between the two vesicles. The nuclei of some of its endothelial cells are seen.
- 4, 4, 4. Capillaries situate between the lymphatic and the epithelial cells.

This drawing also shows certain points at which the lymphatics are *not* separated from the epithelial cells by capillaries.

Fig. 10. From a section of the thyroid gland of the Tortoise, uninjected, hardened in alcohol and stained with hæmatoxylin. Section of a vesicle containing homogeneous material, with indented edges, embedded in which are numerous red blood-corpuscles partly separate and partly fused together to form a ball in the centre of the vesicle. Epithelium drawn semi-diagrammatically. (Obj. F, oc. I.)

Fig. 11. Section of another vesicle from the same thyroid gland as the preceding, prepared in like manner. The vesicle contains, embedded in the homogeneous material, several large round nucleated cells (colourless blood-corpuscles). Epithelium semi-diagrammatic. (Obj. 8, oc. I.)

Fig. 12. From a longitudinal section of the thyroid gland of a Dog (female, aged 7 or 8 years), uninjected, hardened in alcohol and stained with picrocarminate of ammonia. Numerous vesicles are seen in section, almost all of which contain in addition to the usual homogeneous material a greater or less number of partly disintegrated red blood-corpuscles. The epithelium, which is somewhat flattened, probably from the effect of the re-agents, is represented diagrammatically. (Obj. 6, ocs. I. and III.)

PLATE 69.

Fig. 13. From a transverse section of the thyroid gland of a Dog (male, aged 3 months), uninjected, hardened in alcohol and stained with hæmatoxylin. (Obj. F, oc. I.)

1. Epithelial wall of a vesicle, which at—
- 2, 2. Contains numerous yellow pigment granules. At the right-hand lower corner the epithelium is cut somewhat obliquely, so that its inner margin is not well defined. In the interior of the vesicle are seen numerous red blood-corpuscles.
3. Portion of the wall of an adjacent vesicle also containing many red blood-corpuscles. In this epithelial wall are likewise seen numerous pigment granules.

Fig. 14. From a transverse section of a thyroid gland of the Rook, uninjected, hardened in alcohol and stained with hæmatoxylin. Representing the epithelial walls of several vesicles containing yellow pigment-granules of various sizes.

- 1, 1, 1, 1, 1. Cavities of vesicles, whose contents are not represented.
2. Epithelial wall of a vesicle, seen from the surface, showing numerous pigment granules. (Obj. F, oc. I.)

Fig. 15. Large round cells from a longitudinal section of the thyroid gland of the Pigeon, injected from the artery, hardened in alcohol and stained with picrocarminate of ammonia and with hæmatoxylin. (Obj. 8, oc. I.)

Fig. 16. From a section of the thyroid gland of the Tortoise, injected with $\frac{1}{8}$ per cent. solution of nitrate of silver by the method of puncture, hardened in alcohol and stained with hæmatoxylin. Surface view of the endothelium of a large lymphatic, showing in addition to the endothelial markings areas of various size, stained darkly with nitrate of silver. (Obj. 8, oc. I.)

Fig. 17. From a longitudinal section of the thyroid gland of a Pigeon, injected by the method of puncture with $\frac{1}{8}$ per cent. solution of nitrate of silver, hardened in alcohol and stained with hæmatoxylin.

- 1, 1, 1. Small intervesicular blood-vessels, into which the nitrate of silver has run, containing red blood-corpuscles.
- 2, 2, 2. Walls of ditto stained with nitrate of silver.
- 3, 3, 3. Gland-vesicles stained with hæmatoxylin.

In this specimen the blood-vessels also contain coagulated fibres which are not represented in the drawing. (Obj. 6, oc. I, tube drawn out.)

Fig. 18. From a longitudinal section of the thyroid gland of the Pigeon, injected by the method of puncture with Berlin blue, hardened in alcohol and stained with hæmatoxylin.

- 1, 1, 1. Gland-vesicles only represented in outline.
 - 2, 2. Two arteries seen in transverse or slightly oblique section.
 - 3, 3. Vein containing red blood-corpuscles and partly surrounding the arteries
- In addition to the blood-corpuscles the vein contains Berlin blue injection, and some homogeneous balls which are not represented in the figure. (Obj. F, oc. I.) (For explanation of these two figures see above, p. 598.)

Fig. 19. From a longitudinal section of the thyroid gland of a dog (male, aged 3 months), uninjected, hardened in alcohol. Undeveloped portion seen in section lying in a depression on the surface of the gland.

- 1, 1, 1. Layers of connective tissue separating the undeveloped portion (2) from the ordinary gland-tissue, and also forming septa running into the interior of the gland. The connective tissue is also seen to be continuous with the capsule of the gland. Blood-vessels are seen in it in section.

2. Section of an "undeveloped portion," with an indication of its convoluted cylinders.
- 3, 3, 3. Ordinary gland-tissue, the vesicles being represented diagrammatically and in outline. (Obj. O, oc. I.)

Fig. 20. From the same gland. Section of part of an "undeveloped portion" seen under a high power.

- 1, 1, 1. "Cylinders of cells."
- 2, 2, 2. Septa of connective tissue and blood-vessels separating these.
3. A "cylinder" from which the epithelial cells have partly fallen out. (Obj. F, oc. I.)

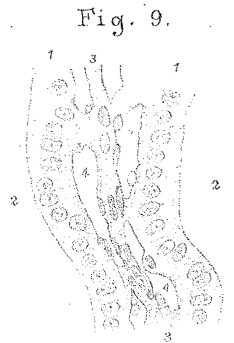
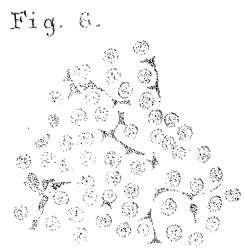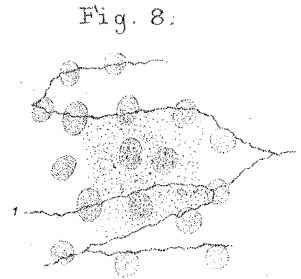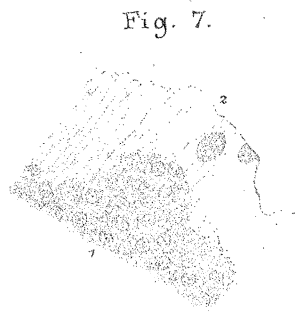
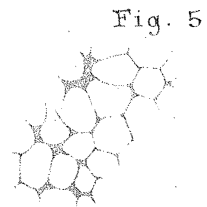
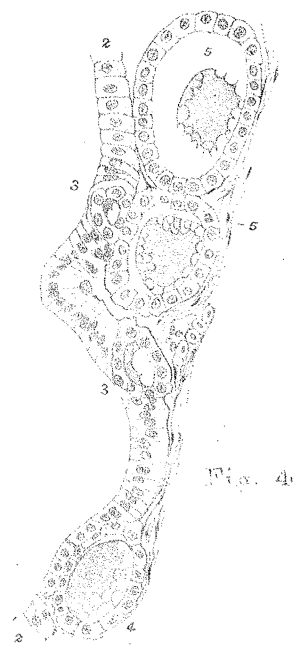
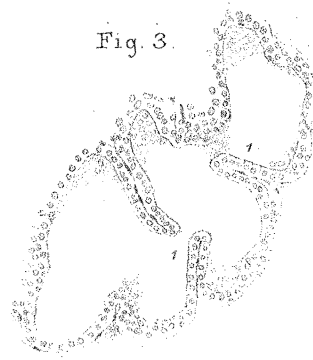
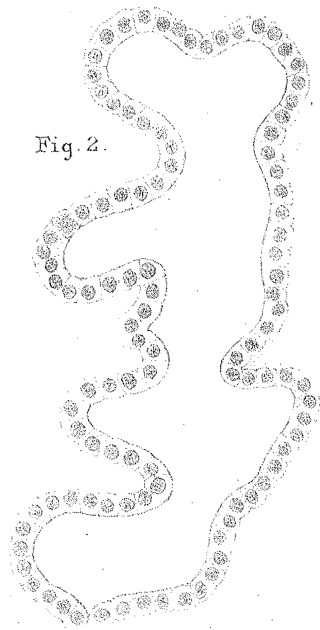
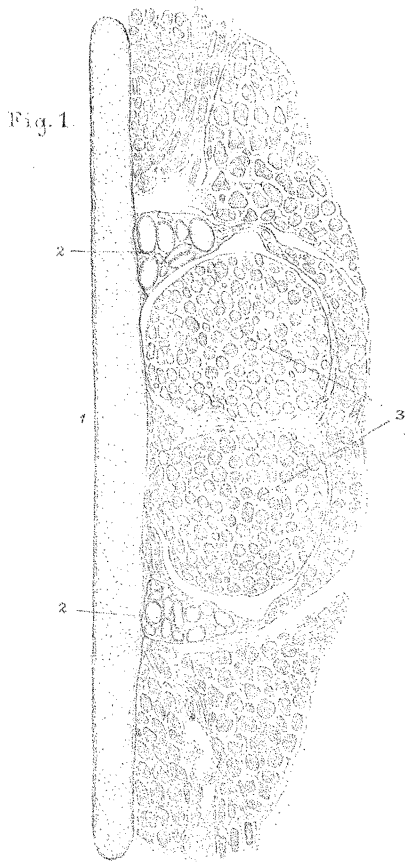


Fig. 11.

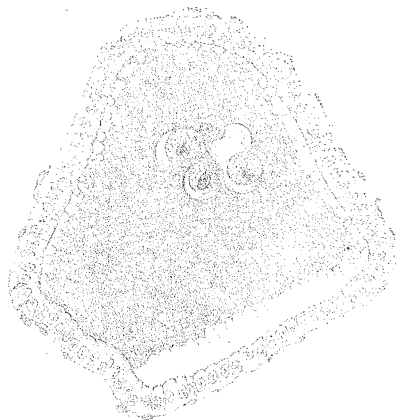


Fig. 10.

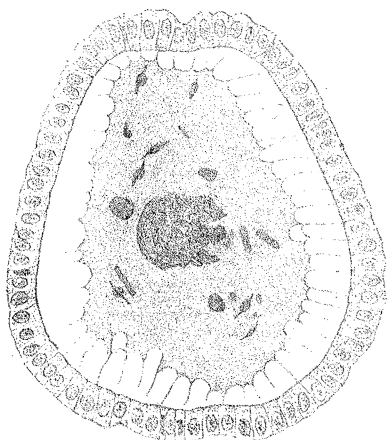
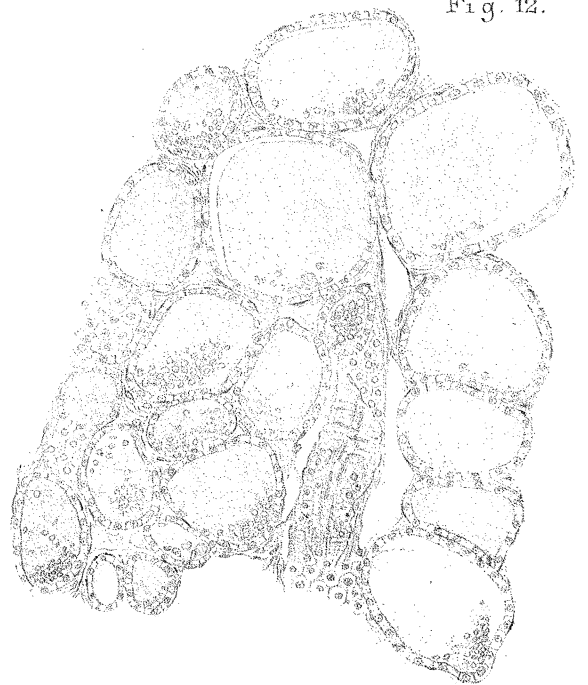
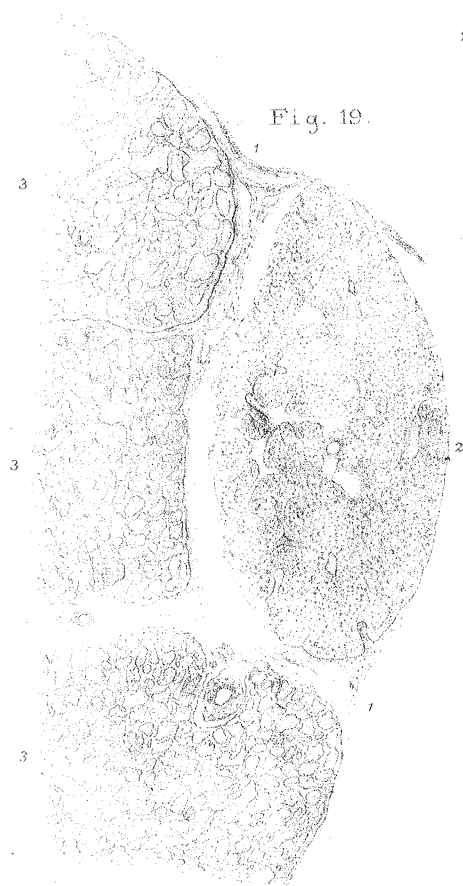
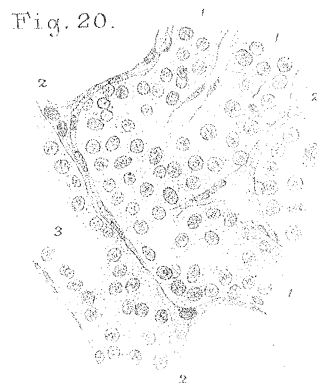
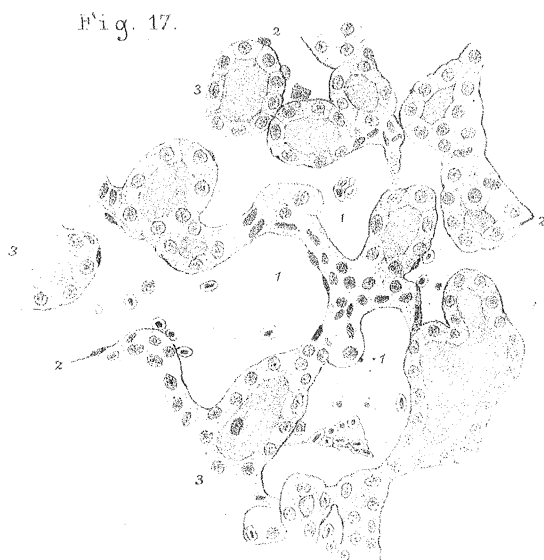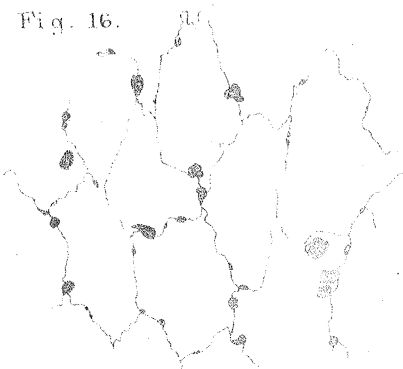
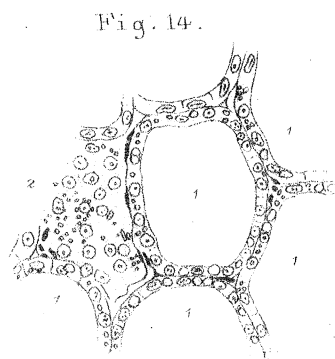
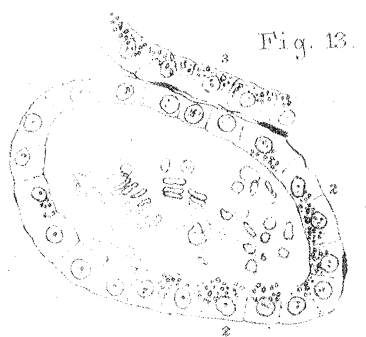


Fig. 12.





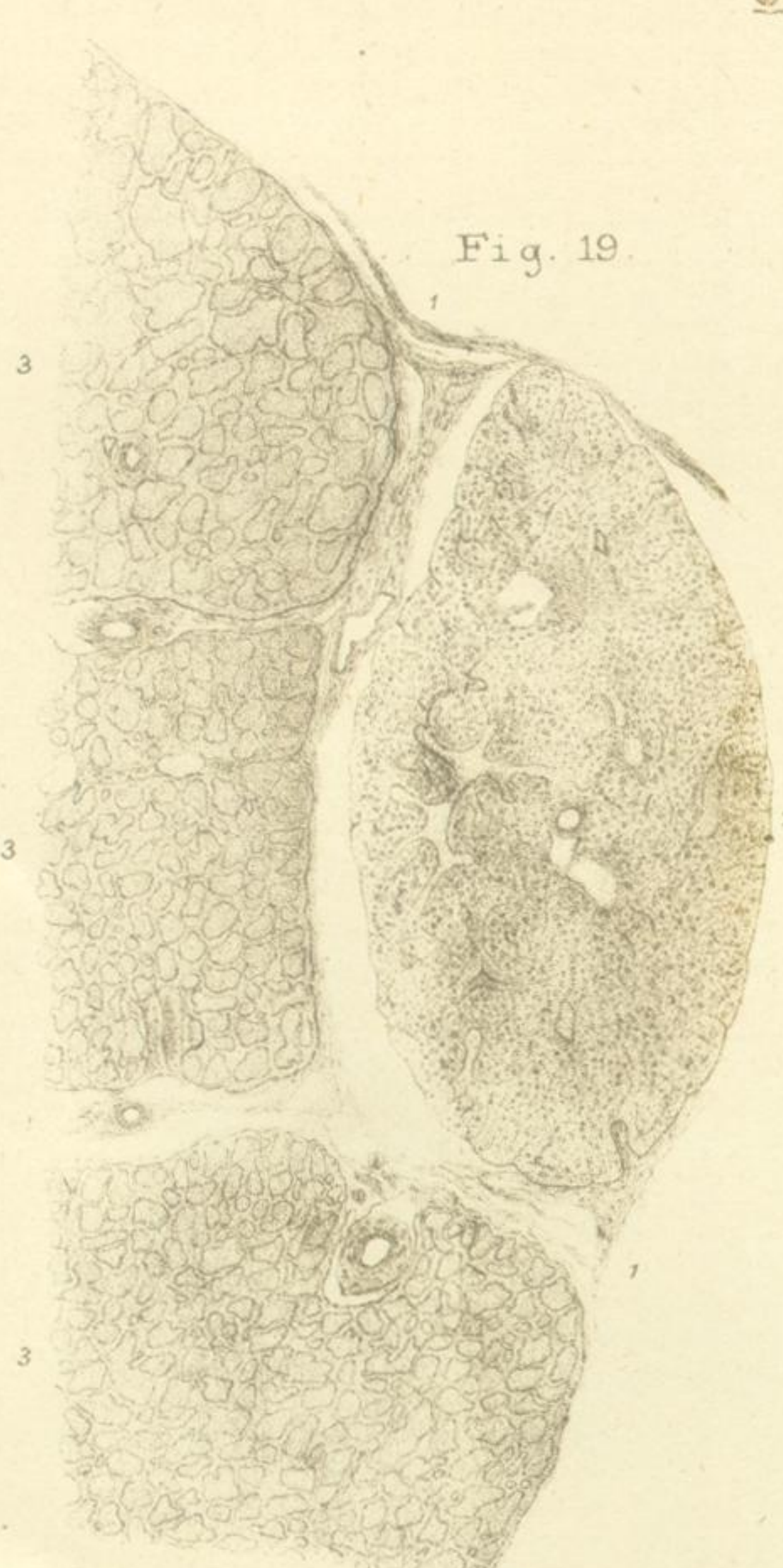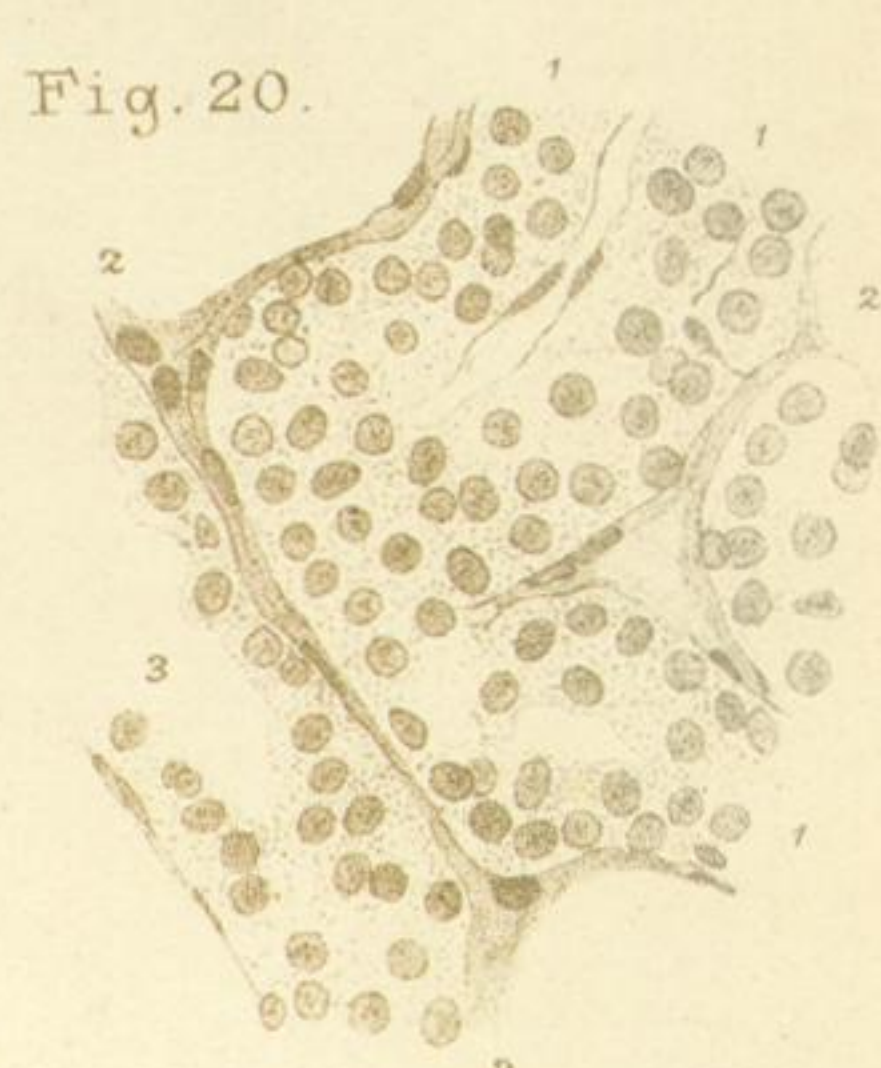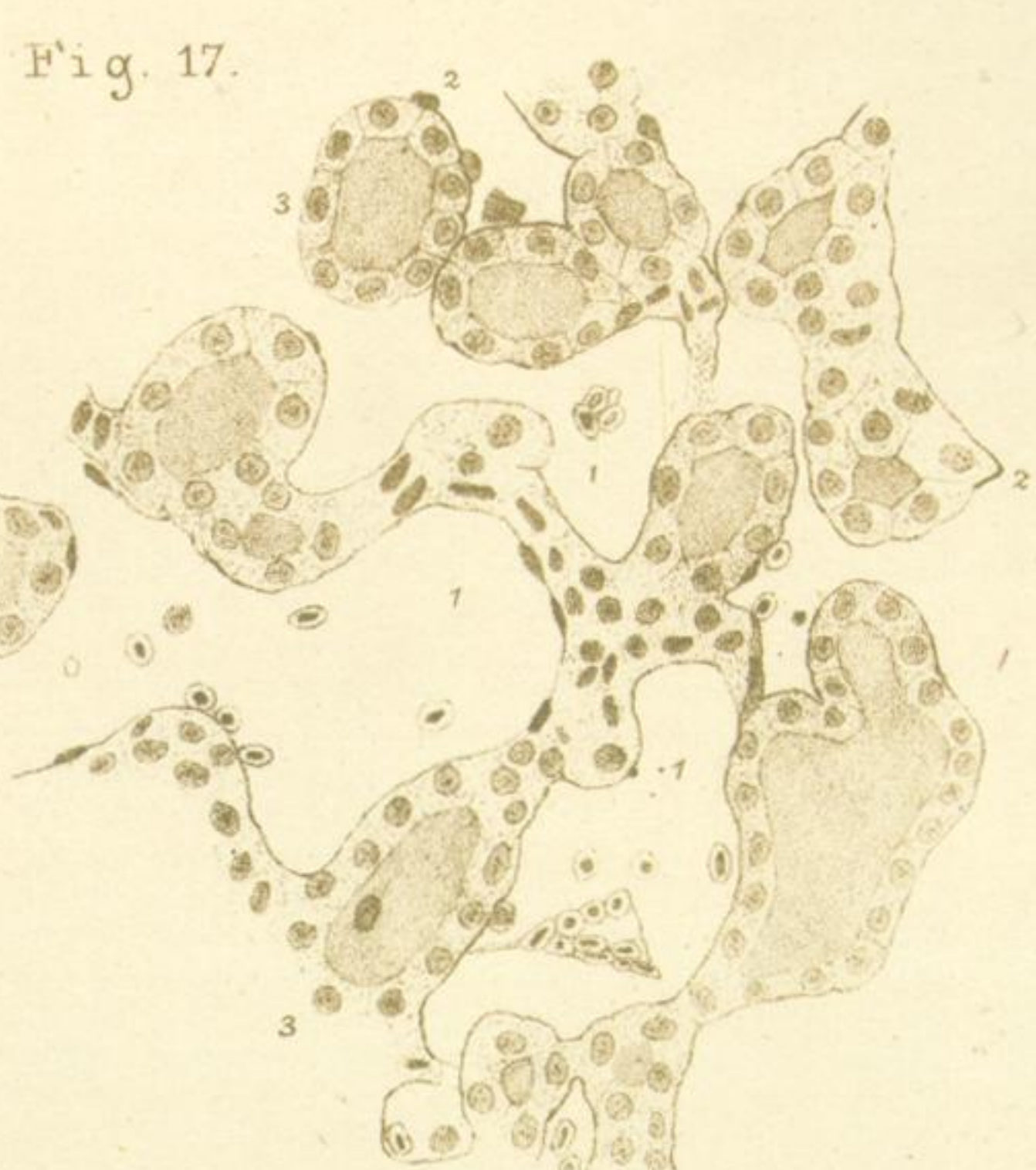
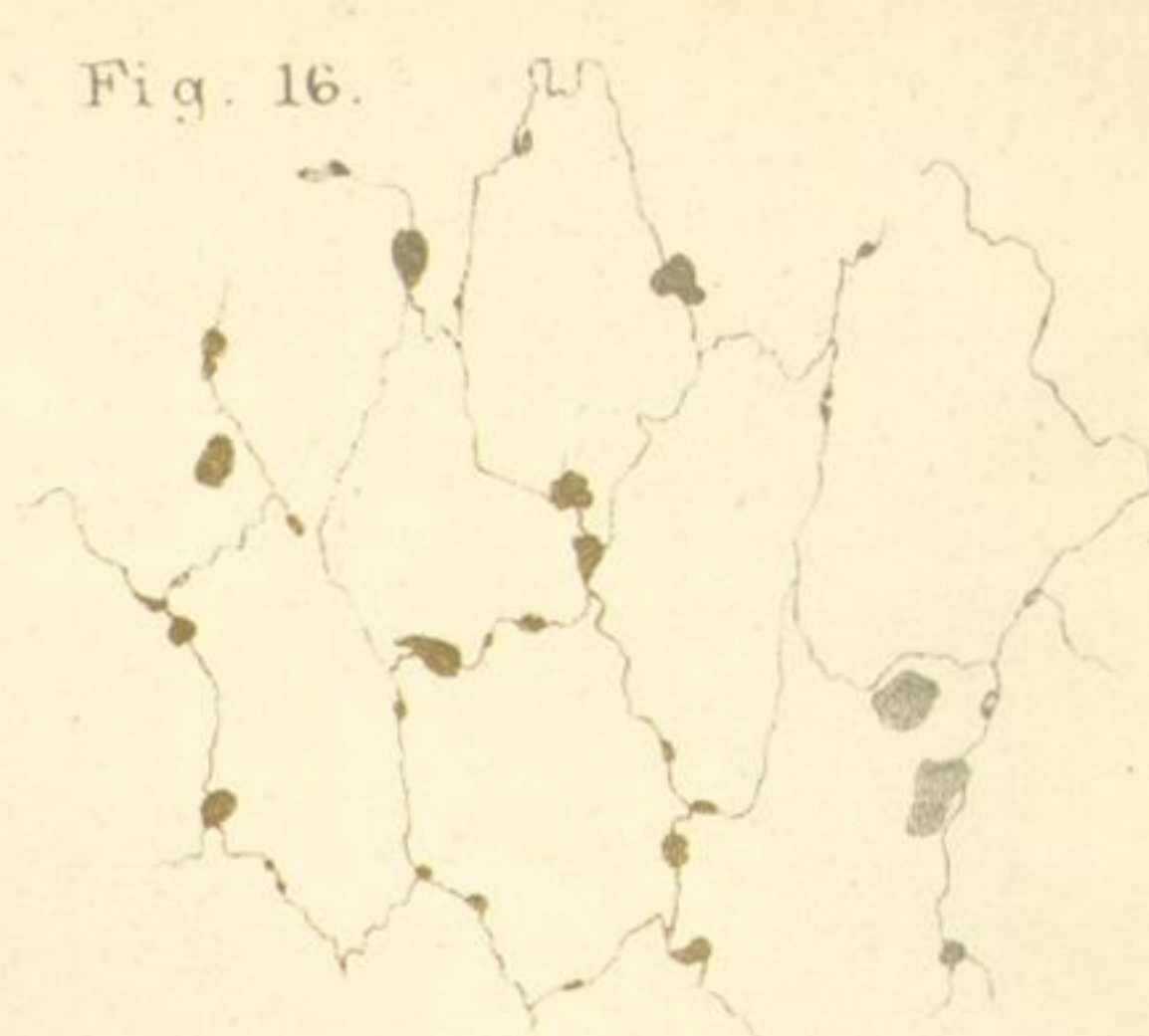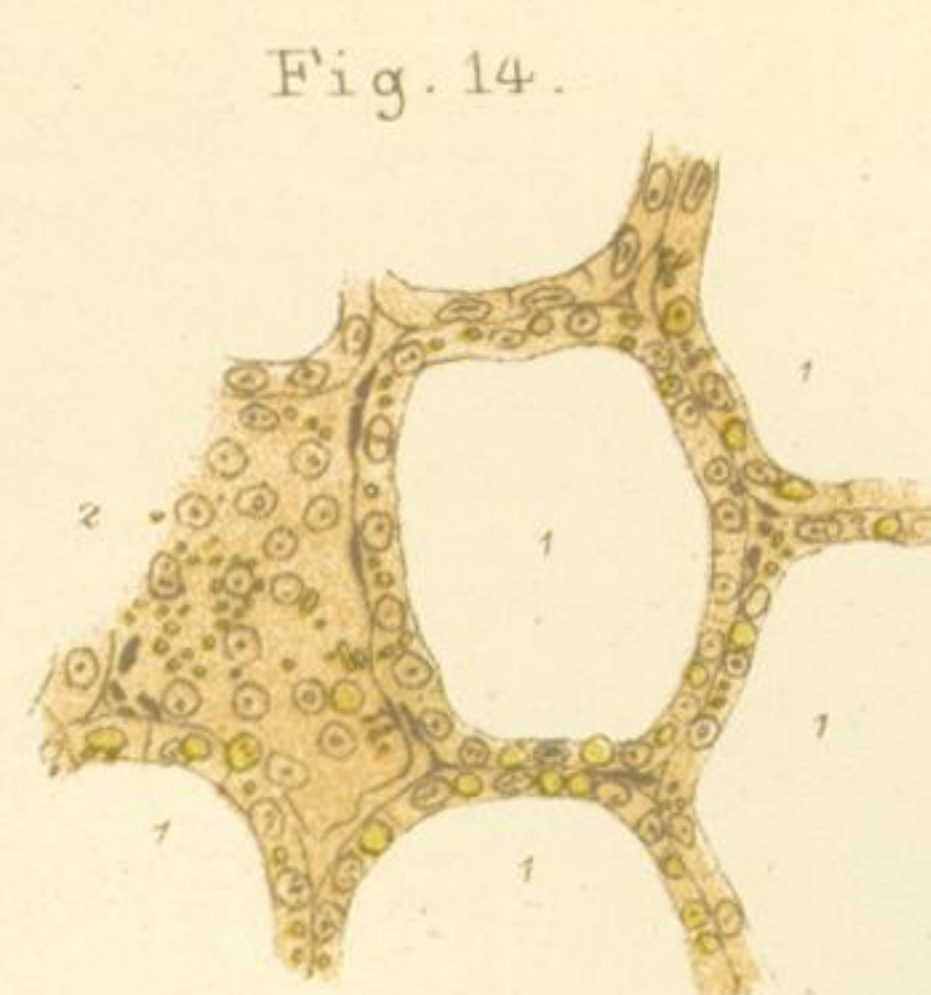
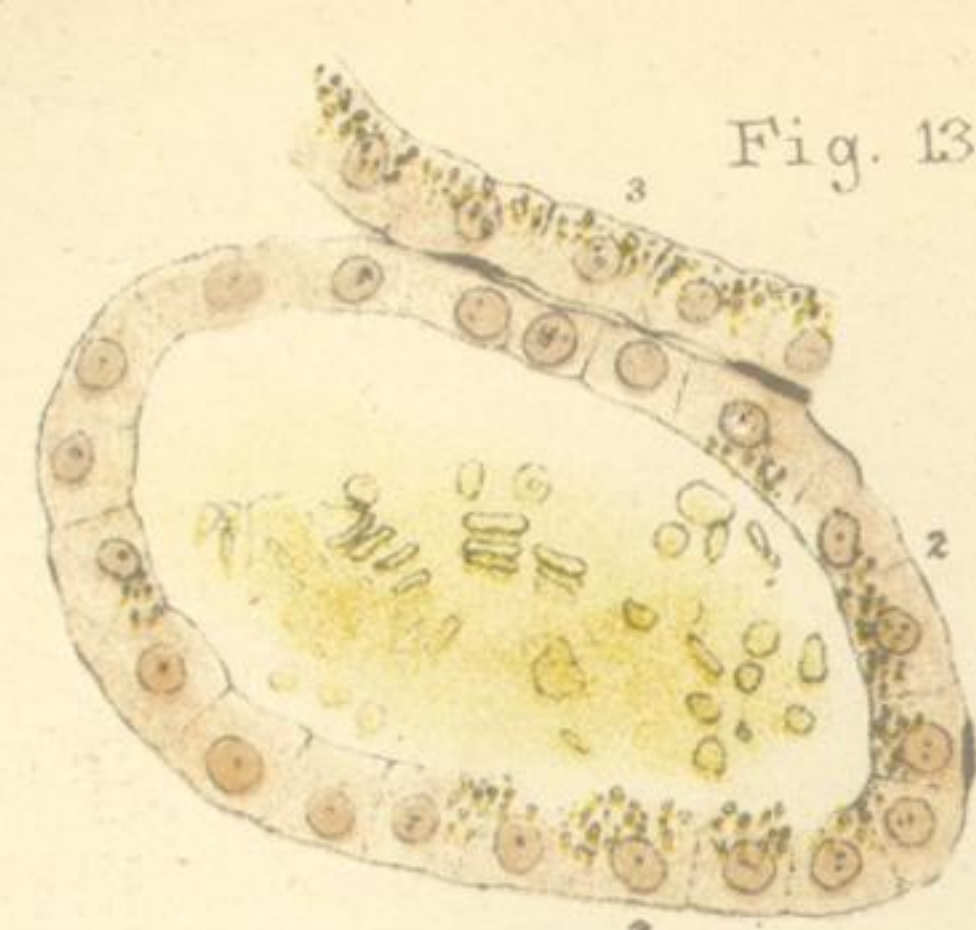


PLATE 69.

Fig. 13. From a transverse section of the thyroid gland of a Dog (male, aged 3 months), uninjected, hardened in alcohol and stained with hæmatoxylin. (Obj. F, oc. I.)

1. Epithelial wall of a vesicle, which at—
- 2, 2. Contains numerous yellow pigment granules. At the right-hand lower corner the epithelium is cut somewhat obliquely, so that its inner margin is not well defined. In the interior of the vesicle are seen numerous red blood-corpuscles.
3. Portion of the wall of an adjacent vesicle also containing many red blood-corpuscles. In this epithelial wall are likewise seen numerous pigment granules.

Fig. 14. From a transverse section of a thyroid gland of the Rook, uninjected, hardened in alcohol and stained with hæmatoxylin. Representing the epithelial walls of several vesicles containing yellow pigment-granules of various sizes.

- 1, 1, 1, 1, 1. Cavities of vesicles, whose contents are not represented.
2. Epithelial wall of a vesicle, seen from the surface, showing numerous pigment granules. (Obj. F, oc. I.)

Fig. 15. Large round cells from a longitudinal section of the thyroid gland of the Pigeon, injected from the artery, hardened in alcohol and stained with picrocarminate of ammonia and with hæmatoxylin. (Obj. 8, oc. I.)

Fig. 16. From a section of the thyroid gland of the Tortoise, injected with $\frac{1}{8}$ per cent. solution of nitrate of silver by the method of puncture, hardened in alcohol and stained with hæmatoxylin. Surface view of the endothelium of a large lymphatic, showing in addition to the endothelial markings areas of various size, stained darkly with nitrate of silver. (Obj. 8, oc. I.)

Fig. 17. From a longitudinal section of the thyroid gland of a Pigeon, injected by the method of puncture with $\frac{1}{8}$ per cent. solution of nitrate of silver, hardened in alcohol and stained with hæmatoxylin.

- 1, 1, 1. Small intervesicular blood-vessels, into which the nitrate of silver has run, containing red blood-corpuscles.
- 2, 2, 2. Walls of ditto stained with nitrate of silver.
- 3, 3, 3. Gland-vesicles stained with hæmatoxylin.

In this specimen the blood-vessels also contain coagulated fibres which are not represented in the drawing. (Obj. 6, oc. I, tube drawn out.)

Fig. 18. From a longitudinal section of the thyroid gland of the Pigeon, injected by the method of puncture with Berlin blue, hardened in alcohol and stained with hæmatoxylin.

- 1, 1, 1. Gland-vesicles only represented in outline.
 - 2, 2. Two arteries seen in transverse or slightly oblique section.
 - 3, 3. Vein containing red blood-corpuscles and partly surrounding the arteries
- In addition to the blood-corpuscles the vein contains Berlin blue injection, and some homogeneous balls which are not represented in the figure. (Obj. F, oc. I.) (For explanation of these two figures see above, p. 598.)

Fig. 19. From a longitudinal section of the thyroid gland of a dog (male, aged 3 months), uninjected, hardened in alcohol. Undeveloped portion seen in section lying in a depression on the surface of the gland.

- 1, 1, 1. Layers of connective tissue separating the undeveloped portion (2) from the ordinary gland-tissue, and also forming septa running into the interior of the gland. The connective tissue is also seen to be continuous with the capsule of the gland. Blood-vessels are seen in it in section.
2. Section of an "undeveloped portion," with an indication of its convoluted cylinders.
- 3, 3, 3. Ordinary gland-tissue, the vesicles being represented diagrammatically and in outline. (Obj. O, oc. I.)

Fig. 20. From the same gland. Section of part of an "undeveloped portion" seen under a high power.

- 1, 1, 1. "Cylinders of cells."
- 2, 2, 2. Septa of connective tissue and blood-vessels separating these.
3. A "cylinder" from which the epithelial cells have partly fallen out. (Obj. F, oc. I.)