

II. *On the Structure and Development of the Skull in the Mammalia.*—
Part III. *Insectivora.*

By WILLIAM KITCHEN PARKER, *F.R.S.*

Received January 15,—Read January 29, 1885.

[PLATES 16--39.]

THE skull in this low group of placental Mammals (*Eutheria*) is of great interest, and, knowing this, I have lost no opportunity, for many years past, of procuring specimens of all sorts, and of all ages and stages. The native kinds, namely, the Hedgehog, Mole, and Shrew, form perhaps, on the whole, as instructive a group as could be found anywhere; they are related, and yet distantly, and the Mole comes in well between the generalised Hedgehog and the very specialised Shrew.

I have been able to follow the Hedgehog and the Mole through a large series of stages, and the Shrew in four—so that these native kinds will now have the history of their skull fairly written out. But the exotic kinds of *Insectivora* do not yield a jot, in interest, to those familiar to us here; these I have been less fortunate in procuring. Yet I think that I can now offer to the Society a sufficiently detailed account to serve, by the help of the more exhaustive account of the skull in the native kinds, to give a clear idea of the morphology of the skull in the more important Families of this most instructive Order.

Any chance of my ever staying my hand from working at the *Insectivora*, and getting to work at other Orders, has simply arisen from failure of further materials, as to embryos and early young, so absorbing did the study of these types become.

The materials* for this present paper have largely poured in during the last three or four years; although I have been collecting, as opportunity has served, for a long time, many of my specimens have been waiting for twenty years, and some were prepared forty years ago.

Yet I feel now, more than ever, that any attempt at working out the morphology of the Mammalian type of skull would have been premature if I had not devoted much time to the lower types of skull seen in the oviparous Vertebrata.

* My hearty thanks are due to my friends for these, namely, to MESSRS. CARPENTER, CUNNINGHAM, DOBSON, GÜNTHER, WALTER HEAPE, T. RUPERT JONES, J. MURRAY, R. MAJOR, NORGATE, PENROSE, SOUTHWELL, G. WEST, and Professor MOSELEY.

For although, of necessity, none of these lie directly below the Mammal, yet they are of great profit to the student of Mammalian descent, when the *mask* of their own particular specialisation has been removed, and that which is essential to the Vertebrate is seen in each "platform," lower and still lower, so as to help the mind to form some useful, if inadequate, idea of the lost types that did underlie, and indeed give rise to, the existing Mammalia.

The Common Hedgehog, besides being more easily obtained than most kinds, is, I feel certain, one of the most generalised types in the Order: it has escaped further from the Metatherian border than some (*e.g.*, *Rhynchocyon*), that nevertheless show much greater signs of advance towards the higher Eutheria. Thus the various characters seen in *Erinaceus* are none of them so low as some to be seen in the type just mentioned, whilst none are so high as others. On the whole I look upon this genus as most normal, for the Order itself, as well as a good instance of a low Eutherian type, with which to compare any of the higher and more specialised kinds—a sort of useful supra-marsupial norma.*

BIBLIOGRAPHICAL LIST.

- ALLMAN, Professor George J., F.R.S. "On Potamogale." Trans. Zool. Soc., vol. vi., 1869; plates 1, 2.
- ALSTON, G. R. "On an undescribed Shrew from Central America." Proc. Zool. Soc., 1877, pp. 445, 446.
- ANDERSON, John, M.D. "On the Osteology and Dentition of *Hylomys*." Trans. Zool. Soc., VIII., Art. XIII., pp. 453–467; plate 64; 1874.
- AUSTEN, N. J. "On the Habits of the Water-Shrew" (*Crossopus fodiens*). Proc. Zool. Soc., 1865, pp. 519–521.
- BARBOZA DU BOCAGE, Dr. J. V. "Sur quelques Mammifères rares et peu connus d'Afrique Occidentale qui se trouvent au Muséum de Lisbonne." (*Bayonia velox*.) Proc. Zool. Soc., 1865, pp. 401–404.
- BRANDT, J. F. "On *Solenodon*." 'Memoirs of the Imperial Academy of Sciences of St. Petersburg,' 1832–3.
- COUES ELLIOTT. "Precursory Notes on American Insectivorous Mammals;" with description of new species. U.S. Survey.
- DOBSON, G. E., F.R.S. "A Monograph of the Insectivora." London: 1882–3.
- GILL, THEODORE. "Synopsis of Insectivorous Mammals." 'Bulletin of the Geological and Geographical Survey of the Territories;' No. 2, Second Series. Washington; May 14, 1875.

* The Metatheria (Marsupials) are now in hand; an account of their skull will form Part IV. The Prototheria (Monotremes) will not be delayed longer than is absolutely necessary; if possible, their skull will be described in Part V.

GRAY, J. E. "A Revision of the Species of Golden Moles" (*Chrysochloris*). Proc. Zool. Soc., 1865, pp. 678-680.

GÜNTHER, Dr. ALBERT, F.R.S.

1. "Description of a New Species of *Chrysochloris* from South Africa." Proc. Zool. Soc., April 6, 1875, plate 43, p. 311.
2. "Remarks on some Indian, and more especially Bornean Mammals." Proc. Zool. Soc., May 16, 1876 (*Tupaia*), plate 36, pp. 424-427.
3. "Notes on some Japanese Mammalia." Proc. Zool. Soc., June 1, 1880 (*Urotrichus* and *Talpa*), plate 42, pp. 440, 441.
4. "Notes on the Species of *Rhynchocyon* and *Petrodromus*." Proc. Zool. Soc., 1881, pp. 163, 164, plate 14.

HEAPE, WALTER. "On the Development of the Mole (*Talpa Europæa*)." 'Quarterly Journal of Microscopical Science,' July, 1883.

MIVART, Professor ST. GEORGE, F.R.S.

1. "Notes on the Osteology of the Insectivora." Journ. of Anat. and Phys., I., 1867, pp. 281-312; II., 1868, pp. 117-154.
2. "On *Hemicentetes*, a new Genus of Insectivora, with some additional Remarks on the Osteology of that Order." Proc. Zool. Soc., 1871, pp. 58-79.

PARKER, W. K. "Shoulder-girdle and Sternum." Ray Soc., 1868; plates 27, 28, pp. 210-213.

PETERS, W.

1. "Neue Säugthiergattungen aus den Insectenfressern und Nagern." Monatsber. Akad. Wissensch. Berlin: 1846, 257-259.
2. "Ueber die Säugthiere-Gattung *Solenodon*." Abhandl. Akad. Wissensch. Berlin: 1863-64, pp. 1-22; plates 1-3.
3. "Ueber die Classification der Insectivora" (besonders *Ericulus*, *Echinogale* und *Potamogale*). Monatsber. Akad. Wissensch. Berlin: 1865, 286.

SUNDEVALL, C. J. "Ofersight af släktet *Erinaceus*." K. Vet. Akad. Handigr., Stockholm, 1841, pp. 215-240. Isis, 1845, pp. 273-280.

THOMAS, OLDFIELD, F.Z.S. "Description of a New Genus and two New Species of Insectivora from Madagascar." Jour. of Linn. Soc. (Zoology), vol. xvi., pp. 319-322. (Read March 2, 1882.)

The following are the stages worked out in *Erinaceus europæus*:—

First Stage. Embryo of *Erinaceus europæus*, about two-thirds ripe; $1\frac{1}{4}$ inch long.*

Second Stage. The same species, about three-fourths ripe; $2\frac{1}{4}$ inches long.

Third Stage. New-born young of the same species; $2\frac{1}{3}$ inches long.

Fourth Stage. Young Hedgehog, two weeks old, or thereabouts; 3 inches long.

Fifth Stage. Young Hedgehog, about a month old; head $1\frac{1}{2}$ inch long.

Sixth Stage. Young Hedgehog, two-thirds grown.

Seventh Stage. Young Hedgehog of first winter.

Eighth Stage. Adult Hedgehog, nearly, or recently—not *old*.

First Stage of Erinaceus europæus; embryo two-thirds ripe; $1\frac{1}{4}$ inch long.

(Plate 17, figs. 1, 2.)

In this solid little embryo, with the “panniculus” formed, the prickles beginning to project (Plate 16, figs. 8, 9), the chondrocranium (Plate 17, figs. 1, 2), is no longer pure cartilage.†

a. Dissected endocranium.

The floor and sides of this *skull-barge* are well formed, except that large cracks or fissures show themselves below; it is almost as fully formed of cartilage as that of a young *Skate* of the same size, but shows some very remarkable modifications that are diagnostic of the Mammal. For instance, the nasal capsule runs along the whole extent of the rostrum, or intertrabecula. The sides of the barge-like structure have given way, right and left between the ear and the eye, or between the auditory capsule and the orbitosphenoid (*o.s.*); thus the alisphenoids are squeezed, as it were, outside the rest of the structure, as if part of a wall should bulge out and break away from the “coping-stone.”

To those two characteristics I may add the extensive plate of perforated cartilage (“cribriiform plate”) for the multitudinous nerves proceeding from the “rhinencephala.”‡

This irregularly pyriform chondrocranium is a very extensive and complex structure, through the union, with the cranium, proper, of the fore and hind sense-capsules.

* In all the measurements I exclude the tail, unless it is specially mentioned; the length is from the snout to the root of the tail, the length of the head and body, separately measured, being added together.

† In my next instance—the Mole—I shall give an account of that earlier stage, before any bony deposit has appeared. (See Plate 25, figs. 1, 2.)

‡ The only other type that shows a cribriiform plate is the *Myxinoïd* (see Phil. Trans., Vol. 174, Plate 17, fig. 4, p. 401); in that case, however, only *five* nerves pass out on each side, through a perforated membrane.

The front pair, or olfactory capsules, are half the length of the skull (fig. 17, *al.n.*, *al.e.*); the hind pair, or auditory (*chl.*), take up much of the skull in its hinder part, aborting, by their implantation, a large amount of the inferolateral walls in front of the occipital arch. The roof is so largely open, when the investing bones have been removed, that the sides and base can be studied as well from the upper, as from the under, face.

On the *under* face of the skull (fig. 1) I have figured three bones of the vomerine series, although they belong to the investing bones; this is because of their peculiar relation to the olfactory capsules, and especially the parts called "JACOBSON'S organs."

Beginning at the snout (fig. 1, *al.n.*), we see that the external nostrils (*e.n.*) are at present inferolateral in position, being seen better on the lower (fig. 1) than on the upper face (fig. 2). Their direction is oblique, and they are extensive open spaces. The rounded and emarginate fore end of the snout is followed by the coils that surround the nostrils, which widen out and are marked off by a groove; behind these coils, the snout enlarges on the under surface into two large flaps, that meet in the middle at an obtuse angle, which, however, is cut away, so to speak, and made acute by the sinuosity of the selvedge of the flaps. Here the labyrinth has its walls pinched in, before it expands to form the swollen olfactory or ethmoidal region. The margining hind flaps of the snout are only partially free, yet they overlap (or rather grow under) the two pairs of cartilaginous growths into which they are developed, backwards. The outer pair of cartilaginous growths simply form the general wall of the capsule, here called aliseptal (*al.sp.*); the sides of the capsule which are confluent with the septum nasi, above (fig. 2), are tucked under, below; and inside their edges another tract of cartilage is seen of, apparently, the same width as this arrested floor. This submarginal tract is the inferior turbinal (*i.tb.*) and is really very extensive, as we shall see in the sections (Plate 18); it arises as a longitudinal outgrowth from the inner face of the outer wall, and is half the length of the entire labyrinth.

There are also two submesial cartilages, three-fourths the size of the inferior turbinals; these are retral developments of the snout, and I call them simply the "recurrent cartilages" (*rc.c.*); they are, however, very important, being the proper capsules of JACOBSON'S organs. These tracts only partially close in above, forming a sort of trough in which the organs of JACOBSON lie. They are elegant, somewhat sigmoid, long, revolute leaves of cartilage, with their convex face looking outwards and downwards.

Each leafy part is supported by a bone, the form of which they dominate, so that each tract is also hollow on the face that looks towards the curved inner edge of the cartilage; it lies on the inside, back to back to its fellow: these are the front, paired vomers (*v'*.), and answer to the paired vomers of the Snake and Lizard among Reptiles.*

* In the two latter these paired vomers are very curiously modified, and have over them an extra pair of bones (septo-maxillaries), the two bones on each side forming a capsule to the organ of JACOBSON,

Between these front paired vomers, the proper azygous *vomer* (*v.*), which only appears in highly specialised types—as Teleostei, Chelonians, certain Birds, and Mammals—passes its fore end between and above the paired bones, and then becomes carinate to rest upon the hard palate; it widens behind to support the olfactory capsule, where are developed the so-called “middle turbinals.”

The aliethmoidal, or the olfactory region (*al.e.*), is divided right and left into a large antero-superior lobe and a small postero-inferior. The latter contains the hinder part of the middle turbinal folds (*m.tb.*), and the former the whole of the upper, and the fore part of the middle turbinals. A deep, sinuous valley is seen between this bilobate swelling, right and left, and the great orbitosphenoidal wings (*o.s.*), whilst, laterally, the cranium is narrowed behind the lateral ethmoidal region, and then swells out still more in the orbitosphenoidal. All the sinuosities of the lateral outline of the endocranium are gentle and very elegant; there are several in the auditory and occipital region, where the “stern” of the barge-like skull narrows in.

The nasal labyrinth, on its lower aspect, shows some of its complexity through its fissures; where the floor of the capsule is bound by the vomerine forks (*n.f., v.*), there it is seen to run forwards, right and left of the vomer, as a spike of cartilage.

This will be seen in its full size in the sections; I have called it the “precurrent cartilage” (see fig. 8, *pc.c.*); it may reach the recurrent cartilage (*rc.c.*), as in *Orycteropus*; here, however, it does not quite reach it. In the hooked angular space between the larger and lesser swellings of the ethmoid the foremost outgrowth of the middle turbinals (*m.tb.*) can be seen.

Between the forks of the vomer the basicranial beam shows itself; here it is composed of all the three prepituitary rods, trabeculæ, and intertrabecula; its anatomical names here are perpendicular ethmoid (*p.e.*), between the forks of the vomer; presphenoid (*p.s.*), for a short distance behind the forks; and basisphenoid (*b.s.*) still further back, where it is perforate; a primary, oval, pituitary opening being left at this part. Right and left of that space we see the “sphenoidal fissure,” which allows a number of cranial nerves to escape—third, fourth, part of the fifth, and the sixth.

The great orbitosphenoid (*o.s.*) has its moderately broad base or proximal part divided off from the presphenoid merely by an inferior groove; it curls round behind the ethmoidal masses (*al.e.*), widening, expanding, and becoming convex. Nearly half-way towards the outer margin is seen the optic foramen (II.), which lies nearer the hind than the front edge of the band. The free upper edge of the orbitosphenoid (*o.s.*) is not seen in this figure (see fig. 2), but it can be seen that the wide upper part is continuous with the nasal capsule (*al.e.*) in front, and with the supra-auditory region of the side wall of the skull (*s.a.c.*), behind.

In this early vegetative state of the endocranium there is something very *flower-like* in its various parts, both as to their shapes and their development. Right and left of which is only partly supported by the feeble, and sometimes detached, recurrent cartilage. The fact is that these curious and enigmatical organs dominate different skeletal parts in different types.

the widening skull-beam (*b.s.*), now becoming *parachordal*, and also osseous, there is a large leafy growth, a broad petaloid, ear-shaped tract; this is the free, outlying alisphenoid (*al.s.*). This "wing" is broadly falcate, the *handle* being made by the cutting away of its proximal part to widen the sphenoidal fissure; the *blade* has its antero-external, sharp edge equal to a quadrant; its *point* is somewhat rounded; and its *back*, looking towards the auditory capsule (*chl.*), is gently concave. This hinder wing does not quite reach to the margin of the continuous skull-wall (*o.s.*, *s.a.c.*). Half-way from the pituitary opening (*py.*) to the edge, and nearer the hind than the fore margin of the wing, we see the *foramen ovale* for the third branch of the trigeminal nerve (*V*³.), but there is no separate passage, as yet, for the *second*—the *foramen rotundum*.

One-third of the hind margin of the alisphenoid is ossified; the bony matter forms a selvedge both to the foramen and the hind edge of the wing. Also behind the pituitary hole there is a pyriform ossification as large as the two alisphenoidal centres together; its broad fore end is perforated—part of the pituitary space; this bone is the basisphenoid (*b.s.*).

Behind this bone the basis cranii shows three wide convex tracts, margined by a lesser concavo-convex tract, right and left. The least convex of the three main parts is cut away, so to speak, right and left, in a perfect semicircle, by the more convex masses, each margin being bevelled down to a sharpish edge. This region is the "spheno-occipital synchondrosis," which gradually becomes less and less until the basisphenoid bone (*b.s.*) meets the basioccipital (*b.o.*).

The large swollen part and the lesser sinuous margins, right and left, both belong to the auditory capsule, the inferior surface of which is well displayed in this aspect. The cochlea (*chl.*) shows three coils, in front of which there is a fissure through which vessels pass, and also the 7th nerve, which runs inside the eave or outer thickening of the ear-capsule under the tegmen tympani (*t.ty.*). That archway is ended by the epihyal (*e.hy.*) in its confluence with the opisthotic region of the ear-capsule, and under it the 7th nerve (*VII.*) runs, and behind it this nerve escapes; its exit is through the stylo-mastoid foramen, and before its exit it gives off its returning fork, the chorda tympani. In front of the epihyal the fenestra ovalis (*fs.o.*) is seen, behind it the fenestra rotunda (*fr.*), and inside that the enlarged fissure for the 9th and 10th nerves (*IX.*, *X.*)

Behind this cranio-auditory chink, the occipital arch is perforated a little nearer the mid-line, for the hypoglossal nerve (*XII.*), and behind the epihyal that arch has a definite paroccipital thickening of an oval shape.

Here the lateral ossification (*e.o.*) has taken up much of the tract between the paroccipital swelling and the condyle (*oc.c.*); it reaches the condyloid foramen (*XII.*). The enlarged cartilaginous tracts, right and left, that form the condyles give the hind margin of the basis cranii an emarginate outline; into this emargination under the

foramen magnum (*f.m.*) the notochord (*nc.*) still projects. It is embedded in the middle of a roughly pentagonal bony plate, the basioccipital (*b.o.*).

The structure of this fundamental and most instructive skull will be still better understood by referring to the *upper aspect* (fig. 2).

Here the snout (*al.n.*) is seen to be much shorter than below, and partly pinched off from the next or intermediate nasal region, the aliseptal (*al.sp.*), which, in turn, passes a little suddenly into the enlarged olfactory region, proper, the aliethmoidal (*al.e.*).

Here all is finished, the crested intertrabecula being confluent with the nasal roofs throughout their whole extent; a peculiarly *Mammalian* structure. The hind margin of the double labyrinth, above, is elegantly bracket-shaped, the proper roof ending thick-edged, in front of the huge lozenge-shaped, perforated, secondary roof, or cribriform plate (*cr.p.*). The partition wall, septum nasi (*s.n.*), in front, and perpendicular ethmoid (*p.e.*), behind, is, at first, scarcely apparent, above; then in the aliseptal region it thickens out considerably, and the tract between the upper turbinals does this again, but to a lesser degree. This top of the wall thickens out in front of the cribriform plate, to fill in the space between the retiring roof; it then, in the rhinencephalic fossa, narrows considerably, to swell out again as the presphenoid (*p.s.*). The perforations for the olfactory nerves are simply countless, two crescentic rows lie back to back, close to the septum, and then about five more valleys, full of holes, run forwards and inwards from the postero-external margin of the great fossa. On a higher level than this valley full of holes are the roots of the orbitosphenoids (*o.s.*) which are not so broad as the basal beam from which they arise, the presphenoidal region (*p.s.*); these frond-like growths of cartilage run up to, and beyond, the most bulging part of the skull in front, and form a good floor and wall to the region of the fore-brain.

Confluent with the edge of the cribriform plate in front, they are free behind, and have a thrice-notched margin there; their selvedge looks upwards, and, in front, melts into the general ethmoidal roof; whilst, behind, it is continuous with the large pterotic or supra-auditory crest (*s.a.c.*), which in turn passes insensibly into the supraoccipital (*s.o.*). The roof of this skull, therefore, although open, or only covered by the investing bones, rests upon a complete rim of cartilage, from the top of the perpendicular ethmoid, in front, to the middle of the supraoccipital cartilage, behind.

But the mid-brain rests upon the bulging, broken wall of the hinder sphenoid, and the alisphenoidal plate, right and left (*al.s.*), is seen, in this view, away from the eye and partly hidden by the orbitosphenoid (*o.s.*). Down in the floor we see the optic passages (II.), the sphenoidal fissure for various nerves ($V^{1,2}$), the foramen ovale (V^3), and the fissure between the cochlea (*chl.*) and the alisphenoid, through the inner part of which the internal carotid artery enters.

Then in the auditory capsule itself the *sieve* for the 7th and 8th nerves (VII., VIII.); between the capsule and the skull the posterior lacerated foramen for the 9th and 10th nerves (IX., X.); and through the contiguous exoccipital tract the proper foramen for the hypoglossal (XII.).

Likewise we see the three posterior sphenoidal osseous centres (*al.s.*, *b.s.*), the three lower centres of the occipital arch (*e.o.*, *b.o.*), and, also, the two upper centres that form this subsequently single keystone piece or proper supraoccipital (*s.o.*)—as distinct from the interparietal which may coalesce with it.

Over the auditory capsule the pterotic band (*s.a.c.*) is notched; behind that notch, looking downward, we partly see the recess under the arch of the anterior canal for the “flocculus cerebelli.”

Visceral arches of First Stage.

The mandibular arch of this stage (Plate 22, figs. 1, 2, *ml.*, *mk.*, *b.mn.*) is a remarkable structure, being composed of both an outer and an inner “ramus.” Part of the epibranchial element of the first arch will afterwards be described as the pterygoid cartilage, the only remnant of the huge overgrowth of this part seen in Selachians. The quadrate region is greatly masked in this case—that of the Mammal—for the orbital process or “pedicle” is suppressed, and the small pterygoid remnant is far off, forwards, whilst the small reduced quadrate segment is thrown into the same line, along the under face, as the large, well-developed lower segment, the ceratobranchial element, or articulo-Meckelian rod. Moreover, comparing the upper segment (*incus* or *quadratum*) with that of a Newt we see that its attachment to the skull is simply by the “otic process,” close in front of the ampulla of the horizontal semicircular canal. Also this segment turns inwards below, behind its articulation with the free mandible, and has a narrow-necked, dilated process to articulate with the dilated remnant of the extrastapedial (the flat face on the head of the stapes).

The articular region of the endocranial mandible is already a “malleus,” and already the “processus gracilis” is there as a delicate ectosteal plate under the neck of the malleus, where the long, rounded part, or MECKEL’S cartilage, begins. The special development of the Mammalian skull, with its much-tilted, auditory capsule, and closely-fitting lower face, makes that hinge *vertical*, which is *horizontal* in all the Oviparous types. A short process on the inside of the cartilaginous malleus answers to the “posterior angular process” of the mandible of the Bird; whilst the “internal angular process” of the Bird, especially that of the Fowl-tribe (*Gallinacæ*), is largely developed, but tethered to the centre of a radiating plate, and acted upon by one special mandibular *adductor muscle*, now called the “tensor tympani.” The rim of this radiating plate is becoming cartilaginous, and is part of the jointed, cartilaginous lining of the ear-passage (*meatus*), but is ready to become bone, even now; it does quickly become the “annulus tympanicus.” Here, at present, the mandible, proper, or MECKEL’S cartilage, becomes more and more solid, forwards, and somewhat flattened; it is well-nigh equal, at this stage, to that of a Selachian. It becomes alate or dilated near the end, and then, *in a peculiarly Mammalian manner*, unites with its fellow, and the two are finished off in front by a long basimandibular spike (figs. 1, 2, *b.mn.*). But this huge main rod already lies in a groove on the inside of a rapidly ossifying

cartilage, which has, already, the form of the *maxilla inferior* of a Mammal, for the coronoid, condyloid, and angular processes (*cp.*, *cd.p.*, *ag.p.*) are present, although not yet ossified. The rest of this superficial tract will be described in the palatal aspect of the skull as the glenoidal facet for the articulation of this superficial and secondary mandible.

The pharyngohyal element of the 2nd arch is already specialised into a stapes by growing as a ring to the stapedial artery, which traverses the auditory capsule exactly where this little, free nucleus, formed in the topmost part of the hyoid facial fold, is fitting itself into the *secondary fenestra* of the auditory capsule much as a Bird's femur sets itself into the widely-perforated "acetabulum." The next or epihyal tract (*e.hy.*) is already confluent with the auditory capsule (Plate 22, fig. 3, *e.hy.*, *au.*), close below the ampulla of the horizontal canal; the facial nerve (VII.) runs under the bridge formed by this junction.

The ceratohyal (*c.hy.*) is divided through its middle, but is continuous with the epihyal above; and this tape-like structure divides again near its base, developing a short subcrescentic segment, the hypohyal (*h.hy.*).

The dilated, semicircular basal element (*b.h.br.*) rather belongs to the 3rd, or 1st proper branchial arch than to the hyoid; it carries not only the hypohyals, but also the thyrohyals (*t.hy.*), short out-bent, thick-ended rods, that articulate with the thyroid cartilage, and are the distal remnants of the abortive 3rd visceral arch.

When once we are well assured of the points just given, all the rest of the Mammalian facial metamorphosis becomes easy to follow, and the "new things" thus produced become the most valuable *diagnostics* of the normal Mammalian face and jaws.

Amongst the *low Eutheria* no better type than this can be found; as a Mammal, the Hedgehog is very normal, yet it is much less specialised than several of its congeners, especially our other native *Insectivora*.

First Stage (continued).—Vertically-transverse sections.

This stage will now be illustrated by a complete series of vertically-transverse sections through all the tissues of the head.

1st Section (Plate 18, fig. 1).—This is in front of the septum and catches the projecting parts of the *alæ nasi* (*al.n.*), and the openings of the external nostrils (*e.n.*).

2nd Section (Plate 18, fig. 2).—This is close behind the external nostrils in the narrow beginning of the nasal passages (*n.p.*). The septum here (*s.n.*) is but little due to the fore part of the crested intertrabecula, it is mainly formed by the confluence of the alinasal folds (*al.n.*), back to back. This projecting part of the snout is grooved, above and below, through this union of the convex faces of the cartilages, which have made a partition thick above and thin below. Close to the openings of the nose the *alæ* are most complete at the sides, and the lower parts are tucked in where they

support the lower part of the deep uncinatè chink, the nasal passage (*n.p.*). Over the out-turned hook of the section a mucous crypt, one of the many small distinct nasal glands (*m.g.*), are formed between the cartilage and the Schneiderian membrane.

3rd Section (Plate 18, fig. 3).—This is from the hind part of the mobile, rooting snout, and here the upper lips begin to show themselves as depending lobes, the hollow of the palate now being more definite. Here the intertrabecula is as round as in an embryo Bird or a Shark; but here there has taken place what is not seen in the projecting part, the “rostrum,” in those very diverse Ovipara, namely, that the alinasal folds (*al.n.*) are confluent with the foremost part of this precranial rod, which now takes the name of septum nasi (*s.n.*). Here each nasal tube is surrounded by cartilage, the alinasals having developed each into an almost complete tube, the lower part of which projects downwards far below the low wall of partition; the two folds rise again, back to back, although they do not touch. Each sweeping fold of cartilage is indented infero-laterally, in correspondence with the form of the nasal passage, which is now trilobate; a mucous crypt (see also fig. 2, *m.g.*) is seen outside the upper lobe.

In several sections, between this and No. 2, the lower part of the alæ nasi had joined back to back, and the whole snout was thus confluent in all its parts and formed a complete double tube, or non-segmented proboscis; sections of other types (Mole and Shrew) well show this.*

4th Section (Plate 18, fig. 4).—This is from behind the flexible snout, and now the investing bones, most of which were removed from the endocranium (Plate 17, figs. 1, 2), are seen in section as thin films of bone. The solid intertrabecula, with its crest, and the confluent aliseptal folds of the nasal labyrinth (*al.sp.*), now form a strong septum nasi (*s.n.*). The alæ are now free at their lower edge, but are enlarged there into a pedate process, which thrusts the lining skin inwards as a rounded lobe, looking downwards; this is the first appearance of the inferior turbinal (*i.tb.*)—its fore end. The lower parts of the cartilage, towards the middle, are now free from the base of the septum (*s.n.*), their section is a hook, the lamina just bending outwards, then inwards, below, turning round to support JACOBSON’S organ (*j.o.*); here seen at its fore end.

These curious submesial retral outgrowths of the alæ nasi are the “recurrent cartilages” (*rc.c.*). Between these are the front paired vomers (*v.*), the bony part of this locally modified skeletal structure; they converge below, and are thin uncinatè splints (see Plate 17, fig. 1, *v.*).

The enlarging nasal passage (*n.p.*) gives off from its main, vertical part, two outer, and one inner, “horn,” the latter turning inwards, below; here and there a mucous crypt is seen.

The nasals (*n.*) and the premaxillaries (*px.*) now come into view. Below, the fore part of the lower face is cut across, in front of the dentary, but through the basimandibular cartilage (*b.mn.*), here nearly circular in section, a tooth-pulp (*t.*) is cut

* The dotted line in fig. 2, shows where the cartilage is complete in the next section.

across on each side of the cartilage, and in the lower skin the bristles show their bulbs.

5th Section (Plate 3, fig. 5).—Here the septum (*s.n.*) is deepening, and its interturbular base is less bulbous. The nasal labyrinth has thicker walls, and besides the expanding rudiment of the inferior turbinal (*i.tb.*), further up, the pointed fore end of the nasal turbinal (*n.tb.*) is cut across; a crypt is seen below it, and below the inferior turbinal. The skeletal parts that protect JACOBSON'S organs (*j.o.*, *rc.c.*, *v.*) are larger here, and the cartilage forms a complete tube for a short distance; above are the nasals (*n.*); at the sides, the bony laminæ belong to both the premaxillaries (*px.*) and maxillaries.

Below, the basimandibular cartilage (*b.mn.*) is depressed; close in front of the Meckelian rods, right and left, a tooth-pulp (*t.*) is seen.

6th Section (Plate 3, fig. 6).—The septum (*s.n.*) is now much higher, and the bulb at the base much less; the side wall is very thick, for here the nasal turbinal inside (*al.sp.*) is beginning to clear itself of the wall; below it the inferior turbinal rudiment is still seen. Here and there a mucous crypt is seen, and here JACOBSON'S organ (*j.o.*) lies in a fold of the recurrent cartilage (*rc.c.*), behind the closed part, and behind the front-paired vomers. The nasals and maxillaries (*n.*, *mx.*) now show more clearly, and the latter are developing the diploë, and are giving off the palatine plate.

Below, the dentary (*d.*) appears, outside the distinct large oval section of each Meckelian rod (*mk.*).

7th Section (Plate 3, fig. 7).—This section shows several new things. The deep septum (*s.n.*) is cut through at the junction of the septum nasi, proper, and the perpendicular ethmoid, the part that becomes solidly ossified in Mammals, in the true olfactory region. Under it the median vomer (*v.*) is seen, and JACOBSON'S organs are small at this their hind part. The nasal passages (*n.p.*) are now becoming very complex or labyrinthic; this is due to the greater development of the various turbinal folds, now that the section is through the proper olfactory region. The nasal turbinals (*n.tb.*) are, here, sharp and turned outwards at their free edge, whilst at the sides the wall is giving off new buds, and the inferior turbinal (*i.tb.*) is dying out. A remarkable free cartilage (*m.tb.*), oval in section, is seen in the principal cavity, covered with a mass of tissue, like the rest of the mucous and submucous lining. This is a process which grows forwards from the lower part of the labyrinth, from the region of the middle turbinal. It is large, here, but much larger in *Orycteropus* (see Plate 15, fig. 1), in which I have called it the precurrent cartilage (*pc.c.*). The vomer (*v.*), the nasals and maxillaries (*n.*, *mx.*) are well seen here.

8th Section (Plate 18, fig. 8).—In this partial section the labyrinth is cut through just in front of the great olfactory fossæ; the perpendicular ethmoid (*p.e.*) has a submoniliform outline, due to three successive bulgings. The rudiments of the turbinal outgrowths are seen here, namely, the upper and middle turbinals (*u.tb.*, *m.tb.*), and outside the latter, and just distinct from it, the thick trihedral

mass—the precurrent cartilage (*pc.c.*) at its hind part; in the next section (fig. 9) it forms the front projecting part, inwards, of the middle turbinal (*m.tb.*).

The vomer (*v.*) is here cut through its middle, where it is roughly carinate; afterwards, this part will rest on the palatine plates of the maxillaries. These bones (*mx.*) have here developed a large alveolar cavity, and a tooth-pulp is seen in the alveolus; the nasals have their place taken by the frontals (*f.*). In the last, and in this, the mucous crypts (*m.g.*) are abundant, especially below. The large oval section of MECKEL'S cartilage (*mk.*) is now overgrown with the diploë of the dentary (*d.*), which also is developing an alveolus, with its tooth.

9th Section (Plate 18, fig. 9).—Here another partial section is given through the forepart of the eye-ball (*e.*), and the middle of the rhinencephalon which is giving off its fibres through a mainly membranous cribiform plate (*cr.p.*). Here the septum (*p.e.*) is much lower, and beneath it the vomer (*v.*) is beginning to divide into its hind forks.

The folds of cartilage are, here, confluent, so that the nasal passage is now in several sections, and at the lower part a section of the space is growing towards the cavity of the other side ready to form the proper “nasopalatine canal.” The maxillaries and dentaries (*mx.*, *d.*) have here large alveoli with their tooth-pulps; the superficial bone, above, is the widening frontal.

10th Section (Plate 18, fig. 10).—This is another partial section, made through the middle of the eye-ball (*e.*), and the hind part of the nasal labyrinth, with the huge olfactory lobes (rhinencephala) overlying a membranous cribriform plate. The nasal wall now forms a protection to the “fossa,” and beneath the floor (*n.f.*) the cartilage runs nearly up to the low dividing wall (*p.e.*). Here the labyrinth is reduced to two passages (*n.p.*), besides the common nasopalatine canal (*n.p.c.*) at the mid-line, below. Here the forks of the vomer (*v.*) are cut across, and at this part the maxillary meets the palatine (*pa.*) on the palatal floor; outside, the former bone (*mx.*) shows its large alveolar plates, as does the dentary (*d.*), below. At this part the frontal is in reality in two pieces, as the next stage will show; the orbital plate being separate from the upper part (*f.*).

11th Section (Plate 18, fig. 11).—This section is through the back part of the eye-ball (*e.*) and the front third of the hemispheres (*C^{1a}*). Here the true cranium comes into the section, for the basal beam is now the presphenoid (*p.s.*), and the wall right and left is the orbitosphenoid (*o.s.*).

The back of the olfactory labyrinth (*n.w.*) is cut through, and these limited tracts of cartilage lie between the two regions of the anterior sphenoid (*o.s.*, *p.s.*), and are confluent with the basal mass. So, also, is the orbitosphenoid confluent, above, with the top of the olfactory wall (see Plate 17, figs. 1, 2). The relation of the orbital plate of the frontal (*f.*) to the orbitosphenoid (*o.s.*) is well seen here; below, the bones of the palate are thick tracts, dividing on their inner edge into an upper and a lower plate to embrace, and protect, the nasopalatine canal (*n.p.c.*); these are, now, the pterygoids (*pg.*).

Below, outside the tongue (*tg.*) and mouth cavity (*m.*) the compound lower jaw is seen to be composed of three tracts of cartilage and two of bone; the latter answer to the dentary and splenial, but these are not actually separate bones, at this part. Then there is MECKEL's cartilage, or the primary mandible, and two points of cartilage belong to the superficial cartilaginous "ramus."

12th Section (Plate 18, fig. 12).—Here the razor has cut through the anterior sphenoid (*p.s.*), continuously, missing the small optic foramen (see Plate 17, figs. 1, 2, *o.s., p.s., II.*), most likely cutting in front of it. Thus the cranial cavity and membranous cranium is more than half engirdled by this tract; the upper deficiency is, at present, only partially made good by the frontal bone. Here we encounter cartilage right and left, below the flat presphenoid (*o.s.*), for the pterygoids are cut through here, and they are largely *preformed in cartilage* (see in next stage, Plate 17, fig. 3, *pg., pg.c.*). These bones only form a wall, on the right hand, and on the left, to the nasopalatine canal (*n.p.c.*), and do not form a bridge, beneath it, as the palatines do. The mandible is growing up, here, towards its coronoid process, above, and its angular process (*ag.p.*), below; the inner rod (*mk.*) lies in a groove of the ramus, near its lower part.

13th Section (Plate 18, fig. 13).—This section will be understood if reference is made to the dissected skull (Plate 17, figs. 1, 2). The basis cranii is cut through at the hind part of the presphenoid (*p.s.*), just where the basisphenoidal region begins. Here the two trabeculæ are cemented together by the wedge-like end of the intertrabecula. The large sphenoidal fissure is cut through, and several nerve-bundles (*V.*) are seen in the interspace; because of the sinuous form of the margin of the orbitosphenoid (*o.s.*) that cartilage is cut through twice, immediately in front of the alisphenoid, which lies in a lower plane. The bulk of the pterygoid is still cartilaginous, and so is the "ramus" of the mandible (*d.*) at this part, where the coronoid and angular processes (*cr.p., cd.p.*) are cut across; MECKEL's cartilage (*mk.*) forms a large oval section at this part, and the dentary is spreading over it; the frontal (*f.*) is seen outside and above the orbitosphenoid (*o.s.*).

14th Section (Plate 18, fig. 14).—This is a very instructive section and should be compared with the dissection of the same and of the next stage (Plate 17, figs. 1, 2, 3). The cranial cavity with the included brain (*C^{1a}.*) is here very large, and the basal part of the skull is cut through where the floor is incomplete (*b.s., py.*), so that we have here the exact form of the trabeculæ behind the intertrabecula; they are oval, with the long axis horizontal. On each side, in a deep fossa, the great Gasserian ganglion (*V.*) is seen, supported by the alisphenoid (*al.s.*) which lies outside and below the general plane of the skull floor and wall; it is ossified at its postero-external margin, and its hollow upper face forms the floor of the trigeminal fossa. The orbitosphenoid (*o.s.*) is narrowing towards its posterior band, and it is supported outside by the orbital part of the frontal (*f.*), which runs far down into the hind part of the orbit, almost touching the alisphenoid.

Two rods of cartilage, oval in section, but with their long axis vertical, are seen

under the basis cranii and protecting the narrow nasopalatine canal (*n.p.c.*); these are the pterygoids (*pg.c.*) in their unossified free part ("hamular process"). Outside, and below, we see a part of the squamosal, its zygomatic region on the jugal (*j.*); and inside it the glenoid facet (*gl.c.*) is cut along its whole transverse extent. A little below it a section of cartilage appears, thick above and below and narrower in the middle; this is the main part of the great superficial slab, a segment of which is given off to form the glenoidal facet. The upper part is the condyle of the lower jaw (*cd.p.*), the lower is part of the angle (*ag.p.*); the inside of the cartilage is becoming bony; in the concavity, on the lower part of the inner side, MECKEL'S cartilage (*mk.*) is still full-sized.

15th Section (Plate 18, fig. 15).—Here the fore brain (*C^{1a}.*) is cut through near the infundibulum, but the pituitary body (*py.*) is seen as a large separate quasi-glandular mass resting upon the basis cranii near the beginning of the parachordals or investing mass (*b.s.*). These are flattish and ovoidal in section, the interspace between them being the primary pituitary space at its hinder part. On the side, the orbitosphenoid (*o.s.*) is still seen as a considerable band of cartilage; this is near the junction of the frontal (*f.*) and parietal bones. The Gasserian ganglion (*V.*) is cut across in its hinder part, and the razor has caught the cochlea (above *i.c.*) in its fore margin. This is behind the hinge of the secondary mandible, and through the part of MECKEL'S cartilage where the bony lamina that forms the ossifying centre of the malleus (*ml.*) has appeared. Outside this the postglenoid part of the squamosal (*sq.*) is seen, and, between the two, the foremost part of the tympanic cavity (*c.ty.*). The internal carotid artery (*i.c.*) is seen entering the skull between the cochlea and the basisphenoid (*b.s.*), and under it the Eustachian tube (*eu.*) is laid open as it is passing towards the fauces or back part of the oval cavity (*phx.*); it opens into that cavity between this and the last section (fig. 14).

Under this tube the cartilaginous lining of the first cleft is seen to extend (*eu.c.*); this Eustachian cartilage is the innermost part of the partly segmented cartilaginous tube which expands externally as the "concha," and which, in the part next outside the Eustachian cartilage, becomes ossified, early, as the annulus tympanicus.

Four arterial branches are seen, here, cut obliquely across, one of them close beneath and outside an oval section of cartilage, the ceratohyal (*c.hy.*). The one above it is that part of the "common carotid" which gives off the "stapedial artery," to inosculate with the artery of the lower jaw.

At the mid-line, below the palatonasal cavity, the pharynx is laid open, and right and below it the hypohyal cartilages (*h.hy.*). Outside and in front of the ceratohyal the chorda tympani (*VII^a.*) is cut across, and outside and below these the main facial nerve (*VII.*).

16th Section (Plate 18, fig. 16).—This is through the widest part of the hemispheres (*C^{1a}.*), and also cuts across the large glandiform pituitary body (*py.*). Several large nervous masses are cut through (*VII.*, *VII.*), close to the top of each cochlea (*chl.*). The

basisphenoidal cartilage (*b.s.*) has a film of bone in it above and below ; its outer edges are beginning to coalesce with the cochlea, which are laid open. The orbitosphenoidal band (*o.s'*) is still large, and is separated by a large space from the inferolateral parts. The processus gracilis has still a solid cartilage lying on it (*ml.*) ; outside this is the postglenoid part of the squamosal. The meatus auditorius externus is partly laid open, and the Eustachian cartilage (*m.c.*) is still seen under the cavum tympani (*c.ty.*), which is here still partly the Eustachian tube. Beneath the middle of these parts the epihyal (*e.hy.*) is cut across, and outside it the chorda tympani (*VII^a.*), with the main facial nerve (*VII.*) lower down, is exposed. The larynx is below the pharynx (*lx.*, *phx.*), and there is seen a film of bone outside, the ramus (*d.*) ; a part of the cartilaginous framework of the larynx is seen in section.

17th Section (Plate 18, fig. 17).—This is another important slice, showing many things. It is in front of the junction of the orbitosphenoid with the crest on the top of the auditory capsule ; the cochlea (*chl.*) is near its widest part, it is just in front of the proximate coil. We are now behind the great trigeminal nerve, with its roots, ganglion, and branches, but the nerves proceeding from the ganglion geniculatum (*VII.*, *VIII.*) are cut across, and the facial nerve (*VII.*) has entered its "aqueductus." The same nerve (*VII.*), and its inosculating anterior branch, the chorda tympani, are seen outside the epihyal (*e.hy.* *VII.*)* Here the great meatus externus (*m.a.e.*) is fairly laid open, and it is seen to be lined with cartilage throughout ; it is indeed one more or less segmented tube, from the opening of the Eustachian tube, within, to the conchal expansion, without. The pituitary body (*py.*) is cut through in its hind part ; the malleus, or dilated end of MECKEL'S cartilage (*ml.*), is partly seen, its head and the tip of the manubrium (*mb.*) ; the rest of that process is indicated on the right side by a dotted line. The archway over the facial nerve (*VII.*) is the fore part of the tegmen tympani, inside the head of the malleus. The postglenoid part of the squamosal is seen, and on right and left of the pharynx (*phx.*) the hypohyals (*h.hy.*).

18th Section (Plate 18, fig. 18).—This section is through the basis cranii where the sphenoidal (*b.s.*) and occipital regions meet. The orbitosphenoidal cartilage has here passed into the supra-auditory (*s.a.c.*), where this great crest is continuous with the top of the auditory capsule. The left side of the figure is from a point in front of the right, so that this section serves instead of two. The left side is through the base of the cochlea (*chl.*), but in front of the cavity of the vestibule. The cartilage lining the meatus externus (*m.c.*) is seen both in the outer opening and under the dagger-shaped section of the cavum tympani (*c.ty.*) ; a small cavity at present lying in the midst of a mass of indifferent tissue. The solid cartilage of the "pterotic" region, close in front of the anterior semicircular canal (see the other side *a.s.c.*), is not perforated until we come to the beginning of the aqueductus for the facial nerve (*VII.*), which is cut across twice on the right side, both where it

* The lines are misdirected in this part of the figure.

perforates the capsule, and where it begins its course under the tegmen, which is imperfect here in its front part. At some distance below this auditory eave the head of the malleus (*ml.*) is seen in section along the whole course of the manubrium on the left side. Under the tympanic cavity and its cartilaginous floor the epihyal (*e.hy.*) and its accompanying nerves, the chorda tympani and facial trunk (*VII^a.*, *VII.*) are seen cut across, and the hypohyal and thyroid cartilage (*h.hy.*, *lx.*) at the mid-line, below. On the left side the cartilage above the cochlea (*chl.*) is perforated by the facial and auditory nerves (*VIII.*), and the right side has part of the anterior canal (*a.s.c.*) visible.

There the tegmen is perfect, and the main part of the incus and its long crus is cut through, the manubrium mallei (*ml.*) appearing beyond and below it. The hyoid and its nerves are similar to what is seen on the other side, for the obliquity of this section is very slight.

19th Section (Plate 18, fig. 19).—This partial section is one of the most important in the series. The parietal (*p.*) is seen outside the pterotic or supra-auditory cartilage (*s.a.c.*), but the squamosal which was seen in the last (fig. 18) is not figured. The arch of the anterior, and the ampulla of the horizontal, semicircular canals (*a.s.c.*, *h.s.c.*) are cut through, besides several other spaces in the vestibule and proximal part of the cochlea. The wall of the cochlea is cut through in front of the band of cartilage that divides the fenestra ovalis from the fenestra rotunda, a band which in the Sauropsida is uniformly ossified by the opisthotic centre; in Mammals that centre is much more potent, and may, as in the next instance (*Talpa*), ossify nearly all the proper capsule. The auditory nerve and its ganglion (*g. cochleare*, *VIII.*) are seen in the meatus internus, and externally the stapes (*st.*) by its base fills the fenestra ovalis. The articular part or head of the stapes, which was nearly in view inside the long crus of the incus on the right side of the last section (fig. 18) is now cut clean through, and the stapedia artery (*st.a.*) is seen traversing the foot-hole of the stapes, on its way to the inside of the maxilla inferior. This section is at the back part of the meatus externus, and at the end of the tympanic cavity, so that here the epihyal (*e.hy.*) is seen already confluent with the hind part of the tegmen; the foramen stylo-mastoideum is laid open and the facial nerve (*VII.*) is seen running downwards behind and outside the epihyal, and the cavity of the tympanum (*c.ty.*) is seen inside, close to the artery. The larynx (*lx.*) is seen below at the mid-line, and the basioccipital floor (*b.o.*) under the hind-brain (*C³*).

20th Section (Plate 18, fig. 20).—Here the supra-auditory cartilage (*s.a.c.*) is close to the supraoccipital, and the film of bone outside belongs to the squamosal (*sq.*).

The anterior and horizontal canals (*a.s.c.*, *h.s.c.*) are cut across, and the hind part of the vestibule at its junction with the cochlea.

The head of the epihyal is seen finishing the tegmen (*t.ty.*), behind, and the narrow hind part of the cavum tympani (*c.ty.*) is shown, here, for the last time. The flat form of the parachordals (*b.o.*), inclosing the notochord, is seen under the hind-brain (*C³*).

21st Section (Plate 18, fig. 21).—The anterior canal (*a.s.c.*) is here cut through where it joins the posterior, and the horizontal canal (*h.s.c.*) is seen where it opens into the cavity of the vestibule (lower part of *vb.*); the wall is imperfect on the inner side (see also next stage, Plate 17, fig. 7). The lowest part of the posterior canal, and its ampulla, is close behind this part. The posterior lacerated foramen (IX., X.) is here cut across, and also the condyloid foramen (XII.); the basis cranii (*b.o.*) is large, here, and partly ossified.

22nd Section (Plate 18, fig. 22).—The thick opisthotic region of the auditory capsule is cut across, here, and the posterior canal at its beginning, above, is one with the anterior canal (*a.s.c.*); below, it is close to the horizontal canal (*h.s.c.*). On the inner face the cartilage is thin, and there is a small vestibular cavity (*vb.*). The supra-auditory cartilage (*s.a.c.*) is so cut across as to be some distance from the top of the capsule; this is due to the slight obliquity of the sections. The vagus and hypoglossal nerves (XI., X.) are still seen outside the bent basioccipital plate (*b.o.*). This section is in front of the sides and condyles of the occipital arch, and is behind the hole for the 12th nerve (XII.).

Second Stage of Erinaceus europæus. Young, three-fourths ripe; $2\frac{1}{4}$ inches long; head, $\frac{3}{4}$ inch.

This larger embryo serves well for showing the development of the ectocranium as well as for the advancement made in the endocranium (Plate 17, figs. 3–8). Beginning with the roof (fig. 4) we find a very orderly series of bony scutes along the mid-line; there are four pairs of these sub-median radiating centres that have all the appearance of belonging to the same category, namely, a double row of subcutaneous scales growing towards each other along the top of the head.

The foremost of these scutes, the nasals (*n.*), are the smallest, they are the tiling of the cartilaginous nasal roof, and the septum nasi (*s.n.*) is seen between them. Like shell-valves, with a pointed end, forwards, and a rounded broad end, behind, these bones just cover the hinder half of the nasal labyrinth.

The next pair are four times as large, these are the frontals (*f.*); they are narrow in the middle and dilated at each end; they scarcely reach the nasals, in front, and only touch the parietals (*p.*), behind, by their convex margin. There is a long fontanelle running between them and the parietals up to the nasals, in front, and to the supraoccipital (*s.o.*), behind; this is dilated in three places, especially in the coronal region. The concave outer edge of the frontal does not run as far as to the supraorbital ridge; this part and the orbital roof are covered with a distinct bone (see also fig. 5, *s.ob.*). This single supraorbital scale bone is new to me in the Mammalia, but familiar enough in the Oviparous forms—the Ganoid Fishes, below, up to the Tinamous and some higher Carinate Birds, above. In all these, however, it is broken up into two or more pieces.

The parietals (*p.*) are nearly twice as large as the frontals, and, behind them, the interparietals (*i.p.*) are not much larger than the nasals (*n.*).

Besides the supraorbitals, the lateral and infero-lateral bones seen in this view are the premaxillaries, maxillaries, lachrymals, jugals, and squamosals (*px.*, *mx.*; see also fig. 3, *l.*, *j.*, *sq.*), these are better seen in the other views (figs. 3, 5, 6).

In the *side view* (fig. 5) the premaxillaries (*px.*) are seen to be of normal size, mounting upwards obliquely, and wedged in between the nasals and maxillaries above. The outer or facial part of the maxillary is large, with its very large infraorbital foramen (*V².*) and its long concave preorbital and suborbital edge. Over the former part the fore end of the supra-orbital (*s.ob.*) fits, and inside, below this, the smallish perforated lachrymal scale (*l.*, *lc.*). The jugal (*j.*) is a small thickish style, and is overlapped both by the jugal process of the maxillary and of the squamosal (*mx.*, *sq.*). Where the uncinat supraorbital (*s.ob.*) and the swollen parietal (*p.*) meet in the post-orbital region there the squamosal is seen, the fore part of its temporal plate, which walls in the temporal fossa, it begins there, and the bone, dilating gently backwards, is trifid behind, in its postglenoid end, where it just hides the ampullæ of the anterior and horizontal canals (*a.s.c.*, *h.s.c.*) The parietals and interparietals (*p.*, *ip.*) meet over the arched junction of the anterior and posterior canals (*a.s.c.*, *p.s.c.*).

But the peculiarly normal Mammalian state of the superficial bones is best seen in the *lower view* (Plate 17, fig. 3).

Here the increasingly perfect desmognathism of the skull and the great development of tooth-pulps, asking for large sockets, are the factors that make the normal Mammalian palatofacial structures so different from their counterparts in the Ovipara, generally. Add to these the metamorphosis of the mandible, giving the last finish to a face with limited motion, and we get the reasons for much that is novel in this type of skull.

The premaxillaries (*px.*) are largely hollowed out for the teeth, and their palatine processes are, *at present*, short and small. The maxillaries (*mx.*) send inwards a large flange from their inner alveolar plate; beyond this, to the mid-line, another equally large tract has been developed, the palatine plate; it is joined to the outer plate by a broadish isthmus, and is never quite distinct from it. The palatine plate of the palatine (*pa.*) is three-fifths the size of that of the maxillaries, and is perforated behind its middle. The two bones wedge in between the maxillaries at the mid-line, and at their hind part are deficient there. Outside they are thick, where they ascend to the basis cranii.

The pterygoids (*pg.*) are merely small ectosteal tracts fastening upon and transforming the thick, short, rounded pterygoid cartilages (*pg.c.*), and spreading above them to plaster the basisphenoid (*b.s.*) with a thin bony tract.

The lower edge of the jugals and squamosals (*j.*, *sq.*) are seen in this aspect, the latter is largely hidden by the wide three-lobed glenoid facet (*gl.c.*), which is placed transversely to the axis of the skull.

The *end view* (Plate 17, fig. 6) shows the roughly-oval interparietals, and the hind part of the parietals and squamosals (*i.p.*, *p.*, *sq.*) as they fit on to the auditory and occipital regions of the endocranium.

But a *lower view* of the *upper palate*, after the hard palate has been removed (Plate 17, fig. 8), shows three more investing bones, namely, the front paired vomers (*v'*), and the vomer, proper (*v.*).

These paired bones are quite distinct from the palatine processes of the premaxillaries, and are delicate, narrow laminæ, with an outside hook in front; they are placed vertically inside the recurrent cartilages (*rc.c.*) and JACOBSON'S organs.

Wedging in between their hinder part we see the narrow, bifid fore end of the main vomer (*v.*), which is roughly carinate in its fore half, and then flattens out, and is alate in its hind half where it is applied, right and left, as an ethmoidal splint, serving to bind the right and left floors of the nasal labyrinth together, as in Passerine Birds; this upper junction of the right and left halves of the face has been called "Ægithognathism," because of its peculiar development in Passerine Birds.

Endocranium of Second Stage of Erinaceus europæus.

In the figure just referred to (Plate 17, fig. 8) we see the *lower view* of the alinasal cartilages (*al.n.*) and the outer nostrils (*e.n.*). Constricted suddenly, these parts give off the neck of the curious, tongue-shaped recurrent cartilage (*rc.c.*), which at its fullest part grows quite round JACOBSON'S organ (see Plate 18, fig. 5). Behind these the floor of the nasal capsule, under the "middle turbinals" (*pc.c.*, the "precurrent cartilages"), is partly shown, and then the narrow, unossified mesethmoidal (*p.e.*), and presphenoidal region (*p.s.*), and the very wide, ossified basisphenoidal (*b.s.*). This bony plate is transversely oval and is perforated in front; this hole is the pituitary space (*py.*).

In the *lower view* (Plate 17, fig. 3), behind the hard palate, the endocranium is well shown; it is a broad osseo-cartilaginous structure. At the mid-line the presphenoid and basisphenoid (*p.s.*, *b.s.*, also shown in fig. 8) come into view, but the latter is partly hidden by the pterygoids (*pg.*, *pg.c.*), outside which the base of each alisphenoid (*al.s.*) swells into an egg-like process (*e.pg.*, or "external pterygoid"), much more distinct, now, than in the first stage (fig. 1).^{*} Outside this swelling the cartilage is largely ossified as the alisphenoid (*al.s.*), which is perforated nearer its hinder, than its fore, margin, by the 3rd branch of the 5th nerve (V^3); the rest of this nerve ($V^{1,2}$) escapes through the sphenoidal fissure.

The outer part of the orbitosphenoidal bony centre (*o.s.*) is just seen in front of the

^{*} This part is similar to what is seen in the embryo (uterine) of *Didelphys*, and the counterpart of which does develop even in some Insectivora (e.g., *Rhyncocyon*, Plate 36, fig. 5) into an "anterior tympanic recess," or *alisphenoidal bulla*; this, however, in the Hedgehog becomes the external pterygoid plate; a part which, in Kangaroos, co-exists with the tympanic wing of the alisphenoid.

fissure; these parts will be better shown in the section (fig. 7). Where the wide posterior sphenoid joins the auditory capsules (see also fig. 1) there we see a wide transverse territory of cartilage, which, at its middle part, is the very extensive sphenoccipital synchondrosis.

Externally, it is notched, here, where the permanent "foramen lacerum," or *jagged passage*, will be; and nearer the mid-line it is perforated, right and left, by the internal carotid artery (*i.c.*). Although the cochleæ (*chl.*) show their form well, their cartilage is confluent with that of the skull, proper, except behind, where the "foramen lacerum posterius" will be, which is now a large oval hole formed by the 9th and 10th nerves (IX., X.). The notched space in front of the capsule allows of the exit of the facial nerve (VII.), the proximal part of which is not drawn in the figure; it is seen further back under the tegmen tympani (*t.ty.*), and then passing under the epihyal (*e.hy.*) to escape through the stylomastoid foramen. On the side of each cochlea the stapes (*st.*) is seen *in situ*, and behind the cochlea the foramen rotundum (*f.r.*). Behind this the occipital arch shows a swelling, a rudimentary "paroccipital." Inside that eminence the 12th nerve (XII.) passes through the condyloid foramen, which is almost surrounded by the rudimentary exoccipital centre. The basioccipital (*b.o.*) is very *Reptilian*, being roughly pentagonal; it is still marked by the notochord (*nc.*).

The occipital condyles (*oc.c.*) have a very *Batrachian* appearance, not being very prominent, and very wide apart.

From the *upper view* (fig. 4) not much of the endocranium is seen, but the alinasal region (*al.n.*) is seen to have developed into a projecting snout, much longer than in the early stage (fig. 2). Behind, the supraoccipital bone (*s.o.*) has become single, and right and left of it the cartilage passes into the supra-auditory crest, and the proper auditory capsule with its canals (*p.s.c.*, *h.s.c.*, *a.s.c.*).

In the side view (fig. 5) the projecting snout and nostril (*al.n.*, *e.n.*) is seen, and the valvular folds covering the nostril. In the orbit the lower frontal (*s.ob.*) ossicle fails to cover the orbitosphenoidal cartilage (*o.s.*) with its orbital plate. Below, the thick bulbous process of the alisphenoid (*e.pg.*) and the pterygoid nucleus (*pg.c.*) are seen, and, behind, the outer face of the auditory capsule, with its canals (*a.s.c.*, *h.s.c.*, *p.s.c.*) is well shown, and also the tegmen tympani, and part of the cochlea (*chl.*). The epihyal (*e.hy.*) is confluent with the capsule behind the tegmen, and the facial nerve (VII.) emerges behind it. Behind this stylomastoid foramen, the paroccipital eminence, the condyle (*oc.c.*), the exoccipital (*e.o.*), and the supraoccipital (*s.o.*) come into view.

So do those parts in the *end view* (fig. 6), where, however, they are displayed more fully; here especially we see how large the great foramen (*f.m.*) is, as compared with the hind skull, even with the investing bones (*p.*, *i.p.*, *sq.*) still in place.

But the most instructive view of the endocranium is to be had by bisecting the skull, *vertically* (fig. 7).

Now we see what a mere tube this skull is, even in the embryo, and also that the

chondrocranium is nearly as perfect as in a Skate. Yet every true Mammalian character is to be seen, well developed, and *diagnostic*.

The cranio-facial axis has two bones in its hinder third, not much larger than the "synchondrosis" that separates them; these are the basioccipital and the basisphenoid (*b.o.*, *b.s.*); all the rest forward is *pro-chordal*, and composes the presphenoidal, ethmoidal, and septal regions of the skull (*p.s.*, *p.e.*, *s.n.*).

The septum runs forwards, between the folds of the alinasal cartilage (*al.n.*) in front, a roundish part, perfect, or nearly so; then a narrow isthmus unites this part with the proper septum nasi (*s.n.*), which passes, at present, without change into the perpendicular ethmoid (*p.e.*), and this into the presphenoid (*p.s.*). This large partition wall is a low triangle, the apex of which forms the rudiment of the crista galli (*cr.g.*). The fore part, above, is continuous with the nasal roof (*al.e.*, *al.sp.*, *al.n.*); the hind part divides the two great olfactory fossæ, with their hollow, cribriform floor (*cr.p.*). The basal part of this great wall is thick, this arises from the primary solidity of the intertrabecula. Where the alæ nasi (*al.n.*) seem to end below, there they give off the recurrent cartilages (*rc.c.*), and these are strengthened by their special splints, the anterior paired vomers (fig. 8, *v'*.); behind these, the intertrabecula is supported by the large grooved vomer, proper (*v.*). From the crista galli (*cr.g.*) to the foramen magnum there is one continuous growth of solid cartilage, the fore part of which becomes the crest of the orbitosphenoid (*o.s.*). Up to the sphenoidal fissure (*V^{1, 2}*.) the cartilage runs from the base to the top without any break save the foramen opticum (*II.*), which passage is now enclosed in the wedge-shaped orbitosphenoidal bony centre (*o.s.*). This beginning of a large plate takes up all but the lowest part of the stem of the great orbital wing, but only reaches one-third of the way to the sinuous upper edge of the cartilage. Hence, a full fourth of the whole side wall *has given way* outwards, and the top of the cartilaginous wall reduced to one half its depth, forms an elegant archway over this breach; it is a very perfect arch, but leans a little forwards. This doorway is only partly shut above by the alisphenoid (*al.s.*), the part which has been thrust out; the lower half of this half-opened valve is ossified, and the lower edge of the bony part has a large notch in it, behind the middle; this notch is finished by cartilage, and is the foramen ovale (*V³*.). The basisphenoid (*b.s.*) is growing into this tract of cartilage, and reaches further backwards than the alisphenoid.

The cartilaginous side wall has then a second great archway larger than that caused by the out-thrust of the alisphenoid; here there is an actual suppression of the wall, but the space, which looks a little backwards, is filled in by the large ovoidal cartilaginous auditory capsule. Over the capsule the cartilage is thinned out by pressure of the lateral sinus (*l.s.*), which forms as perfect an arch as that over the alisphenoid. Under the arched swelling caused by the anterior and posterior semicircular canals, which meet above, there is but a shallow concavity for the flocculus cerebelli. Behind this hollow, there is an unciform opening, with its convex margin behind; this deficiency is caused by the "recessus labyrinthi."

The multiperforate meatus internus, further forwards, and the swollen proximal part of the cochlea (*chl.*), are well seen in this view, over the long spheno-occipital synchondrosis. Between these tracts the bony and cartilaginous parts of the occipital arch (*s.o.*, *e.o.*, *b.o.*), the passages for the postauditory nerves, and the occipital condyle (*oc.c.*) are seen.

Visceral arches of the Second Stage.

The compound mandible has developed considerably since the last stage (Plate 22, fig. 4), the dentary bone (*d.*) having grown round MECKEL's cartilage (*mk.*) for some distance, in its middle part, and the upper edge of the bone is now hollowing out to form the tooth sockets. In front, the basimandibular (*b.mn.*) is less, and it is now well defended by bone on its outside. Behind, the trilobate, semicartilaginous "ramus" has assumed its permanent form, although the coronoid and angular processes are equally cartilaginous with the condyloid or articular part. Under the latter, MECKEL's cartilage is being let into the bony plate; behind this part it arches upwards, and below the arched part the ectosteal malleal centre (*ml.* = *articulare externum*) is enlarging. The malleal part of this primary mandible shows a small but distinct posterior angular process (*p.ag.*), as the elbow of the manubrium (*mb.*), or internal angular process. The incus (*i.*) and the stapes (*st.*) are still quite unossified, but they are assuming their permanent form.

The annulus tympanicus (*a.ty.*) is a crescentic band of not very solid cartilage, which is becoming bony along the middle; this bony tract will use up all the cartilage, not leaving any to form a "bullæ."

Third Stage of the Skull of Erinaceus europæus; new-born young, 2½ inches long.

In the "endocranium" at this stage we find a considerable advancement in growth; seen from *below* (Plate 19, fig. 1), and from *above* (fig. 2), it is roughly pyriform in outline, gradually enlarging up to the auditory region, and then suddenly lessening. The short snout (fig. 1, *al.n.*) has the nostrils (*e.n.*) lateral; this region has a definite bracket-shaped selvedge where it comes in contact with the premaxillaries, and from the submesial part of this hind edge the recurrent cartilages (*rc.c.*) are given off; these are large tongue-like tracts, convex infero-laterally and concave on the upper and inner face, where, for a short distance, they form a perfect tube round each JACOBSON's organ. They are supported on their inner face by the dagger-shaped front paired vomers (*v'*.), whilst the vomer, proper (*v.*), runs in between them in front. That bone, overlapping these parts in their hinder third, runs backward to the end of the right and left subcranial recesses of the nasal labyrinth; it is widely forked in its hinder, and strongly carinate in its middle, third.

The aliseptal region (*al.sp.*) narrows in at its middle, and then expands again to become alieithmoidal (*al.e.*).

The inferior turbinals (*i.tb.*) arise from its inner face, and can be seen in the space right and left of the vomer. Where the vomer forks, there each fork supports the inturned nasal wall, now the floor (*n.f.*), which is finished by the vomer. In the front of this part the inturned walls give off the "precurrent cartilages," already described. At present, the hinder region of the nasal labyrinth forms merely part of a scroll, and has not yet closed in to finish the hinder recess. The very solid basal beam is seen between the forks of the vomer, first as perpendicular ethmoid (*p.e.*), and then as presphenoid (*p.s.*). The proximal part of the orbitosphenoid is hidden by the recesses of the nasal labyrinth, the bony centre (*o.s.*), can, however, be seen in its upper part.

On a lower plane, the large alisphenoids (*al.s.*), with their oblique sinuous outer margin, are seen now to be largely ossified; these bony plates are perforated by the 3rd branch of the 5th nerve (V^3), for they have a large foramen ovale a little behind their middle. Between these wings and the basisphenoid (*b.s.*) there are still two remarkable tracts of cartilage, one of these is the large synchondrosis between the alæ and the base, and the other is a button-shaped projection (*e.pg.*), between the pterygoid (*pg.*, *pg.c.*) and the foramen ovale (V^3), but a little in front of both.

This projection is the cartilaginous rudiment of the external pterygoid plate, which in this broad-floored skull is in its normally Mammalian position, namely, a good distance outside the correlated pterygoid, with its independent cartilaginous nucleus.*

In this type, and in many of its Insectivorous congeners, the basisphenoidal bony centre (*b.s.*) runs behind, largely, for some distance, into the alisphenoidal cartilage (*al.s.*); this is a most important diagnostic of a true, normal, Insectivore. It is, however, a very gentle modification of that which is diagnostic of the skull of the Marsupials, namely, a "tympanic wing," which grows backward from the alisphenoid. Here, the rudimentary tympanic wing arises from that part of the alisphenoid which is ossified vicariously from the basal centre; thus the further growth of the tympanic wing is merely a shell-like flange of the basisphenoid. Hence the bone which develops round the *tympanic air-cell* in the typical Insectivora, assisting the superadded annulus tympanicus, is basisphenoidal. The alisphenoidal centre, in Marsupials, which forms the front part of their drum-cavity, is supplemented by a large, crescentic "os bullæ," which ultimately becomes ankylosed, in most cases, to the alisphenoid. Moreover, the extensive pneumaticity of the basis cranii of the Insectivora, at this part, is very Sauropsidan, and these types have also a considerable upper tympanic recess inside the squamosal bone, as in Crocodiles, Birds, Marsupials, and Edentates. At present the basisphenoid (Plate 19, fig. 1, *b.s.*) does not reach so far forwards as the ali-

* In the typical Ruminants, and still better, in the genus *Cavia* among the Rodents, this sphenoidal outgrowth is seen to be manifestly the homologue of the "basipterygoid process" of the Sauropsida, growing as it does from the side of the basal beam. Its *visceral correlate*, the pterygoid cartilage, which, indeed, dominates it, has undergone most remarkable structural modifications in the types in which it re-appears, *e.g.*, in Chelonians, Crocodilia, Passerine Birds, and, lastly, in the lower Mammalia.

sphenoids, but it goes further backwards, yet there is a considerable tract of cartilage separating it from the basioccipital.

A groove in its lower face leads to the still unclosed pituitary space (see fig. 2, *py.*); whilst right and left it has a deeper groove filled by the terete pterygoid (*pg.*) with its cartilaginous terminal nucleus (*pg.c.*). Behind the pterygoids, and in front of the sinuous wedge-like growth of bone in the middle, there is a definite rudiment, as an oblique ridge, of the future tympanic wing.

The broadest part of the skull is behind the posterior sphenoid; here the huge cochleæ (*chl.*) display their coils, and outside them the broad tegmen tympani has on its inside the groove for the facial nerve (VII.), which escapes from the skull behind the edge of the alisphenoid. This groove is protected behind by the confluence of the epihyal (*e.hy*) with the auditory capsule; the nerve escapes behind it, through the stylomastoid foramen. In front of the epihyal, the fenestra ovalis (*fs.o.*) is seen obliquely, and the fenestra rotunda (*f.r.*) mesiad of it. Behind the fenestra rotunda, and further inwards, the large passage for the 9th and 10th nerves (IX., X.) is seen, and behind that passage the lesser hole for the 12th nerve (XII.) The basioccipital (*b.o.*) is roughly hexagonal; the exoccipitals (*e.o.*) are developing in the hollow between the paroccipital convexities and the condyles (*oc.c.*).

The *upper view* of the endocranium of this stage (Plate 19, fig. 2) is shown with the upper part cut away for the better display of the fundus cranii. The crenate hinder margin of the nasal capsules is almost transverse, only a little concave, and is so thoroughly *pre-cranial* as to display nearly all the large cribriform plate (*cr.p.*). The top of the septum nasi (*s.n.*) and perpendicular ethmoid (*p.e.*) is seen at its junction with the alæ or roof (*al.sp.*, *al.e.*); the middle part of the continuous partition is thicker than the end. The upper part of the capsule is constricted twice, so as to form a front, a middle, and a hind, enlargement. The lateral part is constricted, gently, once. There is no definite cartilaginous crista galli (*cr.g.*), but merely a gentle rising of the wall in front, directly behind the end of the roof.

The cribriform plate has floored the whole fossa, and this tract, as well as the lateral walls, are confluent with the fore edge of the anterior sphenoid. The broad short presphenoid (*p.s.*) is unossified, and it has in its middle a hollow, showing the double nature of the bar. The orbitosphenoids (*o.s.*), are ossified, proximally, close to the base, in their hinder margin; the fore part and the whole of the main wing still remain soft. This pyriform centre is perforated by the optic nerve (II.), which escapes near the hind margin, half-way up the ascending bony tract. The inturned upper edge has been cut away, but the band is shown to run backward to, and to be confluent with, the auditory capsule.

The hind margin of the orbitosphenoid (*o.s.*) is sinuously concave and hides the more distinct alisphenoid (*al.s.*) at its fore edge. The basisphenoid (*b.s.*) occupies the hind half of the small open pituitary space (*py.*); it is separated by a large tract of cartilage, as yet, from the basioccipital (*b.o.*). Both before and behind, that centre is

seen, even above, to be creeping into the alæ, the bony centres of which just touch the foremost of these extensions of the basisphenoid. But more than a third of the hind part of the alæ is still cartilaginous; the posterior external part dips below the auditory capsule, just as the front margin does under the orbitosphenoid.

The sphenoidal fissure ($V^{1,2}$.) is an oblique reniform foramen, and to it a groove for the 2nd branch of the 5th nerve runs from the large foramen ovale (V^3 .). A small sphenotic flap of the auditory capsule overlies the alisphenoid, externally; between this part and the coiled cochlea the facial nerve (VII.) escapes, running first under a bridge of cartilage from the foremost hole of the meatus internus (VII., VIII.). The swellings outside the wall—which has been cut away horizontally—are due to the horizontal and posterior semicircular canals (*h.s.c.*, *p.s.c.*), the arch of the anterior canal (*a.s.c.*) is cut away and its cavity exposed. The hollow for the flocculus is not well shown in this view; behind it, the opening of the “recessus labyrinthi” is seen.

Patches of bony cells are now to be seen, the beginnings of the extensive opisthotic bone (*op.*). These are at the hinder margin of the cochlea in the *lower view* (fig. 1). This bony deposit is to be seen, inside, in front of the large foramen for the 9th and 10th nerves (IX., X.). This foramen and the condyloid (XII.) in front of it are seen in the upper view with the exoccipital (*e.o.*) creeping up to the latter; the large six-sided basioccipital (*b.o.*) still lies in the centre of the large multiangular basal cartilage, flanked, outside and behind, by the occipital condyles (*oc.c.*).

Visceral arches of Third Stage.

The outer and inner elements of the mandible (Plate 22, fig. 5) are still bound up together, and are nearly equal in bulk. The new condyle on the “ramus” is at no great distance in front of the primary morphological condyle—the short crus of the incus (*i.*). This suspensorial segment is still unossified, and so is the stapes (*st.*) or uppermost part of the next arch; but the malleal bony centre (*ml.*) is working into the cartilage. The dentary (*d.*) has grown over MECKEL'S cartilage (*mk.*) in one place, and is converting that part into bone; in front of this ensheathed part the rod is very solid; its basal bar (*b.mn.*) is well formed, and turns upwards somewhat. The cartilaginous ends of the three hind lobes of the ramus keep growing, *pari passu*, with the rest; the annulus tympanicus (*a.ty.*) is now ossified.

The hyoid arch has been cut away where the epihyal (Plate 22, fig. 6., *e.hy.*) is confluent with the auditory capsule (see fig. 3). The cartilaginous segments are solid and strong, but are at present quite unossified.

Fourth Stage of the Skull of Erinaceus europæus; young specimens, 2 weeks old; 3 inches long.

This stage shows but little difference in the general form and condition of the endocranium; but the osseous centres are much more advanced (Plate 19, figs. 3–5). I have

figured the upper aspect as a perfect object, not having cut away the rim and roof of the chondrocranium.

The general description just given of the third stage may serve on the whole for this, but the bony tracts will be especially noticed. The large front paired vomers (*v'*.) protecting the recurrent cartilages (*rc.c.*) and JACOBSON'S organs are still separate. The proper vomer (*v.*) is becoming very strong, and its keel is now double, in front. On each side of its forks, behind, there is a small bony tract; these are the bones which help to unite the two sides of the nasal labyrinth to each other and to the vomers; they are the hinder paired vomers (*v''*.) The folds of the middle turbinal (*m.tb.*) are seen to be undergoing ossification; the hinder pair of these centres is close to the precurrent cartilaginous spikes, which run forwards on each side of, and above, the middle keeled part of the vomer. The hinder part of the nasal labyrinth is opened out somewhat, artificially, for display.

The large orbitosphenoidal bones (*o.s.*) are running upwards towards the marginal band; below, they are beginning to ossify the basal tract, or presphenoidal region (*p.s.*). The posterior sphenoid is now almost completely ossified, but the bones of the alæ and base (*al.s.*, *b.s.*) are distinct. The external pterygoid process (*e.pg.*) is still unossified. The three bones, measured across the foramina ovalia (*V*³.), are of equal width; but, further backwards, the basisphenoid is the widest of the three, having taken in part of the cartilaginous alæ. Here the hole, right and left, for the internal carotid artery (*i.c.*) is fairly enclosed by the bony deposit of the basisphenoid. This shows that we are not far from the Marsupials, and this agrees with what I have just shown, namely, that the tympanic wings of the posterior sphenoid are *basal*, in the Hedgehog, instead of being *alar*, as in the Marsupials, through the special posterior dilatation of the basal bone in this type. The pituitary hole (*py.*) is now enclosed by bone (*b.s.*); this hole is in the fore part of an inferior groove, right and left of which the pterygoids (*pg.*), left *in situ*, have developed an upper dilated part, by which to stick, like Limpets, to the basisphenoid; their cartilaginous nucleus (*pg.c.*) is not yet all ossified.

The ossification of the auditory capsules is progressing rapidly. The opisthotic centre (figs. 3 and 5, *op.*) reaches from the passage for the 9th and 10th nerves, above the inner margin of the cochlea; it encompasses the fenestra rotunda behind (fig. 3, *f.r.*), and runs up to the fenestra ovalis; above (fig. 5), it is growing round the meatus internus. The prootic (*pr.o.*) is a much smaller centre; below (fig. 3), it is growing over the groove for the facial nerve at the inner edge of the tegmen tympani (*t.ty.*), and above (fig. 5) it is running along under the anterior canal (*a.s.c.*) into the recess for the "flocculus." The basioccipital (*b.o.*) is increasing in size, but it is still in the midst of a wide tract of cartilage; the exoccipitals (*e.o.*) are just enclosing the condyloid foramina (XII.); the supraoccipital is widening over the foramen magnum (*f.m.*).

In the *upper view* (fig. 4), the fore part is seen to be quite unossified, but the

orbitosphenoids reach their own cartilaginous base (*p.s.*). The well-ossified alisphenoids (*al.s.*) are seen articulating with the wide, extensive basal bone,* which shows its pituitary hole in front, and has a low postclinoid ridge running across behind the middle, it has, in front of it, a very shallow "sella." The hinder part of the floor is shown in the partial figure (5); but the huge supraoccipital tegmen, with its wide, angular ossification (*s.o.*) overlapped in front by *two* interparietals (*i.p.*), are to be seen in the main figure (4). All the canals (*a.s.c.*, *h.s.c.*, *p.s.c.*) can be seen in this view where the large auditory capsules project outwards, like short ears, from the sides of this curious cranial "vessel." The exoccipitals (*e.o.*) can just be seen rising right and left towards the postero-external margin of the supraoccipital osseous centre (*s.o.*).

Visceral arches of the Fourth Stage.

About one-third of MECKEL'S cartilage (Plate 22, fig. 7, *mk.*) is now enclosed in a canal formed by the dentary (*d.*). In front of this buried part the cartilage rises and swells into a thick mass, up to where it meets its fellow, from which junction the basimandibular (*b.mn.*) grows forwards, and a little upwards.

The condyloid mass of cartilage is now much larger than that which still remains unossified on the ends of the coronoid and angular processes. The parts that form the ossicula (*ml.*, *i.*, *st.*) have merely become enlarged without any noticeable change; the annulus (*a.ty.*) is also increasing in size.

Fifth Stage.—Skull of Erinaceus europæus; 1 month old; head 1½ inch long.

a. Investing bones.—The superficial parts of the skull have been worked out and figured in this stage (Plate 20, figs. 1-3), as in the second (Plate 17, figs. 3-5), and in the sub-adult (Plate 21, figs. 1-6).

In the *upper view* (Plate 20, fig. 2) we see what a strong roof the investing bones now form to the very solid endocranium. The nasals (*n.*) are small, narrow bones, and diverge in front; the frontals (*f.*) are almost as large as the parietals (*p.*); they are now in one piece on each side.

The large convex parietals have the frontals running in between them in the coronal suture, and the double interparietal (*i.p.*) fits on to their concave hinder margin. The sides of the hind skull are well buttressed by the squamosals (*sq.*), and the fore part of the skull by the huge maxillaries (*mx.*), and the middle-sized premaxillaries (*px.*); the jugals (*j.*) are smallish; the lachrymals are not well seen in this view.

But in the *side view* (Plate 20, fig. 3) the lachrymals (*l.*) are seen to be intraorbital; they are oval, have a large opening (*l.c.*) in front, and are very thin. The imbrication of the subcutaneous scutes that invest the endocranium is well seen in this view. The jugal was removed in the preparation figured, to display the interior of the orbit, the inner wall of which is composed of the lachrymal, orbital plate of the frontal, and maxillary, in front; and behind, by the frontal, parietal, and squamosal; it is a very

* For *b.o.* read *b.s.*

open space. The postglenoid part of the squamosal (*sq.*) is short, the hind part of the squama, in the end of the temporal fossa, is perforated. The facial nerve (VII.) is figured, and also its chorda tympani branch (VII^a.), passing to the large inferior branch of the trigeminal (V³). The 1st and 2nd branches of that nerve (V¹., V².), are seen emerging from the sphenoidal fissure, the former re-entering the skull through the main orbital foramen, and the latter running forward through the great maxillary canal, and emerging through the supraorbital foramen.

The optic nerve (II.) is seen between the forks of the trigeminal (V¹., V².), emerging from its own foramen opticum.

The investing bones, as seen *from below* (fig. 1), show the finishing of a very fine piece of architecture; the hinder superficial pieces, the tympanics, were removed to display the proper cranial structures. This individual was just cutting its teeth; the huge sockets for which are shown with but partially developed dissepiments.

The premaxillaries have a large dentary part, and a small, short palatine process; over this, however, the anterior paired vomer (*v'*.), is seen, which afterwards makes that process of the normal size.

The maxillaries (*mx.*) are enormous, being gravid with many large teeth, and, as the palate is very wide between the tooth-rows, the concave palatine plates are of great extent. There is, here, as in many of the Edentata, a sign of some distinctness of the inner, from the submarginal, part of this bony roof. The inner part is wedged in between the rami of the premaxillary (*a.p.f.*) in front, and then an oblique ridge, running backwards, and a little inwards, up to the posterior palatine foramen, marks the inner part off from the outer. The outer part of the hard palate is a concave tract, forming a lanceolate flange to the internal alveolar wall. The hinder part of the alveolar tract is unfinished; the jugal process is short and sharp.

The palatine bones (*pa.*) are very elegant, and quite *Metatherian* in their characters; their palatal plates are sharp wedges, running forwards, together, between the palatal plates of the maxillaries. An irregular subreniform fontanelle is seen in each plate, near its middle, behind the thickening inside the posterior palatine foramen (*p.p.f.*). Each bone has a thick subarcuate margin, as the finishing, behind, of the palatal plate; these ridges are turned a little forwards as well as outwards. Part of the subcranial tract of each bone is seen behind the hard palate, bounding the nasopalatine canal; this is clamped by the pterygoid (*pg.*); outside this, the palatine bone spreads into a hooked wing, which bends round the front of the oblique, oval, small external pterygoid plate (*e.pg.*). The distinct upper vertical tract of the palatine ends a little behind the anterior sphenoid (*o.s.*), then the wall is continued a short distance further back by the pterygoids (*pg.*), which are not distinct, now, but have already coalesced with the sides of the wide basisphenoid bone (*b.s.*); the lower part is terete, and ends in a short, free hamular process, which has, now, used up all the cartilage.

The tympanics are not given in this figure; they have been removed, with the ossicula auditus, to display the auditory region.

The jugals (*j.*) are flat styles; the squamosals (*sq.*), riding over them, are seen to swell out into a convex shell of bone clamping the parietal, and then to grow inwards to be covered with the broadly-reniform glenoid facet (*gl.c.*). The post-glenoid tract is here seen to bend in to the mastoid region of the ear-capsule, and to end in three tooth-like processes.

Both the *end view* (Plate 19, fig. 6); and the *inner view* (Plate 19, fig. 8), also show the investing bones from their aspects.

Endocranium of the Fifth Stage of Erinaceus europæus.

The *vertical section* (Plate 19, fig. 8) shows the whole of the craniofacial axis up to the presphenoid (*p.s.*); behind, that the axis was cut along the middle, and only half the skull was figured; this part is only two-fifths of the whole length. The round snout has its own septum marked off from the proper septum nasi (*s.n.*) by a considerable inferior notch, in which the JACOBSON'S, or recurrent cartilages (*rc.c.*) are seen to arise. These folded leaves are tubular in their most perfect part, and then are open along the side.

Over the notch the intertrabecula (*i.tr.*) is very thick, but it diminishes very little all along the base of the great ethmonasal wall (*s.n.*, *p.e.*); it is ossified behind by the orbitosphenoids (*o.s.*), in the presphenoidal region; there is no separate median bone there.

The front paired vomer, and the vomer, proper, (*v.*, *v.*), are shown *in situ*; the nasals and frontals (*n.*, *f.*) lie over the roof (*al.sp.*, *al.e.*).

The short descending side of the low triangle formed by the great partition is notched by the numerous olfactory filaments, and the cribriform plate (*cr.p.*) is seen to the right of this crested tract, which has a small, special elevation, above—the crista galli (*cr.g.*).

The anterior sphenoid is still continuous with the nasal labyrinth, in front, by the fore edge of the great orbitosphenoidal cartilage (*o.s.*); the lower third of this tract is ossified, and is perforated by the optic nerve (II.) near its hind margin, below.

The rest of that sinuous margin, passing into cartilage above, is now abruptly free, the rest of the band, over the alisphenoid, and along the supra-auditory region (see figs. 1–4) having been absorbed.

Thus the sphenoidal fissure (V^1 , 2) is now very steep, and perfect; it is bounded below by the cartilage still remaining between the fused orbitosphenoids (*p.s.*) and the distinct basisphenoid (*b.s.*). The low-lying alisphenoid (*al.s.*) is free, in front, and bulges outwards; it is only notched in front by the 2nd branch of the 5th nerve, but is perforated by the 3rd branch (V^3), which forms a large foramen ovale near its hind third; this is much the smaller wing, even now. The basisphenoid is both long and wide; over its hinder half the cochlea is seen; the pituitary hole (see fig. 4) is present, but the *sellar* depression is slight.

The auditory capsule is largely ossified, especially on this, its inner, face; the "crest" of cartilage is not quite gone, nor quite ossified. The recess for the flocculus (*fl.r.*) under the arch of the anterior canal (*a.s.c.*) is about the size of the meatus internus or vestibular eave leading to the foramina for the 7th and 8th nerves (VII., VIII.). The other foramina (IX., X., XII.) in front of, and through, the occipital arch (*s.o.*, *e.o.*, *b.o.*) are seen in this section.

Part of the *outer view* of the hind skull (Plate 19, fig. 9) shows the normal division of the petromastoid into prootic, epiotic, and opisthotic centres (*pr.o.*, *ep.*, *op.*), but the wedge-like epiotic is not a very distinct tract; it is bound to the rest of the main centre—the opisthotic—on its inner side.

There is still unossified cartilage over the anterior canal, and outside its ampulla, and that of the horizontal canal; the paroccipital process (*p.oc.*) is still cartilaginous, and also the stem of the epihyal (*e.hy.*).

These parts are also seen in the *end view* (Plate 19, fig. 6), which displays the occipital arch perfectly, and the auditory capsules partially; the broad cartilaginous tracts, here seen, give the whole structure depicted a diagrammatic distinctness.

In the *lower view* of this perfect skull (Plate 20, fig. 1) the broad snout in front, and the broad basis cranii, behind, are displayed, fore and aft of the large investing bones of the upper face and palate.

The hinder part of the anterior sphenoid (*o.s.*, *p.s.*) is seen behind the hard palate, in the roof of the nasopalatine canal, in the middle, and, right and left, in the wall of the orbit. The top of the orbitosphenoid (*o.s.*) is still unossified, and the presphenoid has been formed by the fusion of the proximal parts of the ossified tracts, right and left, of the two orbitosphenoids (see also Plate 19, fig. 8).

But the posterior sphenoid is freely displayed in this aspect, covered, however, in one part, by the small pterygoids (*pg.*) that have coalesced with it by their subcranial flange.

The suture, right and left, between the alæ and the base (*al.s.*, *b.s.*), is fast disappearing, so that the whole tract which forms so large a part of the base and lower wall of the cranium, proper, is now practically one bone. The well-formed temporal squama (*sq.*) forms a slightly squamous suture with the outer edge of the alisphenoid (*al.s.*), which, in turn, lies some distance outside the orbitosphenoid (*o.s.*). But in this view the squamosals are seen only to form a thin clamp to the alisphenoids, which stretch across the wide tract that intervenes between the hard palate and the auditory capsules. In front of the squamous suture the alisphenoid is notched and uncinatè at its antero-external angle, and then has a somewhat notched, thick margin bordering the sphenoidal fissure (*V¹.*, *V².*). Behind this fissure the palatine bone is seen to hook itself round the front and outside of the small, oval, oblique "external pterygoid plate" (*e.pg.*). A moderate fossa is seen between this piece of carpentry and the ankylosed pterygoid bone (*pg.*), behind which a small foramen is seen. The foramen ovale (*V³.*) forms a conspicuous opening, behind, and further outwards, than the

external pterygoid plate. Behind the foramen the outer margin of the alisphenoid is notched, gently, and then grows outwards again to form a wedge, which is strongly jammed in between the squamosal and the petrous bone. Leading from the external pterygoid plate to this wedge, inside the foramen ovale, is an elegant crest of bone, concave, externally, and lying below the rough, dentated, hinder edge of the alisphenoid. This is the boundary line of the junction of the basal and alar osseous centres, and it is this tract which corresponds with the alisphenoidal part of the bulla of a Marsupial, the root of its so-called "tympanic wing." This and the rest of the basisphenoid (*b.s.*) form a very peculiar structure, quite diagnostic of an Insectivore, and, when suppressed, tells of a departure from the normal skull of this Order. The fore part of the basal tract is pinched in so as to form a very narrow passage; the hind part widens into a semioval concave space. Right and left of this space the basisphenoidal tympanic wings grow out; these are square tracts, notched and uncinat behind, and hollow, externally, where they add to the general drum-cavity. These hinder outgrowths of the basisphenoid are separated by a notch, externally, and by a groove continued from the notch, internally, from the *pre-tympanic* wing which has its homologue in the Marsupial. The cochlear part of the opisthotic (*chl.*) articulates on its inner side with the basisphenoid, and in its outer is margined by the grooved tegmental tract which contains the horizontal semicircular canal (fig. 3, *h.s.c.*). Here the fenestra ovalis (*fs.o.*), fenestra rotunda (*f.r.*), and the hinder opening of the groove for the facial nerve (VII.), bridged over by the epihyal (*e.hy.*), are all displayed.

The cartilaginous projection that contains the two front ampullæ is separated by a bony tract of the opisthotic from the next cartilaginous swelling—the paroccipital (*p.oc.*); behind this the condyle (*oc.c.*) forms a third cartilaginous convexity. The broad, short occipital ring has its transversely oblong basal piece (*b.o.*) separated, still by a widish tract of cartilage, from the exoccipitals (*e.o.*); these are bored by the 12th and notched by the 9th and 10th nerves (XII., IX., X.).

The upper view (Plate 20, fig. 2) shows but little of the endocranium; but a dissected skull, shown in its *lower aspect* (Plate 19, fig. 7), as far as the first third of the basisphenoid, displays several parts not yet described.

In this preparation several of the lesser splint bones were left, *in situ*, and figured; the premaxillaries (*px.*) are shown cut through their alveoli, horizontally, and we see that their palatine process is, at present, very short. But the front paired vomers (*v.*) are close behind, and above, the sub-median part of those bones; they are long splints, a little scooped on their outside, and are in close contact with the pointed fore end of the vomer proper (*v.*), which runs in above them. Right and left of the paired bones (*v.*) we see the large cochleate recurrent cartilages (*rc.c.*), and, outside these, the ossified inferior turbinals (*i.tb.*). The fore part of the upper and middle turbinals (*u.tb.*, *m.tb.*) is ossified; but the greater part of the wall and floor of this large bulbous labyrinth is still unossified. The vomer (*v.*) is carinate behind its pointed fore end,

and the keel is grooved; the hinder two-fifths is in two forks, that run back and gently bend in between the basal beam (*p.e.*) and the postero-inferior recesses of the basal labyrinth. Here the winged divisions of the vomer serve to bind together the right and left tracts of the nasal floor, under the fore half of the middle turbinal region. This second upper binding together of the right and left face, making the skull *doubly desmognathous*, is assisted by a pair of oblong splints, the posterior paired vomers (*v''.*), which run from this great opening between the inferior and middle turbinals up to the oval hinder recess, right and left, of the presphenoid. When the middle turbinal is well ossified in its lower as well as in its front part, then the three vomerine bones and the ossified floor and turbinals all become an indistinguishable tract of bone. This preparation is only figured up to the hind margin of the foramina ovalia (*V³.*); the optic, ophthalmic, and maxillary nerves (*II.*, *V¹.*, *V².*) are figured, emerging from the optic foramina and sphenoidal fissures. The rest of the skull in this aspect is seen in the entire palatal view (Plate 20, fig. 1).

Visceral arches of the Fifth Stage.

The lower jaw (Plate 22, fig. 8) is now almost complete, but there is a little cartilage still left on the coronoid and angular processes. The latter (*ag.p.*) is somewhat incurved. The fore part of MECKEL'S cartilage and the basimandibular rod (*mk.*, *h.mn.*) are still present, but the freed part of the bar is now ossified as a large spatulate processes gracilis (*pr.g.*), much larger than the manubrium (*mp.*).* The incus and stapes (*i.*, *st.*) are now ossified, and are seen *in situ*, so also is the annulus (*a.ty*); all these parts are shown from their *inner face*.

The hyoid arch (Plate 22, fig. 9) has acquired all its bony centres, but the thick, crescentic hypohyals (*h.hy.*) are only ossified in their middle, and the upper ceratohyal (*c.hy.*) only half-way up. The epihyal (Plate 20, fig. 1, and Plate 22, fig. 9, *e.hy.*) is ossified in the upper part directly from the bony substance of the opisthotic (*op.*); it has no separate proper centre ("tympanohyal"), nor splint ("stylohyal").

Sixth Stage of Skull of Erinaceus europæus; young; two-thirds grown.

These large young are profitable for study, because, although well ossified for the most part, nearly all the sutures are very visible; a *vertical section* at this stage (Plate 20, fig. 4) is very instructive.

In the fore part we see the rounded form of the snout, and the complete septum that has grown forwards from the proper septum nasi between the alinasal folds (*al.n.*). The whole partition wall, from the front of the snout to the fore-edge of the presphenoid (*p.s.*), is two-thirds the length of the whole craniofacial axis. The highest, or hinder part, is ossified as the perpendicular ethmoid (*p.e.*), and this reaches forwards for nearly a third of the length of the wall behind the snout. The bone runs further forwards above than below; laterally, behind, it is now confluent with the partially

* The letters of reference should have been *mb*

ossified cribriform plate (*cr.p.*) ; behind, it gets to be a low thick wall between the retral recesses of the nasal labyrinth. The septum (*s.n.*) is moderately thick from above, where it gives off the aliseptal folds (*al.sp.*) to the thick base ; that part shows its thickness as a solid rod with a flat crest, from the low hind part to the equally low foremost part of the septum nasi proper. There, the septum is notched, below, and right and left of the notch the base of the alinasal folds gives off the recurrent cartilages (*rc.c.*), large spatulate processes, tubular, proximally. The palatine process of the premaxillary (*p.px.*) is seen in its thick part, the rest, separate, for some time, as a front vomer, is given in outline in the figure, showing that it is inside the cartilaginous process. The vomer (*v.*) is seen supporting the thick intertrabecular base of the partition, and under this we see the thick inner edge of the palatine plate of the maxillary (*mx.*) ; these bones are united by suture, and now we see why the median vomer should have its keel double (see Plate 19, fig. 7, *v.*), for it articulates with two plates beneath it, and these bones, doubly sutured together, divide the right and left nasal passages from each other. This division ceases where this suture ceases, and this is half-way between the external and posterior nasal openings ; the latter open out behind the soft palate, which is strengthened right and left by the descending plates of the palatine and pterygoid bones (*pa.*, *pg.*). The cranial cavity is roofed, and largely walled in, by the frontals, parietals, and interparietals (*f.*, *p.*, *i.p.*), the ossified remains of the endocranium lying low down in the floor of the skull. A round notch makes the orbitosphenoid bilobate ; above the front lobe is a thin ragged tract lining the orbital plate of the frontal. Where these join there the 1st branch of the 5th nerve (V^1 , ophthalmic) has entered (see also Plate 20, figs. 3 and 5, V^1), it is seen in this section riding over the outside of the cribriform plate to gain the nasal cavity. The longer, more regular hinder lobe of the orbitosphenoid (*o.s.*), passes inside the alisphenoid (*al.s.*) ; these parts lie so low down that neither the optic foramen, nor the foramen lacerum anterius, or sphenoidal fissure, are seen in this directly lateral view. The parietal (*p.*) passes so well down the skull wall that the squamosal—as in the Ostrich—is not seen, or scarcely at all ; in this inner view the elegant curve of the lateral sinus (*l.s.*) is seen near the lower edge of the parietal.

The alisphenoid (*al.s.*) is here visible as a strong concave shell of bone, hidden, however, in front, by the orbitosphenoid, and below by its own large basal beam (*b.s.*) ; its thick ear-shaped hind part rides over the front of the cochlea, and the great oval foramen (V^3) is seen opposite its front third ; behind this part of the base the sella turcica is seen as a shallow concavity, and the posterior clinoid wall as a mere thickening of the base ; behind that thickening the postclinoid region dips downwards—a normal state for this and the rest of the base (*b.o.*).

A solid tract of cartilage still exists between all the three basicranial bones, the first of these (*p.s.*) is high, but it is not an independent presphenoid ; it is only formed, as bone, by the juncture and ankylosis of the right and left orbitosphenoids.

The ossified auditory capsule is seen over the second synchondrosis; it is obliquely fixed, large, and full of hills and hollows on this aspect. The supra-auditory tract of cartilage has been largely absorbed, but its base was ossified, and that remains as a rough crest to the capsule. Below this, in front, the anterior canal (*a.s.c.*) is seen with its ampulla; an oblique rib of bone ascends from the cochlea to the crown of the arched canals, the anterior and posterior. This arch and its hinder enlargement behind the hollow for the flocculus (*f.l.r.*) is not formed by the posterior canal and its ampulla, but by the growth of a tubercle of bone inside that arch, bounding the floccular recess behind, as the oblique ridge does in front.

The meatus auditorius internus (VII. VIII.) is a large archway, between which the petromastoid bone swells into the fore part of the deep sulcus for the posterior sinus, and for the exit of the 9th and 10th nerves; the hollow for the sinus opens below into the foramen lacerum posterius. Behind that opening the lesser hole, or condyloid foramen (XII.) is seen in the substance of the exoccipital (*e.o.*); the condyle (*cc.c.*) is seen behind, the basioccipital (*b.o.*) in front, and the supraoccipital (*s.o.*) above it.

The large rough wings of the basisphenoid are seen below the basal section and behind the pterygoid bone (*pg.*).

The *inner view* of the nasal labyrinth (Plate 20, fig. 5), obtained by removal of the perpendicular ethmoid and septum nasi, shows the complex folds of the nasal, inferior, upper, and middle turbinals (*n.tb.*, *i.tb.*, *u.tb.*, *m.tb.*), and here the ophthalmic nerve (*V¹*) can be seen in its course along the interior of the labyrinth. Below the cribriform plate (*cr.p.*), the right recess of the hindermost part of the nasal cavity is seen running by the base where the ethmoidal and presphenoidal regions meet.

Seventh Stage of the Skull of Erinaceus europæus; young; three-fourths grown.

I have merely figured the outer auditory bones in this, a somewhat more advanced stage than the last, as they are now in a very instructive state—a state retained only for a few months longer, after which much absorption and modification of bone will take place.

The *outer view* of the ear-drum and its chain (Plate 22, fig. 10), shows a condition quite comparable to what is found in subadult and adult Marsupials. Moreover the annulus (*a.ty.*), now rapidly strengthening its thickening inner edge, and has there a row of small osseous points quite similar to those that are the only rudiments of the tympanic ring in the Bird; that feeble chain of bones is best seen in the Corvidæ.

The processus gracilis of the malleus is several times larger than the manubrium (*p.gr.*, *mb.*); it is a strongly ribbed bar, which, appearing in front of its tympanic attachment, there shows a rudiment of the *pretympanic hook* so large in many Marsupials. The body of the malleus is large, and the “posterior angular process” (*p.ag.*), behind the manubrium, is a semioval convexity. The short crus of the stout and well-made

incus (*s.c.i.*) is unusually short; the long crus (*l.c.i.*) is also short, but is well inturned, and has an oval facet for the head of the stapes.

That bone (*st.*) is rather high, has a long oval base, narrow, and somewhat snaggy sides, and has a tubercle on its neck, in which is a very rudimentary interhyal (*i.hy.*), rooted in the base of the stapedia muscle's tendon (*st.m.*).

Eighth Stage of the Skull of Erinaceus europæus; nearly adult.

This skull is, conceivably, a very gentle modification of the type we are familiar with in the Marsupials; it is just fairly within the *Eutherian* margin. The *upper* and *side views* (Plate 21, figs. 2, 3) show that most of the sutures are still present, and that where the sagittal is dying out, there a crest is forming between the top of the large temporal muscles. Also a lambdoidal crest is seen behind the wide interparietal (*i.p.*), which, however, is confluent with the proper supraoccipital (fig. 4, *s.o.*). The coronal suture is **W**-shaped, the bones being strongly dovetailed into each other. The large, long nasals (*n.*), narrow behind, take up about a third of the gently arcuate dorsal line of the skull; the frontals (*f.*) flank them in front, but do not reach the large ascending plate of the premaxillaries (*px.*), the much larger maxillaries (*mx.*) intervening. An oblique ridge separates a deep fossa above from the large lachrymal passage (*l.c.*) below; this passage is on the edge of the orbit, but most of the bone, now largely fused with the maxillary, is inside the orbit. The orbital space opens freely into the temporal fossa, and the outlines of the bones that form the whole of this concavity can be well seen for the most part, the fusion of the lachrymal with the maxillary being exceptional. Down at the base of the orbit the orbitosphenoid can be seen passing within the alisphenoid, and some distance outside the former the alisphenoid and maxillary meet and form a narrow longitudinal bridge over the thick edge of the palatine bone (*pa.*).

The infraorbital foramen (V^2 .) is large, and so is the canal that runs backwards into the skull through the hinder part of the sphenoidal fissure, for the alisphenoid (Plate 20, fig. 6, *al.s.*) is deeply grooved for this large 2nd branch of the 5th nerve.

The jugal (*j.*) is moderately strong; it reaches the glenoid fossa, but is sharp there; it does not dilate, terminally, as in the Marsupials. Part of the basis cranii and the auditory ring can be seen from the *side view*, but the lower view (Plate 21, fig. 1), alone, displays these parts well. The premaxillaries and maxillaries (*px.*, *mx.*) at their palatal junction leave a considerable space (*a.p.f.*), right and left, through which the recurrent cartilages and JACOBSON'S organs can be seen. The palatine processes of the premaxillaries are long but lie above those of the maxillaries; they have added to their substance and length, the antero-lateral vomers or splints of JACOBSON'S organs. The palatine plates of the maxillaries form a fine large concave roof; they are followed by the imperfect plates of the palatine bones (*pa.*). The fenestra seen in each bone in the 5th stage (Plate 20, fig. 1, *pa.*) is now a deep notch open in front, for each palatine bone is now formed in its lower part and fore half into a flat fork with long ragged "tines;"

the inner being the larger and uniting by a "harmony suture" with its fellow of the opposite side. The ascending part of the palatines is strong and has coalesced with the external pterygoid plates (*e.pg.*) on the outer side; they have not united with the pterygoids (*pg.*). The hind margin of the hard palate, formed by the palatines, which have not united with the maxillaries, is an elegant archway with a strong upper lintel over it, formed by a thick rib on each of the palate bones; these ribs meet at the mid-line at a very obtuse angle.

The elements of the basis cranii behind and below are fast coalescing with each other; the sutures of the hind skull, however (fig. 4), are most of them visible.

The paroccipital processes (*p.oc.*) are thickish and somewhat foliaceous; they finish a semioval occipital plane, with its large convex obliquely pyriform condyles (*oc.c.*). But in front of the occipital arch the mastoid processes (fig. 4, *op.*) project like wings and are there strongly sutured to the postglenoid process of the squamosal (*sq.*), which is pneumatic, and has its own foramen. There is a large foramen lacerum posterius for the 9th and 10th nerves, and a lesser foramen condyloideum for the 12th (fig. 1, XI).* The ossified auditory capsule has already been described (6th Stage, Plate 20, fig. 4), but the posterior sphenoid, and the turbinal folds of the nasal labyrinth, with the interior sphenoid can be well studied in this scarcely adult stage, whilst the parts are still capable of being taken to pieces to a considerable degree.

The posterior sphenoid shown in its *upper aspect* (Plate 20, fig. 6), is a large winged bone, with a ragged outline and a multiperforate surface.

The large foramen ovale (V^3 .) is at the hinder and the middle third of each great wing (*al.s.*); the 2nd and 1st branches of the 5th nerve pass with the lesser orbital nerves out of the sphenoidal fissure.

The fore part of the bone does not fit itself to the hinder part of the anterior sphenoid (Plate 21, fig. 7, *o.s.*, *p.s.*), except at the middle; the pointed fore end of each large wing grows outside, free of the orbitosphenoid. The outer and hinder part of each wing is rounded, and this upper surface is broken; it is strongly grooved where the 2nd branch of the 5th escapes from the 3rd and runs forwards and inwards to the great fissure. The narrow front part of the basisphenoid lies some height above the wings, and the bone has several small perforations at this part. The hinder broad part of this bar is very gently hollowed for the pituitary body, and the post-clinoid wall (*p.cl.*) is extremely low.

The *lower surface* of the bone shows the greatest number of diagnostic marks of a typical Insectivorous skull. The inferior wings, external pterygoid processes (*e.pg.*), and pterygoid bones (*pg.*), are well developed and have a good fossa between them. The latter are distinct from the palatines, but have come away, in disarticulation, with the basisphenoid, having already become anchylosed to it, above. Between these internal plates the bone is sharply grooved, but, behind, between the tympanic wings, the basisphenoid has a large cup-shaped recess which might have lodged some such body as

* For XI. read XII. in this figure.

the pituitary. This recess is bounded, behind, by a snag from each tympanic wing. These wings are deeply notched in front, on their outer side, and in front of the notch the alisphenoid has a strong rib of bone running with its concave outline forwards to join the external pterygoid process. This rib is itself notched in the young, but in old specimens this notch is converted into a foramen. Here in this immature specimen the hole is finished only on the *left* side—*right* in the figure.

The same parts are seen from the *hinder aspect* of the bone (Plate 20, fig. 8).

The anterior sphenoid (Plate 21, figs. 7, 8) is less than half the size of the posterior; it has coalesced with the compound ethmoidal bone, behind the extensive olfactory fossa with the underlying cribriform plate (*cr.p.*). The sinuous wings (*o.s.*) are deeply grooved, transversely, near their hind margin; these grooves lead to the optic foramina (II.). These wings are formed by the ossification of only the proximal or lower part of the original cartilage (see Plate 17); they lessen, forwards, like the large wings, and grow down into a keel on each side before they unite to form the short presphenoidal bar.

This skull is *doubly desmognathous*, for the vomerine series of bones unite the two halves of the nasal labyrinth into one common complex structure (Plate 21, figs. 7–9); this is very common in the Mammalia; and is sometimes seen in Birds (*e.g.*, *Gymnorhina*—the Piping Crow of Australia), where the maxillary palatine floor has an ethmo-vomerine floor completed above it.

The antero-lateral vomers have coalesced with the palatine plates of the premaxillaries, lengthening them considerably; and the postero-lateral plates have coalesced with the outside of the forks of the main vomer (Plate 21, figs. 7–9), the latter is a long thickly carinate bone, bluntly pointed in front.

That which is most important to remark upon in the ossified nasal labyrinth itself is that the various turbinals—nasal, inferior, middle, superior (*n.tb.*, *i.tb.*, *m.tb.*, *u.tb.*)—are transformed into a light and porous kind of bone, but when the investing bones—nasals, frontals, &c.—are peeled off them the wall is found to have been absorbed; the succeedaneum to this wall is the outer investing plate. Hence, these coils, when stripped before they are ankylosed to the investing plates, have large vacuities between them, displaying their folds. This is due to the fact that the secondary folds or turbinals, ossify first, and only so much of the primary wall becomes ossified as gave origin to these out-growths; the intermediate spaces are absorbed, being pressed upon and defended by the superficial bony plates.

The *pre-olfactory* region occupied by the inferior or maxillary turbinal (Plate 20, figs. 9, 10, *front* and *side* views) is very large, and this part is exceedingly complicated, as indeed it is in most of the Eutheria; in the Rabbit and the Dog, as well as in the Hedgehog.

The lower jaw (Plate 21, figs. 5, 6) is fairly intermediate between that of a Marsupial and that of a high Mammal; the three proximal processes are all large and well formed, and the lower, or angular, is somewhat inflected as well as thickened.

The incus and stapes have altered very little since the last stage (Plate 22, figs. 10, 11, *i., st.*); but the malleus (Plate 22, fig. 12) has lost all its large (metatherian) fore-growth, only a fine, sharp, processus gracilis (*p.gr.*) now remains.

The hyoid arch (Plate 22, fig. 14) is well ossified, now; the epihyal (*e.hy.*) is continuous with the ear-capsule, above, and is joined to the upper ceratohyal (*c.hy.*), below, by a tract of non-segmented cartilage. The lower ceratohyal (*c.hy'*) is about equal to the upper in size, and the hypohyal (*h.hy.*) is only half as long, but broader; all these as well as the basal piece and thyrohyals (*b.h.b.r., t.hy.*) are united by joints, mostly with a perfect joint-cavity. The "annulus" (Plate 21, fig. 1, *a.hy.*) has all its irregular bony nodules confluent with the main bar.

On the Skull of the Common Mole (Talpa europæa).

My materials for working out this type have been very copious; my work links itself on to that of Mr. WALTER HEAPE (Quart. Journ. of Micr. Sc., July, 1883), to whom I am indebted for some of my best specimens.

These materials are divisible into arbitrary *Stages*, as follows:—

Stage 1.—Embryos of Mole, $\frac{1}{4}$ of an inch long; (this and the next were measured round the curve formed by their head and body, the tail not being reckoned; the rest were measured first from snout to occiput, and then from occiput to root of tail, and these were added together to give the full length, of course, excluding the tail).

Stage 2.—Embryos of Mole, $\frac{1}{3}$ of an inch long.

Stage 3.—Embryos of Mole, $7\frac{1}{2}$ and 8 lines (twelfths of an inch) long.

Stage 4.—Embryos of Mole, $\frac{3}{4}$ and $\frac{4}{5}$ of an inch long.

Stage 5.—Embryos of Mole, 1 inch long.

Stage 6.—Embryos of Mole, $1\frac{1}{3}$ inch long.

Stage 7.—Embryos of Mole, $1\frac{1}{2}$ inch long.

Stage 8.—Ripe young of Mole, $1\frac{2}{3}$ inch long.

Stage 9.—Young Moles, three or four days old; $1\frac{3}{4}$ and $1\frac{4}{5}$ inch long.

Stage 10.—Young Moles, 3 inches long.

Stage 11.—Young Moles, two-thirds grown.

Stage 12.—Young Moles, three-fourths grown.

Stage 13.—Adult Moles.

First Stage.—Embryo of Mole, $\frac{1}{4}$ inch long.

This stage (Plate 16, fig. 1) is, here, merely studied from its outer aspects; it is very profitable for comparison with the corresponding stage in other Mammalia and in the Vertebrata, generally; it is *nearly half as long* as a similar embryo of a large Mammal would be.

About twenty-eight somatomes can be made out; the heart is still seen in a large

pouch that projects from the ventral aspect of the embryo. The fore limbs are large flat buds behind the middle of the larviform embryo, and the hind limbs are much smaller and are curved inwards on each side of the rudimentary tail. The mesocephalic flexure is well marked, and the cerebral vesicles very large; the long, lobulate hind-brain is covered with a very thin layer of tissue. The pineal elevation is to be seen between the fore- and mid-brain, and the fronto-nasal process against the former vesicle. Between these parts the notch which contains the rudimentary olfactory organ is seen; this is bounded, above, by a band which runs into the large maxillo-palatine lobe. This lobe is separated by a sharp notch, the oral opening, from the rudimentary mandible, behind which is the hyoid fold, and the first branchial fold; these are separated by clefts.

Over the maxillo-palatine lobe the small eye-ball is seen, and over the hyoman-dibular cleft the oval auditory sac.

Second Stage.—Embryo of Mole, $\frac{1}{3}$ inch long.

I have had sections* made of the embryos at this stage; these have been studied, but not figured, as the tissues of the skeleton were in an *indifferent* state, and it is not part of my plan, as a rule, to give histological figures.

The *external form*, however, in this stage is very important (Plate 16, figs. 2–4), as the influence of heredity, which had begun to show itself in my first stage (fig. 1), in the large size of the rudiments of the fore limbs, is here very evident indeed.

The limbs are now, evidently, pentadactyle; but the fore limb is also very large, and close to the head.

The folds of the outer skin are now perfecting themselves, we see the eye-ball in its circular setting, the external meatus of the ear is formed, and the outer nostril, with its rim complete.

Third Stage.—Embryo of Mole, $7\frac{1}{2}$ and 8 lines long.

In an embryo two-thirds of an inch long (Plate 16, fig. 5) the fingers and toes are distinct, and the small pig-like creature has got a distinct circular eyelid; the meatus externus is very small, and encircled with a fold, and the nostrils are now well fashioned.

The true hyaline cartilage is now differentiated, and in this stage I shall give a description of the sections made from a specimen scarcely two-thirds of an inch ($7\frac{1}{2}$ lines) long. The dissected figures of the skull of the next stage ($\frac{3}{4}$ inch long, Plate 25, figs. 2, 3) will serve, like a ground-plan, to explain both the sets of sections, namely, those of the same stage, and those of this earlier embryo.

From about 200 exquisitely sectioned and perfectly stained slices of this small

* These and most of my sections were made for me by my son, Professor W. N. PARKER; those of the next stage were made by, and belong to, F. PENROSE, Esq.

head— $3\frac{1}{2}$ lines long—I have only figured twelve, but some of these are drawn as separate half sections; they were somewhat oblique.

Section 1 (Plate 23, fig. 1).—This is close to the hind part of the alinasal region (*al.n.*), at the beginning of the aliseptal. The nasopalatine canal is open below, and here, behind the narial valves, the cavity is high and simple. The septum nasi and alinasal folds (*s.n.*, *al.n.*) are well developed; the thickness of the former, below, is due to the size of the intertrabecula, and the cartilaginous walls are thickening above to form the nasal turbinal, and below to form the inferior turbinal.

In the thick mass of tissue below the septum the recurrent cartilages (*rc.c.*) are seen, they are placed subvertically, and are thick above and thin below; outside them JACOBSON'S organs (*j.o.*) are shown, and inside them the palatine processes of the premaxillary (*p.px.*).

The hind part of each premaxillary (*px.*) is cut through laterally, there are two laminae of bone meeting, above, at an acute angle; below, in the mucous membrane, a tooth-pulp (*p.*) is shown; the nasals (*n.*) are forming, above.

Sections 2 and 3 (Plate 23, figs. 2 and 3).—These, which were *one* oblique section, show, on the deepest side (fig. 3), the remarkable manner in which the rudimentary nasal turbinal (*n.tb.*) encloses an oval space; below that space the cartilage grows inwards, and is pedate; this is the inferior turbinal. Here, inside JACOBSON'S organs (*j.o.*), the recurrent cartilages (*rc.c.*) are thick throughout, and the little vomerine bones are not apparent. The maxillary (*mx.*) comes into the section here, and the nasals (*n.*) are seen, above. In this, as in the last, mucous crypts are seen here and there between the lining of the nose and the cartilage; the whiskers are cut through in the outer skin, and a tooth-pulp is shown below.

Sections 4 and 5 (Plate 23, figs. 4 and 5).—These, which were *one* oblique section, were made through the middle of the eye-ball (*e.*) on one side, and on both through the olfactory lobes (*O^b.*). It also takes in the lower face, with the tongue (*tg.*). The mass of soft tissue under the olfactory lobes will be differentiated into the cribriform plate, the olfactory nerves passing through its meshes. This is behind the roof of the nasal labyrinth, and thus the septum, here, the perpendicular ethmoid (*p.e.*), has a free upper edge—the region of the crista galli.

In the side which is the foremost part (fig. 4), the nasal wall passes a little over, above, and under, below, and sends inwards a large plate of cartilage, which is bifurcated and very thick at its inner part. Here we have the rudimentary middle turbinals (*m.tb.*). The same is seen on the other, or hinder, side, but above; the section is near the orbitosphenoid, or fore part of the cartilaginous cranium, for it is continuous with the nasal labyrinth (*al.e.*); the frontal bone (*f.*) is seen outside it. Also, below the bulbous base of the middle ethmoid, formed here of all the three trabeculae, the hinder forks of the vomer (*v.*) are to be seen; whilst below, on the palatine ridge, the palatine plate of the palatines (*pa.*) is cut across. Below, outside the base of the tongue (*tg.*), the dentary (*d.*) and MECKEL'S cartilage (*mk.*) come into view.

Section 6 (Plate 23, fig. 6).—This large partial section is through the back of the eye-balls (*e.*), the front of the cerebral hemispheres (*C^{1a}.*), and the hind part of the nasal labyrinth. The perpendicular ethmoid (*p.e.*) is, as in the last, a wall standing alone, rounded, but thinnish above, thick and bulbous below; at present, the whole roof of the labyrinth, or floor of the cranial cavity at that part, is void of cartilage; there are two nasal passages (*n.p.*) on each side, and between them the rudimentary middle turbinal is growing. The floor of cartilage is imperfect below; the wall (*al.e*) passes into the orbitosphenoidal lamina, above, and there is a fissure more than half-way down. The raphe formed by the meeting together of the right and left palatal laminae is strengthened, still, by the palatine plate of the palatine (*pa.*); a wide, but not deep passage (*n.p.c.*) is seen above this second floor. The root of the tongue (*tg.*), tooth-pulps, and the dentary bone (*d.*), with MECKEL'S cartilage (*mk.*) inside it, are all shown in the lower part of this section.

Section 7 (Plate 23, fig. 7).—Here the cerebral hemispheres (*C^{1a}.*) are large, and the wide orbitosphenoids (*o.s.*) form the floor of the cranial cavity; they are continuous with the presphenoidal bar (*p.s.*), which is oval, with the long diameter transverse. The wings themselves (*o.s.*) are thinner and then thicker, twice over. This section is diagnostic of a *Eutherian* skull; the alisphenoid (*al.s.*) comes into the same section with the orbitosphenoid (*o.s.*) lying outside it, and they have the Gasserian ganglion (*V.*) between them. Here the pterygoid bones (*pg.*) are cut across, and the little nodule of cartilage, which becomes the pterygoid (*pg.e.*). We also see the undiminished Meckelian rod (*mk.*) with the growing ramus of the lower jaw (*d.*) outside it. The large nasopalatine canal is constricted in the middle, and has the ceratohyals (*c.hy.*) in section below it.

Section 8 (Plate 23, fig. 8).—This section is through the fore part of the basi-sphenoidal bar (*b.s.*), close behind the presphenoid; here it has been formed by the three trabecular bars, the hind part of the intertrabecula wedging in between the paired trabeculae.

The angle of the orbitosphenoid (*os'*), and part of its lower hind margin, has been cut through; this latter band is, however, far from the basal beam; it lies over the huge Gasserian ganglion (*V.*), the fore part of which is here seen in section; this mass lies on the out-thrust alisphenoid (*al.s.*) which is hollow above, and has a thick upper edge. On the inside of each alisphenoid the upper part of the corresponding pterygoid is cut across, and below the alisphenoid is the lower jaw or dentary (*d.*) developing outside MECKEL'S cartilage (*mk.*); it is an oblique long oval tract, hollow in the inside where the rod of cartilage lies. The wide nasofacial passage is constricted at its middle; below it, part of the larynx is seen, and on the outside the ceratohyal (*c.hy.*).

Section 9 (Plate 23, fig. 12).^{*}—This section is directly in front of the pituitary body and sella turcica; and here the alisphenoid is cut across, where it runs near the

^{*} The re-arrangement of most of these figures as *half-sections*, so as to get them into a smaller space, has produced some confusion; the figures do not always follow in regular succession on the Plates; but the numbers give the correct order, except in this instance.

basisphenoid (*b.o.*),* the tympanic wings of which are seen as projections, below. A small tract of each wing is seen above the internal carotid (*i.c.*) entering the skull, and the orbitosphenoidal band (*o.s'*.) is also seen at one-third of the height of the side-wall. The inner margin of the huge Gasserian ganglion (*V.*)—here cut across its middle—lies in the bend of the artery, it reaches more than halfway outwards and upwards to the orbitosphenoidal band.

The angle of the outer mandible (*mn.*) is cut through, and below, and further inwards, MECKEL'S cartilage (*mk.*).

Over MECKEL'S cartilage the curved section of a considerable tube is seen, and also under it and nearing outwards a much larger space; the upper cavity is the beginning of the Eustachian tube, and the lower the tympanic cavity. Outside the latter a patch of cartilage is shown; this is part of the meatus. Under the inner edge of the tympanic cavity the epihyal cartilage (*e.hy.*) is cut off close to its junction with the ceratohyal; and towards the mid-line the hypohyal (*h.hy.*) is severed near the larynx (*lx.*), part of the cartilage of which is laid bare.

Sections 10 and 11 (Plate 23, figs. 9 and 10).—These two half sections show the pituitary body (*py.*) above and in front of the ascending postclinoid cartilage, in the upper surface of which we see the point of the notochord. The auditory capsules (*chl.*) are cut across; they lie a considerable distance from the basisphenoid (*b.s.*). The orbitosphenoidal band (*o.s.*) is present here, it soon becomes the supra-auditory crest. Over the auditory capsules the Gasserian ganglia (*V.*) are seen cut across in their hind part, and below them the geniculate ganglia (*VII.*).

In fig. 9, the tympanic cavity is cut across; outside and below it the meatus cartilage is shown. The small upper piece is outside the head of the malleus (*ml.*),† below which the body of the incus is seen, whilst its long crus is shown as turning inwards towards the capsule; the fenestra ovalis is cut across at its front margin in fig. 10, but the stapes is massed.

Section 12 (Plate 23, fig. 11).—In this partial section we see the basilar artery (*b.a.*) cut across obliquely over the hind part of the basioccipital (*b.o.*); here the large hind part of the cochlea (*chl.*) touches the basisphenoid, ready to coalesce with it. The orbitosphenoidal band (*o.s'*.) is now very deep, close in front of its supra-auditory continuation.

The geniculate ganglion is still seen, and also under it the passage in the top of the auditory capsule for the facial nerve (*VII.*), which enters its canal at this place. The outer wall of the auditory capsule is deficient in two places here; the upper deficiency is partly filled up by the base of the stapes (*st.*), it is the fenestra ovalis; between its base and apex the stapedial artery (*st.a.*) is seen as it passes to the inside of the mandible. The other space, not stopped up by cartilage, is the fenestra rotunda; the outer part of the capsule with its tegmental projection (*t.ty.*) is seen external

* The letters of reference should have been *b.s.*, and only one line to *i.c.*

† The line of reference to the figure is made too low down.

to the stapes, and the epihyal (*e.hy.*) growing from it; the notochord (*nc.*) is compressed in the middle of the basal cartilage.

Section 13 (Plate 23, fig. 13).—This partial section is near the last, and shows actual fusion of the capsule with the basis cranii (*b.o.*), and the inferior position of the notochord (*nc.*). The lateral band (*o.s.*) is not yet continuous with the auditory capsule, which is, here, cut through at the meatus internus. The tegmen tympani (*t.ty.*), is severed near part where the short crus of the incus is articulated, and the stapes (*st.*) is cut through behind the middle, so that the stapedia artery has been removed. The two fenestræ have a convex tract of the capsule between them.

Section 14 (Plate 23, fig. 14).—The top and bottom of the section are left out, and the capsule is drawn with the investing basal cartilage (*b.o.*). Under this sinuous thinnish plate of cartilage the notochord is seen, and above it the basilar artery. The crest of cartilage is now the supra-auditory, and the recess outside it at its junction with the capsule will be filled in by the squamosal bone. The tegmen tympani is cut through behind the incus; but the fenestræ (*fs.o.*, *fs.r.*) are still in view, the anterior and horizontal canals (*a.s.c.*, *h.s.c.*) are also seen.

Section 15 (Plate 23, fig. 15).—The supra-auditory cartilage (*s.a.c.*) is deficient below, where it passes into the supraoccipital. From the great obliquity of the capsule we still have the semicircular canals; the anterior (*a.s.c.*) and the horizontal (*h.s.c.*) are here seen to be imbedded in solid cartilage; part of the vestibule is seen below and within. The capsule is separated by a considerable space from the basal cartilage (*b.o.*), which is thick and bracket-shaped; the notochord (*n.c.*) has again reached the upper face of the investing mass of cartilage; the vagus and glossopharyngeal nerves (IX., X.) escape through the interspace, right and left, between the capsules and the basis cranii; the foramen for the hypoglossal (XII., *f. condyloideum*) has been laid open. These sections of the newly chondrified skull will be better understood after I have described the next series.

Third Stage (continued).—*Dissection of the visceral arches of an embryo Mole;*
 $\frac{2}{3}$ inch long.

An inner view of these parts, in connexion with the auditory capsule, is shown as drawn from an outspread preparation; the osteoblastic tracts had been removed from MECKEL'S cartilage (Plate 28, fig. 1). The part of the capsule containing the semicircular canals (*a.s.c.*, *h.s.c.*, *p.s.c.*) is in its natural relation to the arches, and shows their extreme obliquity. The capsule is cut away so as to show the base of the stapes (*st.*) in the fenestra ovalis. That part of the hyoid arch which corresponds to the epibranchial—the epihyal (*e.hy.*)—is seen to be outside the stapes, and to be confluent with the capsule a little above the insertion of the head of the pharyngohyal (stapes). The junction of the inturned end of the long crus of the incus (*l.c.i.*) is from the eye in the figure, and is hidden by the base of the stapes, the perforated stem of which is at a right angle to that part of the incus. Looking upon the short

crus of the incus (*s.c.i.*) as the morphological equivalent of the "otic process" of the quadrate of a Bird, Reptile, or Amphibian, and remembering that the "orbital process" is suppressed in this Mammalian suspensorium, we see by this figure that the incus is well in front of the auditory capsule. Indeed, it is as definitely in front as in the embryo of any of the Sauropsida, in some of which the otic process, ultimately, runs backwards to be articulated with the fore edge of the occipital arch, beyond the auditory capsule, altogether.

The body of the incus (*i.*), as well as its two crura, is already of the normal shape, and so also is the malleal portion of the primary mandible, with its bulbous head, and its large, forwardly-turned manubrium (*ml.*, *mb.*). The large, terete, sigmoid Meckelian rod (*mk.*), after uniting with its fellow of the opposite side, runs into a basimandibular spike (*b.mn.*).

Here, normally for a Mammalian hyoid arch, but not for a branchial arch, as such, there are three segments below the flat, rounded epihyal (*e.hy.*), which is not united with its own uppermost segment, but with the auditory capsule. Nor is it united with the next segment, or upper ceratohyal (*c.hy.*), by cartilage, for that next lower piece is fibrous above.

The two next segments are the straight lower ceratohyal (*c.hy.*), and the curved hypohyal (*h.hy.*); this is the stoutest of all the segments. The common rudiment of the basihyal, basibranchial, and first hypobranchials (*b.h.br.*, *t.hy.*), is a stout, well-formed U-shaped piece, with the front edge of which the two hypohyals are articulated. Over the tympanic cleft, the tympanic annulus (*a.ty.*) is seen, formed of a crescent of tender bone round the membrana tympani (*m.ty.*).

Fourth Stage.—Skull of embryo of Mole; $\frac{3}{4}$ and $\frac{4}{5}$ of an inch long.

Dissection of the chondrocranium of an embryo Mole, $\frac{3}{4}$ inch long.

The basal view of this skull (Plate 25, fig. 2) shows the distinctness of the olfactory and auditory sense-capsules from the cranium proper, and the upper view (fig. 3) displays the large amount of cartilaginous "tegmen," in spite of the cruciform fontanelle. The general outline of the skull is pyriform, the narrow nasal end being the stalk; this is dilated, in front, over the *inferior* external nostrils (*e.n.*), and again where the alinasal region (*al.n.*) ends, opening below at the beginning of the aliseptal region (*al.sp.*), where the inferior turbinals (*i.tb.*) are given off. At its middle the nasal labyrinth swells out, suddenly, so that it is itself pyriform, and ends in front of the orbitosphenoid (*o.s.*) in a large and somewhat bilobate cushion; the right and left masses are separated by the perpendicular ethmoid (*p.e.*) which passes into the septum nasi (*s.n.*). The long alinasal region is closed below, except at the sides, in front; and the hinder fourth of the main labyrinth is also perfectly floored with cartilage. The open space between these two floored regions is largely filled up by the huge recurrent lobes (*rc.c.*) which support JACOBSON'S organs; these tongue-like tracts are three-fourths the length of the long open space, and are themselves supported

on their inner face by the anterior paired vomers, which are very slightly separated from the palatine processes of the premaxillaries (*p.px.*); the whole of these bony tracts has been figured here, *in situ*. In the dilated front end of the lower opening the inferior turbinals (*i.tb.*) are seen, and the folds of the middle turbinal (*m.tb.*) in the hinder rounded space. Where the floor turns inwards and upwards towards the septum (*p.e., s.n.*), there it gives off a spike of cartilage which nearly reaches the recurrent lobe; this spike is the precurrent cartilage. The line of junction of the proper cranium with the nasal labyrinth (*o.s., al.e.*) is quite visible; the orbitosphenoidal region of the cranial wall and roof is very wide, and has a convex outer face. The stem of each tract is narrow, and becomes, after ossification, the permanent, small orbitosphenoid. Each band winds round behind the corresponding lobe of nasal labyrinth, and is not flush with it, below; the two bands are continuous with the presphenoidal region of the prepituitary basal beam.

That beam is thickest where these bands join it; it is mainly formed of the intertrabecula, for the paired trabeculae are flattened against the median part, and then cease between the hinder part of the right and left nasal floors. The chink between the convex hinder edge of the orbitosphenoidal stem (*o.s.*) and the concave edge of the alisphenoidal lobe (*al.s.*) is ear-shaped and curves backwards, and is large and round against the basal beam; this is the large sphenoidal fissure for the ophthalmic and orbital nerves (*V¹.*). The small optic foramen is oblique, and is hidden in this view by the alisphenoid (see fig. 3, II.). The basal cartilage is very narrow between the orbito- and alisphenoids, and then expands suddenly, to remain wide to the end of the skull. Here, as in all typical Insectivores, the basis cranii in the early skull is extremely wide, ready to become pneumatic in relation to the auditory function. Even where the large cochleae (*chl.*) push their coils right and left against the basisphenoidal, at its junction with the basioccipital, region, it is still nearly four times as broad as at the point where the presphenoid and basisphenoid meet.

The stem of each alisphenoid scarcely becomes pinched in, but its margins are both concave, having the emerging orbital nerves in front of it and the swelling cochlea behind. Just where the latter concavity is seen, there the sub-basal cartilage swells out into a mammillate mass, which looks outwards and forwards, reaching three-fourths of the distance to the sphenoidal fissure. These solid masses, which look like the basipterygoids of a Lizard or Bird, are the chondrocranial form of the "tympanic wings;" when ossified, they become pneumatic.

The alisphenoids (*al.s.*) are very remarkable; their broadest part is proximal, but they dilate again at their outer, free edge, after becoming narrowed in by one-fourth at their middle. Their front margin, which helps to form the sphenoidal fissure, is concave, and their postero-external edge is cut away, so to speak, by the large pupiform cochleae (*chl.*), around which the posterior edge of the alisphenoid is carefully bound. The hind margin is a large right-angled notch; the outer edge is sinuous, rounded, and looks forwards and inwards; all this outer part is swollen, but perforated,

equidistantly, in two places, by the 2nd and 3rd branches of the 5th nerve, thus forming the foramen rotundum, and foramen ovale (V^2 , V^3). The thick semicircular inner margin of this outer lobulated part stands off from the main plate, and the whole of the outer part lies below, free of, and at a distance from, the orbitosphenoid, which it overlaps considerably. This very diagnostic Mammalian alisphenoid is followed, postero-externally, by a large fenestra, a space totally devoid of cartilage, but which is being filled up by the squamosal bone; it is the upper part of the tympanic space, and is traversed by the *ossicula auditûs*. Round it, like a bow, the orbitosphenoidal band (*o.s'*) is bent, passing, behind and above, into the supra-auditory cartilage (*s.a.c.*); below, this band forms the fore part of the tegmen tympani, and the incus articulates, by its short crus, at the junction of this lateral band with the auditory capsule. These capsules, in their basicranial setting, are very elegant structures; they stretch from the tympanic lobes of the basisphenoid, antero-internally, to the feebly-expressed paroccipital ridge, right and left, postero-externally. The cochleæ (*chl.*) show their three coils, and the fenestræ rotundæ (*f.r.*); these are very large, and well seen from below.

The fenestra vestibuli is closed by the stapes (*st.*), a small irregular ring of cartilage. Up to the passage for the 9th and 10th nerves (IX., X.) the capsule is very distinct from the chondrocranium, but in the mastoid region below the semicircular canals, and where the posterior canal is imbedded, there is more or less fusion of these parts. The very large relative size of the occipital arch reminds one, at once, of that of the *Echidna*; here the chondrocranium is as complete as in the Skate.

The notochord (*nc.*) is seen from below, up to the point where it rises into the post-clinoid wall (see fig. 3, *nc.*, *p.cl.*), in which the proper, primary axis of the animal ends, and beyond which everything is of the nature of an outgrowth.*

An elegant narrow waist is formed to the basis cranii by the pressure of the large cochleæ; behind this part the parachordal tract expands sinuously, and runs upwards into the side walls. The whole hind part is very smoothly rounded, and the condyles (*oc.c.*) are very flat, and have a sulcus across them; the foramen magnum (*f.m.*) is very large; the f. condyloideum (XII.) is small and far outwards, near the concave edge of the arch.

The upper view (Plate 25, fig. 3) shows the roof of the nasal labyrinth, with its long fore part, and its lateral lobular expansions right and left of the deep, multi-perforate rhinencephalic recess (*cr.p.*). The crested intertrabecula, at its junction with the hind part of the nasal roofs, above, shows a small crista galli (*cr.g.*); the wall below this part is thin above; it is the top of the perpendicular ethmoid (*p.e.*), which widens, gently, to pass into the presphenoid (*p.s.*). The narrow, backwardly-curved

* There are two ways of looking at the prochordal tracts of the skull—the trabeculæ and intertrabecula; some see in these parts a highly modified, *first* visceral arch; I confess that, at present, they merely seem to be *ongrowths* of the proper axis to finish the new, highly expanded fore part of the skull; made necessary, in the Vertebrata, by the great expansion, even in the lowest kinds, of the neural axis.

stems of the orbitosphenoids (*o.s.*) show their optic perforations (*II.*), close behind the outer margins of the cribriform plate; thence the cartilage expands rapidly, and curves over the sides of the roof as far inwards for some distance as the lateral ethmoidal lobes (*al.e.*); the line of union between these parts is still visible. Narrowing from before backwards, and bowing outwards, the cartilage runs so as to become, first, the supra-auditory (*s.a.c.*), and then the supraoccipital region (*s.o.*)

The neat, rounded selvedge of this cranial wall and roof (*tegmen cranii*) forms the outline of a huge cruciform upper fontanelle, through which, the membrane being removed, we see the floor of the cranial cavity. Much of what has been described in the lower view is seen here from its upper face, but the low postclinoid wall (*p.cl.*) and the large multiperforate meatus internus (*VII.*, *VIII.*) are only to be seen on this face. Also the general smoothness of the gently concave inner surface of the chondrocranium is to be noted, and, over the top, the manner in which the supra-auditory part of the *tegmen cranii* flanks the fore edge of the occipital roof (*s.o.*), a sulcus marking the distinct regions.

Fourth Stage (continued).—Visceral arches of the skull of an embryo Mole; $\frac{4}{5}$ inch long.

A somewhat more advanced embryo than the last yielded me a very important stage in the development of the visceral arches. The deep and the superficial jaw are shown in relation, with the hinge-piece (*incus*) attached to the fore part of the auditory capsule. In this inner view (*Plate 28, fig. 2*) the ampullæ of the anterior and horizontal canals (*a.s.c.*, *h.s.c.*) are laid bare, and the short crus of the *incus* (*i.*) is seen to be attached close in front of these parts of the membranous labyrinth; that process is very short and obliquely attached; and in this shortness and obliquity it shows an intermediate stage between the normal Mammalian *incus*, on one hand, and the curiously arrested *incus* of a *Monotreme*, on the other. The long crus, however, is well developed, and is articulated by its inturned discoidal end, with the head of the stapes (*st.*), the base of which is turned towards the eye. The malleal end of the deep mandible is well developed, and the fore-turned internal angular process lies in the centre of a thick cushion of soft stroma—the future *membrana tympani* (*m.ty.*). This is partly enclosed by a delicate lunule of bone, the *annulus tympanicus* (*a.ty.*). The posterior angular process of the malleus is almost suppressed. The main part of MECKEL'S rod (*mk.*) is evenly terete and sinuous, but it is largest near the head, and near the distal end; there it is continued into a median process, the *basimandibular* (*b.mn.*), into which both the rods end. The only bony matter in this primary mandible, as yet, is a short ring, or shaft, close behind the thick part, close to the median rod. Morphologically speaking, this is a hypobranchial bony segment. Outside all but the malleal portion there is, already, a well-formed superficial jaw, bony in front and cartilaginous behind, and having a groove, on its inside, between its condyloid and angular processes (*cd.p.*, *ag.p.*) for the descending Meckelian rod, the bony matter (*d.*) beginning to run up the unciform coronoid process (*c.p.*). Here, if there

were a coronoid bone, like that of a Reptile, this postero-superior part of the dentary would be distinct. The inner alveolar plate corresponds to the splenial bone; an angulare, a supra-angulare, or an articulare would have to be sought for on the malleal part of the deep or primary mandible.

The stapes (*st.*) was dislocated out of the fenestra ovalis in making this preparation. I did not figure the rest of the hyoid arch.

Fourth Stage (continued).—A series of vertically-transverse sections of the head of an embryo Mole, $\frac{3}{4}$ inch long from snout to root of tail.

During the time that the embryo of the Mole grows from 15 mm. to 18 mm., the tissues gain much increase of solidity; this is, indeed, the best stage for studying the structure and relations of the chondrocranium, and the superficial bony plates which it draws to itself for increase of strength.

The long snout (see Plate 25, figs. 2, 3) admits of being sectioned into a large number of slices; I have, however, only figured a moderate percentage of those that were made in this case (Plate 23, figs. 16–19), which was an embryo of the same size as that which was dissected to show the chondrocranium (Plate 25, figs. 2 and 3).

The *1st Section* (Plate 23, fig. 16) is in front of the outer nostrils; here the upper part of the section is the narrower; the lower is the narrow part further back. Here the septum nasi (*s.n.*) is perfect, and is dilated both above and below; the alæ (*al.n.*) are thick above, turn inwards below, and the thick growth below turns upwards. Part of the folded part below is so curled round as to appear in this section as a distinct segment.

2nd Section (Plate 23, fig. 17).—This is close to the nostrils, and the nasal passages are seen projecting outwards, right and left. The septum nasi (*s.n.*) is thinnest at this part, and here the alæ nasi (*al.n.*) turn inwards abruptly, whilst the folds that form the floor (*n.f.*) are reaching further upwards.

3rd Section (Plate 23, fig. 18).—Here the narial tubes are surrounded by cartilage, for the floor has reached the roof (*n.f.*, *al.n.*), and now the septum (*s.n.*) is very thick above, and of considerable thickness below the most dilated part.

4th Section (Plate 23, fig. 19).—Here the roof and floor are confluent at the sides, and in this section it is seen that the floor has turned inwards so as to project, laterally, by its proper end, into the nasal passage, the fold uniting with the dilated septum (*s.n.*)—or intertrabecula—by its upper face.

Here the mandibles are cut across in their fore part, and the basimandibular rod (*b.mn.*) unites the two Meckelian rods (*mk.*).

5th Section (Plate 23, fig. 20).—This is behind the snout, in the front part of the proper nasal labyrinth, which is now open below. Here the nasal septum is seen to be merely the round intertrabecula—like that of an embryo Bird—with the nasal roofs, however, united to it. The only remnant of the floor, so large and perfect in the

last section, is a retral tract of cartilage, convex on the inner face, where it touches the septum, and concave externally; this is the "recurrent cartilage" (*rc.c.*) developed for the support of JACOBSON'S organ. Here the upper lips are seen, and have a hollow palatine part between them; below, the Meckelian rods (*mk.*), are distinct in the mass of the lower jaw, over which the tip of the tongue is seen. The pulps of the whiskers (*vibrissæ*) are cut through in the outer thick skin.

6th Section (Plate 23, fig. 21).—Here the septum nasi is deeper, and the bulbous part less; the aliseptal folds (*al.sp.*) turn inwards below; the inturned part is the rudiment of the inferior turbinal. The recurrent cartilage (*rc.c.*) was tubular between this and the last section; but it is now open again to the end; here it has JACOBSON'S organ (*j.o.*) in its concavity. The pulp of an incisor is seen, and MECKEL'S cartilages are getting some distance apart.

7th Section (Plate 23, fig. 22).—This is a remarkable section, and very instructive. It is behind JACOBSON'S organs and cartilages, and is seen to be girdled with bony tracts—the nasals (*n.*) and maxillaries (*mx.*), with their palatine plates; the base of the deep septum (*s.n.*) also is supported by the main vomer (*v.*). The septum becomes thin above, as it passes into the broad and solid nasal roof (*al.sp.*), which is convex right and left and in the middle. The wall as it becomes floor turns inwards to form the pedate rudiment of the inferior turbinal, which projects upwards so as to lessen the nasal passage below. Below each shallow valley on the roof, a large lamina of cartilage grows downwards and a little outwards, dividing the nasal passage into a larger inner, and a lesser outer, space, both subvertical and somewhat pinched in at the middle.

This is the "nasal turbinal" (*n.tb.*), which for a short distance, fore and aft, and *for a short time* during development, forms a complete secondary nasal septum on each side of the septum proper (*s.n.*).

8th Section (Plate 23, fig. 23).—This is immediately in front of the olfactory fossæ, and through the fore part of the eye-balls (*e.*); this is the widest part of the complete nasal labyrinth. The septum is now perpendicular ethmoid (*p.e.*), and the roof is in the aliethmoidal region. The maxillary (*mx.*) is cut through close in front of the orbit, and again in the palatal region, right and left of which there is a tooth-pulp (*t.*). The vomer (*v.*) is cut through its middle, and over it the deep septum (*p.e.*) thickens twice; it also grows so as to lift the roof over it into a low rounded ridge. Inside, near the septum, and at the upper part of the wall, there are small rudiments of the upper turbinal folds (*u.tb.*), and half way down the wall grows inwards as a large mass of cartilage, pedate in section; this is the common rudiment of the middle turbinal folds (*m.tb.*). The floor is cut through behind the inferior (properly *anterior*) turbinal, it ends far from the mid-line. Below, the dentary (*d.*) is cut through; over it, outside, is a tooth-pulp, and further inwards MECKEL'S cartilage (*mk.*); the tongue (*tg.*) is now developing its *frænum*. The palatine plate of the palatine begins to be seen in section.

9th Section (Plate 23, fig. 24).—The olfactory lobes (*C^{1b}*) are cut through the

middle in this section, and also the eye-balls (*e*). Here we have apparently an open floor to the brain, which is the roof to the nasal labyrinth, for the cribriform plate is not yet chondrified. The solid septum (*p.e.*) is still convex in two places, it stands quite by itself in the section, for the lateral ethmoidal structures at this part, are far from it, right and left; it is supported, below, by the vomer. There is still a small upper turbinal rudiment, and the middle turbinal (*m.tb.*) is in two folds; the floor is strong, it is still at a great distance from the mid-line. Over the eye (*e.*) the frontal (*f.*) is seen, and the maxillary palatine plates, those of the palatines, and the jugal bones (*pa., j.*) are seen in the roof and sides of the mouth. The tongue (*tg.*) is cut through its middle; and the lower jaw is seen as a cruciform section of the dentary (*d.*) holding a tooth-pulp (*t.*) above, and MECKEL's cartilage (*mk.*) below.

10th Section (Plate 23, fig. 25).—The cribriform plate (*cr.p.*) is here a large membranous tract, right and left, hollow above and convex below.

The perpendicular ethmoid (*p.e.*) has lost one-third of its height, and is much thinner above; the floor (*n.f.*) has now reached it, and each plate articulates with its bulbous base. The wall and the last fold of the middle turbinal (*m.tb.*) are thick plates, free above, and having their concave faces looking towards each other; the nasal canal is thus subdivided into two passages, the outer oval, and the inner unciform, in section. Another cartilage has appeared above the low wall, and at a short distance from it; this is the orbitosphenoid (*o.s.*); it is thicker below than above, and convex outside; at a small distance outside it a much larger part of solid tissue is cut through, this is the frontal (*f.*), which, however, only forms a wall—not a roof—to the huge hemisphere (*C^{1a}*). The vomer (*v.*) is still seen in section, and the palatines (*pa.*), with it, almost complete the fence round the bilobate nasopalatine passage. Below, the dentary (*d.*) is thickening over MECKEL's cartilage (*mk.*).

11th Section (Plate 24, fig. 1).—This section is through the hind part of the nasal labyrinth, and the nasal passage (*n.p.*), right and left, is single, large, and heart-shaped. This is the last section through the membranous cribriform plate (*cr.p.*), and the perpendicular ethmoid (*p.e.*) is but little above half its original height; the nasal wall, being cut through obliquely to its plane, looks extremely thick. The ascending floor is still articulated with the bulbous middle wall. Here the orbitosphenoid (*o.s.*) is larger, and is sharp both above and below; it almost reaches the nasal wall. The frontals (*f.*), the palatine (*p.*), and the forks of the vomer (*v.*) are seen in section; also MECKEL's cartilage (*mk.*), and the dentary (*d.*) below.

12th Section (Plate 24, fig. 3).—This and the next section have been accidentally transposed: the back wall of the nasal labyrinth is here seen and the fore part of the Gasserian ganglion (*V.*).

This part shows a very deep orbitosphenoid (*o.s.*), resting by its thick base upon a cartilaginous fold growing out from the back of the nasal labyrinth; although the orbitosphenoid (*o.s.*) was cut through, the small optic foramen was caught in this section. The presphenoid (*p.s.*) is almost trilobate, and is composed of the

three trabecular bars—the trabeculæ right and left, and the intertrabecula above. the fore edge of the alisphenoid is not yet reached, but the fore part of the Gasserian ganglion (V.) is shown. On the side of the wide, oblong nasopalatine canal (*n.p.*) the pterygoid bone and cartilage (*pg.*, *pg.c.*) are cut across, and below we have still the dentary with MECKEL'S cartilage (*mk.*), and also with the superficial cartilage that forms the condyloid and angular regions; the ceratohyals (*c.hy.*) are also seen in this section.

13th Section (Plate 24, fig. 2).—This partial section shows the orbitosphenoid (*o.s.*) in two parts, the postero-superior band, and the hind margin of the stem; the basal part (*p.s.*) is fusiform. Below the stem of the orbitosphenoid, at a considerable distance, the alisphenoid (*al.s.*) is seen as a thickish plate, curved downwards, and beaded at its outer edge. Its concavity makes a nest for the large Gasserian ganglion (V.), which is protected above by the orbitosphenoid. Two thick rods of cartilage are cut through between the alisphenoids, one on each side of the broad nasopalatine passage, they turn inwards and downwards, and are capped with a film of bone above, these are the pterygoid cartilages, with the growing pterygoid bones (see fig. 3). Below we see the mandible as one large folded tract of bone (*d.*) embracing three cartilages; the middle of these is the Meckelian rod (*mk.*), the others are the condyloid and angular parts of the superficial slab. Below the oral cavity (*m.*) the ceratohyals (*c.hy.*) are seen.

14th Section (Plate 23, fig. 4).—Here the same parts are better seen, than in the last, in a more symmetrical figure.

15th Section (Plate 24, fig. 5).—Here only the posterior band of the orbitosphenoid (*o.s'.*) is seen, for the basal part (*b.s.*) now runs into the alisphenoid (*al.s.*), which is cut through proximally, at its postero-external angle. The Gasserian ganglion (V.) still lies on it, at its proximal part, the cartilage dipping considerably to form a nest for it. Here the basisphenoid (*b.s.*) is formed of the outspread and coalesced trabeculæ, this part being somewhat in front of the pituitary space. The squamosal (*sq.*) is seen outside the angle of the alisphenoid, and MECKEL'S cartilage (*mk.*), the latter, the end of the angular, and part of the articular cartilage (*mn.*), are also cut across.

There are three cavities laid open, namely, the nasopalatine (*n.p.c.*), the mouth (*m.*), and the larynx (*lx.*); the Eustachian tubes are also laid open in their inner half, continuously with the nasopalatine passages. Besides the cartilage of the larynx, the epihyal, and hypohyal (*c.hy.*, *h.hy.*), are cut through.

16th Section (Plate 25, fig. 6).—This is from a little further backwards than the last, and takes in part of the meatus auditorius externus, with its lining cartilage (*m.a.c.*). This partial section is below the orbitosphenoidal band, and behind most of the alisphenoid (*al.s.*); outside the proximal part of that wing, which is cut through below the Gasserian ganglion (V.), MECKEL'S cartilage (*mk.*) is seen high in position, and large in size. The Eustachian tubes (*eu.*) are laid further open than in the last

section, and besides the hyoid rods (*e.hy.*, *h.hy.*), the thyroid cartilage, as well as the arytnoids (*lx.*) are cut across.

17th Section (Plate 24, fig. 7).—This section is through the basisphenoid (*b.s.*), close behind the edge of the alisphenoid (*al.s.*), which, however, is caught further outwards, still bearing the Gasserian ganglion (*V.*). The hinder edge of the soft palate is cut through, and the nasopalatine canal (*n.p.c.*) is nearly continuous here with the mouth (*m.*). Besides the hyoid and cartilages (*e.hy.*, *h.hy.*), and the larynx (*lx.*), the upper tracheal rings are seen in section. The tympanic cavity (*c.ty.*) is laid open, and also the inner part of the Eustachian tube (*eu.*); here the meatus cartilage (*m.c.*) is thick. MECKEL's cartilage is now thick: it is the fore part of the head of the malleus (*ml.*) that is seen at this point; above it a small tract of the tegmen tympani (*t.ty.*) is also brought into view; outside these cartilages the squamosal is shown.

18th Section (Plate 24, fig. 8).—This section is behind the alisphenoid and through the ganglion geniculatum (*VII.*, *VIII.*); also, besides a small piece of the tegmen tympani, the fore part of the cochlea (*chl.*) is cut across. In this and the last section the basisphenoid (*b.o.*)* is concave below, this is because the mammillary processes that form the foundation of the "tympanic wings" are cut through (Plate 25, fig. 2, *b.s.*). In the hollow we see the large faucial passage (*phx.*), which opens into the larynx (*lx.*). The laryngeal and tracheal cartilages are similar to those of the last section, and so are the hyoid (*e.hy.*, *h.hy.*); beneath the epihyal, the chorda tympanic nerve (*VII^a.*) is seen in section. Inside the squamosal, and under the tegmen tympani, the whole head of the malleus, with its manubrium, is shown; the latter pushing the membrana tympani before it; this is behind the Eustachian tube.

19th Section (Plate 24, fig. 9).—This section of the cranial basin is oblique and may serve as two; the *right* side is from a point in front of the *left*; and from the somewhat sinuous direction taken by the razor, some things on the left side belong to points in front of the parts shown in the last (fig. 8).

The orbitosphenoidal band and part of the parietal (*o.s'*, *p.*) are cut across, above; whilst the squamosal (*sq.*) and the meatus (*m.a.c.*) are seen lower down. Here, again, the head of the malleus (*ml.*) is seen in its whole extent, capped by the tegmen tympani, and with its manubrium pushing inwards the membrana tympani. Over the malleus, the ganglion geniculatum (*VII.*, *VIII.*) is seen, and under the tympanic cavity (*c.ty.*) the ceratohyal (*ch.hy.*). On that side the cochlea (*chl.*) is just laid open, on the other it is cut across its middle. Between the two, the basisphenoid (*b.o.*)† has become thicker and narrower, and it is still concave below; it carries, here, the pituitary body (*py.*). The obliquity of the section is shown by the form of the upper part of the fauces (*phx.*) below the basis cranii.

The left side is very instructive, for it shows the other elements of the ear-chain behind the malleus. This is the front view of the section, and thin as it is, the

* The letters of reference in this and the next figure should be *b.s.*

† The letters of reference should have been *b.s.*

incus (*i.*),* is seen to be nearer to the eye than the stapes, the fore margin of which lay somewhat back. Here part of both the parietal and squamosal (*p.*, *sq.*) are shown and also the orbitosphenoidal band, now the supra-auditory, where it rests upon the crest of the auditory capsule. Below that crest the thick outer edge of the capsule is seen forming the tegmen tympani (*t.ty.*) under which the body of the incus (*i.*) is shown, *in front of the stapes*. The canal for the facial nerve (VII.), is cut through, outside the cochlea (*chl.*), and under the cochlea part of the vestibule is laid open just at the fore end of the fenestra ovalis. Under the incus (*i.*) a small cavity is seen, this is the hind part of the tympanic cavity which is very small even further forwards; there is very much soft tissue filling in the spaces here. Under the auditory capsule, on the outside, the epihyal is seen (see also Plate 25, fig. 2, *e.hy.*), and to it is articulated the top of the ceratohyal (*e.hy.*).†

20th Section (Plate 24, fig. 10).—The description just given may serve for the next section, but this being a little further back the hole in the stapes (*st.*) has been reached. In this the facial nerve (VII.) was found in two places, besides the one above, owing to the curve it takes in its course. The cochlea is most open on the left side, and on the right it is cut through at its proximal part, and the vestibule is opened through the fenestra ovalis.

21st Section (Plate 24, fig. 11).—This next oblique section shows the malleus (*ml.*) on the right side, behind its manubrium; below it is the tympani cavity (*c.ty.*) and the facial nerve and geniculate ganglion (VII., VIII.) are seen above it. There is still a considerable space between the auditory capsule (*chl.*), and the thick oblong section of the basis cranii, now the basioccipital (*b.o.*). The hyoid bar (*e.hy.*) is cut through obliquely, and under it the facial part of the seventh nerve (VII.) is shown. On the left side the supra-auditory cartilage (*s.a.c.*) is continuous with the capsule, and so also is the basioccipital plate (*b.o.*). Here the razor passed through the meatus internus (VIII.), and the fenestra ovalis; in the latter the stapes (*st.*) is shown exactly through its middle, with the stapedial artery (*st.a.*) threading it. The top of the epihyal only is shown at the back of the tegmen (*t.ty.*), just where the short crus of the incus is articulated. Under the stapes a small cavity is seen, part of the tympanic (*c.ty.*).

22nd Section (Plate 24, fig. 12).—This also is oblique, but is two or three sections further back than that shown on the last figure. Here the right side shows the stapes (*st.*) cut across with the stapedial artery (*st.a.*) threading it; here, however, we get a section of the auditory capsule showing both the fenestræ, the oval and the round (*fs.o.*, *f.r.*), and this also shows the meatus internus (VIII.). The tegmen tympani (*t.ty.*)‡ is deeper here, and the inner edge of the capsule (*chl.*) is seen to come down upon the basal plate (*b.o.*) to unite with it. This plate is fusiform in section and has the basilar artery (*b.a.*) upon it, and the notochord (*n.c.*) grooving its lower

* The line of reference in this figure is too short and does not reach the incus.

† In this figure for *i* read *chy.*, and for *e.hy.* read *c.hy.*

‡ The line of reference passes downwards instead of across.

face; the plate passes directly into the cartilage of the capsule on the left side. There the vestibule (*vb.*) is laid open and the horizontal canal (*h.s.c.*) is exposed.

23rd Section (Plate 24, fig. 13).—This is only a little more than half the floor of the skull. The supra-auditory cartilage (*s.a.c.*) is now passing into the supraoccipital, and is again free from the capsule. The horizontal canal (*h.s.c.*) is cut across its arch, the posterior canal (*p.s.c.*) through its ampulla, and the anterior canal (*a.s.c.*), above. The large space between the capsule and the basal plate allows the 9th and 10th nerves (IX., X.) to pass, and the large size, and the thick edges of the basal plate (*b.o.*) is due to the fact that the condyles are cut across. The notochord (*n.c.*) is now directly beneath the basilar artery (*b.a.*); it is seen again in the *attached* wedge of the *axis* (*ax.*); the condyles of the *atlas* (*at.*) are also seen.

24th Section (Plate 24, fig. 13).—The basilar plate and condyles (*oc.c.*) are cut across in this section in the fore part of the foramen magnum. The roof-cartilage (*s.a.c.*) lies upon the auditory capsule. This latter shows inside it the hinder part of the horizontal canal, and the neck of the posterior canal (*p.s.c.*) close to the ampulla. In this, as in the last, the cartilage is very solid above and behind the canals.

The 1st, 2nd, and 3rd vertebræ (*at.*, *ax.*, and below it, a small nucleus), are partly shown.

Fifth Stage.—Dissection of the lower face and throat of an embryo Mole; 1 inch long.

There is very little difference between these parts in an embryo an inch long and the same in one four-fifths of an inch (Plate 28, figs. 3 and 2). But in the larger embryo I was able to get a side view of the stapes (*st.*). It is shown in the figure dislocated from the incus (*i.*), and thus the triangular form and the round hole are shown. The incus also has its discoid articular facet for the stapes turned towards the eye. The facial nerve (VII.) is seen in its canal, and in front of it the epihyal (*c.hy.*)* is seen to be confluent with the auditory capsule (*au.*), but only connected with the ceratohyal (*c.hy.*) by ligamentous fibres. The extremely thick and soft membrana tympani (*m.ty.*) is just beginning to have an osseous deposit in its rim, and its fibres radiate from the front of the manubrium mallei (*mb.*). The distal ossification on MECKEL'S cartilage (*mk.*) is elongating, and the dentary bone (*d.*) is creeping up the coronoid and condyloid processes of the superficial cartilage (*c.p.*, *cd.p.*). There is no malleal ectostosis, at present.

Sixth Stage.—Dissection of lower face and throat in an embryo Mole; 1½ inch long.

In an embryo a little more advanced than the last there are several things in the facial arches worthy of notice. The superficial mandible (Plate 28, fig. 4) has not only increased its bony matter, but the cartilage has become much more solid and in larger quantity; the middle process ending in the condyle (*cd.p.*), especially, is a thick rounded mass; the glenoid cartilage (*gl.c.*) is seen capping the condyle. The hypo-branchial element of the arch—the distal Meckelian ossification—is now larger, and

* In the letters of reference the hinder *c.hy.* should have been *e.hy.*

under the proximal part of this rod, where the malleal enlargement is, there is a small ectosteal tract; the future bony centre of the malleus. Also in the thick soft outer disk of the tympanum there is a crescentic deposit of bone—the annulus. In this, as in the rest, the short crus of the incus (*i.*) is small and bent downwards; its *symplectic* facet, the orbicular region of the long crus, is shown with the outline of the base of the stapes (*st.*) round it; this is the inner view of these parts. The epihyal (*e.hy.*) is drawn as cut away from the auditory capsule; its lower end is connected with the pointed top of the ceratohyal (*c.hy.*), the long upper piece of which is beginning to ossify; the lower piece (*c.hy'*.) is no longer than the hypohyal (*h.hy.*), which is thick and curved. The basi-thyrohyal piece (*b.h.br.*, *t.hy.*) is thick and roughly U-shaped, with its angles squarish.

Seventh Stage.—*A similar dissection to the last of an older embryo Mole; 1½ inch long.*

This *fifth* inner view of the visceral arches (Plate 28, fig. 5.) shows another sign of advanced growth; the distal ossification of MECKEL's cartilage is almost surrounded by a *splénial* growth of the dentary (*d.*), forming the inner face of the mandible. The dentary is also growing well round the thick tract that ends, above and behind, in the condyloid process (*cd.p.*); this is capped by the glenoidal tract (*gl.c.*), a part derived from the same superficial source. The soft disk round the membrana tympani (*m.ty.*) is a more developed crescent of bone—the annulus (*a.ty.*). The head, both of the malleus and incus (*ml.*, *i.*), is smooth and rounded, and in each case has a very *condyloid* appearance; the stapes (*st.*) is detached from the orbicular facet of the incus (*i.*); it is a stout cartilage, with a small circular hole, a distinct neck below its incudal head and facet, and a thick rim to its base, or proximal plate. I see no interhyal (= intra-stapedial) nucleus of cartilage in the tendon of the stapedius muscle (*st.m.*).

Eighth Stage.—*Vertical longitudinal section of the head of a ripe embryo Mole; 1⅔ inch long from snout to root of tail.*

In this preparation the interior of the right half of the skull was displayed with the whole of the ethmoseptal part of the cranial axis.

The figure (Plate 25, fig. 1) will help to a proper understanding of the skull in its earlier stages, both the sections and the dissections (Plates 23–25). The endocranium is now undergoing ossification. The nasal region, from the back of the cribriform plate to the front of the snout, is exactly of the same length as the cranium, measured from the former point to the top of the foramen magnum. The great internasal septum (*s.n.*, *p.e.*) is twice as high behind, at the crista galli (*cr.g.*), than in front, between the nostrils; the dorsal line of this wall is sinuous; its lower edge is gently concave; behind the presphenoidal region (*p.s.*), the lower line of the skull is gently convex.

Between the nostrils, the floor and wall together form a sinuous tract; behind this part the calinasal artilage gives off the recurrent (or JACOBSON's) cartilage, right and left (*rc.c.*). The great intertrabecular bar thickens the septum all along, giving its

sections a bulbous form, below. The cartilaginous crista galli (*cr.g.*) is a mere retral point of the great septum; below that point the outline is concave, and between the large cartilaginous cribriform plates (*cr.p.*), it rises up at the meeting of the presphenoidal region with the perpendicular ethmoid.

From the middle of the presphenoidal tract (*p.s.*), to the foramen magnum, the skull is drawn as cut along the mid-line; the front part is left entire. Right of the presphenoidal, the orbitosphenoid (*o.s.*) is seen helping to wall in the orbital region; its stem is ossified, and near the hind margin of the bony tract the small optic foramen (II.) can be seen. Above the bone the stem broadens suddenly into an axe-blade of cartilage, which reaches to the top of the skull in front, and also to the top of the side wall, further back.

Then from the hind margin of the stem to the middle of the auditory capsule there is an elegant archway of cartilage nearly equal to the orbitosphenoidal stem in width. Over the junction of this arched band with the auditory capsule the cartilage—supra-auditory (*s.a.c.*)—more than equals the great blade of the orbitosphenoid in size. In reality it is twice as large, but the hinder two-fifths of this large crescentic crest is ossified as the supraoccipital (*s.o.*). The roughly oval space below the orbitosphenoidal archway is filled up, *in its antero-inferior third*, by a small ruptured and out-turned part of the side wall—the alisphenoid (*al.s.*); the angle between this auriform flap and the cochlea (*chl.*) is filled by the huge Gasserian ganglion (V.).

The upper two-fifths of the space under the archway is void of cartilage, and is finished by the investing bones—frontal, parietal, and squamosal. There is no presphenoidal bone; the orbitosphenoids will meet to finish that region; the basisphenoid (*b.s.*) is already present as a short tract in the middle of its own region. The small lobulate alisphenoid is not ossified, it has two large foramina near its upper part, the *f. ovale* (V³.) and the *f. rotundum* (V².). The auditory capsule is relatively very large and extremely oblique in position; it stretches from the hind margin of the alisphenoid upwards and backwards to the lower edge of the supra-occipital. The large archway for the 7th and 8th nerves (VII., VIII.)—the meatus internus—is very near the great orbitosphenoidal archway, where it becomes supra-auditory. The pupiform cochlea (*chl.*) lies in a clearly-margined space, right and left of which the basioccipital and basisphenoidal regions meet. The anterior canal (*a.s.c.*) has its crown looking backwards as much as upwards; it arches over a considerable fossa for the flocculus cerebelli; it is arched over by a very elegant crescentic channel for the lateral sinus, which makes the cartilaginous crest very thin at that part. The gap (foramen lacerum posterius) for the 9th and 10th nerves (IX., X.) is large, and the small hypoglossal foramen (XII.) is seen close behind it in the occipital arch. Above that hole the exoccipital bony centre (*e.o.*) is seen to occupy about a third of the side of the arch, between the supra- and basioccipital centres (*s.o.*, *b.o.*); the latter is a large lozenge-shaped tract.

Various investing bones are seen *in situ*, namely, the nasal, frontal, parietal, inter-

parietal, squamosal, part of premaxillary, maxillary, palatine, and vomer (Plate 25, fig. 1, *n.*, *f.*, *p.*, *i.p.*, *sq.*, *pp.x.*, *mx.*, *pa.*, *v.*).

Ninth Stage.—Dissections of the skull of young Moles, 3 or 4 days old;
 $1\frac{3}{4}$ and $1\frac{4}{5}$ inch long.

Dissections of the skull of the larger of these young ($1\frac{4}{5}$ inch long) serve to interpret the adult skull as well as any of the stages.

The form of the skull is wedge-shaped (Plate 26), the widest part being very near the end, and the whole skull structure narrowing forwards to the growing snout. Seen from above (Plate 26, fig. 1), the normal investing bones are shown to increase in size from before backwards, very remarkably. The oblong nasals (*n.*) are of considerable width, but they are not so long as the uncovered snout in front of them; they are flanked by the premaxillaries and maxillaries (*mx.*, *px.*). The small convex frontals (*f.*) added to these six bones of the face do not cover so large a surface as the two parietals (*p.*); which, together, form half a large ellipse.

A considerable fontanelle (*fo.*) still exists along and across the skull in the frontal, coronal, sagittal, and lambdoidal regions; the last of these is the largest space, but it is partly filled up, behind, by a small semi-annulus of bone—the interparietal (*i.p.*). Looked at from the side (Plate 26, fig. 3), other splint-bones come into view. In this view the premaxillary (*px.*) is seen to have considerable facial tract, interdigitating with the maxillary (*mx.*) and reaching up to the nasal (*n.*). The maxillary is notched by the frontal (*f.*) and has the small heart-shaped lachrymal (*l.*) set into its orbital edge, where, also, the canal (*l.c.*) is seen just on the outer margin of the orbit. The canal for the 2nd branch of the trigeminal nerve (V^2) is not finished, and behind and below the groove, first the jugal (*j.*) is seen as a small style, followed by the styloid jugal process of the small, oblique, multilobate squamosal (*sq.*). That bone is very peculiar in this small wedge-shaped skull, which is bent downwards, behind, at a considerable angle; nearly all the hinder half of the skull is unprotected by superficial bones, and the squamosal, thereby, forms a small adherent scale on its antero-inferior surface. Scarcely reaching the lower edge of the parietal in front, it recedes, downwards, from that bone, leaving a large triangle of the endocranium bare; it is marked off into two regions, one in front and above, narrow and forked, and the other behind and below, wide and semi-ovate.

The broad upper tract in front of the proper squamous part has a sharp point, the jugal process, which overlies the jugal bone (*j.*); under this fore part we see the glenoid cavity (*gl.c.*). The lower and hinder lobe reaches by its rounded end nearly to the stylomastoid foramen (VII.) and quite to the ampulla of the anterior and horizontal canals of the ear (*a.s.c.*, *h.s.c.*). The lower edge, rising forwards, forms the eave of the tegmen tympani; under it is seen another superficial bone, the annulus tympanicus (*a.ty.*), better seen from below (fig. 2). The frontal (*f.*), half the size of

the parietal (*p.*), shows the foramen for the ophthalmic nerve (*V¹*.) on its lower margin; its orbital plate leaves much of the endocranium (*o.s.*) naked; it shows no signs of distinctness from the roof-plate of the bone, such as is seen in the Hedgehog.

The parietal is a fine shell of bone, and is the largest in the skull. The frontal and parietal clamp each other mutually in the postorbital region, but the latter imbricates itself on the frontal in the coronoid region; from the top of that suture to the top of the lambdoidal, the convex dorsal outline of the bone forms a large and accurate arc.

The compound superficial mandible (*d.*) is almost perfect, but the coronoid, condyloid, and angular processes (*c.p.*, *cd.p.*, *ag.p.*) are still cartilaginous; they are rounded and sub-equal.

In the lower view (Plate 26, fig. 2) the surface is only invested with superficial bones in the narrow palatine region; the occipital, and most of the sphenoidal, regions are left bare.

Each premaxillary, carrying three teeth, is well developed, but the palatine processes (*p.px.*) are largely hidden by those of the maxillaries (*mx.*; see fig. 5); the antero-lateral vomers, also, are not seen, they have a very temporary and doubtful existence independent of these processes of the premaxillaries. The vomer (*v.*), also, is only partly seen, but is really very large and typical (fig. 5, *v.*), being wide, carinate, pointed in front and forked behind, and has a semidistinct postero-lateral vomer (*v''*.) attached to the outside of each fork.

The hard palate is well developed, three-fifths of it belongs to the maxillaries (*mx.*) and the rest to the palatines (*pa.*), which have their palatal plate very large, perfect, and typical; yet the fore part of the median suture even of these bones is imperfect, and the vomer (*v.*) is partly exposed; the maxillaries meet each other nowhere, at present. The hinder and upper part of each palatine is a thick lobe of bone turned outwards, behind, and bevelled on its inner face for the pterygoid bone (*pg.*). A club-shaped cartilage adheres to the inferior surface of this small bone, the pointed end is in front and the clubbed end is turned outwards, behind; this is the pterygoid cartilage (*pg.c.*), and is a genuine remnant of the endoskeletal upper jaw of a branchiate type. The broad hind skull is seen from this aspect, flanked and supported by the infero-lateral squamosals (*sq.*); the annuli (*a.ty.*) are seen as U-shaped bones—right and left—with their crura looking outwards and backwards, and their arch almost touching the pretympanic boss of the basisphenoid. These are all the investing bones that I can discover at this stage.

The endocranium may now be described. I shall begin with the *palatal* (or basal) part first (Plate 26, fig. 5). Looked at, as a whole, this is a very solid cartilaginous structure, here and there undergoing ossification. The snout (*al.n.*) with its inferior external nostrils (*e.n.*) has a length about a fourth greater than its breadth; it is quite a continuous structure. The snout passes into the proper nasal labyrinth, not only above and at the sides, but the floor, also, sends backwards a remarkable tongue-like process—the recurrent or JACOBSON'S cartilage (*rc.c.*). This tract, right and left, is

very large in the Mole, and is half the length of the proper labyrinth, reaching backwards almost as far as the inferior turbinals (*i.tb.*), here largely hidden by the inturned nasal wall (*al.sp.*).

The tubular part of the recurrent cartilage is short; the rest is convex below and outside, and concave on the other face, where it is in relation to JACOBSON'S organ. In front of the terminal point of these processes the labyrinth expands rapidly right and left, and these moieties are then to be seen a pair of swollen cushion-shaped masses, that first bend outwards and then converge towards each other, having only the basal beam between them. Where that beam escapes from the vomer it is the perpendicular ethmoid (*p.e.*); a little further back it is the presphenoid (*p.s.*), and has the stem of each ala, or orbitosphenoid (*o.s.*) ossified; thence, to the top of the skull, these rapidly widening wings are cartilaginous. The posterior sphenoid is a very remarkable structure; it is ossified in its median or basal part only, at present; the anterior sphenoid does not develop a median piece, but the basal beam receives its bony growth from the ossifying alæ.

The basal region of the posterior sphenoid is at present ossified for about three-fifths of its length; this centre (*b.s.*) is very broad, and is alate in front; it is not a mere ossified basal beam, for whilst the anterior sphenoid forms its base from its alæ, the posterior sends its basal bony centre far into the proximal part of its wings—right and left. Outside the hinder half of the basisphenoid, where it has narrowed in so as to occupy but little more than the proper base (trabecular roots arising from parachordals) there, right and left, we see a large rounded boss of cartilage just in front of each cochlea (*chl.*). This swelling part, or process (*lg.*), at the junction of the ala with the base, is homologous with the cartilaginous “lingula” seen in the embryos of Crocodiles and Birds (Trans. Zool. Soc., vol. ii., part 9, plate 64; and Phil. Trans., 1869, Plate 82). It becomes ossified very variously in these different types, but its meaning is the same in all. It is the root of an enlargement for the tympanic cavity—the posterior sphenoid becoming pneumatic. Behind these bosses the basal part has an elegant “waist” and then broadens into large “hips,” on which the cochleæ (*chl.*) rest.

The alisphenoids (*al.s.*) are still unossified; they have a very broad proximal part, even beyond the cartilaginous bosses and the alæ of the basisphenoidal centre; they expand so as to grow round the pupiform cochleæ, and then are so notched behind as to leave a large oval space between their hind margin and the outer part of the auditory capsule (*chl.*). In front of this lateral fontanelle (or fenestra) each alisphenoid (*al.s.*) forms an ear-shaped free lobe, looking inwards and forwards; this lobe is bi-perforate for the 2nd and 3rd branches of the 5th nerve (V^2 , V^3).

There is a cartilaginous tract between the new basisphenoidal and basioccipital centres (*b.s.*, *b.o.*) equal in size to each of these bones; the hinder centre (*b.o.*) is peculiarly reptilian, being at present polygonal, and broader than it is long. The chondrocranium is huge in this part of the head; from the waist-like synchondrosis

the basal region swells out into broad hips which end, behind, in the slightly convex but very large condyles (*oc.c.*); these are wedge-shaped and have a sulcus across them at their front third, they are almost pointed behind, when they reach nearly to the end of the enormous foramen magnum (*f.m.*), the fore part of which is a semicircle, whilst the hind part widens out irregularly. The fore margin of each condyle is gently emarginate.

The hinder or opisthotic region of each large auditory capsule is completely confluent with the corresponding side of the occipital arch; the paroccipital region is a mere gentle convexity. The exoccipitals (*e.o.*) can be seen outside the condyles as narrow tracts of endosteal bone; the supraoccipital (*s.o.*) reaches the top of the foramen magnum.

Outside the front part of the condyle (*oc.c.*), the condyloid foramen (XII.) is seen, the 9th and 10th nerves (IX., X.) are seen in the distinct foramen lacerum posterius, and the facial nerve (VII.) is visible in this view, emerging from the f. stylomastoideum, behind the epihyal (*e.hy.*). The uppermost part of the hyoid arch—the stapes (*st.*)—is shown, *in situ*, on the right side of the figure, and the incus and malleus, with a part of MECKEL'S cartilage (*i., ml., mk.*) on the other side. The "otic process" or short crus of the incus or quadrate—a *secondary retral* part of the suspensorium of the mandible in the Ovipara, and which in them often reaches beyond the auditory capsule to join the occipital arch—is here seen to be in front of the semicircular canals. Both the mandibular elements of the ear-chain lie, now, in a large vacuity of the chondrocranium, which is caused by the curious non-development of the alisphenoid at that part. All round the pupiform cochlea (*chl.*) the line of separation of the capsules and chondrocranium, proper, is perfect; and again, on the outside, the opening into the lateral sinus (*l.s.*) marks off the epiotic region from the supraoccipital cartilage; but in front of the sinus-opening, laterally (fig. 3), and along the paroccipital region (fig. 5), the confluence of the two structures has been complete. The fenestra ovalis is filled by the stapes (*st.*), the fenestra rotunda (*f.r.*) is seen on both sides.

In the *lateral* view (fig. 3), the supraoccipital, supra-auditory, and posterior orbitosphenoidal tracts of cartilage (*s.o., s.a.c., o.s.*), are seen to be confluent, and the whole hind part of the skull, strongly bent downwards, is composed either of cartilage or of cartilage-bone (endostosis). Over the foramen magnum the supraoccipital is large, both high and wide, and the exoccipital (*e.o.*), is seen to be wider than the lower view would indicate. There is no appearance of bone in the auditory capsule, except over the front part of the anterior canal (*a.s.c.*), and the sinus-opening; the labyrinthine part of the capsule is still cartilaginous. The oblique oblongo-crescentic tract of bone seen, already, in the *sphenotic and pterotic* regions, is the *first of the two* bony *periotics* formed in the auditory capsule in this type; notwithstanding its growth along the crest of the capsule, and the fact that it does not help to enclose the labyrinth, I consider it to be the "prootic," and the other, formed afterwards, the "opisthotic."

The tilting of the canal-region of the capsule is well shown in the side view; the fore part of the large anterior canal (*a.s.c.*) leans backwards, under the prootic bone (*pr.o.*), at a right angle to the squamosal bone; its hinder half, below the sinus-canal is parallel with the outer edge of the occipital roof. The posterior canal (*p.s.c.*), which joins the anterior, is parallel with the general direction of the occipital condyle, and the horizontal canal (*h.s.c.*) runs downwards and backwards, from the end of the squamosal to the exit of the facial nerve (*VII.*).

But for the ossifications of the hind skull, and the continuation of the nasal roof cartilages to the end of the intertrabecular beam—a peculiarly valuable Mammalian diagnostic—the *upper view* of the skull (fig. 4) might have seemed to belong to a *Skate*. There is a large membranous fontanelle (*fo.*), but it is well surrounded by solid hyaline cartilage, and in several places the “tegmen cranii,” or cartilaginous roof is well developed.

The large and long nasal labyrinth is practically divisible into three regions, namely, the snout, or alinasal (*al.n.*); the middle region with the nasal and inferior turbinals, and, like the snout, supplied from the 5th nerve only (*al.sp.*); and the true olfactory region, containing the upper and middle turbinals—the aliethmoidal region (*al.e.*). The fluted roof becomes concave near the end, and then terminates abruptly, in an almost transverse line, at the middle of which there is a small projection—the crista galli (*cr.g.*). The wide, lateral, olfactory regions, with their hill-and-valley markings, reach backwards, right and left, beyond the end of the roof; the oblique postero-internal margin is confluent with the front of the tegmen tympani, a part which is continuous with the orbitosphenoid (*o.s.*). Its tegmental lobe has a sinuous inner margin, it ends behind, in the narrowish posterior band that runs from the posterior angle of the orbitosphenoid to the supra-auditory tract (*o.s', s.a.c.*); this band is convex on its outer, and concave on its inner, side. From the end of this band the cartilaginous tegmen is almost complete, but the supra-auditory tracts (*s.a.c.*) do not meet, they are separated at the middle by a large round notch, at the back of which there is already a smallish crescentic interparietal scale (*i.p.*). These tracts, however, send forward a thinner bilobate lamina, sharply marked off from the hinder main part by a crescentic line, whose convexity is behind; this line, and the thinning-out of the tegmen, is caused by the parietal bone. Behind the lateral band (*o.s'.*) the supra-auditory cartilage is ossified, beyond the turning over of the roof, by the prootic (*pr.o.*). Answering to the great size of the occipital arch, the supraoccipital (*s.o.*) is already more than a third the width of the widest part of the hind skull, its sides are bilobate, its extent, lengthwise, is from the fontanelle to the foramen magnum.

An *upper view* of the cranial floor (Plate 26, fig. 6), after the membranous fontanelle has been removed and the orbitosphenoids (*o.s.*), lateral bands (*o.s'.*), and the tegmen (*s.a.c.*, *pr.o'*, *s.o.*) have been cut down to the top of the wall, shows some things very instructively. The top of the great internasal septum (*p.e.*) projects backwards, as a small triangular crista galli (*cr.g.*), and below that ends as an oblique,

rather thin, somewhat projecting wall-top, right and left of which we see the large cribriform plate (*cr.p.*). Each plate is perfect, is circular in outline—as cartilage, and is grooved obliquely, inwards and forwards; it is also riddled full of holes for branches of the olfactory nerve. The top of the presphenoid (*p.s.*) runs into the hind part of the perpendicular ethmoid (*p.e.*) which is broad behind, and has the thick crescentic top of each moiety of the nasal labyrinth pressing against it; these curious curved lobes, which are thick and bulbous against the median cartilage, and thin externally, contain the hinder folds of the middle turbinal; they are separated from the orbitosphenoids (*o.s.*) by a narrow chink. These latter tracts are ossified up to the thick middle beam (*p.s.*); and the bony deposit is, now, complete for some extent, proximally, and then it merely strengthens the fore edge of the tract up to the anterior chink. At their inner third, and near the hind margin, these bony centres show a small foramen opticum (II.). The hind margin of the orbitosphenoidal stem is first convex, and then concave, and this sinuous line, the front boundary of the sphenoidal fissure (V^1) is a good height above, and not behind, the fore edge of the alisphenoid; it crosses over the foramen rotundum (V^2 .)

The rest of the alisphenoid (*al.s.*) is seen, away from the eye, behind and below the orbitosphenoid (*o.s.*); the basisphenoid (*b.s.*) is, on this upper surface, of less lateral extent than below; it only passes for a small extent beyond its own boundary line.

The synchondrosis is large, and in it is seen the seat of the sella turcica (*py.*) and the low transverse postpituitary wall (*p.cl.*). The *middle fissure*, right and left, between the synchondrosis and the cochleæ (*chl.*) is wide; the “helix” projects upwards, but is not so well seen as below; the meatus internus (VII., VIII.) is wide and large. The fore margin of the auditory capsules runs almost transversely across the lower part of the base of the hind skull, and the outer two-thirds of this edge forms the hinder boundary to the great infero-lateral fontanelle. The separateness of the capsules from the chondrocranium, proper, is very perfect, especially on the anterior and inner side; but above, it is more apparent than real, for there the great sinus canal (*l.s.*) seems to part the crest from the tract containing the semicircular canals. The whole arch of the anterior canal (*a.s.c.*) shows its convexity here, and under the archway there is the large recess for the “flocculus” (*fl.r.*). The lower part of the occipital arch binds, sinuously, against the two huge capsules; in this view we see most of the exoccipitals (*e.o.*) and all the basioccipital (*b.o.*), the fore edge of which nearly reaches the post-clinoid wall (*p.cl.*). The cartilage is thick; it is perforated by the 12th nerve behind the posterior fissure, and somewhat notched by the 9th and 10th nerves (IX., X.), in the margin, behind that fissure.

Ninth Stage (continued).—Visceral arches of a Young Mole; $1\frac{3}{4}$ inch long.

I shall finish my description of the skull at this stage by an account of the inferior arches of a somewhat smaller specimen than the one whose main skull has just been treated of. The front *fourth*, and the hinder *half*, of the mandible are shown from the

inner side (Plate 28, fig. 6). Here we see that the deep and the superficial mandibles are both well developed; the basal cartilage (basimandibular, *b.mn.*) is still large at the symphysis, and the subdistal part of MECKEL's rod (*mk.*), although undergoing ossification (*mk'*), and hidden partly by the *splénial lamina* of the dentary (*d.*), is still perfect up to its malleal end (*ml.*). That part (*ml.*, *mb.*) is now undergoing endostis, answering to the ectosteal plate applied to it; but the incus (*i.*) and the stapes (*st.*) are still unossified. The annulus (*a.ty.*) is growing larger round the membrana tympani (*m.ty.*), but the fold of skin that lies outside that membrane is still very thick and spongy. The cartilage that pre-forms so much of the permanent mandible is very solid, now; on the articular or condyloid process the glenoidal facet (*gl.c.*) is figured, like a cap; it was derived from the same primary subcutaneous tract, and has the same morphological meaning, as the slab which is ossified by the dentary bone.

Tenth Stage.—Young Moles; 3 inches long from snout to root of tail.

When the young are more than one-third longer than in the last instance we get a great advance towards the permanent condition.

In the *side view* of the skull (Plate 27, fig. 3) the jugal, squamosal, lower jaw, and most of the hyoid arch are left out.

The long, non-segmented, decurved snout (*al.n.*) reaches half-way to the badly-formed orbit. The valvular nostril (*e.n.*) is almost terminal, and is seen best in the under face. The facial part of the premaxillary (*px.*) is half as large as that of the maxillary (*mx.*); at present the canal for the maxillary nerve (V^2) is not finished externally. On the process above it the small crescentic lachrymal (*l.*) rests, and the canal (*l.c.*) is seen in front of the bone, on the face. The slender nasals (*n.*) and the small frontals (*f.*) are still distinct from each other, and from the facial plates of the bones below them (*px.*, *mx.*). The large parietal (*p.*) always keeps distinct from its surroundings: the interparietal (*i.p.*) is now a broad, transverse plate between the parietal and the supraoccipital (*s.o.*). The palatine (*pa.*) and the pterygoid (*pg.*), with its terminal cartilage (*pg.c.*) still visible, can be seen below and behind them, the annulus (*a.ty.*). Behind the lachrymal (*l.*) the thin convex frontal shell (*f.*) is turned inwards suddenly in its orbital part. Near the hind corner of the orbital plate the opening for the ophthalmic nerve (V^1) is large and oval. Below that bony plate the lateral ethmoidal mass (*al.e.*), and the cartilaginous top and bony lower part of the orbitosphenoid (*o.s.*) can be seen, as also the emerging optic nerve (II.). The alisphenoid, with its two large foramina (V^2 , V^3), is seen outside and behind the orbitosphenoid; below their foramina the broad basisphenoid (*t.b.s.*) is exposed. Over the drum of the ear (*a.ty.*) we see the large four-sided, infero-lateral fontanelle (*fó.*), which is hidden in the perfect skull by the squamosal. Behind that membranous space a *deep temporal bone* is shown; it is large, convex, and has a polygonal outline; this is the prootic (*pr.o'*), which has rambed away from the labyrinth, to

ossify the chondrocranial wall. Behind and below that bone, the large labyrinth, in this view, is unossified, and in the cartilage the semicircular canals can be traced (*a.s.c.*, *h.s.c.*, *p.s.c.*). The epihyal (*e.hy.*) is seen descending, with the facial nerve (VII.) emerging behind it; and from the posterior fissure, and from the condyloid foramen the 9th, 10th, and 12th nerves are escaping (IX., X., XII.). Parallel with the posterior canal (*p.s.c.*), and a little behind it, the junction of the opisthotic with the occipital cartilage can be traced, and a little behind that the growing exoccipital bone (*e.o.*); under it is the condyle (*oc.c.*). The gentle, general curve is formed by the parietal, interparietal, and supraoccipital bones (*p.*, *i.p.*, *s.o.*); between the latter and its side bone, the exoccipital (*e.o.*), there is still much cartilage.

In the *lower view* of a skull at this stage, with most of the investing bones removed (Plate 27, fig. 2), we see how much advance has been made. The long snout (*al.n.*), with its infero-lateral nostrils (*e.n.*), is followed by the labyrinth, proper, with the peculiar supporting and conjugating investing bones that lie beneath it or between its moieties. The premaxillaries (*px.*) have very long laminar palatine processes (*p.px.*), (involving the antero-lateral vomers); these support JACOBSON'S organ and cartilages (*j.o.*, *rc.c.*), and reach as far back as those tongue-shaped cartilaginous tracts. The vomer (*v.*) is set between and above the palatine processes of the premaxillaries, and its pointed fore end is hidden by them; its keel begins in their angle, and is very short. The body of the bone first narrows and then suddenly widens between the converging floor-plates of the nasal labyrinth (*n.f.*). In the chink right and left of the recurrent cartilage (*rc.c.*) the inferior turbinals (*i.tb.*) can be seen; then the gap widens, and the upper and middle turbinal folds, now ossifying, are exposed (*u.tb.*, *m.tb.*). But where, *as in Passerine Birds*, the broad hinder part of the vomer connects the right and left ethmoidal masses, there at each edge there is a small, additional postero-lateral vomer (*v''.*), and outside it an osseous patch in the cartilaginous floor itself (*n.f.*).

The lateral cartilaginous tracts—floor and side-wall—first become constricted, and then expand; becoming, indeed, the upper broad unossified part of the orbitosphenoid (*o.s.*). But the hind part of each half of the nasal labyrinth is seen to end, in a bulbous form, right and left of the forks of the vomer, above which the end of the perpendicular ethmoid (*p.e.*) passes into the short presphenoidal region (*p.s.*), still unossified. The orbitosphenoidal bony centres (*o.s.*) can only be partially seen from this aspect (see fig. 1), being hidden in front by the end of the nasal floor (*n.f.*), and behind by the alisphenoids (*al.s.*).

The posterior sphenoidal region is now well ossified; it is exceedingly broad and thick.

Referring to the early chondrocranium (Plate 25, figs. 2, 3, *b.s.*, *al.s.*), we see that the basisphenoidal region, just where the parachordals pass into the trabeculæ under the pituitary body, is greatly dilated, right and left. If two imaginary lines be drawn obliquely backwards and a little outwards from the sides of the presphenoid to the side of the narrow waist in the base, between the cochleæ, then we shall get the

true width of the basal beam. Such a width is kept for the basisphenoidal ossification in the Marsupials, whilst all the part outside that definite bar is ossified by the alisphenoid, which also takes in the whole region that is left bare in the Mole between its alisphenoid and cochlea. Thus, in them, that thickening of the cartilage which is the foundation of the *tympanic ala* is ossified by the alisphenoid, and the tympanic wing has a large "os bullæ" attached to it, behind and towards the mid-line. Here, as in the Hedgehog, there is no os bullæ, and the dilated pneumatic part of the posterior sphenoid is ossified by the abnormally large median centre (*b.s.*).*

Behind the presphenoidal cartilage (Plate 27, fig. 2, *p.s.*) the ossified basal beam is seen to be flanked, right and left, by an outgrowth, which grows into a lower plane, and stretches outwards as far as to the under and inner edge of the alisphenoid (*al.s.*). These suboval masses look inwards in front, and are notched in that part; their inner margin is swollen and rounded, their outer and harder edge is sinuous. A large air cell is forming on the outer part of the under surface, and the whole mass is spongy.

This very *ornithic* condition of the dilated and pneumatic basisphenoid is only a modification of the parts quite similar to what I have just described in the Hedgehog, where, however, the bones are more solid, and are devoid of this peculiar spongy growth. Resting on this wide, pneumatic basisphenoid, we see the narrow oblongo-crescentic alisphenoids with their large foramina—*foramen ovale* and *foramen rotundum* (*V³.*, *V².*); the outer front corner of each bone lies under the corresponding orbitosphenoidal cartilage (*o.s'*). The rest of the cranium proper, is seen wedged, in between, and expanding behind, the large auditory capsules. The synchondrosis is lessening fast, and the rest of the parachordal region is occupied by the very Reptilian basioccipital (*b.o.*). This relatively large plate is polygonal, has a notched fore edge, a concave hind margin, and roughly-sinuous sides; it is concave, right and left of the mid-line. Behind it we see the huge, flattish condyles (*oc.c.*), which are reniform, having a large notch on their inner edge; outside these we see the creeping ossification of the exoccipitals (*e.o.*), and outside these a very low and narrow paroccipital tract (*p.oc.*). The perforating foramen condyloideum (*XII.*), and the hinder foramen lacerum (*IX.*, *X.*) in front of, the occipital arch, are here seen.

The deeply notched antero-lateral margin of the great ear-capsule is bounded externally by the rambling bony growth of the prootic (*pr.o'*). The inner edge of that rounded notch, and the rest of the opisthotic region behind it, and behind the cochlea (*chl.*) is still unossified, and shows in this aspect the horizontal and posterior canals (*h.s.c.*, *p.s.c.*); shining through its semitransparent substance. The cochlea and the contiguous part of the vestibule (*chl.*) are well ossified; the fenestræ are at right angles to the general basal plane, and are not well seen in this view. From the outer

* In this remarkable pneumaticity of the basal and sub-basal parts of the skull, in relation to the tympanic air-cavity, the fundamental structure is quite similar in the Crocodile, Bird, Marsupial, and Insectivore: the after-modification gives the *diagnostic*, in each case.

edge of this *opisthotic* centre the bony matter has run forwards, and a little outwards, to the front of the cartilage, inside the antero-lateral notch.

An *upper view* of this dissected skull—peeled of most of its investing bones (Plate 27, fig. 1) shows the continuity of the elongated nasal labyrinth with the large orbitosphenoidal wing (*o.s.*). The long unjointed double nasal tube is but little enlarged, although sinuous, up to the proper olfactory region (*al.e.*); there, in the swollen part, the marks of the turbinal folds are seen outside. The fore brain and large olfactory lobes overlie the hinder part of the labyrinth, and then the roof ends abruptly, a long way in front of the end of the floor; there we see the large cribriform plate (*cr.p.*) between the roof and floor, in two hollows, greatly perforated, and separated by the perpendicular ethmoid (*p.e.*), which gives off a short cartilaginous crista galli (*cr.g.*), above. The partial ossification of the turbinals, within, is shown in the lower view (fig. 2); in this figure the cribriform plate and mesethmoid (*cr.p.*, *p.e.*) have a small centre, in the middle. Behind, the ethmoidal wall thickens, and right and left of it the end of the capsules is swollen in front of the orbitosphenoidal bony centres. These two bony tracts (*o.s.*) are subarcuate, narrow at their origin, and broader above; where the cartilage enlarges suddenly, there they end near their hind margin; half-way outwards they are perforated by the small optic nerve (II.). The short and narrowish presphenoidal tract (*p.s.*) is not ossified by them at present. Behind these parts the basisphenoid (*b.s.*) is altogether abnormal, as compared with that of a Marsupial; it reaches nearly as far outwards as the orbitosphenoids, and has the small ear-shaped, biperforate alisphenoids (*al.s.*) placed on its edges.

From side to side the basisphenoid is marked off into three nearly equal regions; the two outer of these have a rounded hind margin; behind the fossæ marking them off from the middle the cochleæ (*chl.*) wedge in. Between the cochleæ and the alisphenoids there is a membranous space; and between the basisphenoid and the basioccipital (*b.o.*) there is a considerable tract of cartilage; here, at its narrowest, part, the basis cranii is very broad. Right and left the great misplaced prootic (*pr.o.*) is as well seen as in the lower view; it has a vertical position, for the cartilage further back turns inwards at its inner edge; the opisthotic bony centre has crept outwards from the well ossified cochlea (*chl.*); its elegant coils are seen in this view, and behind them the archway and recesses for the 7th and 8th nerves (meatus internus, VII., VIII.). Backwards, and a little outwards from that passage, the huge anterior canal (*a.s.c.*) is seen, and has its walls bony, but the recess for the flocculus (*fl.r.*) and the cartilage round and behind the great canal, are still unossified. In this view the basioccipital (*b.o.*) appears still broader and more reptilian than on the lower aspect; its fore part is still notched, where the *bony cephalostyle* was formed by the ossification of the cranial notochord. Right and left of the notched hind margin of the bone we see a large tract of cartilage separating the basal from the lateral bones—the exoccipitals (*e.o.*); the supraoccipital (*s.o.*), and the surrounding cartilage, has been cut away to expose the cranial floor.

Tenth Stage (continued).—The visceral arches.

Notwithstanding the more specialised nature of the Mole, as compared with the Hedgehog, some things in it are much more like what is seen in the Metatheria than anything to be found in that larger and more normal Insectivore.

In these large "nestlings" the three lobes of the lower jaw (Plate 28, fig. 7, *c.p.*, *cd.p.*, *ag.p.*) are still largely composed of cartilage. MECKEL'S cartilage (*mk.*) is to a great extent lost in the general dentary ossification (*d.*), but it is seen behind, wedged in between the condyloid and angular processes of the jaw. The ossicula are now largely ossified and the bony deposits forming the malleus (*ml.*) are exceedingly instructive and very Metatherian. Besides the ordinary ectosteal tract, which has set up endostosis in the head of the malleus, there is an almost distinct splint under the neck of the malleus, which is the true counterpart of the os angulare of the Ovipara. The manubrium (*mb.*) is mainly cartilaginous, but there is a fusiform epiphysis in the middle of this process; this is very noteworthy; for in *Lepidosteus* and in *Amia* the "articulare" is ossified by two centres; and this is manifestly the additional centre cropping up once more.*

The three most projecting parts of the incus (*i.*) are still unossified; the short crus (*s.c.i.*) is very small. The stapes (*st.*) is merely indicated in outline; so also is the annulus; the epihyal (*e.hy.*) is confluent with the auditory capsule (*au.*) where the facial nerve (VII.) emerges. A short ligament connects that second segment of the hyoid arch with the top of the subdivided ceratohyal (*c.hy.*); this is a gently curved rod, occupied by a shaft of bone for half its extent. The next segment (*c.hy'.*) is only two-thirds the length of the upper, and is one-third thicker; it is just beginning to ossify. So also is the still shorter and stouter hypohyal (*h.hy.*) which fits obliquely on to the basi- and thyrohyals (*b.h.br.*, *t.hy.*); these rods are ossifying, but the distal half of the paired rods is soft. The annulus (Plate 25, fig. 13, *a.ty.*) and the imperfect cartilaginous tube of the meatus (*m.c.*) show the normal type of the outer ear, with arrest of the concha; it has four rudimentary rings.

Eleventh Stage.—Young Mole; two-thirds grown.

The *side view* of the skull at this stage (Plate 27, fig. 4) is very similar to that of the last (fig. 3). I have, however, figured the squamosal, *in situ*, in this; the malar or jugal, is left out, here, for the better display of the fundus of the imperfect orbit. The length of the figures is nearly the same, those of the larger specimen being somewhat larger, although they are magnified much less.

The bones are much stronger and more polished, and the cartilage is rapidly disappearing; the snout (*al.n.*) is relatively slenderer. The imbrication of the

* In the Green Turtle there are two articular centres: one the endosteal, developed late, and the other the ectosteal, developed early, and just like the other bony plates around it; these, however, are merely the two elements of one ossification.

investing bones is now seen to be that of the one behind on the one before it; had they taken up more of the *cutis vera* they would have differed but little from the bony scutes on a fish's head. Below, there is now a more evident angle where the premaxillary meets the maxillary; in this latter bone the infraorbital foramen (V^2 .) is still unfinished. It is covered over, in some degree, in the perfect skull, by the jugal (figs. 5, 6, *j*.). The frontals (*f*.) have grown down well inside the orbit, but they are singularly free from the usual orbital processes; the upper part there forms a rounded eave over the retiring orbital plate. That plate has a very large oval foramen for the ophthalmic nerve (V^1 .), and a lesser hole behind that in the extreme part. The gap in the wall of the skull seen in the last (fig. 3, *fo'*.) is here shown as filled up by the small oblique squamosal (*sq.*), the thin, sinuous upper edge of which overlaps the antero-inferior part of the large parietal (see also fig. 3). There are three sharp processes growing from the slanting lower edge of the squamosal. The first is its own front corner, overlapping both parietal and frontal; the next is the small, sharp jugal process; and the third is the postglenoid process. The hinder swollen part over the auditory region is bilobate; the temporal fossa is extremely small and ill-defined. Over the roof, behind, the interparietal (*i.p.*) has grown so as to be, relatively, the largest, or nearly so, to be seen in the whole class; antero-posteriorly, it is only one-third the extent of the parietal, but seen cross-wise, or at the side, its extent is very large; it nearly reaches down to the exoccipital (*e.o.*).

Below, the palatine (*pa.*) is seen a little, and the pterygoid (*pg.*) better; this has still a nodule of cartilage on its hook (*pg.c.*). Under the very perfect system of investing bones—which serve the purposes of “ashlar” in a building—the almost completely ossified endocranium is partly seen. The orbitosphenoid (*o.s.*) does not show its optic foramen well in this view (see fig. 8, *o.s.*, II.), but the sphenoidal fissure, and the foramen rotundum and foramen ovale in the alisphenoid (*al.s.*, V^2 ., V^3 .) are displayed in this aspect. Under the alisphenoid, the broad, cellular tympanic wing of the basisphenoid (*t.b.s.*) is quite visible in this side view. A remarkable amount of the very large skeleton of the auditory capsule is seen in this figure. In the somewhat obtuse angle between the parietal and interparietals (*p.*, *i.p.*) the polygono-ovoidal prootic wing (*pr.o'*.) is almost entirely displayed; it is very convex, and, if shorter, is much broader than the squamosal, for which it might be taken in a cursory view of the adult skull. The opening from the lateral sinus is behind the prootic wall-piece; under that bone there is a large tongue-shaped epiotic tract (*ep.*), it is not a distinct centre, but merely a lobe of the opisthotic (*op.*).^{*} Under it there is a foramen, above the large passage for the vagus and glossopharyngeal nerves (X., IX.). The *opisthotic region* of the opisthotic bone, the proper “mastoid” tract, is an irregular wedge of bone running from the post-temporal part of the squamosal to the exoccipital (*e.o.*), with its almost suppressed paroccipital ridge; that bone is, like the mastoid region of the opisthotic, an oblique, irregularly-oblong tract.

* There is a deficiency in the lines of reference to these parts in this figure.

Over it is seen the large, smooth supraoccipital, and below it the flattish condyle (*oc.c.*).

At the fore part of the mastoid tract the epihyal and facial nerve (*e.hy.*, VII.) are shown in relation, and the 9th, 10th and 12th nerves are figured as they escape from the skull. There is still a considerable tract of cartilage between the supraoccipital, exoccipital, prootic, and opisthotic bones.

The *upper view* of this rapidly growing skull is shown in fig. 6; without the long cartilaginous snout (*al.n.*) this view would have been very imperfect. That finishes this long, flattened, boring, wedge-shaped skull. Eight pairs of investing bones, and one single pair—the interparietal—finish the upper and lateral parts of the skull; they are so developed and imbricated as to increase their general breadth up to the auditory region, and then the skull ends in a somewhat irregular semicircle, not perfected by any superficial bone, but by ossification of the walls and roof of the chondrocranium (*s.o.*, *pr.o'*).

A *lower view* (Plate 27, fig. 5), with the tympanics and ossicula removed, shows the great progress in ossification and general development that have taken place, whilst the young Mole has rapidly become twice as heavy as it was when only 3 inches long—the last stage. The dentigerous semicircle formed by the premaxillaries (*px.*) with their long palatine processes (*p.px.*), largely hidden by the maxillaries (*mx.*) is followed by the long sinuous dentary line of the maxillaries; several of the molars are only just cutting the gums with their sharp cusps. The palatine plate formed by the palatine bones (*pa.*) is shorter and wider than that formed by the maxillaries, for the suture between the two pairs of bones is very far forward; the Mole has a very perfect and normal hard palate. The openings of JACOBSON'S organs (*j.o.*) are seen in the anterior palatine foramina, and the posterior foramina are large and wide apart, they are in the line of the lateral suture between the palatines and maxillaries. The palatine plates of the palatines have a beaded edge, and this thick or limbate margin, which turns inwards and backwards to form the wall of the nasopalatine canal behind the hard palate, is, altogether, bracket-shaped. The palatines go twice as far back on their palatine plate, and are very solid and spongy where they embrace and support the base of the skull. On to them, the pterygoids (*pg.*), are articulated, and they also have a pedate expansion above, supporting the skull; their hamular process is not quite ossified (*pg.c.*). The presphenoid (*p.s.*) is a long beam of bone, formed by fusion of the orbitosphenoids, and separated by a considerable synchondrosial tract from the basisphenoid (*b.s.*); this latter is a truly marvellous bony centre, and as far as my experience goes is, in this creature, relatively wider than in any other type. In this aspect, the basisphenoid runs across the whole basal region up to the floor of the orbits, so that very little of the top of the skull can be seen right and left.

The fore edge is narrower than the hind margin; both are sinuous, and the outer margin is rounded, and almost semicircular. The anterior third, which is clamped by the cranial plates of the pterygoids, has its floor perfect, but the bone is burrowed,

above the floor, there being a continuation there of the great pneumatic recess seen, right and left, in the hinder two-thirds of the bone. Each recess occupies about half the large hinder tract; the inner half is convex, and meets its fellow at the mid-line in a deep fissure or sulcus.

All this wide, spongy, pneumatic structure is merely a peculiar *Talpine* modification of the normal skull of an Insectivore, such as that of the Hedgehog, or the Tenrec.

The slender zygomatic arch (*j.*) is finished behind by the squamosal (*sq.*) with its glenoid facet (*gl. c.*); this is close outside the tympanic recess of the basisphenoid. A character is seen here which is only partly shown on the side view (fig. 4), namely, that the squamosal after giving off its zygomatic process, and forming the sinuous plate for the glenoid cartilage, grows round and *under* the skull, strongly clamping and binding all the parts by a large squarish postglenoid plate, which grows obliquely inwards and a little backwards, and is notched on its inner edge. The two plates, right and left, hold the large auditory capsules as in a widely opened *vice*.

A considerable tract of cartilage separates the basioccipital (*b.o.*) from the ear-capsules; it runs backwards, and a little outwards; it is almost straight, and passes nearly into the cartilage of the condyle. Behind the postglenoid region of the squamosal, and to some degree clamped by it, is the large prootic plate (*pr.o.*). In the angle between the squamosal and prootic plate (*sq., pr.o.*) there is an oblong tract of bone, *subdistinct*; this is the epiotic (*ep.*); it is bounded within by the hinder part of the main opisthotic tract (*op.*), which has left a considerable tract unossified behind, up to the small fusiform cartilaginous paroccipital ridge (*p.oc.*). In front of that cartilage, up to the basisphenoid, there is a large irregular tract of the opisthotic visible below; this is beset with cranial landmarks. Close inside the front lobe of the under part of the squamosal the ceratohyal (*c.hy.*) is seen, tied to the epihyal snag; behind this the facial nerve (VII.) emerges through the stylomastoid foramen. Inside the nerve, the hole for the internal carotid may be seen, and behind that, at a good distance, the foramen lacerum posterius for the 9th and 10th nerves (IX., X.) is enclosed, nearly, by the opisthotic; behind it, over the border, is the hole for the 12th nerve (XII.). There is also a crescentic hole under the notch of the squamosal. The use of this I did not discover.

The foramen magnum (*f.m.*) has a neatly egg-shaped outline; in front of it the huge basioccipital (*b.o.*) has a subpentagonal shape. The fore edge is very extensive and gently sinuous, for this plate is notched and grooved in front, and this fore edge is thick and spongy, answering to the hind part of the basisphenoid. Then, behind each thickening, there is a round concavity, from which the bone becomes generally gently convex up to the semielliptical notch at the fore part of the foramen magnum. A large lozenge-shaped tract of cartilage, pierced on its outside by the hypoglossal nerve (XII.), is seen between each postero-lateral edge of the basioccipital and the condyles; these (*oc.c.*) rise but little in front, and are grooved, crosswise, at their fore third, and then on their hinder, narrower part, are more perfectly defined. Wedging

in between the small cartilaginous paroccipital and the large condyle, the exoccipital (*e.o.*) is seen, and behind the foramen magnum the crescentic lower edge of the supraoccipital (*s.o.*).

In the *end view* (Plate 27, fig. 7) some of these things are better seen; supplementing the large, smooth parietals (*p.*), the great transverse interparietal (*i.p.*, see also fig. 6) stretches across the top of the occiput from one prootic plate (*pr.o'*) to the other. Under and behind that superficial plate the true supraoccipital is seen as a large and almost semicircular ossification of the endocranium; the lower transverse edge of the plate is notched over the foramen magnum, and rises, and then falls, outside that archway. A little cartilage exists at its outer edge, between it and the prootic plate (*pr.o'*), and this cartilage forms a short arched tract over each exoccipital, and then fills in a square space over the notched hind part of the mastoid bone (*op.*). The hindermost projecting part of each squamosal (*sq.*) can be seen, right and left, away from the eye. Around the foramen magnum the crescented exoccipitals, capped, behind, by the curious condyles—oval above, grooved, and then transversely lobate; outside the exoccipitals, the small fusiform unossified paroccipital ridges (*po.c.*) are flanked by the mastoid bone (*op.*).

A very instructive preparation was made of the *inner face* of the skull-floor (Plate 27, fig. 8); the nasal labyrinth was largely cut away. The top of the upper wall (*al.e.*) ends in the short, cartilaginous crista galli (*cr.g.*); behind this, the top of the ethmoidal partition wall (*p.e.*) and the contiguous part of the cribriform plate (*cr.p.*) are ossified as a trowel-shaped centre, with the handle below. The rest of this large, exquisite, double sieve, with its thickened rim, is still unossified. Behind, this structure is embraced by the gently concave front margin of the orbitosphenoids (*o.s.*), which now meet in the middle of the skull-floor and there lie upon the presphenoid, which they have ossified (see fig. 5).

They are very narrow planks, bent backwards behind, forwards in front, and with a sinuous hind edge, the middle part being the narrowest. The small, oblique optic foramen (*II.*) begins at the inner third, and is behind the middle of the bony tract.

The posterior sphenoid is as remarkable from this view as from below (fig. 5). The alisphenoids (*al.s.*), with their two foramina (V^2 , V^3), are about twice the size of the orbitosphenoids, they project beyond their basal plate in front as much as they fall short behind; there they are free and pointed; in front, they are rounded and turn under to the base of the skull; they are wide apart from the orbitosphenoid, and the sphenoidal fissure (V^1) between the two plates is large. The huge basisphenoid (*b.s.*) has a concave fore edge, and convex sides, and then ends behind in four large sharp cusps. The two submesial cusps reach much further backwards than the outer; between these pointed projections, externally, the whole bone is toothed and splintery, and is attached to the rough toothed fore edge of the cochlear region of the ear-capsule by fibrous tissue.

In front of the deep lateral notch, the bone, right and left, is gently concave, as

also is the middle part in front of the synchondrosis, but the sella turcica is badly defined.

The prootic plates (*p.ro'*.) have been cut through; between them and the proper bony capsule there is a considerable tract of cartilage. The cochlea (*chl.*) is much masked by bony growths; the meatus internus (VIII.) is large and very near the inner edge; there is a special foramen for the 7th (VII.).

The remarkable archway over the deep recess for the "flocculus" is ossified; the enlargement in front, on the outside, is due to the ampulla of the anterior canal (*a.s.c.*), and its arch is over the archway; the common sinus for the anterior and posterior canals runs, inside the thickening of this curious internal "porch," downwards and forwards, on the inner side; the appearance of an ampulla below, and in front, where it ends, is deceptive, that is due to a swelling of the vestibule (*vb.*).

The horizontal canal (*h.s.c.*) is not well seen from this aspect, its ampulla is only visible under that of the anterior canal. The posterior canal (*p.s.c.*) is seen in the postero-internal face of the porch where it meets the anterior canal, and where the two pass into the common sinus on the inner side. The ampulla of the posterior canal is formed after the arch has crossed and passed under that of the horizontal canal, just where the latter is entering the vestibule; these parts lie at the bottom of the bony labyrinth, just outside the passage for the 9th and 10th nerves (IX., X.). The basal, and part of the lateral, regions of the occipital arch (*b.o., e.o.*), are seen, also; in this figure, the hypoglossal nerve (XII.) is on the edge of the exoccipital ossification on this inner side; outside, or below (fig. 5), it is still surrounded by cartilage.

Inferior arches of the young Mole in the Eleventh Stage.

The malleus in this eleventh stage is thoroughly Marsupial in character.*

Seen from the inside (Plate 28, fig. 9) the head projects as a semioval mass, having, behind, the saddle-shaped condyloid cartilage. Under the head there is a pneumatic recess bordered by a sloping, sinuous edge of bone, from which the manubrium (*mb.*) is continued. That process is rather a round hook than an angular part, and the whole hind margin is sinuous, without showing on this face any very definite posterior process (*ag.p.*). The neck of the malleus is broad and irregular; it is followed by a rough, rounded, perforated lobe or crest. Then the bone dips and runs forwards as a straight "processus gracilis" (*p.gr.*). But this is only a part of the foregrowths of the malleus, for beneath the upper lobe there is a lanceolate, almost distinct tract (seen also in fig. 7, tenth stage), and in front of this, running away from the line of MECKEL'S cartilage (see fig. 7, *mk.*), there is an elegant *pretympanic* sickle of bone, enlarged and split at its end.

* My own figures of the Marsupial skull will show what I mean by this assertion; meantime the reader is referred to Mr. DORAN'S valuable paper on the *Ossicula auditus* (Trans. Linn. Soc., ser. 2, Zool., vol. i., plate 64, figs. 15-34).

On the *outer face* (fig. 10) that process is well marked off, as if it had formed separately, and then became ankylosed to the straight process; here, also, the upper lobe has a very distinct form and outline, behind, whilst the lower lanceolate tract is less distinct.

On this face we miss the pneumatic recess, but get a view of the remnant of the cartilage that separates the epiphysis in the manubrium (fig. 7, *mb.*) from the main part of the bone. It is evident that, about the time of weaning the young Mole is developing, in a rough, irregular, and abortive manner, the well-known "angular" and "supra-angular" of the Oviparous tribes, in addition to the "articulare externum," and the two endosteal articular tracts that are found in Holostean Ganoid Fishes. We shall soon see what becomes of all this effort to restore the old compound mandible.

The *hyoid arch* (Plate 28, fig. 8), when detached from its two upper elements (the epihyal and stapes), shows a considerable advance upon the last stage (fig. 7), all the bony shafts are rapidly developing along the cartilaginous rods; the articulations, also, are very distinct.

Twelfth Stage.—Young Mole; three-fourths grown.

Among my materials—gathered during the last forty years or more—I found the malleus of a somewhat older Mole than the last; it is of great importance, for it shows (Plate 25, fig. 4, *inner view*; fig. 5, *outer view*) the softening down, by absorption, of much that was rugged and irregular in the last stage. The processus gracilis is still very large, and is cochleate proximally; the crest and the pretympanic sickle are gone. But the cartilage separating the manubrial centre (*mb.*) from the main bone, on the outer side, is still evident. Of the same age also are the other ossicles here figured, the incus (Plate 25, figs. 6, 7) and the stapes (Plate 28, fig. 11), and also the annulus (Plate 25, fig. 11).

Both the orbicular facet for the stapes (*l.c.i.*) and the short crus of the incus (*s.c.i.*) are feebly developed and look towards the Monotrematous condition; the whole inner face is open to the tympanic cavity.

The stapes (Plate 28, fig. 11) cannot be detached in this stage, as in the adults of some other Insectivores, *e.g.*, *Myogale moschata* and *M. pyrenaica* (see DORAN, *op. cit.*, p. 435).

This is a very remarkable modification (Plate 28, fig. 11, *st.*), and its transitoriness in this type is also noteworthy; the Mole gets beyond *Myogale* in this respect. This little bone is kept in its place by the ossification of the outer sheath of the stapedia artery (*st.a.*); a sheath similar to that which protects the outer part of the internal carotid in the Bird. There, the bony arterial sheath traverses the light diploë of the basis cranii between the basitemporal plate and the proper spheno-occipital skull floor. I am under the impression that this sheath is formed just as the stapedia artery becomes

obliterated; then the bony sheath, itself, soon afterwards, is absorbed; these things are enigmas to us at present.

The annulus tympanicus is shown in the young Mole, three inches long, from the side (Plate 27, fig. 3, *a.ty.*); and the curious flat, imperfect ring is figured in several of the earlier stages (Plates 26 and 28). In the adult it is wholly blended with the skull floor, but during the first summer it remains distinct; that of the right side, in this stage, is shown from its inner face (Plate 25, fig. 11); it looks like a well-made annulus that has been crushed into a flat coiled band of bone. The outer opening is roughly pyriform, quite pointed on the inner or lower side, and broad above, and having its margins dentated. The part nearest the opening, outside, is very thin; then the bone thickens up to the margin; on the inner face the edge is seen to be strongly ribbed by bony deposits. The anterior crus is very large, and grows along the inside as a large rostral plate, looking backwards, and nearly meeting the sharp, inturned, hinder crus. Thus the great inner opening, which is thrice the size of the outer, is also transverse to it; it is a nearly finished oval, with the long diameter at right angles with that of the outer opening. The great rostral process of the front crus is grooved on the inside, outside its arched edge, for the still large processes gracilis of the malleus (Plate 25, figs. 4, 5, *p.gr.*).

Thirteenth Stage.—Skull of the adult Mole.

I could have wished to have given figures fully illustrating the structure of the skull in the adult Mole, but considerations of space have deterred me; I have, however, figured the ossicula auditûs (Plate 25, figs. 8-10), and the snout, in section (Plate 25, fig. 14). This latter part has been affected by the generally intense ossification of the skull, and not only the proper septum nasi (*s.n.*) has been well ossified on from the perpendicular ethmoid, but that fore-growth of the septum (*s.n'*) which divides the long alinasal region (*al.n.*), in front of the premaxillaries, has acquired an endosteal tract, almost to its front end; the *teleology* of this structure is evident enough, but it comes in as a part of the general osseous modification of this type, which is everywhere intense.

The prootic plate, and the hinder or mastoid region of the auditory capsule, have sutures separating them from the surrounding bones. The parietals, also, are always free; they form a squamous suture with the frontals, which they overlap up to the middle of the interorbital region, but the true squamous suture, between them and the squamosals, is very slight; they keep their own mutual sagittal suture perfect. With these exceptions the skull of a Mole has its bones as completely ankylosed together as in any Bird; and the structure of the base of the skull is as light and pneumatic as anything seen in any Passerine, or highest, kind of Bird. During the first summer there is but little promise of the exquisite polish of the bones nor of the excavated condition they will soon attain to. Everything becomes smoothed down,

outside; the hamular processes of the pterygoids are small but perfect, and behind and outside them the whole of the wide hind skull is flattened, and bevelled, and polished to a marvellous degree. On the inside, also, the surface is exquisitely smooth, and the bone delicately cellular; the cochleæ have their bony walls polished and thinned down so as to show the coils as if through a transparent medium, and the great porch for the "flocculus cerebelli" is the most remarkable piece of miniature architecture I am acquainted with. The bony tubes containing the semicircular canals strengthen the porch at its margin, and the intervening bone roofing it is extremely thin. The base of the skull now shows a shallow but distinct sella turcica, and behind it the postpituitary wall is well defined, although rather low. The cribriform plate is very large and abundantly perforated.

But the basal and basilateral regions of the skull, in its floor, although highly polished, is marvellously broken up into hills and holes, because of the extreme delicacy of the upper table of the bone; the supratympanic bony shell, the cochleæ, the *floccular porches*, the pituitary cup, and postclinoid wall,—to say nothing of the foramina and fissures for nerves, vessels, and the like,—make this little skull, in its inside, a most admirable object for study and contemplation.

All this is true of the outside or lower surface, but the large flattened tympanic annulus, completing the unlippped bony meatus externus, and thoroughly anchylosed to the surrounding bones; and the extensive air-galleries that are excavated inside the huge basisphenoid, and the small squamosals, may be mentioned.

The ossicula auditûs are figured and will now be described, as they show the last specialisation of the inferior arches of the face.

The malleus (Plate 25, fig. 8, *inner*, and fig. 9, *outer* view) shows a very small processus gracilis (*p.gr.*) and a small manubrium (*mb.*), whose axis forms one continuous curve with the body of the bone. In front, under the head, but most on the inside, a considerable pneumatic recess is seen, and outside the obtuse angle (*p.ag.*) of the manubrium, there is a loop-shaped ridge where the remnant of the last tract of cartilage was seen. In this malleus almost the whole of the attempted mandibular structures has been absorbed; and the Metatherian type, *at its lowest grade*, has been exchanged for the typical Eutherian form.

The incus has lost much of its typical Mammalian character* (see Plate 28); its short crus (*s.c.i.*) has dwindled to a fine transverse style, the incurvation of the lower part of the long crus (*l.c.i.*) is almost lost, and the orbicular facet is a mere oblong condyloid tract.

Thus this little representative of the quadratum has lost, not only much of the "otic process" (= short crus), but also that special Mammalian character, the orbicular plate on an inturned narrow neck, has greatly suffered degradation. Now this relapse is

* I here include both the Marsupial and Placental Mammals, for in the former the incus has its highest development; the long crus and the orbicular plate being better developed than in the Eutheria, generally.

in the Prototherian direction ; if carried further, and the bone were flattened out, we should have an incus very similar to that of a Monotreme.

The long crus is hollowed out into a pneumatic *boat*, its long opening looks forwards and outwards (fig. 9).

The stapes of the adult (Plate 25, fig. 10) is greatly altered from that of the larger young (Plate 28, fig. 11), at the time when it is fastened in the fenestra ovalis by the bony arterial tube.

Then it had narrow sides, and its incudal condyle had a rounder shape ; now, that articular face is oblong, and the sides have become inflated, as also the base ; so that the whole bone is a sort of *lagena*, with an oblong apex and a bulbous base ; whilst the flattened sides are perforated, one by a large, and the other by a small, oval fenestra. The sides of the base are neatly limbate, the rim being adapted to the edges of the fenestra ovalis. That there is nothing in the structure of the skull of the adult Mole that is not in harmony with the life and habits of the creature, I feel certain ; but questions of that sort are of less interest than the correspondences seen in this terricolous Mammal with that we are familiar with in Reptiles (Crocodilia) and Birds. Besides the general pneumaticity of the whole hind skull, we have the *hollow* counterparts of the quadratum, articulare, and columella of those high Sauropsida.

On the skull of the Common Shrew (Sorex vulgaris).

There are three native species of the Soricidæ—*Sorex vulgaris*, *S. pygmaeus*, and *Crossopus fodiens*. I have worked out the skull in the first of these, comparing it in its adult condition with that of the last, or largest, kind.

My materials yielded me four stages, as follows :—

1st Stage.—Embryos, $\frac{5}{8}$ ripe ; $8\frac{1}{3}$ lines long from snout to root of tail (Plate 16, figs. 10, 11).

2nd Stage.—Ripe embryos ; $9\frac{1}{2}$ lines long.

3rd Stage.—Young from the nest, 10 or 12 days old ; $1\frac{1}{3}$ inch long (Plate 16, fig. 12).

4th Stage.—Adult Shrews.

Besides these I obtained early embryos, with the somatomes well formed, a little less developed than my earliest embryo of the Mole (Plate 16, fig. 1) ; these were merely examined externally.

The *First Stage* here given was examined in sections, but as these corresponded very literally with those of the younger Mole, already described, they were not figured. In these almost ripe young the general form is such as one might imagine in some early Tertiary types, in which the characters of the Orders of Mammalia now existing had not been developed.

It is a simple pentadactyle form, very similar to my third stage of the Mole (Plate 16, fig. 4), but having smaller fore limbs that are further back from the head.

Along the annular folds of the outer skin the bud-like hair-pulps are seen cropping up in corresponding rows, as though they had been planted by a farmer's "drill." The eyelids are developed, and closed over the eye-balls; the concha auris is a kidney-shaped fold of skin, the snout is, relatively, no longer than that of a full-grown Mastiff, and shows little promise, as yet, of its future length.

Second Stage.—*Ripe embryos of Sorex vulgaris*, $9\frac{1}{2}$ lines long
(about $\frac{3}{4}$ of an inch, or 20 mm.).

The chondrocranium (Plate 29, fig. 7), is undergoing ossification, but its general form is not altered, and absorption of those parts of the cartilage which do not ossify has scarcely set in; it serves well at this stage for comparison with the skulls of the Mole and the Hedgehog at a similar stage of development (see Plates 17 and 25). In the Mole the chondrocranium is less massive, relatively, than in the Hedgehog, and in the Shrew less than in the Mole. The Hedgehog is the least modified and most primitive type. The Shrew is the most modified, and that mainly through dwarfing, so that some parts are arrested, and others actually suppressed—as if for want of room for them. They may easily have arisen from one common stock, and the Mole comes in as a connecting link between the well-developed Hedgehog and the scant and stunted form of the Shrew.*

Therefore we may look for signs of that peculiar form of *degeneration* which arises from dwarfing. The cartilage may be expected to be scanty, and the number of osseous centres lessened.

In this ripe embryo of the Shrew the top of the nasal partition wall (Plate 29, fig. 7, *s.n.*, *p.e.*) reaches half-way back to the front of the supraoccipital (*s.o.*); at its crown it is much more than half the height of the skull; at its base, from the front of the snout (*al.n.*) to the middle of the presphenoid (*p.s.*), it is twice as long as from that point to the foramen magnum.

The snout, itself, has only half the relative length it will have in ten or twelve days—next stage (Plate 29, figs. 1–4). The septum in front is perforated and circular; then it narrows to half its width in front, and is narrowest in the front part of the true septal region, behind the snout, proper. Thus between the large recurrent or JACOBSON'S cartilages (*tc.c.*)† the thick intertrabecular base of the whole partition wall (*i.tr.*) is formed into a low arch, and is especially thick where it descends again, as it passes backwards towards the presphenoidal region. The thinner, main part of the partition—septum nasi (*s.n.*), and perpendicular ethmoid (*p.e.*)—is very even, and forms a low triangle, the hinder side of which is the shortest, and is the dividing line between the two perforated (cribriform) plates (*cr.p.*); that line is a little arched, the longer line in front, towards the snout (*al.sp.*) is first convex, and then concave before

* The pygmy Shrew (*Sorex pygmaeus*), is not only the smallest British Mammal; it is as nearly as may be the smallest beast in the whole Class of the Mammalia.

† For *tc.c.* read *rc.c.*

it passes into the gently arched snout (*al.n.*). The basal cartilage behind the cribriform plate and nasal labyrinth is thick, but from being high and narrow, becomes depressed and broad; thus the middle ethmoidal region passes into the short presphenoidal, and that into the fore part of the basisphenoidal territory (*b.s.*). That region is perforated and partly ossified (see Plate 30, fig. 18, *b.s.*). Here we meet, again, with the open pituitary space which we found in the Hedgehog (Plate 17, figs. 1, 2, *py.*), but did not find in the Mole (Plate 25, figs. 2, 3). Behind that passage the basal tract thins out, becomes gently concave, thickens again, is again ossified, partly, as the basioccipital (*b.o.*), and then ends, with a narrow cartilaginous selvedge, at the foramen magnum. The primary fontanelle is very large, for the band of cartilage connecting the great orbitosphenoidal wing (*o.s'*) with the equally large supra-auditory tract (*s.a.c.*) is narrow.

The upper orbitosphenoidal expansion is confluent with the nasal wall in front; it is sinuous, notched in a rugged manner, above, and its hind margin, both above and below the narrow posterior band, is concave; there is no optic foramen through its stem. The optic nerve passes through the great sphenoidal fissure, in company with the orbital nerves, as in Marsupials. The skull is unprotected by cartilage for a very large space both above and below the narrow band; for that band, dipping a little, bounds a huge space below of an irregularly oval shape, with its long diameter—which reaches from the cribriform plate to the meatus auditorius internus (VII., VIII.)—two-fifths the length of the whole cranial cavity. Below, this space is partly occupied, in front by the alisphenoid (*al.s.*), and behind by the cochlea (*chl.*). The alisphenoid (see also Plate 30, fig. 18, *al.s.*) is a small ear-shaped tract of cartilage, notched on its hinder margin near its upper angle for the 3rd branch of the trigeminal nerve (*V³.*), and lying quite outside the plane of the orbitosphenoid.

Thus the optic, 3rd, 4th, 1st and 2nd branches of the 5th, and the 6th nerves all pass through the gaping sphenoidal fissure. Some distance behind the proper alisphenoid the basis cranii becomes alate, and that small rounded wing is perforated and has its hinder margin adapted to the apex of the cochlea, on its inner side. The posterior orbitosphenoidal band (*o.s'*) runs upwards and forms a sinuous ribbed edge to the supra-auditory plate (*s.a.c.*), the high upper margin of which has a convex outline, and passes into the supraoccipital region (*s.o.*), already ossifying.

That speno-pterotic tract (*s.a.c.*) is as broad as the inner face of the huge, geniculate auditory capsule (*chl.*), its hinder half, and the capsule, form the very perfect semioval margin to the hinder part of the great lateral fontanelle. The archway formed by the upper cartilaginous wall (*s.a.c.*, *s.o.*) for the setting of the oblique upper half of the auditory capsule, is much larger than is needed for that part; the whole margin is occupied by the large, and accurately semicircular "lateral sinus" (*l.s.*).

There are three arched and convex tracts to be seen in the postero-superior part of the auditory capsule; the middle tract is nearest to, the hinder tract furthest from, the eye. The foremost arched convexity contains the anterior canal (*a.s.c.*), and

the middle tract, which bulges inwards, the "sinus" or common tube of the anterior and posterior canals. The latter is in the convexity that is just seen behind in the great space for the lateral sinus; the hollow oval space between the first and second arched convexity is for the "flocculus cerebelli." Where the antero-inferior and postero-superior regions of the capsule meet, there, above, the inner and outer openings of the short tunnel for the portio dura (VII.) are seen.

Below these holes the perforations for the portio mollis (VIII.) are seen in the short arched meatus internus, and the space between the capsule and the basi-occipital leads to the foramen lacerum posterius. There the outline of the capsule is gently concave; in front of that part it swells again with the coils of the cochlea (*chl.*), and behind it with the galleries of the vestibule (*vb.*). The halved occipital arch is much narrower than the capsule in front of it; we see the supraoccipital (*s.o.*) and the exoccipital (*e.o.*) already large centres; the condyloid foramen (XII.) and the articular condyle (*oc.c.*) are both clearly seen in this view.

The investing bones are rapidly forming; the nasal (*n.*) above the septum, and the vomer (*v.*) below; and the maxillary and palatine (*mx. pa.*) below the nasopalatine passage (*n.p.c.*) are seen edge-wise.

The frontals (*f.*) are no larger than those of a Snake, but the parietals (*p.*) are very large; and project from the outside, at the upper third of the front lateral fontanelle, yet they fail to meet the small, low-lying squamosals (*sq.*), and there, between them and behind the alisphenoid, there is a large pyriform tract entirely unsupported, either by cartilage or bone.

In a dissection of the basis cranii at this stage, seen from *below* (Plate 30, fig. 18), we get further light upon the parts just described as seen in the inside of a halved skull. The cartilage of the snout (*al.n.*) is represented in this figure as detached from the sides and roof of the septal region, but having the inferior tracts that grow from it, namely, the recurrent cartilages (*rc.c.*) attached. These remarkable capsules, that contain JACOBSON'S organs, arise as alæ from the base of the septum in the lower and hind part of the snout, then expand into horizontal laminae, and then form a hook round the opening of JACOBSON'S organ, enclose it entirely for a short distance, and then only on the internal and lower side, thus forming a long cochleariform tract which reaches half-way to the pituitary space (*py.*). On the inside of these cartilages the palatine processes of the premaxillaries (*p.px.*) run; they are thin vertical plates, and show no separate antero-lateral vomer attached to them. The Mole has the same deficiency.

The vomer, proper, (*v.*) is long and normal; it is pointed in front, and slightly split behind. Behind the sheathing vomer the intertrabecular bar widens, it is first ethmoidal (*p.e.*) and then becomes the presphenoid (*p.s.*).

On each side I have figured the hind, closing part of the lateral ethmoidal regions (*n.f.*); the primary form of the so-called "sphenoidal sinus," which has wedged in here between the alisphenoid (*al.s.*) and the base of the great orbitosphenoidal tracts

(*o.s.*). The narrow stalk of these great leafy growths of cartilage is out of sight; it is imperforate. A true Insectivorous diagnostic is seen in the sudden widening of the basisphenoidal region (*b.s.*), which is *five times as long, and three times as wide* as the presphenoid, and has an open pituitary space (*py.*) in its middle, in which it agrees with the Hedgehog and differs from the Mole. Around this hole the bony basisphenoid (*b.s.*) is forming; it is circular at present. The alisphenoids (*al.s.*) are small ear-shaped tracts of no greater extent than the cochleæ (*chl.*), and having an oblique position, they look forwards as well as outwards, and are quite outside the plane of the orbitosphenoids. A round notch is seen between them and the base, in front; they are gently sinuous in front and on the outside, whilst, behind, they have a deep notch for the 3rd branch of the 5th nerve (V^3) near their outer angle. The base is clear of all alate growths in its middle part, but, behind, it gives off a small perforated crescentic wing which is applied to the fore end of the cochlea (*chl.*); this, however, is soon lost, and the tympanic wing, so characteristic of the typical Insectivore, is aborted. The spheno-occipital region of the basis cranii is elegantly cut away, so to speak, to let in the rounded apex of the cochlea, right and left. The basioccipital centre (*b.o.*), nearly reaches the foramen magnum, and is growing fast towards the lateral notches; it is polygonal and reptilian. A superficial tract of cartilage and of bone, forming the pterygoid (*pg.c., pg.*) is shown attached to the base of the skull. The visceral arches are well developed. I have figured the upper part from the inner side (Plate 30, fig. 16) of the tympanic region. The malleal end of MECKEL's cartilage (*mk.*) shows a well formed head, a deep and wide tract beyond the articular facet, a very large "posterior angular process" and a short straight "internal angular process," or manubrium (*m.ml.*). The annulus (*a.ty.*) is already a considerable crescent of bone. The incus (*i.*) is quite normal and well developed, and so is the stapes (*st.*), the base of which looks towards the eye in this figure.

Ossification has begun in the perichondrium of the neck of the malleus (*ml.*), below; it is a thin ectosteal tract.

Third Stage.—Young Shrews (Sorex vulgaris) from the nest; 10 or 12 days old; and measuring $1\frac{1}{3}$ inch in length, from snout to root of tail.

The dissected skull at this instructive stage, in its *upper view* (Plate 29, fig. 1), shows a cartilaginous snout (*al.n.*), nearly as long as the long, and relatively large nasals (*n.*). The nostrils (*e.n.*) are sublateral, and the snout itself is narrow at first, and then widens so as to become ventricose where it passes under the investing bones. Those bones are very thin at present, and show the elegant radiating lines of growth. The premaxillaries (*pa.*)* run well up the face, wedging in between the much larger maxillaries (*mx.*) and the nasals (*n.*); these two pairs of bones run backwards to about the same extent at present, widening backwards. The small, almost Ophidian frontals

* For *pa.* read *px.*

(*f.*) are much shorter than the nasals and about twice as broad on their upper face; that face is only one-third as large as that of the parietals, which are very large, have a strongly marked *umbo*, the primary centre, and have a small diamond-shaped fontanelle between them and the frontals in which the coronal, sagittal, and frontal sutures meet. These bones elbow outwards, strongly, over the temporal region, and lie well over the squamosals (*sq.*), which are scarcely visible in this aspect. Behind, the parietals are largely suppressed, a space (fontanelle) existing there almost equal to a whole parietal; this is beginning to be filled in, behind, by a bow-shaped band of bone, the interparietal (*i.p.*), which forms a transversely-long beading to the well ossified and extensive supraoccipital bone (*s.o.*).

The *side view* (Plate 31, fig. 10) shows the form and relations of the parts just described, and many other things besides. The snout (*al.n.*, *e.n.*) is largely arched, and reaches half-way to the middle of the badly-defined orbit. Under the long thin nasals (*n.*) the premaxillaries and maxillaries (*px.*, *mx.*) are seen to form large thin-walled troughs, for the huge tooth-pulps; through which the sharp, red cusps shine, ready to cut the gums.

In front of the orbit there is a process of the maxillary which is beginning to form the nerve channel, but no separate malar bone; in an emargination of the maxillary, above, a small lachrymal, with its canal (*l.*, *lc.*), is seen.

The roof plate of the frontal (*f.*) becomes convex at its edge, and then dips suddenly to form the thin, vertical orbital plate, under which the small, but bulging, alisphenoid (fig. 11, *al.s.*) can be seen; the orbitosphenoid is hidden by it, and by the frontal, in this aspect. The lateral extent of the frontal is only half that of the parietal, which is a *wall*, in this case as much as in our own skull. It lies over the frontal somewhat at its antero-inferior angle, close behind the coronoid process of the lower jaw (*c.p.*). Large as is the parietal, it has two great deficiencies or emarginations, one above, already described, and one along the hinder half of its lower margin. In this aspect we see the squamosal (*sq.*) in its whole extent; and much as this bone is modified by the dwarfing of the skull, generally, it is normally Mammalian. It lies quite down at the lower edge of the skull, rising somewhat where it forms an abortive zygomatic process, in front of the condyloid facet (*cd.p.*). The first two-thirds of the upper edge is concave where it fits over the lower edge of the parietal, and the last third is emarginate when it overlaps the prootic plate (*pr.o'*). Behind, it interdigitates with that plate in some degree. The postero-inferior margin is convex, for a short extent, and then the lower edge looks quite straight, but is only partially seen, being curved inwards (Plate 29, fig. 2, *sq.*). Under the squamosal, the tympanic (*a.ty.*) is just seen, and under the face the characteristic mandible. This latter structure for its fore two-thirds is a thin tooth-trough, behind which the large, elegant coronoid process (*c.p.*) ascends, vertically; its fore edge is two-thirds as long as the dentary part of the ramus. The condyloid process (*cd.p.*), on the other hand, is very short; looks downwards and backwards, covered with its cartilaginous coat. The angular process (*ag.p.*)

is, in the Shrews, very long and very slender, it runs backwards and a little inwards. Some parts of the endoskeleton are best seen in this *outer side* view; especially the prootic plate (*pr.o'*) and the proper mastoid region. The prootic plate, which takes the work here of the "sphenotic and pterotic" of Fishes, and does but little of its own, is a large shield-shaped ossification of the supra-auditory region of the cartilaginous endocranium. Its arched top does not yet reach the emargination in the parietal, nor the lateral sinus (*s.c.*), which now forms an elegant bow over the side skull, inside the parietal for the most part, but exposed, behind. The roughly dentate lower hinder edge of the prootic plate overlaps the ampulla of the anterior canal (*a.s.c.*) and in some degree that of the horizontal canal (*h.s.c.*); then this bone meets with the very extensive opisthotic (at *h.s.c.*). That bone can be seen behind the tympanic (*a.ty.*), and also creeping over the junction of the anterior and posterior canals (*a.s.c.*, *p.s.c.*); much of that part of the capsule (epiotic region) is still cartilaginous; there is no appearance of a distinct epiotic bony centre. Part of the interparietal (*i.p.*) is seen in front of the supraoccipital (*s.o.*), and the occipital arch is seen edge-wise; there is still cartilage between the supra- and exoccipitals (*e.o.*) and the latter run up to the auditory capsule, without forming any definite paroccipital process; the condyle (*oc.c.*) is very large, and looks obliquely downwards and outwards. The whole hind skull is gently convex and very similar to that of the Mole, with which it agrees in having the large *prootic plate*.

The *lower view* (Plate 29, fig. 2) shows the large alveolar grooves, overfull of tooth-pulps, with cusps cutting the gums; thus the marginal part of the premaxillaries (*px.*) as well as of the maxillaries (*mx.*) is very wide and bulbous. The palatine processes of the premaxillaries are very long and slender, and continuous with each anterior paired vomer, right and left. The palatine plate of the maxillaries is large, and twice the extent of that of the palatines (*pa.*); the suture between these four plates is arched forwards, and the fore margin of each palatine is deeply notched; there the anterior palatine foramen is open in front.

The merely vertical and upper part of the palatines is short and swollen, and the similar tracts formed by the pterygoids (*pg.*) are swollen also; the hamular processes are small, but sharp; they have used up the primary cartilaginous nucleus. Of the other investing bones to be seen in this aspect the squamosals (*sq.*) are the most striking; they are much larger than they seem to be from the side view, being curled round under the side of the skull in a remarkable manner. The postglenoid region is very large; the preglenoid a short free spike; the glenoid facet (*gl.c.*) looks forwards and a little inwards, and is, *at present*, a continuous selliform facet to the wide, thick infero-anterior lobe of the bone. Inside the hinder portion of the squamosal, the annulus tympanicus (*a.ty.*) is seen as a relatively large, very thin, imperfect ring of bone, bending upon the emerging primary mandible—MECKEL'S cartilage (*mk.*)—and supporting a wide membrana tympani (*m.ty.*); the hinder crus has a widened part or blade at its free end, and the fore end is dilated, but to a less degree. The vomer (*v.*) is seen in its hind part, with its forks, supporting the perpendicular ethmoid (*p.e.*).

Between the forks of the main vomer (*v.*), behind the middle ethmoid (*p.e.*) a small, thick crescent of bone is seen lying crosswise with its convexity forwards; this is the independent presphenoid (*p.s.*), a bone not found in the Hedgehog and Mole.*

On this face the orbitosphenoids are not seen, or very slightly (see figs. 3, 4, *o.s.*); the basisphenoid (*b.s.*) is separated from the presphenoid by a broad tract of cartilage; the bony tract is four times as long as that synchondrosis, and, in front, three times as wide. Behind, it is twice as wide, and so also is the spheno-occipital dividing cartilage; this is also somewhat more extended, axially, than the front tract. Here we have the abortive development of the large diagnostic Insectivorous basisphenoid; it is very large, has stout shoulders, on which the alisphenoids (*al.s.*) rest, but it is not specialised for pneumatic purposes. The anterior fissura lacera ends in the rounded notch between the forwardly-thrust alisphenoid, and the narrow anterior synchondrosis. These parts will be understood better when we come to the disinvested endocranium (figs. 3, 4); so also will the occipital arch and the auditory capsule.

The *side view* (Plate 31, fig. 10) is still more intelligible when the divided skull is seen from the *inside* (fig. 11); this also gives us one of the three views of the endocranium, as distinct from its ectocranial investing scale-bones.

This view of the skull of a Shrew, about the twelfth night after birth, should be compared with the counterpart figure of the skull of the ripe embryo (Plate 29, fig. 7); thus the decadence of the deep chondrocranium and the development of the superficial elements of the ectocranium will be understood. Measured along the basal line, the septal and ethmoidal (continuous) regions of cartilage are five-sevenths the length of the whole axial tract from the fore end of the snout to the foramen magnum; at birth that fore part was two-thirds the whole length. It is the snout which has lengthened most (relatively), as if to form a proboscis; but there is no segmentation of the cartilage enclosing the double tube. The basal line of the snout is strongly, that of the septo-ethmoidal region feebly, arched; nearly all the thick basal part is due to the development of that azygous median prepituitary (= pro-chordal) rod, the intertrabecula; for the trabeculae and cornua trabeculae run but a short distance forwards and only meet at the mid-line in the region immediately in front of the sella turcica. Thus the middle element of the cranial fore-growths is as large as in the Selachian Fishes and the embryo Bird. The foremost part of the septum (*s.n.*) is perforate—a very common thing in Mammals, the alae nasi throwing themselves out from the middle wall, in forming the valvular nostrils. Up to the anterior palatine foramina this wall is very low; it then gently rises up to the top of the rhinencephalic fossae, with the cribriform plate (*cr.p.*) as its floor; there is no crista galli projecting from the obtuse angle from which the great partition descends, twice as rapidly as it ascended, until it reaches the presphenoidal bony centre (*p.s.*).

The fan-shaped upper part of the great orbitosphenoid of the embryo (Plate 29,

* We shall see this again in *Rhynchocyon*; and it is also present in some of the lesser Rodents (at any rate in *Arvicola*, *Mus*, &c.). Nevertheless, it is a Marsupial character.

fig. 7, *o.s.*) is now much lessened (Plate 31, fig. 11, *o.s.*); its posterior band has been absorbed, leaving only a point to the hind corner of the wing; the hind edge is now ossified as the narrow orbitosphenoidal centre.

The oblique, notched, anteriorly-placed alisphenoid (*al.s.*) is only partly seen in this view, because of its great out-thrust; its base (*b.s.*) and the basioccipital (*b.o.*) are seen to be rather thick plates of bone. The other elements of the occipital arch (*s.o.*, *e.o.*) are set in a crescent, whose convexity looks backwards; all the synchondroses are large, as yet.

There are only two periotic bony centres—the prootic (*pr.o'*.) which forms the curious wall-plate, and the opisthotic, which builds-in the labyrinth.

The mastoid region behind, enclosing the posterior canal (*p.s.c.*), and the arch of the anterior canal (*a.s.c.*) are still invested with cartilage, but the common sinus, behind the cerebellar fossa, has a bony inner wall. Everything in this skull, as in that of the Mole, conforms to the dominant idea of a skull to be manipulated, so to speak, into a smooth, elongated borer, so that it may resemble the head of a Weevil (*Curculio*). Thus all the investing bones are thin, gently convex, and so imbricated as to thrust out no projecting points, externally.

This section shows the nasal, frontal, parietal, and interparietal (*n.*, *f.*, *p.*, *i.p.*) above; and the premaxillary, maxillary, palatine, pterygoid, and tympanic (*px.*, *mx.*, *pa.*, *pg.*, *a.ty.*), below. Infero-laterally, the trough-shaped squamosal (*sq.*) is seen from the inside as a narrow tract, arched above, but not reaching the rounded lower edge of the parietal, and the concave edge of the latter fails to reach the arched top of the prootic plate, thus there is a considerable lateral fontanelle or part formed of membrane only. Near the lower edge of the parietal, the lateral sinus (*s.c.*) throws its elegant arch over the inside of the skull, from the auditory capsule to the orbitosphenoid.

When the endocranium is seen divested of nearly all its investing bones, *from below* (Plate 29, fig. 4), we have what seems to be a remarkably imperfect skull, even considered as a *basin*, and not as a *box*. What we see is a remarkable result of *dwarfing* and *elongation*; there is a thrifty use of every kind of skeletal material, and the substances used have been thinned out as far as could be done safely. Yet the skull of a Child at the same stage, similarly prepared, would show the same elements disposed in a similar manner, and there would be little difficulty in recognising most of the homologous parts.

The conchoidal narial region (*e.n.*, *al.n.*), right and left, and the fluted double nasal tube, are seen to form a very perfect cartilaginous structure up to the part where the dentary region of the premaxillaries is attached. There the floor is cut away in a rounded manner, and the nasal labyrinth is open below, almost to its end, where its moieties do close in, independently of each other, right and left of the forks of the vomer (*al.e.*, *v.*). This open region begins by forming the long retral tracts that help to encapsule JACOBSON'S organs (figs. 4, 5, *rc.c.*, *j.o.*); there is no Mammal in which I have, as yet, been able more satisfactorily to work out these parts than in this young

Shrew; and this both in the dissections (Plate 29, figs. 4, 5), and the sections (Plate 30).

Where the perfect narial floor ends, there on each side of the intertrabecular base of the septum (Plate 29, figs. 4, 5, *s.n.*), a gradually increasing wing is given off, which, on reaching the notch in the premaxillary—between the dentary margin and the palatine process—at once expands, hooks itself round the front of the opening of JACOBSON'S organ, and then completely surrounds that organ for a short distance. The rest of the cartilage is like the bowl of a spoon, and protects the organ infero-externally. Along the inside of each retral tract the palatine process of the premaxillary (*p.px.*) runs as a vertical lamina, connate, apparently, as in the Mole, with the anterior paired vomers. Between the hinder third of these laminae the fore part of the long, normal, main vomer (*v.*) is seen. The inferior turbinal is developed from the inside of the lower edge of the nasal wall (*al.sp.*); the upper and middle turbinals (fig. 4, *al.e.*, *m.tb.*) from the inner face of the capsule in its dilated part. There, for some distance, the floor is very deficient, the wall, simply bending inwards, with a sinuous selvedge underneath; at the end it finishes in a sort of pouch, right and left of the forks of the vomer.

Where a kind of secondary *desmognathism* is made by the vomer (as in Passerine Birds), there a small oblong tract of bone runs in between the main vomer and the ossifications already forming in the nasal wall and floor; these little bones are the posteriorpaired vomers (*v''*). Behind the short exposed tract of the perpendicular ethmoid (*p.e.*) the small crescentic presphenoid (*p.s.*) is seen, with its concavity looking backwards; a tract of cartilage, larger than this bony centre, separates it from the next bony tract—the basisphenoid (*b.s.*).

The semiosseous orbitosphenoids are partly hidden in this view, but are fully shown in the upper (fig. 3). The posterior sphenoid is well displayed in this aspect. The basal bone (*b.s.*) is inordinately large for a Mammal, but small and aborted for an Insectivore. It is, roughly, an equilateral triangle, with its hinder angle truncated, and its anterior side transverse to the cranial axis; the imperfect lateral margins are sinuous, so that there is a rounded lobe at each angle; this is the arrested "tympanic wing." The alisphenoids (*al.s.*) are sutured to the fore edge of this lobe, right and left, and run forwards and a little outwards; their rounded fore angle is not quite ossified.

Each bone is a rough, notched, snaggy wedge; the notch is on the outer margin, just a little in front of the projecting hinder angle or lobe. This is the imperfect foramen ovale (*V³*); it is a large vacuity, as seen from below. The scarcely ossified fore end is rounded on its inside; it reaches to the middle of the incurved nasal floor (*al.e.*) much beyond, and some distance below, the orbitosphenoid (*o.s.*); the inner margin is notched both at this front part and at the hinder third. There is a considerable membranous space between the alæ and the narrow fore part of the base, right and left.

Then there comes, behind and outside the posterior sphenoid, a very large space, in the dissected endocranium, which in the perfect skull (fig. 2) is only partly filled in by the squamosal (*sq.*). This was the case very remarkably even in the skull of the embryo (fig. 7), but the auditory capsule has not grown so much, since, as the rest of the skull and snout (figs. 3, 4); it scants very much towards the great semicircular space developed for its reception. The small perforated ala of cartilage seen in the embryo growing right and left, from the basisphenoidal region (Plate 29, fig. 7; and Plate 30, fig. 18), and coiling round the front of the cochlea—helping to complete the setting—is now absent; it has evidently been used up in the ossification of the cochlea (*chl.*); it now exists as the toothed rim of its semicircular fore part. There is still some cartilage between the prootic plate (*pr.o'*) and the main part of the capsule; and also behind the bony top of the epihyal (*e.hy.*), as well as on the inner face, above (Plate 31, fig. 11). The coils of the cochlea (*chl.*), the fenestra ovalis and fenestra rotunda (*fs.o.*, *f.r.*), and the great fissure widening for the exit of the 9th and 10th nerves (IX., X.) are clearly seen in this lower view.

The wide basioccipital (*b.o.*) with its semicircular notch in front of the foramen magnum; the large reniform condyles (*oc.c.*); the exoccipitals (*e.o.*) separated by a large tract of cartilage from the base, and that tract perforated by the 12th nerve (XII.), are also shown. There is scarcely any paroccipital ridge to the exoccipital bone, which, above, is separated by a definite tract of cartilage from the large, shield-shaped supraoccipital (*s.o.*).

In the *upper view* (Plate 20, fig. 3) the nasal labyrinth is complete (*al.n.*, *al.sp.*, *al.e.*), and ends above, as below, in a rounded lobe right and left. The fluted top part is very uniform up to the proper olfactory region; that region is ossifying, rapidly, in its middle. The grooved top, formed by the septum (*s.n.*) does not end in a cartilaginous crista galli; from the median, notched part the margin of the nasal roof is first concave, and this swells into the lateral, terminal convexity.

The great perforated floor, or lamina cribrosa (*cr.p.*), has, outside, a sublobate edge; the rest is evenly semicircular; more than half of the plate, with the top of the perpendicular ethmoid, is ossified. In this curiously scanted skull there is a considerable membranous space between the cribriform plate and the orbitosphenoid; these tracts (*o.s.*) are remarkable in several ways, and are almost the least normal of any I have yet seen in the Eutheria. The top part is still fan-shaped, but the whole of the large posterior band (see fig. 7, *o.s.*) is gone. The sharp angle left is now ossified separately (*o.s'*), and the stem (*o.s.*) is also bony; it does not reach more than two-thirds of the way to the upper margin of the wing. The lower end is pedate, and is beginning to form a suture with the base (*p.s.*); it is then reduced to a mere rod, which curves forwards and backwards twice, becoming flat, but still narrow, above.

There is no optic foramen, as in Marsupials; but in front of the main bar, below its middle, there is, in a notch, a separate spicule of bone (*o.s''*), a third bony centre to

this abortively developed orbitosphenoid. The sphenoidal fissure is a long space under the orbitosphenoidal bar, and over the alisphenoid; through it, not only the *orbital*, but the *optic*, nerves also pass. The hinder half of the alisphenoid (*al.s.*) only can be seen in this view; the bone is twisted over the notch for the 3rd branch of the trigeminal (*V³.*). The notches and shoulder of the basisphenoid (*b.s.*) are well seen; there is scarcely any *sellar* concavity on its upper face. Much cartilage is still seen in the synchondrosis between the two basal bones and between the elements of the occipital arch; and also, above, where the auditory and supra-occipital regions unite. The cartilage in the auditory recesses (see Plate 31, fig. 11, *a.s.c.*, *p.s.c.*) are scarcely visible in this aspect, but the capsule appears to be almost wholly ossified; the base of the floccular recess, the holes for the portio mollis (*VIII.*), and the bridge under which the portio dura (*VII.*) runs, are well seen. In front of the very shallow *meatus internus* the capsule sends forwards a bony snag, which helps the toothed rim of the cochlear region to give some bony support to the largely membranous region in front of it.

Third Stage (continued).—Dissections of the visceral arches of the young Shrew.

I have not figured the fore half of MECKEL'S cartilage, which still persists, not larger, but not evidently lessened, inside the lower jaw (see Plate 29, fig. 2). Towards the malleus (Plate 29, fig. 6, *mk.*) it is seen as a solid terete rod, having a bony style supporting it further forwards than the manubrium (*mb.*) extends. But that primary style of bone has grafted itself upon, and set up extensive ossification in, the head of the malleus (*ml.*). This rambling bony tract has forced its way down to the neck of the manubrium, but has left a large core of cartilage in the middle of the head. The partly bony head of the malleus is quite normal, and has the tensor tympani (*t.t.m.*) attached to its inner face; but the manubrium and the posterior angle of the part from which it springs are very remarkable. The slender manubrium looks like the tube of a retort, the bulb of which is imitated by the angle; the main part of the head projects well, backwards, below the articular facet; the bony matter then forms a ring round a contracted tract, or waist; from this part the bulbous tract hangs, so to speak. Thus the bulbous head, the enlarged body, and the subglobular "angle" form three enlargements, all in one line, and that at a right angle to MECKEL'S cartilage, and to the manubrium. The incus (*i.*) is rather small, and its articulation with the malleus is becoming indistinct; the short crus (*s.c.i.*) is very short; the long crus (*l.c.i.*) is rather longer than ordinary; the head is unossified, and so also is the inturned orbicular facet.

The stapes (*st.*) is large, relatively, and has a perfectly stapedia shape; it is nearly all bony, the top and base being still soft; I could not find any separated interhyal in the tendon of the stapedius muscle (*st.m.*).

The short crus of the incus fits into a little cup close above the part where the

epihyal (*e.hy.*) has fused with the auditory capsule; here the bone (*au.*) extends; but the main part of the unusually well-developed epihyal is still cartilaginous, and is continued without any segmentation into the unossified part of the ceratohyal (Plate 29, fig. 6; and Plate 31, fig. 12, *c.hy.*). Half the upper ceratohyal is ossified—its middle part; then comes a joint, and then the short, lower ceratohyal (*c.hy'*), which, in turn, articulates with the short, ossifying hypohyal (*h.hy.*).

The latter, in turn, articulates with the almost straight, transverse, nearly ossified basihyal (*b.h.br.*), which has, articulating with it, the ossified, short thyrohyal rods (*t.hy.*).

Third Stage (concluded).—Vertically transverse sections of the Nestling Shrew.

A description of these sections will throw further light upon the structure of the skull at this stage.

Section 1 (Plate 30, fig. 1).—This is through the outer nostrils (*e.n.*), and shows how the roof (*al.n.*) turns inwards to form the narial valve, and how the floor, also, of the opening, is cartilaginous; many of the *vibrissæ* are seen in section in the thick skin of the snout, in this, and in the following sections.

Section 2.—Here (Plate 30, fig. 2) the narial valve is seen in the hind part of each nostril; it curves downwards at its free end; the *alæ nasi* (*al.n.*) are confluent, back to back.

Section 3.—In this (Plate 30, fig. 3) there is a definite tract of the septum nasi (*s.n.*) with an enlarged—intertrabecular—base. The narial valve is gone, and the cartilage that formed it is now confluent with the floor, so that there are two perfect narial tubes (*n.p.*) at this part.

Section 4.—At this part (Plate 30, fig. 4) the floor and walls are separating, again; the floor, right and left, touches the lower part of the septum, which is carinate below its bulbous part.

Section 5.—The tubes now (Plate 30, fig. 5) are not surrounded, below, by cartilage, and the floor is in two short, oblique tracts; the almost vertical wall turns inwards below, and the septum, still carinate, is much thicker; these narrow floor-tracts are those that give off JACOBSON'S (=recurrent) cartilages (Plate 29, fig. 5).

Section 6.—We are now (Plate 30, fig. 6) behind the snout, and through the premaxillary (*px.*), with its thin walls, and its relatively huge incisor teeth (see also fig. 7, *t.*) just developing in these large, swelling pulps. The double tube is contracted here, the top is still flat, and the septum (*s.n.*) is very thin above and thick below; the enlargement at the bottom of each inturned wall (*al.sp.*) is the rudiment of the inferior turbinal (*i.tb.*), at its very beginning, in front. The rods of the recurrent cartilages (*rc.c.*) are seen lying obliquely below the bulbous intertrabecula (*s.n.*); below, the fore part of the lower lips are seen in front of the dentary bones (*mn.*).

Section 7.—This (Plate 30, figs. 7, 7A) is through the fore part of JACOBSON'S

organs (*j.o.*) and the perfect part of the cartilage. The roof (*al.sp.*) is now arched, with a very small median groove; this roof is very thick for some distance, and then thins out below, where it is bulbous. The upper three-fifths of the septum (*s.n.*) is of the same thickness as the main part of the roof, and then suddenly swells into a large bulb, with a flattened basal outline. Here the cartilaginous capsules of JACOBSON'S organs (*rc.c.*) are at their perfect part. They are solid above, and nearly vertical where they fit obliquely to the septal base; then they curve outwards to form an oval cavity (for JACOBSON'S organ, *j.o.*), and are keeled and turned inwards below. In the middle of the pyriform space between them the thin palatine plate of the premaxillary is seen to rest obliquely on the top of the inner face of the tubular part. The nasal passage opens into the palatal space below; the nasals (*n.*) are cut through above, and the fore part of the maxillaries (*mx.*) with a tooth and its pulp (*t.*) on each side. Three mucous follicles (*m.s.*) are seen in the interspace between the mucous membrane and the aliseptal cartilage. This part is close behind the anterior palatine foramina, and here the palate is rugous and sub-carinate in the middle.

Section 8.—This (Plate 30, fig. 8) is through the open part of the recurrent cartilages (*rc.c.*) and the hind part of the palatine processes of the premaxillaries. The thick aliseptal wall has now formed a definite rudiment of the nasal turbinal (*n.tb.*), but the rudiment of the inferior turbinal (*i.tb.*)* is still very imperfect. The nasals were present, but not figured, and part of the maxillaries (*mx.*), with a pulp, are cut across and the fore part of the vomer (*v.*). Also, below, the dentaries and their teeth-pulps (*d.*) are seen.

Section 9.—Here (Plate 30, fig. 9) the vomer (*v.*) comes fully into view behind the palatine processes of the premaxillaries (see Plate 29, figs. 1, 2, 4, 5). The nasals (*n.*), and the maxillaries (*mx.*), with their palatine plates ascending to articulate with the vomer, are all clearly seen. Also the dentaries (*d.*) below, with their teeth. Here the nasal and inferior turbinals (*n.tb.*, *i.tb.*) have good rudiments. The front of the tongue (*tg.*) and the lower jaw (*d.*) have been cut through, below.

Section 10.—Here (Plate 30, fig. 10) the nasal labyrinth is widening towards the true olfactory region; the septum is deeper and less bulbous below. The inferior turbinal rudiment is no longer seen, but the nasal (*n.tb.*) is still in view. The nasals, maxillaries, and dentaries (*mx.*, *d.*) are still seen in section.

This section is behind the angle of the mouth; the tongue (*tg.*) is now at its middle.

Section 11.—Here (Plate 30, fig. 11) the eye-balls (*e.*) are cut through their front part, and the nasal labyrinth, largely osseous, is cut across where the nasal, upper, and middle turbinals (*n.tb.*, *u.tb.*, *m.tb.*), can all be seen; the floor is ossified at this part. The nasals, vomer, maxillaries, and palatines (*n.*, *mx.*, *pa.*) are here cut through, and the dentaries (*d.*) below. In the last (fig. 10) the nasal passages

* The line in the figure is carried too low.

were separate, here they communicate, below, under the vomer; here the middle of the palatine skin is keeled again; it was flat in the last two sections

Section 12.—In this section (Plate 30, fig. 12) the fore part of the olfactory lobes (C^{1b}) are cut across as they lie in the large fossæ upon the ossifying cribriform plate (*cr.p.*). Part of the roof-cartilage is seen right and left, and from the walls and floor copious turbinal growths (*u.tb.*, *m.tb.*) are seen. Here, the frontals (*f.*) are perfect and roof the whole over, whilst below, the palatines and vomer (*pa.*, *v.*) are seen in section, protecting the small, square naso-palatine passage (*n.p.c.*).

Here the perpendicular ethmoid (*p.e.*) is spear-shaped above, and clubbed below; it is very thin for the most part. The jugal process of the maxillary (*j.*) is seen, the mandibles and teeth (*d.*), with tongue, below.

Section 13.—This (Plate 30, fig. 12A) is from a little further back behind the general roof, and where the frontals (*f.*) do not meet in the middle; one description may serve for both of these sections.

Section 14.—This (Plate 30, fig. 13) is through the hemispheres (C^{1a}), the great fontanelle, at the back part of the frontals (*f.*), and the large orbito-sphenoidal wings (*o.s.*); the basal part, here, is behind the middle ethmoid, and is the front of the presphenoid. The cribriform plate still comes into section in its hindmost part; this is where the skull-walls (*o.s.*) are united to the olfactory capsules. This is behind the vomer, and the low bulbous section of the basis cranii (*p.s.*) lies over a triangular section of the nasopalatine passage. The bony alisphenoid (*al.s.*),* is seen outside the nasal wall.

The palatines and pterygoids overlap at this part, and here the frontal (*f.*) gets well under the skull in the imperfect orbit.

The articular and angular processes of the lower jaw (*cd.p.*) and MECKEL'S cartilage (*mk.*) are cut across, close in front of the ear-drum.

Here the nasal cavities are small, oblique, and reniform in section, in this, their retral subcranial part. The wall, although well coiled round the cavity, does not completely wall it in; the median cartilage (*p.s.*) is some distance from the walls.

Section 15.—In this partial section (Plate 30, fig. 14), the basioccipital (*b.o.*) is cut across in its front part; on the side, at some distance, the cochlear and part of the vestibular region of the auditory capsule are cut through; the wall, very thin, is ossified. The prootic plate (*pr.o'*) is seen in section, with the hind part of the squamosal (*sq.*) outside and below it. The ossifying opisthotic region, outside and below the vestibule, shows the facial nerve (VII.) in its whole course—infra-cranial, auditory, and extra-cranial—escaping close behind the sigmoid hyoid arch (*e.hy.*, *c.hy.*); the stapes (*st.*) is partly seen, and also the folds of the concha auris (*mc.*, *m.a.e.*).

Section 15.—In this still more limited section (Plate 30, fig. 17) the ossifying auditory capsule is cut through across the fenestra ovalis (*fs.o.*) and the bar between it and the fenestra rotunda. The well-formed stapes (*st.*) is seen *in situ*; its head and neck and

* The line in the figure is too short.

its base are still cartilaginous, and the long crus of the incus (*l.c.i.*) has its distal part attached. The opisthotic and epihyal (*e.hy.*), at their junction, are cut through, and the continuation of that bar, unossified, into the ceratohyal (*c.hy.*). The facial nerve (VII.) is seen escaping from the foramen stylomastoideum.

Section 16.—In this section (Plate 30, fig. 15) more than half is figured; it shows the basis cranii (*b.o.*) cut through in the fore part of the foramen magnum; the fore part of the condyles (*oc.c.*) are in section; and the atlas and axis (*at.*, *ax.*) also come into view. The occipital roof (*s.o.*) is ossified above, and below, runs (*s.a.c.*) into the top of the auditory capsule over the anterior canal (*a.s.c.*). Below, the posterior canal (*p.s.c.*) is cut across; the thin, inner wall of the vestibule is ossified; the thick outer part is still cartilaginous.

Fourth Stage.—The skull of the adult Shrew (Sorex vulgaris).

The interpretation of the skull in its perfect state will now be easy, in spite of its great unlikeness to that of an ordinary good-sized Mammal, or even of that of a typical Insectivore.

Seen *from above* (Plate 31, fig. 1) the peculiar tenuity of this small skull is shown; the long bi-tubular snout (*al.n.*) is half the length of the dorsal line of the ossified cranium. Laterally, however, the projecting premaxillaries (*px.*) protect the cartilage in its hinder third. The preorbital region and half the orbital, together, from one continuous bony growth; faint signs only of the sutures between the nasals, frontals, premaxillaries, maxillaries, and lachrymals (*n.*, *f.*, *px.*, *mx.*, *l.*) being visible. The tooth-sockets make the sides sinuous, and they only diverge, increasing the breadth very gently, up to the jugal processes of the maxillaries.

The foramen infraorbitale (V^2) is very large, and well seen in this aspect; the space between the frontal and the jugal process of the maxillary is a sharp notch. From that notch to the general swelling of the hind skull the cranium enlarges but little; the upper part of the coronal suture runs straight across the middle of the skull-waist; it is well-toothed and somewhat squamous, the frontals (*f.*) being imbricated by the parietals (*p.*). The frontals are but little larger than in a Snake; but in that Reptile the frontals remain distinct, whilst the parietals coalesce—just contrary to what takes place in this little Mammal. The parietals (*p.*) cover about four times as much space as the frontals, they are far from each other, and from all the surrounding bones, except the squamosal, in front. The sagittal and lambdoidal sutures are well-toothed, like the coronal; the general surface of the bone is smooth—polished, as it were—and gently convex. The fore part, helping to form the orbits, is narrow; the rest becomes almost twice as wide. Flanking the frontals the squamosals can just be seen, giving additional width to the temporal region. The middle half of the lambdoidal suture has, set in it, a transverse plate of bone which projects forwards into the notched parietals in front, and lies straight along the fore margin of the supra-occipital (*s.o.*), behind; this bone, which is slightly crested, is the interparietal (*i.p.*).

The interparietal is small for an Insectivore, but the true supraoccipital (*s.o.*) is unusually large, and suggests at once a Monotrematous relationship. The thrice-convex hind margin is wide, but the fore edge runs across the skull to the post-temporal region, and is nearly as wide as the two parietals, together, at their widest part. Moreover, the tract covered by the supraoccipital tegmen is almost as extensive as that which is covered by the frontals.

In the *side view* (Plate 19, fig. 3) the peculiarities of the Soricine skull are well shown; a Mammalian skull, truly, but reduced to its utmost tenuity. There is a general parallelism in the downward and forward curve of the various parts; the snout also is thus followed by the premaxillaries (*px.*), with their notched and ferruginous teeth—like the mandibles of a Beetle—and the elements of the skull, further back, dip in front, in like manner.

Back, as far as to the coronal and squamous sutures, which are largely persistent, there is no sign, in this view, of composition; the badly formed orbit has the frontal coming well down on its inside, but it merely dips inwards a little, it forms no brow; nor is there any definite post- or preorbital wall or outwork.

For such a snout the maxillary nerve (V^2 .) has to be very large, for the lips are thick, and the *vibrissæ* well developed; the canal, therefore, is very large, and it is perfected by the maxillary, which has a stump of bone in the jugal region; the canal-wall for the infraorbital nerve is itself perforated. The lachrymal (*l.*) is melted into the fore edge of the maxillary, and the sphenoidal wings, front and hinder (*o.s.*, *al.s.*), are all confluent with the overlying membrane-bones; so also are the palatine bony tracts with the bones above them. In the inner and lower face of the undefined orbit, the sphenoidal fissure (II., $V^{1,2}$.) is seen as a large channel, opening obliquely; this is due to the fact that the alisphenoid (*al.s.*) embraces the orbitosphenoid (*o.s.*), growing freely outside it.

The curious, low-lying, oblong squamosal (*sq.*) opens in front as two short blunt blades, which seem to bite the outspread alisphenoid; this is due to the fact that, whilst the jugal process is aborted and has no jugal bone to lie upon, the condyle (glenoid cavity) has become subdivided into two tracts of articular cartilage, one above and one below. Thus the two-faced condyloid head of the lower jaw (figs. 3, 4, *cd.p.*) is really held between the two blades of the squamosal. In the crescentic hollow behind these blades the normal pneumatic foramen is seen; the bone there is narrower, then broadens somewhat, and then, dipping gently, ends as a rounded or ear-shaped lobe in the re-entering angle formed by the prootic plate (*pr.o.*), and the mastoid region of the ear capsule (*op.*). Under its concave edge—greatly turned inwards (see fig. 2, *sq.*)—the tympanic (*a.ty.*) can just be seen. The structure of the skull in the temporal region is very elegant; the larger hind skull is finished by the large parietals (*p.*), which imbricate the frontals in the postorbital region, and throw themselves backwards and downwards, over the hinder auditory region, clamping all the parts with their toothed edge. They come down with a straight edge to the

slightly overlapping squamosals, with which they partly coalesce, and then ride over the prootic plates, with a concave edge; then, as if for purposes of architectural ornament, the "lateral sinus" (*s.c.*) throws its low arch over the whole of these temporal sutures; three foramina are seen close to it, one in front, one in the middle, and another over it, near its hind part.

Wedged in between the parietal and squamosal, the curved prootic plate (*pr.o'*) is seen; its fore-part is like a pruning knife; its hind part passes insensibly into the epiotic and opisthotic regions, where the three canals (*a.s.c.*, *h.s.c.*, *p.s.c.*), by their burrowing, mark the outer face of the bone, which is very thin over them. The occipital condyles (*oc.c.*), are large, bold, and pyriform in outline; between them and the opisthotic region (*op.*) the ex-occipitals (*e.o.*) are wedged, scarcely forming any definite paroccipital process. Over the whole, like half a dome, the great supraoccipital (*s.o.*) is seen.

The lower jaw (seen from the *inside*) is very small, but strong; it is hinged half way between the front of the nasal bones and the occiput. The coronoid process (figs. 3, 3a, *c.p.*) is high, vertical, and scooped on its inner face; the articular process (*cd.p.*) is sub-triangular, thick, and has a two-faced condyle (*gl.c.*); the angular process (*ag.p.*) is long, terete, and incurved at its end; the dentary canal (neuro-vascular passage) begins under the muscular fossa of the coronoid process. The teeth, here, as above, are curiously mimetic of the mandibles of Coleopterous Insects—the food, especially of the Shrew, who, himself, is less than some of the members of the Beetle Family.

In the *lower view* (Plate 19, fig. 2) the snout (*al.n.*) is partly supported by the protruding incisors; and the bony palate, between the fine dental armature, is a high triangle, whose short base is behind; this boundary is directly transverse, but somewhat bracket-shaped, and is strongly limbate. The longitudinal extent of the pre-maxillaries (*px.*) is one-seventh that of the whole hard palate; they are very partially distinct from each other, and from the maxillaries (*mx.*); the anterior palatine foramina (*a.p.f.*) are small. So also are the posterior foramina (*p.p.f.*), and they are some distance in front of the persistent palato-maxillary suture. The fused maxillary plate is subcarinate in its middle third, under the junction of these bones with the vomer; the fore half of the middle palatine suture persists, and that part of the hard palate has four small foramina; its fore margin wedges in between the maxillaries, and yet its extent is less than half of the plate formed by the latter bones.

The jugal processes of the maxillaries projecting beyond the last tooth-socket make the narrow-waisted part, next following, very remarkable. In the distance, the orbital plates of the frontal and the rounded supraorbital edge are seen beyond the open region of the palate. The thick, spongy walls of the nasopalatine passage (*n.p.p.*) are equal in width to that passage; and the roof, where the forks of the vomer (*v.*) end, is perforated with holes and slits.

The pterygoids and palatines (*pg.*, *pa.*) are thoroughly fused together, and are equally confluent with the posterior sphenoid (*al.s.*, *b.s.*). The hamular processes

of the pterygoids are small, terete, short, parallel, and unusually near together. Behind them there is a small foramen, right and left, and still further back, another pair of holes, wider apart, near the junction of the basisphenoid with the basioccipital (*b.s.*, *b.o.*). The basis cranii, from the perpendicular ethmoid (over the thick hind rim of the hard palate) to the foramen magnum, is a peculiar structure; in front it is narrow, but behind the pterygoid hooks it widens out rapidly into two triangular wings, where the ali- and basisphenoid are anchylosed together. The basal plate then narrows gently and sinuously up to the middle of the basioccipital region, and then gently widens to the end, until it becomes just half the width of the widest sphenoidal part. The median part is made into a broadish and rather shallow groove by a thick, ribbed part, the rudiment of the hinder part of the tympanic wing of the typical kinds; these thickenings run up to the occipital condyles; but they do not enlarge the tympanic cavity. The inner (and also lower) facet of the glenoidal cavity (*gl.c.*) turns inwards and lies under the *foramen ovale*—now perfected by a bony hinder bar;—so that this hole is not seen, either laterally (fig. 3) or from below (fig. 2); the longitudinal direction taken by this nerve passage is indicated in both figures by a bristle (*V*³). The inner edge of the squamosal, where it curls under the skull, is sinuous; it diverges from the outer edge of the basis cranii, so as to leave a large space, the hind margin of which is finished by the opisthotic region of the auditory capsule (*op.*). This pyriform space, with its wide end behind, is as large as the dilated posterior sphenoidal region of the basal and basilateral parts of the skull; it is largely finished by membrane—a permanent basilateral fontanelle. This space in the macerated skull occupies nearly all the side of the hinder or postorbital part; it is heart-shaped, being filled in somewhat in front by the postglenoid wing of the squamosal (see fig. 3). In the undisturbed state of the parts where the huge auditory capsule is kept in its place by ligamentous tracts, the hinder and outer part of each great fontanelle is filled in by that complex, intercalated labyrinth.

But on the lower face, between the squamosal and the basis cranii, this fontanelle is only partially latticed across by the small *annulus* and the *ossicula*, which, with the drum-membrane, only half hide this great gap. In this under aspect the cochlea (*chl.*), that part of the vestibule which passes into the tegmen tympani and overarches the facial nerve and ossicula, and the part containing the horizontal and semicircular canals (*h.s.c.*, *p.s.c.*), are all well seen. The large, pyriform condyles (*oc.c.*) and the oval foramen magnum (*f.m.*) surrounded by the elements of the occipital arch (*s.o.*, *e.o.*, *b.o.*), are shown in this view.

When the auditory capsules have been loosened out by maceration, and are examined separately (figs. 4 and 5; oblique views of the *inner* and *outer* side), then we find that the capsule has used up and carried with it, in its ossification, a large amount of the primary endocranium, not properly belonging to the capsule. Not only is there a pterotic and a sphenotic tract of this kind, but, as I have already shown, the small alæ that originally grew from the basis cranii behind the pituitary region, have been

ossified by the corresponding opisthotic centres, and made to serve as a rim to the cochlea.*

Seen obliquely from the outside (fig. 5) there is, above and in front, the shell-like prootic plate (*pr.o'*), and below it a similar, but lesser wing-like growth of bone. The cochlea (*chl.*) is also crested, the crest running forwards into a sharp point. A notch still persists where the two bony centres meet in front; below that notch the canal for the facial nerve (VII.) is seen at both ends, and below and outside its foramen of exit (stylomastoid) a thick, hooked club of bone runs across between and outside the two fenestræ—fenestra ovalis, and fenestra rotunda (*fs.o.*, *f.r.*); the clubbed part is the stump of the epihyal (*e.hy.*) confluent with the capsule.

The anterior canal (*a.s.c.*) shines through the thin bone, and the posterior and horizontal canals (*p.s.c.*, *h.s.c.*) project from the surface of the opisthotic region.

On the inside (fig. 4) the anterior canal stands out as an elegant arch over the deep and large floccular recess, which is bounded behind by a sharp crest of bone inside which is the common sinus of the anterior and posterior canals. Three convexities are seen below the recess; these are, from before backward—the ampulla of the horizontal canal (*h.s.c.*); that of the anterior (*a.s.c.*) and the third rising is formed by the vestibule (*vb.*). Below these mammillary risings the great porchway for the auditory nerve (VIII.) and the bridge over the facial (VII.) are shown; and there is a small tube behind, on the edge of the capsule: in front of these foramina the coils of the cochlea are partly hidden by the limbation of its margin, running into the anterior sharp process.

The small, strong annulus (figs. 6, 7, *a.ty.*) quite enclose an oval space, although the crura do not coalesce; the hinder crus has a broad, bilobate end, which overlaps the somewhat pointed end of the front crus, and from the *outside* (fig. 6) partly hides the manubrium mallei (*mb.*). The fore part of the annulus projects, being also dilated considerably; below, and at both ends, the outer face is convex; the upper crus is ridged and grooved below the ridge. On the inside (fig. 7) there is but little concavity; this is for about a third of the inner rim, in front of the sharp groove on which the processus gracilis of the malleus (*p.gr.*) lies.

That process is styloid, slightly decurved, and diverges from the manubrium, which runs straight along the long axis of the elliptical space formed by the annulus for the membrana tympani; it traverses three-fifths of that axial line; and is very slender and straight, with a gently bulbous free end. The neck of the malleus (*ml.*) is flat, and rises suddenly into the rounded head, which is confluent with the head of the incus (*i.*). Half-way down below the condyloid region the bone projects as an obtuse

* There is nothing *new* in the morphology of the skull; in the Frog each of the three great lateral bony centres that harden the chondrocranium takes up both a sensory and a cranial tract; thus we have a "sphenethmoid," a "prootico-alisphenoid," and an "opisthotico-exoccipital." In osseous Fishes the semicircular canals run far into proper chondrocranial regions, and are ossified by tracts that have a double morphological significance—*e.g.*, the "sphenotic" and the "pterotic."

angle, the hinder edge is then notched twice, and then comes the solid bulbous "posterior angular process" (*p.ag.*) of this highly modified "articulare." The main part of the malleus has ribbed edges, is limbate, and the neck is flat and thin; on the inside the root of the manubrium is thick and rough.

The incus (*i.*) shows signs of degradation, being fused with the malleus and reminding the observer of the arrested and, in the adult, fixed state of that segment of *Echidna*. The short crus (*s.c.i.*) is a mere snag; the long crus is very long, feeble and bent forwards; the neck of the orbicular condyle is well bent, very thin, and carries a well-made circular facet for the stapes. That bone (fig. 8, *st.*) is a miniature model of a stirrup, thoroughly normal, and unusually perfect in form. The hyoid arch, proper (Plate 31, fig. 9), has become much stronger, and yet more slender, than in the young stage (fig. 12). The cartilaginous continuation of the epihyal, from its bony stump (fig. 5, *e.hy.*) to the top of the upper ceratohyal (fig. 9, *c.hy.*), is a complete band of cartilage; the next tract is slender and curved, and is unossified in its lower third; the lower ceratohyal (*c.hy'*), the hypo-basi- and thyrohyals are largely ossified; the latter (*t.hy.*) are much longer now, and are bent outwards in the middle.

The interior of the skull was not figured; nor any of the figures made from an *old* specimen. The cribriform plate is very large, oblique, and richly perforated; the median ethmoid, between its halves, is thin, but strong; all the parts, inside the front of the cranial cavity, are well ankylosed together. The orbitosphenoids have very narrow edges to the hind margin of the cribriform plate; the basisphenoid has a very slight sellar depression. In old skulls the parietals coalesce with the frontals and with the fore half of the upper part of the squamosals; so that the sutures left are the hinder main part of the sagittal, that between the parietal and interparietal, and the hind part of the squamous suture.

Yet these remains of sutures, the independence of the extensive auditory capsules, and the general thinness and elasticity of the larger bony tracts defending the brain, all help to make this small skull more or less flexible under accidental pressure.

I have not added certain figures made from the skull of the adult Water Shrew (*Crossopus fodiens*); it merely differs from that of the Common Shrew (*Sorex vulgaris*) by its larger size, greater robustness, and a somewhat more intense ossification generally. The orbitosphenoids are wider, and the "foramen ovale" is quite visible on the lower aspect of the skull; in the common kind (Plate 31, fig. 2) the bristle (*V*³) is seen to pass over the incurved *lower glenoid* process; there is a notch between it and the hind corner of the alisphenoid (*al.s.*), and then a bridge of bone between this notch and the fore-end of the great infero-lateral fontanelle. In *Crossopus fodiens* the emerging nerve is bounded in front by a tract of bone, where the notch is in the lesser third; here it appears to pass through the neck of the lower glenoid process; as a matter of fact, the foramen is made by the confluence of the alisphenoid with that part of the squamosal.

On the skull of the Centetidae.

My materials for working out the structure and development of the skull in this peculiarly Mascarene Family of the Insectivora are as follows :—

A. Stage 1.—An embryo of the largest kind—*Centetes ecaudatus*—7 lines long, (head 3, body 4), (Plate 16, fig. 13); this is intermediate between my 1st and 2nd Stages of the Mole (Plate 1, figs. 1, 2, 3).

Stage 2.—A three-fourths ripe embryo of *Centetes ecaudatus*, $1\frac{1}{2}$ inch long.

Stage 3.—Young individuals of *Centetes ecaudatus*, $3\frac{1}{4}$ inches long.

B. Almost adult specimens of *Hemicentetes madagascariensis* and *H. nigrescens*.

C. An adult *Ericulus nigrescens*.

D. An adult (or nearly) *Microgale longicaudata*.

Stage 1 (Plate 16, fig. 13).

In the smallest embryo the snout is just beginning to project from the front of the face; the brain vesicles (C^{1a} , C^2 , C^3 .) are very large; the eye-ball is very small, and surrounded by a circular lid; the concha auris has commenced its folds; the limbs are mere flaps; and the tail is, relatively, longer than in the more advanced specimens; the head is very large, relatively.

Stage 2.—Embryo of Tenrec, Centetes ecaudatus, $1\frac{1}{2}$ inch long (Plate 16, fig. 14).

The head is still (*and always will be*) very large in proportion to the body; the tail is a mere stump, the limbs are well-formed. The eyes, and their lids, are very small, and so are the outer ears; the snout is now a considerable structure, running in front of the lips.

The skull (Plate 32) has acquired a large amount of solidity from ossification, both external and internal; the whole structure is very evenly conical, with the snout as its obtuse apex.

The investing bones.

Seen from above (Plate 32, fig. 1) the endocranium only comes into view at the two ends; behind, it is largely ossified. The scale-like superficial bones of the roof, the nasals, frontals, and parietals (*n.*, *f.*, *p.*), show their radiating lines of growth; as to size, the nasals are broader, the frontals much longer, and the parietals much shorter than in the Mole and Shrew; they are more normal in this type. A large fontanelle (*fo.*) still exists above, it spreads into sharp wings, right and left, in the coronal region, and in the lambdoidal to a less degree, where it runs back as a large semicircular notch in the huge, roughly crescentic interparietal (*i.p.*). Here this superficial cranial element that is absent from all the Edentata except *Orycteropus*, but constant in the Insectivora, as in the Marsupials beneath them, attains its highest

relative development. The premaxillaries and maxillaries (*px.*, *mx.*) are not well seen in this view.

In the *side view* (fig. 3) the premaxillaries (*px.*) are of the average size, and show a diamond-shaped oblique facial plate, which wedges in between the nasal and maxillary on each side. The maxillaries (*mx.*) are nearly half the length of the whole bony skull; the postero-superior angle runs somewhat into the orbit, and inside this process, and the one below it, the small lachrymal and its canal (*l.*, *l.c.*) are seen. That space is triangular, but under the sharp style that bounds it below, there is a deep chink along which the maxillary nerve (V^2 .) passes; it is unprotected on its outer side; behind this chink the general alveolar roof runs for a considerable distance.

The frontals (*f.*) have a thick supraorbital edge, and a large concave orbital plate. The growing parietals (*p.*) run forwards obliquely under the postorbital edge of the frontals, just meeting the upper and front angle of the alisphenoid (*als.*). Thence, each parietal runs backwards to the antero-external edge of the azygous interparietal (*i.p.*); the obtuse re-entering angle formed by their junction exposes the huge auditory capsule.

There are no jugals; each squamosal (*sq.*) applies its small squamous plate over about a third of the lower edge of the parietal, rather in front of its middle. The jugal process does not reach so far forwards as the squamous; it only serves to carry the glenoid facet (*gl.c.*); the postglenoid process is very small, and the post-temporal plate small; its sharp hinder angle reaches half-way over the horizontal canal (*h.s.c.*) Under the squamosal the annulus (*a.ty.*) is just seen, and the pterygoid (*pg.*) with its cartilage (*pg.c.*) behind the alveolar angle of the maxillary (*mx.*).

The lower jaw (*d.*) is well formed, and most of the cartilage on its three processes is ossified. The coronoid (*c.p.*) is twice as prominent as the angular (*ag.p.*), and the condyloid (*cd.p.*) is rounded, and definitely marked off by a neck. The splenial region is seen in this *inner view* to be deficient inside MECKEL'S cartilage (*mk.*), (a part soon to be described), this is ossified, and fills a large groove all along the ramus.

The *lower view* (fig. 2) shows the superficial bones that form the hard palate; the premaxillaries (see also fig. 4, *px.*) form the narrow fore part of a long ellipse, truncated behind. The dentary region is shorter and thicker than the palatine process. The two palatine processes together form a long lanceolate, leafy structure, with their flat, high suture, simulating a mid-rib. I could find no separate front paired vomers; as in the Mole and Shrew, these are probably connate with the premaxillary.

The short jugal process of the maxillary projects beyond the last large tooth-pulp; of these I find five large pulps in each maxillary, and three small ones in the premaxillary.

Inside the crenate alveolar wall the palatine plate of the maxillary is divided by a groove into two subequal narrow tracts. Each of these ends in front in a sharp spike, the outer binding on the inside of the alveolar plate of the premaxillary, and the inner on its palatine process; thus the anterior palatine foramina are very long slits.

Between the sides of the palatine plates of the palatine bones and those of the maxillaries there is an oblique, fusiform fenestra. The former bones (*pa.*) are like two blades, they are closed, at their suture, which is nearly half as long as the maxillary suture, and have their handles behind the hard palate. On each side, at their broadest part, they nearly touch the alveolar plate of the last tooth; they then bend inwards and become a mere oblique short tract of the wall of the nasopalatine passage. This wall is finished by the pterygoids (*pg.*), which are bent inwards and downwards also, behind, where they are capped with a nucleus of cartilage (*pg.c.*); their basicranial flange is moderate and continuous. There is no mesopterygoid centre. The tympanic (*a.ty.*) is a narrow U-shaped bony staple, with its fore limb sinuous, and lobate at its end.

The vomer (figs. 4 and 6, *v.*) is an extraordinary structure; the main median bone is relatively smallest in the Marsupials, and largest in the Tenrec, if we except the abnormally long-faced Cetacea.*

The low septum (fig. 6, *s.n.*) and the large thick vomer (*v.*) at once suggest the comparison with those of the Cetacea. This bone overlaps two-thirds of the recurrent cartilages (*rc.c.*), becomes roughly carinate, pinches in a little, and then gives off an ala, right and left of the sharp split in its hinder end. The whole bone is rough and cellular, and in the hind part is undergoing absorption along certain lines, the meaning of which we shall see in the next stage.

Second Stage of Centetes ecaudatus (continued).—Endocranium and visceral arches.

The exposed part of the nasal labyrinth—the snout (*al.n.*)—is barrel-shaped; the nostrils are latero-terminal; the rest of the large labyrinth is not figured, but I have shown the septum (fig. 6, *s.n., p.e.*) and the recurrent cartilages (figs. 4–6, *rc.c.*); these are tongue-shaped, scooped tracts, and are quite normal. The highest part of the perpendicular ethmoid (fig. 6, *p.e.*), between the large oblique olfactory fossæ is in reality low, but the septum nasi, proper (*s.n.*), is a crest to the huge, thick intertrabecula, scarcely higher than that bar. Where the septum divides the snout, there it becomes deficient, and, indeed, the partition in front of that oval fenestra is mainly formed by the fusion, back to back, of the alæ nasi (*al.n.*); the snout is bent downwards considerably.

The basis cranii behind the perpendicular ethmoid (figs. 4, 5,† *p.e.*) is beginning to ossify as the presphenoid, but the independence of this centre is doubtful in this case, as the orbitosphenoids (*o.s.*) have met over the middle bar (fig. 5) and are closely embracing it. These wings are about two-thirds the size of the alisphenoids (*al.s.*), already they are quite ossified and have lost the large superlateral tract of cartilage,

* This species—*Centetes ecaudatus*—is the one land Mammal that rivals the Whale in the relative length of the head—it is one-third of that of the body.

† Figs. 4 and 5 are from the dissected endocranium after it had been pressed out so as to display the parts.

which did not ossify, but was absorbed. Each of these bony plates is widest above and narrowest in the middle, and the large optic foramen (II.) is well in the middle of the proximal part. When fully seen from above (fig. 5, *o.s.*) the hind margin has two emarginations, one large, in the middle, and one small, near the base; the projection between these notches has, on the *right* side, a small additional nucleus of bone (*o.s.^a*).

The posterior sphenoid is at this early stage a single bone, for the base and the alæ (*b.s.*, *al.s.*) have already largely become confluent; the lower surface (fig. 4) is much larger than the upper (fig. 5), this is mainly due to the great tympanic development in the base; but the alæ are partly overlaid both by the orbitosphenoids and the cochleæ (*o.s.*, *chl.*); the alisphenoids are most remarkably out-thrust in these and other normal Insectivores. Half the cartilage between the basisphenoid and the presphenoidal tract of bone (fig. 4, *b.s.*, *p.s.*) belongs to the former and half to the latter; also, behind, there is much cartilage between the basioccipital (*b.o.*) and the basisphenoid.

There the basal beam has doubled its width; but that is only two-fifths of the whole width of the basisphenoid, which has two crescentic wings, shell-like outgrowths, placed back to back, with their hollow face outside. In front, these tympanic wings only reach half way along the basisphenoid; behind, they overlap the basioccipital, so that they are retral in relation to their origin. The whole inferior surface of the posterior sphenoid is broken up into ridges, grooves, and holes. On each side, in front, there is a rough ridge parallel with the basal cartilage and bone; these are for the fixation of the basicranial flanges of the palatines and pterygoids. Outside these, separated from them by a fossa, there is, right and left, a triangular wing, the external pterygoid process (*e.pg.*); the hollow is the pterygoid fossa; these wings spread further out than the tympanic wings, behind, and they resemble them in form.

Outside the front of the curved tympanic wing there is a rough foramen (*f. ovale*, V^3) which on the inside (fig. 5) is a mere notch. Outside and in front of this is the hinder opening of the alisphenoidal canal (fig. 4, *al.s.c.*), and on the same oblique line, looking outwards and forwards, is a semioval fossa, its truncated end being at the edge of the great wing (*al.s.*). On the inside this is not seen, and the bony wing has a generally concave face in front of and outside the foramen ovale (V^3). The posterior clinoid wall (fig. 5, *p.cl.*) is low and broad; there is, however, a very definite sellar depression.

The auditory capsules—here artificially squeezed outwards to display their parts—are large and pyriform; they are quite normal in having two subequal osseous centres—the prootic and opisthotic (*pr.o.*, *op.*). The latter, on the lower face (fig. 4), embrace the base of the cochlea (*chl.*), and the two are fast approaching each other over the first coil. The prootic (*pr.o.*) is creeping backwards, and (fig. 5) along the front edge of the capsule.

The opisthotic is seen from below (fig. 4, *op.*) creeping round as an unciform shell, behind and under the cochlea and vestibule; it has already formed the familiar *inter-*

fenestral bar between the fenestra ovalis and the fenestra rotunda (*fs.o.*, *fr.*); above (fig. 5, *op.*) it has formed a roughly crescentic shell round the inside of the meatus internus (VII., VIII.). On the inside, the great anterior canal (*a.s.c.*) arches over the large but shallow fossa for the "flocculus" (*fl.r.*); the convexity behind this fossa is formed by the *sinus*, common to the anterior and posterior canals. Below (fig. 4), the horizontal and posterior canals are seen. These views have, however, to be corrected by the other figures (figs. 1-3) when the parts had not been subjected to pressure. Above (fig. 1), the top of the huge auditory convexity is seen, and then the posterior canal (*p.s.c.*) can just be seen where it has passed away from the anterior.

On the side (fig. 3) all the three canals (*a.s.c.*, *h.s.c.*, *p.s.c.*) are seen, showing through the hyaline cartilage, in their natural position, and leaning backwards: a normal state of things for a Mammal.

Below (fig. 2), in the undisturbed condition of all the cranial elements, the horizontal and posterior canals (*h.s.c.*, *p.s.c.*) come well into view and meet at a right angle. But the ampulla of the horizontal canal is, here, hidden by the epihyal (*e.hy.*), which is confluent with the capsule, and by the facial nerve (VII.) passing through the stylomastoid foramen.

The occipital arch must be described from the figures of the complete skull (figs. 1-3) as well as from those of the outspread endocranium. The keystone (figs. 1, 2, *s.o.*) is very large, and its evenly emarginate fore edge is adapted to the hinder round edge of the still larger interparietal (*i.p.*). The cartilage is wide between it and the exoccipitals (*e.o.*), and they are separated by a tract, half their own width from the polygonal basioccipital (*b.o.*) whose hind margin is notched to form the fore boundary of the large foramen magnum (*f.m.*). The occipital condyles (*oc.c.*) are long-oval in size and shape, and are moderately convex.

The foramen condyloideum (XII.) just behind the chink for the 9th and 10th nerves (IX., X.) is through the thick cartilage in the lower edge of the ex-occipital.

The *deep mandible* (*mk.*) in its proper mandibular part, inside the superficial "ramus" is now invested, roughly, with bone, possibly derived from the dentary (*d.*). Under the condyloid process of the ramus (*cd.p.*) the proximal part of MECKEL'S cartilage has acquired a styliform ectosteal plate, and this is spreading over, and growing into, the head of the malleus (*ml.*) nearly up to the articular condyloid facet for the incus. That facet is deep and selliform; below it, the hinder margin of the malleus is semicircularly notched, and has an unciform angle.

From this angle, and from the lower edge of the bony centre, the main enlargement grows obliquely forwards; it then dips to form a subglobular posterior angular process (*p.ag.*) from which the manubrium (fig. 7, *mb.*), arcuate and dilated at its free end, passes forwards. The incus (*i.*) is perfectly normal; its straight, conical "short crus" (*s.c.i.*) is large, and its "long crus" (*l.c.i.*) is thick, well inturned, and has a short-oval orbicular plate for the stapedial head; the body of the incus is rapidly ossifying from the hinder concave margin. The stapes (*st.*) is very short, has an almost circular fenestra, and

a very perfectly limbate margin, with a flat outer face all round, for insertion into the fenestra ovalis. I did not find any interhyal segment. The short round epihyal (fig. 2, *e.hy.*) is followed by membrane up to the equally small hypohyal (fig. 8, *h.hy.*).

The basal piece (*b.h.br.*) is a longish transverse bar, narrow in the middle where it is beginning to ossify, and then where it reaches the hypohyals it is thicker; thence, at a very obtuse angle, the thyrohyals (*t.hy.*) grow outwards and backwards, without any sign of segmentation from the basal piece.

Third Stage.—*Young of Centetes ecaudatus*; $3\frac{1}{4}$ inches long.

I. *The investing bones of the skull.*

At this stage, before the development of the crests and ridges seen on the hind skull in the adult,* the general form is like that of a Mole, or still more of a Shrew, as there are no jugal bones. Very little of the great fontanelle is now visible at the junction of the parietals and frontals, and the whole investiture of bony plates is strong and smooth; ossification takes place very rapidly in this type, but not so rapidly as in the Marsupials, whose premature birth is provided for by precocious ossification of the skull. Behind the moderately long, and rather slender snout (*al.n.*), the skull is at first narrow, and then widens gently to its orbital "waist;" the temporal region is the widest, notwithstanding the great size of the maxillaries with their large teeth and tooth-sockets (Plate 33, fig. 1). In the *upper view*, we see that the nasals (fig. 2, *n.*), flanked by the premaxillaries and maxillaries (*px.*, *mx.*), are long, and already give promise of the intense ossification of the Tenrec's skull.

The notch between the nasals in front is followed by a suture dividing their fore third, and behind, there is a slight division; for the rest they are thoroughly confluent. The frontals (*f.*) are longer than the nasals, but their mutual suture—the frontal—is only two-thirds the length of the bones, as the nasals run their double wedge far in between them. The frontals, in turn, to a less degree, divide the parietals (*p.*), and their strong suture—the sagittal—is only two-thirds the length of the frontal suture. There is a remarkable amount of mutual inter-wedging above, in the preorbital region, for the frontals divided by the nasals run forwards between the maxillaries and the nasals, whilst the lesser premaxillaries do the same between the nasals and maxillaries, in front, so that the latter only reach the middle part of the nasals for a short distance.

The supraorbital region of the frontal passes very gently down into the orbital, and each bone gently widens out to the postorbital corner. From the V-shaped coronal suture the parietals widen at first very little, and then suddenly in the temporal region; they are bounded behind by the huge interparietal (*i.p.*), and divided from it by the lambdoidal suture.

The suture is, here, an inverted V, and is similar to the coronal; its crura are concave in front, those of the coronal are arched forwards. The dentation of these

* See DOBSON'S "Insectivora," Part ii., Plate 8, figs. 1, 1A.

non-persistent sutures is very strong, as in the Salamander's skull. The hinder outline of the parietals and interparietals, together, is a very neat semi-circle, just flanked, and made to look irregular by the partial view, in this aspect, of the squamosal, auditory, and supraoccipital bones.

In the *side view* (fig. 3) the parts just spoken of as flanking the great roof-bones, come fully into sight, as also the bones of the upper face, so imperfectly seen from above.

Behind the deflected snout (*al.n.*), the strong, oblique, unciform premaxillary facial plate (*px.*), is seen with its sharp and rather large teeth; over it the nasal (*n.*) is seen somewhat; the maxillary (*mx.*) is nearly half the length of the whole bony skull, and is a notable prophecy of what this bone, with its heavy burden of teeth, will become in the great herbivorous Eutheria; from its rounded edge, closely fitted to the premaxillary, it runs backwards as far as the coronal suture, ending there as a flat, free jugal process. A low triangle, its posterior edge is shorter than its anterior, and that is the most irregular. That irregular edge bounds the front of the badly enclosed orbit; near its upper part, the squamous, perforated lachrymal (*l.*, *lc.*) fits into a deep recess, and below this the great infraorbital foramen (V^2) runs on, forwards, as a large groove; it is very feebly finished, outside, by an arched bar which articulates with the lachrymal. Behind that suture the maxillary is seen as a large rounded lobe of bone, the outer alveolar wall of the two last molars, and the jugal process, all in one tract. Even now the frontals and parietals have separate convexities, that of the former is the higher of the two. The orbital plate is notched where the 1st branch of the 5th nerve (V^1) re-enters the skull, and there the frontal, parietal, orbitosphenoid and alisphenoid, all approach each other. In the temporal region the parietal swells over the squamosal, whose scale-like temporal flange overlaps the lower edge of the former; it is sharp at its fore corner, where it lies on the projecting alisphenoid, and it turns upwards in its post-temporal region, to bind, tightly, between the parietal outside, and above, and the auditory capsule within, and below. The oblique retreating front margin of the squamosal is notched, and meets its outer oblique edge at an obtuse angle, beyond the glenoid cavity (*gl.c.*); it scarcely projects at all as a jugal process. The lower postglenoid facet binds upon the canal-region of the auditory labyrinth by its oblique, toothed, and notched posterior margin. This side view shows the interparietal (*i.p.*), the pterygoid hook (*pg.*) and the annulus (*a.ty.*). At present, therefore, the temporal fossa is badly enclosed, and the sagittal and lambdoidal crests have no existence.

In this same side view the mandible is seen as an almost crescentic bone; the axis of the ramus and of the high coronoid process (*c.p.*), being coincident. The three processes are almost equal, for the smallest of the three, the angular (*ag.p.*) is larger than it seems to be as seen from the side; seen endwise (fig. 3A) it has a thick limbate inturned edge, and is manifestly Marsupial. The condyloid process (*cd.p.*) is oval, transverse, and has the narrow end inwards. The dentary canal can be seen

from behind, protected by a wing of bone in the *true coronoid region*, and the remarkable thickness, roundness, and solidity of the ramus is also shown.

The *lower view* (Plate 21, fig. 1) shows a large pyriform tract, two-thirds of the whole inferior area, covered with superficial bones. The premaxillaries (*px.*) have a considerable dentary edge, and long, slender, compressed palatine processes. Each large maxillary (*mx.*) shows on this face three tracts, first, the series of alveoli, expanding from before, backwards; then the outer part of the palatine plate wrought into subtransverse ridges, and hollow with perforations; and, close to the mid-line, a narrow tract, on a higher level. The two halves of the palatine plate end, in front, as spikes, the inner binding on the palatine process, and the outer on the dentary region, of the premaxillary. The inner tracts run short behind, the palatines (*pa.*) wedging in, in an irregular manner; the outer reach as far backward as the alveolar walls, binding strongly on the outer face of the open part of the palatines. The rough splintery fore part of the palatine plate of the palatines is split for some distance, and then towards the transverse ribbed edge, behind, shows the posterior palatine foramen (*p.p.f.*). Where the nasopalatine passages open, there both at the middle part and the sides each palatine bone is thick and solid; and then, suddenly thinning out, they bind on the small subparallel blunt-hooked pterygoids (*pg.*); the pterygoid fossæ are very indefinite.

Over the opening of the nasopalatine canal the vomer (*v.*) is just seen in its hinder part; and on the right side of the figure the annulus (*a.ty.*) is shown, with its thick twisted anterior, and its sharp posterior, crus. The orbital plate of the frontal (*f.*) is seen in the distance, and the squamosal (*sq.*) shows its obliquely oval glenoid facet (*gl.c.*), its stunted jugal process, and its short, strong, three-limbed postglenoid tract, with the postglenoid pneumatic foramen, close to the glenoid cartilage.

On the *hinder face* of the skull (fig. 4) we get an imperfect view of the parietals, interparietals, squamosals, and tympanics (*p.*, *i.p.*, *sq.*, *a.ty.*).

On the *inside* of the skull, with the septum (*s.n.*, *p.e.*), perfect, and shown from its left face, we get an instructive view of the investing elements of the skull. In front we see the nasals (*n.*) above, and the palatine process of the premaxillary (*p.px.*) severed from its body below; and behind it, at the lower edge, the palatine plate of the maxillary and palatine (*p.mx.*, *pa.*), and the free retral hook of the pterygoid (*pg.*), growing from its ascending plate.

Above, the frontals (*f.*), at their edge, and in their orbital region, and the parietals and interparietals (*p.*, *i.p.*); the imbrication of the parietal over the frontal is very great; that of the squamosal (*sq.*) below, over the parietal, is very moderate; over this latter squamous suture the elegant furrow for the lateral sinus (*s.c.*) is well seen.

But the most remarkable of all the investing bones still remain to be described, and are best seen in this view; these are the large vomers (Plate 33, fig. 5, *v.*, *v'*, *v''*). In the earlier stage (Plate 32) I failed to find a distinct anterolateral vomer; this bone appears to be connate with the palatine process of the premaxillary, as in some other

kinds. It is represented here (Plate 33, fig. 5) by the rising on the upper edge of the palatine process of the premaxillary (*p.px.*) close in front of the foremost vomer (*v'*).

Here the posterolateral vomers that bind the hind part of the main vomer (*v.*) to the lateral ethmoidal masses (Plate 33, figs. 5 and 8, *v''*.) are well developed but not large.

The main vomer of the unripe embryo (Plate 32, fig. 6, *v.*) was shown to be extremely large, thick, and spongy; now (Plate 32, figs. 5, 8) it is in three pieces, and these are not arranged on one plane, as in the Marsupials (which, as I shall show in my next paper, have many separate vomers) but the large upper bone (*v.*) lies in the trough of the two lower pieces. These occupy about the first and second third of its length (see also fig. 8, showing the hind part of the second lower piece (*v'*.), and the hind third of the main bone *v.*).

The *subdivision* of a primarily single centre is much more frequent in the higher Vertebrata than I had imagined, a process curiously in contrast with that more familiar phenomenon—ankylosis of primarily distinct bones.

This special peculiarity of the Tenrec, and of the Centetidæ, generally, as I shall soon show, is, after all, merely a modification of the Marsupial type of structure, and it is not the only instance in its skull of a *new* Insectivorous character formed by a very gentle modification of an *old* Marsupial one.*

I have already referred to the only other splint-bone to be noticed, namely, the annulus tympanicus (figs. 1, 3, 4, *a.ty.*); this, as seen from the inside, separated from the skull (figs. 6 and 7, *a.ty.*), is an imperfect ring of bone, convex on its outer side, ribbed at the edge and then scooped on the inner side; it is irregularly crenate on its inner, growing edge; its elongated front limb binds strongly on the outer side of the huge processus gracilis of the malleus (*p.gr.*).

Third Stage (continued).—On the endocranium of the Young Tenrec.

By a comparison of what is shown in the various figures just referred to we shall be able to understand the structure of the inner skull; the younger stage (Plate 32) will help us in the interpretation of its parts and regions.

The snout (fig. 3, *al.n.*), as seen from the side, leans over at the fore end; the nostril (*e.n.*) is large, oblique, and well surrounded by a valvular fold; it is also made more complex by an internarial lobe, above. The fenestra in the fore part of the septum, seen in the last stage (Plate 32, fig. 6, *s.n.*), is now filled in with cartilage,

* The process itself, by which a thick spongy bone splits into concentric laminæ, is quite like that which is seen in the bark of the Plane tree (*Platanus*). Considered architecturally, in the *building* of the skull, it is oddly unlike anything wrought by art or Man's device; and as a mode of the *imbrication* of bony scutes, everywhere, from the Ganoids to the highest Mammals, so familiar to us, this is (apparently) unique. The greater part of the huge rounded septo-ethmoidal base, or intertrabecula, lies over one large semitubular *balk*, which is, itself, sheathed by two similar but smaller semitubular pieces.

and the great partition is complete from front to back (Plate 33, fig. 5, *al.n.*, *s.n.*, *p.e.*); that tract, now partly bony (*p.e.*), is *almost three-fourths* the length of the whole basicranial axis, for a time, in this young suckling. The huge rounded intertrabecular base of the septum is, in the figure, largely hidden by the vomers, whose swelling form, however, tell of the bulk of the mass of cartilage covered by them. The septum nasi (*s.n.*) is low, and the perpendicular ethmoid (*p.e.*) rises to no great height between the large cribriform plates (*cr.p.*). There is no cartilaginous crista galli; from the free margin of the partition, a little forwards and then backwards, two-thirds of the way to the presphenoid (*p.s.*), the perpendicular ethmoid is bony, already. Bone is now seen in the base between the two orbitosphenoids; this is the presphenoidal region (*p.s.*), doubtfully or only partially independent as a bony centre. The orbitosphenoids (*o.s.*), and alisphenoids (*al.s.*) are scarcely seen at all in this internal sectional view, they lie down so low, infero-laterally. But their upper margin is shown, and in the other lateral view (*outside*, fig. 3) their structure and relations can be seen.

The optic nerve (fig. 3, II.) emerges above and inside the wide sphenoidal fissure ($V^1, ^2$); its passage through the middle of the proximal part of the orbitosphenoid was shown in the last stage (Plate 32, fig. 5, *o.s.*, II.). The orbitosphenoid is also seen—in the distance—in the lower view (Plate 33, fig. 1, *o.s.*) bound upon by the orbital plate of the frontal (*f.*).

The posterior sphenoid forms a very large part of the endocranium, and attains here its fullest development as a special (Insectivorous) type. The overlapping of the orbitosphenoid by the alisphenoid is seen well in the *side* view (fig. 3, *o.s.*, *al.s.*), and in that aspect the foramen ovale (V^3 .) and the additional hole or hind opening of the alisphenoidal canal (*al.s.c.*) in front of it also; the front overlapping lamina mounts up, and is seen under the junction of the frontal parietal and squamosal; the external pterygoid process is aborted. Below (fig. 1), the posterior sphenoid is seen to extend from the place where the maxillaries overlap the palatines in front, to the foramen lacerum posterius (IX., X.), behind; thus this great region ends, behind, opposite the middle of the basioccipital (*b.o.*). This extreme front and hind extension is peculiar to the typical Insectivora, and is due to the forward growth of the alisphenoid at a good distance outside the orbitosphenoid, so making the sphenoidal fissure a side passage to the skull; whilst, behind, the tympanic wings of the basisphenoid grow beyond their root, and thus extend that bone, backwards.

There is still some cartilage at the mid-line in the fore part of the presphenoidal region (fig. 5, *p.s.*), but where the two orbitosphenoids have met further back the bony base is complete, and that tract has already coalesced with the fore part of the independent basisphenoid (*b.s.*) (see also Plate 32, figs. 4, 5, *p.s.*, *b.s.*), the basisphenoidal region is full twice the extent of the presphenoidal. The remarkable hollow under the fore part of the basisphenoid of the Hedgehog (Plates 17, 20, and 21) is also seen here, and the pituitary floor (sella turcica) is perforated; this hole,

however, appears to be secondary and not primary as in the Hedgehog. I did not see it in the embryo (Plate 32, figs. 4, 5, *b.s.*), so that this character is not primary, as in the Hedgehog.

The tympanic wings (*t.b.s.*) are more clearly marked off from the main basal bone than in the Hedgehog, and thus a clue is got to their real nature; they are mere periosteal outgrowths, and, had they arisen independently, their homology with the "ossa bullæ" of the Marsupial would have been seen at once; they are the morphological equivalents of those bones. These tracts are roughly in the shape of the shell of a bivalve Mollusk, but they grow inwards; in front, the right and left processes meet. Behind this junction only a small triangular space of the basisphenoidal bone is seen, it is somewhat apiculated; at the middle, the synchondrosis is still present. These shells (or wings) grow outwards and backwards some distance beyond their root.

The alisphenoids are confluent with their common key-stone piece (*al.s.*, *b.s.*), they are very large, reaching from the fore-third of the tympanic wings (fig. 1) to the bottom of the coronal suture (fig. 3). Thus they lie *over* the large tympanic cavity in its front-third; they also, like their basal piece, have developed a large *tympanic wing* (*t.al.s.*) *in front* of the tympanic cavity; this wing has converted the hinder angular notch (Plate 32, figs. 4, 5; and Plate 33, figs. 1, 3) into a foramen—the *foramen ovale* (*V³.*).

The hole through the alisphenoid, further forwards, is the hinder opening of the alisphenoidal canal (*al.s.c.*); the 2nd branch of the trigeminal escapes through the sphenoidal fissure. The subdistinct tympanic alæ of the basisphenoid, the very large alisphenoids, and their tympanic wings, are all characters that are Marsupial, or *nearly so*.

But the internal carotids do not enter the skull *through* the basisphenoid; there is no foramen rotundum; there is a hollow recess under the basisphenoid, and the alisphenoids have broken away from the general skull wall, far outside the orbitosphenoids. In Marsupials, however, this does not take place, but the planes of these alæ are coincident, and the alisphenoid, as well as the orbitosphenoid, ossifies upwards into the great supero-lateral band of cartilage.

All these things are intelligible; these low Eutheria are developing typical characters, which are curiously mixed up with certain archaic characters inherited from the forms on a lower level (Metatheria), from which these Insectivores once sprung.

The auditory capsules are relatively less now than they were in the unripe embryo (Plates 32, 33), only the supra-auditory crest—running into the supraoccipital, where it is joined by the exoccipital—is still cartilaginous.

The cochleæ (fig. 1, *chl.*) are well formed, and their position is almost transverse; the tegmen tympani is burrowed by the facial nerve (*VII.*), which emerges behind and within the stunted epiphyal (*e.hy.*); behind the stylomastoid foramen)

the opisthotic region grows into a distinct mastoid process. The fenestra ovalis (*fs.o.*) is seen inside the canal for the facial nerve, and the large fenestra rotunda (*f.r.*) is reniform, being notched somewhat in front. A considerable tract of the bony capsule is seen behind the squamosal (figs. 3, 4); the canals (*a.s.c.*, *h.s.c.*, *p.s.c.*) mark this part, but the anterior canal is best seen on *the inside* (fig. 5), in front of the recess for the "flocculus (*fl.r.*). Behind this moderate hollow the thickened bone contains the common sinus of the anterior and posterior canals. The large meatus internus (VII., VIII.) is oblique, going backwards and downwards; the passage for the facial nerve, in front, is well marked. The occipital arch has its elements still separated by considerable tracts of cartilage; the basioccipital (*b.o.*) is a sinuous, transversely polygonal plate, sharply notched in front, where the notochord ran, and having a concave margin behind, at the foramen magnum. The supraoccipital (*s.o.*) is a large shield of bone, thickened and convex along its middle, and arching over the foramen magnum by its lower edge. The exoccipitals (*e.o.*) form a very small paroccipital ridge behind the mastoid process; the foramen condyloideum (XII.), close behind and within the posterior lacerated foramen (IX., X.), is large. The whole arch is small relatively to the rest of the skull, and this is Eutherian in this respect.

MECKEL'S cartilage (figs. 3, 6, *mk.*) is being lost in the mandible in front; where it has become free behind, tracing it backwards and upwards, it is still quite thick and is endosteally ossified, continuously with its proximal part, the malleus (*ml.*). The primary ossification (Plate 32, fig. 7, *ml.*) is ectosteal, and now, on the inside, this is roughly and imperfectly subdivided into three bony laths, binding the front of the head of the malleus, which is now well ossified throughout, the endosteal tract seen in the early state (Plate 32, fig. 7, *ml.*) having used up all the cartilage except the selliform condyle.

Here we have the counterpart, first, of the endosteal or *inner* articulare of the Sauropsida; and then the *outer* articulare, the supra-angular, and the angular of the endocranial mandible, in a state of imperfect differentiation.

Below the condyle the malleus projects towards the incus (*i.*), the head is then bent on itself, growing obliquely forwards; it gives off two processes, manifestly equal to the internal and posterior angular processes of the Bird; the latter is represented here by a rounded knob (*ag.p.*), and the former by the long straight, slender manubrium (*mb.*). On the outside the malleus is strongly tied by the anterior crus of the annulus (figs. 7 and 8, *a.ty.*); behind that bar the malleus grows into a crescentic foliaceous plate and is concentrically grooved to a less degree in front of the condyle, and much more in front of the foliaceous outgrowth. All these things admit of no Teleological interpretation, but show that the hinder third of the Sauropsidan type of mandible is here *aborting itself*, so to speak, into an Eutherian malleus.

The incus (fig. 6, *i.*) is well formed; the short crus (*s.c.i.*) straight and conical, and the long crus (*l.c.i.*) is short, capped with an orbicular facet where it turns inwards to articulate with the stapes.

The stapes (*st.*) is thoroughly typical, having an unusually large foot-hole. I see no interhyal in the hinder of the stapedius muscle (*st. m.*, see also Plate 32, fig. 7).

The very Marsupial os hyoides (fig. 9) has small, unossified hypohyals (*h.hy.*) on a transverse basihyal (*b.h.br.*); this is ossified now, and so are the thyrohyals (*t.hy.*) which are now segmented from it; they were not in the last stage (Plate 32, fig. 8).

Going back again to the olfactory region, we find that the nasal, inferior, upper, and middle turbinals (fig. 10, *n.tb.*, *i.tb.*, *u.tb.*, *m.tb.*) are large and well developed, but at present they are cartilaginous.

For a description and figures of the *adult* skull the reader is referred to Dr. DOBSON's invaluable work (Part I., p. 72; and Part II., plate 8). The whole structure is as much modified from what I have shown in the young (Third Stage) as that is from the skull of the unripe embryo (Second Stage). Its great length, and the large size of its transverse and longitudinal crests, make it one of the most remarkable skulls in the whole Order.

On the skull of Hemicentes (sub-adult).

For figures and a description of the adult skull of this type the reader is referred to Prof. MIVART's Paper (Proc. Zool. Soc., Jan. 17, 1871, p. 58), and for a further account of this type to Dr. DOBSON's Monograph (Part I., p. 69).

Fortunately, my specimens—one of *H. madagascariensis* (Plate 34, figs. 1–5), and another of *H. nigrescens* (Plate 34, figs. 6–9)—were not quite full-grown, and therefore yielded me better results for my special work than older skulls would have done.

On the investing bones of the skull of Hemicentetes.

This extremely elongated skull gains its great length, as in most other Mammals with a long head, not by elongation of the premaxillaries, as in longirostral Birds, but by the great length of the maxillaries and nasals.

The *upper view* (Plate 34, fig. 2) shows that the nasals (*n.*) are more than half the length of the bony skull; they are much separated in front, and their suture only reaches to the middle; in their hinder half they are completely ankylosed. The fore part of each is a mere style of bone; the united hind part is a convex lanceolate tract, overlapped at its edges by the thin internal edge of the divaricated frontals (*f.*). The facial plate of the premaxillaries (*px.*) is about a fifth of that of the maxillaries (*mx.*), but the upper margin is extended backwards between each nasal and maxillary, so as to keep those bones apart for the front half of their related edges. Each maxillary shows two regions laterally, the lower or alveolar is seen in the distance in this view, but the upper is in full view, it runs well up to the badly defined orbit; the whole of this upper facial tract is a long, gently convex lath of thin, but strong, bone; it reaches a little further backwards than the nasals, and, below and behind, shows between itself and the alveolar part, the infraorbital opening (*V²*).

The frontals and parietals (*f.*, *p.*) have a nearly equal *axial* length, but the former are far inferior to the parietals in width.

The frontal and coronal sutures are perfect, at present, and are *semi-squamous*; the two frontals mutually overlapping each other, in this place and that, and the parietals overlapping the frontals laterally.

Where the frontals are wedged in between the nasals and maxillaries there they are very thin, sharply angular in form, and splintered at their edges.

Behind, they run in between the parietals, with strong dentations; their orbital edge is rounded and smooth, and has a gently arcuate outline. The parietals (*p.*) run as far forwards, below, as they retreat, above; inside the gently concave temporal fossæ, they swell together, into a dome-like structure, which is divided by the sagittal suture. This is larger than the general convexity of the frontals; but it is enlarged still more by the subconcave part which extends into the temporal fossæ. The squamous suture with the squamosal (*sq.*) is not well seen from above; the wedge-like fore part of the interparietal (*i.p.*) is more clearly defined than its narrow, extended outer wings; it is rather a large bone, and is convex above, where it fits to the fore margin of the supraoccipital (*s.o.*). It there forms the lambdoidal crest; but the sagittal crest has not any existence, at present, and there is a shallow concavity running across the skull where the parietals and interparietals meet, which connects together the two temporal fossæ.

The *side view* (Plate 34, fig. 3) brings out things that are not well seen from above; it shows a dorsal line gently sinuous, with even fewer interruptions than the lateral outline which is broken by the hind part of the maxillaries; compared with normal skulls it looks as though it had been artificially elongated whilst in a plastic state; the great distance of the teeth from each other increases this appearance. The dentary edge of the premaxillary (*px.*) is only one-fifth the extent of that of the maxillary (*mx.*); the whole line is gently sinuous, convex in front and behind, and concave in the middle. The nasals (*n.*) are scarcely seen from this aspect, but the maxillary is well displayed, with its upper facial plate, its infraorbital hollow passage and narrow bridge (*V²*), and the hills and hollows caused by the series of teeth. The maxillary ends, behind, in thin lobes, the upper of these is broad, and overlaps the small angular lachrymal (*l.*) with its canal (*l.c.*) in front, in the notch between the upper and lower outer lobes; the lower lobe is sharp and upturned, it is the end of the alveolar region. The third lobe is a flattish tridentate tract, further inwards, and binds upon the palatine (*pa.*). The orbital plate of the frontal (*f.*) runs down to the middle tooth of this inner lobe of the maxillary; its hollowest space is the shortish tract between the lachrymal and the overlapping parietal. The hinder and most convex part of the frontal where it passes under the parietal is not marked by any lines or grooves, but in front of that tract it is sinuous, rising and falling over the turbinal coils within, which shine through it, as through a thin plate of horn. The hinder margin of the orbital plate is notched, deeply, by the outstanding alisphenoid

(*al.s.*), and behind this part the narrow fore corner of the parietal lies over it. The parietal, in this aspect, is seen as a fine shell of bone, with its hinder three-fourths overlapped by the squamosal. That scale is perforated at its hinder part, near the almost straight squamous suture.

The squamosal (*sq.*) is ribbed (or limbate), outside, the fore part of the thick edge being the rudiment of the jugal process, which however scarcely projects beyond the glenoid cavity (*gl.c.*). The thick, ribbed edge dips and forms the post-glenoid tract behind its middle; it then rises, and runs into the low lambdoidal crest, which is formed above by the interparietal (*i.p.*). The palatine (*pa.*) is hidden by the maxillary in this aspect, but the pterygoid (*pg.*) is seen with its short, blunt hook; the tympanic (*a.ty.*) also just comes into view.

The dentary region of the lower jaw (*d.*) is not much more than half the length of the ramus; it is as remarkable for its slenderness, as the hinder, shorter part is for its breadth. The coronoid process (*c.p.*) is small, and uncinatè; it is separated from the large, well-formed condyloid process (*cd.p.*) by a round notch. The angular process (*ag.p.*) is separated from the condyloid by a round notch twice as large as the upper: it is twice as large as the coronoid, and also uncinatè; hooking towards the coronoid hook. Below, the angular process is notched and another third sharp hook is seen; there (see also fig. 5) the bone is very thick, and both the thickening and the hook are curved inwards, as in Marsupials. The outer face of the broad divided part of the ramus is made concave by the outward leaning of the coronoid process (fig. 5).

The *lower view* (fig. 1) shows the peculiar lathiness of the palatal region, the bones having much the character of those investing the face of the embryo of a longirostral Bird.

The premaxillaries (*px.*) show four parallel tracts; the two outer are the alveolar, and the two inner are the palatine regions, and these are separated by a deep cleft, ending in a round notch in front, where JACOBSON'S organs (*j.o.*) open in the anterior palatine foramina. Right and left of the median suture each maxillary palatine plate is split half-way backwards to the palatine bone (*pa.*); the inner spikes bind on the inner spikes of the premaxillaries, and the outer splintery, interalveolar tracts bind against the alveolar tracts of the premaxillaries. Then each palatine plate of the maxillary is hollow at the mid-line, and against the alveoli, and convex along its middle, up to the palatine bone, which impinges upon the hinder third of the maxillary. This latter bone then divides into a short jugal and a long inner process. The hollow behind the last tooth is the infraorbital canal (*V²*), and the small, bony bridge over it is seen in the distance. The palatines (*pa.*) are very long, nearly as long as the submesial part of the maxillary palatine plate; they run in under those tracts, first with an inner, and then with an outer spike; only their front two-fifths is complete up to the mid-line, for they soon form a thick short process, which meets its fellow at an obtuse angle over the open nasopalatine passage. Each palatine is there convex, and a little broader than the open space in the middle; the bone widens to

bend on the end of the maxillary, and is then cut away, so to speak, to receive the fore part of the ascending plate of the pterygoid (*pg.*). The latter spreads out under the basisphenoid (*b.s.*), and is ankylosed with it, some distance behind and above the hamular process or hook. In this view the orbital region of the frontal (*f.*) is seen in the distance, a large space existing between it and the bulging alisphenoid. On the right side of the figure the annulus (*a.ty.*) is shown; it is well formed, convex outside, has a retreating, broad, notched, anterior crus, and a strong, crescentic hinder crus; both these crura are strapped on to a strong ridge of the squamosal, inside and behind the oval glenoid cartilage (*gl.c.*). Round that facet the latter bone is thickened everywhere, though the inner and front part of that thickening is the stunted jugal process. The post-glenoid tract bends back against the bony auditory capsule and the inner edge is excavated, and united by a serrated suture with the tympanic wing of the alisphenoid (*al.s.*), thus helping to form the tympanic cavity, as well as to enlarge the tegmen tympani.

In the *end view* (fig. 5) the investing bones (*i.p.*, *p.*, *sq.*) are but little seen; a *side view of the septum* of the olfactory organs (fig. 8) shows the large and remarkable vomerine series of bones. These are quite similar to those of *Centetes* (Plate 33); there is a large upper semitubular vomer, proper (*v.*), and two lesser semitubular bones sheathing it (*v'*). Behind, the main bone has attached to it a pair of postero-lateral centres (*v''*); the antero-lateral vomers are not distinct from the palatine processes of the premaxillaries (*px.*).

The endocranium of Hemicentetes.

The snout (*al.n.*, *e.n.*) is straight and bulges at the end and below; the nostrils are surrounded, except below, by a valvular fold of cartilage, they look downwards and forwards, and the antero-inferior face of the snout is oblique. The fore part of the septum nasi (fig. 7, *s.n.*) is obliquely oval, answering to the form and direction of the snout; the rest is a very low crest to a very solid and well-marked intertrabecula (*i.tr.*). Where the septum becomes ethmoidal there it rises into a low triangle, and is ossified as the perpendicular ethmoid (*p.e.*); it has a kidney-shaped swelling with the "hilus" looking forward, just in front of its free inter-olfactory crest. The whole septum is rather saddle-backed; it has a considerable cartilaginous tract behind, between the large bony plate and the presphenoid (*p.s.*). The latter tract is hidden from view in the *lower aspect* (fig. 1) by the main vomer (*v.*); the orbitosphenoids (*o.s.*) can be seen in the *side view* (fig. 3), they are perforated by the optic nerve (II.) as can be seen by looking forwards through the foramen magnum. In that figure the alisphenoids (*al.s.*) can be seen both above, where they form the curious thin dentate outer wall to the intersphenoidal passage, and also below, where the hinder openings of the alisphenoidal canal (*al.s.c.*) is seen a little in front of the foramen ovale (V.). That canal opens in front into the general cavity of the wide "sphenoidal fissure" (or passage).

In the *lower view* (fig. 1), the foramen ovale (V^3 .) is seen just inside the stunted jugal process of the squamosal and the glenoid facet (*gl.c.*), but the canal (*al.s.c.*) is hidden by a lamina of bone, and the extremely outward position of the thin shell-like alisphenoidal wall is seen, and the crescentic notch that emarginates its oblique front edge. The huge alisphenoid—nearly as large as in a Marsupial—forms, behind the foramen ovale (V^3 .), an oblique strongly dentated suture with the inner edge of the squamosal, and then becomes hollow over the tympanic cavity, outside the tympanic wing of the basisphenoid. The hinder edge of that supratympanic lamina is deeply notched, and terminates close in front of the cochlea (*chl.*).

The shell-like tympanic wings of the basisphenoid (*t.b.s.*) reach as far forward as the foramen ovale (V^3 .) in front, and nearly to the fenestra rotunda (*f.r.*) behind; they are manifestly “bullæ” that have lost their distinctness from the basisphenoid, whilst the hollow cavity of the greatly extended alisphenoid is, as surely, the counterpart of the tympanic wing of that bone seen in Marsupials. The hollow, in front, under the basisphenoid, is present, but it is not so much marked as in *Centetes*; the rest of the basisphenoid is of an hour-glass shape and is somewhat carinate; its hind edge is bracket-shaped and is separated from the basioccipital (*b.o.*) by a clear synchondrosis.

The auditory capsules are ossified; there is, however, some cartilage near the horizontal canal (fig. 1, *h.s.c.*); this is the small epihyal (*e.hy.*) in front of the foramen stylo-mastoideum (VII.). The cochlea (fig. 1, *chl.*) is well formed, and the fenestræ (*fs.o.*, *fr.*) are seen outside and behind it, also the chink and channel for the facial nerve (VII.) emerging from the cranial cavity. The horizontal and posterior canals (*h.s.c.*, *p.s.c.*) are seen on the outside, showing through their thin bony walls. Behind the posterior canal there is a bony ridge, and then a suture between that ridge and the short paroccipital process (*p.oc.*). The basi- and exoccipitals (fig. 1, *b.o.*, *s.o.*) are confluent; the supraoccipital (figs. 1, 4, *s.o.*) is a very large distinct shield of bone, cut away in a semicircle, over the huge foramen magnum; the condyles (*oc.c.*) are large, pyriform, and wide apart.

The “ossicula,” separately figured on a large scale and seen from within (fig. 9), attached to the thick-rimmed middle-sized annulus (*a.ty.*), are worthy of note.

The cartilage is gone in front and has left a large tongue-shaped processus gracilis (*p.gr.*), twice as large as the manubrium (*mb.*), and parallel with it. The body of the malleus is at a right angle with these *handles*, and is of great extent. Over and in front of its condyloid facet there is a large solid helmet of bone; behind that facet the hind margin projects backwards as a rounded elbow; and below the root of the manubrium there is a subglobular “posterior angular process” (*ag.p.*)—a familiar Sauropsidian remnant.

The incus (*i.*) and the stapes (*st.*) are large, well-formed, and quite typical.

A small hypohyal (fig. 6, *h.hy.*), equal to the epihyal (fig. 1, *e.hy.*) above, is attached to a transverse basal bar (*b.h.br.*), and from this proceed the two short diverging thyro-

hyals (*t.hy.*, cornua majora—1st hypobranchials), separated from the base by cartilage, but not segmented off.

Skull of adult Ericulus nigrescens. (Male.)

The hinder half of the *palatal view* of the skull of this type has been figured (Plate 35, fig. 11); this is a very instructive skull, and typical of the Mascarene modification of the Insectivorous type; nearly typical, as respects the Order itself, in its *modern* development.*

The palatines (fig. 11, *pa.*) end in a straight line at the end of the hard palate; they are behind the maxillaries, and have the well-formed pterygoids (*pg.*) attached, subvertically, to them.

In the roof, the vomer (*v.*) is seen sheathing the perpendicular ethmoid, and the forepart of the presphenoid (*p.s.*); the orbitosphenoids (*o.s.*) are not seen in this view, except a little in front of the great fissure ($V^1, 2$). Like the presphenoid, the forepart of the huge basisphenoid (*b.s.*) is of moderate width, and flat; it is rendered somewhat concave by its union with the pterygoids.

The *sub-pituitary* hollow is perforated, above, as in *Centetes*; behind it the basisphenoid broadens out, and behind, both it and the basioccipital (*b.o.*) for some distance are subcarinate; this ridge is due to the bulging of the earliest bone deposited round the notochord. The tympanic wings (*t.b.s.*) are not symmetrical, that on the left side being much the larger of the two; a notch separates these shells in front, from the equal and well-developed tympanic wings of the alisphenoid (*t.al.s.*). These, with a similar process of the squamosals (*sq.*), form the antero-external outline of the obliquely oval tympanic spaces. These spaces are roofed, in front, by the same bones, and, behind, by the oblique, well-formed cochleæ (*chl.*). From those *helices*, to the fore edge of the great sphenoidal side gallery, out of which the 1st and 2nd branches of the trigeminal nerve ($V^1, 2$) emerge, is a large space—half the cranial floor; it is an unmistakable Marsupial character. But the foramina are typical for an Insectivore; this *foramen ovale* (V^3) is finished behind by the tympanic shell of the alisphenoid, and for a distance, in front, equal to its own width. Another oval hole of the same size is seen, but it has not its long axis outwards and backwards as in the foramen ovale, but inwards and backwards; this is the hinder opening of the alisphenoidal canal (*al.s.c.*); the anterior opening being made into the common sphenoidal fissure or *side passage*. The squamosal (*sq.*) has a stunted zygomatic or jugal process, and a large oblique saddle-shaped glenoidal facet (*gl.c.*). Where the bone widens towards the tegmen tympani (*t.ty.*), and bounds the tympanic cavity, there is a short postglenoid tract and a small post-glenoid foramen.

The external part of the ossified auditory capsule outside the tegmen has grown beyond its contained horizontal canal (compare with *Microgale*, figs. 1, 3, *h.s.c.*) into an

* The original skull from which this figure was made is in the *Biological Laboratory*, South Kensington Museum.

ear-shaped mastoid process, not unlike, in size and form, the glenoid region of the squamosal close in front of it. The openings here are numerous; inside the post-glenoid foramen and outer tympanic wall the canal for the facial nerve (VII.) is seen, and further backwards and outwards, behind a stunted and ossified (epihyal) (*e.hy.*), the same nerve (VII.) escapes through the large stylomastoid foramen. Nearly opposite, but much further inwards the two fenestræ—fenestra ovalis and fenestra rotunda (*fs.o.*, *fr.*) are seen, and the large foramen lacerum posterius, or the common chink for the exit of the 9th and 10th nerves (IX., X.) in front of, and further out than the foramen condyloideum for the 12th nerve (XII.) in the exoccipital (*e.o.*).

The supraoccipital (*s.o.*) can be just seen behind the foramen magnum (*f.m.*); the lateral and basal tracts (*e.o.*, *b.o.*) are ankylosed. The condyles (*oc.c.*) are roughly pyriform, with the narrow part in front; each exoccipital grows out into a large, thick, down-turned paroccipital process (*p.oc.*). This is unusually large and well developed for one of the *lower* Eutheria. The whole occipital arch is distinct from the auditory capsules in front of it.

The skull of the adult Microgale longicaudata.

The skull, and indeed the whole skeleton of this small, very long-tailed Tenrec, resembles, very closely, that of the Common Shrew (*Sorex vulgaris*, see Plate 31)* both in size and form. But there are very important differences between the two, and on the whole this dwarf kind is but little altered, except in form, from the Centetidæ of a more normal size. The snout (*al.n.*) is somewhat shorter than in the Shrew; it is similarly deflected.

Investing bones of the skull of Microgale longicaudata.

In the *upper view* (Plate 35, fig. 2) the sutures are largely filled up, yet their place is seen in various markings. There is, however, one long, almost perfect, median suture from the snout to the lambdoidal suture, and the coronal is only filled in below. The premaxillaries (*px.*) are of considerable length, and are well wedged in between the nasals (*n.*) and maxillaries (*mx.*) above. The upper tract of the maxillaries is about equal to the nasal with which it is fused; they project over the lachrymal (fig. 3, *l.*); the alveolar part of the maxillary is seen in the distance. The boundaries of the frontals (*f.*) can be seen above, wedging in between the nasals and maxillaries in front, and between the two parietals behind; through their thin walls the ethmoid and its turbinal folds can be seen in the front half; the hinder half, apiculate before and behind, is smooth and gently convex. Swelling to a width one third greater than that of the frontals, the parietals (*p.*) nearly hide the lateral parts (*sq.*, *ep.*). Each forms its own round convexity (see also fig. 5, *p.*), the sagittal suture lying in a furrow. The bracket-shaped lambdoidal sutural line has a remarkable setting of

* See also DOBSON, *op. cit.*, Part ii., Plate 8, figs. 3-3f.

bones in a half-ring; these are undoubtedly the progeny of two primary interparietal scales that united at the middle and then broke up again in fresh places. There are three main pieces, subcrescentic in form; the convexity of the middle piece being in front, and of the other two behind; these are embedded along this wavy line of suture, besides several small pieces, like the fragments of the larger tracts. This curious *breccia* is very instructive; the median piece is the proper interparietal (*i.p.*), and the main lateral pieces (*s.t.*) are the counterparts of the familiar supernumerary temporal bones, or "supratemporals" of the Lacertilia. Bones so situated and so related are common enough in the *Ganoid* Fishes, and in those Teleosteans (Siluroids) that come nearest to them in their cranial scutes.

The *side view* of this skull is curiously mimetic of that of the Shrew (Plate 31), but the teeth are sharply diagnostic. Almost everything is revealed through the thin horn-like bony walls in this most exquisite little skull; the roots of the sharp teeth show through the outer alveolar wall; there is no special jugal process beyond the last of the series. The maxillary overlaps the frontal above, and then has a round notch in which the lachrymal and its canal (*l.*, *l.c.*) can be seen, although this fine film of bone has lost its sutural enclosures. Then there is a sharp spur, under and inside which the bone is hollowed out, and becomes a canal for some distance, opening in front on a very large infraorbital foramen (V^2). Above the sloping postero-superior edge of the maxillary, which is parallel with that of the ethmoidal region, a large tract of the badly-defined orbit, half its upper, and most of its lower inner face, is marked by the rich turbinal folds—middle and upper—of the lateral ethmoids. In the middle of their hinder boundary, sloping downwards and backwards, there is a large vascular foramen; and the curled lower edge of the orbital plate of the frontal is notched in the middle, below and in front of the larger notch, for the ophthalmic nerve (V^1). Here, at the postero-interior part of the open orbit, a lobular tract is seen, at the bottom of which the orbitosphenoid, *pierced by the optic nerve* (*o.s.*, II.), can be seen imperfectly.

Behind that oblique bony edge, which runs backwards and downwards, and is formed by the frontal, in front, the parietal above, and the squamosal behind, the lateral sinus (*s.c.*), throws its exquisite arch, clearly shining through the diaphanous walls of the parietal in its temporal region. Half-way between the end of the arch and the supratemporal bone there is a rough vascular foramen, close to the ragged hind edge of the parietal.

The squamosal (*sq.*) is about equal to that of the Shrew, but its temporal squama is higher, and is lobulate; it is confluent with the parietal in front.

The thick outer edge forks in front; and in the fork the glenoid facet (*gl.c.*) lies; the upper fork does not grow forwards as a definite zygomatic process.

The ribbed outer edge then goes backwards and a little upwards, and then spreads into an oblique four-sided enlargement, before it ends, as a sharp spike below the

hinder crus of the sinus canal (*s.c.*); the rest of the squamosal will be seen *from below* (fig. 1).

Here there is a real additional temporal scale-bone, or supratemporal (*s.t.*), but in those other dwarfed types—the Mole and the Shrew—the apparent second temporal bone was shown to be only a peculiar rambling of the *prootic bone* into the *pteric region*—a part, in fact, of the chondrocranium, ossified by a periotic bony centre.

Here, the likeness of this, the smallest of the Tenrecs to the dwarfed Shrew, is seen to be largely superficial; they are very wide apart, zoologically.*

The slender hamular process of the pterygoid (*pg.*) can be seen passing backwards from the thick palatine wall, and the annulus (*a.ty.*) also comes imperfectly into view in this aspect. The mandible (*d.*) is long, gently arched downwards, sinuous above, through the swelling caused by the teeth roots, and gently convex below. The coronoid process (*c.p.*) is a blunt, high triangle; the condyloid (*cd.p.*) is neat and rounded; the angular process (figs. 3, 4, *ag.p.*) is slender (almost Soricine) and somewhat incurved, below.

The *lower view* (Plate 35, fig. 1) shows a well-formed hard palate; the maxillary (*mx.*) fits by a sharply-pointed end against the premaxillary (*px.*), and the palatines against the maxillaries by a transverse, deeply toothed suture, in front of which each maxillary has a small fenestra. In front of that suture there are two, and behind it one, strong subtransverse ridge. The maxillaries bind against the open part of the palatines by a vertical plate, and the latter, after forming a strongly ribbed end to the hard palate, finish as a thick spongy wall to the nasopalatine passage; this is enlarged behind, as it narrows in, by the pterygoids with their delicate hooks; all the parts, here, are ankylosed together, so that the upper flange of the pterygoids is not distinguishable from the sphenoid bones, or the palatines from the pterygoids. The hinder part of the main (upper) vomer (*v.*) is seen in the roof of the nasopalatine passage; the other vomers could not be exposed either in this skull or that of *Ericulus* (fig. 11) without injury to the preparation. I take it for granted that in these parts these two kinds agree with *Centetes* and *Hemicentetes*. The squamosal (*sq.*), like the alisphenoid (*al.s.*), is dominated by the middle part of the organ of hearing. The outer part of the roof of the drum-cavity is formed by a shell-like ingrowth of the squamosal, behind and within the reniform glenoid facet (*gl.c.*).

The annulus (figs. 1 and 7, *a.ty.*) is strong, and well made for so small a beast, and has a considerable external convexity. Its rim is well-finished, its anterior crus binds upon and holds the processus gracilis (*p.gr.*), and its posterior crus is thickened where it is tied to the posterior angular process (*ag.p.*) of the *transformed articulare*.

The *end view* gives the relations of the parietal to the interparietal and super-

* There is no Soricine type as large as the Great Tenrec (*Centetes ecaudatus*), with which that large Insectivore might be compared; but the largest that can be found must be worked out, and the two compared together, if we would know how much in our little Shrew, and in this little *Microgale*, is due to their dwarfing.

temporals (*p.*, *i.p.*, *s.t.*), but it scarcely shows the squamosal (*sq.*); the form of the skull thus seen is reniform, with the hilus below, and is gently convex, with many sinuosities.

Endocranium of Microgale longicaudata.

I have no *inner views* of this skull, but through the huge foramen magnum (fig. 5, *f.m.*) the large cribriform plate is seen to have two deep antero-superior recesses; and the orbitosphenoids to be pierced by the optic nerves in the middle of their basal regions; the shallow sella turcica, and the deep *recessus flocculi*, in the auditory capsule, can also be seen thus, without injury to the prepared skull.

At this point and that the endocranium can be seen from without (Plate 35, figs. 1-5). The nonsegmented deflected snout, with its sublateral nostrils (*al.n.*, *e.n.*), is exposed; but the form of the true olfactory region can be traced and seen through the semitransparent frontals. The orbitosphenoid (figs. 1, 3, *o.s.*) is seen but little in any of these figures; the optic nerve (fig. 3, *II.*) is shown as emerging in front of the great sphenoidal side-passage, out of which escape the 3rd and 4th, the 1st and 2nd branches of the 5th, and the 6th, nerves. The alisphenoidal canal (*al.s.c.*) is short and its anterior opening, although less perfect than in the Dog, is plainly shown by a deep notch in the front of the alisphenoidal wall (*al.s.*); the foramen ovale (*V³.*) is well seen both in figs. 1 and 3, laterally; the suture between the alisphenoid and squamosal above (fig. 3, *al.s.*, *sq.*) is indistinct. In the *basal view* (fig. 1) the whole posterior sphenoid is displayed, a structure equally elegant and instructive. The sub-pituitary hollow is obsolete, the basisphenoid running backwards as a rounded balk from the presphenoidal, up to the basioccipital, region (fig. 1, *p.s.*, *b.s.*, *b.o.*).

Behind, in the latter region, the exposed part of the bone is a mere chink, owing to the proximity of the tympanic wings of the basisphenoid, which almost touch, back to back, like the aliseptal cartilages of the nasal labyrinth. These shell-like periosteal outgrowths (exogenous "ossa bullæ") are broad, notched, and out-turned in front; behind, they are pointed, and the last third of the strong *aponeurosis* is not ossified; so that these wings (or shells) do not finish the floor of the large tympanic cavity, but a large membranous space is left, bounded by the annulus in front, the bony ala inside the occipital arch, behind, and the mastoid process (*op.*) externally. On the other side, where the annulus has been removed, and the cochlea (*chl.*) exposed, the imperfection of the bony floor of the skull is seen. In front of the large auditory region the skull has a very fenestrate appearance, the two openings of the alisphenoidal canal (*al.s.c.*) and the large foramen ovale (*V³.*) cause this. The alisphenoids do not end after letting out the 3rd branch of the trigeminal nerve; a thick bar of bone runs across behind the foramen ovale, this is continuous, now, with the basisphenoid within, and supplemented, externally, by a similar wing or bar of the squamosal (*sq.*). This bony boundary of the drum-cavity is continued backwards by the outer (tegmental) edge of the squamosal, so as to form, roughly, a quadrant, which ends close in front of the

stylo-mastoid foramen (VII.). That tegmental edge of the squamosal runs inwards as a vaulted roof to the cavum tympani, nearly half-way across. Inside, the cochlea fills up the space behind, but, in front, the retral growth of the alisphenoid (*al.s.*) fills in three-fifths of the remaining space and sends backwards a spur to the cochlea, which divides the rest into a large outer, and a small inner, fenestra, covered only by the *dura mater*. This structure is *Soricine*, but it is also Marsupial; it is *much more Marsupial* in character than that which is seen in the Shrew.

The suture between the squamosal and alisphenoid is nearly lost, but the former sends downwards a thin lamina of bone which shows where they have joined; close inside the glenoid cartilage the squamosal is bent inwards, and appears as a convexity in the fore part of the tegmen. The (Marsupial) alisphenoidal wing (*al.s.*) is extremely thin, and coils over backwards as a sharp selvedge. The basisphenoidal wings (*t.b.s.*) are much deeper and more hollow than they appear at first sight, in the basal view (fig. 1).

Behind (fig. 1), the relatively spacious tympanic chamber is partly closed in, and filled up, by the remarkable auditory capsule, which is thoroughly ossified, and retains its distinctness all round its border; it is, however, not so loosely set in the skull as in the native Shrew, or as in our native Bat (*Pipistrelle*).

The tilting of the auditory capsules is shown in the side view (fig. 3), and the horizontal and posterior canals (*h.s.c.*, *p.s.c.*), are seen in that and also in the posterior view (fig. 5), and in the lower view (fig. 1). There is no prootic wall-plate in front of the smoothly convex part, through the walls of which these canals are seen.

The facial nerve (VII.) is seen emerging close behind a small, *separate* epihyal bone (*e.hy.*); inside these parts the fenestræ of the capsule lie out of sight. Inside and in front of the posterior canal, and of that part of the labyrinth into which it opens, there is a convex oval enlargement of the postero-inferior face of the cochlea (*chl.*), hiding its fenestra, which opens in front of, and above, the oval swelling, and externally forms the front margin of the *foramen lacerum posterius* (IX., X.). The basal and lateral upper elements of the occipital arch (*b.o.*, *e.o.*) are fused together; the basioccipital is short axially, and the lateral parts each form a small paroccipital process (*p.oc.*) close outside the large pyriform condyles (*oc.c.*). The supraoccipital (*s.o.*) is a large shield of bone, well in the back of the skull, and not lying over, as a hind *tegmen*, as in the Mole and Shrew. It is quite distinct from the auditory capsules, and is fused with the lateral elements of the arch (*e.o.*); lying over a very large foramen magnum, round, but with a recess in front, it is a relatively great shield of bone, with a large circular convexity in the middle, separated by two oblique fossæ from a subcrescentic convexity, right and left.

The supratemporal pieces (*s.t.*) impinge upon the bone over each fossa; it arches very accurately over each auditory capsule above and outside, where it has ankylosed with the exoccipitals (*e.o.*). The whole of the upper margin of the supraoccipital is

somewhat everted (fig. 2); the exoccipitals are pierced by the hypoglossal nerve (fig. 1, XII.); as usual, these foramina are very wide apart.

The ossicula auditûs,—hyoid arch, and meatus-cartilage of Microgale longicaudata.

The malleus (fig. 7, *ml.*) is remarkable in this, and in other small Insectivora; here the transverse extension of its main part is carried to the extreme, and here also the posterior angular process (*ag.p.*) is wrought into a very ornamental form, like a carved fruit-ornament; it is, as it were, suspended from the part which gives off the strong manubrium (*mb.*). The processes gracilis (*p.gr.*) is about equal to the manubrium; they are very far apart, and diverge, evidently; each is a twisted and thick-edged blade of bone, the *back* of which is in the inner side. The head is less definitely hooded than in the larger Centetidæ, but the large posterior margin is more elbowed; the condyloid face is deep and oblique, but not large. The incus and stapes (figs. 8, 9, *i., st.*) are quite typical, relatively large, and very elegant in form; the short crus of the incus (*s.c.i.*) is larger than in the Shrew; the stapes, most neatly finished, shows no interhyal on its neck.

The hyoid arch has a separate epihyal above (figs. 1, 3, *e.hy.*), and has also an upper and lower ceratohyal (fig. 6, *c.hy., c.hy'.*), the former is attached by ligament to the epihyal, above. The short hypohyals (*h.hy.*) are articulated to a process of the basal bar (*b.h. br.*), whose thyrohyals (*t.hy.*) are not distinct, but short, and diverge greatly.

Thus this small kind approaches our native Insectivora in the structure of its hyoid arch, which is much more perfect than in the kinds just described.

When the meatus externus is dissected, and the lining cartilage opened out (fig. 10), it is seen that there are three imperfect annuli, separated by deep notches, inside the continuous concha, the proximal edge of which has also two round notches.

The skull of the embryo of Rhynchocyon cernei; 4 inches long from snout to root of tail.

This is the largest of the *Elephant Shrews* of the African mainland, and is from the eastern part, near Zanzibar.

The Macroscelidæ, of which this is an outlying member and the largest of the family, are extremely unlike the insular forms from Madagascar, just described; this particular kind is the more interesting as being a native of that part of the African continent which lies nearest to that large and most remarkable island, which is not *African*. The Macroscelidæ, however, have a wide African distribution, continental and insular, and this large kind—*Rhynchocyon*—is somewhat aberrant.

So much does this type differ from the forms already described, namely, our native types and those from Madagascar, and also from those yet to be noticed, that, considered from the standpoint of their cranial morphology, I am surprised at the colloca-

tion of such diverse forms into a single Order of the Eutheria. But in this, as in many other types of Vertebrata, the highly compound cranial region retains a large number of archaic characters that are suppressed or lost in the body, and especially in the soft organs.*

The investing bones of the skull of the embryo of Rhynchocyon.

In this apparently nearly ripe embryo the bones as seen from *above* (Plate 36, fig. 1) form a nearly perfect roof to the rather long cranium. Of these the foremost, or nasals (*n.*), are only moderately long and broad; they are two-thirds the length of the frontals (*f.*), and of the same length as the sagittal suture. Rounded in front, they widen up to the triradiate suture, where they, the premaxillaries, and maxillaries (*px.*, *mx.*), meet; they are then somewhat pinched, and widen a little, once more, to unite with the frontals.

In strong contrast with what we see in the Mole and the Shrew, the frontals (*f.*) are nearly as wide as, and nearly one-fourth longer than, the parietals (*p.*), and although, together, they have a well-formed mid-orbital waist, they are very wide even there. Towards the still open, four-cornered fontanelle (*fo.*), the main upper part of these bones is gently convex; this convexity narrows, forwards, and there is a definite fossa marking it off from the supraorbital margin, which is very neat and finished, and quite unlike what we have just seen in the more typical Insectivora. Slightly overlapping the frontals, and wedging into their lower and hinder edge, the parietals (*p.*) give a great breadth to the intertemporal region; their convexity, above, is greater, altogether, than that of the frontals. The conspicuous temporal fossa runs round them, on the side and behind, up to the large triangular wedge of bone that shortens the sagittal suture and separates the two bones from the supraoccipital; this triangle of bone is the interparietal (*i.p.*).

Laterally, the premaxillaries, maxillaries, lachrymals, jugals, and squamosals (*px.*, *mx.*, *l.*, *j.*, *sq.*) can be seen flanking the great, gently convex, pyriform roof; all these are better seen, however, in the *side view* (fig. 3).

Here we find that the premaxillary (*px.*) is one-fourth the length, and one-half the greatest height, of the maxillary (*mx.*); its facial plate, thus seen, is notched in front, where it embraces the snout, and behind, when it is dented by the maxillary; above, instead of wedging in between the nasal and maxillary, it is actually rounded off. The maxillary is swollen in front where it runs against the premaxillary; above, where it runs up to the frontal, still more; and below, under the lachrymal and jugal bones (*l.*, *j.*). That last swelling is the outer alveolar wall of the last tooth, and above it there is a large and deep fossa for the maxillary nerve (V^2), but this

* Whilst very grateful for what the Zoologists send me, I feel no ways bound to their groupings of the types. Their zeal for Taxonomy is not always according to knowledge, and by their hard and fast lines they often put asunder what Nature has joined, and leave together types that are not closely related, but merely mimetic, or isomorphic.

nerve has no maxillary bridge over it at present. The lachrymal (*l.*) has a large, pentagonal facial plate; its thick orbital margin is somewhat notched, and inside that notch is the canal; the thickness of the orbital margin, which helps the frontal and jugal to give finish to the orbital ring for nearly three-fourths of a circle, is so large as to hide the interorbital plate of the bone and its canal.

Lying between the aberrant *Tupaia* and the typical *Erinaceus*, this type tends to finish its orbital ring, especially in the perfection of the supraorbital rim of the frontal; there is, however, no free postorbital process, the ribbed edge merely runs back and binds upon the parietal. The frontal is perfect in the upper half of the huge orbital cup, but unfinished, behind; yet giving promise of the Lemurine orbit—a promise fulfilled in *Tupaia*, soon to be described.

Behind that very extensive hollow, thin orbital plate, the parietal (*p.*) just comes in and divides it from the squamosal; the rest of the parietal is seen to be convex above, and gently pressed inwards over its lower edge, which has two large shallow emarginations; the one, in front, over the squamosal, and the other, behind, over the huge auditory capsule. The triangular interparietal (*i.p.*) is sinuously united to the parietal above, and hooks round its rounded hinder margin, lower down. From the middle of the lower edge of the parietal to the lachrymal the outworks of the skull are completed by two bones, the squamosal (*sq.*) and the jugal. The latter bone (*j.*) is strong for an Insectivore; it protects the maxillary nerve (V^2), wedges into the lachrymal and maxillary, is grooved and broad in front, outside, and ends as a blunt style below the jugal process of the squamosal, some distance in front of the glenoid facet (*gl.c.*). The squamosal (*sq.*) just rests its spike upon the jugal, and then broadens out into the glenoid tract, which is covered with a subconvex oval cartilage looking inwards and somewhat forwards (see fig. 2, *gl.c.*), and into the oval, hollowed, temporal plate, which overlaps more than half of the lower edge of the parietal. The jugal spike runs into the thick outer part, whose upper edge is sharp and sinuous, first convex and then concave, where it runs up and meets the squamous or temporal edge. The lower margin has two concavities, the glenoid, and tympanic, and two processes, the post-glenoid and the post-temporal, the latter is the larger of the two; under these we just see the tympanic annulus (*a.ty.*).

The mandible (*d.*) is scarcely developed into distinct processes, behind; the coronoid (*c.p.*) being very low; the rounded condyloid process (*cd.p.*) is separated by a rounded notch from the small, sharp, angular process (*ag.p.*); the ramus, with its swollen alveolar space, and teeth just cutting the gums, is gently convex, below, and with a slightly arcuate outline runs forwards to its narrow, pointed fore end.

In the *palatal view* (fig. 2) there seems nothing, at first, to remind one of the Marsupial; in this, *Rhynchocyon* agrees with the two types next to be described, namely, *Galeopithecus* and *Tupaia*. The general form of the palate is roughly oval, but emarginate at its narrow, fore end, and having a broken or dentate hind margin. The premaxillaries (*px.*) are of short extent, being largely overlapped by the maxillaries

(*mx.*). The alveolar walls of the *only upper incisor tooth* are imperfect behind; this tooth is often wanting in the adult. The openings for JACOBSON'S organs (*j.o.*) are far forwards, and the palatine processes of the premaxillaries are largely hidden by those of the maxillaries.*

The maxillaries (*mx.*) show three parallel regions in this view: the alveolar, with the large tooth-sockets and teeth just appearing; the submarginal, with oblique ribbings and hollows; and the sub-mesial, separated from the ribbed part by a crack, or sharp, roughish fissure, which looks very much like a suture. The outer part binds on the premaxillary, and the inner tract on its palatine process, hiding most of it. The submesial tract rises somewhat where it meets its fellow, so as to form a definite fossa; these two tracts fail behind, being aborted by the counterpart tracts of the palatines.

These bones (*pa.*) form a very elegant winged part of the hard palate, for the posterior palatine foramina notch them, close behind the fissure, in the maxillary plate, and inside the foramen they each have a round lobe running forwards, and outside it another, which fits obliquely to, and extends beyond, the end of the maxillary.

In front, these palatine plates of the palatines are hollow where they meet, and then this shallow fossa runs obliquely outwards on each bone, leaving the middle part convex. The hind margin, as a whole, is transverse, but it is deeply crenate, there being two notches on each side the projecting ends of the bone at the median suture. The orbital, or ascending, part of the palatines is steep, hollow inside, and gently convex outside; the hind half of each plate embraces the side of the presphenoid, and, slightly diverging, is joined by the small subvertical pterygoid (*pg.*), which diverges still more, and has a nucleus of cartilage (as in the Hedgehog and Mole) on its hamular process. I find no trace of the mesopterygoid—a *test-bone* for Marsupial relationship. Nor does the jugal (malar—*j.*) come near the glenoid facet; here, again, this type is normally Eutherian. The squamosal (*sq.*) has a short, triangular jugal process, overlying that great bone, and behind it the concave glenoid cartilage has a pyriform outline and an oblique position—inwards and a little forwards, also.

The lateral and post-glenoid part of the squamosal is rather feeble, and is bound upon by the tympanic (*a.ty.*); its processes are best seen in the *side view* (fig. 3); the hollow face of the wide orbital roof (*f.*) is seen in this view, in the distance.

The annulus (*a.ty.*) is like a large capital **G** with the top looking backwards; it gives a wide space for the membrana tympani, has a large trowel of bone on its front crus, and has the hind crus inturned and blunt. The cartilage of the Eustachian tube (*eu.*) is large, as in Marsupials, and as in Marsupials, behind and outside it, but inside the proper thick annulus, there is a thin crescentic “os bullæ”

* The abortive development of the single upper incisor, and the perfect condition of the hard palate, carry us far away—upwards—from the Marsupial territory. These things foreshadow what will be seen in Bats, some Lemurs (*Lepilemur*), and, ultimately, in the Ruminants.

(*o.b.*), exactly as in young Marsupials; the annulus thickens in front, just where it lies under the front crus of the os bullæ.

There are here five vomerine bones, as in the embryo Hedgehog, and Armadillo; the main bone or vomer proper (fig. 5, *v.*) is strong and carinate, and bluntly pointed at both ends; it is short for so long a skull, and its keel is very thick. The two antero-lateral vomers (*v'*.) are the largest I have seen, as yet, reminding one of their large cupped counterparts in the Ophidia and Lacertilia; they are ovato-oblong, and sculptured in their infero-external face, and are like two chaff scales of the Oat. The fore part of the main vomer (*v.*) is hidden by these two bones; the recurrent or JACOBSON'S cartilages (*rc.c.*) are seen outside them.

The narrow hind part of the main vomer (*v.*) is partly hidden by the two large postero-lateral vomers (*v''*.), which, as far as I know, are in this case relatively larger than in any other Eutherian; they are perfectly Metatherian in size and relations, nearly meeting in the middle, having there a ribbed edge, and sending outwards a large rounded lobe from their middle part; they are each nearly as long as the main vomer, and are twice as long as the antero-lateral pair (*v'*.). The hind part of each postero-lateral vomer (*v''*.) just overlaps the base of the orbitosphenoid (*o.s.*) and reaches the presphenoid (*p.s.*). The above are the whole of the investing bones I have been able to find in this type.

Endocranium of Rhynchocyon cernei.

The deep parts of this skull are as remarkable as the superficial; the diagnostic characters of several Orders meeting in one endocranium. That tract of the nasal labyrinth which is in front of the proper olfactory region is very long (Plate 36, figs. 4-7), and is segmented in all but its foremost and hindmost part; there are *thirty* double rings, and this is as true a "proboscis" as that of the Elephant. So long is this proboscis that the completely closed part is half as long as the whole labyrinth, which, altogether, is twice as long as the basis cranii, proper.

The nostrils (*e.n.*) are nearer the lower than the upper face of the snout, and are very near its end; the valvular coil of the nostril is very complete, and terminates in a free outer process. There the double tube is very narrow, but widens gently to twice its first width, it is then constricted twice, and swells again before the definite enlargement for the middle turbinals begin. There is then a deep constriction, and then the whole structure swells out to almost tenfold the width of the neck of the double snout-tube. Those swollen bags of cartilage do not meet each other below (fig. 5); above (fig. 4), they are deeply excavated, behind a short, perfect roof-region to form the two large circular multiperforate olfactory fossæ, each floored by the cup-shaped cribriform plate (*cr.p.*). Above, the septum (*p.e.*) terminates in a bulbous, free "crista galli" (*cr.g.*), but the sloping hind margin of the wall continuous with the cribriform plate, and notched where the multitudinous branches of the olfactory nerve pass through from the cranial into the nasal cavity (see fig. 7, *p.e.*), becomes much

thinner than it is above. Above (fig. 4) the inflated olfactory chambers turn round behind, and clasp the fore part of the orbitosphenoid (*o.s.*); there they are sharp or angular, but below (fig. 5), they end as rounded pouches, clasped by the base of the orbitosphenoids, and separated by the base of the perpendicular ethmoid (*p.e.*), where it is floored by the two large postero-lateral vomers (*v''*). These huge olfactory pouches reach nearly as far outwards as the equally large auditory capsules (*chl.*), although these latter are separated by the mass of the hind brain. Where the palatine processes of the premaxillaries are given off, and in the space between them and the alveolar margin of those bones (figs. 2 and 5), there the floor of the snout is emarginate and soon ceases; its hind selvedge being elegantly bracket-shaped. In that emargination lies the openings of JACOBSON'S organs (*j.o.*), seen in the anterior palatine foramina. For the rest there is a large ovato-oblong open space divided at the middle by the great septum and its splints. In front, the recurrent cartilages (*rc.c.*), are seen outside the antero-lateral vomers (*v'*); for some distance, then, the inferior turbinals (*i.tb.*) are also seen; but the nasal turbinals are out of sight, and the upper and middle are well within the great pouches. All these parts are cartilaginous at present; their detailed structure is quite like what I have already described in the Hedgehog and the Mole—by *dissections* and *sections*.

But the axial part of the nasal labyrinth (Plate 24, fig. 7) deserves special notice; it is mainly formed by the huge intertrabecula (*i.tr.*), which is as large relatively as in the embryo Bird, or in an average Selachian Fish. When we come to the long-faced Cetacea we shall see this element playing an important part—as in the embryo Bird—in the formation of the face, serving as a model on which the huge facial splints are laid; in them, however, the olfactory organs and their outer openings are drawn backwards, and this bar runs forwards independently of them; here, as is normal for a Mammal, the nasal roof is continued along its whole extent, and the alinasal part, runs round its front end.

In the rounded front of the snout the internarial septum is fenestrate (*i.n.f.*), a common thing in low Eutheria; and at that part the septum itself is largely formed of the alinasal cartilages, that, placed back to back, have coalesced with each other as well as with the median intertrabecular bar. Now, here, for the whole length of the aliseptal region, this is the case, so that up to the true olfactory territory the intertrabecula itself, is only slightly crested, the top of the low septum is, in reality, merely the confluent *alæ*, or roof cartilages. Hence, in this low wall, the first *three-fifths* is septum nasi, part of it roofed by the alinasal and part by the aliseptal tracts; these tracts are, of course, continuous, but they are true morphological *regions*. Of the hinder *two-fifths*, the first half is twice as high as the septum in front of it; it is now the perpendicular ethmoid (*p.e.*), then it lowers again, at first suddenly, and becomes a mere rounded bar, which passes insensibly into the presphenoid (*p.s.*), most of which is already ossified. The roof has several regions, well marked out; beginning at the front of the snout, we see the *alæ nasi* turned round and formed into the coiled nostril-valves, then comes a

narrow neck; these parts are all in a continuous tract of cartilage. But from the middle of that narrow neck up to the part under the triradiate suture formed by the nasals, premaxillaries, and maxillaries (compare figs. 1 and 4), each nasal tube is segmented into narrow rings, all of which, except those at the end (fig. 5) are perfect below. Yet at the mid-line each ring loses its distinctness, being confluent, above and below, with the septum.

This is a true proboscis, quite like that of an Elephant, and like that of the Myxinoid Fishes, except that it is double instead of being single, as in those *permanent larvæ*, with their primordial "cribriform plate." A little in front of the part which swells with the middle turbinals, these rings cease; there are *thirty* of them on each side.

The ossification of the proper cranium is very abruptly marked off from the unossified olfactory labyrinth. The anterior sphenoid is but little less than the posterior; it is in three "centres," but little united as yet, for the presphenoid (*p.s.*) is here, as in *Sorex* and the Marsupials, as distinct an element as the basisphenoid (*b.s.*); it is of the same length and not much narrower, but is somewhat hour-glass shaped. The orbitosphenoids have a large and pedate downgrowth proximally (fig. 5, *o.s.*), which fits close to the corresponding postero-lateral vomer (*v''*.) by the fore part of its pedate process.

The orbitosphenoids lie well over the hind part of the olfactory fossæ and their cribriform floor (*cr.p.*), and form a concave margin to that part, for they project far beyond their basal piece, fore and aft; most behind. Towards each other, right and left of the median ethmoidal wall-top, they are rounded and notched, and behind their junction with the presphenoid they have a large notch—a quadrant. Their outer margin, directed backwards outwards and upwards, is crenate, and the hind margin is also sinuous; its inner part ending as a spur *just inside* the foremost angle of the alisphenoid (*al.s.*). Hence these alæ do not, with their own basal piece, finish the "sphenoidal fissure;" it is completed by the posterior sphenoid, base and wing, with the help of the pre-basisphenoidal synchondrosis. The widened hind part of the presphenoid runs into the large oblique sphenoidal fissure, making it reniform, instead of oval.

The *optic*, as well as the *orbital*, nerves pass through this large, dilated fissure; *there is no optic foramen*; thus there are *three Marsupial characters* in this anterior sphenoid: (1) the orbito-sphenoid is only slightly overlapped by the alisphenoid—there is no gap, only a small squamous suture; (2) there is no optic foramen; and (3) the presphenoid is an autogenous bony element. The posterior sphenoid has about the same extent, axially; but laterally, it is one third larger, or nearly. The basisphenoid (*b.s.*) is as long as the presphenoid (*p.s.*), and is about one-fourth wider, on its upper face (fig. 4). It has a small open pituitary space (as an *Erinaceus* and *Sorex*), but the seat of the sella is shallow; there are no tympanic alæ. The alisphenoids (*al.s.*) are larger than they would seem to be, viewed merely from the upper surface (fig. 4); they are best seen from below (fig. 5). The 3rd branch of the 5th nerve (*V*³.) passes

through a large round notch in the middle of the hind edge of the bone, and the bone grows under the nerve for some distance in its passage to the lower jaw. The alæ are set on to the base obliquely, and the suture is on a level with the flatter upper face of the basisphenoid (fig. 4).

If there is no tympanic ala to the basisphenoid, that part being a separate "os bullæ" (fig. 2, *o.b.*), there is nevertheless a large tympanic ala (*t.al.s.*) growing from the hinder and under part of the alisphenoid; in form this hollow growth is like an ordinary tympanic annulus, being crescentic, and having a wide convex face and a ragged opening looking outwards. All this is truly Marsupial, and if these alæ coalesce with the ossa bullæ in the adult the conformity is perfect.

The auditory capsules are extremely large, and the petrous region is well ossified; but the mastoid region is almost wholly cartilaginous. The fore margin is convex and bulbous, where the capsule, by its cochlear region (*chl.*) fits into the large interspace between the alisphenoid and exoccipital (*e.o.*); but higher up the fore margin is notched and sharp in front of the ampulla of the anterior canal (*a.s.c.*), the upper margin is free, but the hinder has coalesced with the occipital arch, yet not so as to obliterate the boundary line.*

In the upper view (fig. 4) the coiled cochlear region (*chl.*), the meatus internus (VII., VIII.), and the base of the recess for the flocculus are seen, but the main part of that hollow is hidden by the subvertical part of the capsule, unossified, and showing the form of the arch of the great anterior canal (*a.s.c.*). In the side view (fig. 3) the large convex mastoid region shows the elegant sweep of the horizontal and posterior canals (*h.s.c.*, *p.s.c.*), the latter giving a smooth, rounded form to the mastoid margin of the capsule, with no "mastoid process." Beneath (fig. 5), the prootic and opisthotic bones are wholly amalgamated, the fore edge of the capsule and the cochlea being one common tract of bone—probably never quite separate centres, but developed, as in many Mammals, in a generalised way, as also is frequently the case in the Anurous Amphibia. The 7th nerve (VII.) can be seen running in its canal, reappearing inside the tegmen tympani, and burrowing again, to escape through the stylo-mastoid foramen, close behind the epihyal (*e.hy.*). In this view also (fig. 5) the fenestræ (*fs.o.*, *fr.*) of the auditory labyrinth are well seen, divided, as in *Marsupials*, by a wide opisthotic bony tract. Then comes the wide interspace, or foramen lacerum posterius (IX., X.), and the actually perforated exoccipital (*e.o.*) (XII.) for with the exception of the olfactory sieve, the hypoglossal nerve is the only one which passes through a proper endocranial foramen; the 7th and 8th perforate a sense-capsule, and not a part of the true cranium.

The occipital arch follows the auditory capsule, finishing the skull in a smooth and

* This embryo was probably ripe, or nearly so, yet the development of bone in the skull is very remarkable, and quite like the early ossification of the Marsupial skull; the sharp free edges of the infero-lateral bones have been formed by arrest of the ossifying process, combined with absorption of a large tract of chondrocranium.

rounded manner; the paroccipital ridges of the exoccipitals are scarcely marked, and the supraoccipital (*s.o.*) is gently convex. The basioccipital (*b.o.*) is large, and through the bulging of the bony sheath of the notochord (cephalostyle), subcarinate in front, below. The condyles (*oc.c.*) are large and obliquely reniform, and there is, besides these, much cartilage still left between the bony centres of the arch; the foramen magnum (*f.m.*) is very large, and pyriform in shape.

The ossicula auditus are already well developed, MECKEL'S cartilage being absorbed or used up in the lower jaw. The malleus (fig. 6, *ml.*) is almost completely ossified; the processus gracilis is still one-third larger than the manubrium (*mb.*), which is short and straight, and nearly parallel with the processus gracilis. The head of the malleus is bulbous and large, the posterior angular process (*ag.p.*) forms a small cartilaginous elbow to the manubrium. The hind margin of the bone is oblique and sinuous; altogether this malleus is very much unlike what is seen in the Mascarene types. The incus (*i.*) is quite typical, and has, for an Insectivore, a very large processus brevis (*s.c.i.*). The stapes (*st.*) is nearly typical; it is higher, however (or longer), and has a smaller fenestra than that of the typical Insectivora; it is fairly an intermediate form between the typical and the Marsupial stapes. Its neck and base are not yet ossified completely; I see no interhyal on the tendon of the stapedius muscle.

The slender epihyal (fig. 3, *e.hy.*) cartilage is continuous both with the auditory capsule above, and with the upper ceratohyal (*c.hy.*) below; that tract is now a slender bony rod, separated by a cartilaginous piece half its length from the lower ceratohyal (*c.hy'*), which is straighter, shorter, and stouter. The hypohyal segment is solid, conical, short, and articulates by its base with the basal bar; it is, at present, unossified.

The thick basal hyoid is U-shaped, and has a bony centre on both the base, proper (*b.h.br.*), and in the thyrohyals (*t.hy.*).

The emargination of the fore edge of the basihyal, and the general breadth of the whole of the hinder tract, makes this part, also, intermediate between the hyoid of a typical Insectivore and that of a Marsupial.

On the skull of the Colugo (Galeopithecus).

My materials for this type are as follows:—

Stage 1 (A).—A naked, but apparently ripe, embryo of *Galeopithecus volans* (?locality), 5½ inches long from snout to root of tail, with the umbilicus thick and soft.

Stage 2 (B).—A young specimen of *Galeopithecus philippensis*, 8 inches long to root of tail (well covered with hair).

Stage 3 (C).—A second young form of the same kind, one-fifth larger.

Stage 4 (D).—Two adult specimens of *G. philippensis*, which were taken with the two young individuals, in the Philippines, by Professor MOSELEY, F.R.S., during the

“Challenger” expedition, and put into my hands by JOHN MURRAY, Esq.; and one dry skull of the same species; locality unknown.*

Stage 1, A.—*The embryo of Galeopithecus volans*; $5\frac{1}{2}$ inches long.

The figures given of this embryo (Plate 16, figs. 15, 15A) at once show its utter unlikeness to the normal Insectivora; it belongs, undoubtedly, to their level or platform, but its relation to them is doubtful in the extreme. To the group below—the Marsupials—it is related, and to a group above—the Chiroptera—it is also related, as I shall show anon.

I shall not enter into either the zoological characters, or the visceral anatomy of this type, but speak of what I have found in the developing skull. Biologists can then deal with the evidence as to the Insectivorous or Chiropterous nature of this very archaic beast, at their leisure.

Stage 1 (A).—*Skull of Galeopithecus volans*; *embryo*, $5\frac{1}{2}$ inches long.

a.—*Investing bones.*

The general appearance of the dissected skull, with the investing bones complete upon it (Plate 37, figs. 1, 2; and Plate 38, fig. 1) is very similar to that of a young Phalanger, or *Cuscus*, of the same size, but about three months old,† but the form is in reality intermediate between that of the skull of those Metatherian types, and that of the young *Pteropus*, or Frugivorous Bat. By keeping these comparisons in mind we shall be able to see the meaning of many things in this type, which, however, has some unique characters; these are strange and unique, because the kindred of the two Colugos are all extinct. This skull is very flat or depressed, and its great breadth across the middle gives it an almost oval outline; the short snout scarcely breaking such a supposed circumscribing line, and the occipital region being merely sinuous, instead of regularly arcuate. The roof (Plate 37, fig. 2, *upper view*) is mainly composed of three pairs of bones that form a very regular series; these are the nasals, frontals, and parietals (*n.*, *f.*, *p.*), and behind these is the single interparietal (*i.p.*), once, no doubt, composed of a pair of centres. The nasals (*n.*), flanked by the maxillaries and premaxillaries (*mx.*, *px.*), are as long as the parietals, and nearly as long as the frontals. They are pointed in front and very broad behind, stretching outwards so as to be sutured to most of the fore margin of the frontals. Here, at once, we see the effect of the general depression of this peculiar skull, almost unique in the class, in its flatness and breadth. The frontals are well formed, and from the lachrymal to the parietal grow outwards as a neat supra-postorbital ledge; a large supra-

* The large size of the embryo which had, apparently, been taken from the uterus—as there was no shrinking whatever of the umbilicus—and the remarkable differences, soon to be described, between it and the other kinds, satisfy me that this belongs to the large species, *Galeopithecus volans*.

† At birth the Australian Marsupials range from the size of a new-born Mouse to that of a new-born Rat; this larger size is what is attained by *Macropus major*.

orbital foramen is seen near the front of this bony selvedge. The postorbital processes seem to clasp the parietals behind; these, the largest of the series, carry on and increase the general, gentle convexity of the skull-roof; the frontals wedge into them before, and the interparietal (*i.p.*) behind, so that the sagittal suture is scarcely more than two-thirds of the length of the frontal. The fore edge of the interparietal (*i.p.*) makes the lambdoidal suture bracket-shaped; that transverse, oblongo-oval bone, raises a new convexity over the hind brain; at present, the parietals are scarcely imprinted at all by the top of the temporal muscle.

This skull, which reminds one of anything rather than that of an Insectivore—for the Colugo might be called a *small primordial Herbivore, with a parachute*—has pneumatic squamosals as in the Marsupials; the squamous suture is seen in this upper view, and also the swelling of the bone caused by large air-cells outside the temporal fossa. The short zygomatic process is also seen in this view, and the thick top edge and hollow inner face of the jugal or malar (*j.*) which reaches far back, as we shall see in the other figures. Another thing is seen here in this marvellous little Herbivore, namely, the great backward extension of the maxillaries (*mx.*), with their large dentary region (see also figs. 1 and 3). We see also, obliquely over the growing hind sockets, the hinder opening of the infraorbital foramen or channel for the 2nd branch of the 5th nerve (V^2). Outside that passage, in the antero-external part of the orbit, there is another large passage, this is the lachrymal canal in the lachrymal bone (*l.c.*, *l.*), a large perforated shell of bone growing out upon the face, as well as forming a large part of the orbital cup in front.

All these things want supplementing by the lateral, lower, and end views of the skull (figs. 1 and 3; and Plate 38, fig. 1).

The *side view* (Plate 38, fig. 1) shows that the face is deflected considerably—an embryonic character—and that there is a definite hollow between the nasal and frontal regions above.

The orbital and temporal regions run into each other, but the enclosure of the post-orbital region is begun.

In the adult (Plate 39, fig. 3) the cranial cavity and the upper nasal region, from the end of the snout to the crista galli are equal; now (Plate 38, fig. 1), the brain-cavity measures nearly twice the upper nasal length; this is an early and also a Marsupial state of things, and would have been still more remarkable in an earlier embryo.

The nasals have a very convex dorsal outline, and dip where they slightly overlap the frontals laterally; they are in sutural relation with the deep facial plate of the pre-maxillaries and maxillaries (*px.*, *mx.*); the upper edge of the former is extensive, being three-fourths as large as that of the maxillaries. Two-thirds of the exposed outer face of the maxillaries is suborbital; a hollow, beginning in the premaxillary, runs along the maxillary up to the lachrymal (*l.*); near its end there are two small infraorbital foramina (V^2); the first hole is small on both sides; they, however, are very variable, as in one adult *Philippine* Colugo, I find two openings on each side, and in another four on

both sides. At present, the thickening of the orbital edge is formed by the lachrymal, and the maxillary is hollow up to it; below, the whole alveolar region is swollen but sinuous, it reaches to within a very short distance of the preglenoid convexity. The lachrymal is very large; its infraorbital plate was best seen in the last figure (Plate 37, fig. 2, *l.*); there it is seen to carry on the orbital ring, forming at least a quadrant; its swollen outer facial part corresponds to the excavated infraorbital tract (see the upper view). Riding over and outside the last two alveolar swellings of the maxillary, the large jugal (*j.*) begins narrowish and convex, and then forks, and becomes somewhat concave. The foremost upper fork tends to unite with the postorbital process of the frontal, and then to make a perfect orbital ring such as we shall see in the next type (the Lemurine *Tupaia*). This large jugal, like that of a Marsupial, grows over the fore part of the glenoid cartilage—a diagnostic Metatherian character. Most of the side of the skull is taken up by the enormous squamosal (*sq.*) which, measurement for measurement, is as large as the parietal.*

The squamous suture is very extensive; when seen from above (Plate 37, fig. 2) it is seen to be formed by overlapping the parietal, although it just touches the interparietal. The junction of the jugal with the zygomatic process of the squamosal is extensive, and its lower part is plastered by the glenoid cartilage; the glenoid cavity is deep and looks forwards and downwards, and is supported behind by a large postglenoid ridge. Behind that, the bone is cut away in a circular manner, with toothings over the eardrum; then from its postero-inferior angle it rises obliquely, being furthest backwards above, and has its thin rounded hind edge notched just below the middle, where it overlaps the mastoid region.

The suture with the alisphenoid (*al.s.*) in front is short and almost vertical; from it the temporal fossa runs backwards and upwards. The pterygoid hook (*pg.*) is just seen below the jugal and inside the small external pterygoid process of the alisphenoid (*e.pg.*). The annulus (*a.ty.*) is very instructively imperfect for comparison with the next stage (fig. 4), where it already forms a vertical opening or slit with bony lips. Here (fig. 1) it lies under the tegmen tympani as a shallow saucer-like bone, projecting in front, hiding its hinder and front crura inside the squamosal, and developing a rudiment from the hind crus which will become the hinder and lower part of the vertical bony meatus.

The mandible (figs. 1 and 2, *d.*) is decurved like the upper face, quite unlike the ascending “mentum” of *Cuscus*; so also the extended and out-turned angular region (*ag.p.*) is unique; it does, however, show an inflated inner face, as in Marsupials. The condyloid process (*cd.p.*) is not very sharply defined; the condyle itself is oval, with the long axis transverse; the coronoid process (*c.p.*) is small, oblique, and subuncinate; the whole ramus is sigmoid in its general outline.

* Here the skull of a young *Cuscus maculatus*, of the same size as this large embryo of *Galeopithecus volans*, comes in in a most timely way; that type is to me the most generalized Marsupial I have seen, and the squamosal in it is only less than that of the embryo Colugo.

The under view (Plate 37, fig. 1) is remarkable for its size, both in length and breadth; its length is considerably greater than that part of the basis cranii which lies behind it, and its breadth is equal to that part—the main part—which is formed by the maxillaries and palatines. The general form of the palatine region is oval, but irregular in front, and emarginate behind. Laterally the large alveolar tracts with their pushing teeth (some of them are *cut*) are very large; there are no teeth in the fore part of the premaxillaries, but two in each, on the side; these, however, are small. The fore margin of the premaxillaries is narrow, where they meet in a very obtuse angle; the lateral part of each bone projects forwards, and is subuncinate. The slender palatine processes of the premaxillaries (*p.px.*) are hidden, behind, by the maxillary palatine plates; when these are removed (Plate 39, fig. 1) then they can be seen as long, slender, arcuate, compressed bars, having no distinct antero-lateral vomers attached to them; but these bones *may* have become confluent with them. Through the narrowness of the premaxillaries in front, and the deficiency of the maxillary plates towards the mid-line, the anterior palatine foramina are very large; they are oval, and show a considerable tract of the recurrent cartilages (*rc.c.*), behind the opening of JACOBSON'S organs (*j.o.*). Behind the emargination the maxillaries scarcely meet for some distance, but the last two-thirds of their suture is perfect; right and left of this part the bone is concave, but this hollowing of the roof is much less than that which is found in young Marsupials; the sides also are hollow, thus there is a general crescentic convexity along the middle of each palatine plate. The hard palate is not extended backwards more than one-sixth further by the palatines (*pa.*), but they are strong bones, and the whole hard palate shows nothing of that economy of bony deposit seen in Marsupials and typical Insectivores. The skull set up, and with the palate towards the eye, shows, here, a very elegant double archway to the two nasal passages. The thick, ribbed margin of the bones projects where they meet, so that the end of the hard palate is bracket-shaped; in front of each thickening the oblique posterior palatine foramen (*p.p.f.*) is seen. These narrow curved palatines lie like scales under the maxillary plates, and their curved thin fore edge retreats, laterally, and then turns a little inwards, where it is pressed against the alveolar wall of the two last teeth. The thick side wall of the open part still gently curves inwards; it is separated outside from the palatine portion by a large sharp notch. The shell-like orbital or ascending part of the palatines meets the hinder part of the main vomer (*v.*), almost reaching as far backwards as its four terminal prongs. The small pterygoids (*pg.*) also ascend, and below, where they are spliced obliquely to the palatine wall of the great nasopalatine canal, they end, behind, in the hamular process, which is small, flat, and turned outwards; it is supported, outside, by the equally small external pterygoid process (*e.pg.*). The pterygoid is very small, as in the Marsupials, and this comes from the fact that what is generally, in the higher mammals, the upper or basicranial flange, is here, as in the Marsupials, a long, tongue-shaped mesopterygoid (*ms.pg.*). This flat bone is sharp in front, where it wedges in

between the palatine and pterygoid, and blunt behind, where it partly hides the basisphenoid (*b.s.*); its front part hides the side of the presphenoid (*p.s.*); it is gently arcuate, the convex side being towards the mid-line. To see the rest of the splints of the fore part of the skull the palatine plates have to be cut away (Plate 39, fig. 1). The main vomer (*v.*) is five-ninths the length of the whole bony skull, measured along its base. Its blunt point fits in between the hinder third of the palato-premaxillary bars; there it becomes subcarinate, widening gently; its broadest hinder part is distinctly keeled, and that keeled part is exposed in the open nasopalatine passage (Plate 37, fig. 1). The subcarinate part is strongly clamped by the bones of the hard palate, and thus the nasal passages are divided. The postero-inferior part of the nasal labyrinth is underfloored by lateral bones, behind the great inferior openings which have the maxillary plates as their floor; but for these plates the greater part of this region would be "schizognathous." Behind, however, the "desmognathism" is double—upper and lower; this is caused by the meeting together of the notched orbital plate of the palatines and the "postero-lateral vomers" (*v''.*)—two triangular wedges of thin bone that by their most acute angle fit in between the vomer and recurrent cartilage in front, have their obtuse angle external, and their less acute angle wedged in between the vomer and palatines. These bones are larger than usual for even an Insectivore, but are not distinctly Metatherian—as in *Rhynchocyon*, where they nearly meet behind the median vomer. Thus the creature sways, so to speak, everywhere, between a normal Eutherian and one of the Metatheria. The strong jugals (*j.*) bind against the maxillaries in front and widen out; they then thicken, are hollow outside, and end obtusely just over the glenoid facet (*gl.c.*). The great pneumatic squamosals (*sq.*) show some of their most marked characters in this aspect, for both the hinge (*gl.c.*) and the pneumatic cavities are to be seen from below. The zygomatic process is short, the glenoid facet is concave, oval, and almost transverse,—it looks obliquely downwards, and forwards, and retreats a little at its inner end. The post-glenoid ridge is large and thick, and the bone extends inwards beyond it, clamping the alisphenoid (*al.s.*), and nearly reaching the cochlea (*chl.*). The outer edge is tucked, as it were, under the skull and round the top of the tympanic cavity.

Behind, the squamosal embraces the mastoid part of the ear-labyrinth, and that edge is, close in front of the arrested and coalesced, epihyal (*e.hy.*). The roof of the tympanic cavity—tegmen tympani—is largely formed by the squamosal, and that roof opens into the air-galleries above, that give the sinuous appearance, and apparent thickness to the bone (fig. 2, *sq.*).

The tympanic ring (*a.ty.*) is in a remarkable state of development for an embryonic Insectivore; its development is equal to that of a Rodent or a Herbivore (Ungulate). But although large, the bone is shallow—a mere saucer, and the air cavity in it is very limited as to depth; but this is compensated by the extensive galleries that are developed in the squamous and mastoid regions (see in the adult, Plate 39). This tympanic dish (Plate 37, fig. 1, *a.ty.*) has a spout in front, an accurate round notch—the

opening—on its outer edge, and a small unfinished part behind that notch; its general form is round and gently concave above and convex below, but it runs into crenations at the postero-external margin, and also (Plate 38, fig. 1, *a.ty.*) is developing a process which is the rudiment of the compressed bony meatus externus (see Plate 38, fig. 4, *a.ty.*).

The *end view* (Plate 25, fig. 3) shows the imbrication of the roof-plates as they fit upon the occipito-auditory region; the parietals, interparietal, and squamosals (*p.*, *i.p.*, *sq.*) are thus seen, and the latter show their sinuous enlargements, due to the excavations within them.

Endocranium of embryo of Galeopithecus volans; 1st Stage (A).

Many things belonging to the inner cranial structures can be seen in the dissected, but perfect, skull (Plate 37, figs. 1–3; and Plate 38, fig. 1); but only when the investing bones have been removed are the deep parts thoroughly visible.

Such further dissections are figured in *lower* and *upper views* (Plate 39, figs. 1, 2), with some of the investing bones, left for the most part in outline, to be useful as landmarks.

The short, broad snout (*al.n.*) has its nostrils (*e.n.*) near the end, and rather underneath; the snout narrows in front, broadens behind the nostrils, and then is somewhat pinched in.

From the middle of the floor, which crosses over the premaxillaries (*px.*), the recurrent cartilages (*rc.c.*) are given off, these grow round the opening of JACOBSON'S organs and then run along on their inner and under side as their proper, but imperfect, capsule. These curious retral growths of the snout are *twice as long* in this species as is normal, a fact the meaning of which I cannot explain, but which will be understood when our knowledge of these parts is more advanced.

The inferior turbinals (*i.tb.*) are very feeble, but the foremost coil of the middle turbinal series (*m.tb.*) is very large indeed—both in width and in length; it extends forwards twice as far as usual: three other coils of this series are seen behind it.

Above (fig. 2), in this species, the olfactory labyrinth (*al.e.*) is seen to be short, and not very wide; this is partly due to *age*, and is partly a specific distinction. The whole *face* being shorter and broader in this embryo than can be accounted for by difference of age; the thick top of the septum (*p.e.*) does not end in a definite crista galli. The top of the great septum (*p.e.*) is very oblique, it is narrow, and has a smaller perforated plate (*cr.p.*), right and left of it, than is usual in Insectivores. This cribriform plate is quite unlike that of the Hedgehog or the Mole, and is quite like that of a young Frugivorous Bat (*Cynonycteris collaris*), now before me. Its upper recesses are shallow, its size is small and sub-oblong—widest above—and its perforations are comparatively few; the Frugivorous Bat on one hand, and *Cuscus* on the other, gives us the two cribriform plates most like it. A tract of median cartilage is

seen above, behind the cribriform plate, which is the end of the perpendicular ethmoid, and the beginning of the presphenoid. All the fore part of the basis cranii on the *under surface* (fig. 1) up to this point is hidden in the lower view by the vomers. In the upper view (fig. 2) the orbitosphenoids have lost their large cartilaginous upper part, and now form two oblique, four-sided wings (*o.s.*) that have met, and largely coalesced below, to form a long presphenoidal region, as in the Hedgehog and the Mole; the Shrew, as I have shown, agrees with the Marsupials in having an independent presphenoid; that is a rare thing among the Eutheria, but is seen in small Rodents. The optic foramen (II.) is very large—a good Lemurine character—and the bar enclosing it, behind, is strong; here we are far away from the Marsupials. There is still much cartilage between the presphenoid and basisphenoid (*b.s.*); the fore margin of the latter is bilobate, and its sides show some remnants of the expanded parts that in typical Insectivores form the tympanic wings; there are two irregular knobs on each side. The alisphenoids (*al.s.*) are still distinct from the basisphenoid, they are one-third larger than the orbitosphenoids, and overlap them by their inner and anterior angle much more than in *Rhynchocyon* and the Marsupials; this corresponds with what we see in Bats, but is quite unlike the peculiar overlapping growth of the alisphenoid in typical Insectivores. Each wing is ear-shaped, narrowing in behind, and so deeply notched for the 1st and 2nd branches of the 5th and the orbital nerves in front (V^1 , 2), and by the 3rd branch (V^3) behind, that there is only an isthmus of bone one-third the extent of the wing between the two great round notches; this is equally true of these parts in a young *Pteropus*. When the soft tissues are removed between the posterior sphenoid and the auditory capsules (fig. 2), then a very irregular middle lacerated foramen is seen, this is bounded posterolaterally by the squamosal (*sq.*). That bone covers nearly all the auditory capsule, externally (Plate 38, fig. 1, *sq.*, *op.*), and *below* (Plate 39, fig. 1. *op.*), only a small mastoid tract is seen clamped by the squamosal, perforated by the facial nerve (VII.), and having in front of that foramen (stylomastoid), a very small rough bony elevation, the arrested and confluent epihyal (*e.hy.*). There the bony capsule is pinched, for the exoccipital (*e.o.*) nearly meets the squamosal in front of the epihyal knob. Then the auditory labyrinth expands, running inwards and forwards, and showing, from behind forwards, the heart-shaped fenestra rotunda, the oval fenestra ovalis, and the notch in front of the latter, through which the facial nerve (VII.) passes to get under the tegmen tympani (*t.ty.*); the whole fore and under part is the smallish, obtuse cochlea (*chl.*).

Above (fig. 2), the capsule is well displayed; it has a rough keel in front of the proximal cochlear eminence, behind which, running inwards and a little backwards, are several holes. The porched meatus internus, on the inner side, contains several of these, the outermost being for the facial nerve (VII.) and the other for the auditory or portio mollis (VIII.). The former passes under a thick bridge of bone, and then runs round and escapes through the notch in front of the fenestra ovalis (fig. 1, *fs.o.*,

VII.). Then comes the arched part containing the anterior canal (*a.s.c.*) bent over the hollow for the flocculus cerebelli; the arch runs backwards and inwards to meet the occipital arch, strongly clamped by the thick hollow squamosal (*sq.*). From the bridge over the facial nerve there is on the left side a short, and on the right side a long, spur of bone, running upwards towards the arch of the anterior canal. The whole auditory capsule is well ossified, just a little cartilage remaining in the mastoid eminence (*op.*) and along the epiotic margin, but the occipital arch has still large synchondroses (Plate 37, figs. 1–3; Plate 38, fig. 1; and Plate 39, figs. 1, 2). The supraoccipital (Plate 37, fig. 3, *s.o.*) is a large shield of bone, round above, notched below, and with sinuous sides; it was, evidently, double at first, is convex above, and along the middle, and is a little scooped for muscular attachment infero-laterally. Then comes a large triradiate tract of unossified cartilage, below which there is, outside, the mastoid bone (*op.*), and inside, the exoccipital (*e.o.*); the former ends in a small cap of cartilage. The curved exoccipitals are everted against the mastoid bone, but they keep well inside it, and form no definite paroccipital prominence. The condyles are long (deep) and roughly crescentic—broad above, narrow below—and help to enclose a large foramen magnum (*f.m.*).

The basioccipital (Plate 39, figs. 1, 2, *b.o.*) is twice as long as the basisphenoid, it is narrow in front, broad behind, subconcave above, and subcarinate below; it is separated from the lateral ossifications by a large tract of cartilage, and is perforated by the large hypoglossals (XII.), and notched by the vagus and glossopharyngeal (X., IX.).

So far advanced is the embryo before birth—equal to that of a young Marsupial eight months old—and the Marsupials ossify their skull earliest of all kinds—that the processus gracilis of the malleus (Plate 37, fig. 4) is already only half the size of the manubrium (*mb.*). The posterior angular process (*p.ag.*) is a distinct knob, but small; the head of the bone is bulbous. The incus (*i.*) is very bulbous, and is very similar to that of a very different Order of Herbivores, namely, the Ruminantia (DORAN, plate 61, figs. 12–21). The short crus (*s.c.i.*) is very short and small, and the long crus (*l.c.i.*) although normal in form, is small as compared with the bulbous body. The height and basal breadth of the stapes (*st.*) are about equal, the fenestra is small, as in those Marsupials that have this hole; the interhyal is arrested.

The ceratohyal (Plate 38, fig. 3, *c.hy.*) is in one slender subfalcate segment, with the lower part ossified; the hypohyal (*h.hy.*) is less than half of the length of the ceratohyal, but it is thicker; it is not ossified. Nor is the U-shaped basal cartilage (*bh.br.*) which has flat and uncinat thyrohyals (*t.hy.*), not yet segmented from the basal tract, which is small and narrow. This os hyoides is quite unlike the perfect arch of the British Insectivora and the East African *Rhynchocyon*; it is better developed than that of the larger Centetidæ, and is about equal to that of a Marsupial at the same stage of development. The small, simple *concha* (Plate 37, fig. 5), shows an imperfect segmentation of the annuli inside the dilated leafy growth of cartilage.

Stage 2 (B).—Young of Galeopithecus philippensis; 8 inches long from snout to root of tail.

The investing bones of the skull.

The *side view* of the skull (Plate 38, fig. 4) reminds one of that of an Ewe, or of a Llama, just as the incus, as we have seen, is like that of the Ruminants; the side view of the head in the embryo of the other species (Plate 16, fig. 15A) suggests the same resemblance. Anyhow, whatever it is *like*, the skull is as *unlike* that of a normal Insectivore as it can well be. The centre of the orbit is at the middle of the length of the whole skull, including the snout; the facial part is much shorter in the embryo of the other kind (compare Plate 38, figs. 1 and 4). More than a third of this large orbit—Lemurine as to size—is unenclosed behind; it is more circular than in the young specimen. Through advanced growth, the hollow over the fore part of the orbits, and the deflection of the snout, are less marked. Now, the highest convex part, above, is parietal (*p.*), and the supraorbital ridge is higher than the upper face of the frontals (*f.*), and the convex dorsal line of the nasals (*n.*) is a little less rounded. The embryonic curve of the whole skull is now much less evident; but the straightening process is not finished yet. The premaxillary (*px.*) runs further into the maxillary (*mx.*) in the facial suture, and the latter is much more outspread in the preorbital region, quite flush with the lachrymal (*l.*) The latter bone encloses a fourth of the orbit, and a third of its actual rim. Its canal is well inside the edge, as in the *Hyrax*, and not outside as in Bats, Lemurs, and most Marsupials. These latter, as a rule, have two *canals*—one in *Phalangista*. The facial part of the lachrymal is a large lunule and the orbital a thin polygonal plate. The small double infraorbital foramen (V^2) is below the convex preorbital margin of the maxillary. The developed orbital rim hides the inner opening when looked at in this aspect. The orbital edge and postorbital process of the jugal (*j.*) are better grown now, and the latter is not so far back; it is nearly over the middle of the well-developed cheek-bone. A tri-radiate concavity traverses the large orbital plate of the strong-browed frontal (*f.*); that shallow fossa ends below and behind in a rounded notch, which is made into a foramen (*f. orbitale*) for the re-admission of the ophthalmic nerve (V^1) inside the skull-wall. The frontal bone interdigitates with the parietal (*p.*) under and behind the postorbital process, and then that gently swelling roof-bone runs back to the transverse interparietal (*i.p.*). Behind the *f. opticum* (see fig. 1, II.), the large alisphenoid wedges apart the frontal, parietal, and squamosal; the latter (*sq.*) is squarish, and large enough to hide most of the side of the hind skull; it corresponds with that of an Eastern Marsupial; in *Didelphys* it is much smaller; it is in remarkable contrast with that of *Erinaceus* and *Rhynchocyon* (Plate 20, fig. 3; and Plate 36, fig. 3); in *Pteropus* and *Lepilemur* the parietals throw the squamosal down to the side, and, in their much fuller growth, overshadow it.

Here the zygomatic process, the glenoid cavity, the postglenoid ridge, the supra-tympanic notch, the temporal fossa, the tempora squama, and the post-tympanic angle are all in a high state of development. Below and inside the elegant sigmoid jugo-squamosal suture we see the internal pterygoid hook, and the small external pterygoid plate (*pg.*, *e.pg.*). Built well into the deep rounded tympanic notch of the squamosal, we see the strong compressed bony meatus externus (*m.a.e.*), standing out from the general tympanic dish (*a.ty.*); it is open above, as the squamosal is below; together they make a vertical narrow bony-lipped passage to the shallow drum-cavity and its extensive upper galleries—that is, after the membrana tympani has been removed from the inside of this narrow porch. The lower jaw (figs. 4 and 5) has, already, nearly assumed the adult form, with its deflected mentum, its oblong dentary region, its small unciform coronoid process, its non-pedunculate condyle, notched behind, and its wide out-turned angular region, with an incurved inner edge.

The *lower view* (Plate 37, fig. 6) shows some contrasts with that of the embryo of the other species (fig. 1) that cannot all be put down to a further stage of development. Here we must make allowance for two causes of difference—age, and diversity of species.*

Here (Plate 37, fig. 6) the alveolar tracts are more nearly parallel than in the other kind (fig. 1), and this is not merely due to advance in growth, but is partly also specific. The fore part of the premaxillaries (*px.*) is slenderer, and the maxillary palatine plates have grown further forwards.

With this fuller development of the palatine plates, the hollowness of the palate in its middle—a remnant of the old Marsupial feebleness of this part—is almost gone, although the mid-line is hollow, and a shallow fossa runs right and left, cross-wise, near the hind margin of the maxillary plates. The palatine plates of the palatines (*pa.*) are like those of the other kind, but they are more extensive, and in this stage we have a complete sutural analysis of the peculiarly elegant archways of the nasopalatine passages of the adult Colugo. The squamous suture of the maxillaries and palatines is arched, but runs transversely in this case, and the narrow fissure between the flat part and the ribbed edge is widened out into a very remarkable uncinat concavity, ending sharply, outside, in the posterior palatine foramen (*p.p.f.*). Here, again, we see the sharp angular space between the palatine part and the mere side wall, which turns inwards to join the feeble pterygoids (*pg.*), which have a basicranial tract, ending in a toothed edge, between the orbital plates of the palatines and the long tongue-shaped mesopterygoids (*m.s.pg.*). These latter reach nearly to the basi-occipital (*b.o.*).

* The difference is as remarkable as the similarity (Plate 37, figs. 1 and 6); and if these two *waifs* can show such curious and notable modifications, although so close akin, there can be no difficulty in imagining a large number of similar but greater differences in structure in whole hosts of related forms, which may at one time have existed, and which were, probably, potent in species, genera, and even sub-families.

The splint bones that support the basis cranii, lying on a higher level, are the vomer and the "parasphenoid;" the former (fig. 6, *v.*) is here seen to be the common keystone of this very perfect double archway of the nasopalatine passages (*n.p.c.*). The keel of the vomer wedges itself in between the ribbed edges and the two palatines, and these complete the divisions of the common nasopalatine channel; its broad sides then unite by harmony with the orbital plates of the palatines, so that it is conjoined with those bones both in the middle and also right and left. These lateral flanges of the vomer end as free spikes under the presphenoid (*p.s.*), and the middle, shorter part is also split. But the other bone just mentioned—the "parasphenoid"—is not seen in the embryo of *G. volans* (fig. 1), nor, indeed, in *any other Mammal* examined by me, as yet.*

This small style of bone lies under the foremost two-thirds of the basisphenoid (*b.s.*), but is very distinct from it; it resembles, at first sight, the ridge often seen under the basioccipital, which is due to the ossification of the sheath of the notochord; but this tract is wholly *pro-chordal*. It is the exact counterpart of the parasphenoid of the Lacertilia, which disappears as mysteriously in some kinds as in *G. volans*; in the case of two closely related Cyclodonts—*Cyclodus nigroluteus* and *Trachydosaurus rugosus*: in the latter it has been taken away, and in the former it has been left. Here the Marsupial condition of the well-developed jugal (*j.*) is seen again (fig. 6, *j.*), and a still more extensive development of the equally Marsupial squamosal (*sq.*) with its thick, crescentic, hollow postglenoid process, its large pretemporal part clamping the alisphenoid (*al.s.*) and its extensive swollen post-temporal plate. The tympanic (*a.ty.*) is, here, most instructive as to the interpretation of the thoroughly ankylosed adult skull (Plate 39, figs. 3–8). This bone, now well-formed, is a remarkable shallow dish with a most irregular outline, and a crescentic convexity in its deepest part, the convex outline of which runs close to the fissure for the exit of the glossopharyngeal and vagus nerves (IX., X.).

Where, as a rough wedge, it runs forwards and reaches the mesopterygoid, there it has a considerable oblique foramen, the Eustachian opening (*eu.*); this is surrounded by cartilage in the embryo (fig. 1). Externally it is jammed in between the postglenoid and post-temporal elevation of the squamosal (*sq.*, see also Plate 38, fig. 4, *a.ty.*). Thus, since birth, it has finished the bowl of the dish and formed the deep two-lipped spout—the bony meatus externus.

In the *end view* (Plate 37, fig. 7) the parietals (*p.*) are seen with their lower edge forming the top of the temporal fossa, which half is scooped out of the squamosal (*sq.*). The swelling of the post-temporal part of the latter bone (see also Plate 38,

* I shall have to describe a pair of bones found *in membrane*, and added to the basisphenoid, when I come to other and higher kinds of Eutheria; these have long been known in Man as the "lingulæ sphenoidales." I strongly suspect that they are the "basitemporals"—symmetrical remnants of the parasphenoid—so well seen in Birds and the Crocodilia (Phil. Trans., 1869, Plate 82, fig. 2, *b.t.*; and Trans. Zool. Soc., vol. 11, plate 66, fig. 3, *b.t.*).

fig. 4, sq.), close to the large air cavities within, is also well seen. The interparietal (*i.p.*) has begun to develop the occipital crest so large in the adult (Plate 39, fig. 4).

Stages 2 and 3 (B and c).—Showing endocranium and certain of the investing bones of Galeopithecus philippensis.

These two stages differ but little from each other, and for the advance of the endocranium may be taken together. In the longitudinally vertical section (Plate 38, fig. 7) the cranial cavity, and the nasal labyrinth are equal in length; the former overlaps the latter in front. The obliquity of the top of the perpendicular ethmoid (*p.e.*) is such as to make a very obtuse angle with the top of the general septum (*p.e.*, *s.n.*), whilst it is almost in a line with the basis cranii behind, just rising a little at the crista galli (*cr.g.*). The recess for the olfactory lobe, lying on the oblique cribriform plate, is not large—very little in advance of the same in the Marsupials. Only about a fifth of the general partition (*p.e.*) is ossified at present; this is a long way from the presphenoid (*p.s.*) and does not reach the bottom; the intertrabecula itself is hardly touched, only its crest.

This is a very long septum (*p.e.*, *s.n.*) for so short a snout; in most of the Insectivora it is that part which prolongs the septum, forwards; here, it is the elongated facial region itself, with but little alinasal addition. The deflection of the whole face is still evident, and the end of the septum is almost in a line with the general palatal tract. Behind that part the opening of JACOBSON'S organ (*j.o.*) and the fore part of its cartilaginous capsule of the near side is shown; behind, where it is cut across, the vomer (*v.*) is seen.

That long trough of bone is half the length of the cranio-facial base, reaching from the front third of JACOBSON'S (recurrent) cartilage (*rc.c.*) to behind the middle of the presphenoid (*p.s.*). As it supports the intertrabecular base of the nasal partition, so it is itself supported by the bones of the hard palate (*p.mx.*, *pa.*) at their junction along the mid-line; thus the nasal cavities as they pass towards this hinder opening are kept distinct.

Over the septum nasi (*s.n.*) the nasal (*n.*) is seen, and the frontal (*f.*) over the ethmoid, and over the cavity of the skull in front. At this stage the roof-bones are thick; the parietal receives the hinder angle of the frontal into a notch, laterally, and is partly overlapped by, and partly overlaps, the frontal. The well-ossified anterior sphenoid (*o.s.*, *p.s.*) is seen in this view, the wing rising into a rounded angle, and having the large optic foramen (II.) near its hind edge below; the presphenoidal tract is rather thick, and is longer than the bony plate—basisphenoid (*b.s.*)—behind it. The alisphenoid (*al.s.*) leans against the orbitosphenoid, and rises to the same height; it overlaps it in front, and is then only partially visible in this view.

The short basisphenoid (*b.s.*) dips a little, but gets no postclinoid ridge again, behind; there is a small tract of cartilage between all these basal bones (*p.s.*, *b.s.*, *b.o.*). Under

the basisphenoid the parasphenoid (*pa.s.*) is seen. Between the alisphenoid and the auditory capsule there is a large semi-oval space filled in by the squamosal (*sq.*), which is hollow inside, the concavity being a continuation of that formed by the parietal. Above the hind corner of the squamosal and over the upper and front part of the auditory capsule the parietal forms a thick and rough rudiment of the "tentorium cerebelli." Under that rafter-like bar the squamosal (*sq.*) shows a roughly triangular inner face, which lies outside the arch of the anterior canal (*a.s.c.*), and supports the lower half of the fore edge of the supraoccipital (*s.o.*); the re-appearance of the squamosal inside is due to its great height, especially behind. The auditory capsule is subvertical in position, and in this view shows the great arch over the recessus flocculi, the multiperforate meatus internus (VIII.), with the bridge over the facial nerve (VII.) a thickening where the posterior canal (*p.s.c.*) begins, and a somewhat notched edge where the 9th and 10th nerves (IX., X.) emerge. The basioccipital (*b.o.*) is thick in front and thin behind; it is one-third longer than the basisphenoid (*b.s.*). By an obtuse angle it wedges in between the capsule and the lateral occipital (*e.o.*), which is a broad and high bone, having a large oblique hole for the hypoglossal nerve (XII.) not well seen in this aspect, and a small posterior condyloid foramen (*p.c.f.*). The supraoccipital (*s.o.*) and interparietal (*i.p.*) now form one large shield-shaped bone, finishing the postero-superior face of the skull, and articulating with the parietals and exoccipitals, but kept apart from the petromastoid by the large post-temporal part of the squamosal.

In the side view of the smaller young of *G. philippensis* (Plate 38, fig. 4) the snout with its valvular opening (*al.n.*, *e.n.*) is seen in front, and the top of both the orbitosphenoid and alisphenoid (*o.s.*, *al.s.*) laterally, in the fundus and back of the orbit. Here it is seen that the alisphenoid reaches much higher than the inner view (fig. 7) would seem to show. The occipital condyle (*oc.c.*) is seen in both these views, and some part of the mastoid (*op.*), the exoccipital (*e.o.*), and the supraoccipital (*s.o.*).

In the *basal aspect* (Plate 37, fig. 6) several important parts are displayed, not covered by the superficial bones. In front, the alinasal region shows with great distinctness the origin of the recurrent cartilages (*rc.c.*); the external nostrils (*e.n.*) are more terminal, as in Marsupials, than in the other kind. The presphenoid, basisphenoid, and basioccipital (*p.s.*, *b.s.*, *b.o.*) are displayed, with the parasphenoid (*pa.s.*) under the middle piece; the basisphenoids and basioccipitals are much wider in this space than in the other. The alæ are not much displayed, and the alisphenoid is largely overlapped by the squamosal. The small mastoid process (*op.*), with the stylo-mastoid foramen and epihyal in front of it, and the exoccipital void of any distinct paroccipital process, are also well seen. The subcircular foramen magnum (*f.m.*) is bordered by the large projecting semioval condyles (*oc.c.*), and, behind, the supraoccipital (*s.o.*) can be seen finishing the great doorway.

Part of another lower view in the larger young (fig. 8.) shows the foramen ovale (*V³.*), the channel for the facial nerve (VII.), the fenestræ—fenestra ovalis

and fenestra rotunda (*fs.o.*, *f.r.*)—in the auditory capsule, the outlet for the facial, glosso-pharyngeal, vagus, and hypoglossal nerves (VII., IX., X., XII.); a bristle shows the opening from the ear-drum into the labyrinth of air-cells in the squamosal (*sq.*).

The end view of the skull, younger specimen (Plate 37, fig. 7), shows the well-built occipital arch, with its elements distinct; the large foramen magnum, the outstanding condyles (*oc.c.*), and the mastoid process (*op.*) all well set in under and within the great investing plates.

There is a remarkable difference between the hyoid arch in the lesser and larger of these young Philippine specimens (Plate 38, figs. 6 and 8).

In the former (fig. 6) this part is not so well developed in some respects as in the embryo of the larger species, for the hypohyal *h.hy.* is not segmented off from the ceratohyal (*c.hy.*), whilst the latter region is not ossified, but the hypohyal region has an oval centre. The basal and thyrohyal regions have now each a small bony tract.

In the larger young (fig. 8.) these parts are much more advanced, and the hypohyal is segmented off from the ceratohyal; each of these is rapidly ossifying, and so are the basal piece and thyrohyals; but these are continuous in the cartilaginous interspaces.

Stage 4, D.—On the skull of the adult Galeopithecus philippensis.

This is one of the most remarkable skulls to be found in the whole of the Eutherian division of the Mammalia; it is, thus, like the skull of a Serpent—a low type, and yet specialized, in its own way, to the uttermost. Just now, I am only responsible for the skull; the structure of all the rest of its organization must be accounted for and argued about by others; but I must mention the size of its brain-cavity (Plate 39, fig. 3), as showing how small a brain this creature has. The proportion that the foramen magnum bears to the greatest intercranial breadth will serve my purpose, as I cannot go further into that matter. In the adult *Galeopithecus philippensis* and in the sub-adult *Cuscus maculatus*, that opening is two-fifths the greatest breadth of the skull inside; in *Lepilemur mustelinus* it is only one-third, and in *Loris gracilis*, and *Pteropus medius*, only one-fourth.

In the cranial characters that have been already described in the young specimens and embryo, I have shown that there are several things that are manifestly Metatherian, but these are not the same things as those that show a Marsupial affinity in the Hedgehog and its allies; they belong to another set of parts.

I have already spoken of the help the young of *Cuscus maculatus*—one of the lowest and most generalized of the Eastern Marsupials—has been to me in the study of the growing skull of the Colugo. I now find that with the adult skull of that species, and the adult skull of a great Frugivorous Bat (*Pteropus medius*) I have the two extremes, with the skull of *Galeopithecus* half-way between them. Not but that this bizarre type has its own unique characters; this might have been expected, for it

is left alone—at most with but one companion—the other species—and its proper Family must have suffered very largely from causes of extinction. This is one of the lightest and most highly polished of all skulls—quite Bird-like in this respect, and in the thorough fusion of all its cranial elements.

The impression that rises first is that it is a *foliaceous* skull (Plate 39, fig. 4), as unlike other more familiar skulls, as the Leaf Insect is unlike normal Orthoptera. The temporal and nasal regions are about equal, the orbital one-third shorter; this opens into the temporal, behind. The general convexity of the upper surface is made gently sinuous by the special convexities of the various bony elements of which it is composed; these have just been described, and will enable anyone to understand the finished and fused adult skull, in which, instead of sutures there are fine, and often clear, depressed lines. There is a supraorbital fossa on each side, as in aquatic Birds, as though it had a pair of nasal glands; these end sharply behind, and lead to a supra-orbital foramen, which is further forward than in *Pteropus* and its allies. Over the small hemispheres, as in Marsupials, the frontal region is flat, in front, and then rises gently; the whole brain cavity has its form revealed in this way by a definite convexity, the outworks being well marked off. The orbit has the posterior fifth incomplete, for the finely turned supraorbital ridge ends in a large uncinatè leaf of bone, the postorbital process and the jugal has a clean edge, growing up towards the postorbital process of the frontal; the lachrymal projects inward in the preorbital region, and forms about a fifth of the actual ridge of the orbit; its canal is small. In front of the lachrymal and jugal there is the small, but double, infraorbital foramen. The ridges on this skull serve the purposes both of beauty and of use; the hind edge of the postorbital process curves forwards and then, at its sides, over the swelling brain-cavity, becomes the supratemporal ridge, which converges towards its fellow, getting within a half of the front distance, as they meet on the top of the interparietal. There the temporal fossa rounds itself, and is enclosed by the transverse occipital edge (Plate 39, fig. 4). This large oval enclosure, half as long again as the orbital territory, has then below it a low oblique wall which is very strong behind, and runs down over the meatus externus; and, with two rounded elevations, one small and the other large, the sharp boundary line passes into the hinder edge of the ascending uncinatè postorbital process of the jugal bone. This outer boundary—orbital and temporal—is greatly bowed outwards in this depressed skull, in sharp contrast with the same parts in the neat narrow skull of *Pteropus*. Along the middle of the extensive temporal fossa, for the wide *origin* of the huge temporal muscle, the convexity of the wall of the skull cavity is clearly seen. The side view of the temporal region in this skull shows nothing new to the student of the higher Mammalia, but the form and condition of the parts is both Marsupial and also *unique*. Only the narrow outer end of the large transverse glenoid cavity is seen in this aspect of the skull, but the large postglenoid process, the notch for the deep tympanic trough, and the part of the squamosal overlying the mastoid process are best

seen in the side view. Then the post-temporal and mastoid regions are concave, turn obliquely, and are swollen and sinuous, with the great air-cells within, which are well-marked on the outside, every cell marking its own convexity. The supraoccipital ridges, vertical and transverse, can be seen in this view, and the large projecting occipital condyle.

The *end view* (Plate 39, fig. 4) shows the gently hollow sagittal region (*i.p.*); the outspread, foliaceous postorbitals (*p.o.*); the widely extended glenoidal part of the squamosals (*sq.*); the post-temporal region of the same bones, overlapping the mastoids (*op.*); the projections further forwards of the postglenoid ridges, and the free fore legs of the tympanic (*a.ty.*). The large foramen magnum is seen to be somewhat elliptical, with the long axis transverse; over it the supraoccipital forms a low arch, and on that bone, above, there is a keel, derived first from the interparietal; and from the top of the keel or crest a transverse ridge, right and left, enclosing the supraoccipital region.

The very large condyloid foramina (XII.) are well seen inside the foramen magnum, in front of the large subpedunculate condyles; then the occipital arch is constricted, and the paroccipital ridges are obsolete, but the mastoid grows inwards over that region, and forms a thin-edged floor to the passage for the 9th and 10th nerves. The general form of the great hard palate in the adult is oblongo-elliptical, and it is half the length of the whole basal tract. The anterior palatine foramina are large and oval, the posterior palatine foramina are moderate, far back, and far apart, lying in the fossa of the palatine plate of the palatines, close to the junction of these bones with the maxillaries.

The general surface of the hard palate is gently hollow, margined by the edentulous part of the narrow premaxillaries, in front, by the large sockets and teeth laterally, and by the exquisitely wrought, thickened and ribbed edge of the narrow palatines, behind. These plates grow backwards to receive the crest of the vomer, and then arching forwards, run round the posterior nares, curving in again to form a waist in the open part, and then ending in a sharp ridge, turned outwards, which ends in the small unciform external pterygoid process. Inside these alisphenoidal hooks there is a more delicate pair of hooks, the hamular processes of the pterygoids. The hinder edge of each pterygoid is notched above the hook, and then runs backwards and outwards in a sharp ridge, reaching the foramen ovale. The keel of the vomer ends between the pterygoids; then the skull is made carinate by the slender acicular *parasphenoid*, is then gently convex along the middle, and becomes subcarinate in front of the foramen magnum.

The transverse well-margined glenoid cavities, underlapped behind by the thick incurved postglenoid process, might belong to some stout Carnivore.

The neat foramen ovale lies between the glenoid facet and the cranial part of the pterygoid; behind and inside it is the ragged opening of the Eustachian tube, floored by the sharp, rough fore lip of the tympanic bone. The keeled bottom of the deep,

folded meatus externus wedges in between the postglenoid process and the mastoid; the latter is an oval, ear-shaped tract, subconcave below, with a limbate margin, and a narrower hole in its inner, proximal part; that hole is the stylomastoid foramen, and a small convexity in front of and outside it is due to the fusion, with the mastoid, of a small epihyal.

Behind and within the ear-shaped base of the mastoid process the smallish opening for the 9th and 10th nerves is seen. The opening for the 12th nerve, behind, and for the internal carotid arteries, further forwards, are very large indeed. Only half of the large strongly curved occipital condyles can be seen in the lower aspect of the skull.

A *section* of the skull of the adult (Plate 39, fig. 3) shows three convexities along the dorsal line: the first long, over the nasal labyrinth; the next somewhat shorter, over the front parietal region; and the third short, over the ear-capsules and hind brain. The great septum (*p.e.*) is ossified over all the proper ethmoidal territory and most of the proper septal; this latter is elongated in front by the partition of the snout (*s.n.*, *al.n.*), which hooks, downwards, in front. From it the recurrent or JACOBSON'S cartilage (*rc.c.*) proceeds, scarcely lessened in relative size since birth (Plate 39, fig. 1, *rc.c.*). The ridge of the perpendicular ethmoid (*p.e.*), behind and above, forms a very obtuse angle with its top in front, and a very acute angle with the axis of the skull, behind and below, thus the cribriform plate lies well down in front of the proper cranial cavity. The septum bulges downwards in the true olfactory region, and rises again where the perpendicular ethmoid passes into the presphenoid (*p.e.*, *p.s.*); inside that part the optic foramen (II.) and sphenoidal fissure (*V^{1,2}*) can just be seen. The nasals and frontals form the wall-plate of the great partition; below, the vomer (*v.*) has become fused with the palatine plates (*p.mx.*, *pa.*) dividing the nasal channels, below. Underneath, the right channel can just be seen, and further back the palato-pterygoid side wall (*pa.*, *pg.*), and the lip of the tympanic (*a.ty.*) under the Eustachian opening. The basis cranii (*b.s.*, *b.o.*) is thin and sinuous, thickest behind, where it dips and forms the free fore margin of the foramen magnum. But little *sellar* depression exists inside the foramen ovale (*V³*). Above, the frontal and parietal (*f.*, *p.*) form a thinner roof than in the young (Plate 38, fig. 7); there is a rudiment of the tentorium cerebelli growing from the inner face of the parietal, and from the fore edge of the auditory capsule. The arch of the anterior canal (*a.s.c.*) is well marked, the prootic bone is crested, roughly, above it; below, is the deep floccular recess (*fl.r.*), and below that the multiperforate meatus internus (VIII.), and the bridge over the facial nerve (VII.). The large openings for the 9th and 10th (IX., X.) and the 12th nerves (XII.) are also seen in this aspect. Above, the vertical and transverse ridges of the supraoccipital (*s.o.*) are seen projecting beyond the line of section, which was on the left of the middle.

In front of the auditory capsule the septa between the large air-cells shine through the inner table of the squamosal (*sq.*).

In the *front view* (Plate 39, fig. 5) the huge foremost coil of the middle turbinal

(*m.tb.*) is seen thrusting itself forward over the feeble inferior, and under the small nasal, turbinals (*i.tb.*, *n.tb.*); here the cartilaginous part of the partition has been removed, and the front of the bony part (*s.n.*) is towards the eye; it is hollow below where it has not ossified, and rests upon the grooved vomer (*v.*) in front of the palatine processes of the premaxillaries (*px.*). A vertical slice of the skull in the region of the meatus (Plate 39, fig. 6, *a.ty.*, *m.a.e.*), and through the glenoid cavity (*gl.c.*), shows the large air-cells of the squamosal (*sq.*) and their somewhat radiating arrangement.

In a part of the hind skull cut across horizontally (fig. 8) the air-cells of the squamosal and mastoid (*sq.op.*) are shown; where these two bony parts have coalesced behind, there the cells are very regular and their septa for some extent radially arranged. In this figure the parasphenoid (*pa.s.*), pterygoid (*pg.*), external pterygoid process (*e.pg.*), and glenoid cavity (*gl.c.*) are shown. The tympanic lip, under the Eustachian tube (*eu.*), is not injured, but the *dish itself* is largely cut away and the small tympanic cavity (*c.ty.*) exposed, inside and above which is the small melon-like cochlea (*chl.*) and the fenestræ (*fs.o.*, *fr.*), and also the opening for the 9th, 10th, and 12th nerves (IX., X., XII.); the latter are very large, but are only seen obliquely in front of the occipital condyle (*oc.c.*).

The lower jaw of this beast might belong to some generalized Herbivorous Ungulate; it is indeed almost a miniature of that of the *Hippopotamus*. To say nothing of its unique pectinated front teeth, the general shape is very remarkable, with its depressed mentum, oblong ramus, short uncinat coronoid process, transverse, sessile condyloid, and deep out-turned angular, process, the edge of which is thickened inwards; its whole shape is half a circle.

The malleus (Plate 39, fig. 7, *ml.*) has lost all its processus gracilis (*p.gr.*), except one or two sharp prickles; the manubrium (*mb.*) is strong, curved, dilated at its end, and sinuous outside. The incus (*i.*), like that of the Ruminants, has a heavy, solid body, with short processes (*s.c.i.*, *l.c.i.*); the stapes (*st.*) is somewhat inflated and hollow behind, and at its base oval; there is a minute interhyal bone in the tendon of the stapedius muscle (*i.hy.*, *st.m.*).

The hyoid bone (Plate 38, figs. 9 and 10) shows a hypohyal as large as the ceratohyal (*h.hy.*, *c.hy.*). The basal bar (*b.h.br.*) is concave in front, and has a right and left tubercle behind; the thyrohyals (*t.hy.*) are large, uncinat, and separate, as bony tracts, from the base; all these bones are flat and splintery.

On the skull of the adult Tupaia Javanica.

This is another very isolated form of the Insectivora; I can only mention here certain peculiarities of the structure to be seen in the adult skull, hoping at some future time to be able to describe its development.

The *Tupaia* is another instance to be added to *Rhynchocyon* and *Galeopithecus*, in which a clear prophecy of higher signs of development is combined with characters

most unmistakably Marsupial; the sudden ascent, so to speak, above the general level in these types has been partial, and combined with a failure to free themselves from low and archaic characters derived from an ancestry belonging to an inferior grade.

As to the relative size of the brain this is evidently one of the highest of the Insectivora; it may be said in this to approximate at once to the Lemurs and the lower Carnivora. To the Lemurs it is comparable also in possessing a large and well developed orbital ring, rare in low forms, keeping its own special character in having a huge oval fenestra in the jugal arch, where the squamosal overlaps the jugal bone.

The hard palate is less complete than in *Galeopithecus*, but more perfect than is normal for an Insectivore. The external pterygoid approaches that of the adult *Petrodromus*, where there is a large oblique lamina of bone outside the proper pterygoid. But in the embryo of the closely allied *Rhynchocyon*, at this part there is manifestly a shell-like tympanic wing to the alisphenoid, as in Marsupials. Here in *Tupaia* there is a hole through the root of the external pterygoid process; this is evidently the counterpart of the alisphenoidal canal of certain Insectivora, Carnivora, &c.; in *size*, that process equals what we have in Marsupials. The supra-orbital foramen is very large, and is further forwards than in *Galeopithecus*; in *Pteropus* it is still further back.

But the annulus tympanicus and os bullæ are not only well developed, they are also the almost perfect counterparts of what we find in the lesser Australian Marsupials, especially *Petaurus sciureus*; the greater degree of ankylosis, which has completely fused these two elements of the ear-drum, is the only difference I can find in the two types. The lower jaw is a good intermedium between that of a Marsupial and that of a normal Eutherian.

SUMMARY AND CONCLUSION.

Although this paper is confessedly only a fraction of what is necessary to be done in this polymorphic Order, it at least shows how difficult a group it is to handle.

For the Insectivora are set in the midst of the other Mammalia—low and high; they might be called the Biological stepping-stones from the Metatheria to the Eutheria.

One thing can be done, even now, with the present fragmentary knowledge of the structure and development of the Insectivorous types—we can assure ourselves that these types are immediately above the Marsupials; that they have the Bats (Chiroptera) obliquely above them; that their nearest relations must be sought for amongst extinct Eocene forms; and that lowly as they are—arrested and often dwarfed to the uttermost, so that Nature could not safely go further in that direction,

they are, one and all, rich in prophetic characters that have come to perfection in larger and nobler types.

I think it will not be denied that, in the ascent of the types, the Chiroptera are above the Insectivora, and as it were a sort of special "new leader" from that stock, and that the Insectivora are more or less transformed modifications of what is characteristic of the Marsupials.

I suspect that the existing Insectivores just yield the Zoologist one of his groups of types classed together because he knows not what else to do with them; not forming a proper, clear, special branch, or "leader" of the Mammalian life-tree. They form one group, under one designation, just as the poor of this Metropolis form a group; their brand is simply lowliness; they differ, *inter se*, almost as much as the whole remainder above them differ. The higher forms, however, because of their elevation can afford to be subdivided again and again, into Order after Order.

If we could descend and see the transforming and newly-transformed Placentalia of the Eocene epoch, then the Morphologist and the Zoologist would find common ground; the Taxonomy of the latter, however, would be as useless as the titles and distinctions of modern society to some undeveloped race of savage men.

The evidently extreme specialization of the existing Monotremes or Prototheria, and their manifest close relationship to the Edentates—a strange, lowly group of Eutherians, almost extinct in the Old World, and not potent in genera and species in the New—makes it necessary for me, in the present stage of my research, to leave them until I have mastered both them and the great Marsupial sub-class. Of the latter, however, I can speak already; and as no interpretation of the meaning of the parts seen in a Eutherian skull can be made until they are read in the light of the structure of the *quasi-reptilian* skull of a Marsupial, I shall in this summary compare the two types together, using the lower and older as a measure of the higher and newer type of skull.

Anatomists are familiar with the characters of the skull in adult Marsupials; to these may be added others that have turned up to me in the study of the development of that type. When these are seen in the light of the types outside and below the Mammalia, then that which is typical in a high Mammal, as such, can be formulated, and the specialization of this great branch of the Vertebrate stock be understood.

I will therefore, here, give a list of the more important and striking cranial characters of the Marsupials, promising to bring forward, as early as possible, the figures and descriptions of the skull in various stages and in many kinds.

But before making this comparison of the characters of the skull in the Marsupials with what is seen in the Insectivora, I will state that in the latter—a mere "Order"—the diversity is four-fold that to be found in the Marsupials, which are worthy to be put, not as a mere Order, but as a "Sub-Class."

For in these, whether they be Eastern or Western types, the uniformity on the whole is very remarkable—as remarkable as the diversity seen in the Insectivora.

The problem put to the Morphologist, however, is to explain why the characters that distinguish a Marsupial from a high or Eutherian Mammal are, for the most part, characters which the former possess in common with the Sauropsida: the residuum of proper, unique Metatherian characters, neither to be found in the higher Mammals on one hand, or in the Sauropsida on the other, is but small.

Another crucial difficulty is this, namely, the Sauropsida, which of all others help us most in the interpretation of the Marsupial skull, are not those to be found in low Reptilian, but in the highest Avian, types.

Of all Birds the Passerinæ are the noblest and most marvellously specialized for their own peculiar mode of life, having many accomplishments and high intelligence.

Yet it is from this Order of Birds that I have had most help in this matter, finding in their skull special structures which closely correspond with what is most remarkable in that of the Marsupials.

There are several characters in the *superficial* or *investing* elements of the skull of Marsupials that are unlike what we find in the highest forms of placental Mammalia, but which linger in the lower:—

(a.) The frontals are very small in proportion to the parietals, and the squamosals are relatively, especially in the young, inordinately large, as large as the frontals.

(b.) The lachrymals are not only large and have generally a facial plate, but they have, as a rule, *two* canals.

(c.) The palatine plates of the maxillaries and palatine bones form an extremely hollow or dome-like structure, and by the time the creature is full-grown much of their substance has been absorbed, so as to leave larger or smaller fenestræ; thus there is an attempt to return to the schizognathous condition of those parts seen in many Sauropsida.

(d.) The palatines are often formed of several pieces, very irregular patches of bone, and their irregular centres are largely absorbed or united with the main parts in the adult.

(e.) The pterygoids are very small, and their basicranial part limited, on account of the constant separate development of a large mesopterygoid.

(f.) The main vomer is often relatively small; there is, nearly always, a pair of antero-lateral vomers, protecting the cartilaginous capsule of JACOBSON'S organs, and large postero-lateral, and other, or postero-medial vomers; these are very irregular and unsymmetrical in the young *Cuscus*, especially, in which I find *ten* vomerine bones.

(g.) The floor of the tympanic cavity ossifies before the cartilage is ripe, but in two subequal centres—the annulus and “os bullæ”—inside the latter a larger folded cartilage protects the Eustachian tube, and outside the former the *meatus externus* is protected by a more or less segmented tube of cartilage, which ends outside in the continuous *concha auris*.

(h.) The jugal (or malar) bone is large, and reaches back so as to lie over the cartilage of the glenoid cavity, thus helping to form the joint.

(i.) The angular part of the lower jaw is greatly incurved, forming a remarkable hollow inside.

In the *endocranium* there are some very curious structures, that differ from what we find in the high forms of Mammalia, but which mostly agree with what is seen in the Sauropsida :—

(a.) The nostrils are sub-terminal and give off large tongue-shaped cartilages to protect JACOBSON'S organs.

(b.) The whole nasal labyrinth is small, especially in the young, not more than half as large as in an average Placental Mammal, and the cribriform plate is less depressed in front, and very limited in size, and is square in form.

(c.) The orbitosphenoids do not form the presphenoid by meeting together below, but the presphenoid is as independent as the basisphenoid.

(d.) There is no special optic foramen in the orbitosphenoid, but the optic nerve passes through the common sphenoidal fissure with the orbital nerves, and the 1st branch of the 5th; the 2nd branch, like the 3rd, has its own foramen rotundum, as in Man, and many other Eutheria.

(e.) The next character is one of the most important: it is this, namely, that the orbitosphenoids are flush with the alisphenoids. The latter, which are extremely large, ossify a tract of the general cartilaginous side-wall of the embryonic skull—the highly developed “chondrocranium,”—and *not a free flap* of cartilage, merely continuous with the basal bar, as in the Eutheria. For in these latter the more bulky brain pushes out the lower part of the side-wall of the skull, leaving for some time a band of cartilage, which runs free from the alisphenoid, passing on from the orbitosphenoid up to the supraoccipital. In front, the orbitosphenoid is confluent with the ethmoid, so that but for the breach in the wall, made by the alisphenoid, there would be, even in Placental Mammals, a chondrocranium very similar to that of the skull. This breach does not take place anywhere among the Vertebrate types until we get above the Marsupials. The other character just mentioned, namely, the absence of a special optic foramen, is of similar import; there never is such a foramen until we are among the Placental Mammalia.

(f.) The alisphenoid helps to form the drum-cavity by developing behind its small external pterygoid process a shell-like growth, similar to the “anterior tympanic recess” of Carinate Birds. Thus, as the squamosal is a labyrinth of air-cavities, opening into the upper part of the drum-cavity, these and the tympanic recess in the alisphenoid greatly enlarge the space for air. Indeed, not only those parts, but the mastoid region of the auditory capsule, and the sides and top of the occipital arch, all became pneumatic—as in *Crocodiles and Birds*.

(g.) The internal carotid arteries pierce the basisphenoid submesially—that part of the basis cranii is not perforated in the Eutheria,—and the clinoid processes and the concavity for the pituitary body are but little developed.

(h.) The limited, suberect, and flattish cribriform plates, and the small frontals are the necessary correlates of a small brain-cavity and brain. The *occipital plane* corresponds with those parts, being suberect: it forms but little more than a right angle with the general basicranial axis.

(i.) In the Marsupials, as well as in the Monotremes, we see the “ossicula auditûs” *in making*, so to speak. In all the three subdivisions of this class—Monotremes or Prototheria, Marsupials or Metatheria, and Placentals or Eutheria—the lower jaw is broken up, the larger front part becoming the persistent mandible, and the shorter hind part the *malleus*, whilst the starved and modified quadrate becomes the *incus*.

For a long while in the growing Marsupial the malleus is manifestly a compound bone; it is an “articulare” with an internal and a posterior angular process, as in the Fowl. On it the “angulare” can be seen, and sometimes, as in the half-grown Koala (*Phascolarctos*), a “supra-angular” too.

The working mandible attached to a new pier on the jugal and squamosal is composed of a sort of morphological mixture of a large *inferior labial cartilage*, a dentary bone, with coronoid and splenial *regions*, and the greater part of MECKEL’s cartilage—the *true primary ramus*.

(j.) The topmost segment of the next arch (pharyngohyal) is often a “columella,” and not a *stapes*. In the early young and embryo of the Marsupials it is V-shaped, its greater front fork enlarging above and forming the inverted base of the columella or stapes, and the lesser hind fork becoming, after a time, detached and then ossified, and forming the interhyal.

In Fishes, the uppermost element of a branchial arch (and the hyoid is a branchial arch) often forks; in the Sturgeon these become two separate pieces, as in this particular case of the embryo Marsupial. There is not much to remark upon in the rest of the hyoid arch, the functional suspensory part.

For comparison with the Insectivora the *existing Marsupials* do not yield me all the archaic characters I want.

For the existing low Eutheria are, of course, the descendants of Metatheria that were much more generalized and archaic than any now existing; these latter, during the whole Tertiary period, must have undergone, on their own low platform, many adaptive changes that would make them look very strange beside the Marsupials of the Secondary epoch, if these latter could be restored for comparison.

The best type of Insectivore for general comparison is the Hedgehog (*Erinaceus europæus*), as it shows the least suppression of parts, and the best development of that which is diagnostic, so to speak, of the Order.

In it the greater investing bones of the skull are similar to those of the Marsupial, but the nasals and squamosals are smaller, and the frontals are larger. In the hard palate there is a considerable relapse, as in Marsupials, certain tracts of bone being absorbed, but it has no mesopterygoids, and only *five* vomers; yet the antero-lateral pairs are well developed.

Moreover the tympanic region has only one "annulus," the outer bone. There is no separate "os bullæ." Instead of the latter there is a crescentic shell of bone which grows from the basisphenoid, greatly increasing the size of the tympanic cavity. In the endoskeleton, in front of the tympanic cavity, there is a remarkable ridge of bone growing outwards from the alisphenoid. That ridge is the remnant of the alisphenoidal tympanic wing of the Marsupial, and a shell of bone growing from the basisphenoid is the same morphological element as the separate "os bullæ," but it has lost its independence. The higher Mammalian type is fully reached in the thorough freedom of the alisphenoid from the general cranial wall. This character, indeed, is intensified into the special diagnostic of an Insectivore, for it lies almost wholly outside the orbitosphenoid. Here the sphenoidal fissure—which in this case lets out the 1st and 2nd branches of the 5th, but not the optic, nerve, that nerve having its own foramen in the orbitosphenoid,—is not a mere gap, but a *side passage*, a sort of sphenoidal corridor, right and left.

In these things the Hedgehog is higher than the Marsupials, but in some others it is lower, or more archaic. These latter characters, which suggest an uprise from a more generalized type than the existing Metatheria, are—*first*, the development of a considerable rod of solid hyaline cartilage in the pterygoid region, a remnant of the pterygo-quadrato of the Ichthyopsida; and *secondly*, the presence of a persistent pituitary hole, which is connected with a curiously specialized structure, only seen in typical Insectivores, namely, a hollowing out of the basis cranii beneath the pituitary region.

A *third* archaic character, not seen in the existing Marsupials, is the huge relative size, long persistence, and separate distal ossification of MECKEL'S cartilage, so that in the embryo Hedgehog, and even in the Nestling, the *primary lower jaw* is as large as in Fishes, generally, scarcely excepting the Selachians.

The ossicula auditûs are typically Eutherian; we have lost the imperforate stapes or columella, the interhyal is very small or absent, and the malleus and incus are much like what we find in the higher Mammals generally. The pneumaticity of the skull is much reduced; and the olfactory region is almost double the relative size of that of a Marsupial. In the head of another family of the Insectivores, namely, the Mole (*Talpa europæa*), there is much that is in accord with what is found in its distant relation, the Hedgehog, but in it there are evident signs of degradation, or of relapse into what is Marsupial in character.

The nasal labyrinth is relatively immense, and the skull walls below, laterally, and behind, are as exquisitely pneumatic as in the Flying Marsupial (*Petaurus*), the Bird, or the Crocodile. The swollen basis cranii, all air galleries within, is so excavated that the hinder sphenoid, both base and wings, largely helps the flat single tympanic to form the drum-cavity.

The pituitary hole does not exist, but there is a considerable pterygoid cartilage; the ossicula, *in the adult*, are normal, but a curious special character is seen during ossification. In the young the bone grows along the sheath of the stapedia artery,

which for a time holds the stapes in its place ; it is, however, absorbed afterwards, but remains in the related genus *Myogale*. In nearly half-grown young Moles the malleus is quite like that of the Marsupials, and it is an evident articulare, with copious wild growths of bone, sub-distinct and answering to the "angular" and "supra-angular" of a Reptile or Bird. This malleus in its articular part has two endosteal and one ectosteal bony centres. MECKEL's cartilage, long continuous with the malleus, is nearly as massive as in the Hedgehog, and has a more distinct separate ossification in its subdistal part—a long independent, but temporary *hypobranchial bone*.

The Mole shows a most remarkable development of the endocranium, which, twenty years ago, suggested to me that its skull retained unmistakable Monotrematous characters. In the large young of the *Echidna* and *Ornithorhynchus* the solidity of the chondrocranium is immense—like that of a *Chimæroid* Selachian—and the investing bones are thin and splintery. I have not made out the mode of ossification of the inner skull in those types, but *in spirit*, if not *in the letter* the Mole agrees with them, that is in the great development and independence of the inner skull. The "opisthotic" bones ossify the normal petromastoid region, whilst the "prootic" bony centre begins in its right place on the front edge of the cartilaginous capsule and then runs away from it into the wall of the skull ; thus there is a large bony tract in the temporal region, between the *small* squamosal and the large interparietal, which is not one of the ordinary outer cranial bones, but an endocranial bony tract, overshadowing and yet imitating the true temporal bone or squamosal. This bone is represented by *three* separate centres in Osseous Fishes, namely, the prootic, pterotic, and sphenotic, whilst their true auditory region is ossified by the epiotic and opisthotic ; the epiotic is only subdistinct in the Mole.

If I am asked why I dive so far down for my illustrations instead of being satisfied with what Reptiles and Birds would show me, my answer is that those are often of no use for comparison, for they are as thoroughly specialized for their own mode of life as the Mammalia, generally, and are as completely, and often more completely, transformed from the original archaic type or types.

Thus the Mole, like most of the Edentata lately described by me, suggests as the root-stock of the Eutheria, generally, not Marsupials (Metatheria) as we know them, but Prototherian forms, in which, in ages long past, the existing Monotremes and Marsupials had a common origin.

The Shrew (*Sorex vulgaris*) represents another family of the Insectivores, the Soricidæ. It combines the characters of the Mole and Hedgehog with peculiarities of its own that are manifestly due to dwarfing ; many things are suppressed, as if there was not room in so small a skull for their development. The pituitary hole re-appears, and the pterygoid cartilage—but the tympanic wing of the alisphenoid and of the basisphenoid are gone ; the malleus does not show itself so unmistakably Marsupial, and MECKEL's cartilage is slenderer. The sheathing alisphenoids are well seen ; the squamosal is small, low down, and devoid of a jugal process ; the jugal bone is suppressed.

So much for the British representatives of three families of the Insectivora—the Erinaceidæ, Talpidæ, and Soricidæ.

The Mascarene Insectivora are all so evidently related as to suggest at once a common origin; these are the Centetidæ, the largest of which is the Tenrec (*Centetes ecaudatus*); the other genera treated of in this paper are *Ericulus*, *Hemicentetes*, and *Microgale*.

These are almost typical Insectivora, but they agree with the Shrews in having the jugal bone suppressed; they are also more Marsupial than our native kinds.

In these types the normal characters of the skull of an Insectivore are combined with a remarkably Marsupial tympanic wing to the alisphenoid, but the os bullæ is not free, it is merely an outgrowth of bone from the basisphenoid. The pituitary hole is present, and in the larger species the curious basicranial excavation; also the optic foramina; whilst the sphenoidal side passages are remarkably developed.

As in the genus *Phalangista* among the Marsupials, and *Talpa* and *Sorex* among the British Insectivora, the antero-lateral vomers are evidently suppressed, or have a very temporary independent existence. The postero-lateral vomers are rather small, as in the Hedgehog.

In the embryo the main vomer is *relatively* as large as in the embryo Whale, and is curiously cellular or spongy.

In Nestlings this one primary azygous centre has broken up into three; one, the largest, above, and two lesser, below, sheathing it, as it sheathes the base of the nasal septum. Now this multiplication of the vomers, proper, is thoroughly Marsupial; it is unique, as far as I know, in the mode of its subdivision into secondary bony centres.

In the African (Continental) Family of the Elephant, or Jumping, Shrews (Mascrosce-lidæ), as illustrated by the largest forms—*Petrodromus* and *Rhynchocyon*—we have a curious mixture of Marsupial (Metatherian) and Eutherian characters, so that they are very aberrant as Insectivores.

The Marsupial characters are most remarkable, these are: 1, the absence of an optic foramen; 2, the alisphenoid, scarcely overlapping the orbitosphenoid; 3, tympanic wings to the alisphenoid, well marked hollow shells in the embryo; 4, large antero-lateral vomers and postero-lateral vomers as large as in average Marsupials, and, as in many of them, meeting and uniting at the mid-line; 5, a large, distinct "os bullæ," which makes a tympanic cavity as large as, and much like that of, *Petaurus* or *Phascolarctos*.

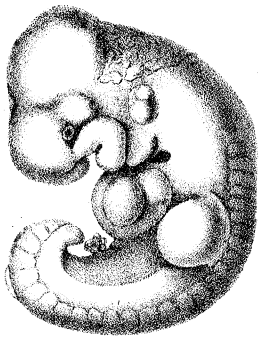
On the high Eutherian side we have, in the embryo, frontals as large as the parietals, and, strangest of all anticipations of Mammalian specialization, a *long proboscis*, composed of thirty double rings of cartilage, a structure quite similar to the proboscis of an Elephant. The mesopterygoids are suppressed, but the pituitary hole is present.

Galeopithecus and *Tupaia* are manifestly annectent. I shall treat of them, again, when I come to the Bats and Lemurs.

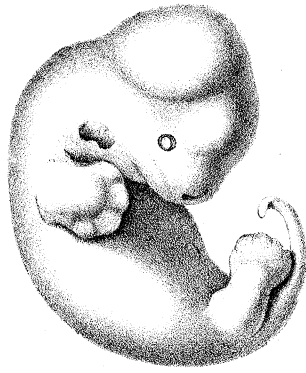
PLATE 16.

Figures.		Number of times magnified or reduced.
1	<i>Talpa europæa</i> (1st stage); embryo, $\frac{1}{4}$ inch long; side view	9
2	<i>Talpa europæa</i> (2nd stage); embryo, $\frac{1}{3}$ inch long; side view	$7\frac{1}{2}$
3	The same; front view	$7\frac{1}{2}$
4	The same; lower view of head	$7\frac{1}{2}$
5	<i>Talpa europæa</i> (3th stage); $\frac{2}{3}$ inch long	$3\frac{1}{3}$
6	<i>Talpa europæa</i> (5th stage); embryo $1\frac{1}{4}$ inch long; front view of upper part	$1\frac{1}{2}$
7	The same; side view of upper part	$1\frac{1}{2}$
8	<i>Erinaceus europæus</i> (1st stage); embryo, $1\frac{1}{4}$ inch long; side view	2
9	The same; front view	2
10	<i>Sorex vulgaris</i> (1st stage); embryo, $\frac{3}{4}$ inch long nearly; side view	$3\frac{3}{4}$
11	The same; front view	$3\frac{3}{4}$
12	<i>Sorex vulgaris</i> (3rd stage); nestling, 10 or 12 days old .	2
13	<i>Centetes ecaudatus</i> (1st stage); embryo, $\frac{7}{12}$ inch long . .	$5\frac{1}{4}$
14	<i>Centetes ecaudatus</i> (2nd stage); embryo, $1\frac{1}{12}$ inch long .	$1\frac{1}{2}$
15	<i>Galeopithecus volans</i> (1st stage); embryo nearly ripe . .	$\frac{2}{3}$ nat. size.
15A	The same; side view of head	$\frac{2}{3}$ do.
16	<i>Rhynchocyon cernei</i> ; embryo, ripe, or nearly ripe . . .	$\frac{3}{4}$ do.


1 x 9



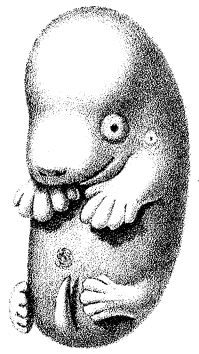
2 x 7½



3 x 7½



5 x 3½



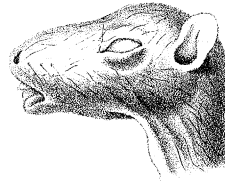
6 x 1½



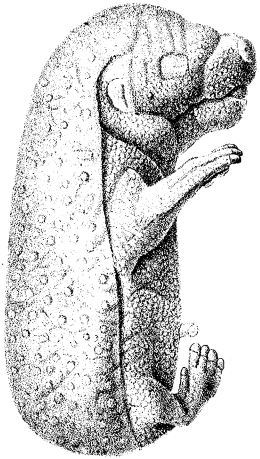7 x 1½



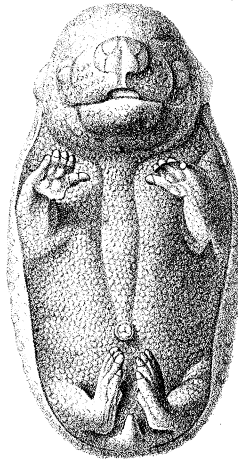
15^a ⅔ n.s.



8 x 2



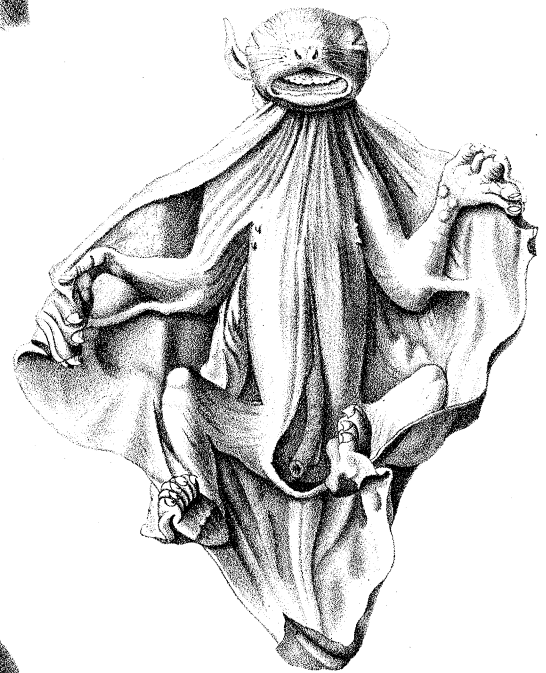9 x 2




4 x 7½



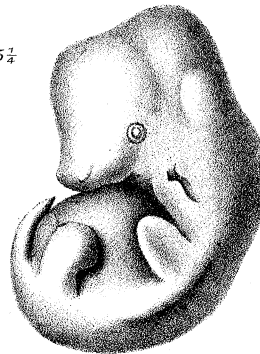
15 ⅔ n.s.




12 x 2



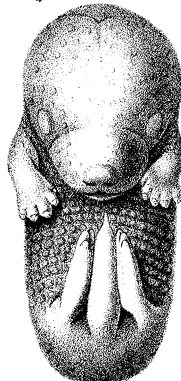
13 x 5¼



10 x 3¼



11 x 3¼



14 x 1½



16 ¾ n.s.

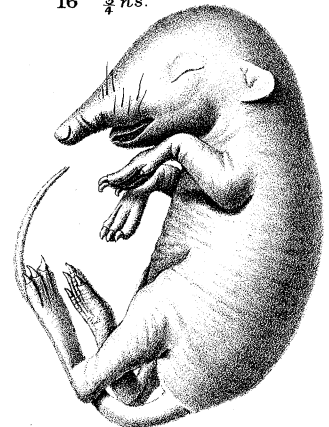
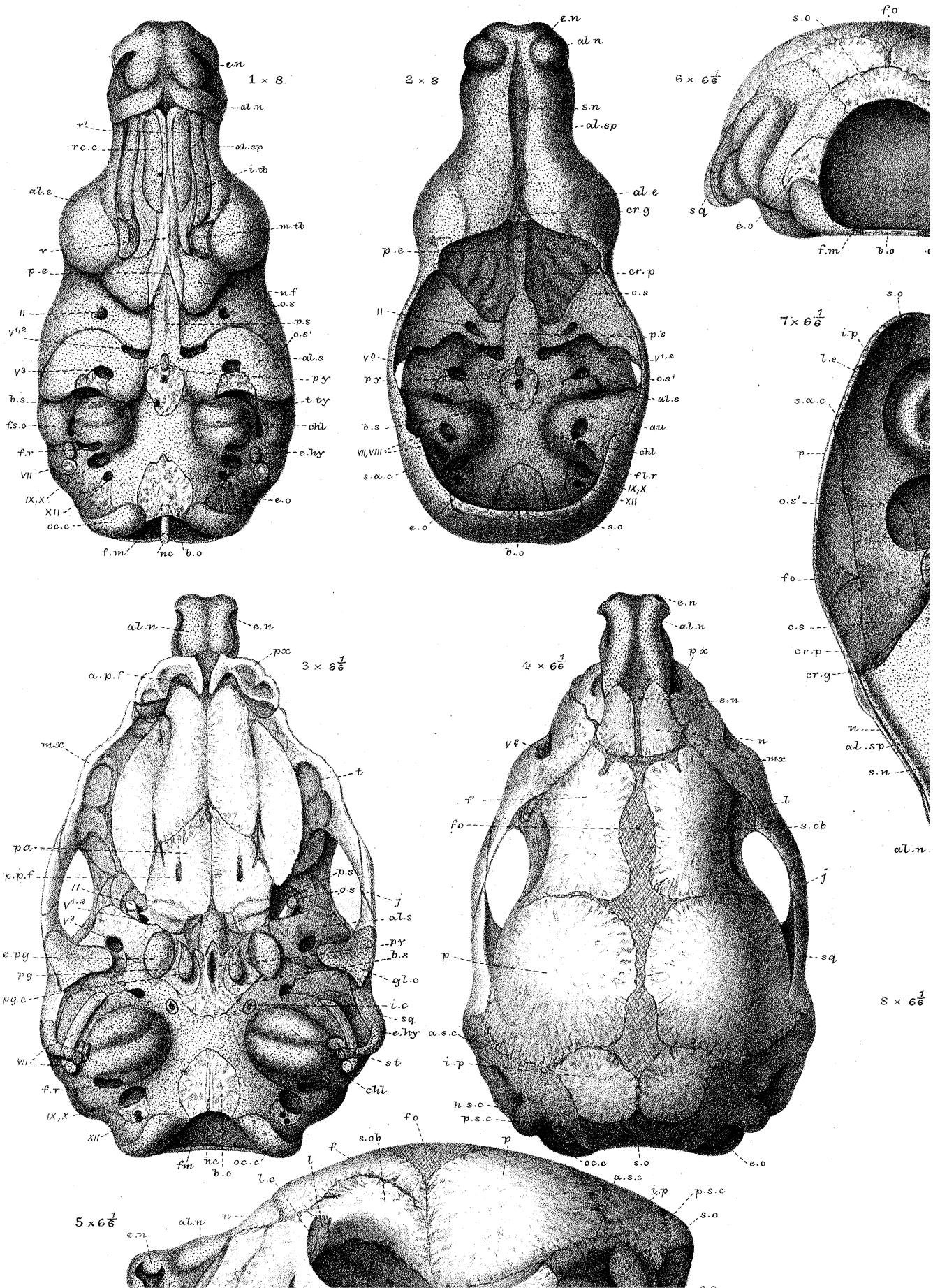
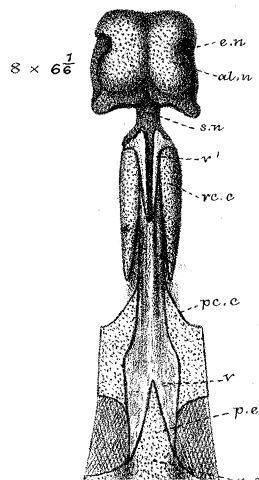
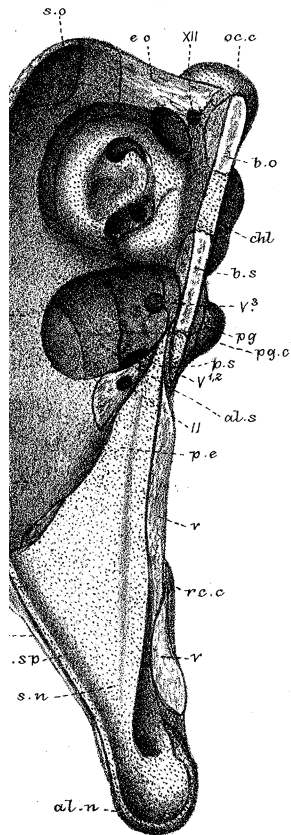
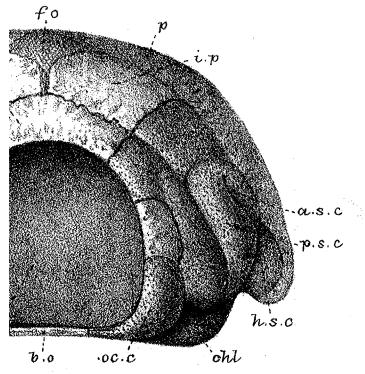
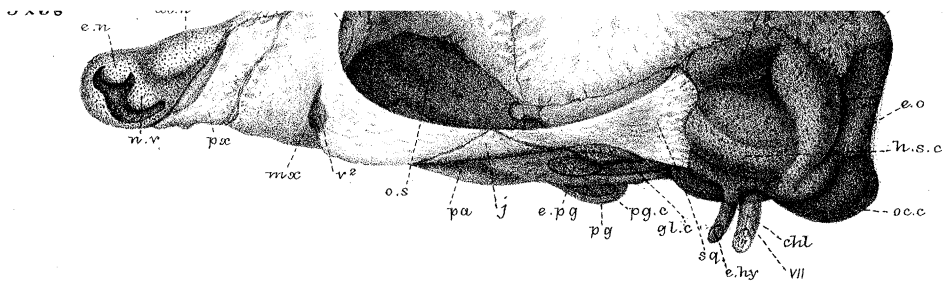


PLATE 17.

Figures.		Number of times magnified.
1	<i>Erinaceus europæus</i> (1st stage); embryo, $1\frac{1}{4}$ inch long; endocranium; lower view	8
2	The same; upper view	8
3	<i>Erinaceus europæus</i> (2nd stage); ripe young, $2\frac{1}{4}$ inches long; dissected skull; lower view	$6\frac{1}{6}$
4	The same; upper view	$6\frac{1}{6}$
5	The same; side view	$6\frac{1}{6}$
6	The same; end view	$6\frac{1}{6}$
7	The same; section	$6\frac{1}{6}$
8	The same; part of basal view, with hard palate removed	$6\frac{1}{6}$

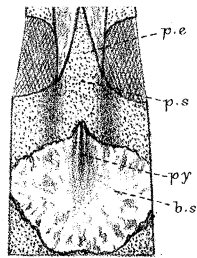






W.K.P. del. ed. nat.
Parker & Coward lith.

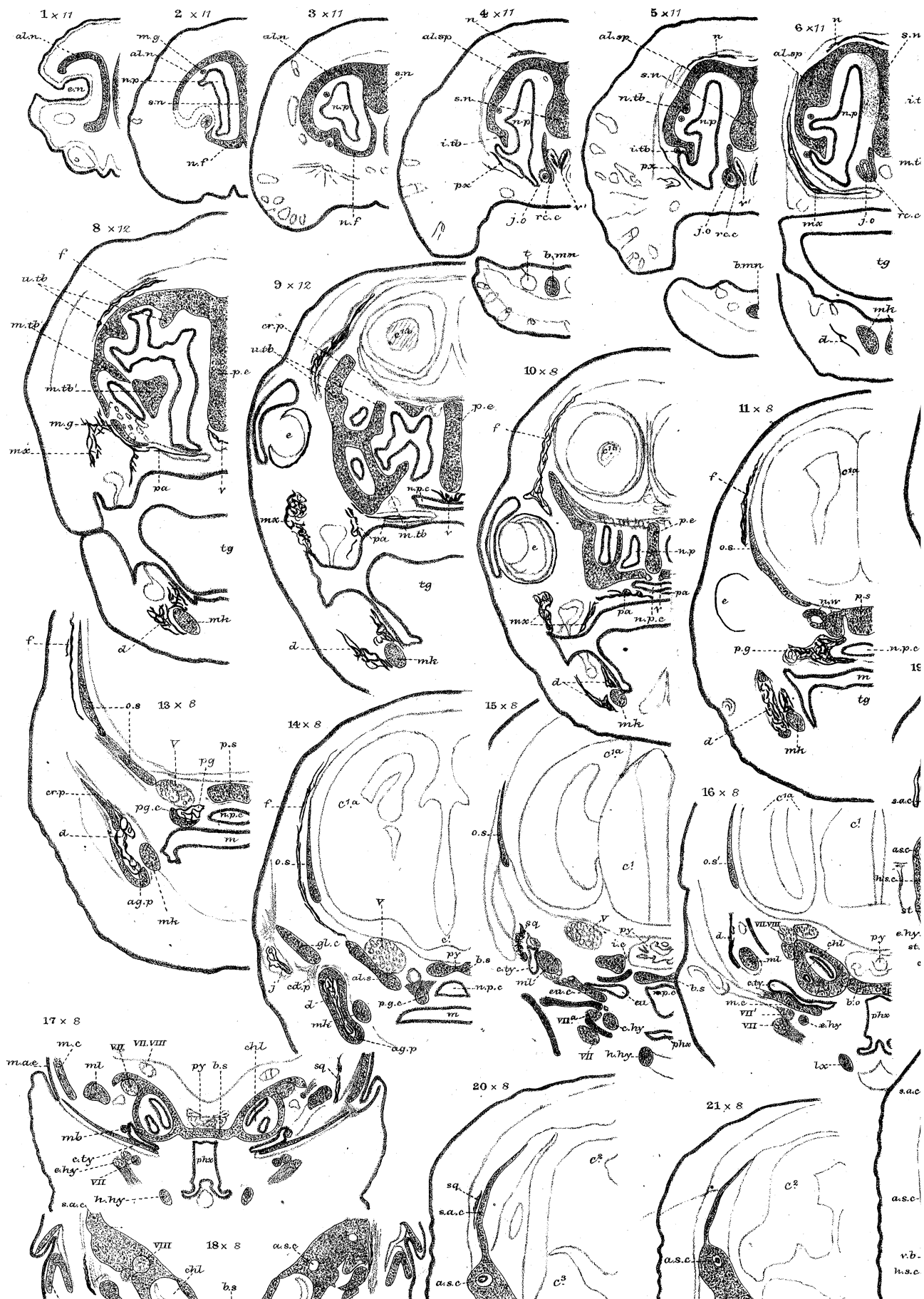
Erinaceus.

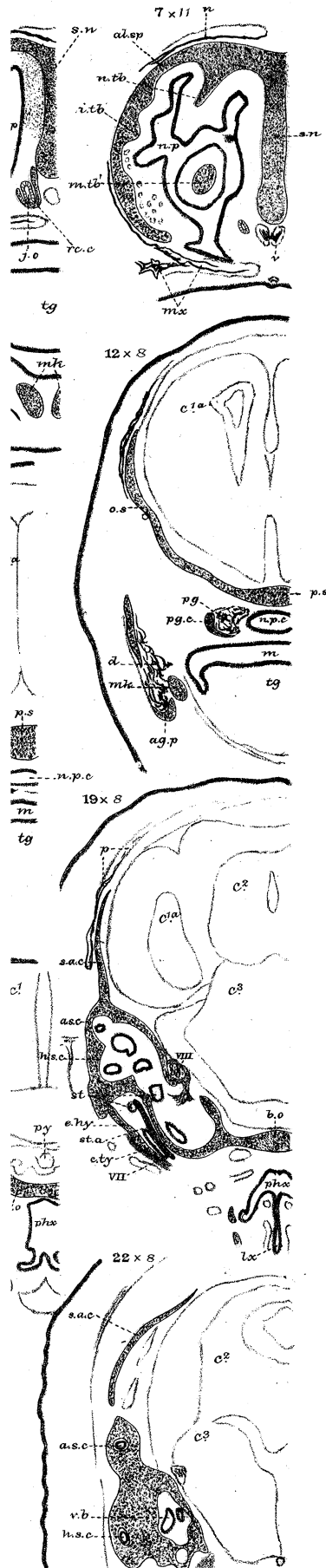


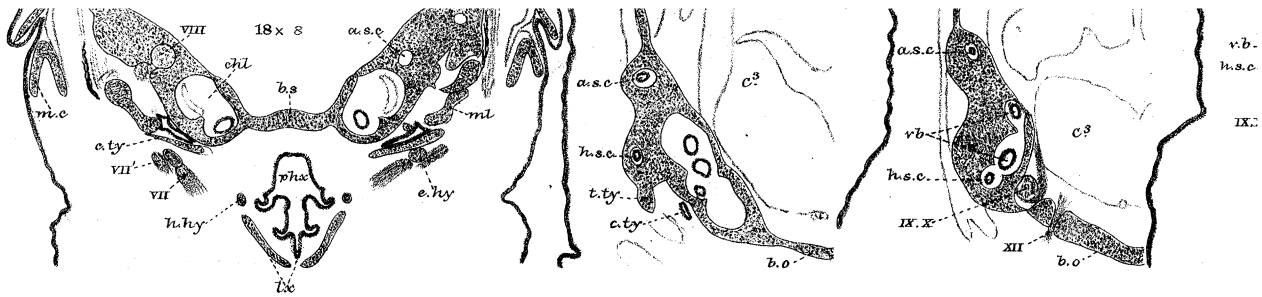
West, Newman & Co. imp.

PLATE 18.

Figures.		Number of times magnified.
1	<i>Erinaceus europæus</i> (1st stage); embryo, $1\frac{1}{4}$ inch long; 1st of a series of vertically-transverse sections	11
2	The same; 2nd section	11
3	The same; 3rd section	11
4	The same; 4th section	11
5	The same; 5th section	11
6	The same; 6th section	11
7	The same; 7th section	12
8	The same; 8th section	12
9	The same; 9th section	12
10	The same; 10th section	8
11	The same; 11th section	8
12	The same; 12th section	8
13	The same; 13th section	8
14	The same; 14th section	8
15	The same; 15th section	8
16	The same; 16th section	8
17	The same; 17th section	8
18	The same; 18th section	8
19	The same; 19th section	8
20	The same; 20th section	8
21	The same; 21st section	8
22	The same; 22nd section	8

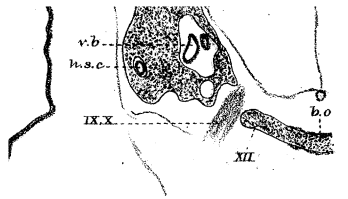






Parker & Coward del. et lith.
W.K.P. dir.

Erinaceus.



West Newman & Co imp.

PLATE 19.

Figures.		Number of times magnified.
1	<i>Erinaceus europæus</i> (3rd stage); new-born young, $2\frac{1}{3}$ inches long; endocranium; lower view	5
2	The same; upper view	5
3	<i>Erinaceus europæus</i> (4th stage); suckling, 2 weeks old; 3 inches long; endocranium; lower view	4
4	The same; upper view	4
5	The same; part of endocranium; upper view	4
6	<i>Erinaceus europæus</i> (5th stage); 1 month old; head, $1\frac{1}{2}$ inch long; dissected skull; end view	3
7	The same; part of endocranium, with some splints retained; lower view	3
8	The same; section of skull	3
9	The same; part of skull; outer view of auditory region .	3




PLATE 20.

Figures.		Number of times magnified.
1	<i>Erinaceus europæus</i> (5th stage, continued); skull; lower view	3
2	The same; upper view	3
3	The same; side view	3
4	<i>Erinaceus europæus</i> (6th stage); young, $\frac{2}{3}$ grown; section of skull	$2\frac{2}{3}$
5	The same (part); with septum removed	$2\frac{2}{3}$
6	<i>Erinaceus europæus</i> (8th stage); sub-adult; posterior sphenoid; upper view	$2\frac{1}{2}$
7	The same; lower view	$2\frac{1}{2}$
8	The same; end view, behind	$2\frac{1}{2}$
9	The same; inferior (maxillary) turbinals; front view . .	$2\frac{1}{2}$
10	The same; internal view	$2\frac{1}{2}$

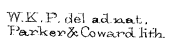


PLATE 21.

Figures.		Number of times magnified.
1	<i>Erinaceus europæus</i> (8th stage, continued); sub-adult; skull; lower view.	$1\frac{2}{3}$
2	The same; upper view	$1\frac{2}{3}$
3	The same; side view	$1\frac{2}{3}$
4	The same; end view	$1\frac{2}{3}$
5	The same; lower jaw; outer view	$1\frac{2}{3}$
6	The same; inner view	$1\frac{2}{3}$
7	The same; nasal labyrinth; upper view	$2\frac{1}{2}$
8	The same; lower view	$2\frac{1}{2}$
9	The same; side view	$2\frac{1}{2}$

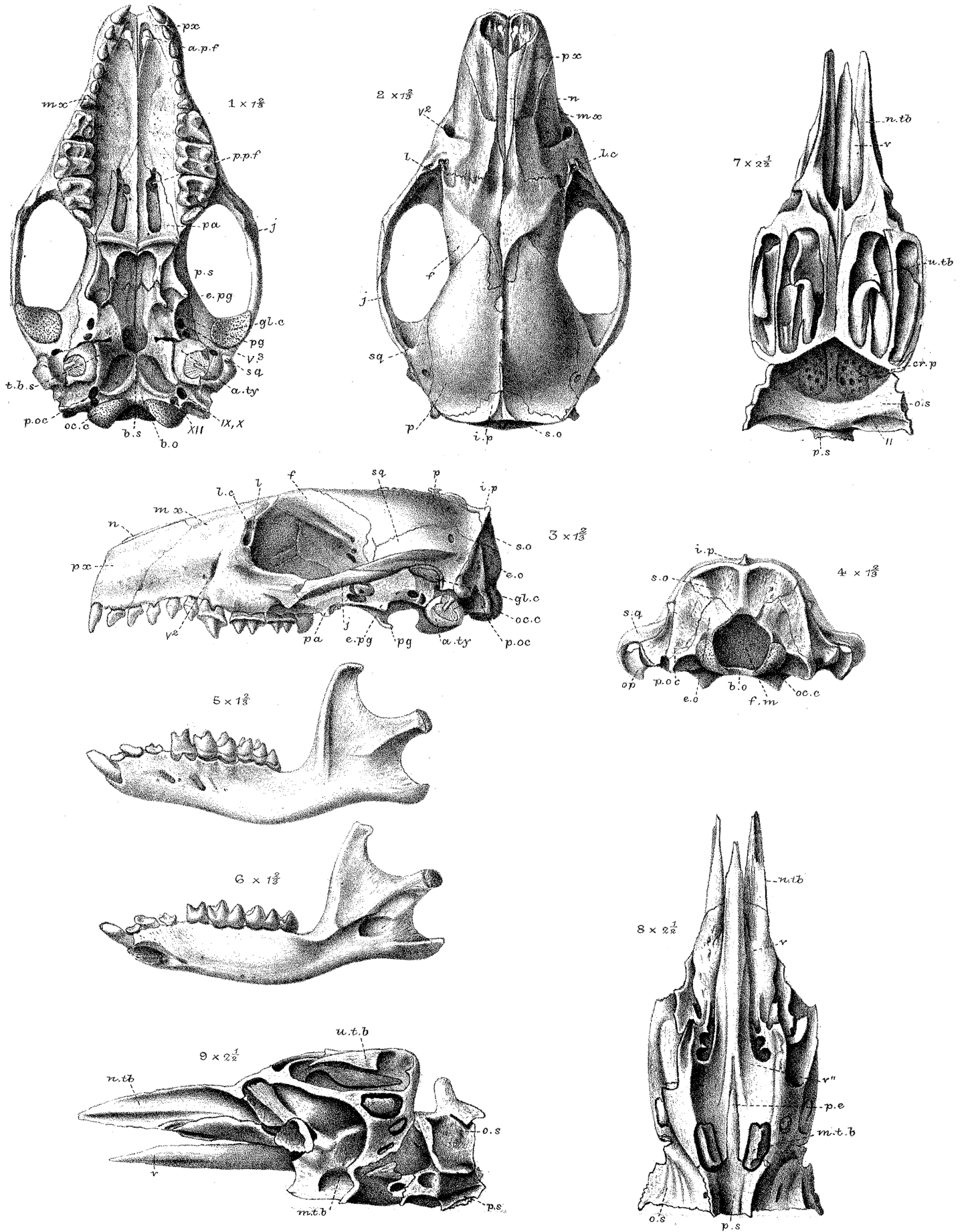
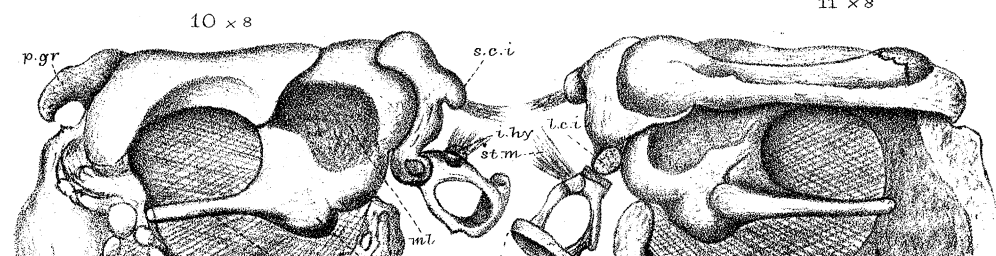
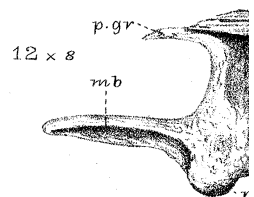
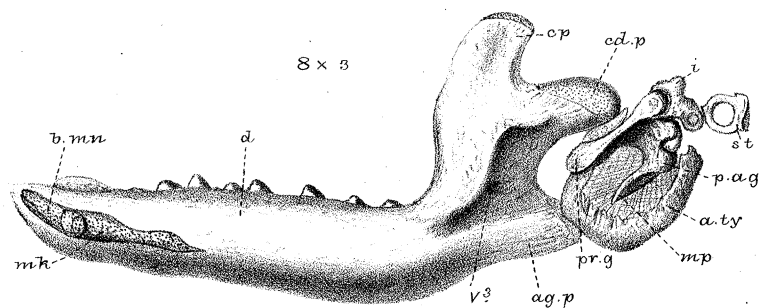
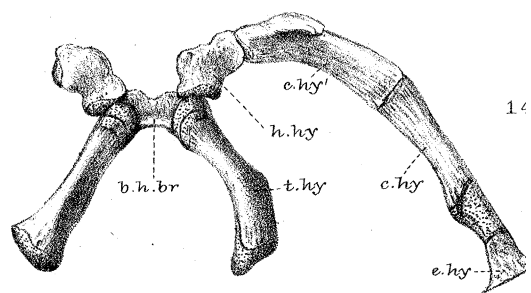
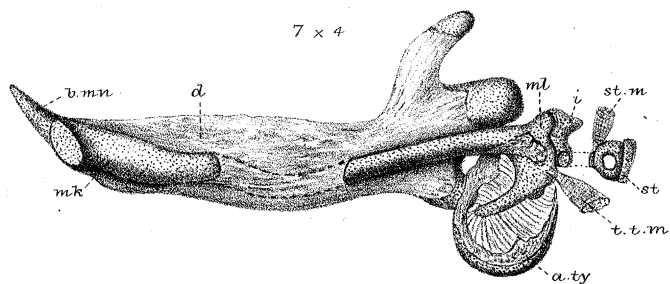
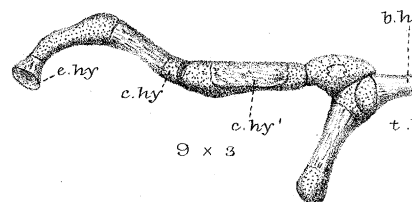
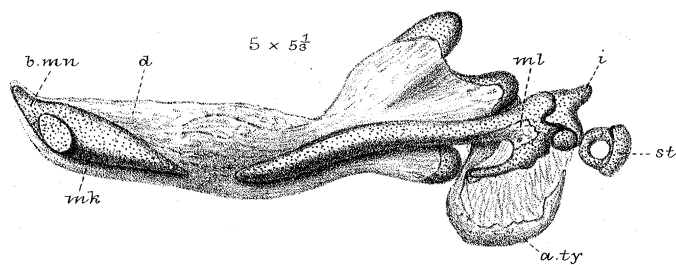
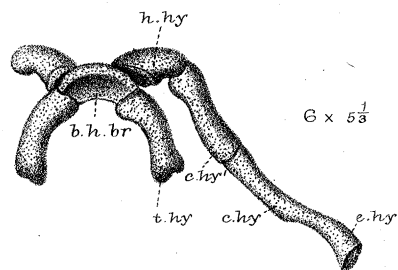
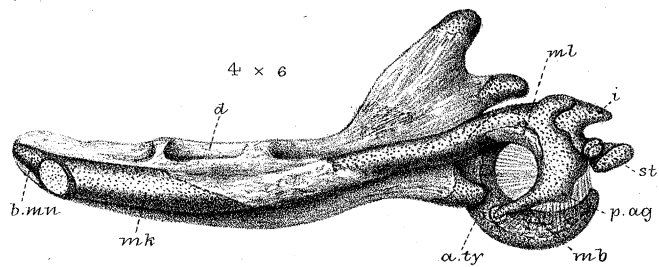
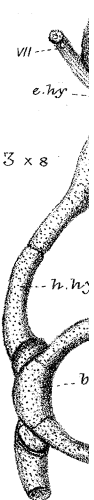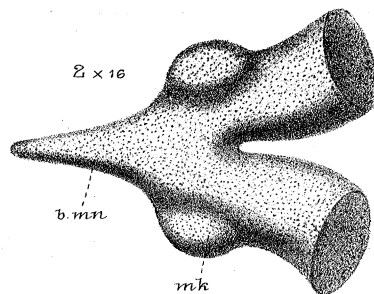
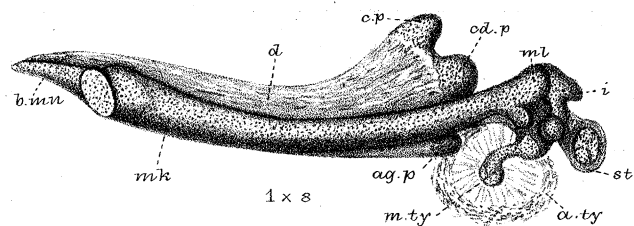

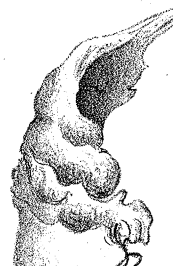
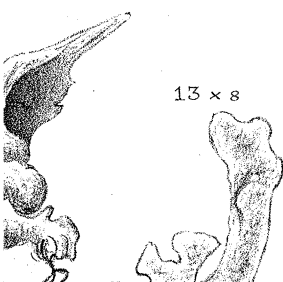
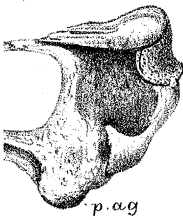
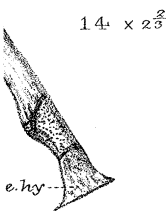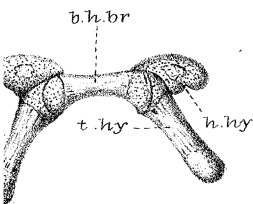
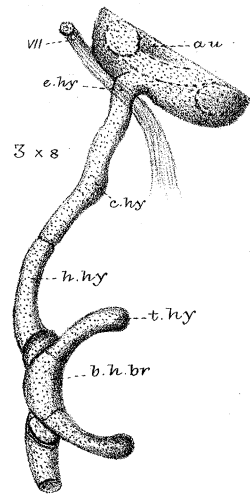
PLATE 22.

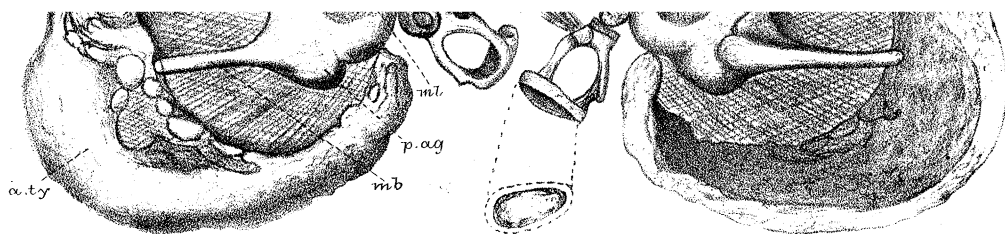
Figures.		Number of times magnified.
1	<i>Erinaceus europæus</i> (a series of stages of visceral arches); deep and superficial mandible and ear-drum; inner view (1st stage); embryo; $1\frac{1}{4}$ inch long	8
2	The same; fore part of deep mandible; upper view . .	16
3	The same; hyoid arch; oblique view	8
4	2nd stage; embryo; $2\frac{1}{4}$ inches long; deep and super- ficial mandible; and ear-drum; inner view	6
5	3rd stage; ripe young; $2\frac{1}{3}$ inches long; the same parts; inner view	$5\frac{1}{3}$
6	The same; hyoid arch; upper view.	$5\frac{1}{3}$
7	4th stage; young, 2 weeks old; the same parts; inner view	4
8	5th stage; head, $1\frac{1}{2}$ inch long; same parts; inner view .	3
9	The same; hyoid arch; upper view.	3
10	7th stage; $\frac{3}{4}$ grown; ear-drum; outer view	8
11	The same; inner view	8
12	8th stage; adult; malleus; outer view	8
13	The same; annulus tympanicus; outer view.	8
14	The same; hyoid arch; upper view	$2\frac{2}{3}$



11 x 8

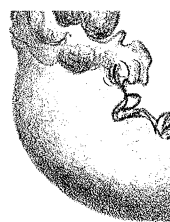



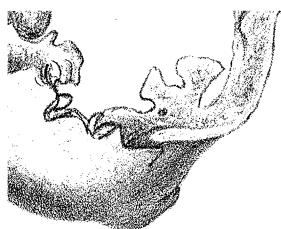


W.K.P. del.
Parker & Coward lith.

Erinaceus.



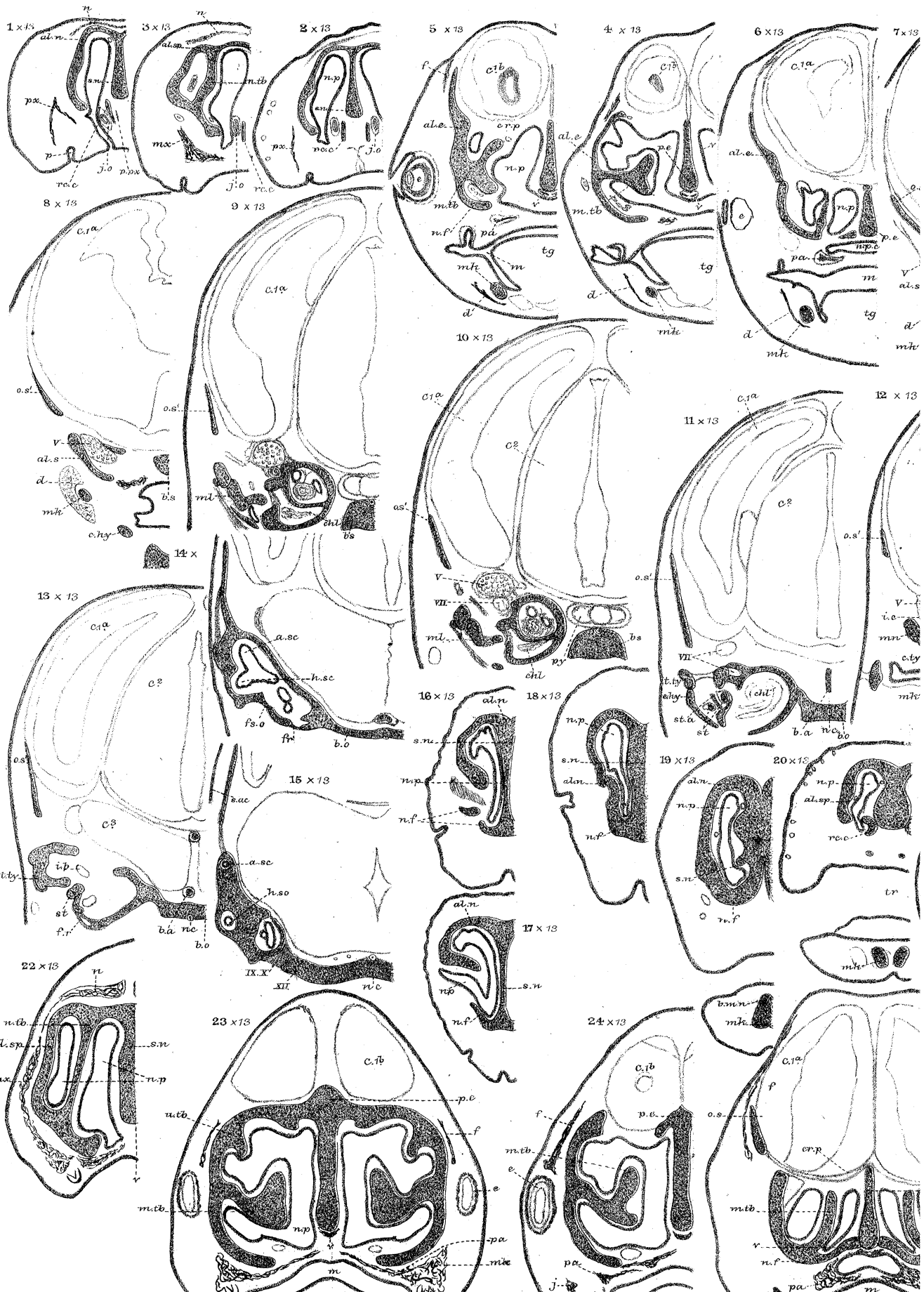
We

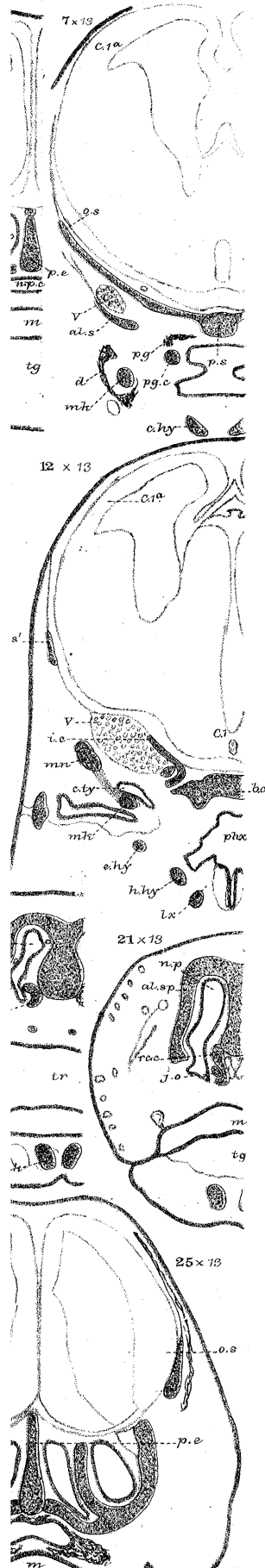


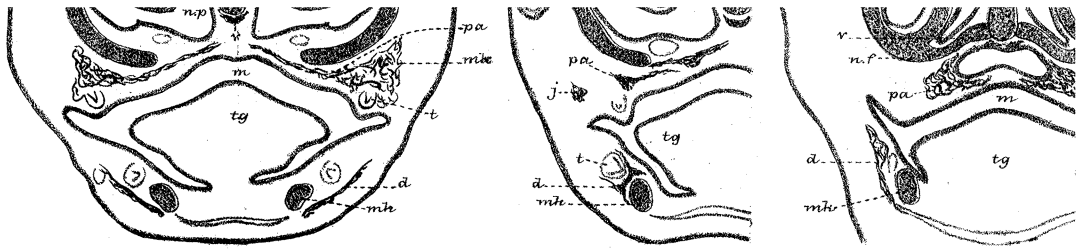
West, Newman & Co imp.

PLATE 23.

Figures.		Number of times magnified.
1	<i>Talpa europæa</i> (3rd stage) ; embryo ; $7\frac{1}{2}$ lines long ; 1st of a series of vertically-transverse sections	13
2	The same ; 2nd section	13
3	The same ; 3rd section	13
4	The same ; 4th section	13
5	The same ; 5th section	13
6	The same ; 6th section	13
7	The same ; 7th section	13
8	The same ; 8th section	13
9	The same ; 10th section	13
10	The same ; 11th section	13
11	The same ; 12th section	13
12	The same ; 9th section	13
13	The same ; 13th section	13
14	The same ; 14th section	13
15	The same ; 15th section	13
16	<i>Talpa europæa</i> (4th stage) ; embryo ; $\frac{3}{4}$ inch long ; 1st of a series of vertically-transverse sections	13
17	The same ; 2nd section	13
18	The same ; 3rd section	13
19	The same ; 4th section	13
20	The same ; 5th section	13
21	The same ; 6th section	13
22	The same ; 7th section	13
23	The same ; 8th section	13
24	The same ; 9th section	13
25	The same ; 10th section	13



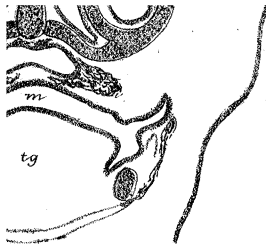




Parker & Coward del et lith.
W.K.P. dir.

Talpa .

West



West, Newman & Co imp.

PLATE 24.

Figures.		Number of times magnified.
1	The same (continued) ; 11th section	$13\frac{1}{3}$
2	The same ; 12th section	$13\frac{1}{3}$
3	The same ; 13th section	$13\frac{1}{3}$
4	The same ; 14th section	$13\frac{1}{3}$
5	The same ; 15th section	$13\frac{1}{3}$
6	The same ; 16th section	$13\frac{1}{3}$
7	The same ; 17th section	$13\frac{1}{3}$
8	The same ; 18th section	$13\frac{1}{3}$
9	The same ; 19th section	$13\frac{1}{3}$
10	The same ; 20th section	$13\frac{1}{3}$
11	The same ; 21st section	$13\frac{1}{7}$
12	The same ; 22nd section	$13\frac{1}{3}$
13	The same ; 23rd section	$13\frac{1}{3}$
14	The same ; 24th section	$13\frac{1}{3}$


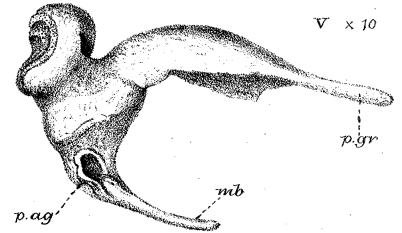
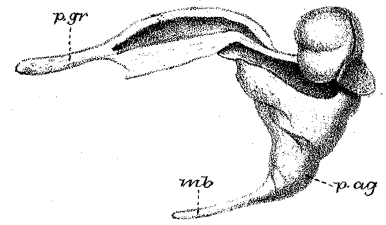
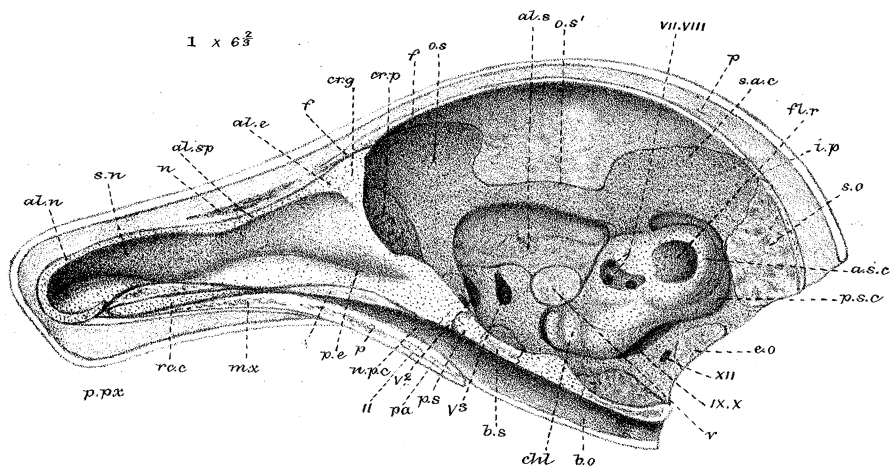


PLATE 25.

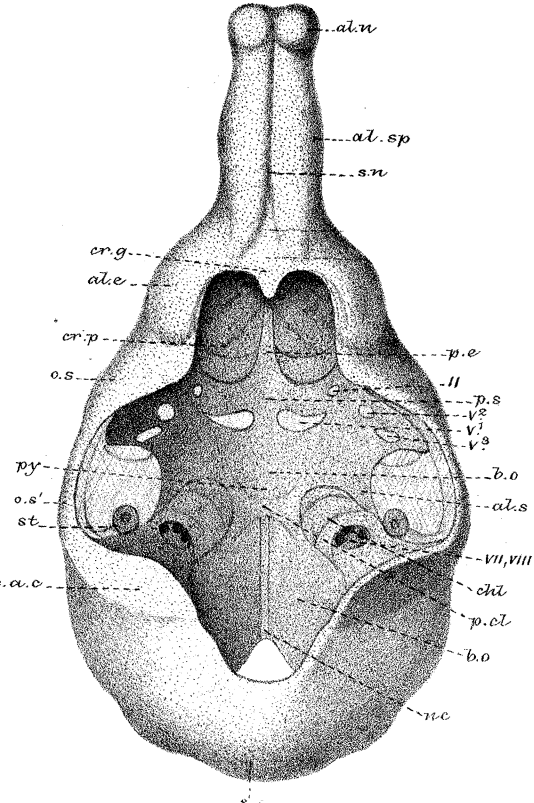
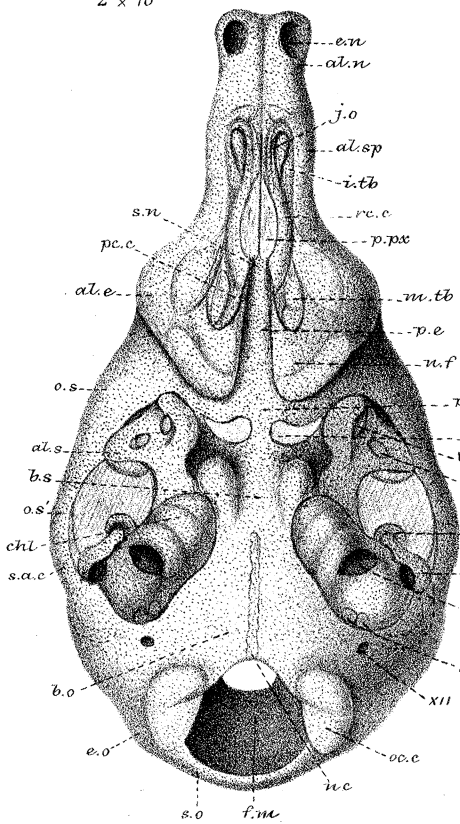
Figures.		Number of times magnified.
1	<i>Talpa europæa</i> (8th stage); ripe young, $1\frac{2}{3}$ inch long; vertical section of head	$6\frac{2}{3}$
2	<i>Talpa europæa</i> (4th stage); embryo, $\frac{3}{4}$ inch long; endo- cranium, lower view	10
3	The same; upper view	10
4	<i>Talpa europæa</i> (9th special, 12th general stage); young mole, $\frac{3}{4}$ grown; malleus; inner view	10
5	The same; outer view	10
6	The same; incus; inner view	10
7	The same; incus; outer view	10
8	<i>Talpa europæa</i> (10th special, 13th general stage); adult; malleus and incus; inner view	10
9	The same; outer view	10
10	The same; stapes; side view	10
11	<i>Talpa europæa</i> (12th stage); young mole, $\frac{3}{4}$ grown; annulus tympanicus; inner view	$6\frac{2}{3}$
12	<i>Talpa europæa</i> (3rd stage); embryo, $\frac{3}{4}$ inch long; hori- zontal section of snout	$6\frac{2}{3}$
13	<i>Talpa europæa</i> (10th stage); young mole, 3 inches long; annulus and meatus externus	$6\frac{2}{3}$
14	<i>Talpa europæa</i> (13th stage); adult; vertical section of snout	$3\frac{2}{3}$

4 x 10



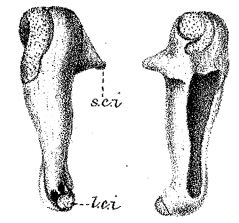
2 x 10

3 x 10

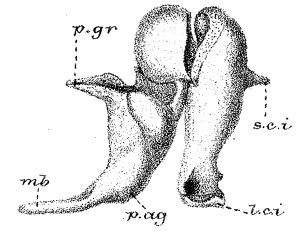


6 x 10

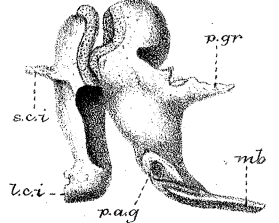
7 x 10



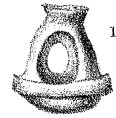
8 x 10



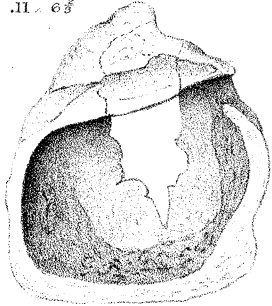
9 x 10



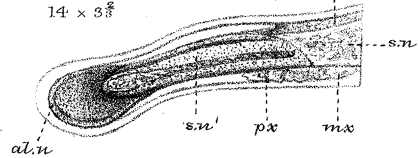
10 x 10



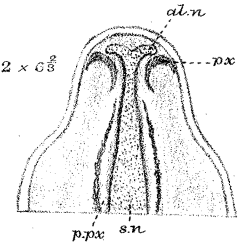
11 x 6 2/3



14 x 3 2/3



12 x 6 2/3



13 x 6 2/3

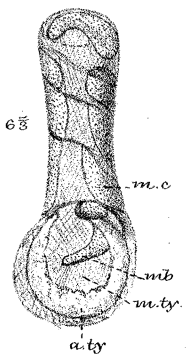


PLATE 26.

Figures.		Number of times magnified.
1	<i>Talpa europæa</i> (9th stage); young, $1\frac{4}{5}$ inch long; dissected skull; upper view	$6\frac{2}{3}$
2	The same; lower view	$6\frac{2}{3}$
3	The same; side view	$6\frac{2}{3}$
4	The same; endocranium; upper view	$6\frac{2}{3}$
5	The same; lower view	$6\frac{2}{3}$
6	The same; inner view (part)	$6\frac{2}{3}$

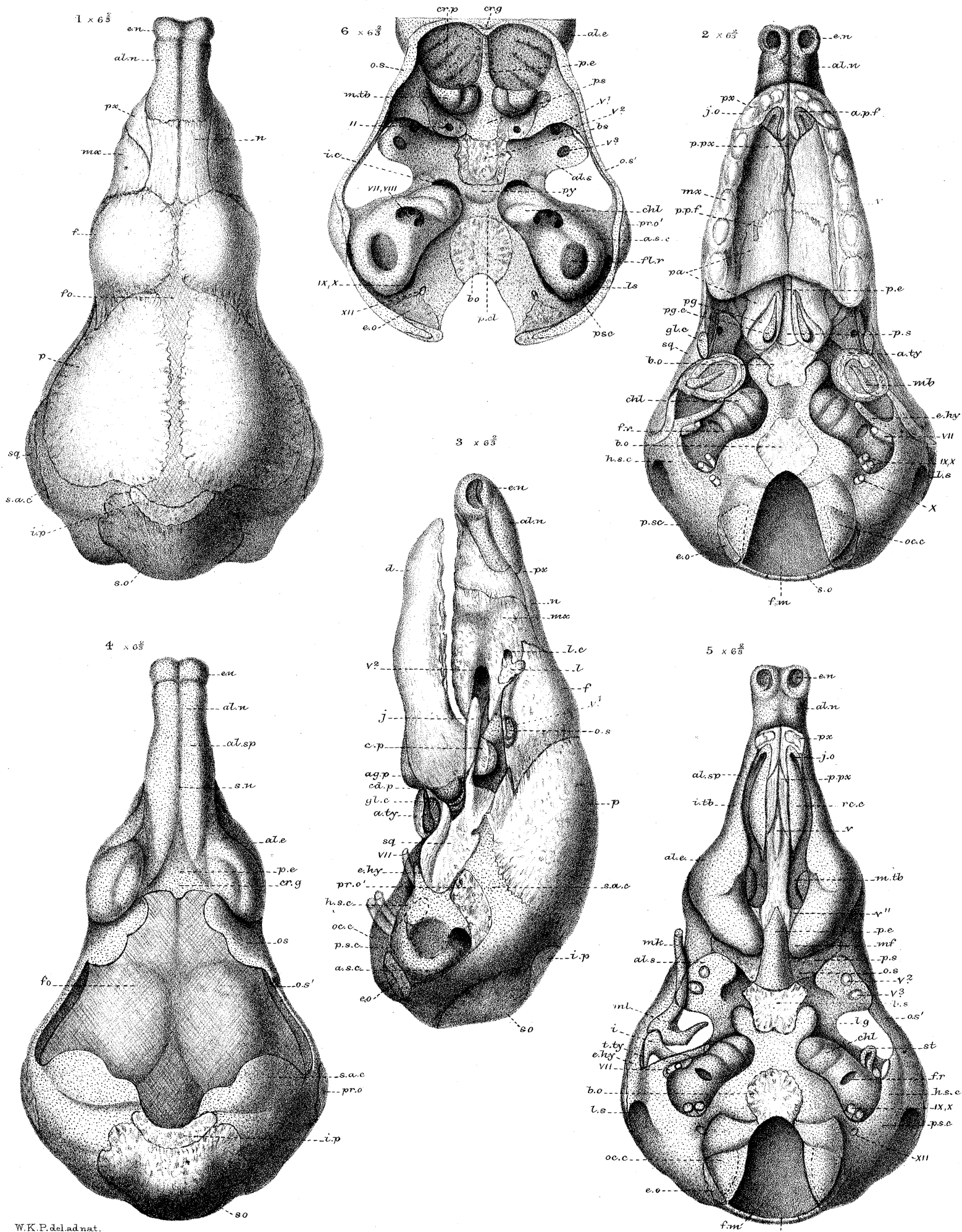
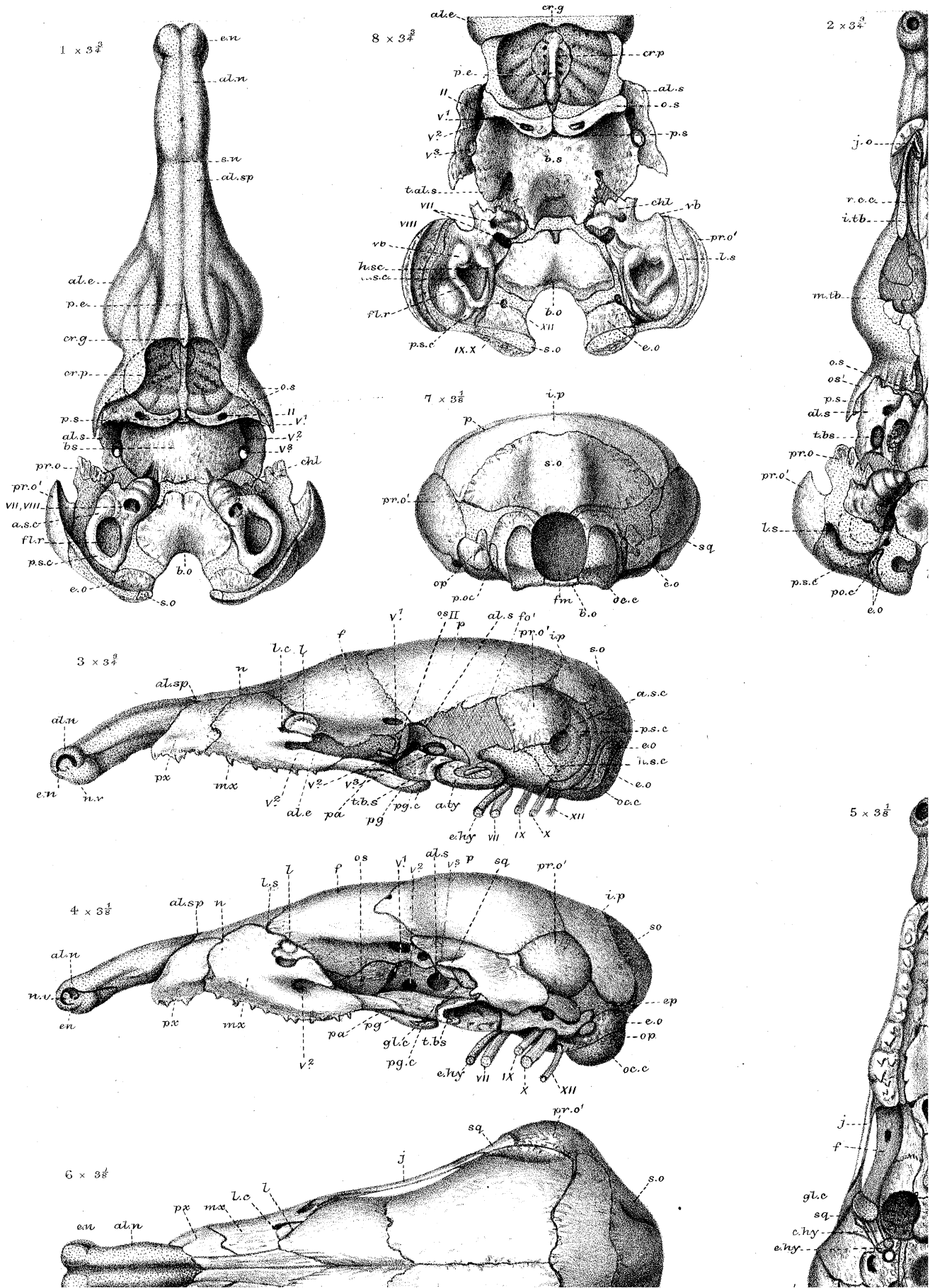
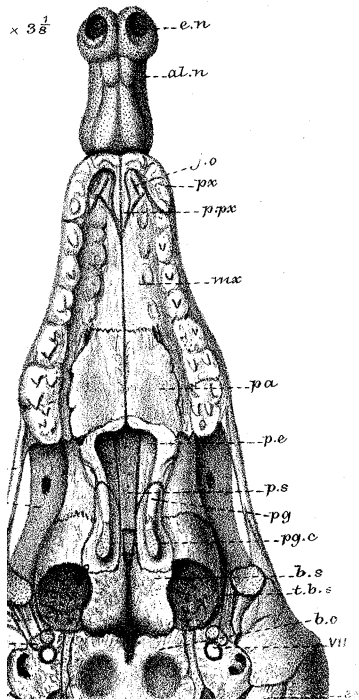
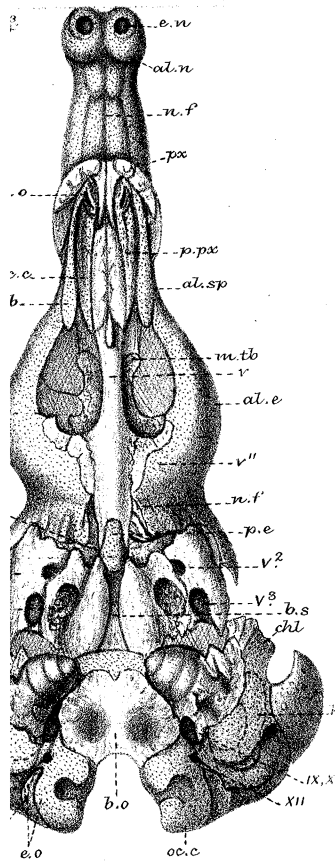
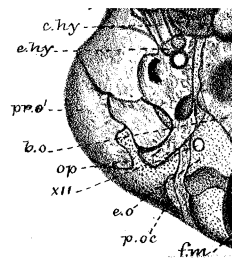
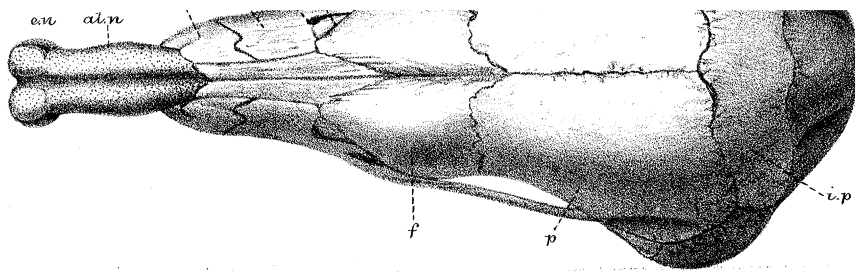


PLATE 27.

Figures.		Number of times magnified.
1	<i>Talpa europæa</i> (10th stage); young mole, 3 inches long; endocranium; upper view	$3\frac{3}{4}$
2	The same; lower view	$3\frac{3}{4}$
3	The same; dissected skull with some bones removed; side view	$3\frac{3}{4}$
4	<i>Talpa europæa</i> (11th stage); young mole, $\frac{2}{3}$ grown; skull, with jugal bone removed; side view	$3\frac{1}{8}$
5	Same skull (perfect); lower view	$3\frac{1}{8}$
6	The same; upper view	$3\frac{1}{8}$
7	The same; end view	$3\frac{1}{8}$
8	The same; inside of hind skull	$3\frac{3}{4}$

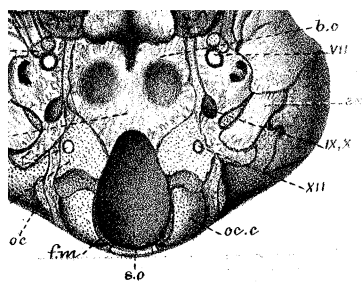






W.K.P. del. ad nat.
Parker & Coward lith.

Talpa europæa

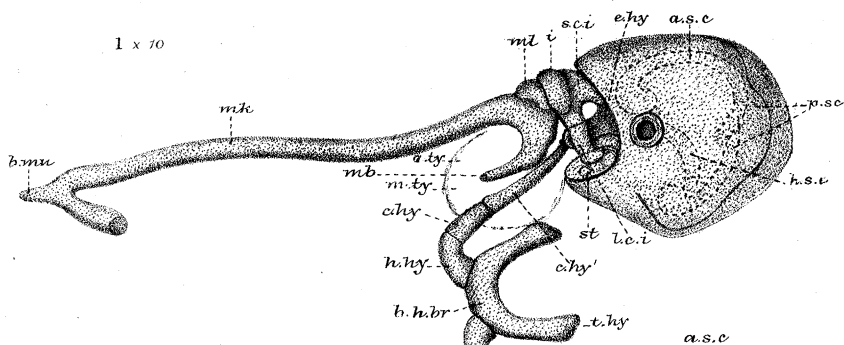


West, Newman & Co.

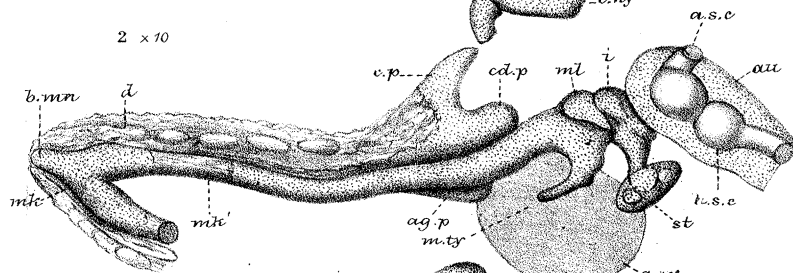
PLATE 28.

Figures.		Number of times magnified.
1	<i>Talpa europæa</i> ; first of a series of stages of the visceral arches, the main figures all drawn from the inside (3rd stage of the whole series) ; embryo mole, $\frac{2}{3}$ inch long .	10
2	The same (2nd special, 4th general stage) ; embryo, $\frac{4}{5}$ inch long	10
3	The same (3rd special, 5th general stage) ; embryo mole, 1 inch long	10
4	The same (4th special, 6th general stage) ; embryo mole, $1\frac{1}{3}$ inch long	10
5	The same (5th special, 7th general stage) ; embryo mole, $1\frac{1}{2}$ inch long	10
6	The same (6th special, 9th general stage) ; suckling mole, 2 or 3 days old	10
7	The same (7th special, 10th general stage) ; young mole, 3 inches long	10
8	The same (8th special, 11th general stage) ; young mole, $\frac{2}{3}$ grown ; hyoid arch ; upper view	10
9	The same ; malleus ; inner view	10
10	The same ; malleus ; outer view	10
11	The same species (9th special, 12th general stage) ; stapes <i>in situ</i>	10

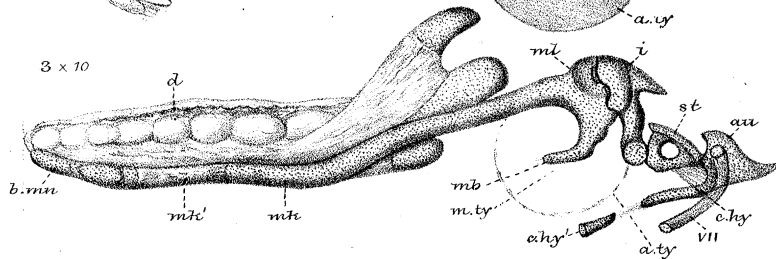
1 x 70



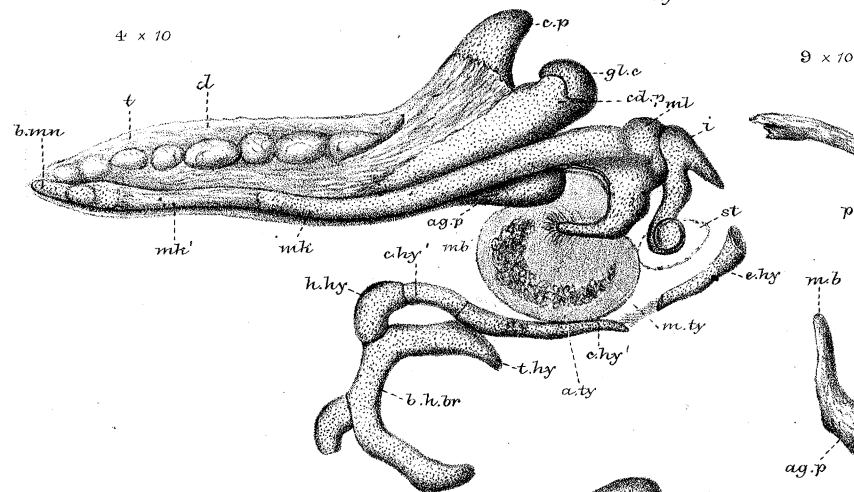
2 x 10



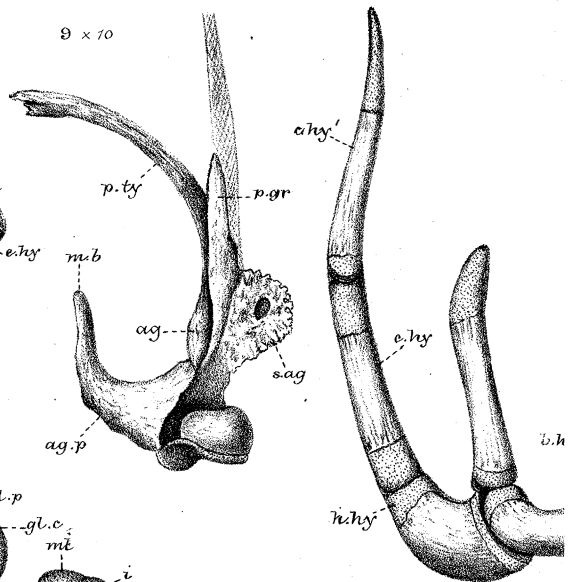
3 x 10



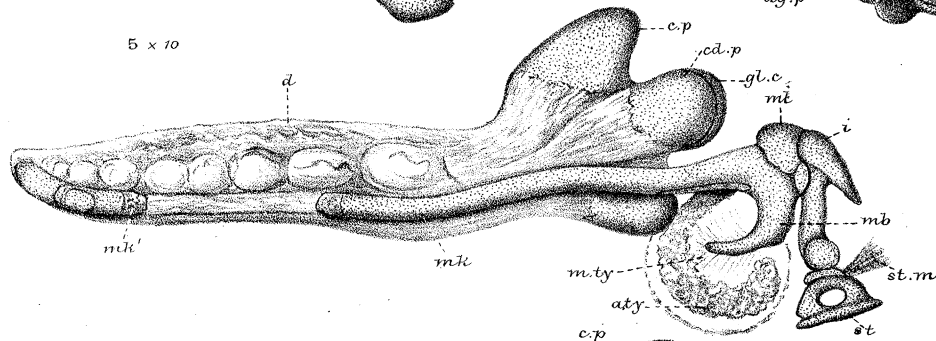4 x 10



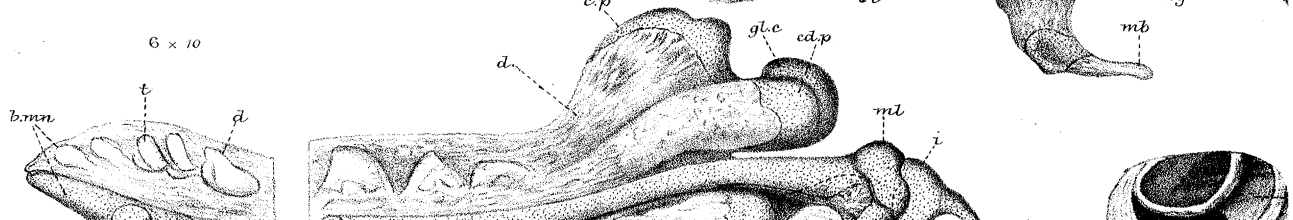9 x 10



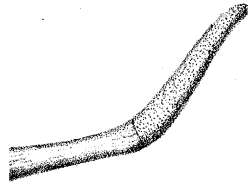
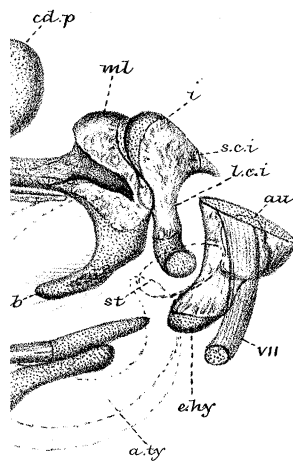
5 x 10



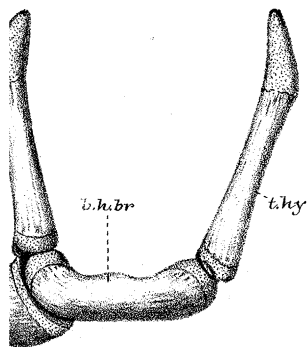
6 x 10



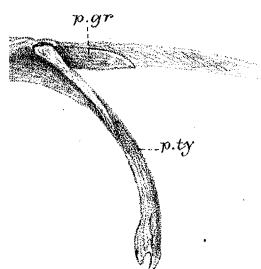
$\times 10$



8×10

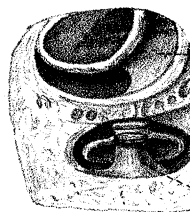
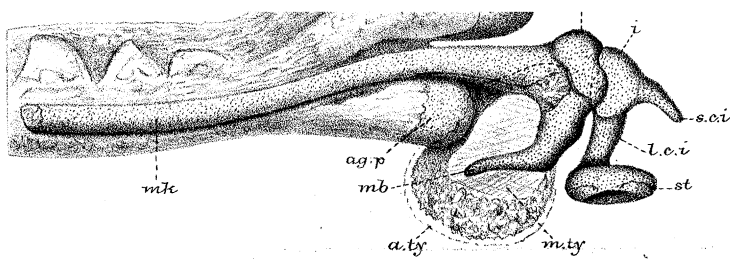
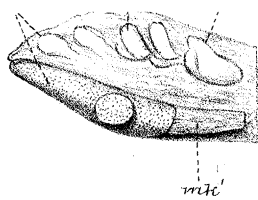


10×10



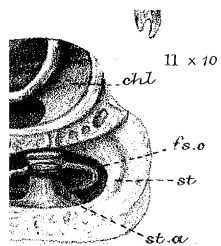
11×10





W.K.P. del. adnat.
Pariser & Coward lith.

Talpa europæa.



West, Newman & Co. imp.

PLATE 29.

Figures.		Number of times magnified.
1	<i>Sorex vulgaris</i> (3rd stage); dissected skull of young shrew, $1\frac{1}{3}$ inch long; upper view	8
2	The same; lower view	8
3	The same; endocranium; upper view	8
4	The same; lower view	8
5	The same as fig. 4; part	22
6	The same; ossicula auditûs; outer view	20
7	<i>Sorex vulgaris</i> (2nd stage), $9\frac{1}{2}$ lines long (19mm.); section of skull	12

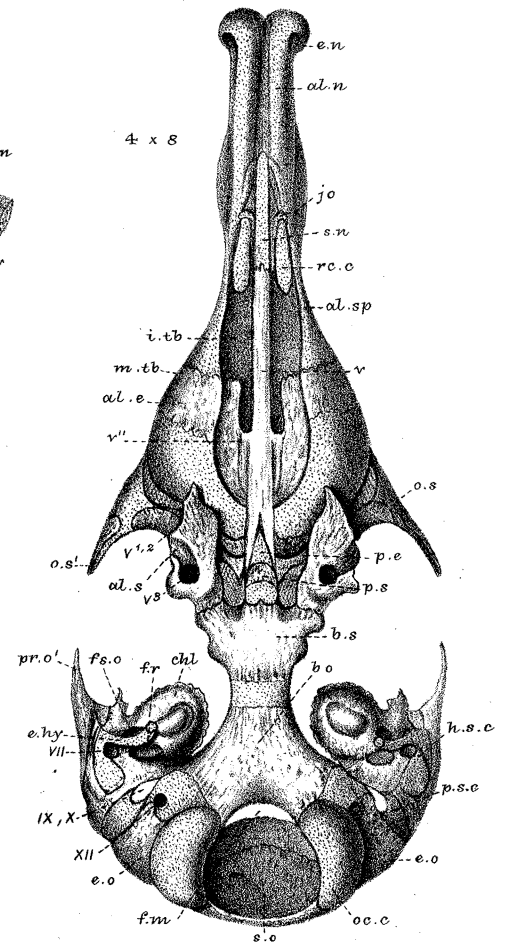
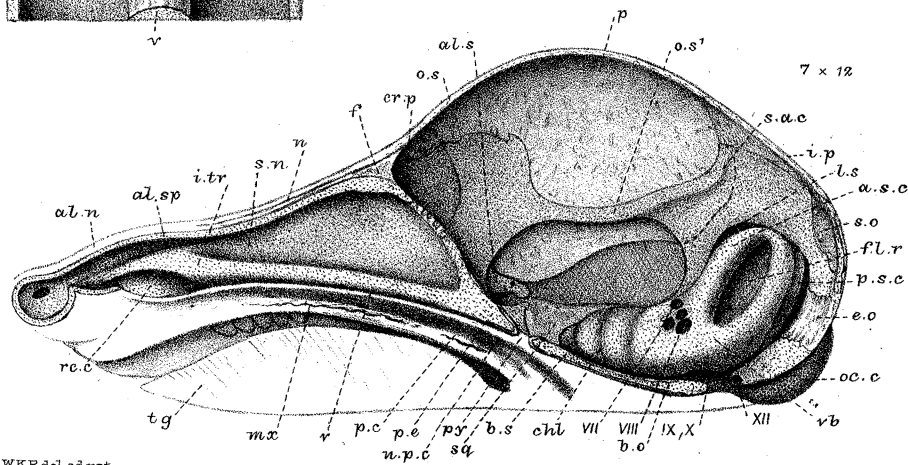
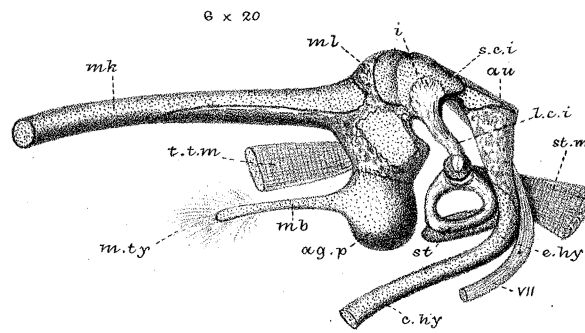
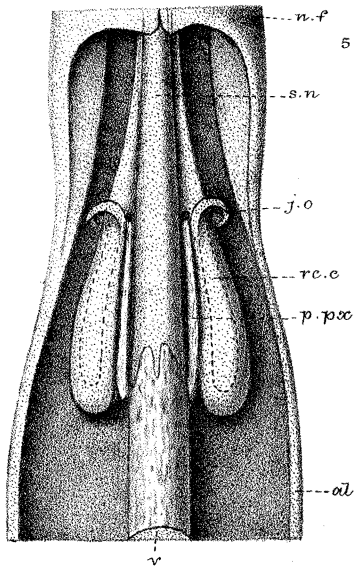
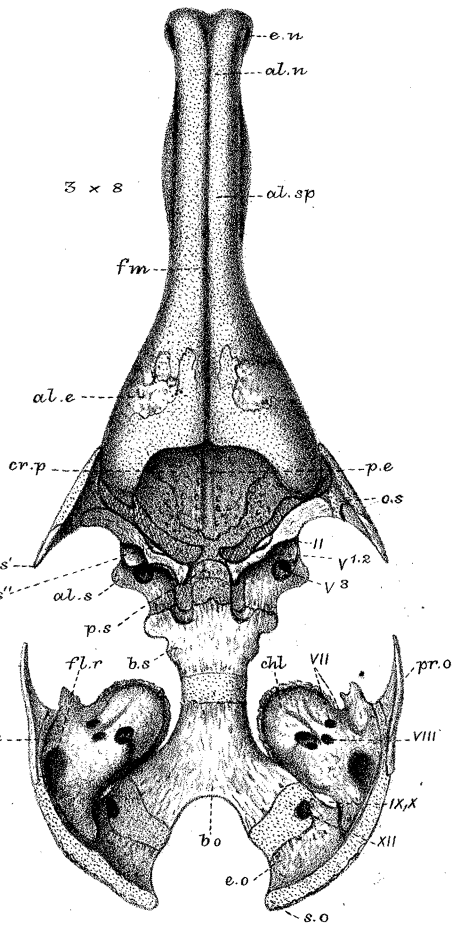
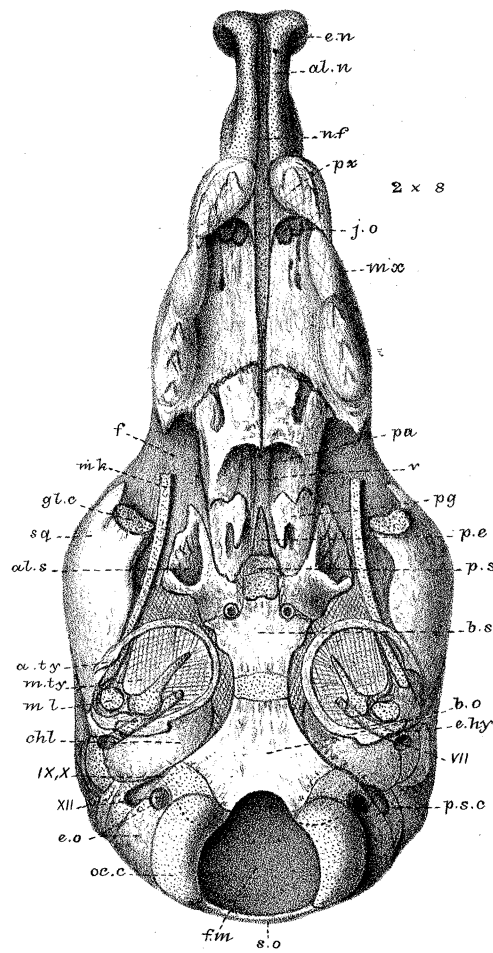
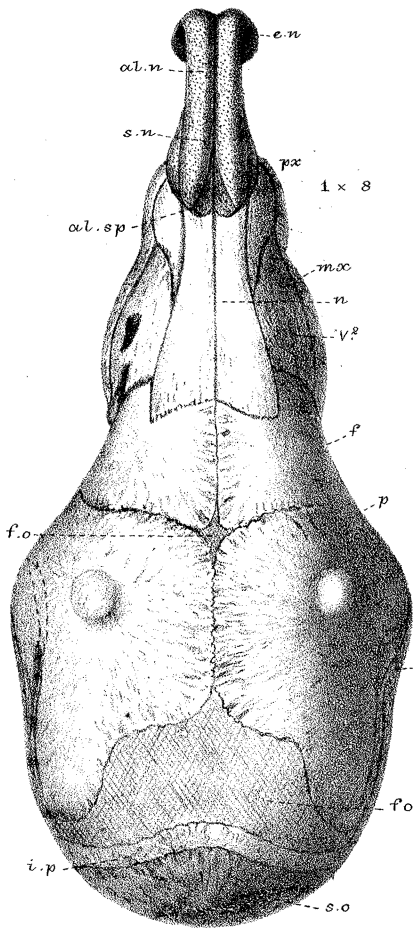
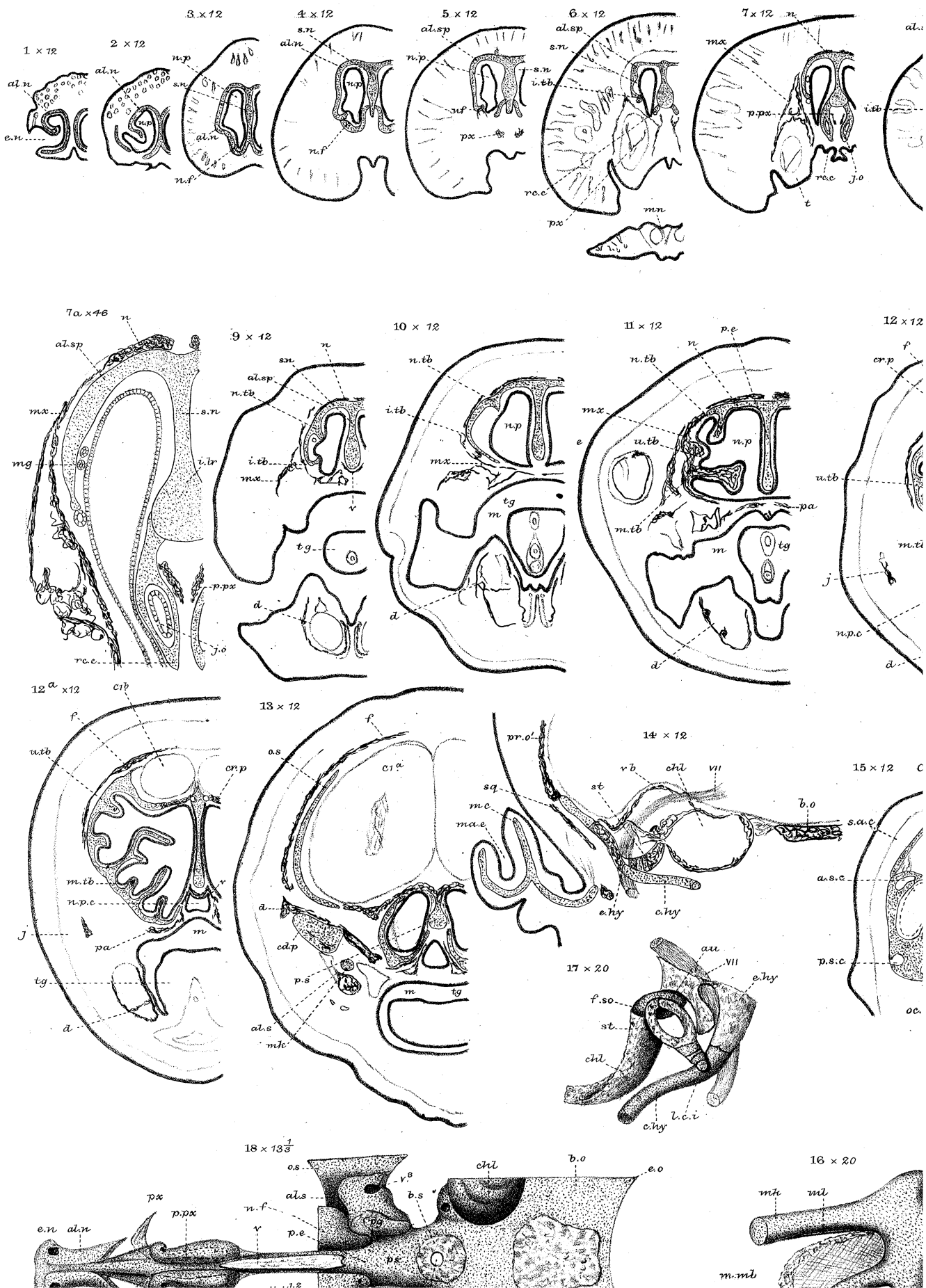
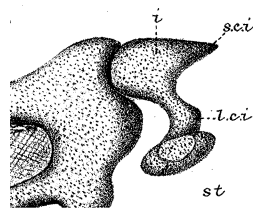
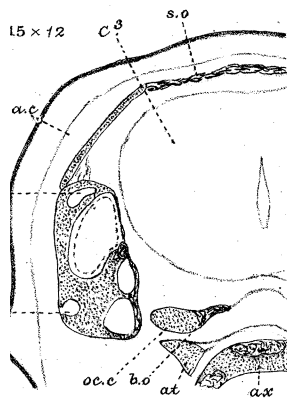
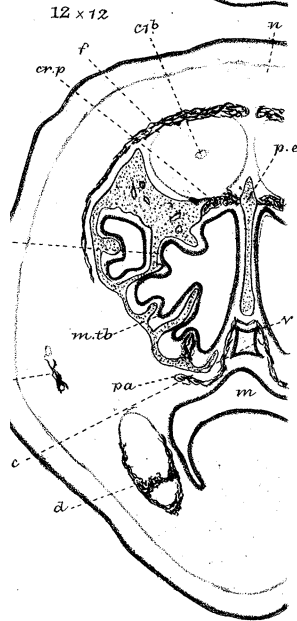
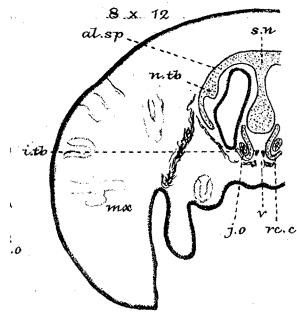
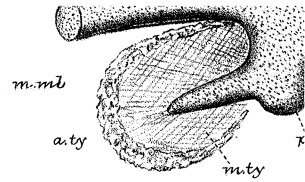
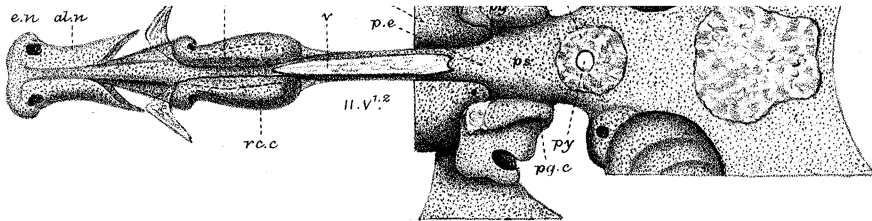


PLATE 30.

Figures.		Number of times magnified.
1	<i>Sorex vulgaris</i> (3rd stage) ; young $1\frac{1}{3}$ inch long ; first of a series of vertically-transverse sections of head . . .	12
2	The same ; 2nd section	12
3	The same ; 3rd section	12
4	The same ; 4th section	12
5	The same ; 5th section	12
6	The same ; 6th section	12
7	The same ; 7th section	12
7A	The same (part of fig. 7)	46
8	The same ; 8th section	12
9	The same ; 9th section	12
10	The same ; 10th section	12
11	The same ; 11th section	12
12	The same ; 12th section	12
13	The same ; 13th section	12
14	The same ; 14th section	12
15	The same ; 15th section	12
16	<i>Sorex vulgaris</i> (2nd stage)	20
17	Ditto (3rd stage) ; ossicula auditûs ; inner view . . .	20
18	The same ; endocranium (part) ; lower view (2nd stage) .	$13\frac{1}{3}$

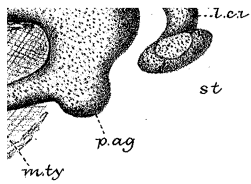






W.K.P. direx et del.
Parker & Coward lith.

Sorex Vulgaris.



West, Newman & Co imp.

PLATE 31.

Figures.		Number of times magnified.
1	<i>Sorex vulgaris</i> (4th stage); skull of adult; upper view .	5
2	The same; lower view	5
3	The same; side view	5
3A	The same; end view of lower jaw	5
4	The same; petromastoid bone; inner view	12
5	The same; outer view	12
6	The same; malleus, incus, and tympanic; outer view . .	18
7	The same; inner view	18
8	The same; stapes; side view	18
9	<i>Sorex vulgaris</i> (4th stage); adult; hyoid arch; inner view	7
10	The same (3rd stage); skull; side view	7
11	The same; section; side view	7
12	The same; hyoid arch	12

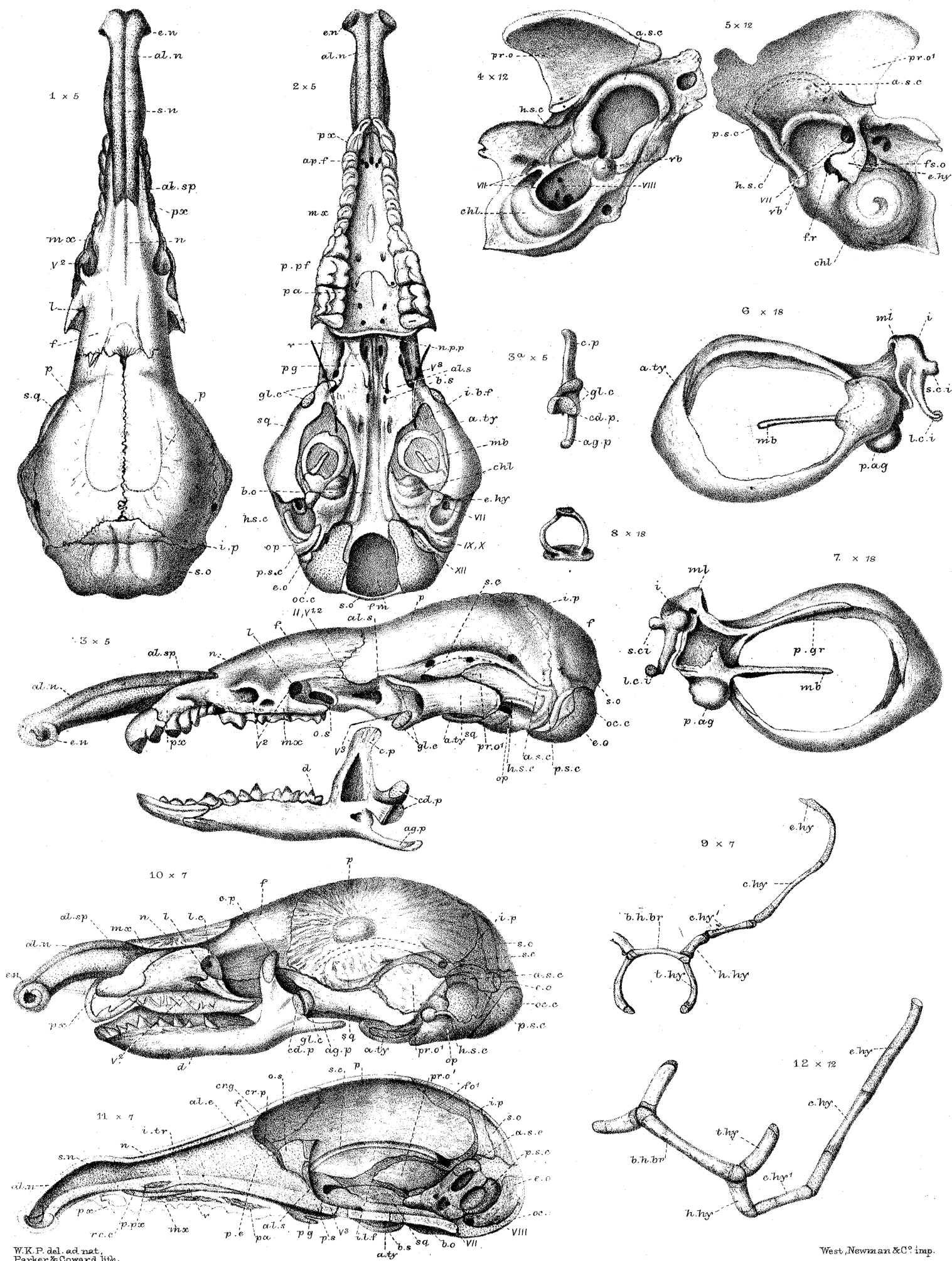


PLATE 32.

Figures.		Number of times magnified.
1	<i>Centetes ecaudatus</i> (2nd stage); embryo; $1\frac{1}{2}$ inch long; skull; upper view	$5\frac{1}{3}$
2	The same; lower view	$5\frac{1}{3}$
3	The same; side view	$5\frac{1}{3}$
4	The same; endocranium; lower view	$5\frac{1}{3}$
5	The same; upper view	$5\frac{1}{3}$
6	The same; ethmo-septal region; side view	8
7	The same; ossicula auditûs; inner view	20
8	The same; hyoid arch; inner view	$13\frac{1}{2}$

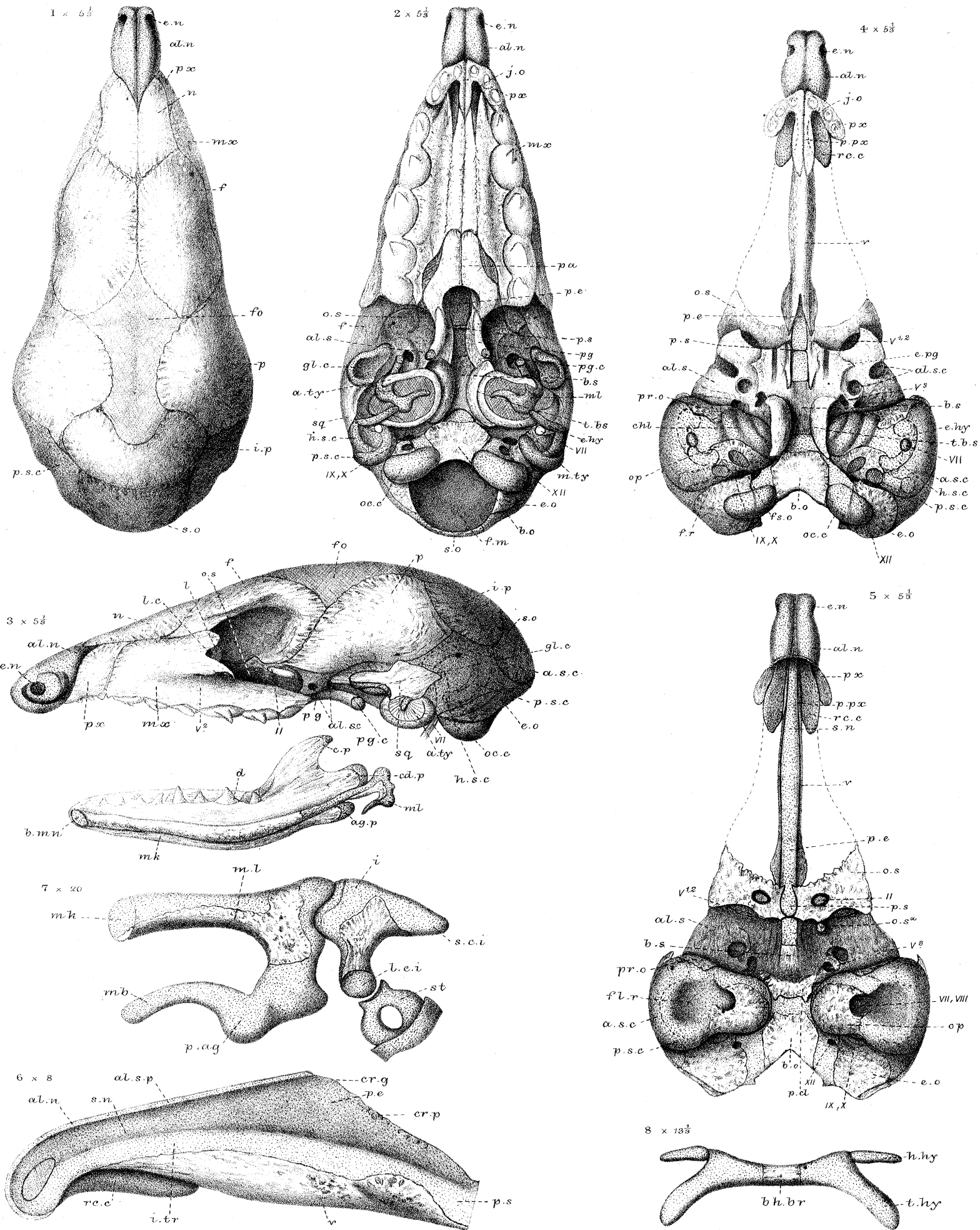


PLATE 33.

Figures.		Number of times magnified.
1	<i>Centetes ecaudatus</i> (3rd stage); nestling Tenrec; $3\frac{1}{4}$ inches long; skull; lower view	$3\frac{1}{3}$
2	The same; upper view	$3\frac{1}{3}$
3	The same; side view	$3\frac{1}{3}$
3A	The same; lower jaw; end view	$3\frac{1}{3}$
4	The same; skull; end view	$3\frac{1}{3}$
5	The same; skull in section	$3\frac{1}{3}$
6	The same; ossicula and tympanic; inner view	$13\frac{1}{3}$
7	The same; bones (part); outer view	$13\frac{1}{3}$
8	The same; part of vomerine region; lower view	$3\frac{1}{3}$
9	The same; hyoid arch; upper view	$3\frac{1}{3}$
10	The same; nasal labyrinth; side view	$3\frac{1}{3}$

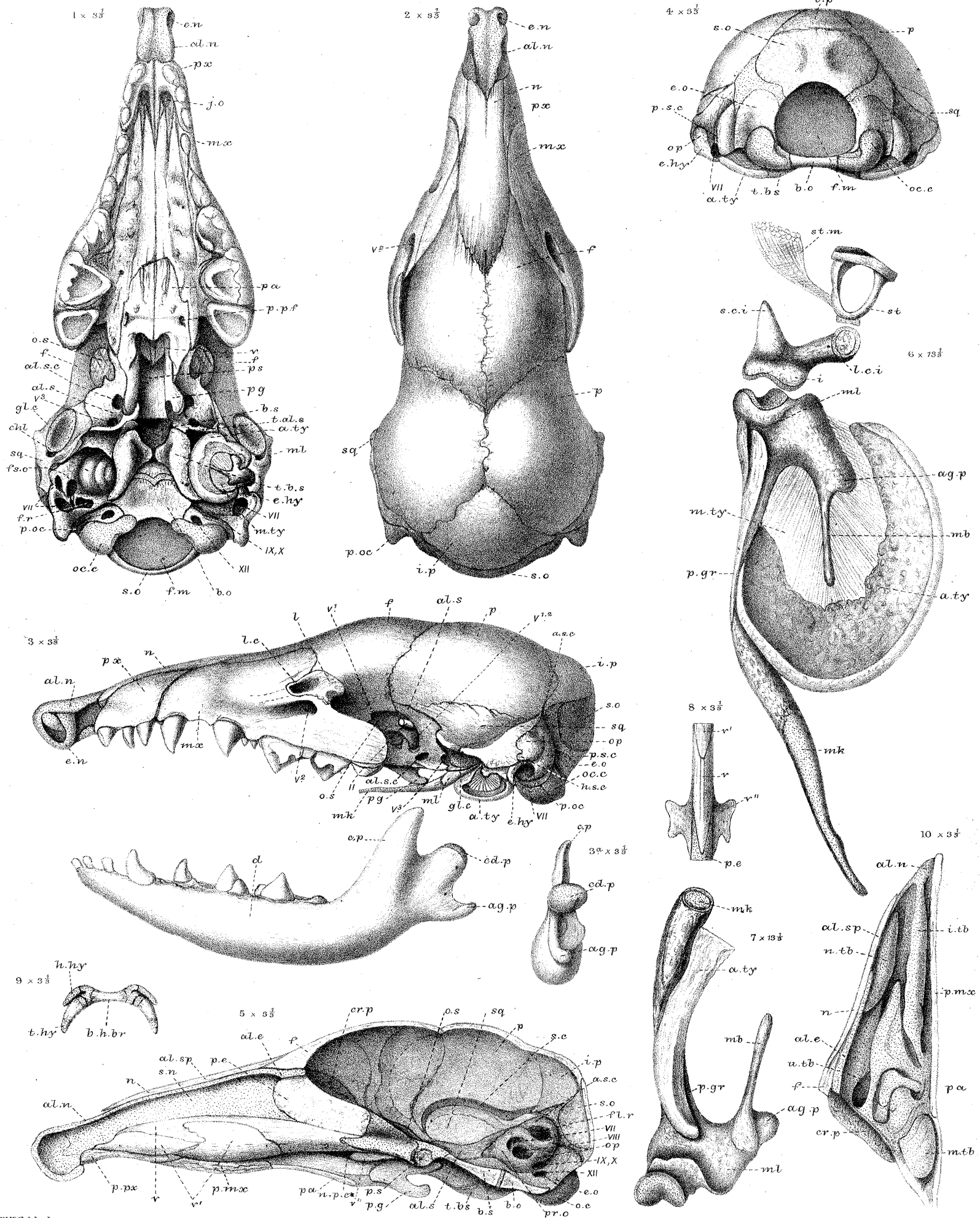


PLATE 34.

Figures.		Number of times magnified.
1	<i>Hemicentetes Madagascarensis</i> ; sub-adult; skull; lower view	$3\frac{1}{3}$
2	The same; upper view	$3\frac{1}{3}$
3	The same; side view	$3\frac{1}{3}$
4	The same; end view	$3\frac{1}{3}$
5	The same; lower jaw; end view	$3\frac{1}{3}$
6	<i>Hemicentetes nigrescens</i> ; sub-adult; hyoid arch; inner view	$3\frac{1}{3}$
7	The same; ethmo-septal region	$3\frac{1}{3}$
8	The same; with vomers <i>in situ</i>	$3\frac{1}{3}$
9	The same; ossicula and tympanic; inner view	15

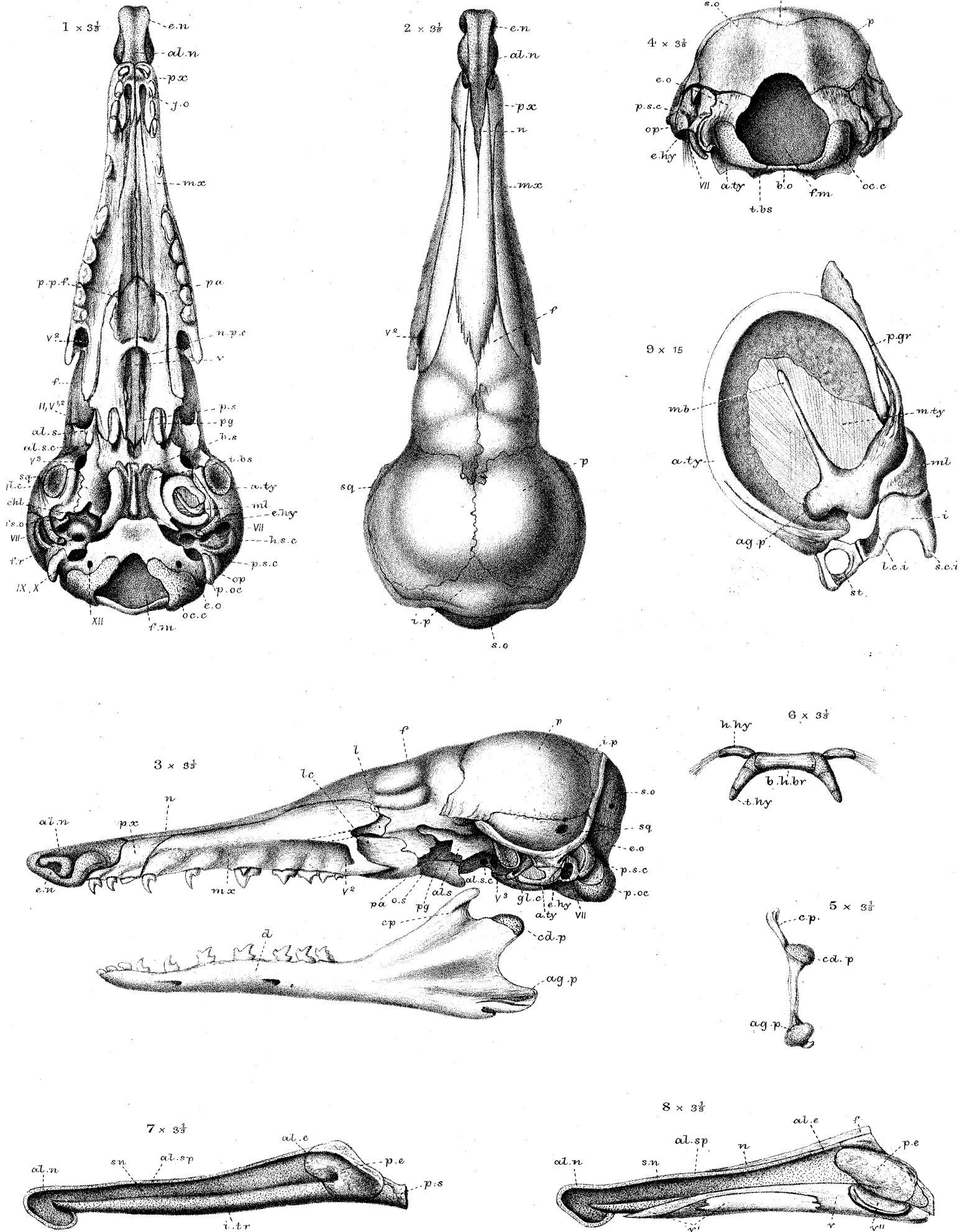
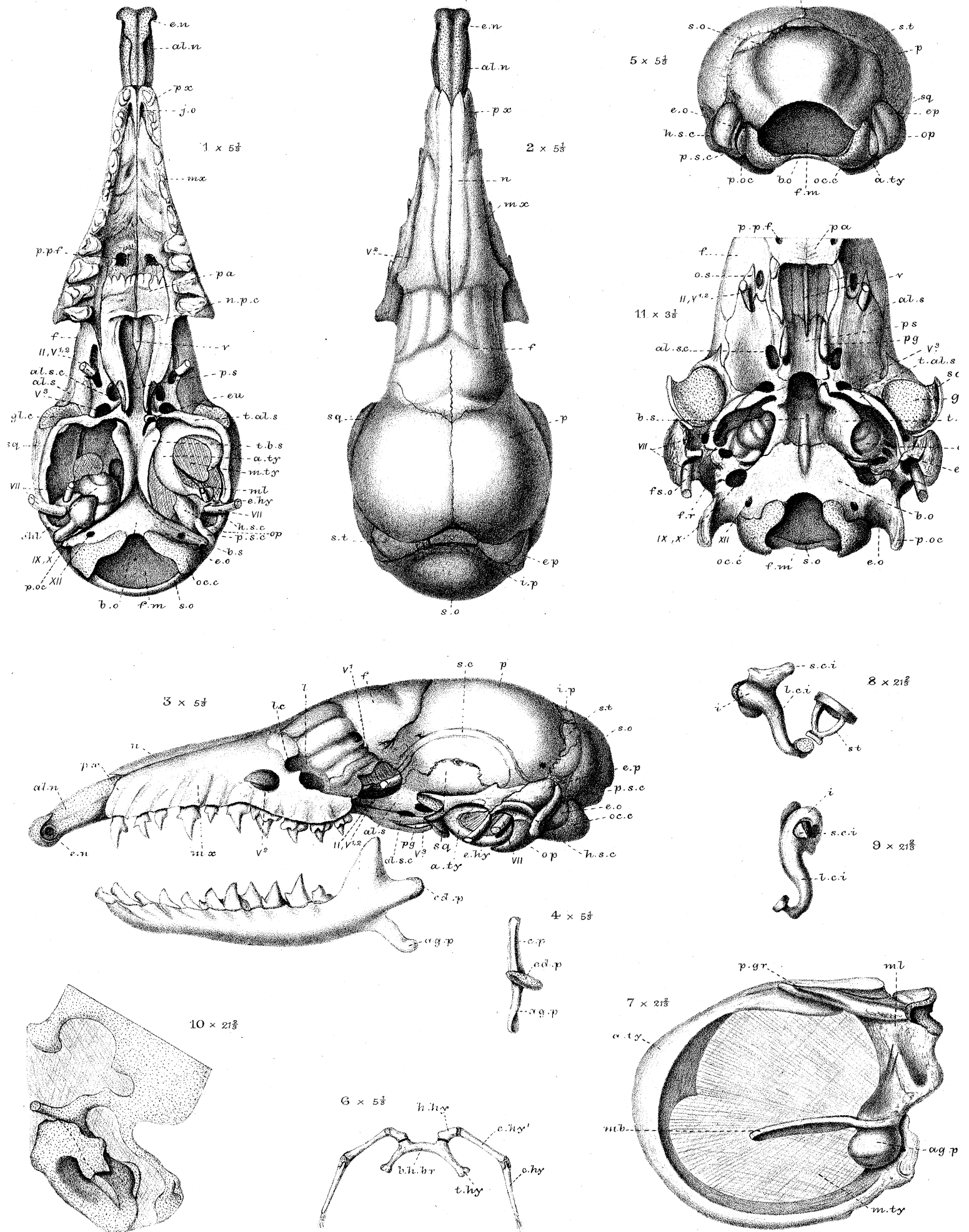


PLATE 35.

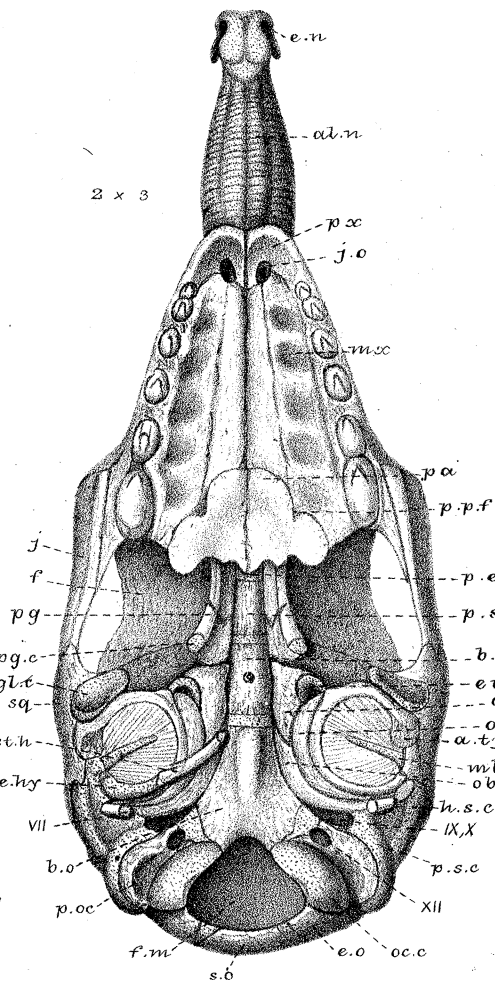
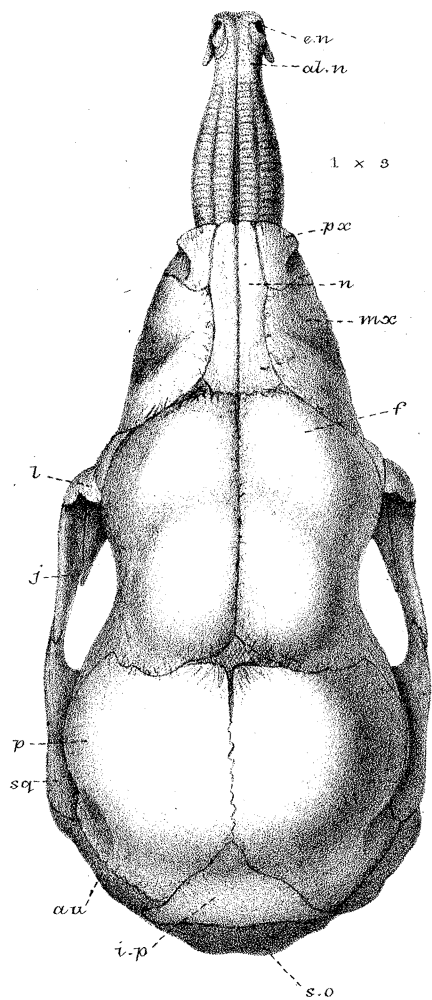
Figures.		Number of times magnified.
1	<i>Microgale longicaudata</i> ; adult; skull; lower view . .	$5\frac{1}{3}$
2	The same; upper view	$5\frac{1}{3}$
3	The same; side view	$5\frac{1}{3}$
4	The same; end view of lower jaw	$5\frac{1}{3}$
5	The same; skull; end view	$5\frac{1}{3}$
6	The same; hyoid arch; inner view	$5\frac{1}{3}$
7	The same; malleus and tympanic; inner view	$21\frac{2}{3}$
8	The same; incus and stapes; inner view	$21\frac{2}{3}$
9	The same; incus; outer view	$21\frac{2}{3}$
10	The same; meatus-cartilage	$21\frac{2}{3}$
11	<i>Ericulus nigrescens</i> ; adult; lower view of skull (part) .	$3\frac{1}{3}$



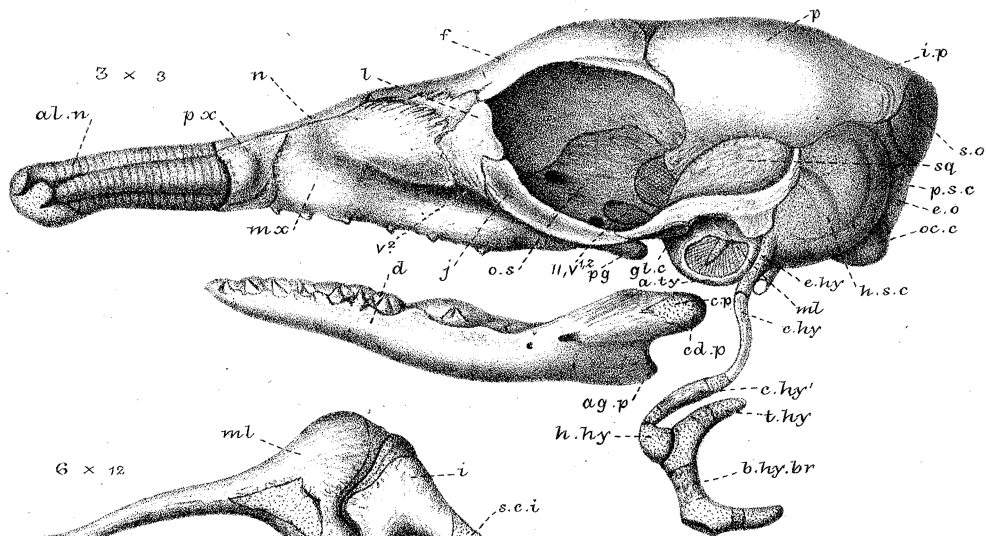
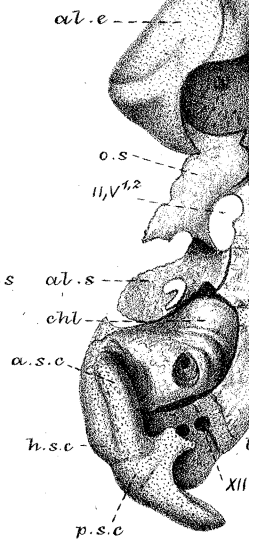
Figs. 1-10. Microgale. Fig. 11. Ericulus

PLATE 36.


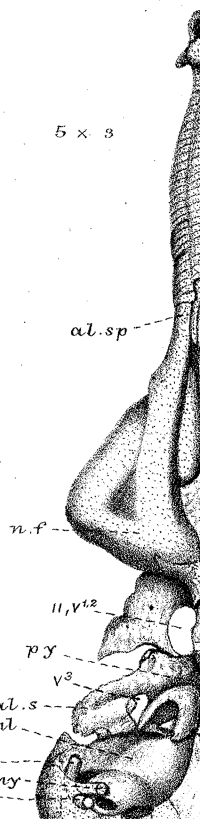
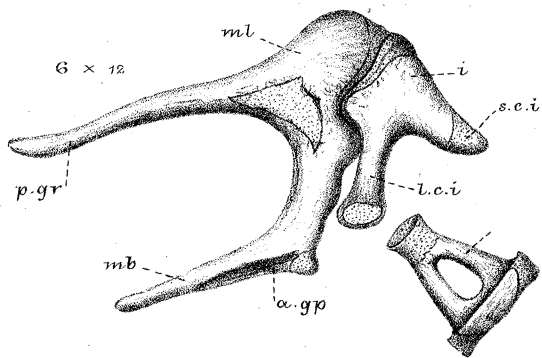
Figures.		Number of times magnified.
1	<i>Rhynchocyon cernei</i> ; embryo; 4 inches long; skull; upper view	3
2	The same; lower view	3
3	The same; side view	3
4	The same; endocranium; upper view	3
5	The same; lower view	3
6	The same; ossicula auditûs; inner view	12
7	The same; ethmo-septal region	4 $\frac{1}{2}$

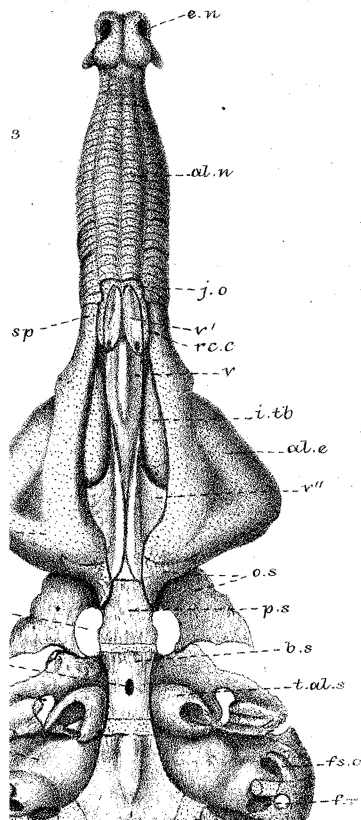
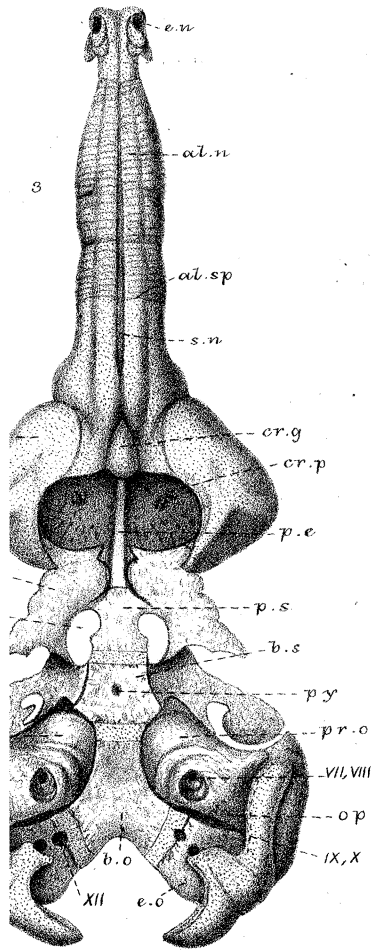


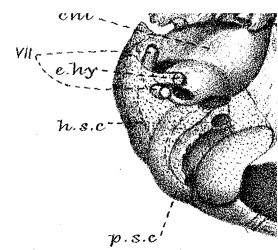
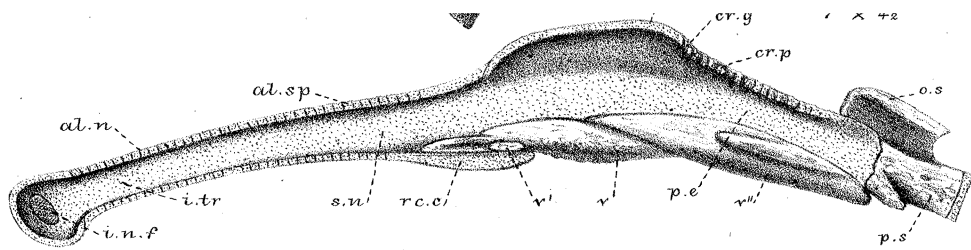
4 x 3



5 x 3

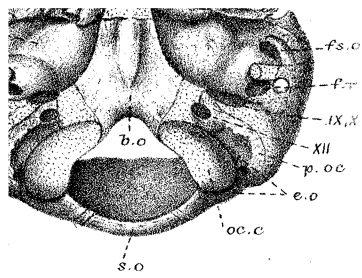






W.K.P. del. ad. nat.
Parker & Coward lith.

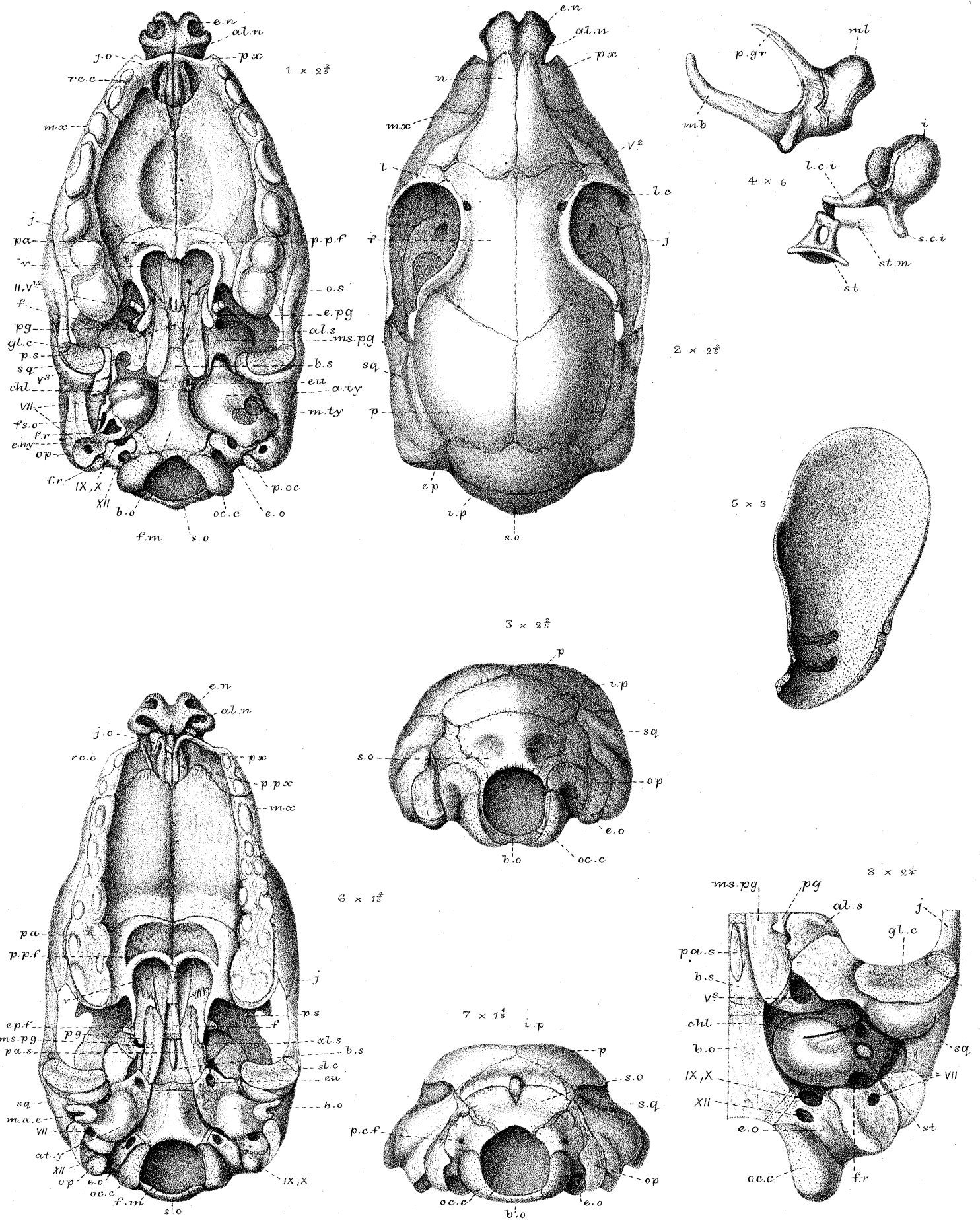
Rhynchoceyon.



West, Newman & Co imp

PLATE 37.

Figures.		Number of times magnified.
1	<i>Galeopithecus volans</i> (1st stage); embryo; $5\frac{1}{4}$ inches long; skull; lower view	$2\frac{2}{3}$
2	The same; upper view	$2\frac{2}{3}$
3	The same; end view.	$2\frac{2}{3}$
4	The same; ossicula auditûs; outer view	6
5	The same; concha auris	3
6	<i>Galeopithecus philippensis</i> (2nd stage); young; 8 inches long; skull; lower view.	$1\frac{4}{5}$
7	The same; end view.	$1\frac{4}{5}$
8	The same species (3rd stage); larger young; part of skull; lower view.	$2\frac{1}{4}$

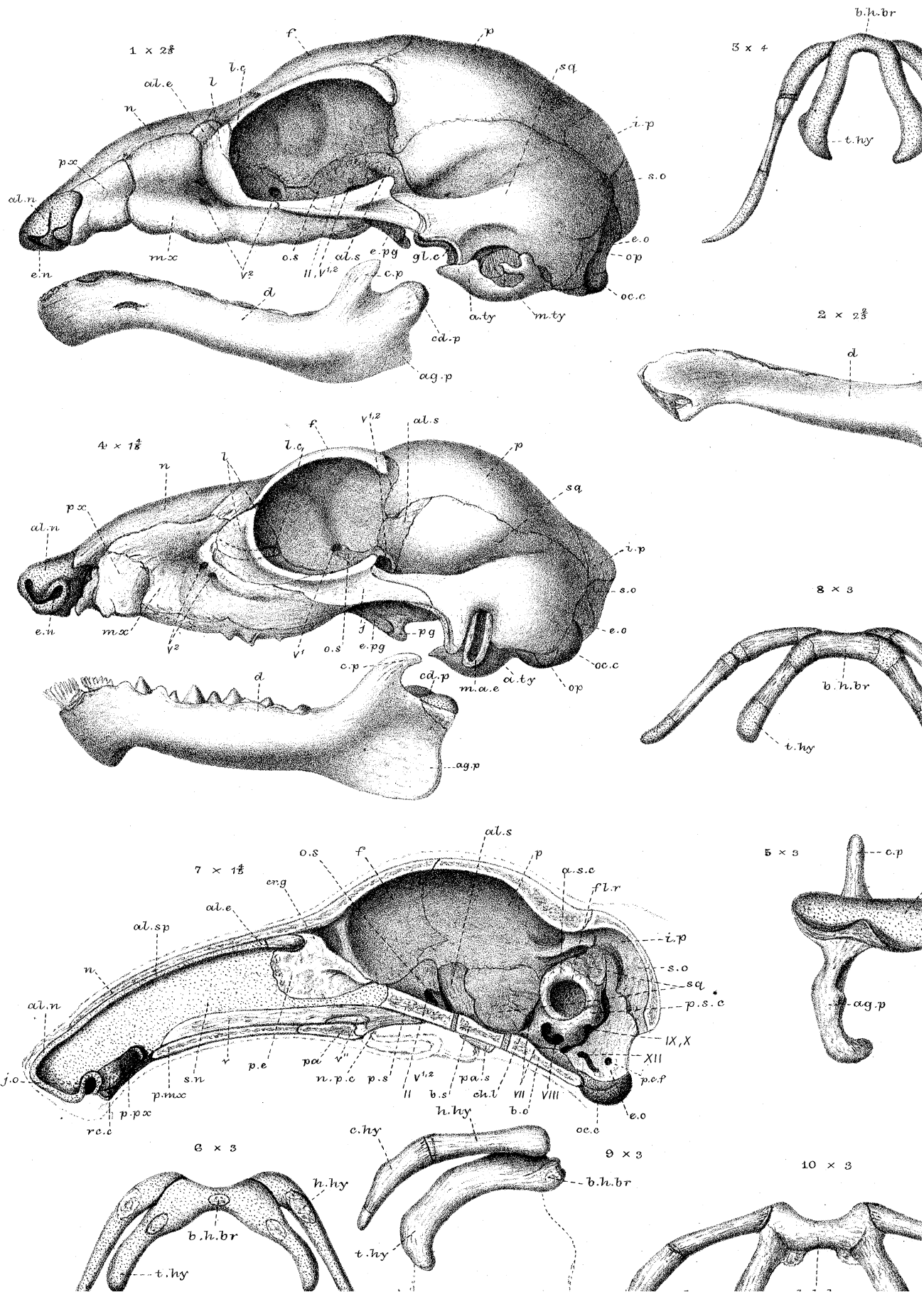


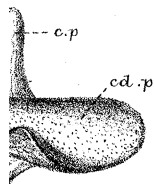
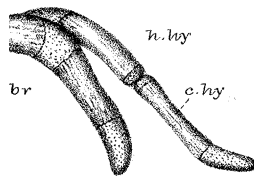
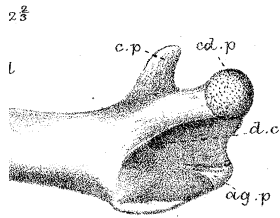
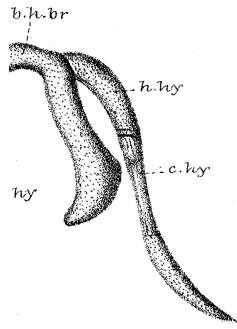
W.K.P. del. ad. vas.
Parker & Coward lith.

West, Newman & Co's imp.

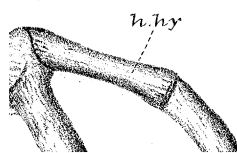
PLATE 38.

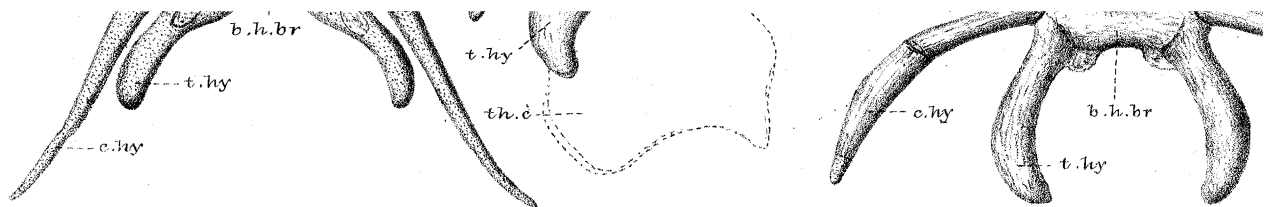
Figures.		Number of times magnified.
1	<i>Galeopithecus volans</i> (1st stage); embryo; $5\frac{1}{4}$ inches long; skull; side view	$2\frac{2}{3}$
2	The same; lower jaw; inner view	$2\frac{2}{3}$
3	The same; hyoid arch; upper view	4
4	<i>Galeopithecus philippensis</i> (2nd stage); young; 8 inches long; skull; side view	$1\frac{4}{5}$
5	The same; lower jaw; end view.	3
6	The same; hyoid arch; upper view	3
7	Same species (3rd stage); section of skull	$1\frac{4}{5}$
8	The same; hyoid arch; upper view.	3
9	Same species (4th stage); adult; hyoid arch; side view	3
10	The same; upper view	3





ag.p

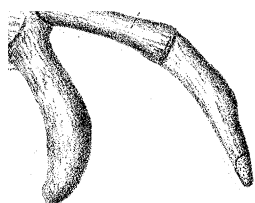




W.K.F. del. ad nat.
Parker & Coward lith.

Galeopithecus.

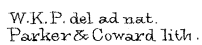
We

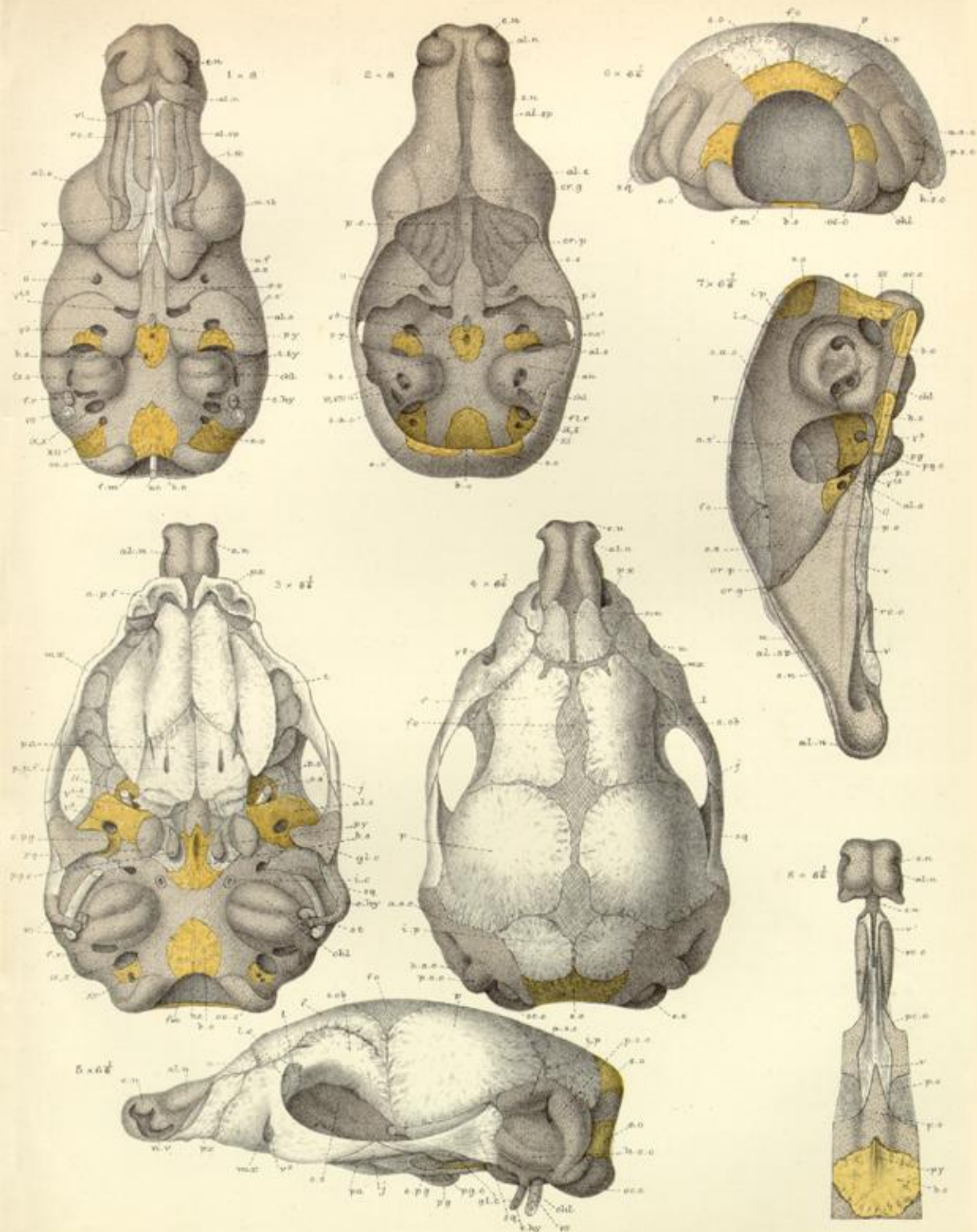


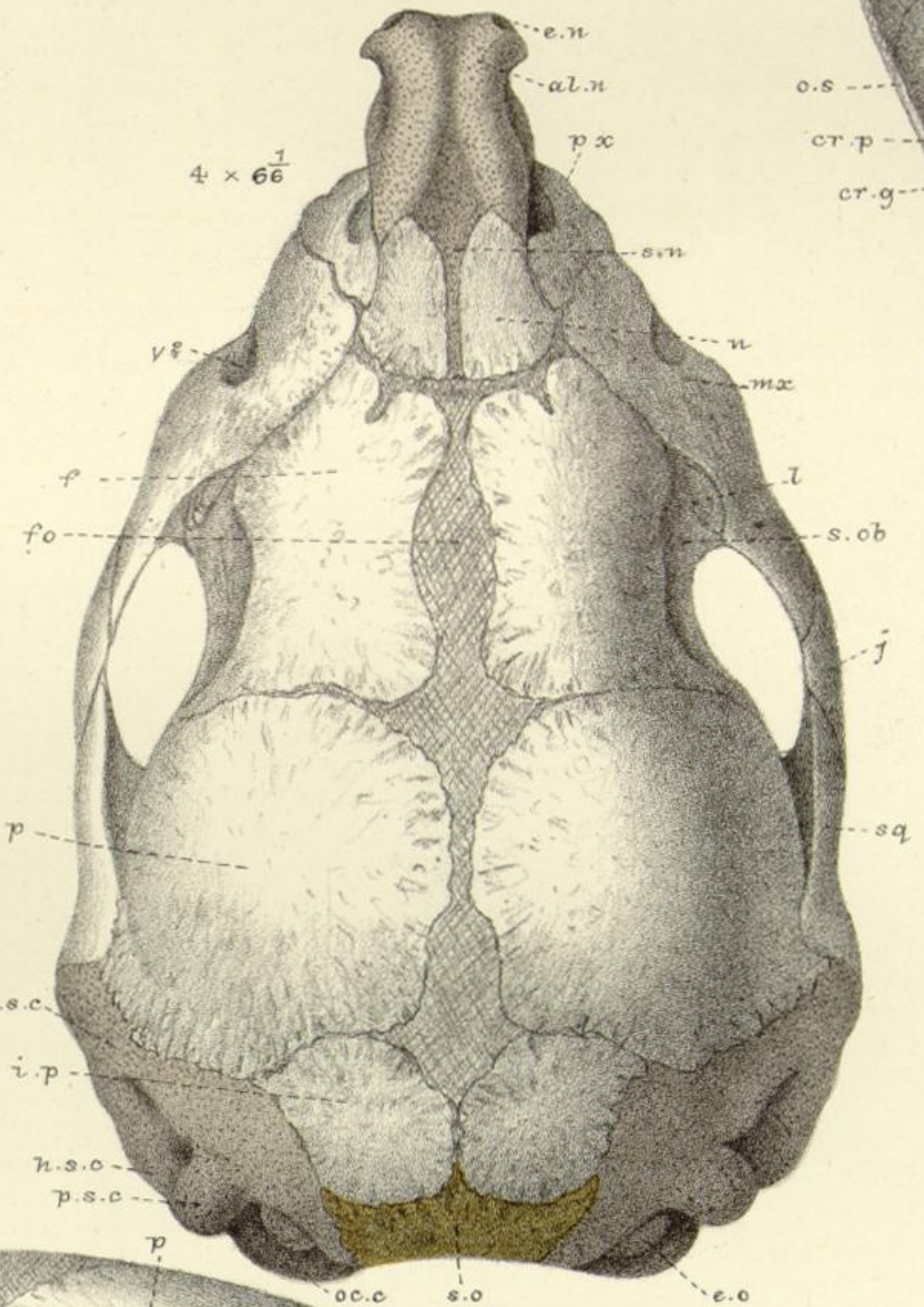
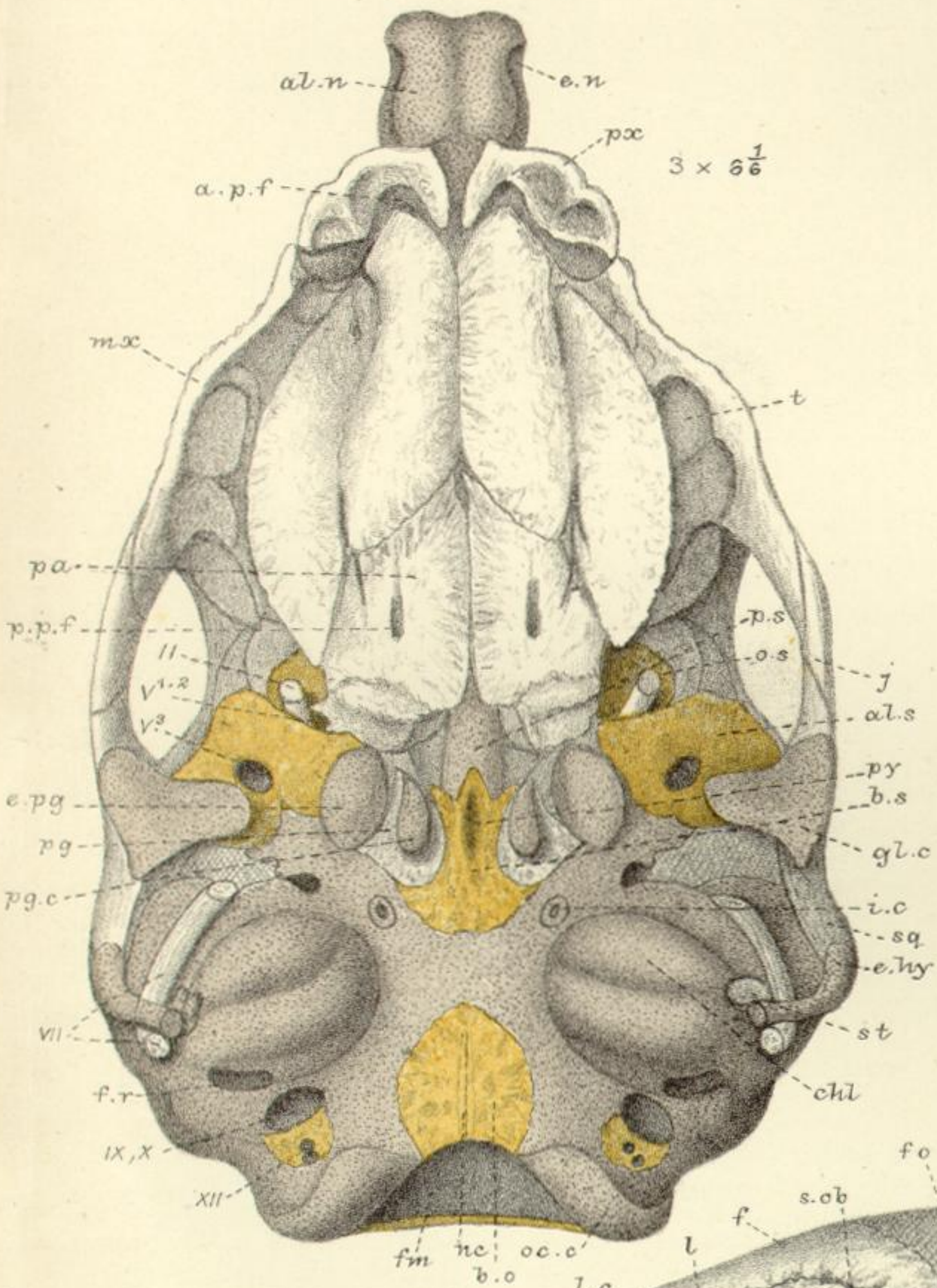
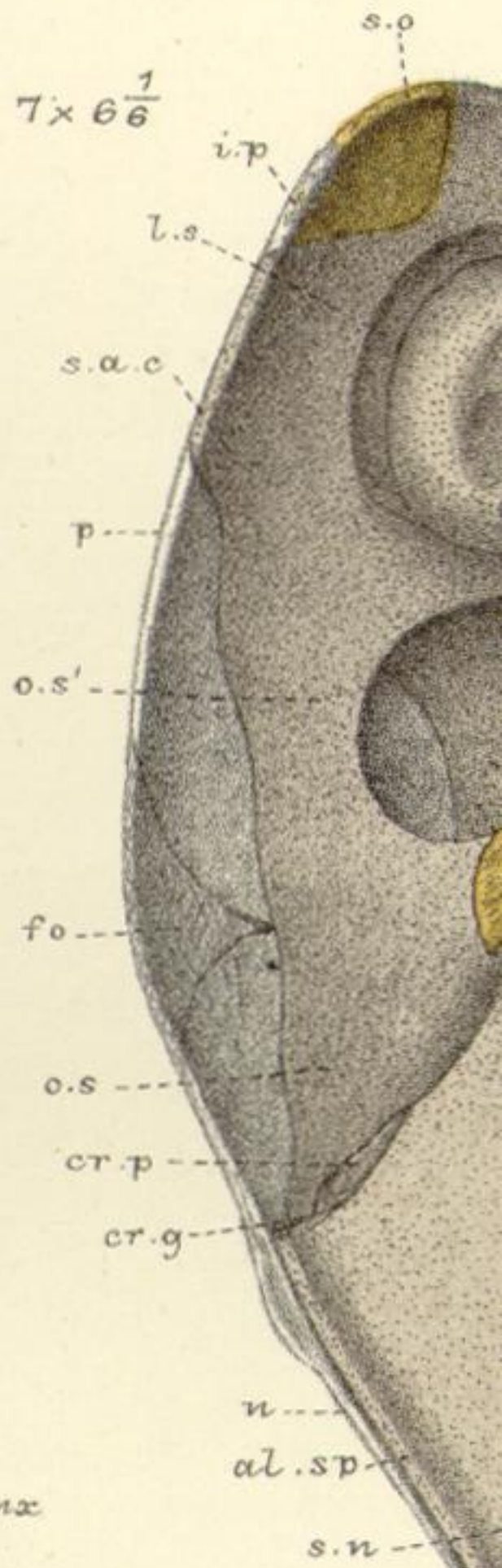
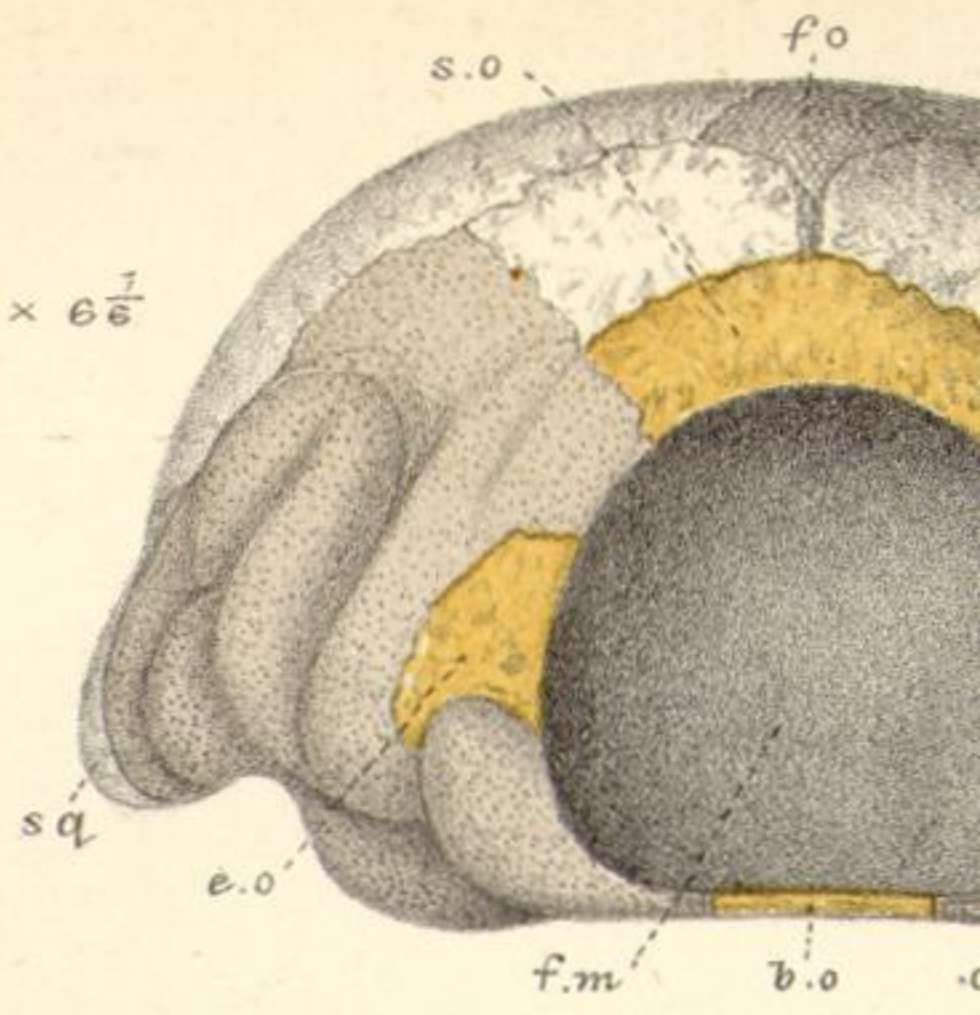
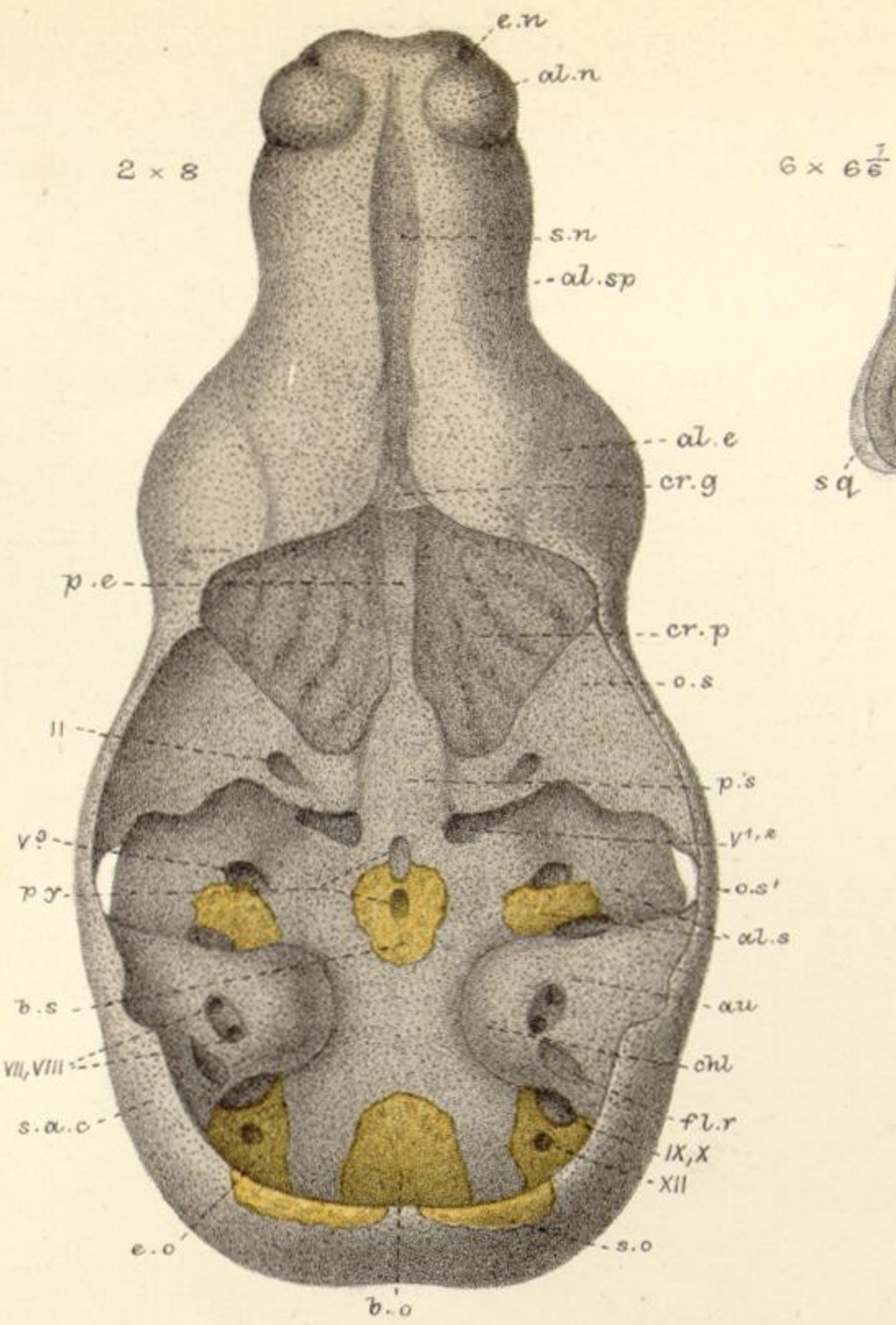
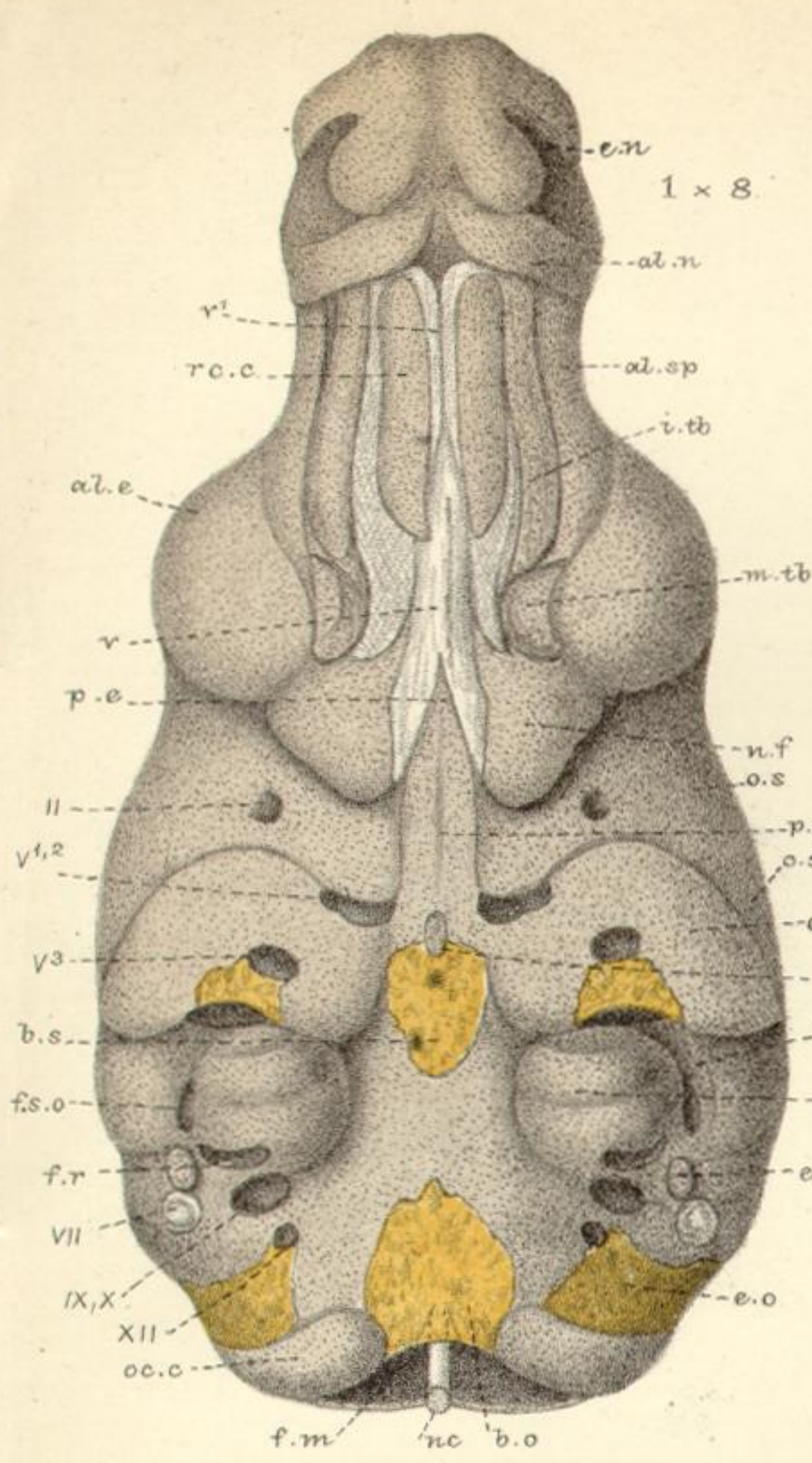
West, Newman & Co. imp.

PLATE 39.

Figures.		Number of times magnified.
1	<i>Galeopithecus volans</i> (1st stage); endocranium; lower view	$2\frac{2}{3}$
2	The same; upper view	$2\frac{2}{3}$
3	<i>Galeopithecus philippensis</i> (4th stage); adult; section of skull	$1\frac{1}{2}$
4	The same; end view.	$1\frac{1}{2}$
5	The same; front view	2
6	The same; vertical section of temporal region	3
7	The same; ossicula auditûs; outer view	8
8	The same; lower view of skull, with part sawn away. .	3

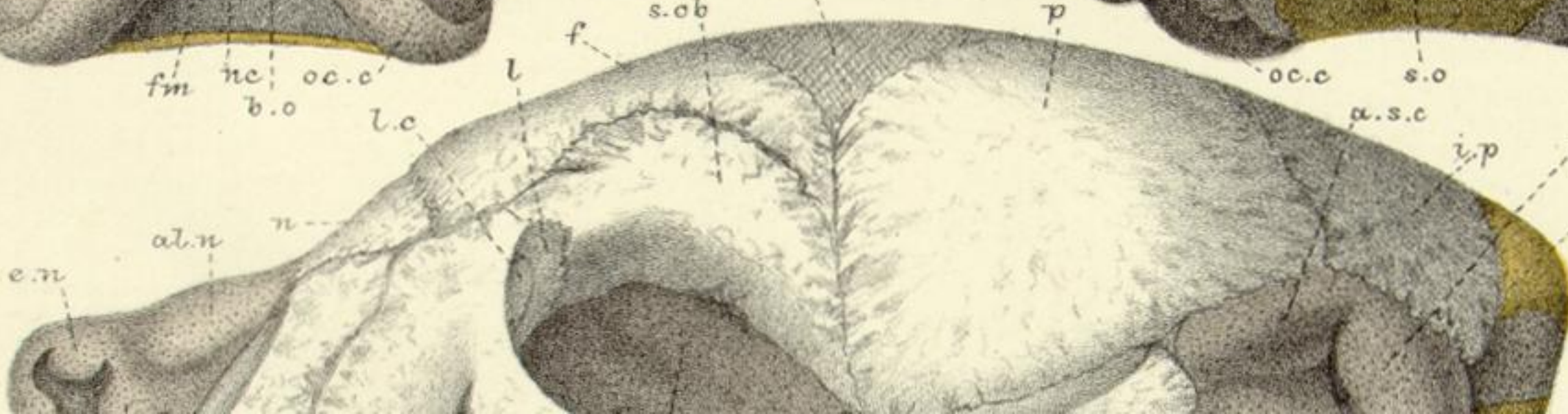


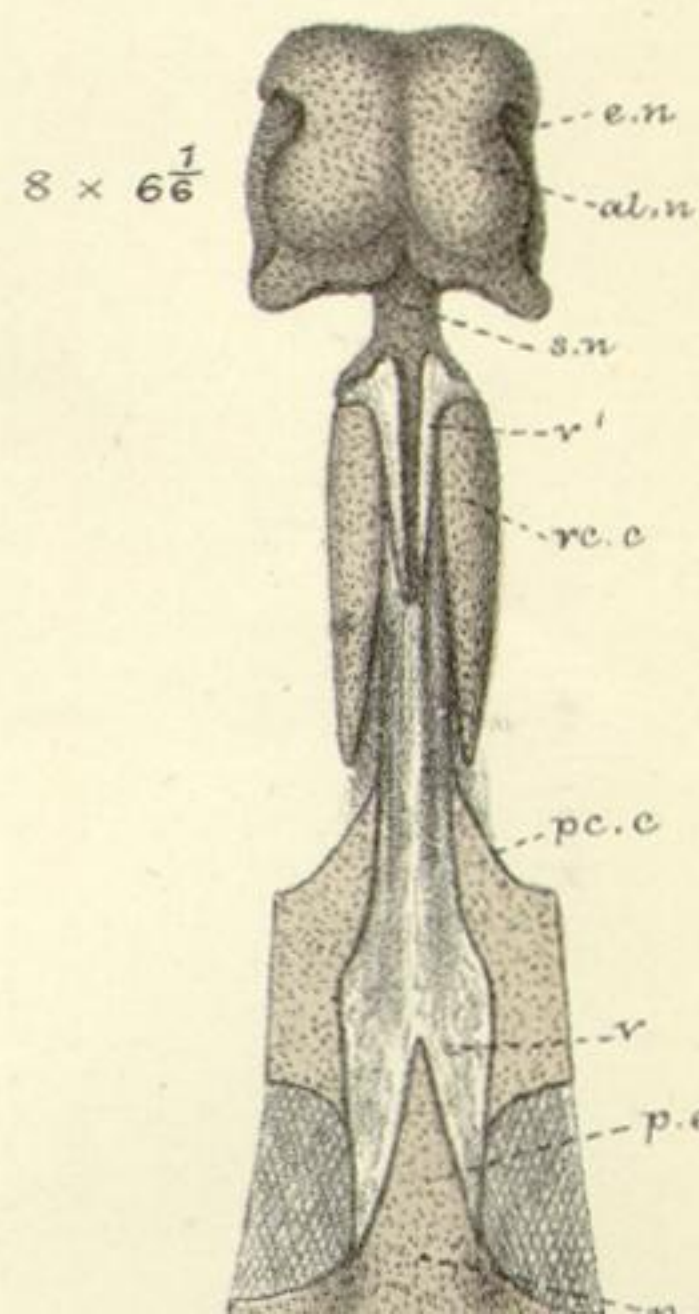
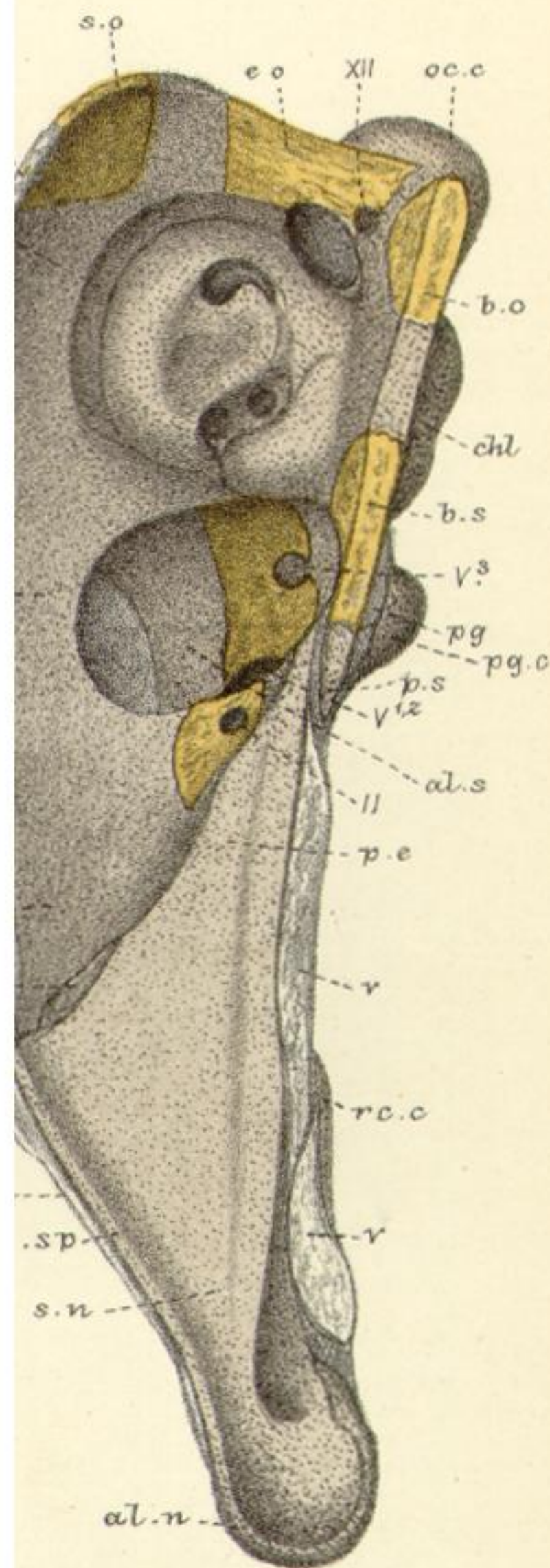
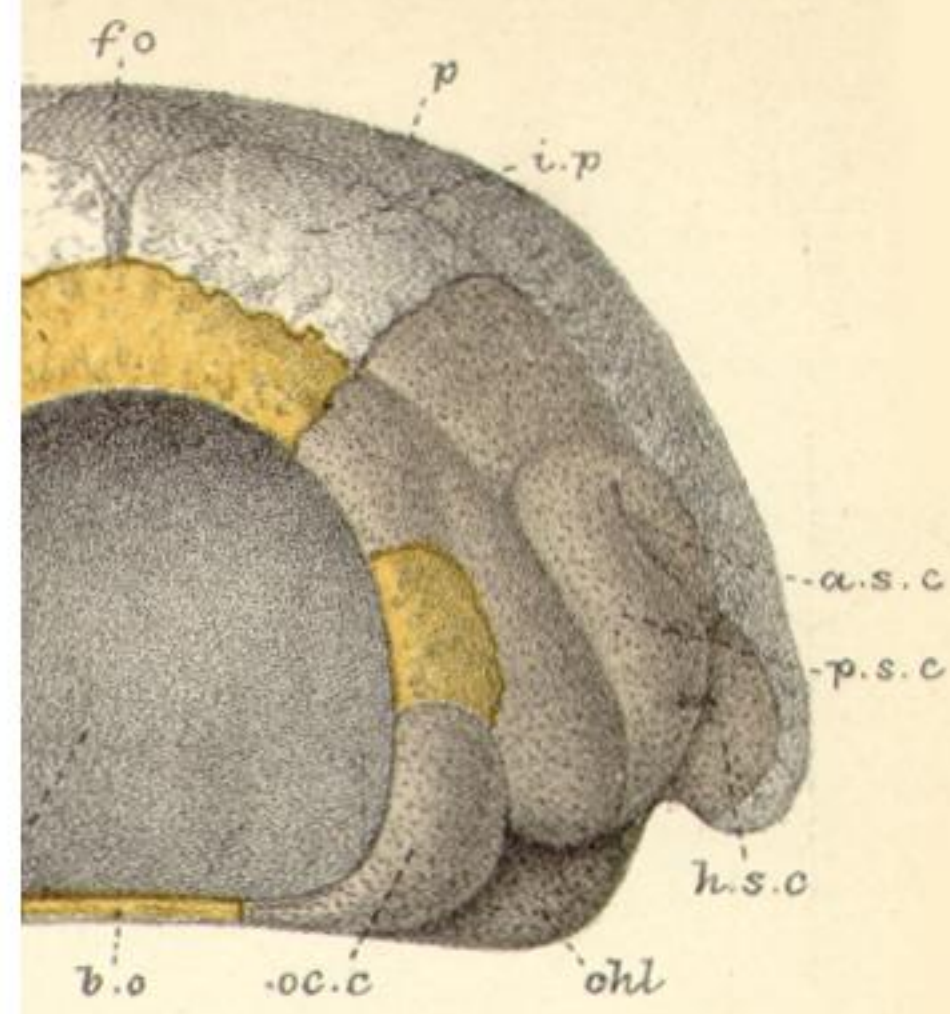




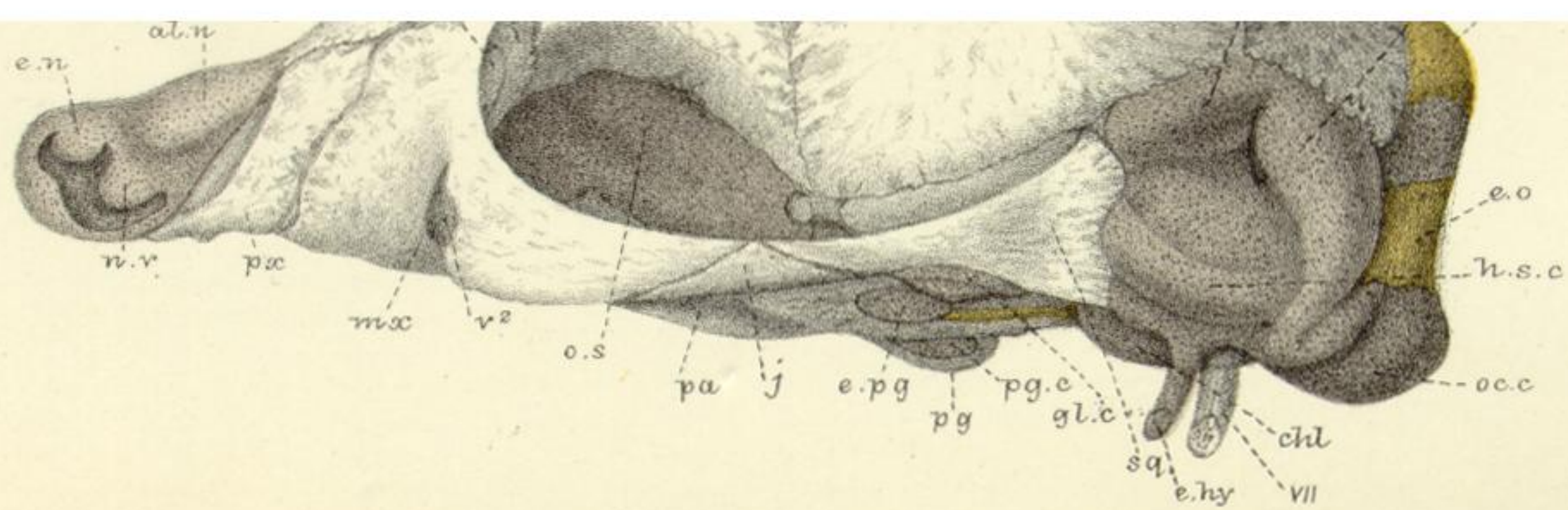
8 x 6 $\frac{1}{6}$

5 x 6 $\frac{1}{6}$



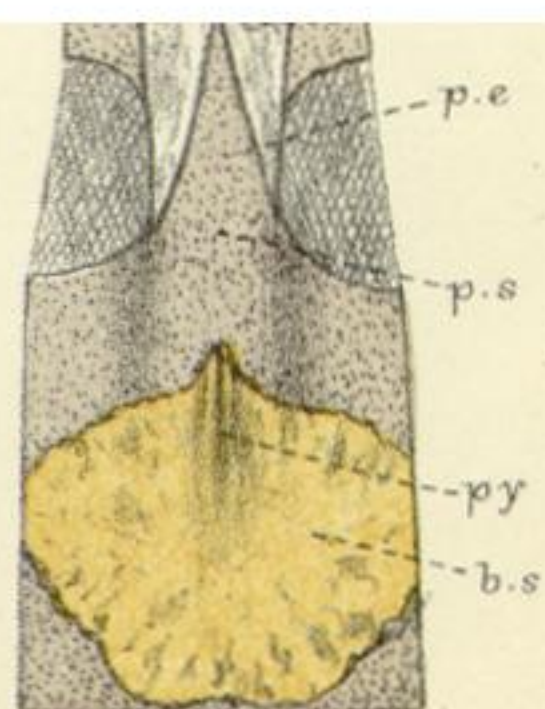


5 x 6 6




W.K.P. del. ad nat.
Parker & Coward lith.

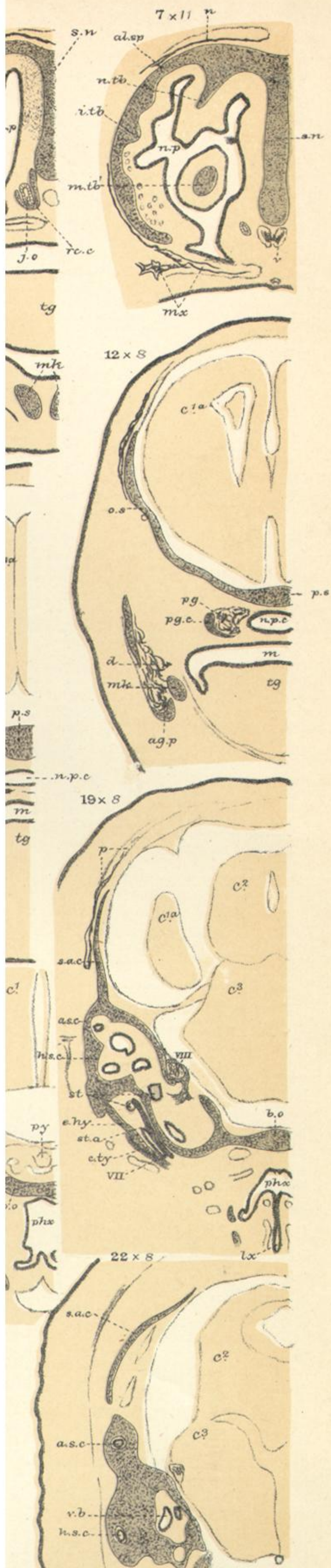
Erinaceus.

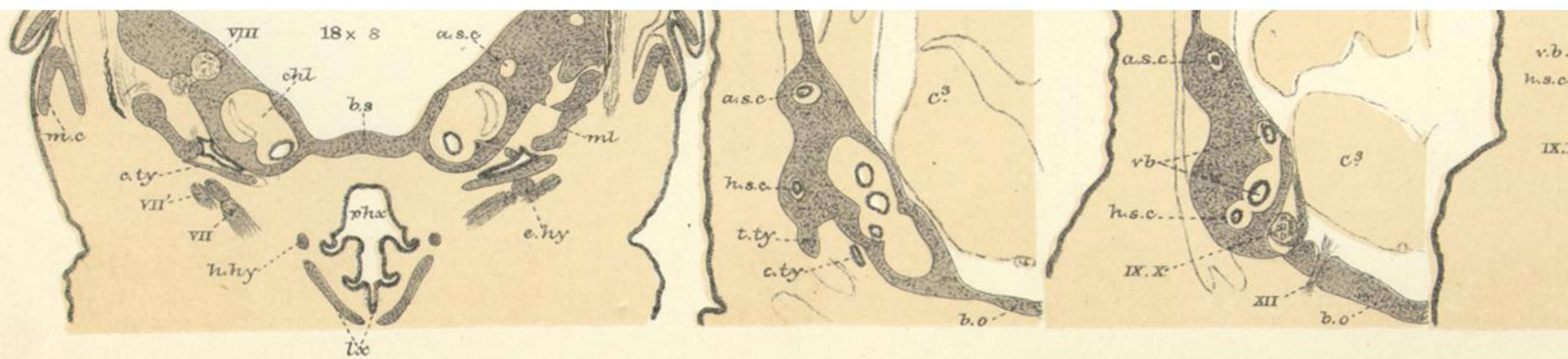


West, Newman & Co imp.



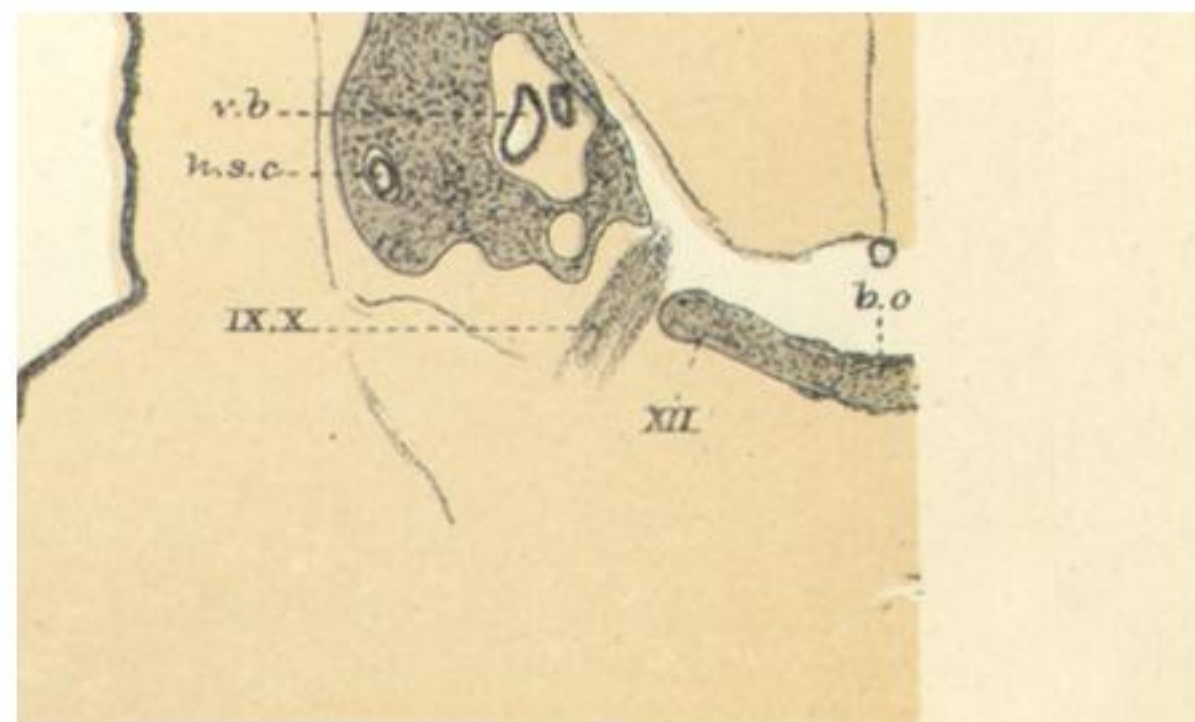




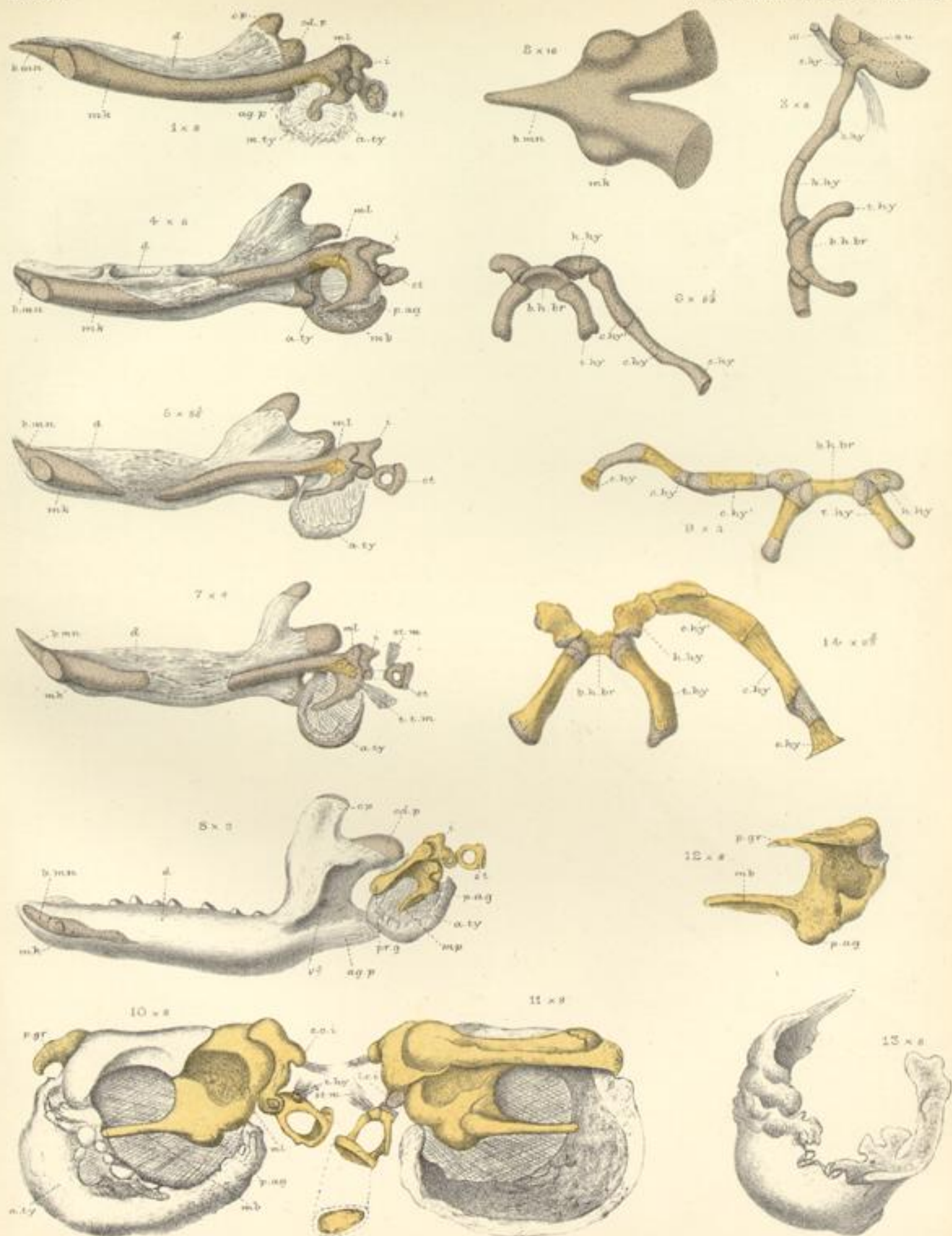


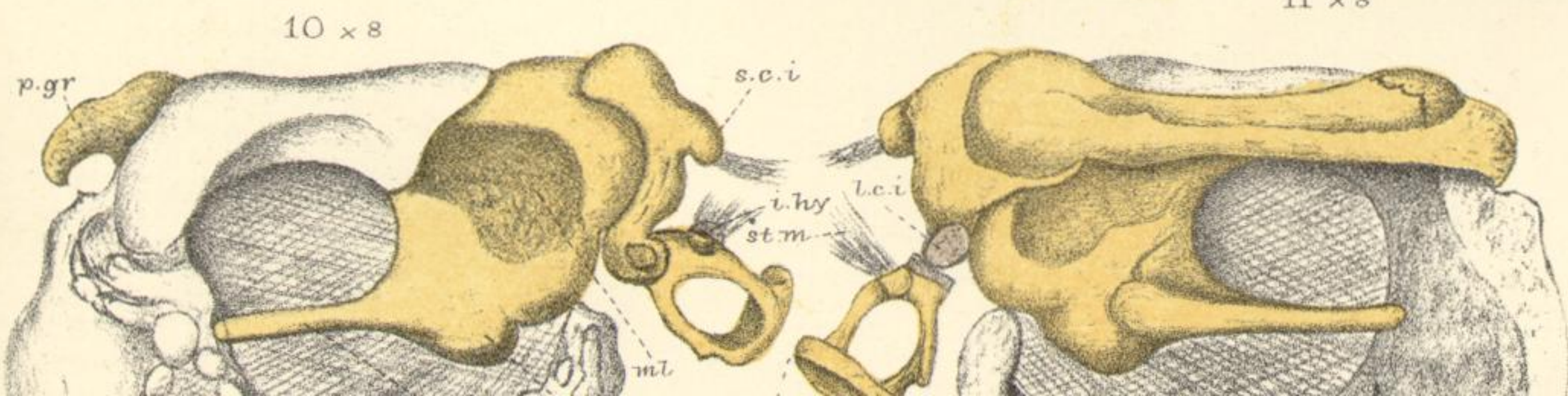
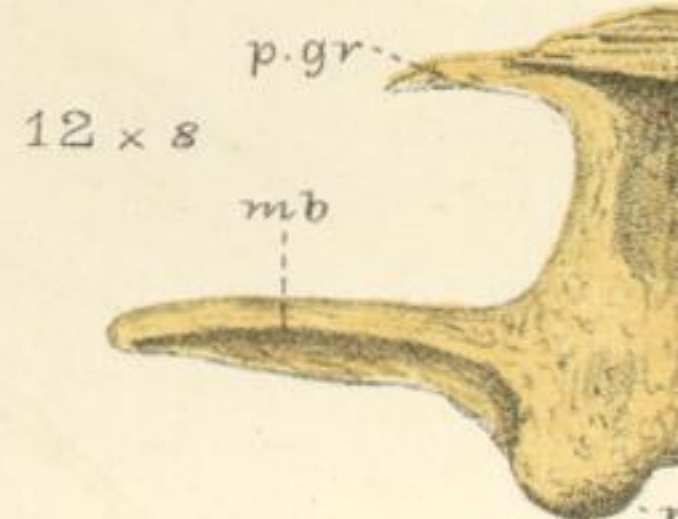
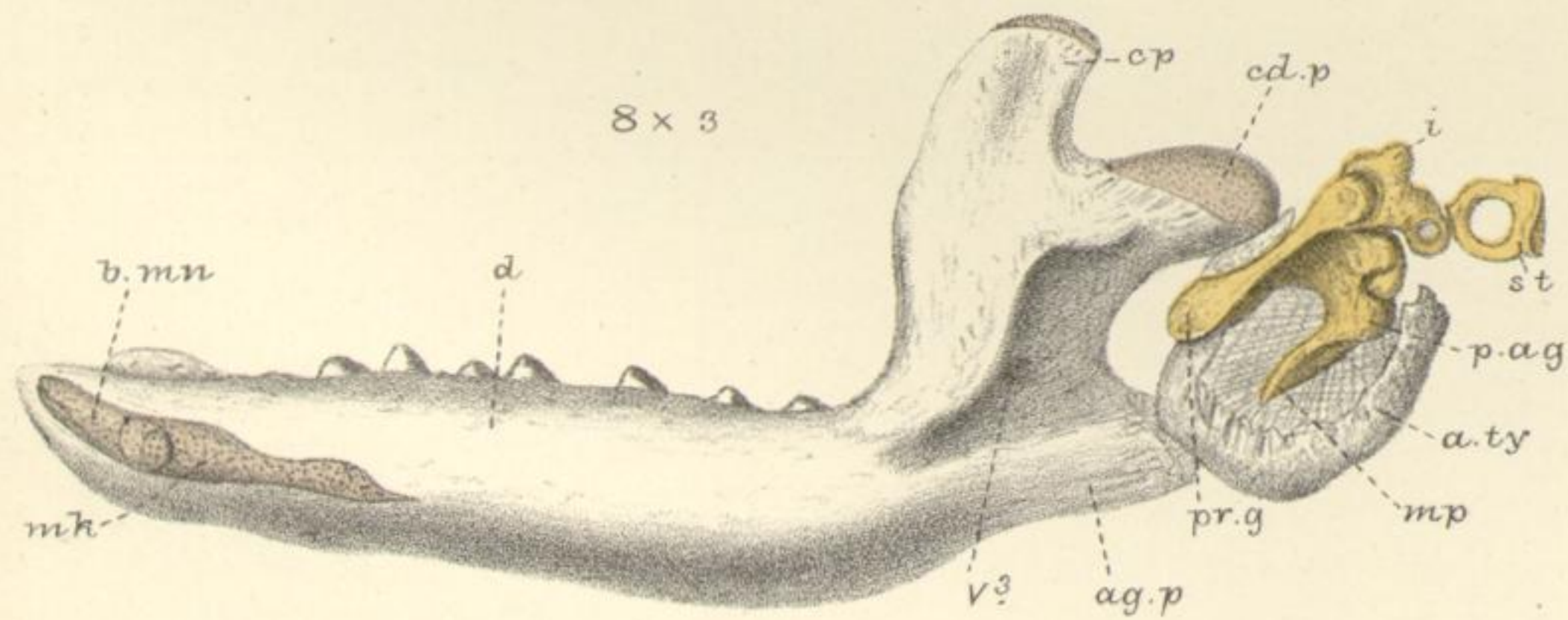
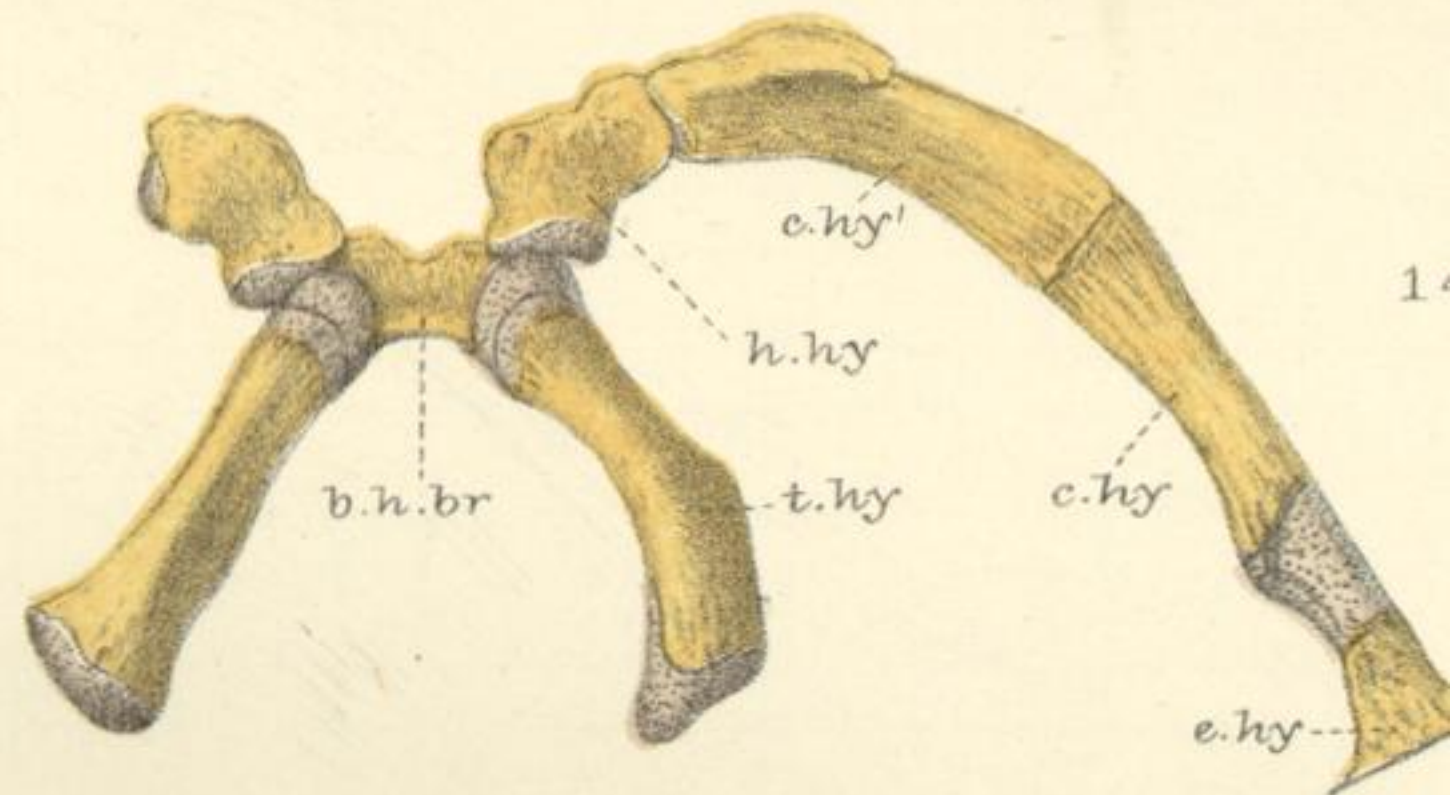
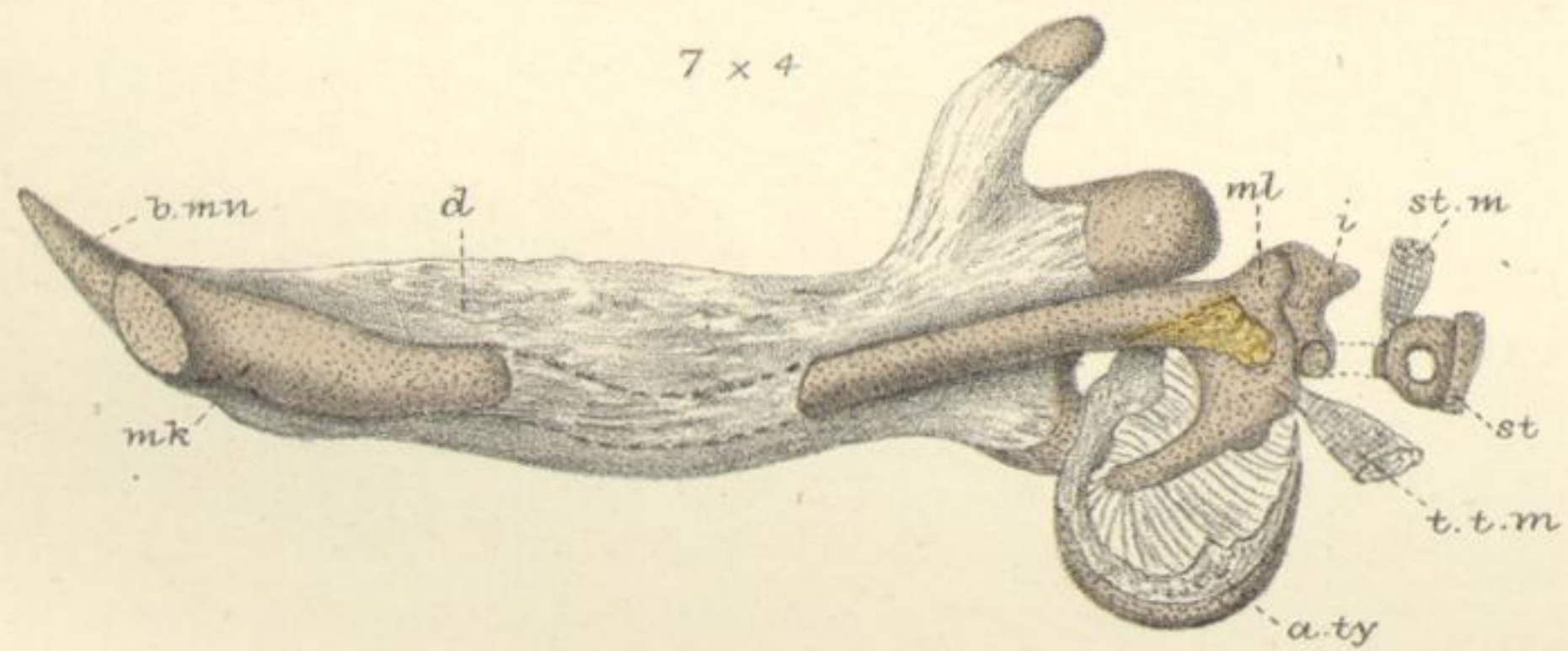
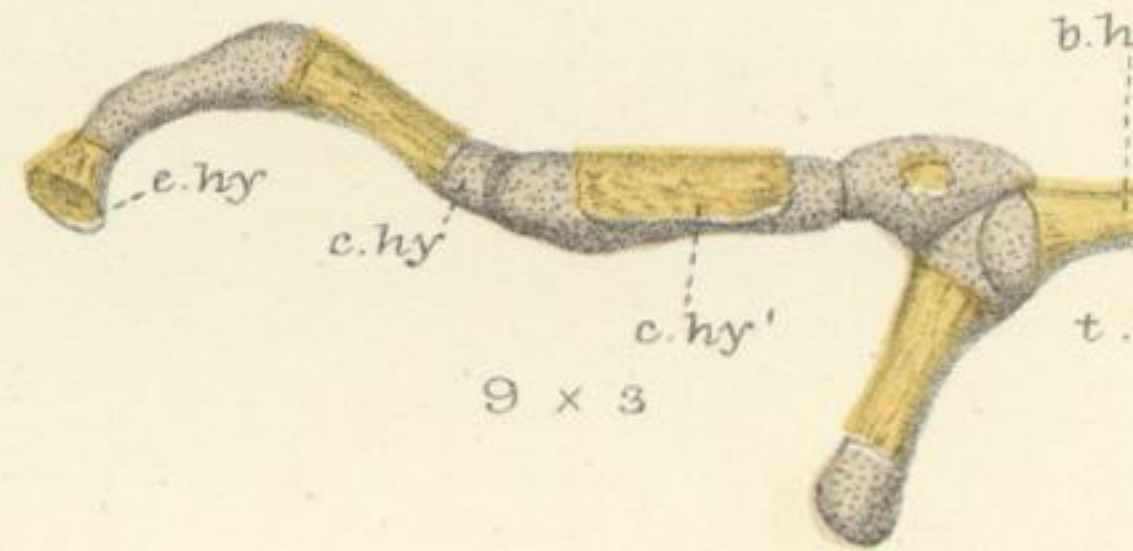
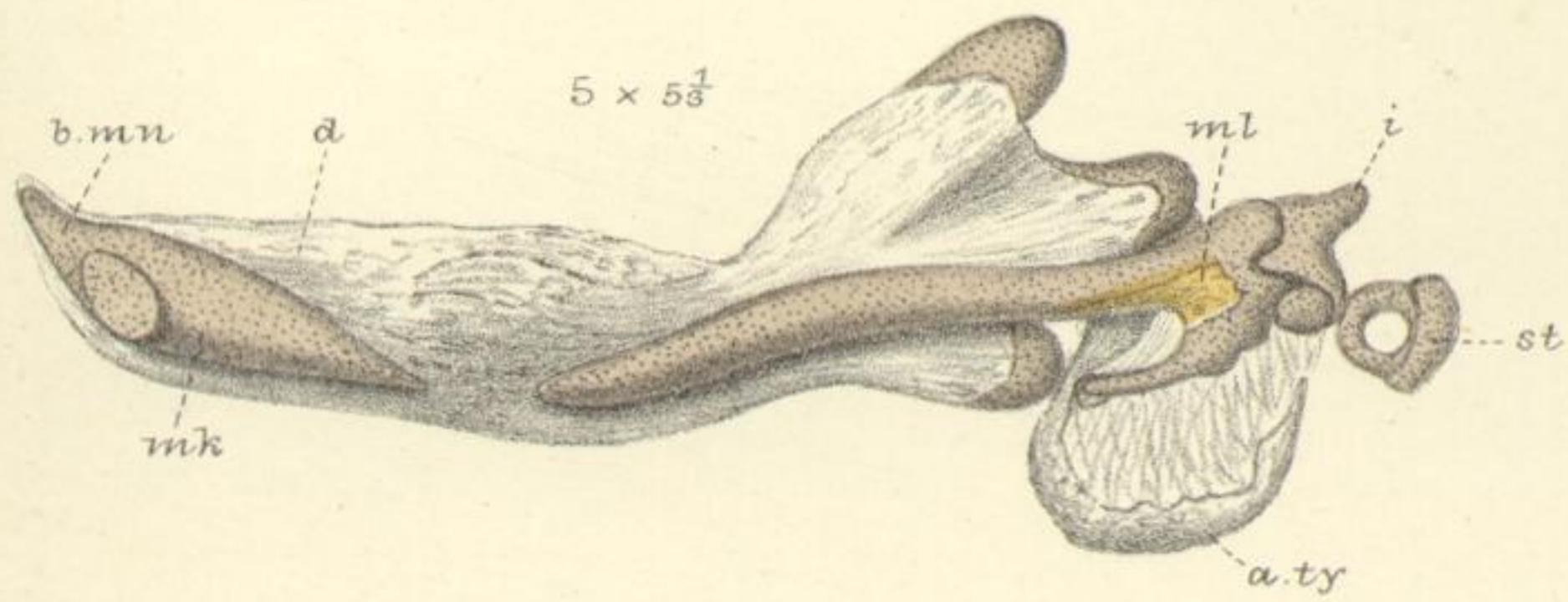
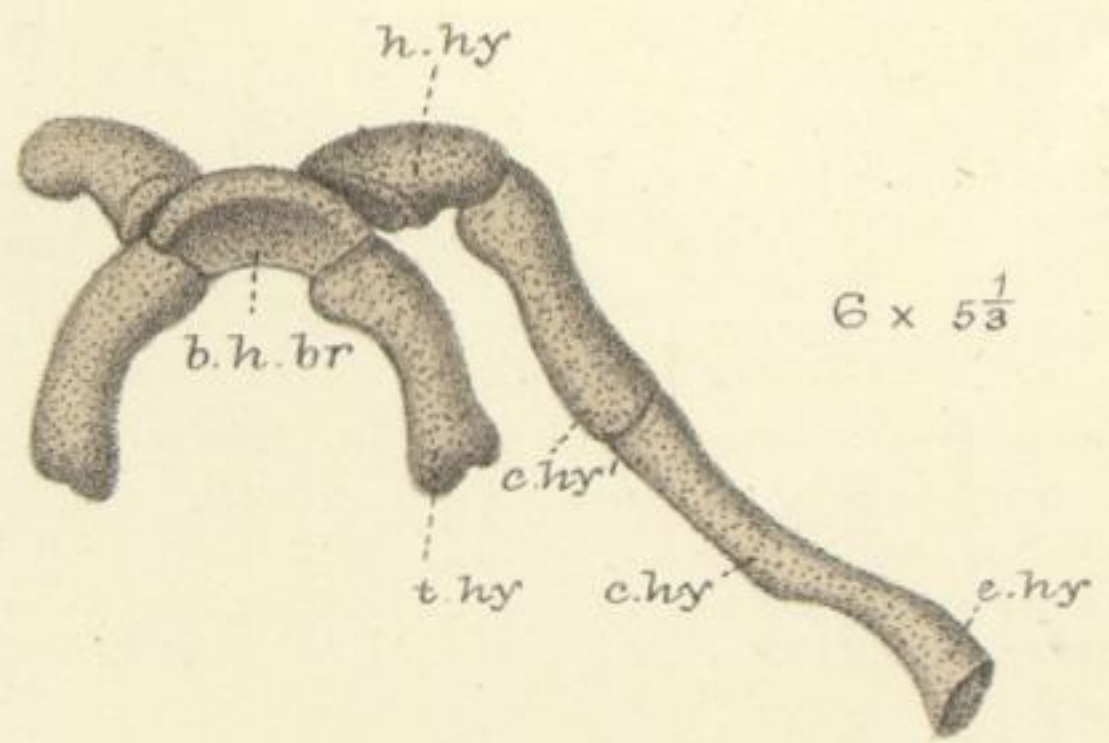
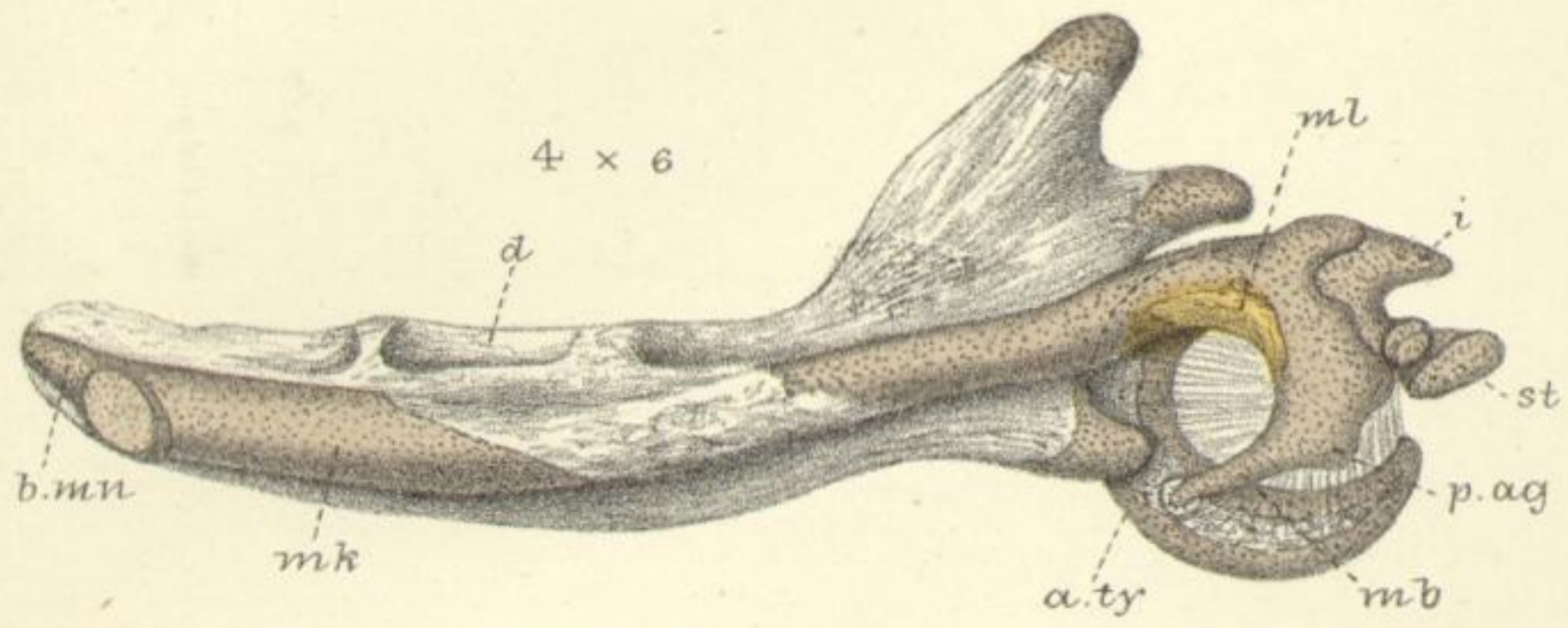
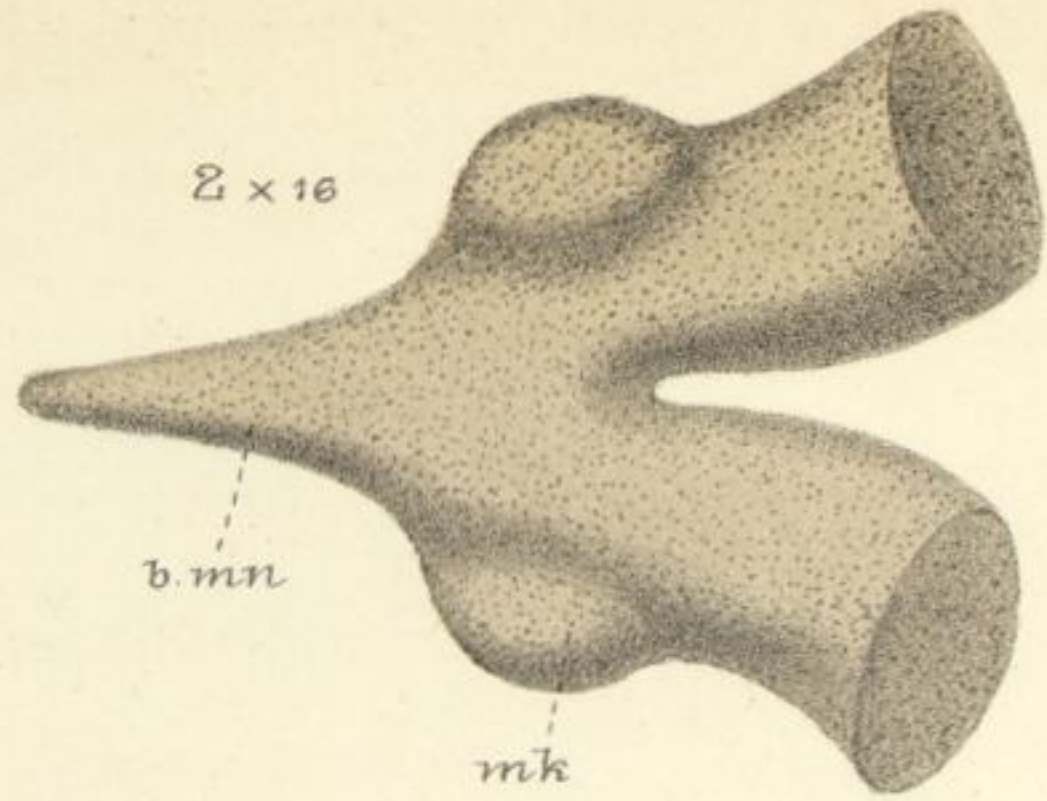
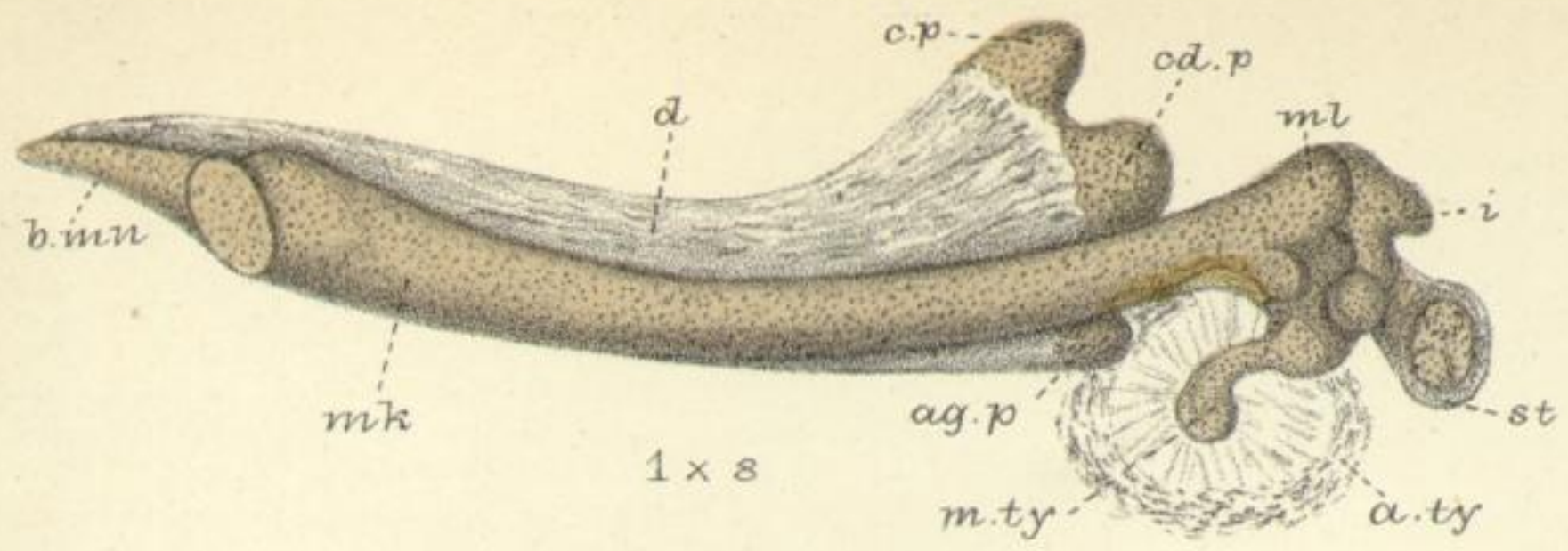
Parker & Coward del. et lith.
W.K.P. dir.

Erinaceus.

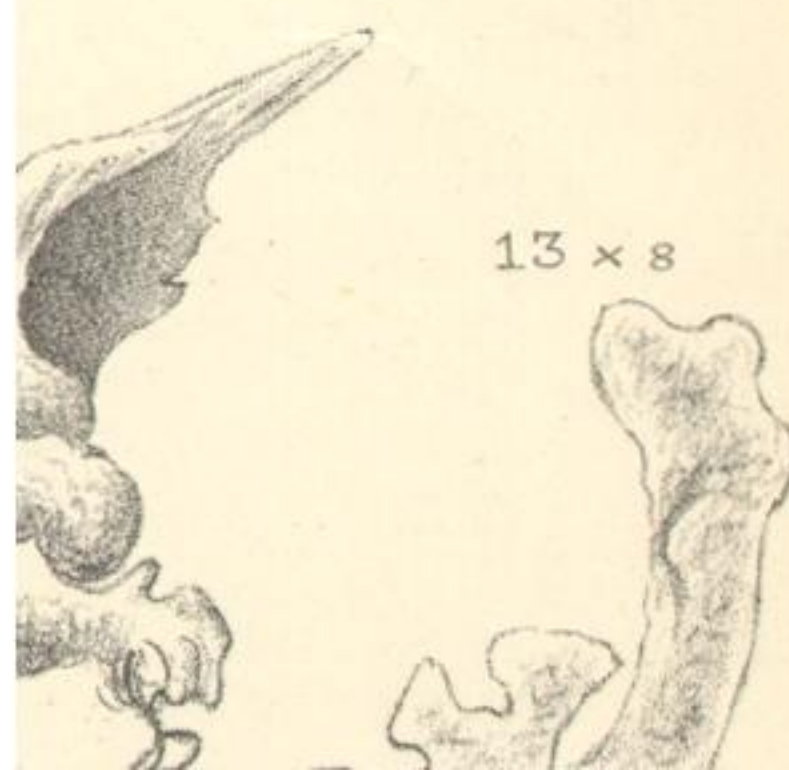
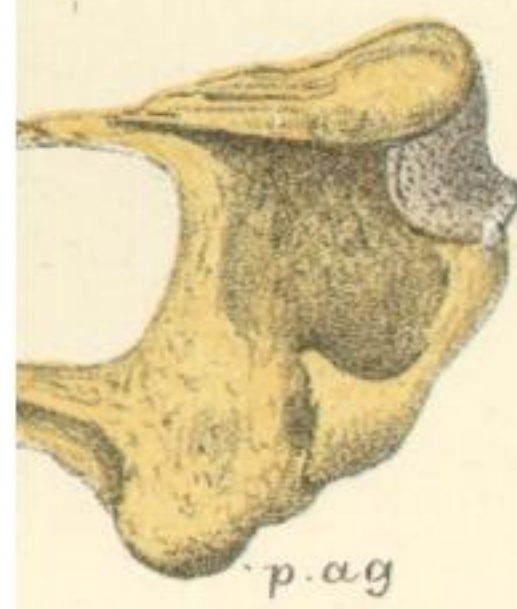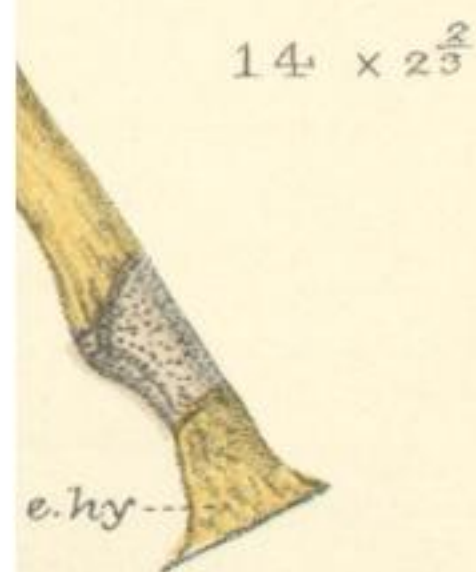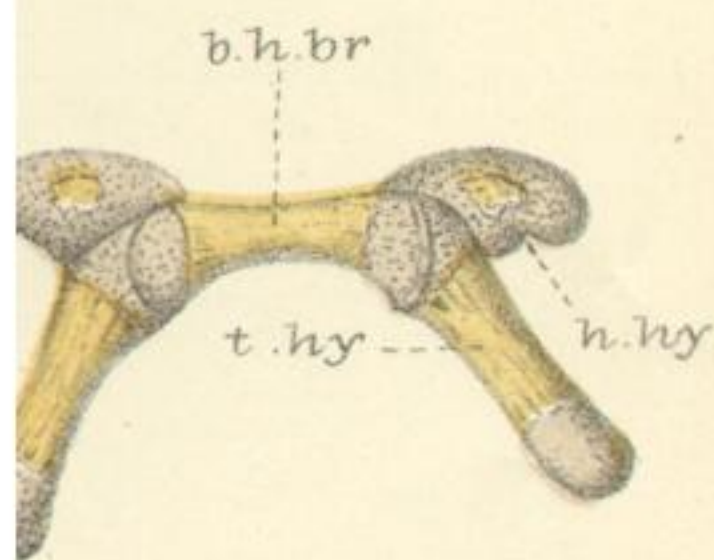
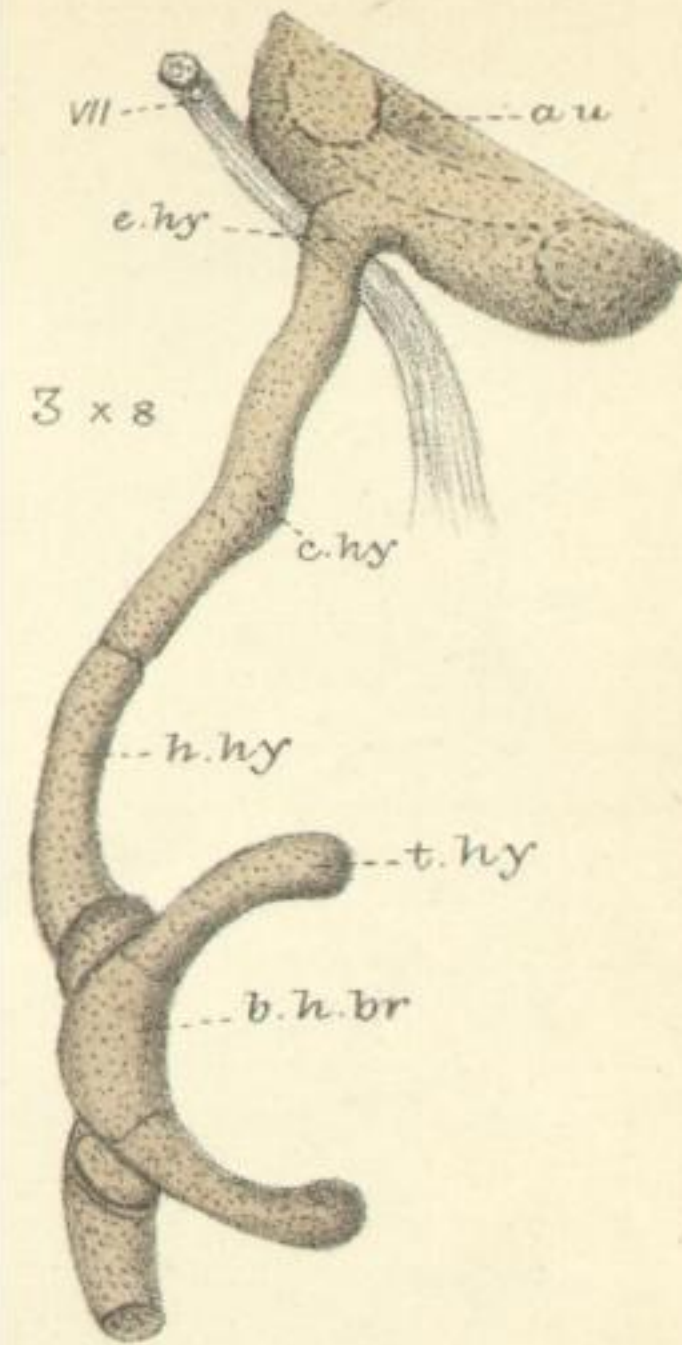


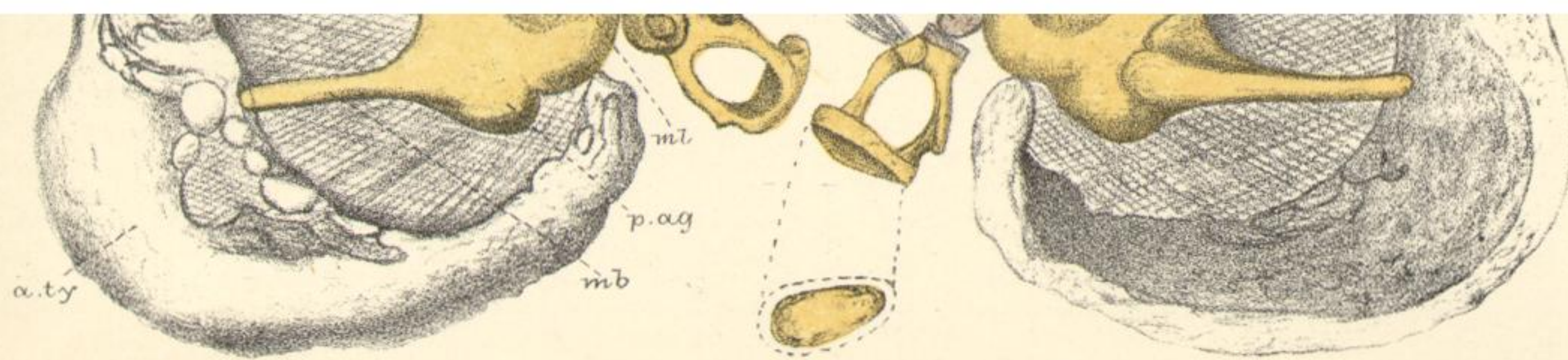
West Newman & Co imp.





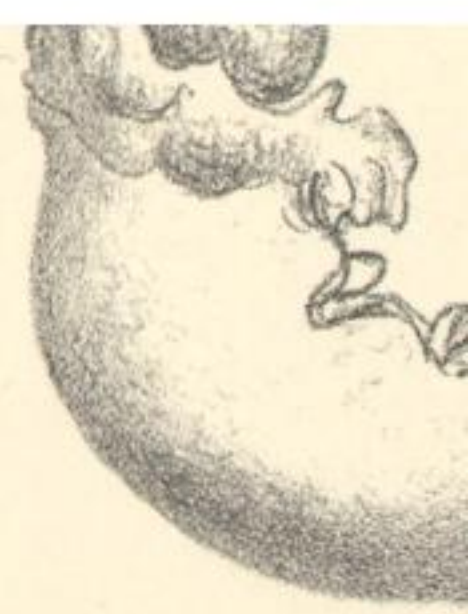11 x 8



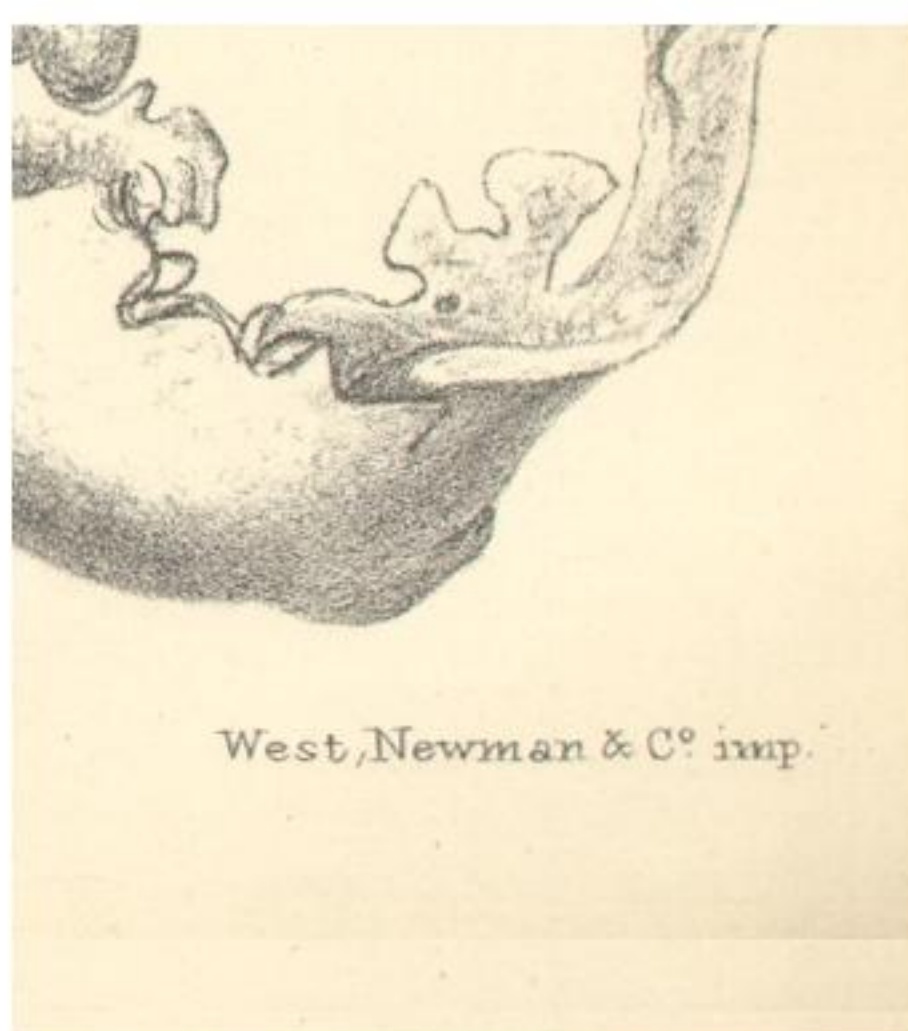


W.K.P. del.
Parker & Coward lith.

Erinaceus.




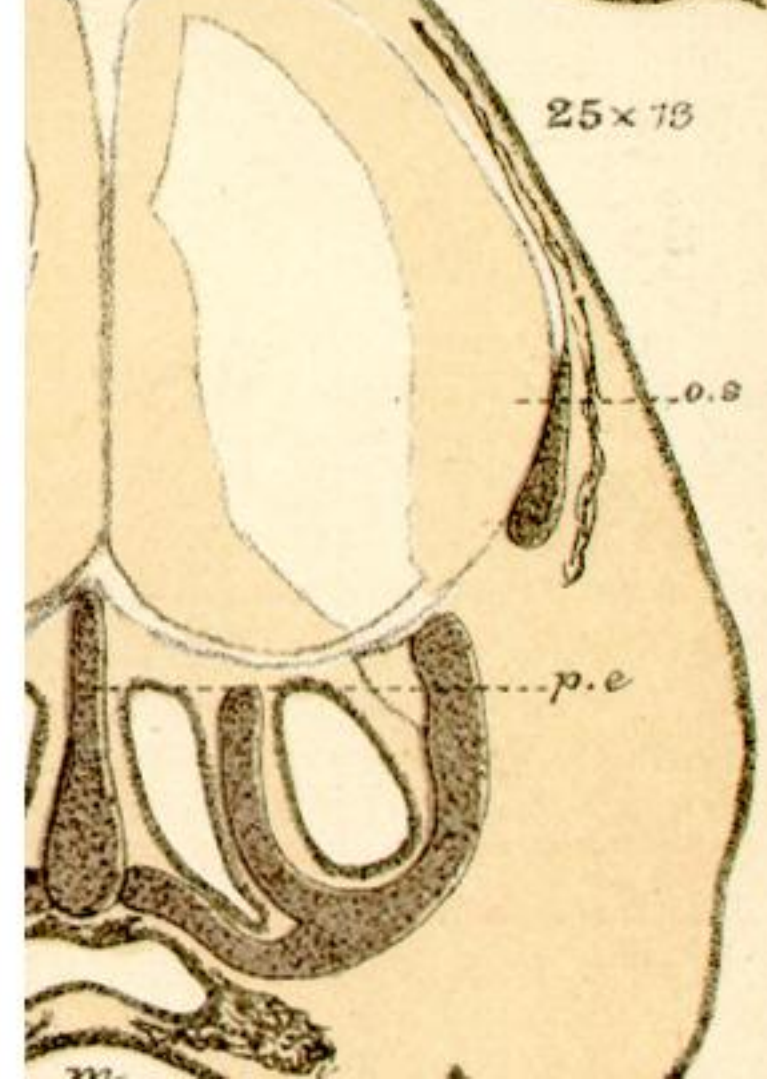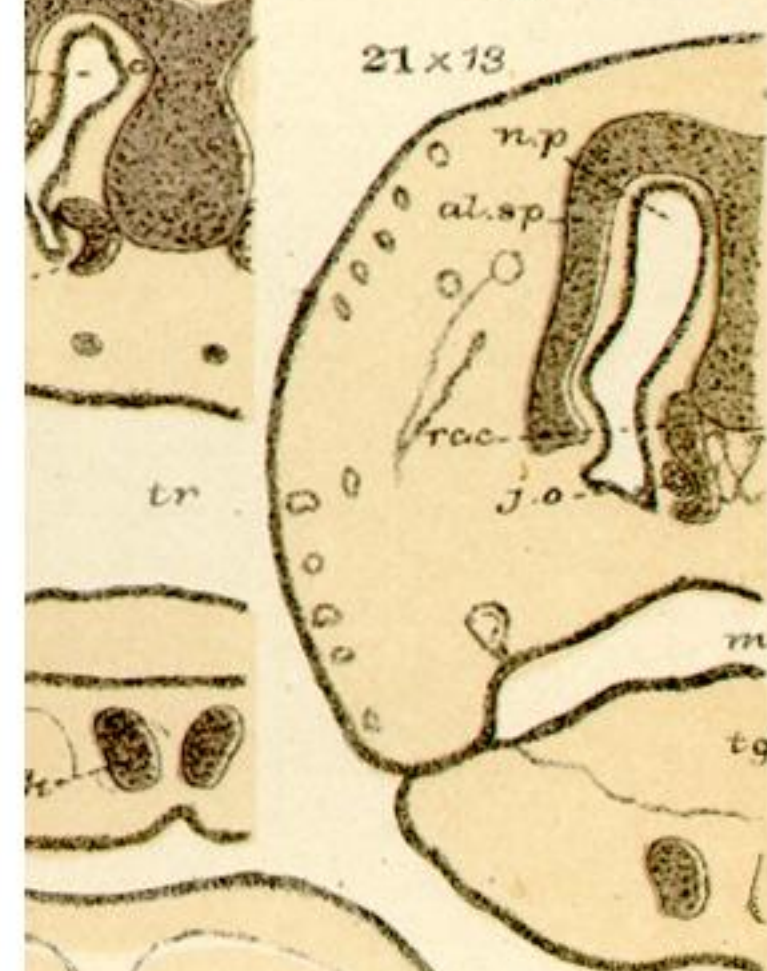
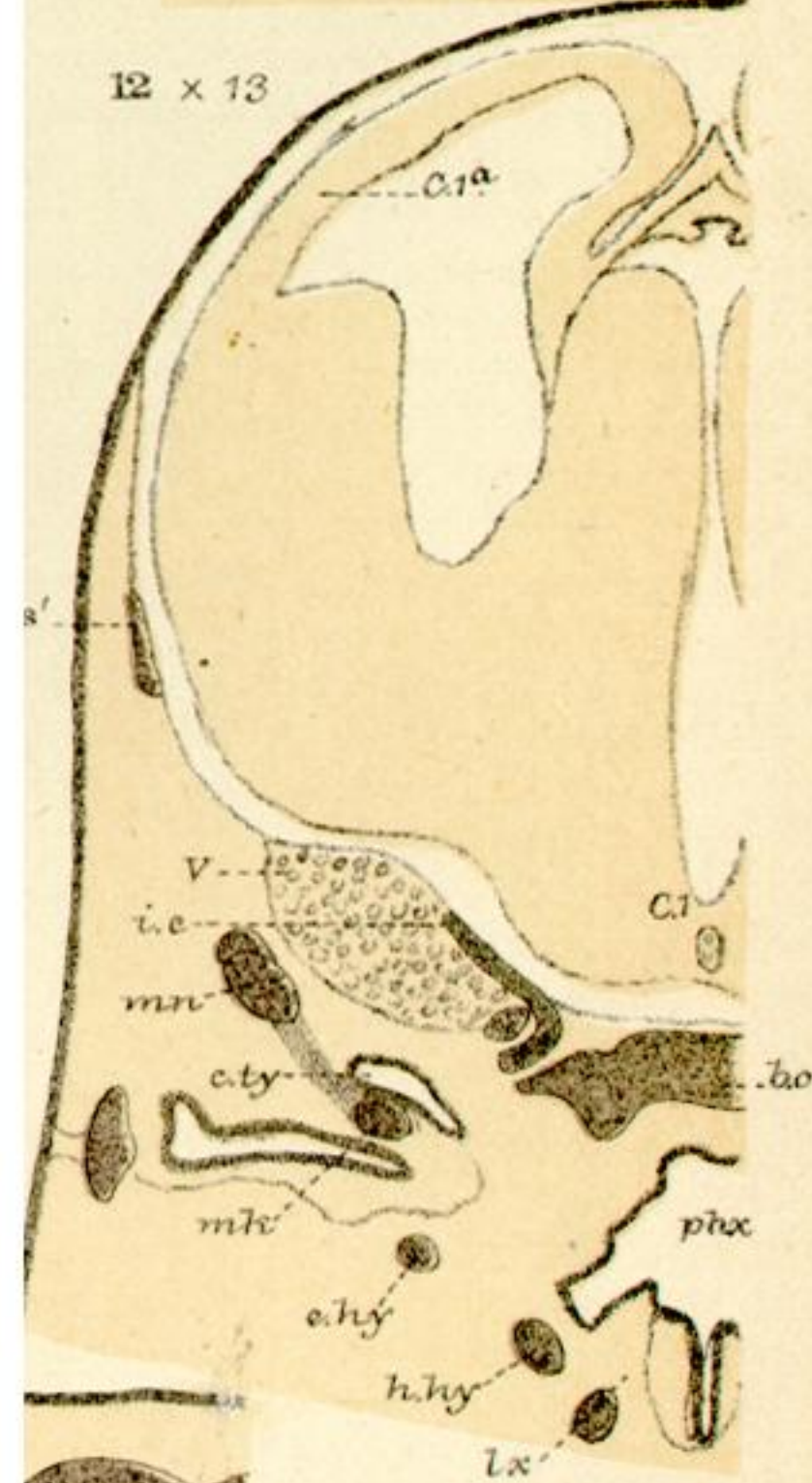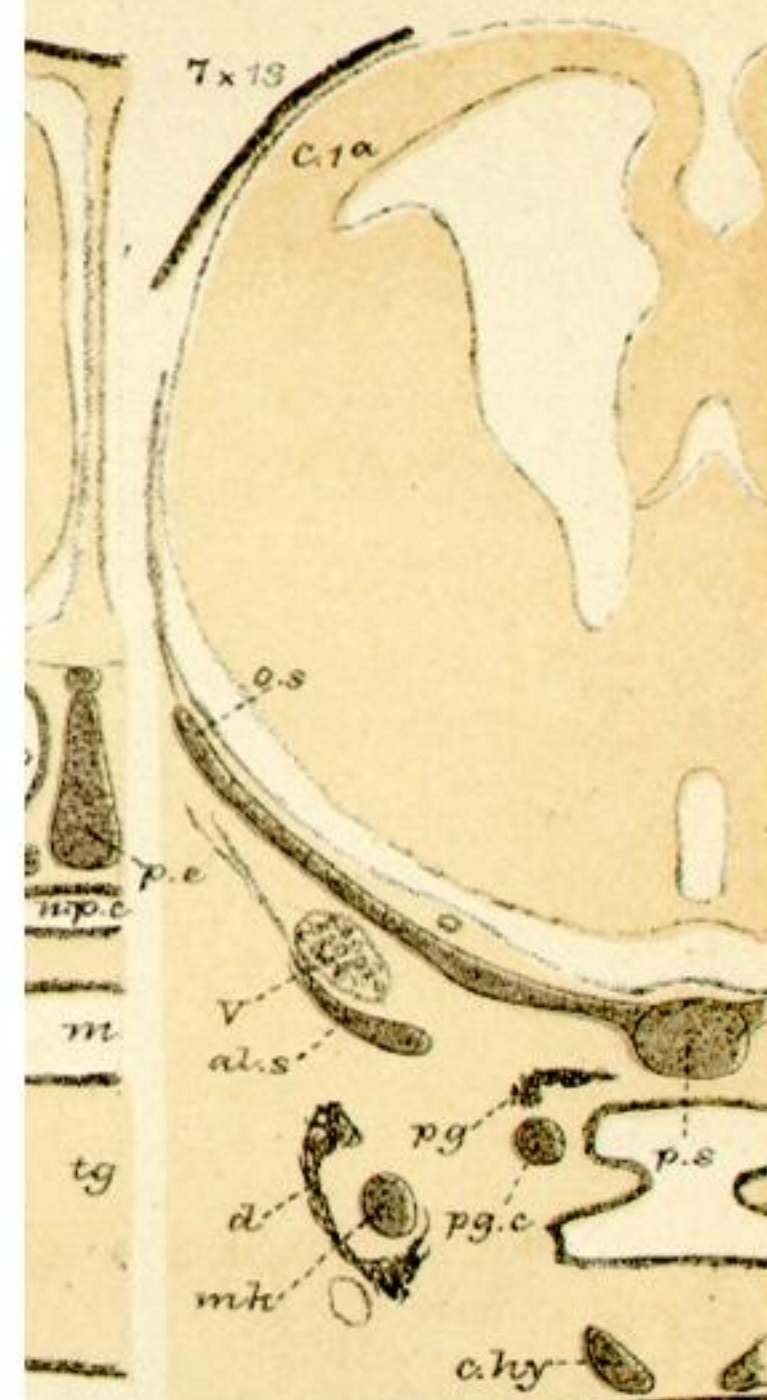
We

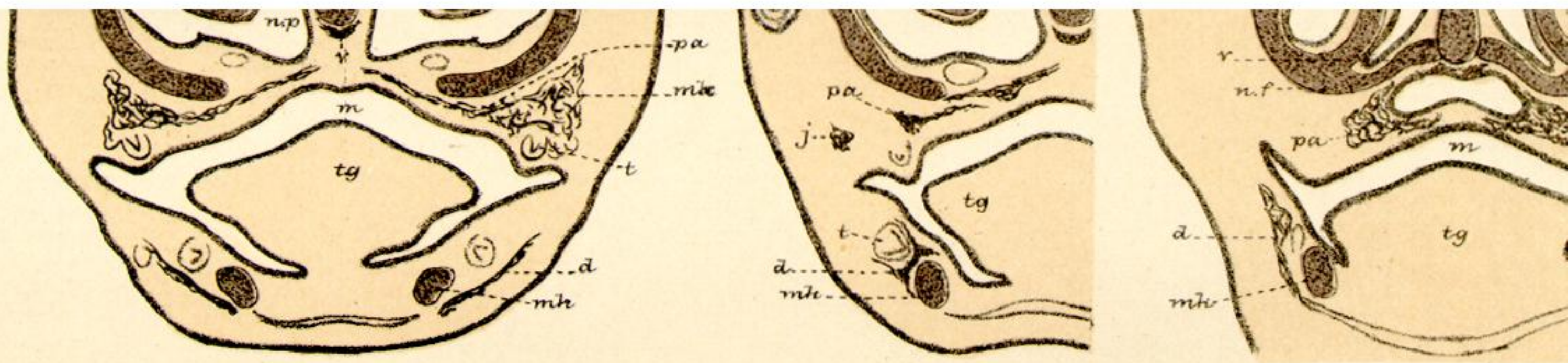


West, Newman & C^o imp.





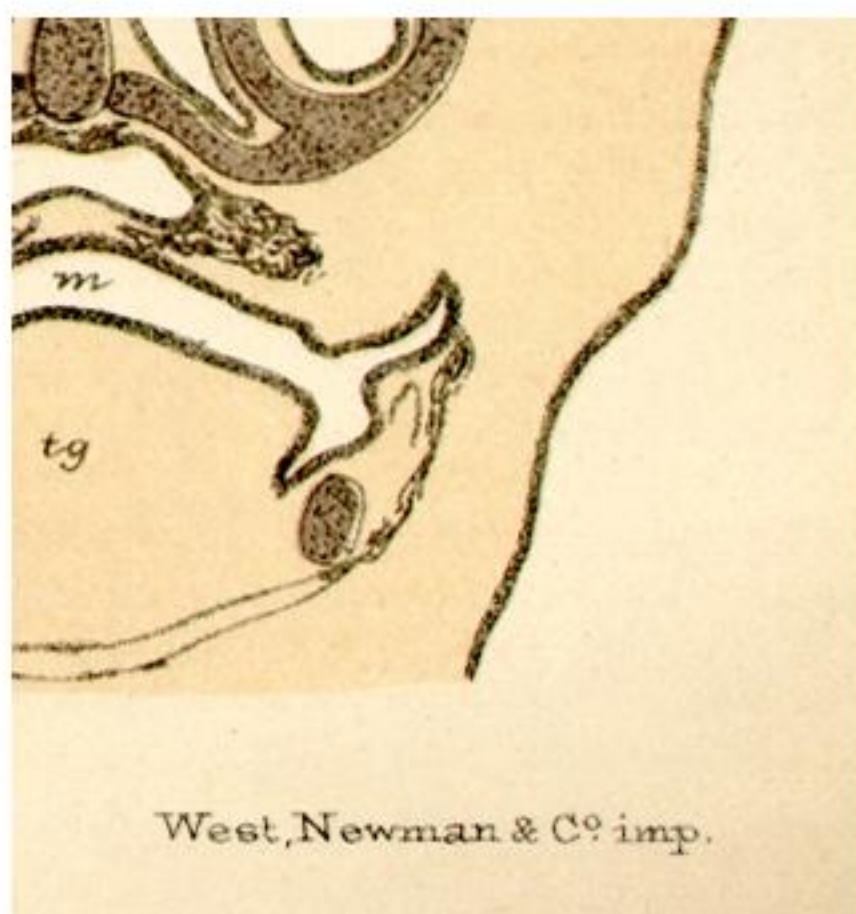




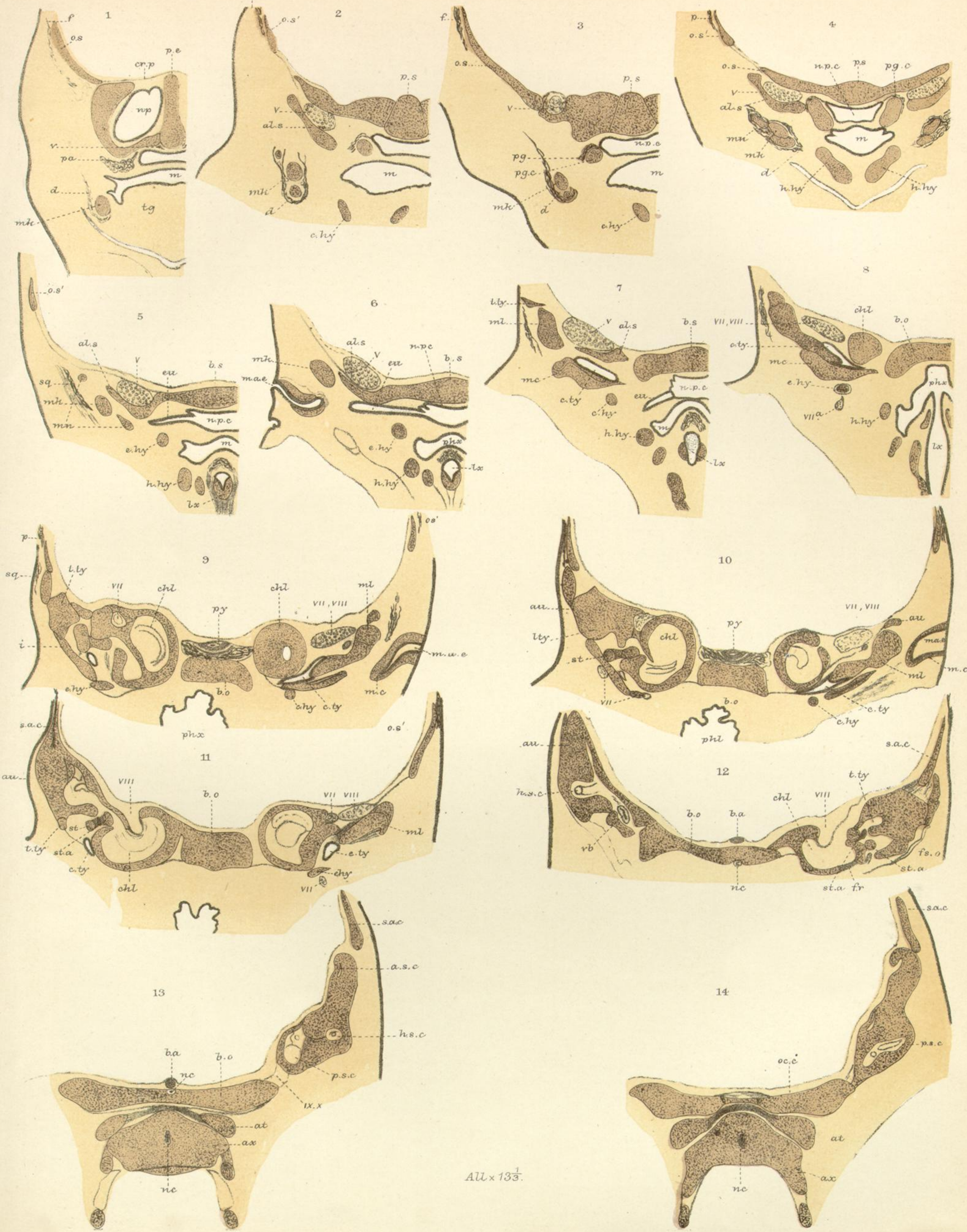
Parker & Coward del et lith.
W.K.P. dir.

Talpa.

West



West, Newman & Co imp.

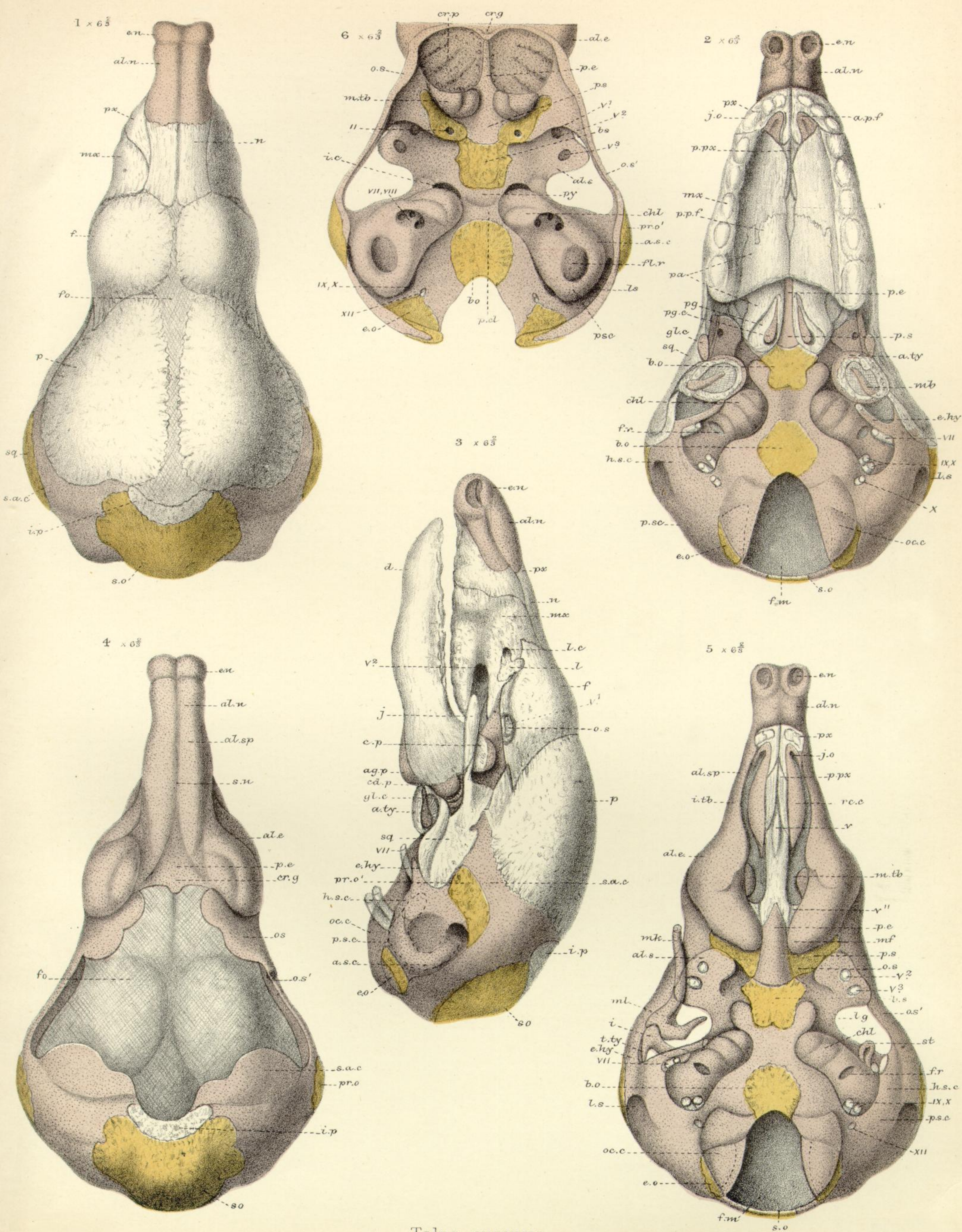


All x 133.

Talpa Europea.

PLATE 24.

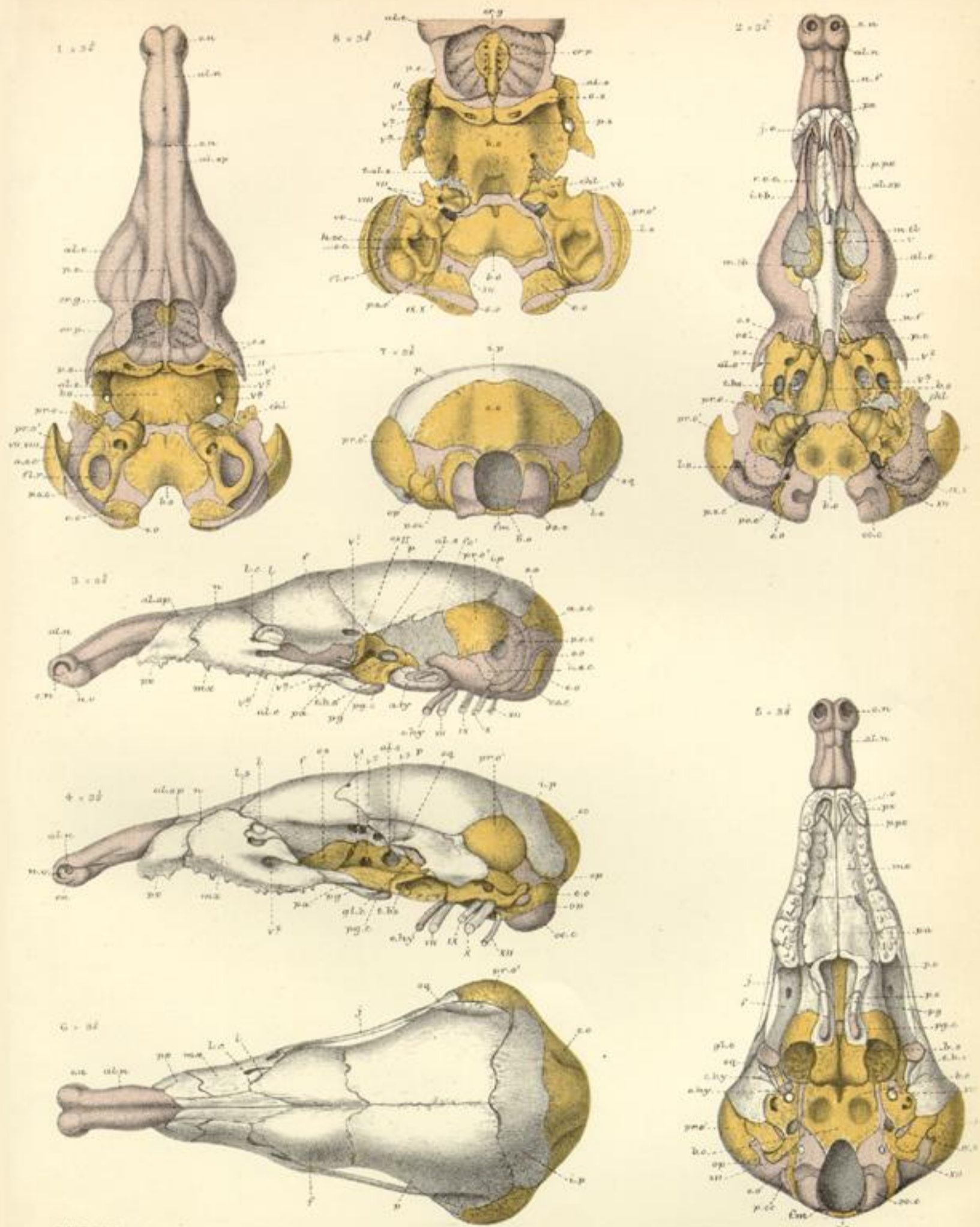
Figures.		Number of times magnified.
1	The same (continued) ; 11th section	13 $\frac{1}{3}$
2	The same ; 12th section	13 $\frac{1}{3}$
3	The same ; 13th section	13 $\frac{1}{3}$
4	The same ; 14th section	13 $\frac{1}{3}$
5	The same ; 15th section	13 $\frac{1}{3}$
6	The same ; 16th section	13 $\frac{1}{3}$
7	The same ; 17th section	13 $\frac{1}{3}$
8	The same ; 18th section	13 $\frac{1}{3}$
9	The same ; 19th section	13 $\frac{1}{3}$
10	The same ; 20th section	13 $\frac{1}{3}$
11	The same ; 21st section	13 $\frac{1}{7}$
12	The same ; 22nd section	13 $\frac{1}{3}$
13	The same ; 23rd section	13 $\frac{1}{3}$
14	The same ; 24th section	13 $\frac{1}{3}$



Talpa europæa.

PLATE 26.

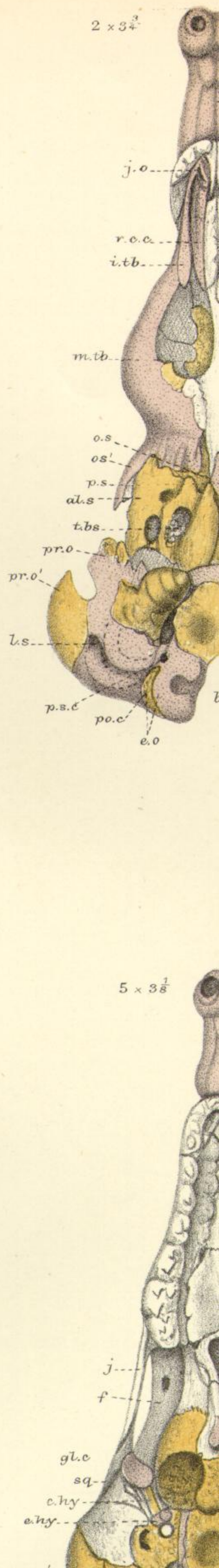
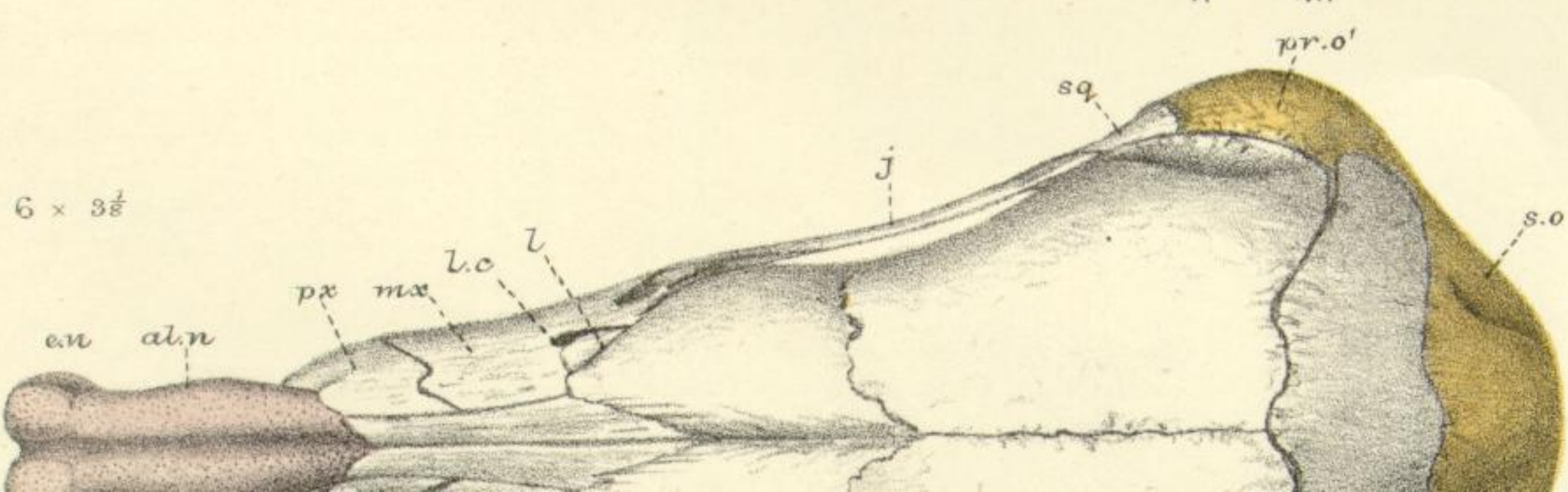
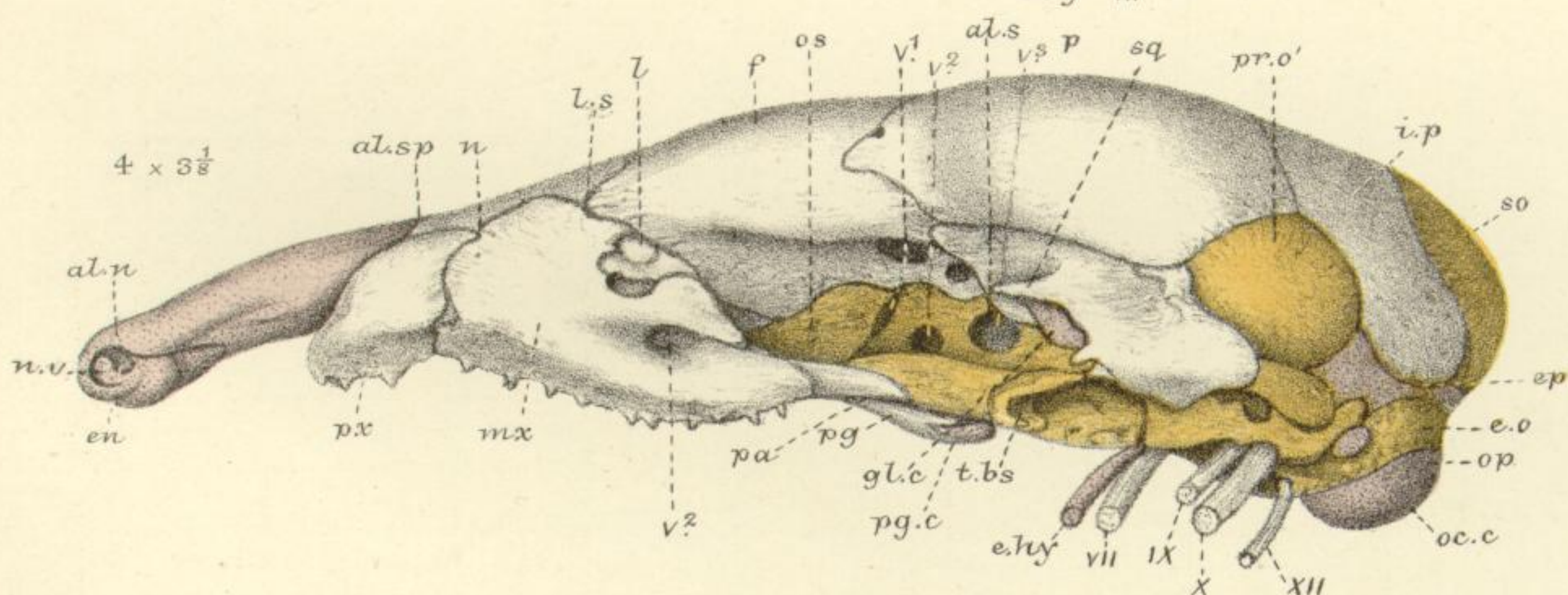
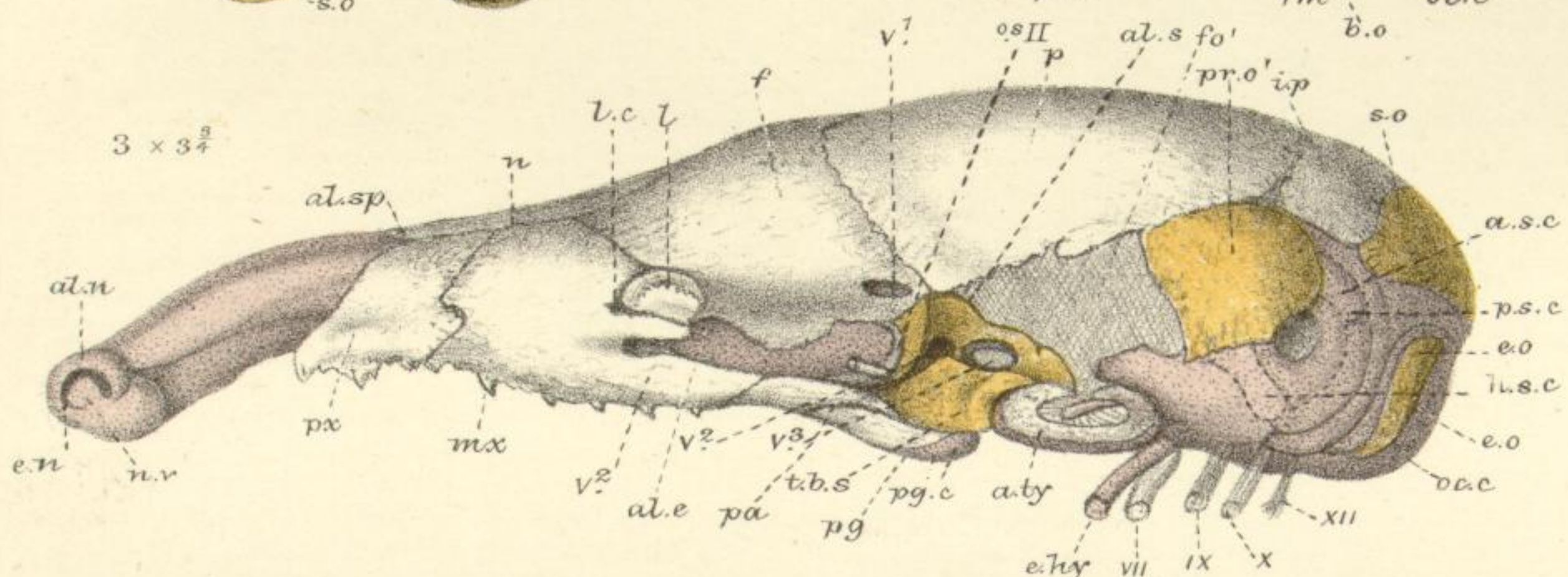
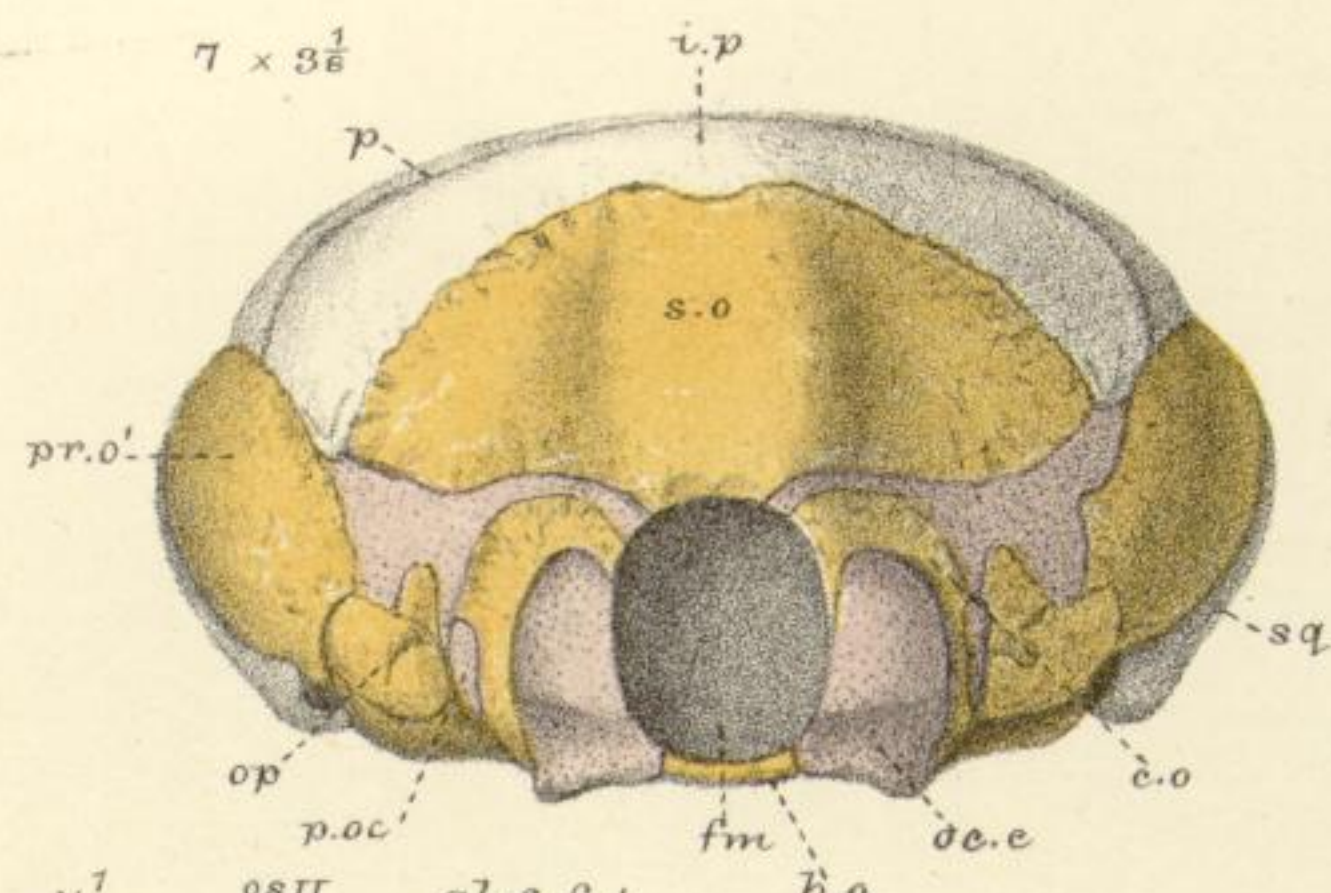
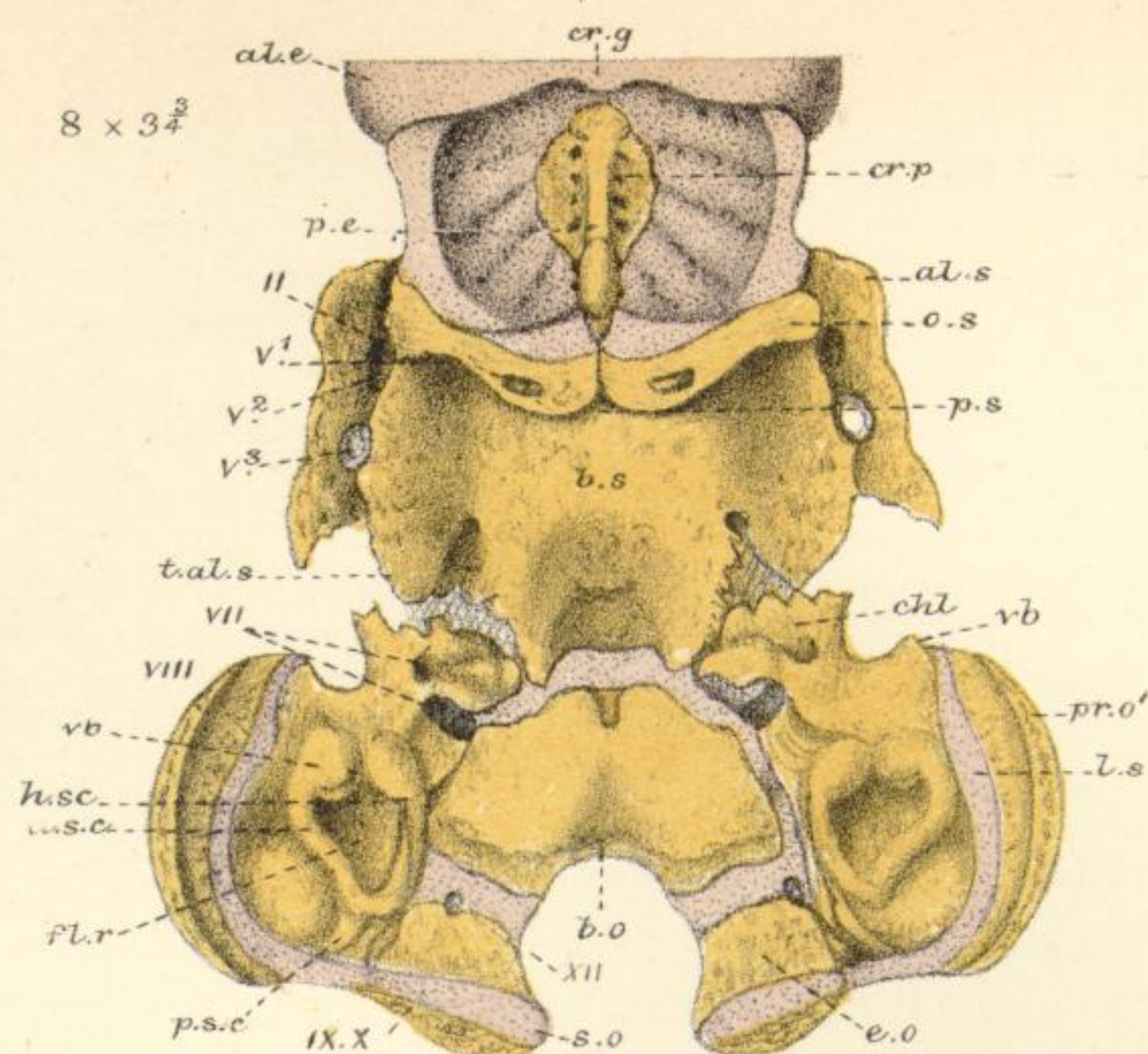
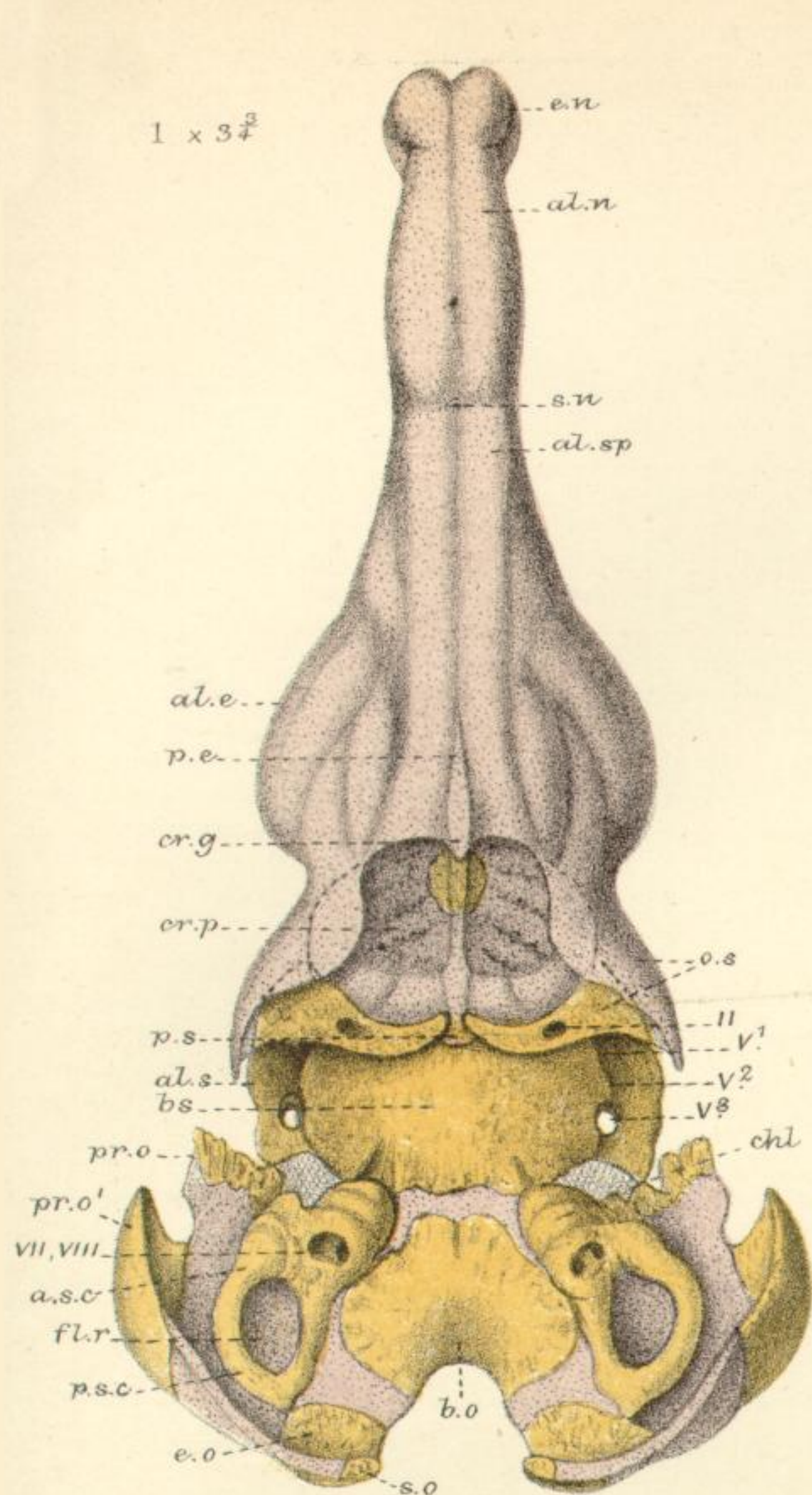
Figures.		Number of times magnified.
1	<i>Talpa europæa</i> (9th stage); young, $1\frac{4}{5}$ inch long; dissected skull; upper view	$6\frac{2}{3}$
2	The same; lower view	$6\frac{2}{3}$
3	The same; side view	$6\frac{2}{3}$
4	The same; endocranium; upper view	$6\frac{2}{3}$
5	The same; lower view	$6\frac{2}{3}$
6	The same; inner view (part)	$6\frac{2}{3}$

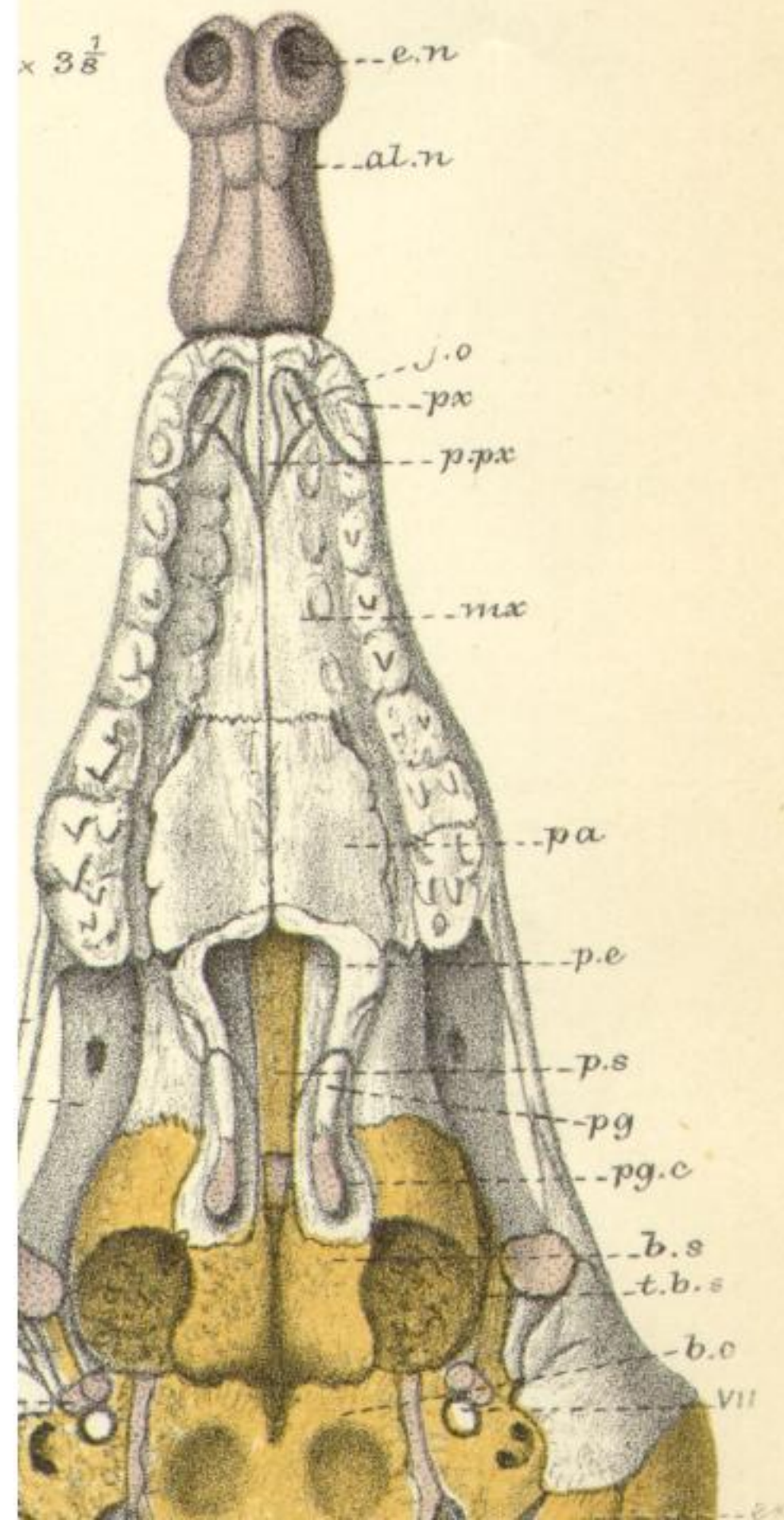
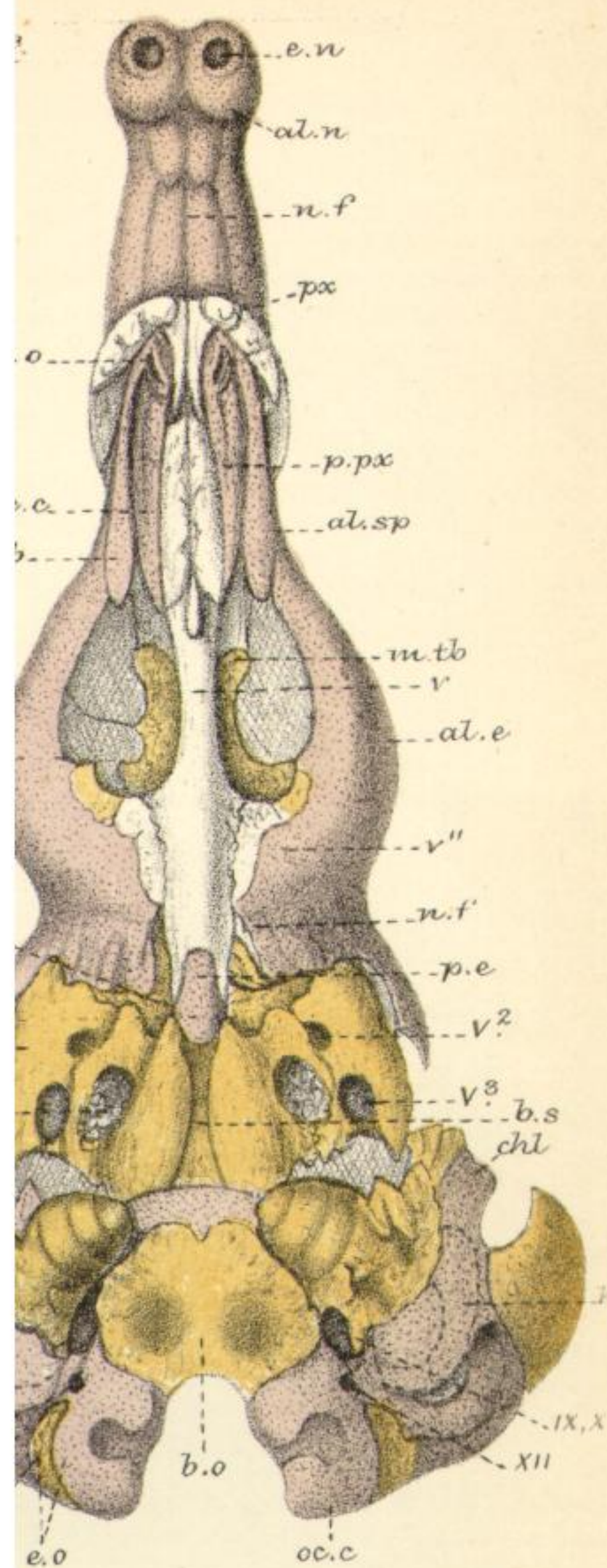


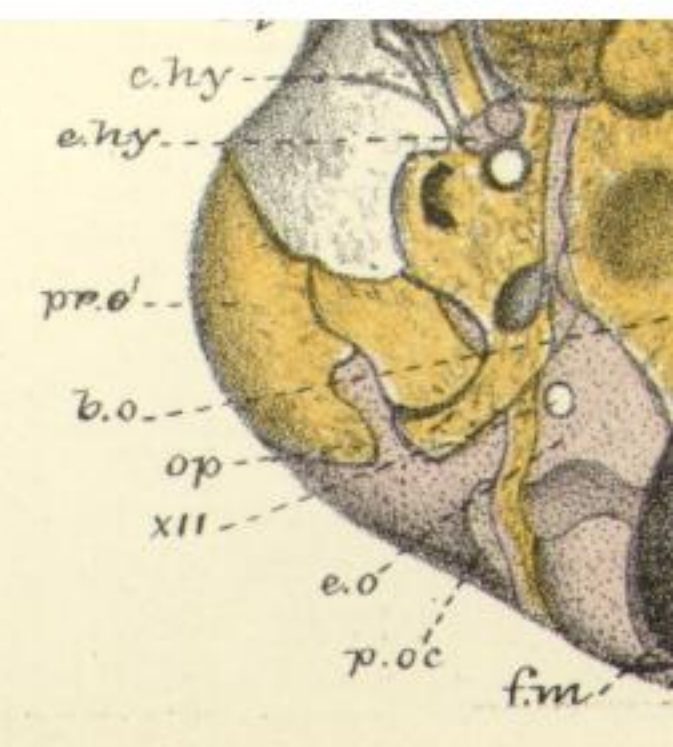
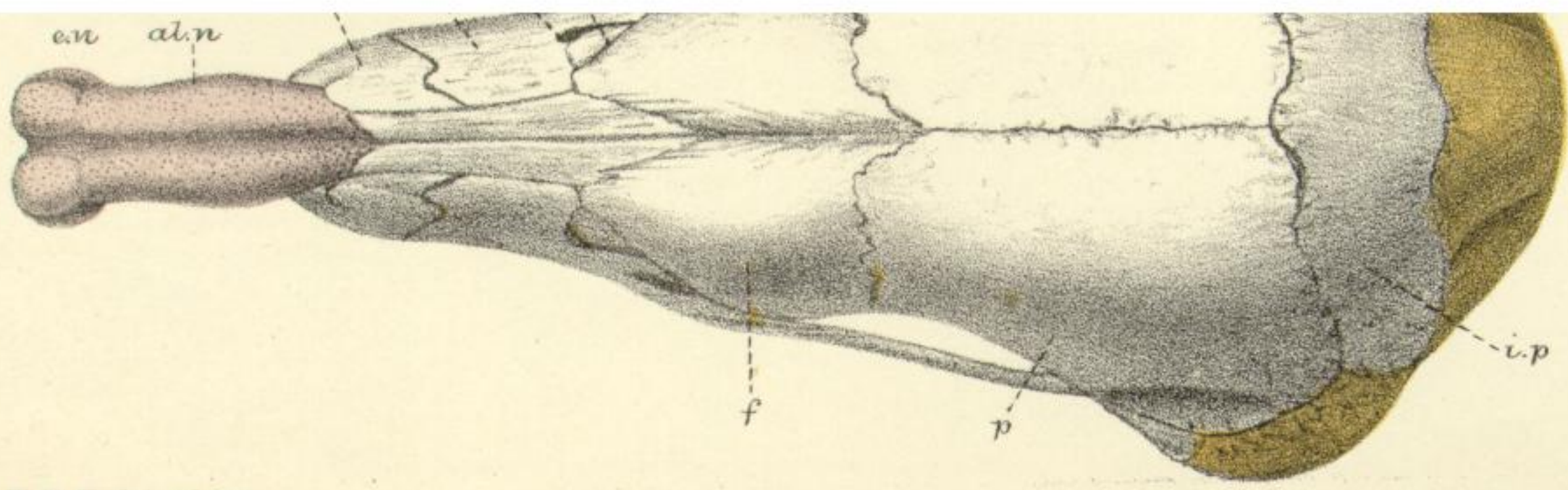
W. H. P. de L. and J. de L.
 Publisher & Co. 188.

West. Newspaper B.C.

Talpa europaea

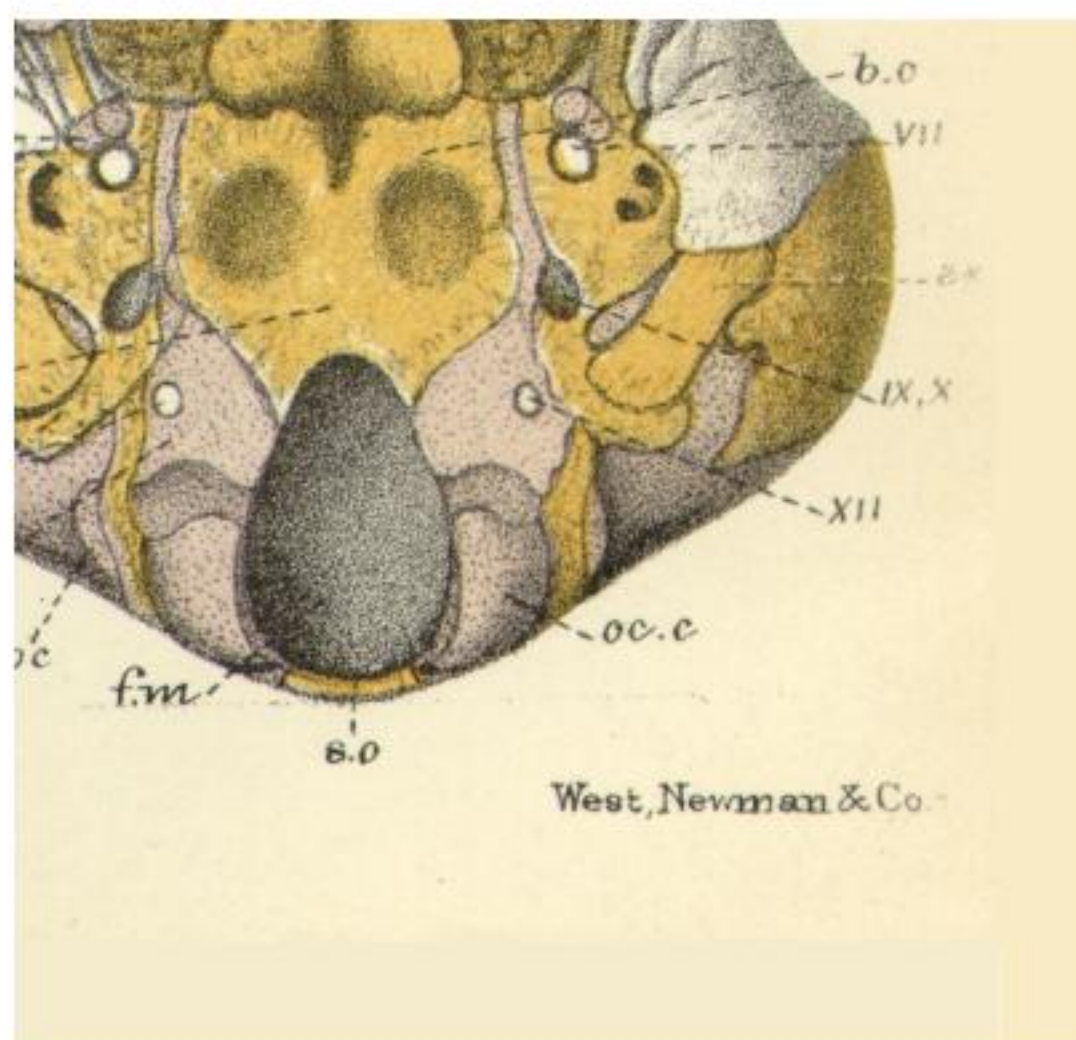


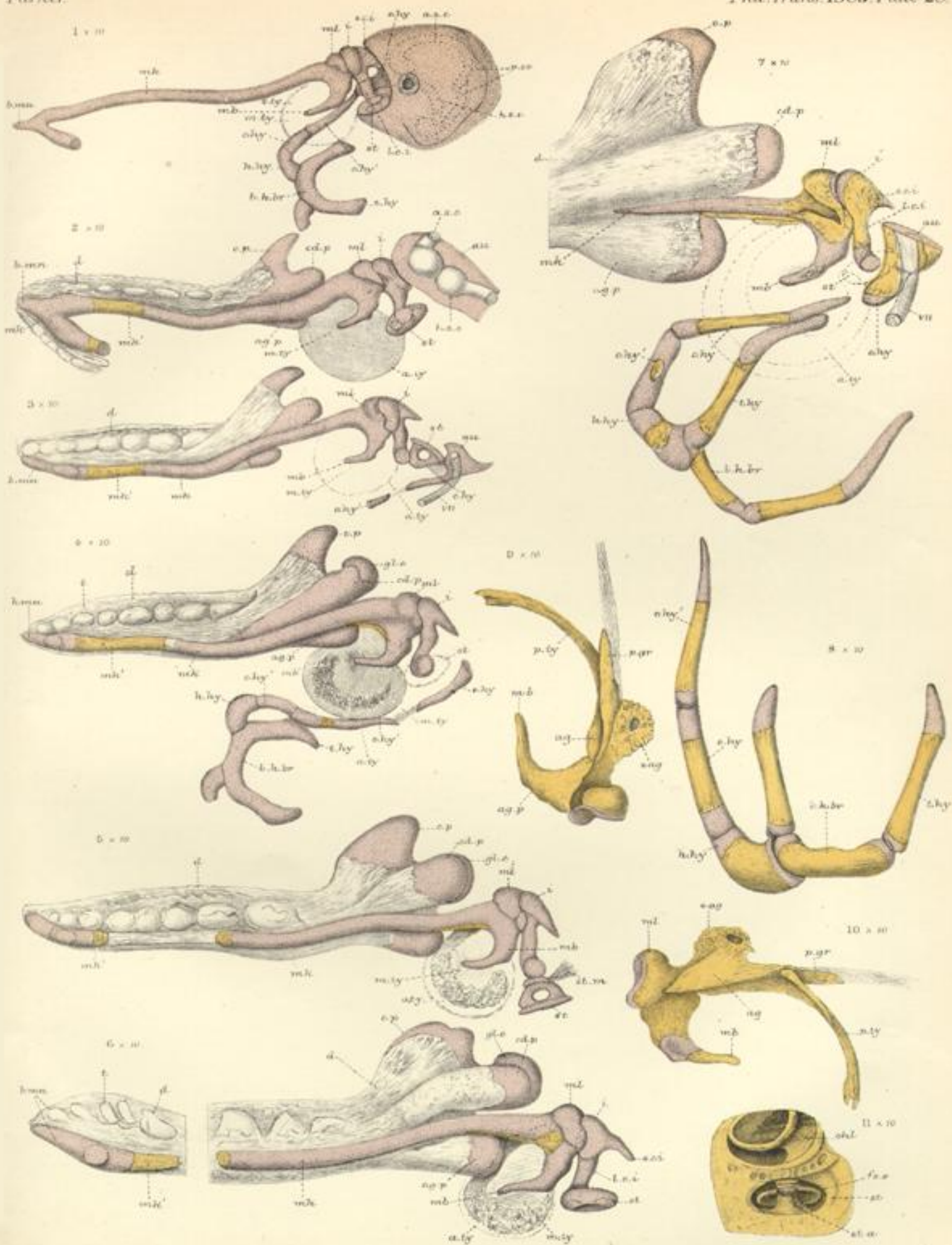




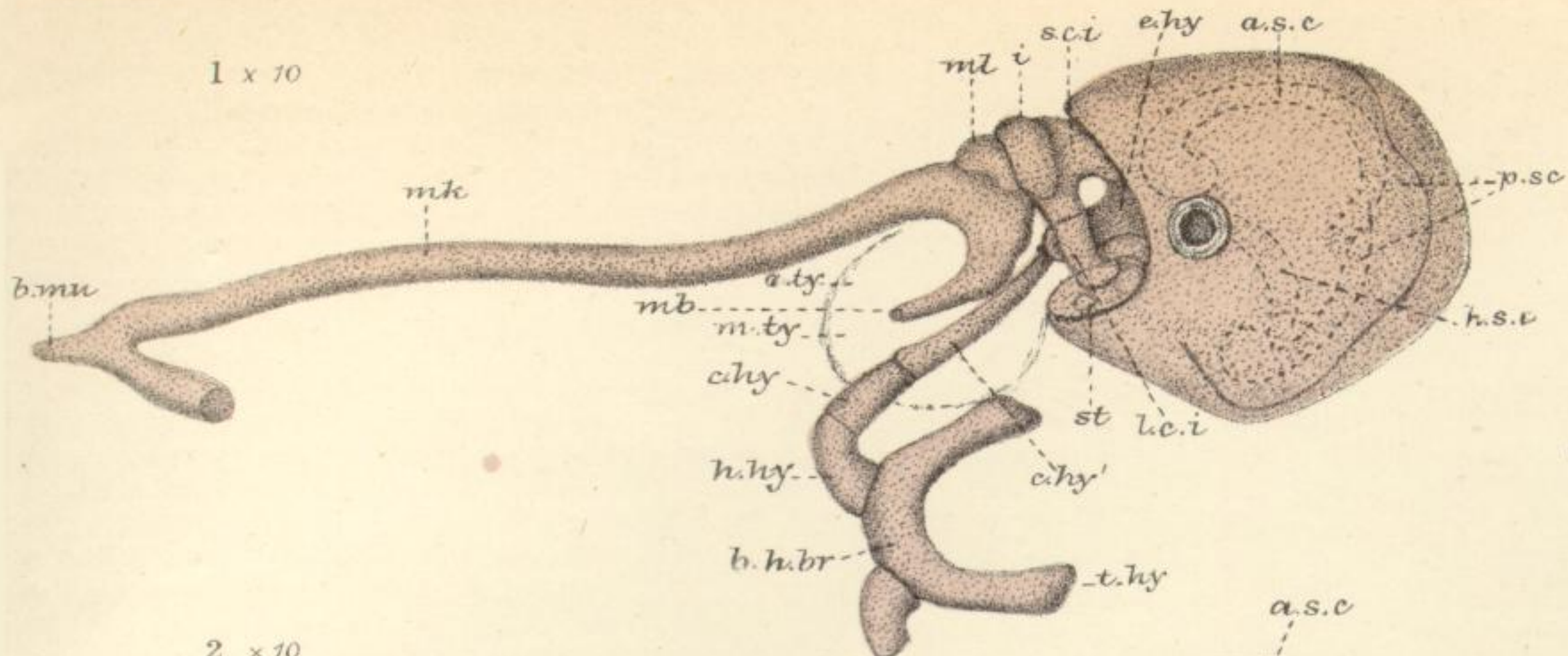
W.K.P. del. adnat.
Parker & Coward lith.

Talpa europœa

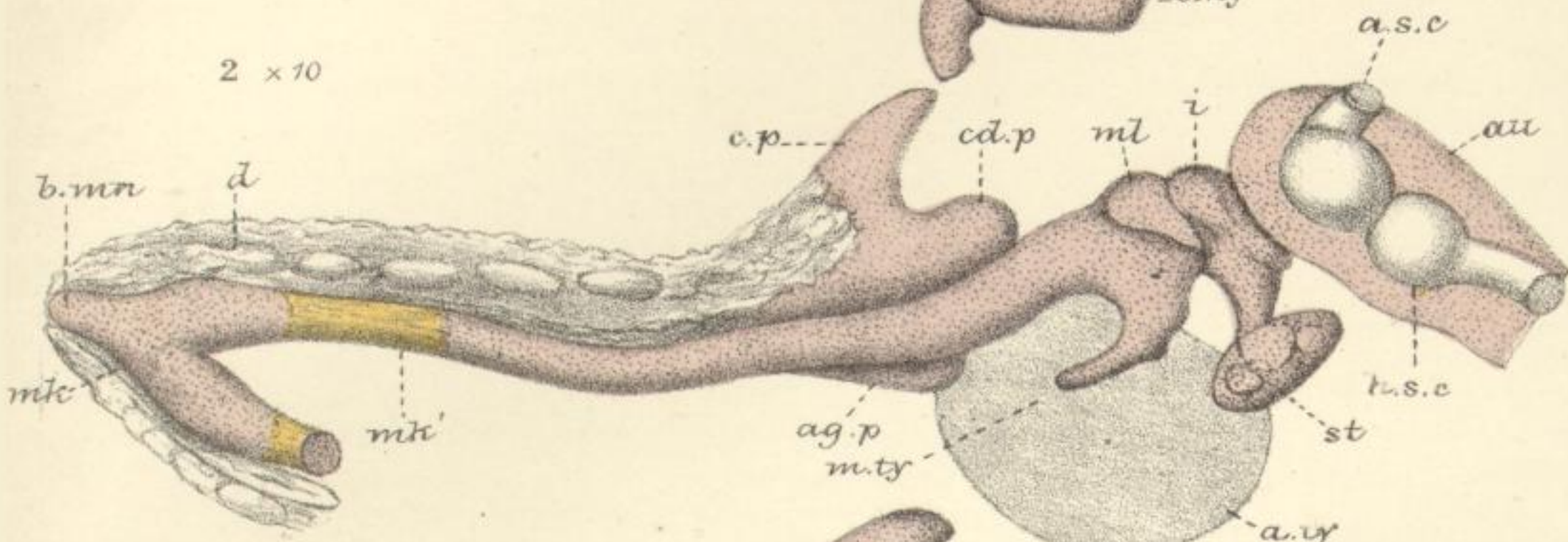




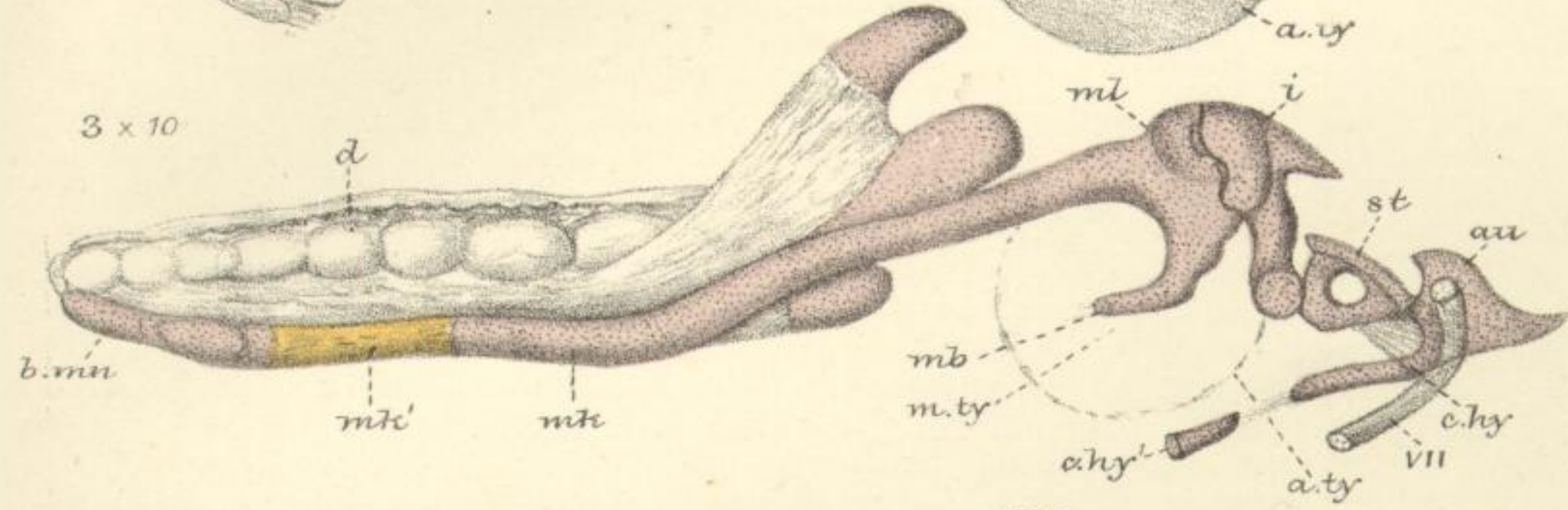
1 x 10



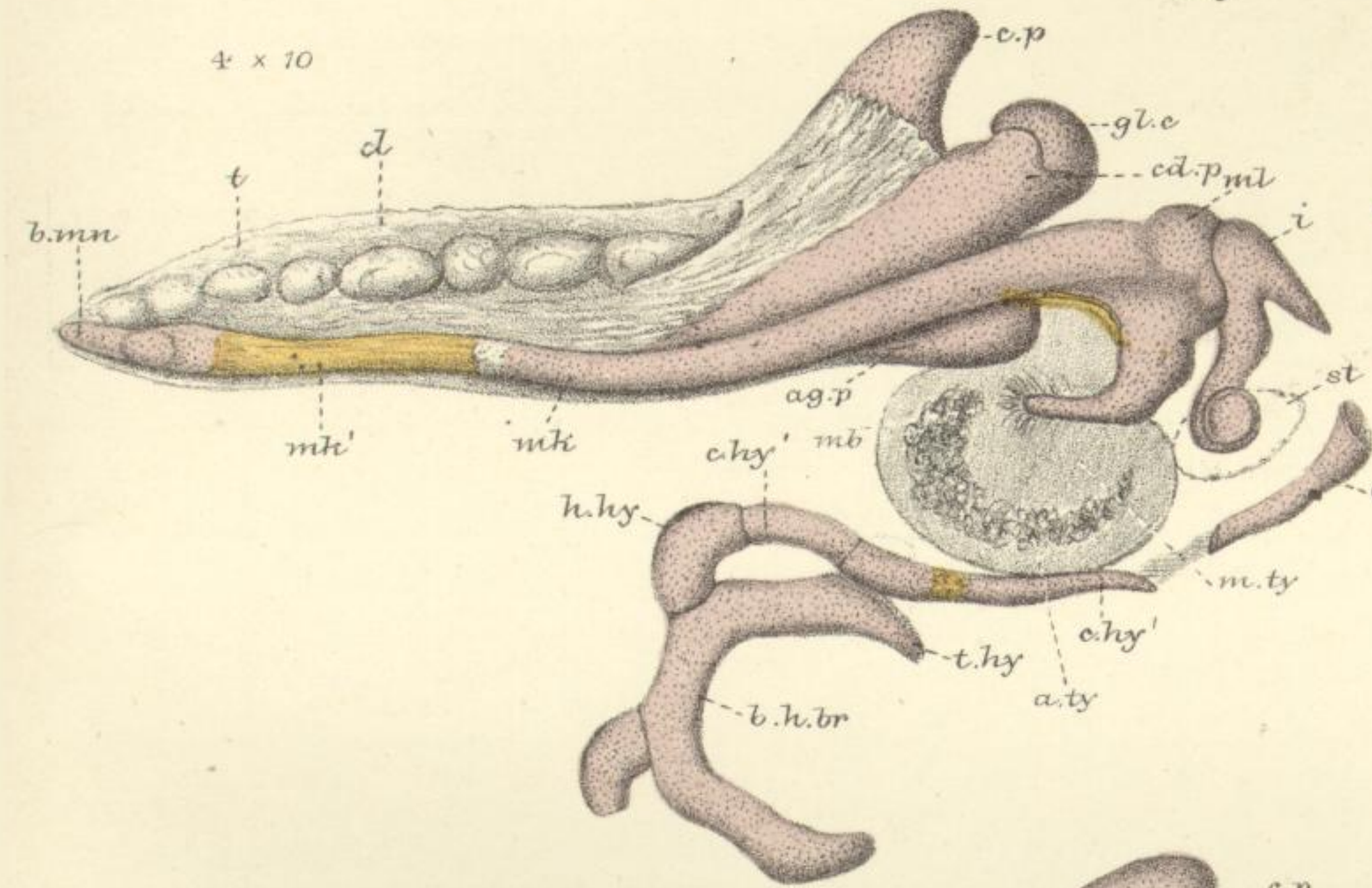
2 x 10



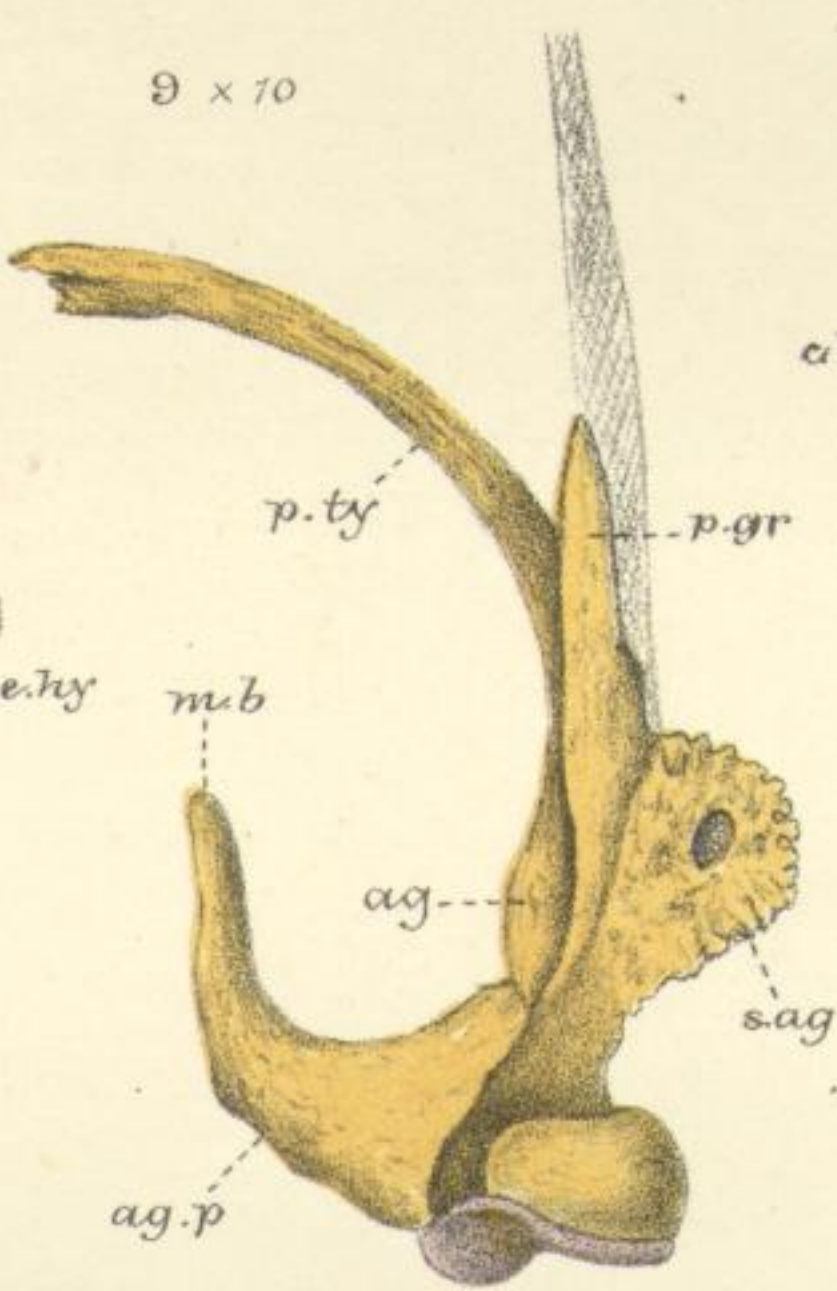
3 x 10



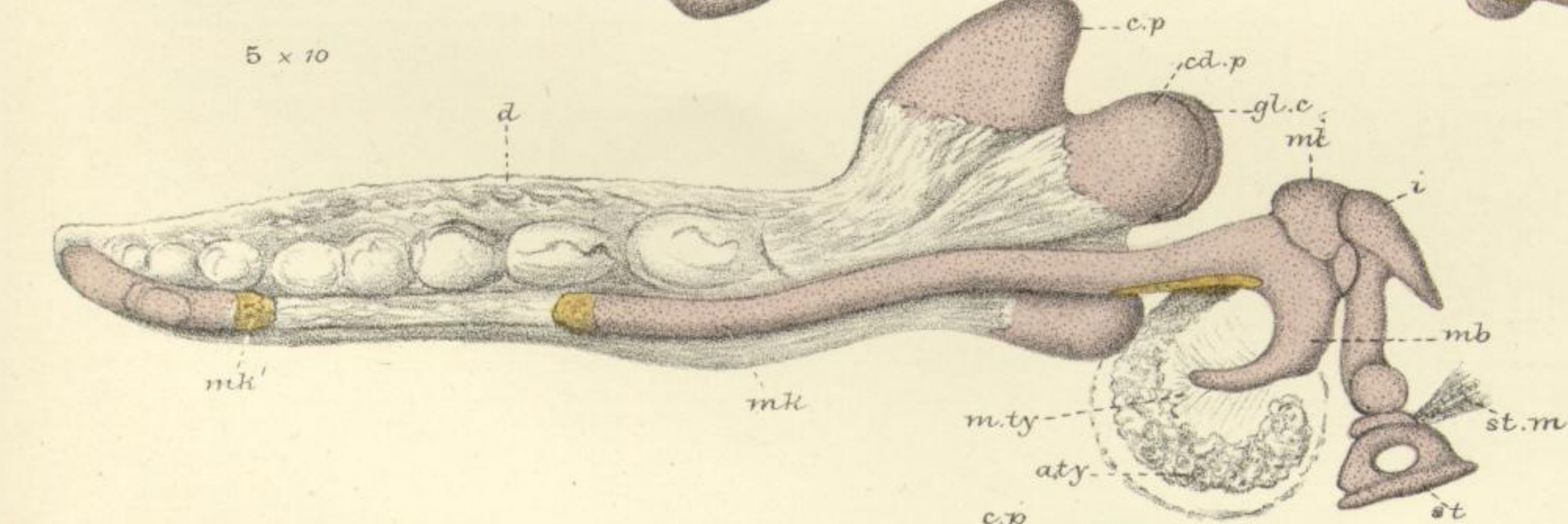4 x 10



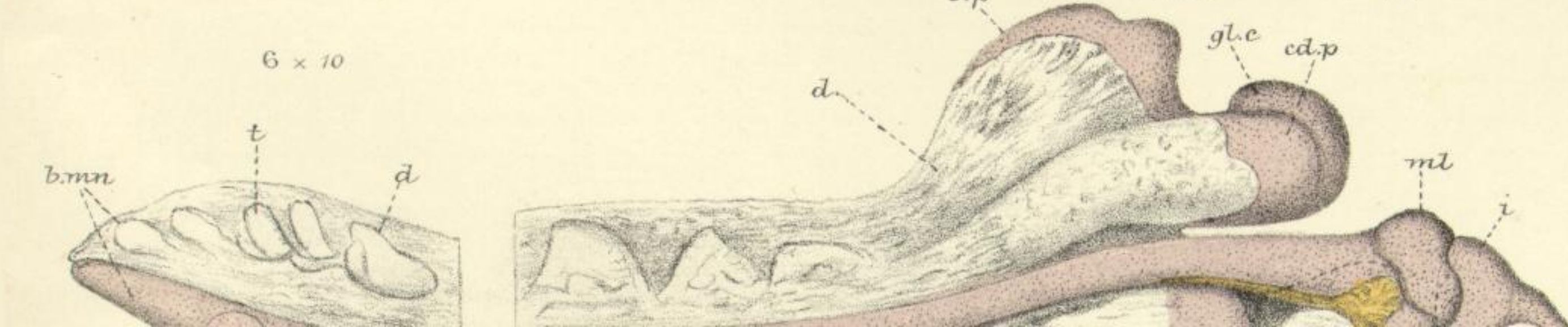
5 x 10



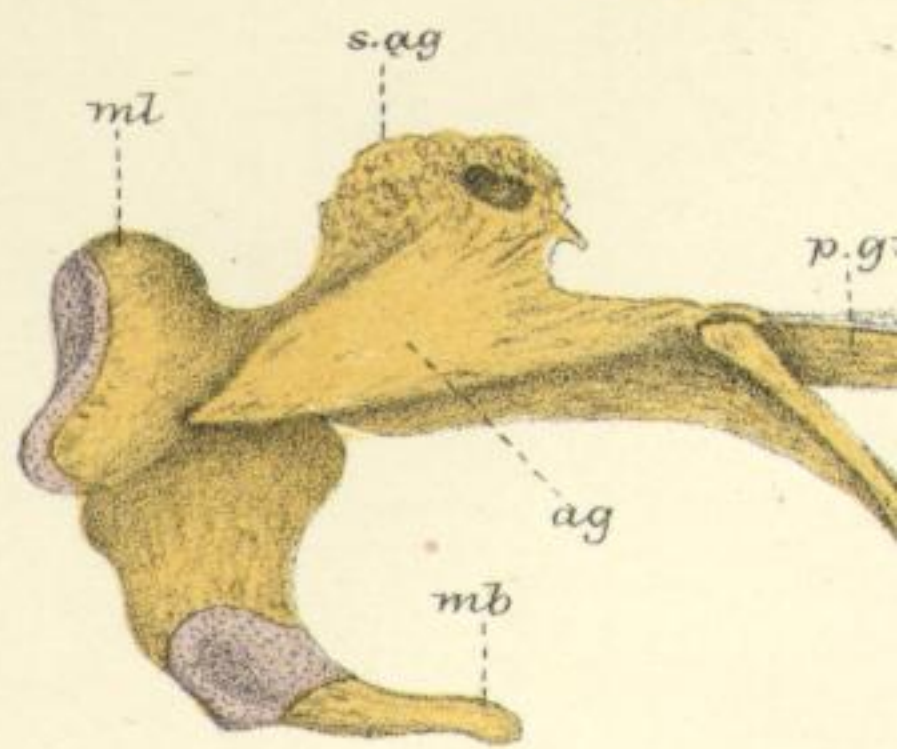
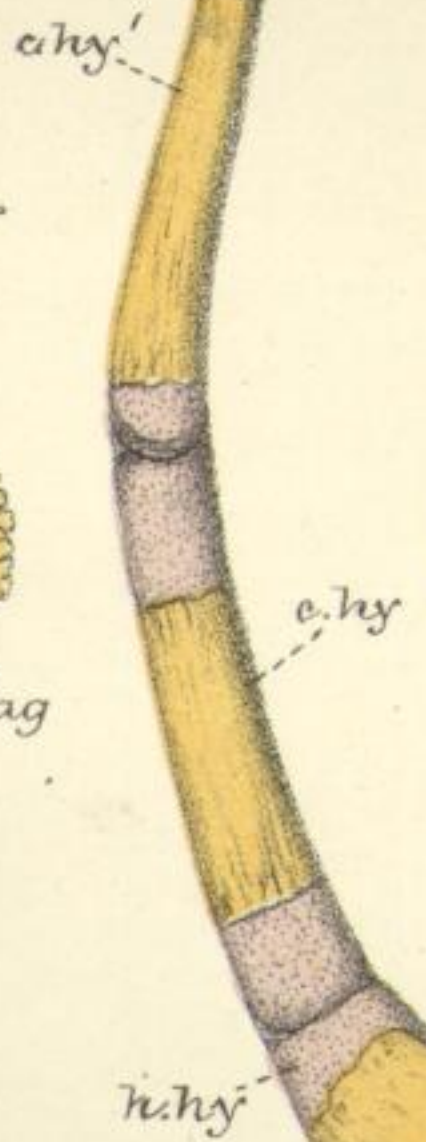
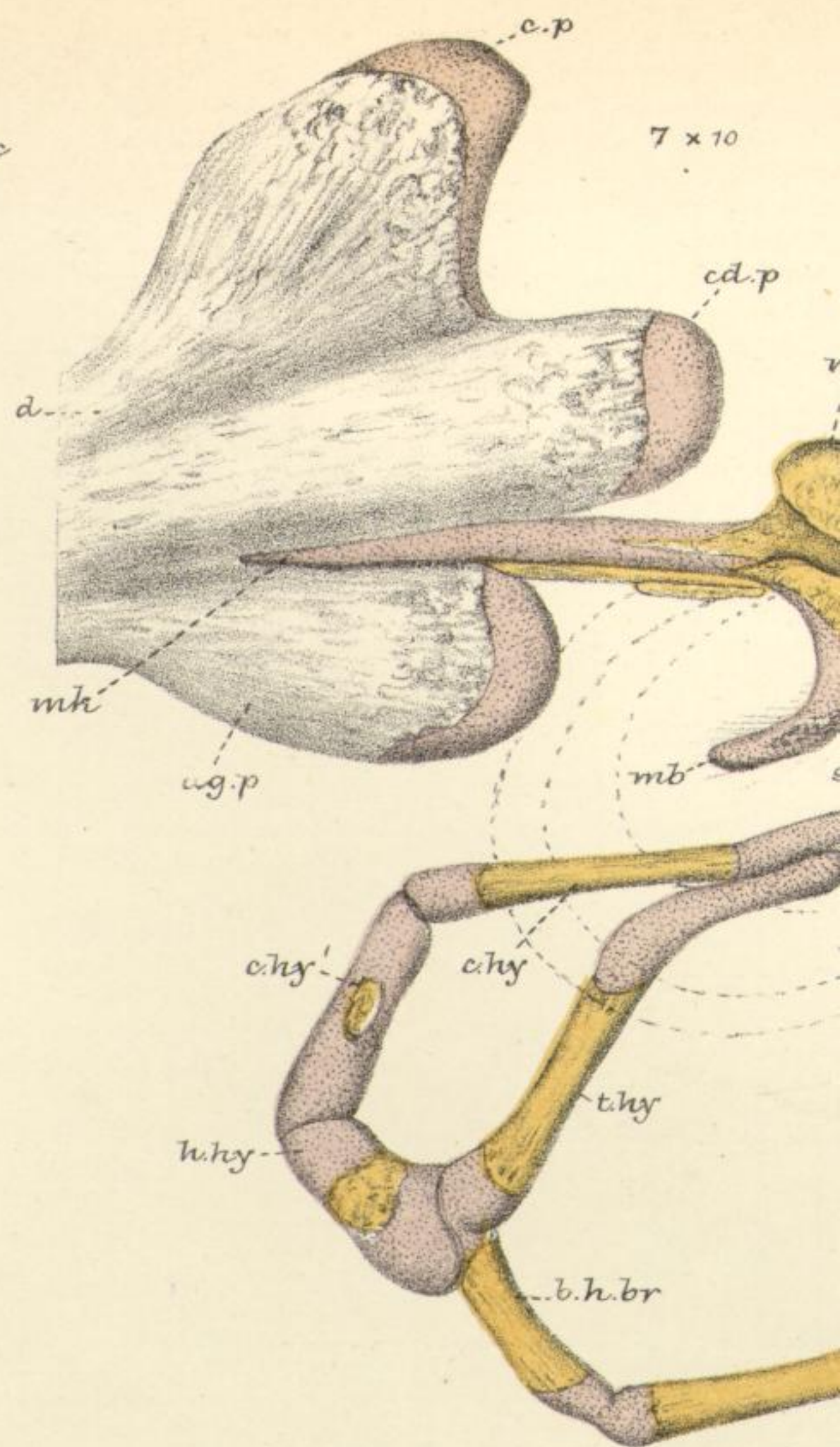
6 x 10



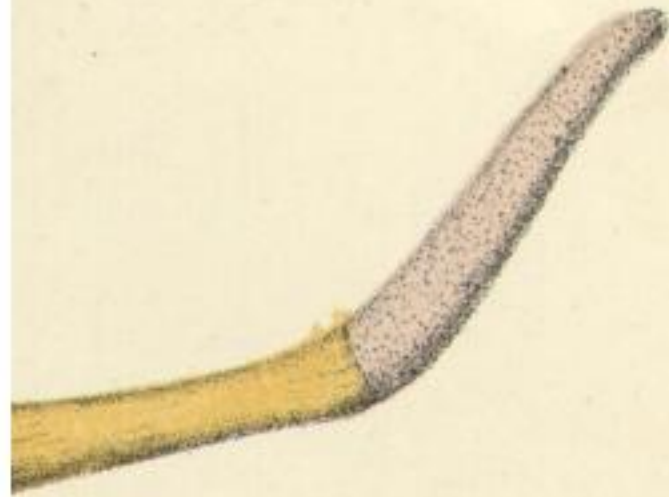
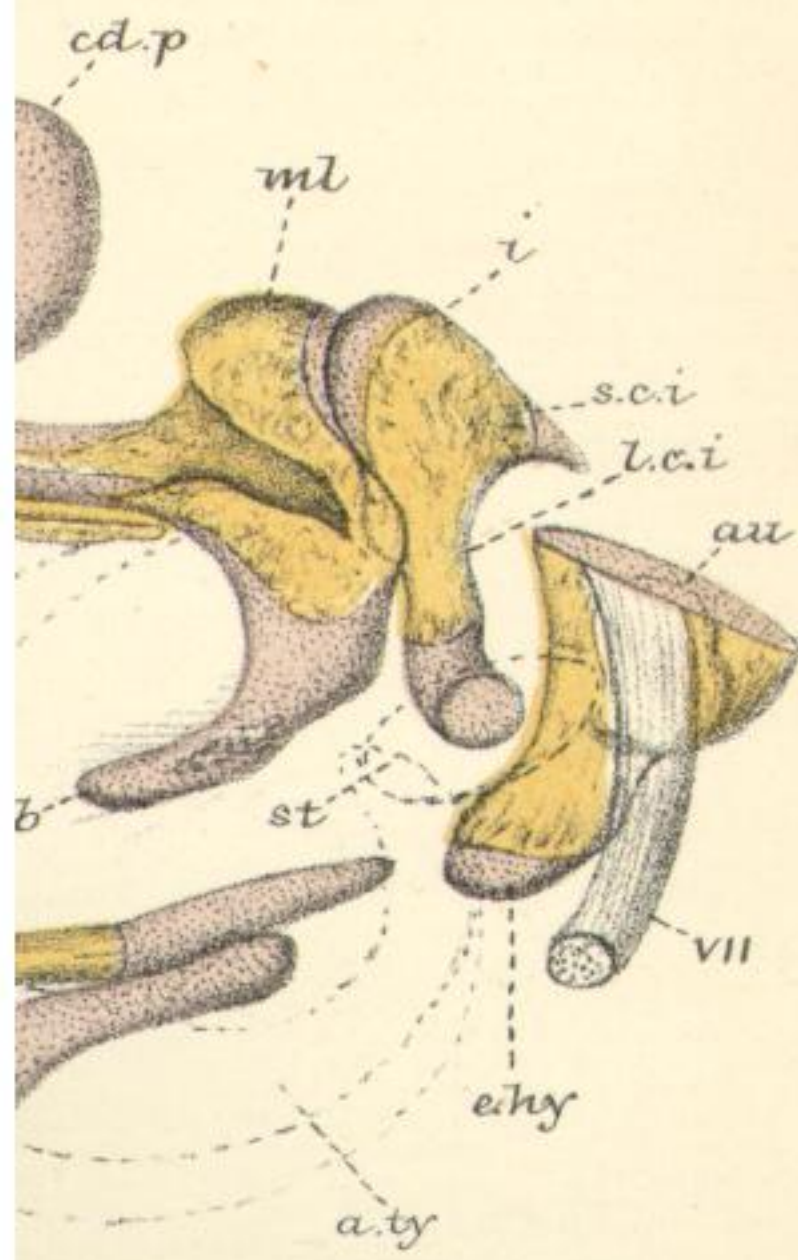
7 x 10



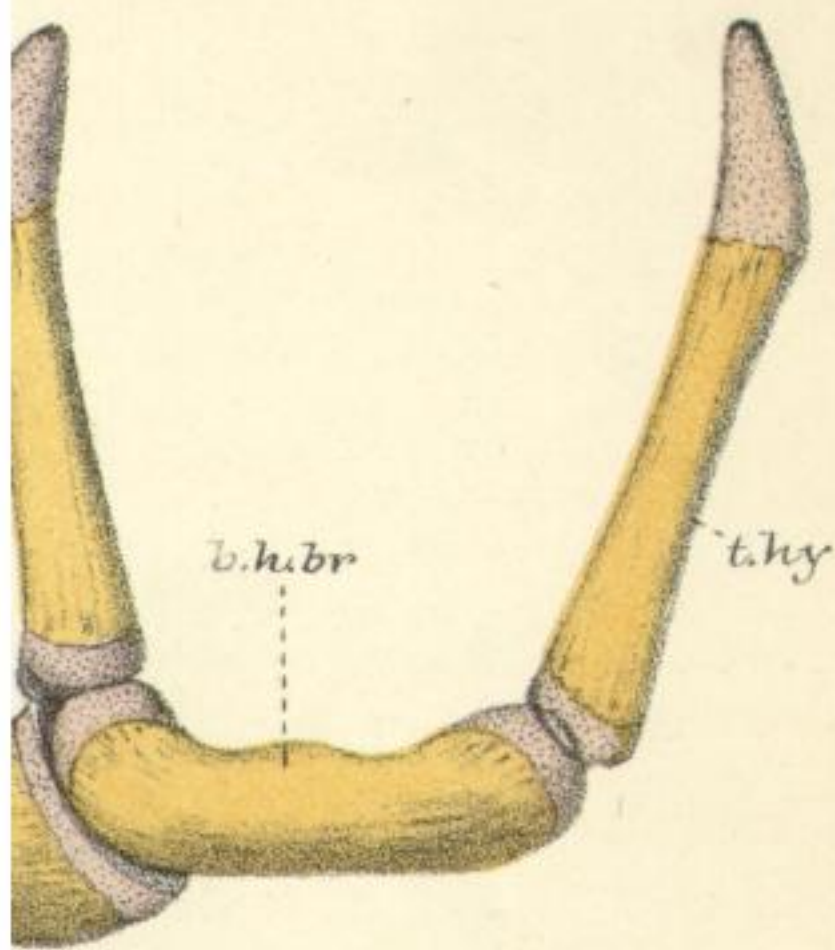
7 x 10



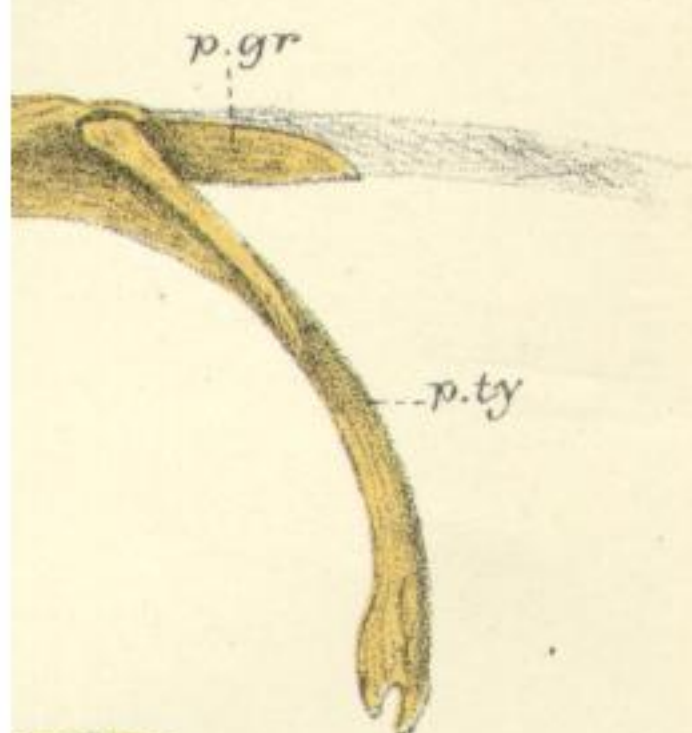
x 10



8 x 10

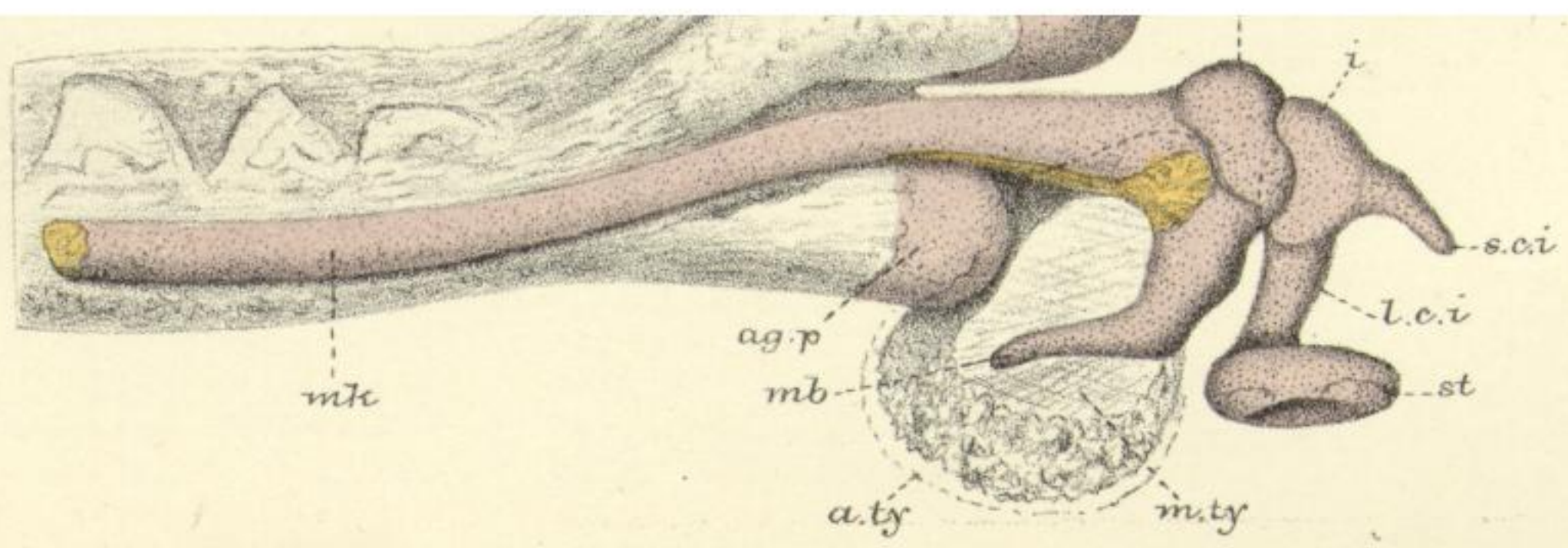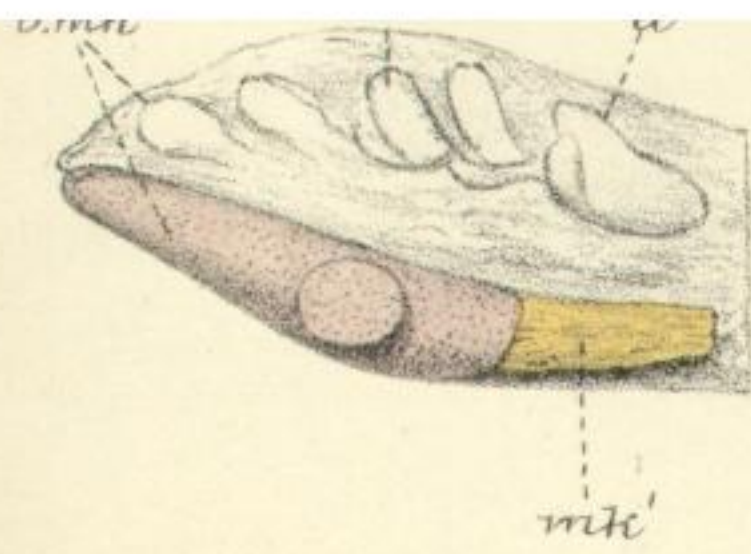


10 x 10



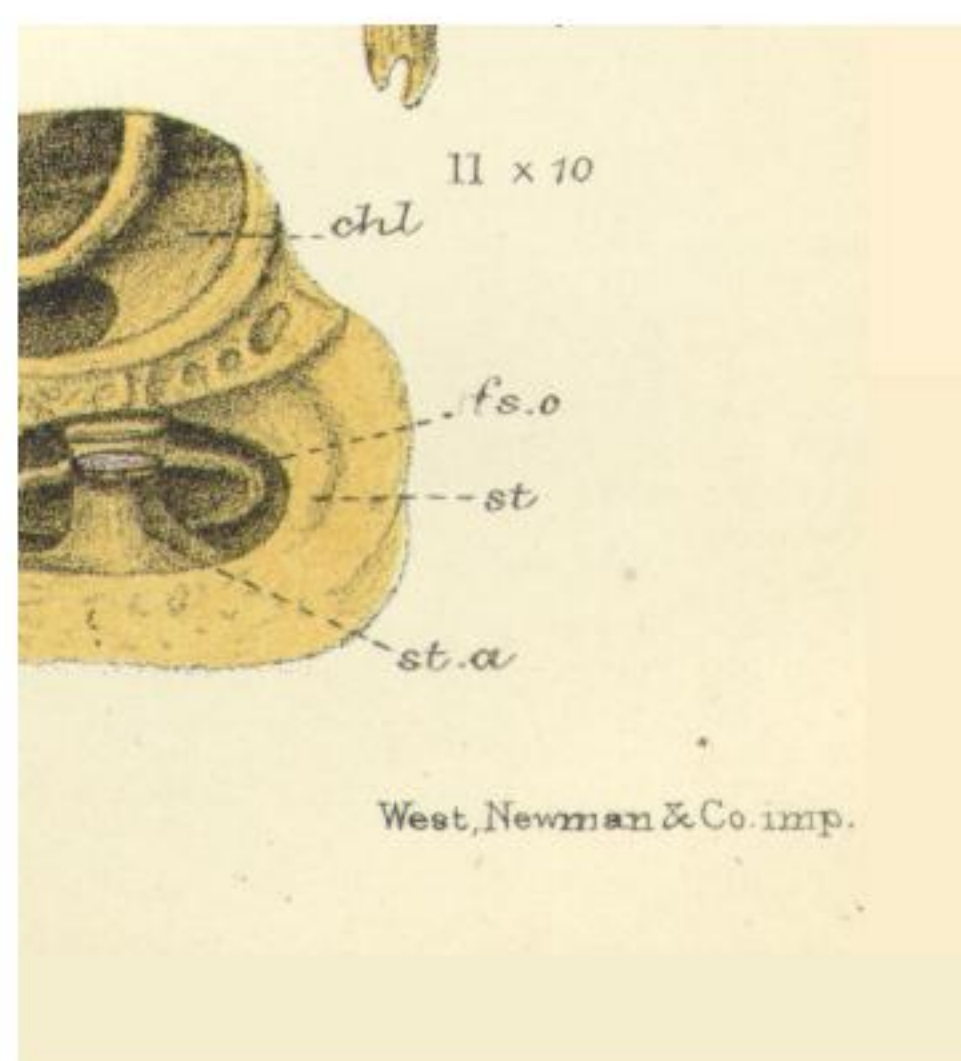
11 x 10

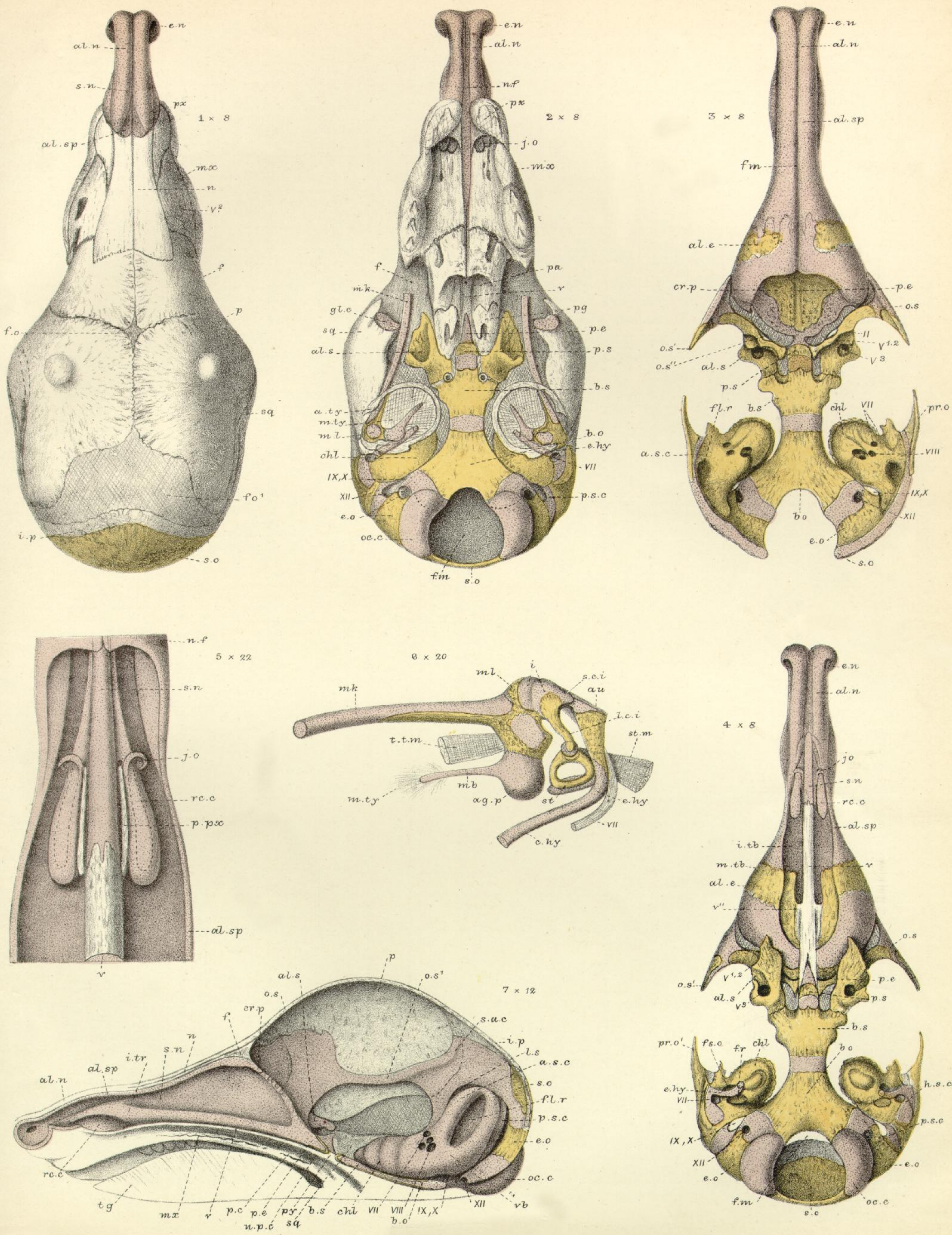




W.K.P. del. ad nat.
Parker & Coward lith.

Talpa europæa.

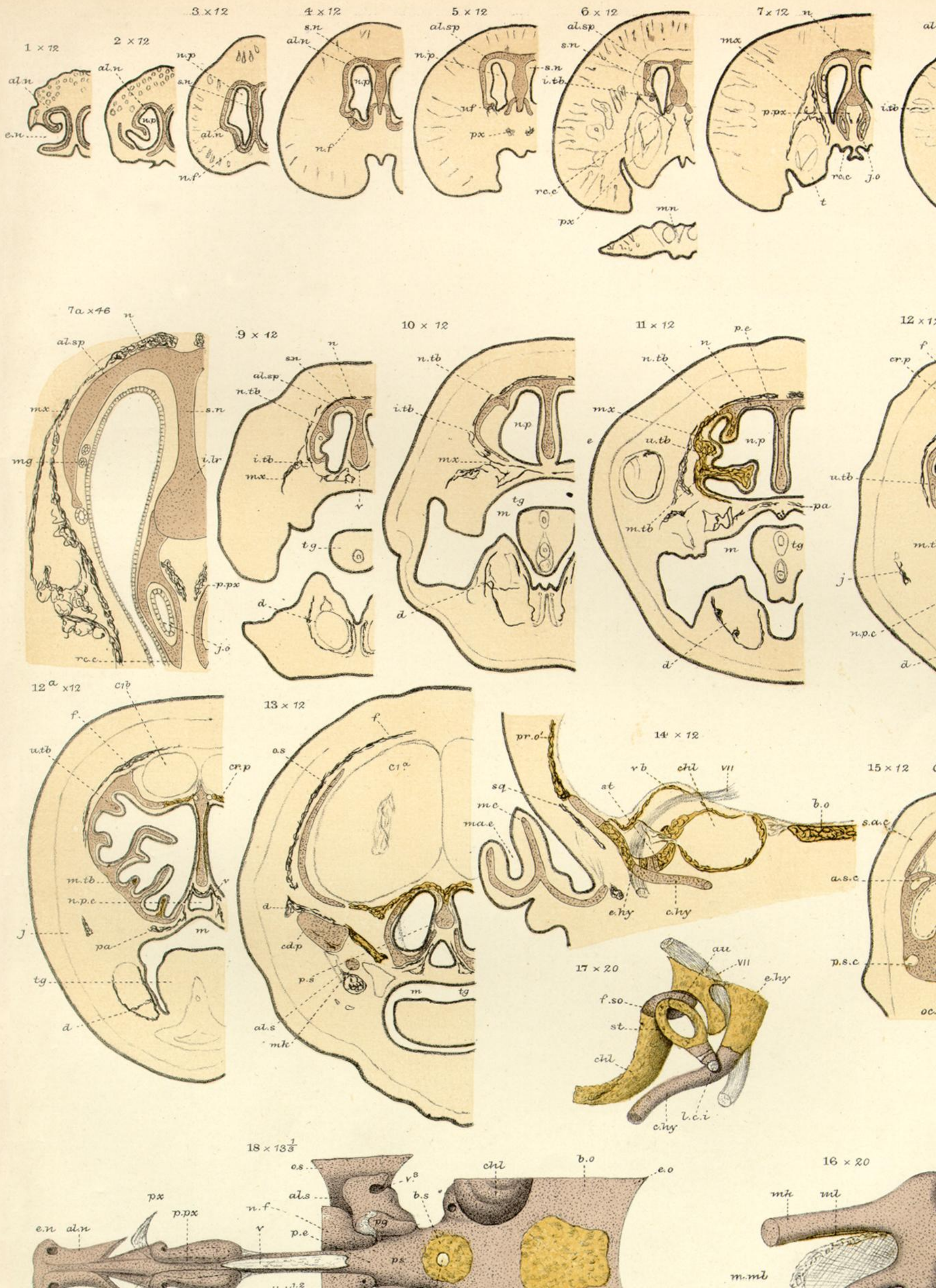


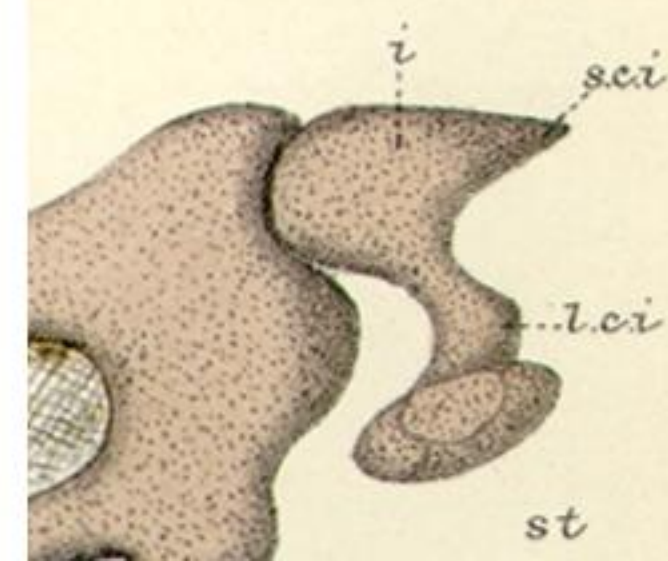
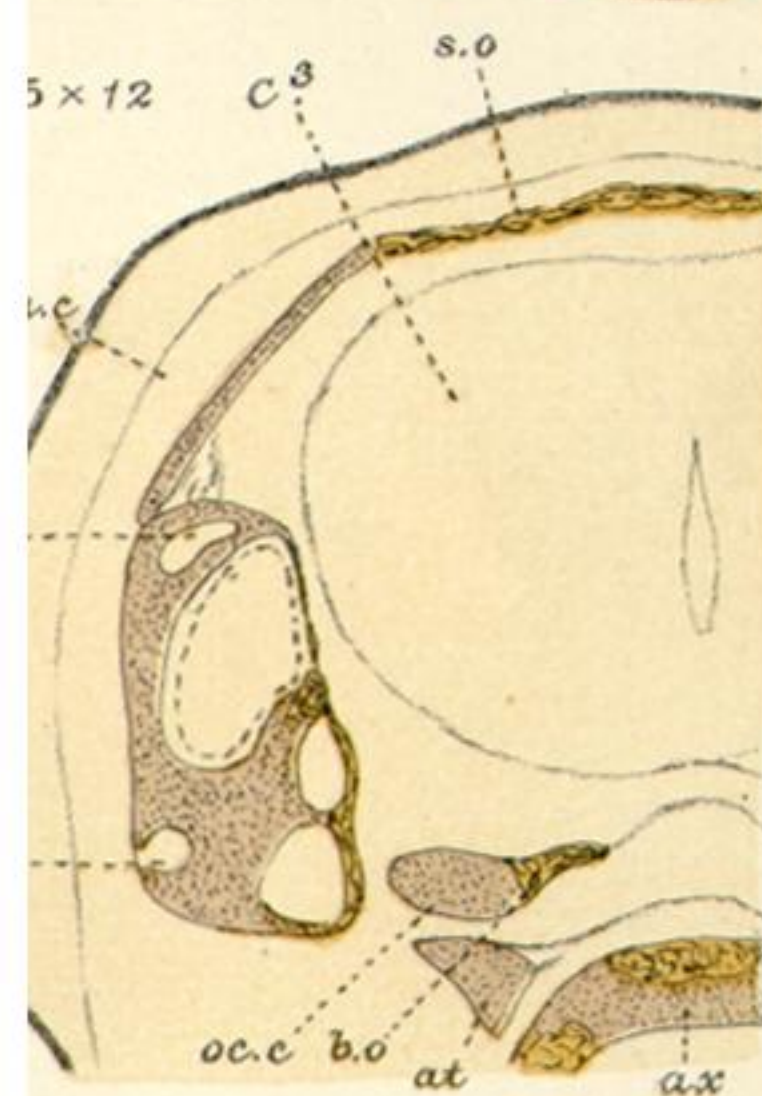
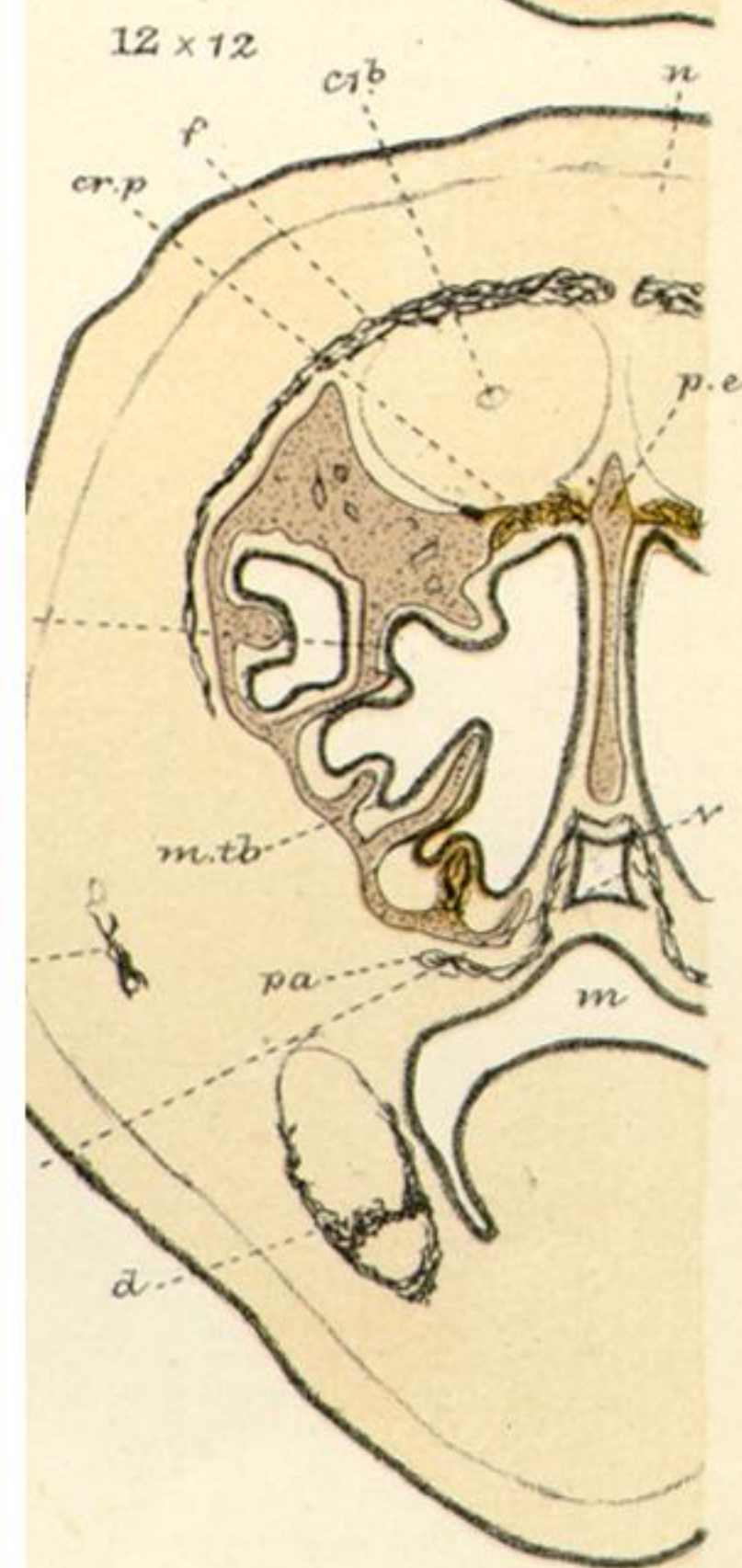
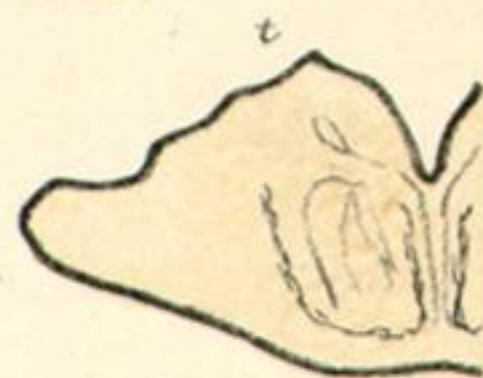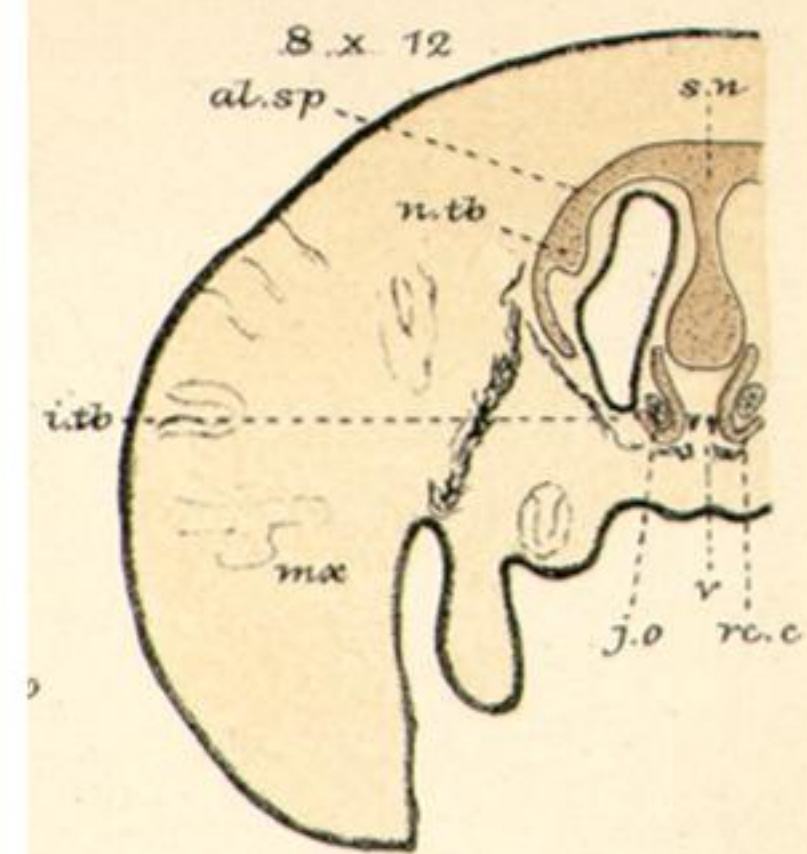


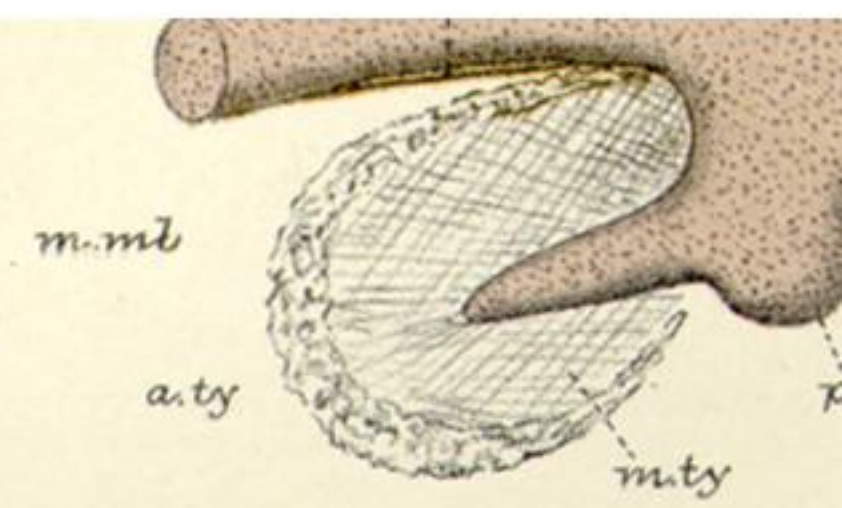
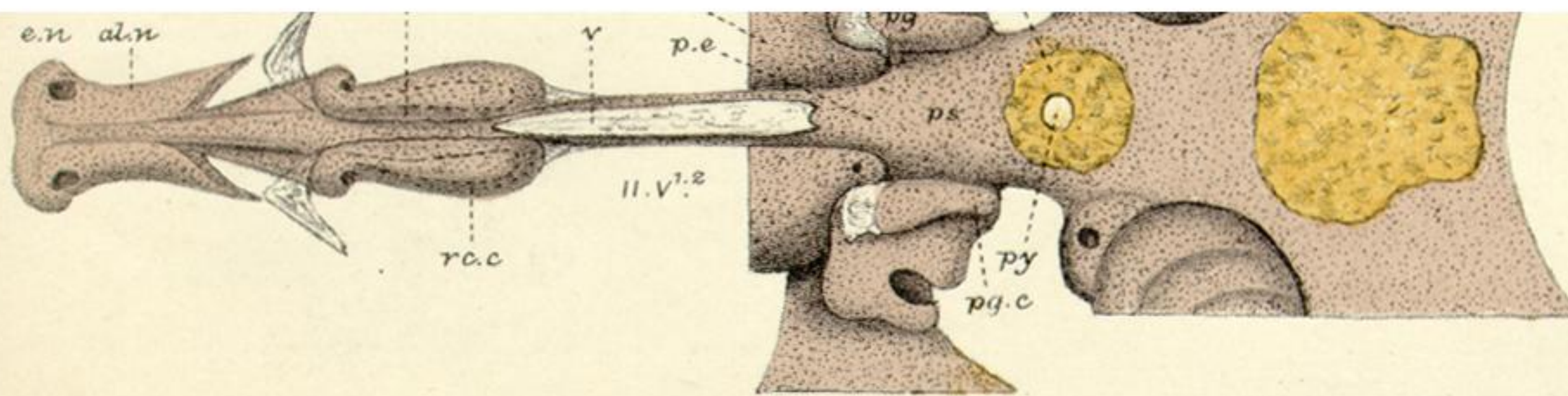
Sorex vulgaris.

PLATE 29.

Figures.		Number of times magnified.
1	<i>Sorex vulgaris</i> (3rd stage); dissected skull of young shrew, 1 $\frac{1}{3}$ inch long; upper view	8
2	The same; lower view	8
3	The same; endocranium; upper view	8
4	The same; lower view	8
5	The same as fig. 4; part	22
6	The same; ossicula auditûs; outer view	20
7	<i>Sorex vulgaris</i> (2nd stage), 9 $\frac{1}{2}$ lines long (19mm.); section of skull	12

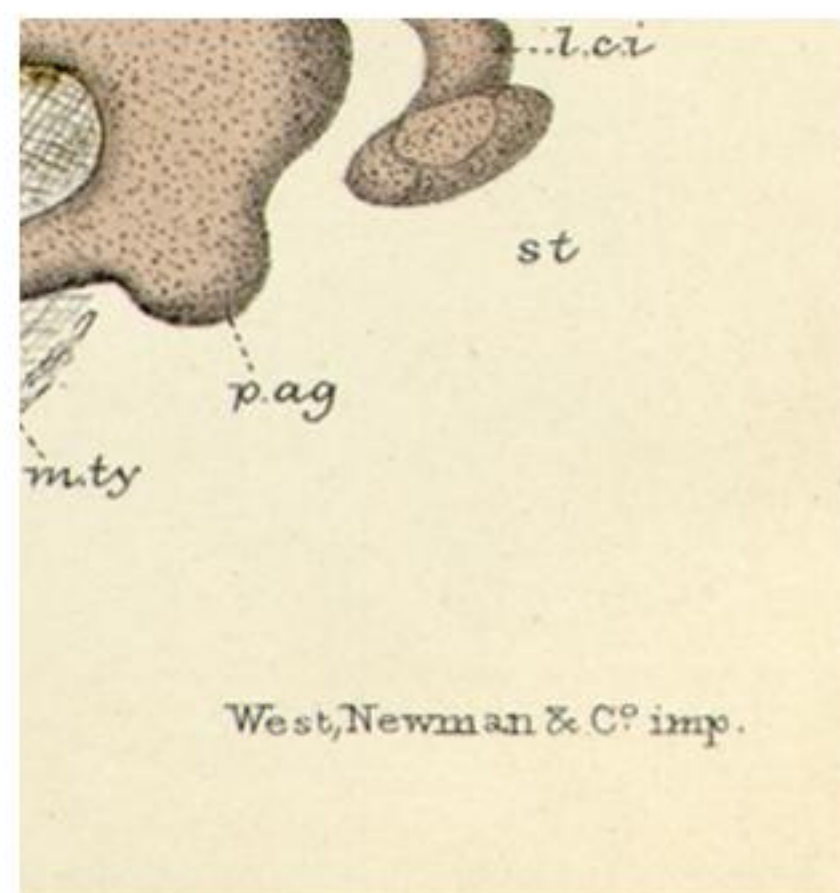


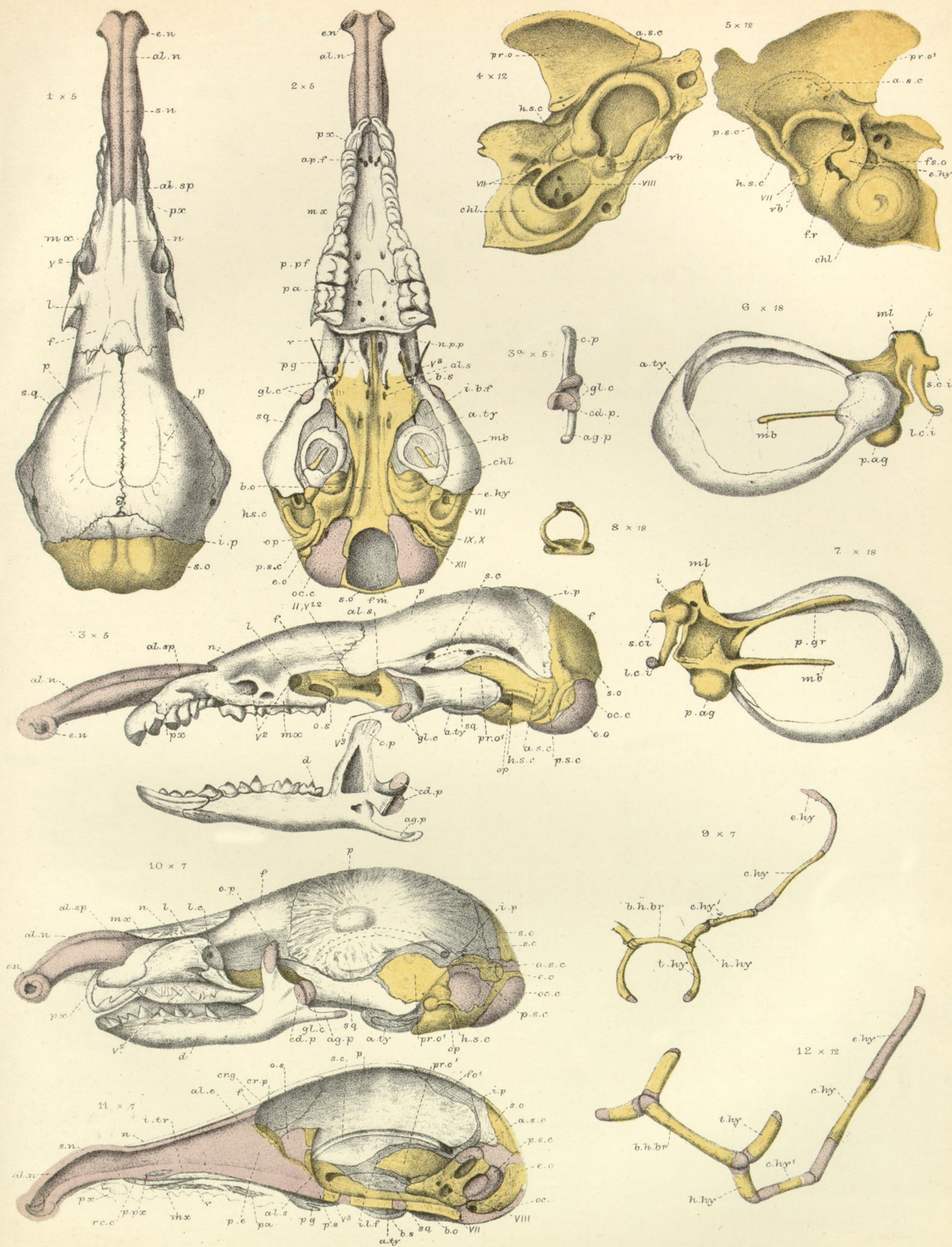




W.K.P. direx et del.
Parker & Coward lith.

Sorex Vulgaris.

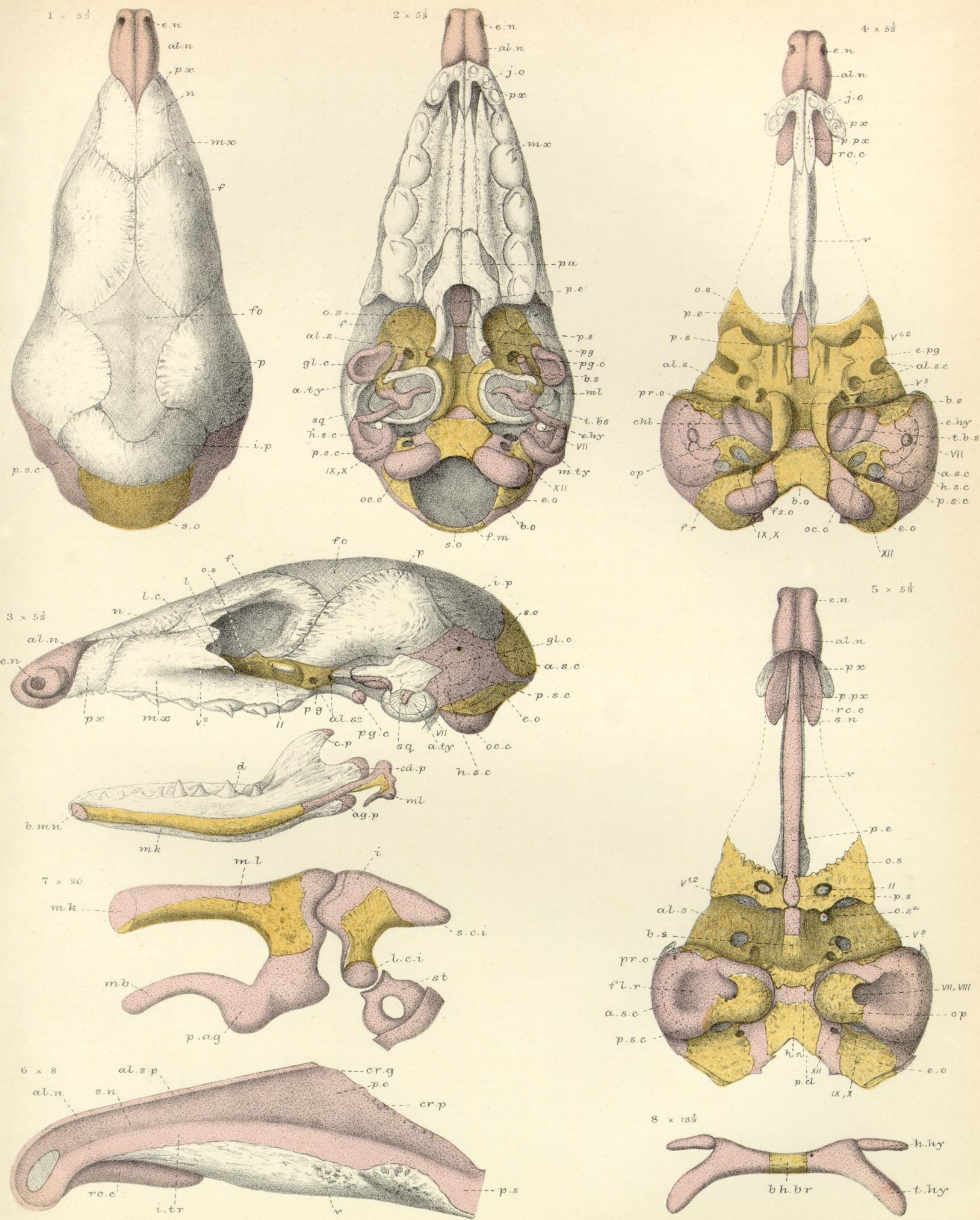




Sorex vulgaris.

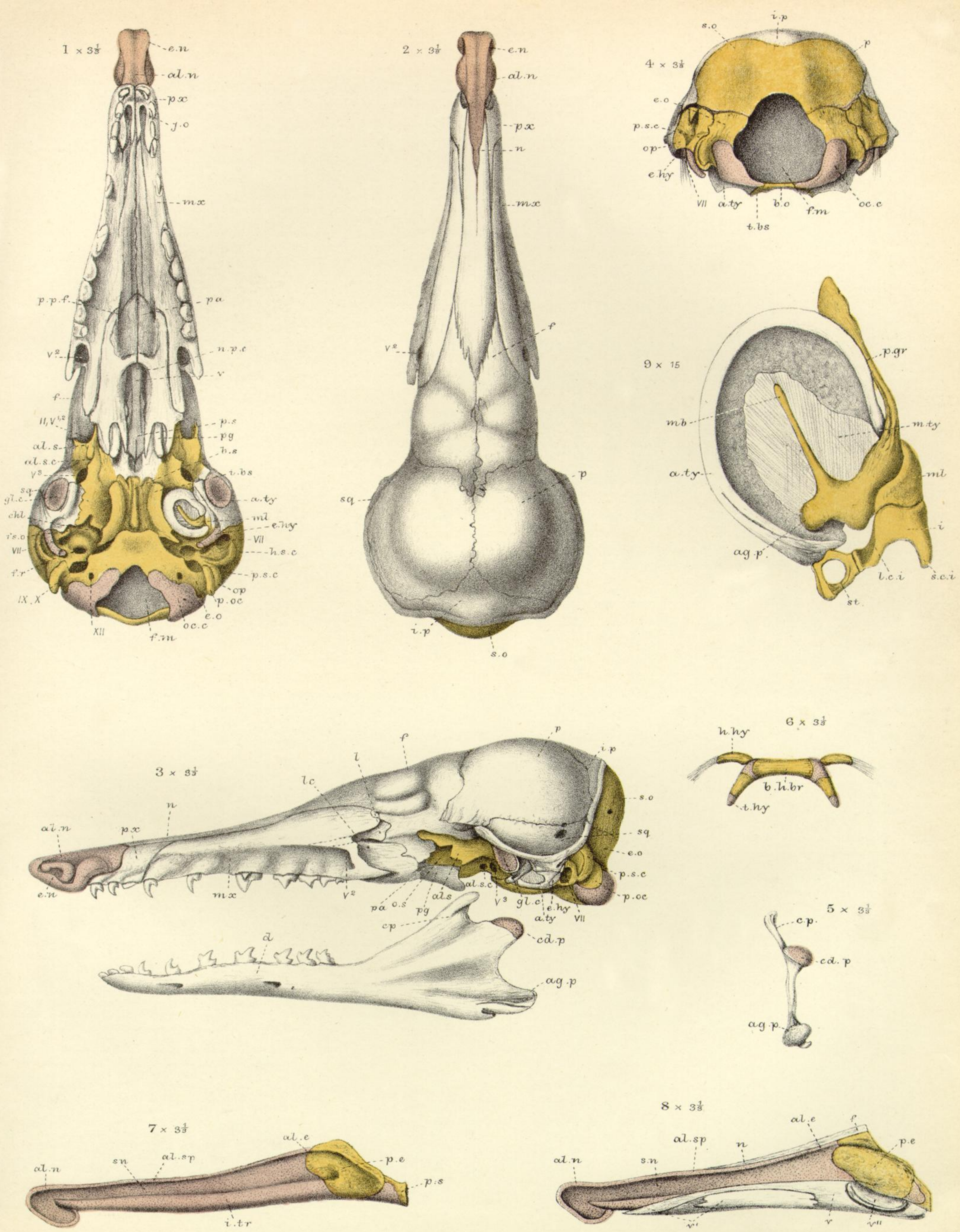
PLATE 31.

Figures.		Number of times magnified.
1	<i>Sorex vulgaris</i> (4th stage); skull of adult ; upper view .	5
2	The same ; lower view	5
3	The same ; side view	5
3A	The same ; end view of lower jaw	5
4	The same ; petromastoid bone ; inner view	12
5	The same ; outer view	12
6	The same ; malleus, incus, and tympanic ; outer view . .	18
7	The same ; inner view	18
8	The same ; stapes ; side view	18
9	<i>Sorex vulgaris</i> (4th stage); adult; hyoid arch ; inner view	7
10	The same (3rd stage); skull; side view	7
11	The same ; section ; side view	7
12	The same ; hyoid arch	12



Centetes.
PLATE 32.

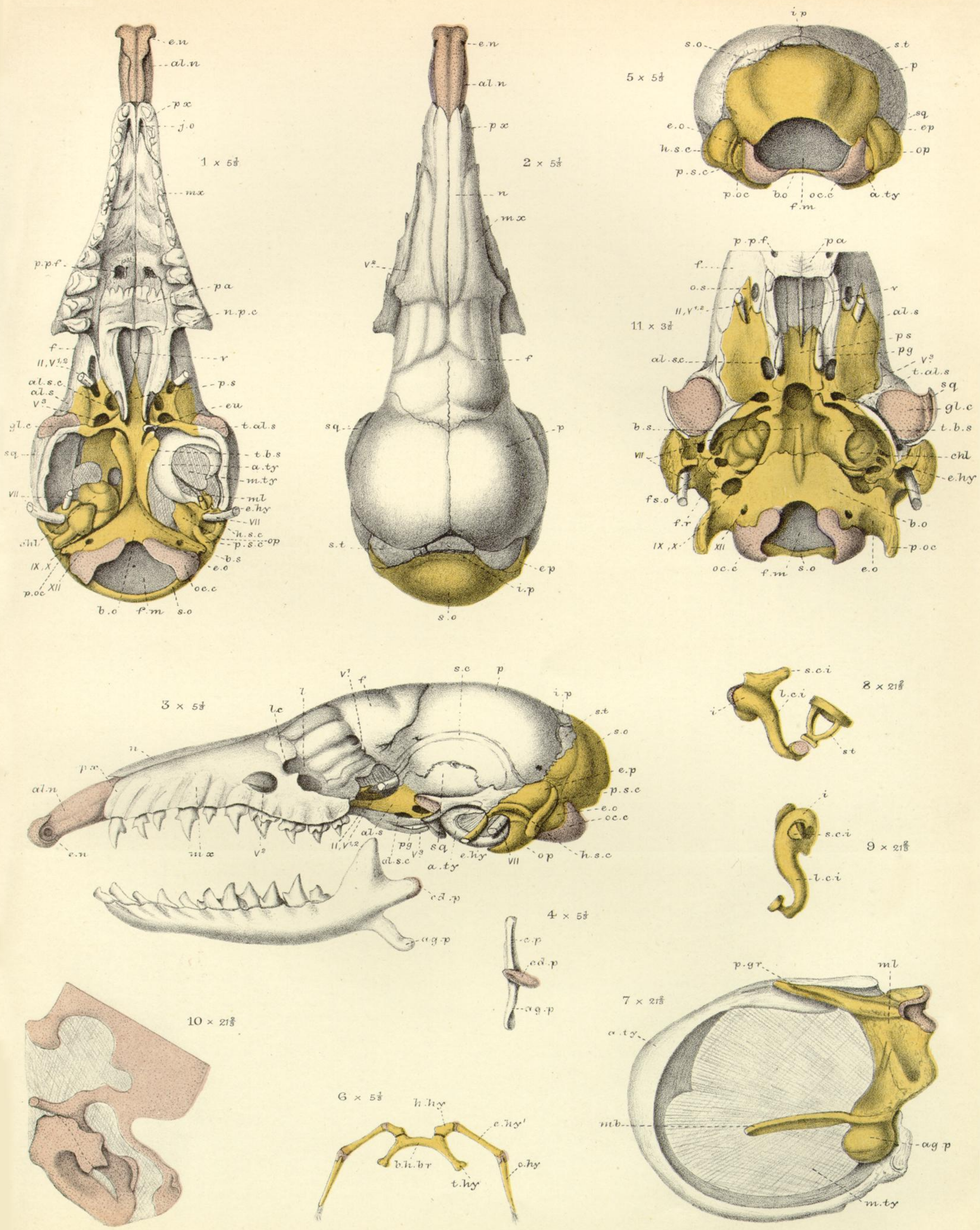
Figures.		Number of times magnified.
1	<i>Centetes ecaudatus</i> (2nd stage); embryo; $1\frac{1}{2}$ inch long; skull; upper view	$5\frac{1}{3}$
2	The same; lower view	$5\frac{1}{3}$
3	The same; side view	$5\frac{1}{3}$
4	The same; endocranium; lower view	$5\frac{1}{3}$
5	The same; upper view	$5\frac{1}{3}$
6	The same; ethmo-septal region; side view	8
7	The same; ossicula auditus; inner view	20
8	The same; hyoid arch; inner view	$13\frac{1}{2}$



Hemicentetes.

PLATE 34.

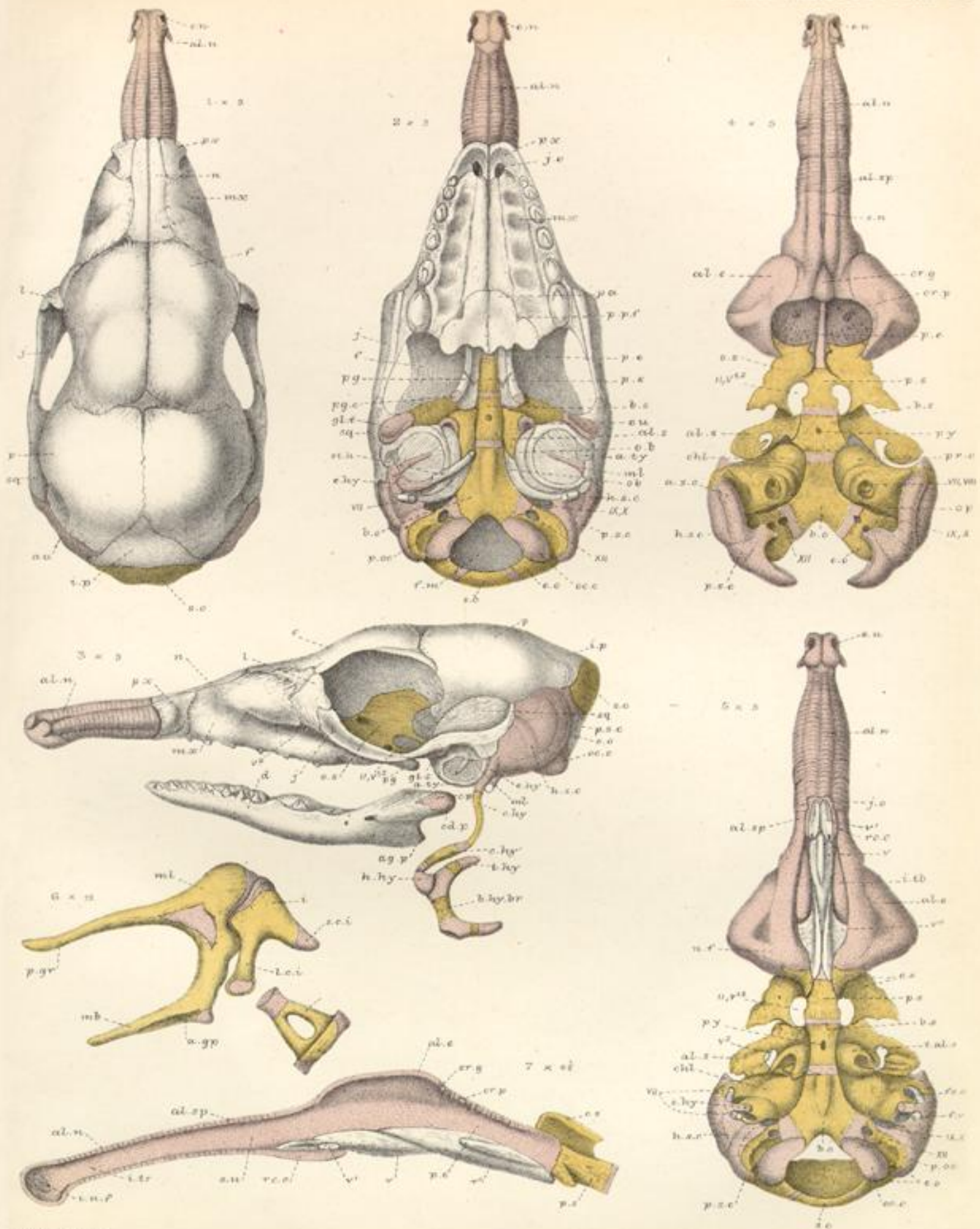
Figures.		Number of times magnified.
1	<i>Hemicentetes Madagascarensis</i> ; sub-adult; skull; lower view	3 1/3
2	The same; upper view	3 1/3
3	The same; side view	3 1/3
4	The same; end view	3 1/3
5	The same; lower jaw; end view	3 1/3
6	<i>Hemicentetes nigrescens</i> ; sub-adult; hyoid arch; inner view	3 1/3
7	The same; ethmo-septal region	3 1/3
8	The same; with vomers <i>in situ</i>	3 1/3
9	The same; ossicula and tympanic; inner view	15

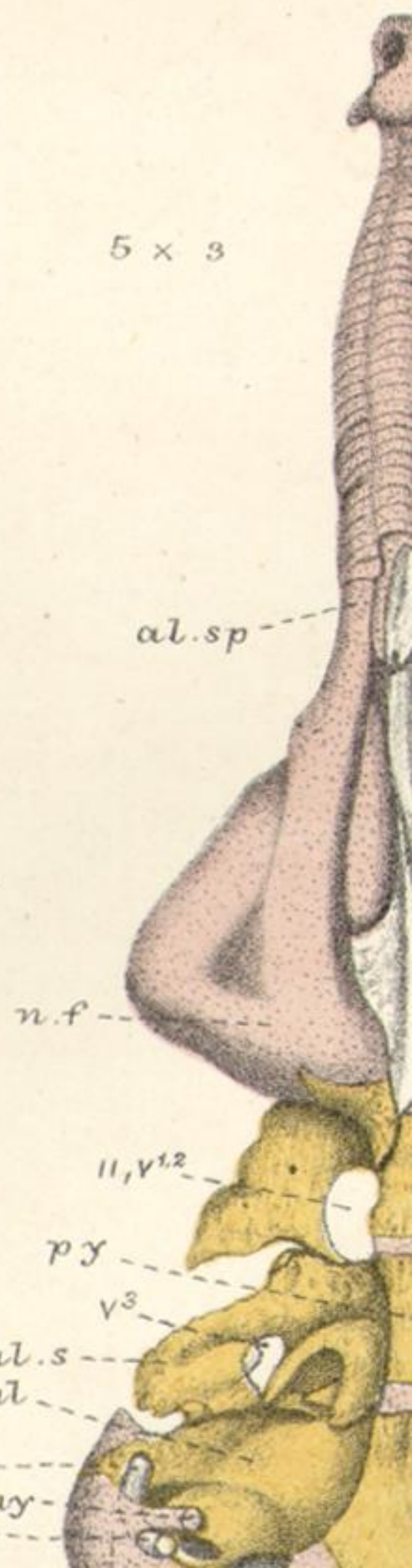
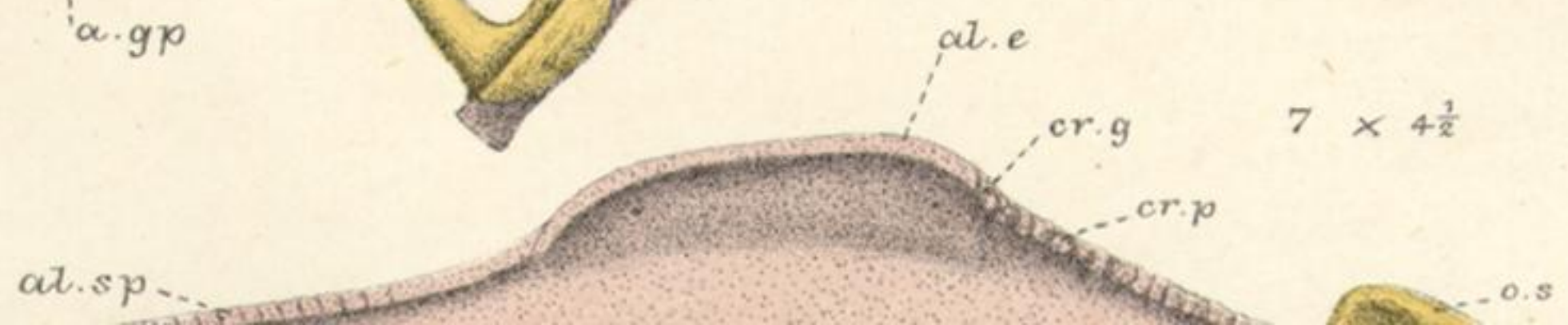
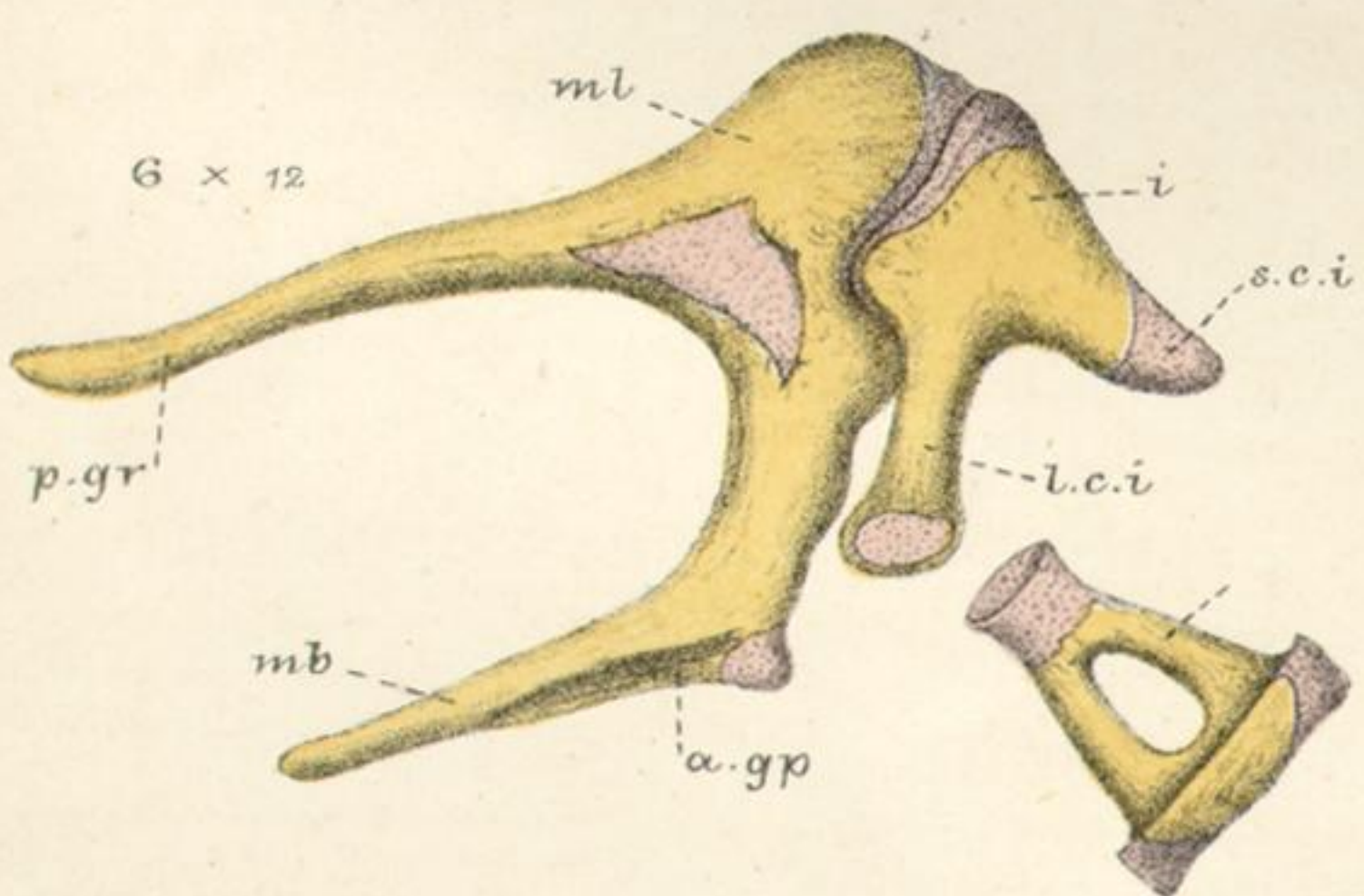
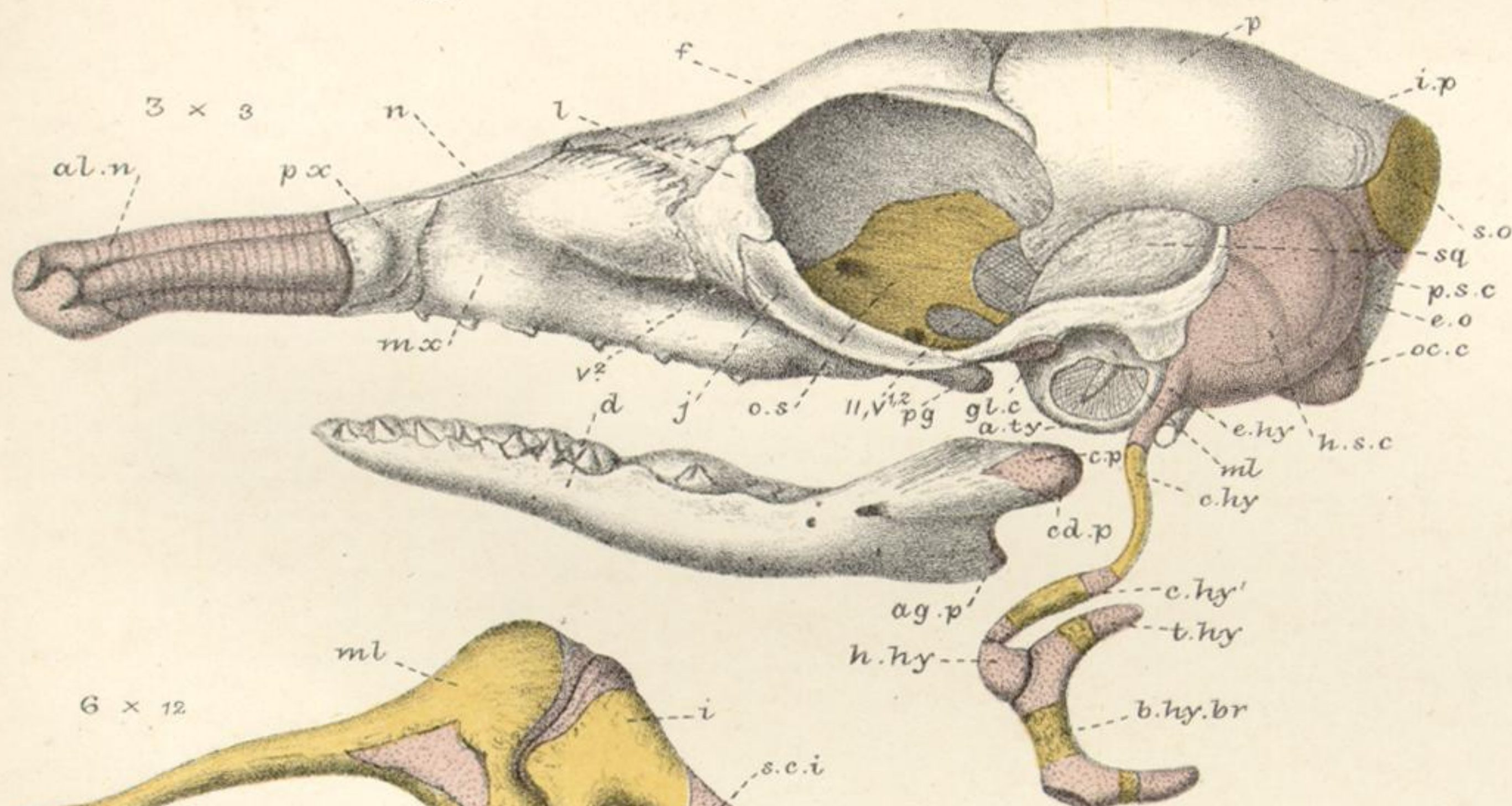
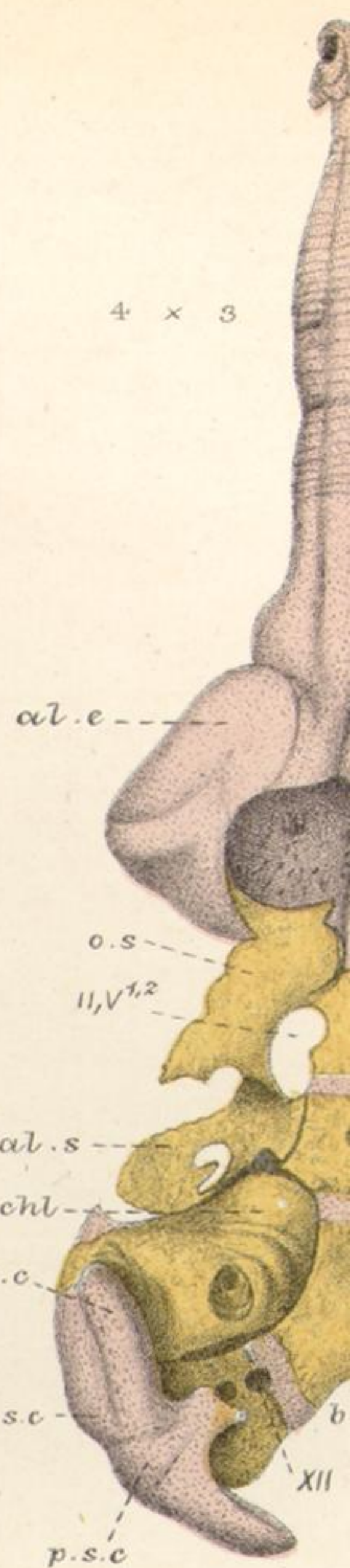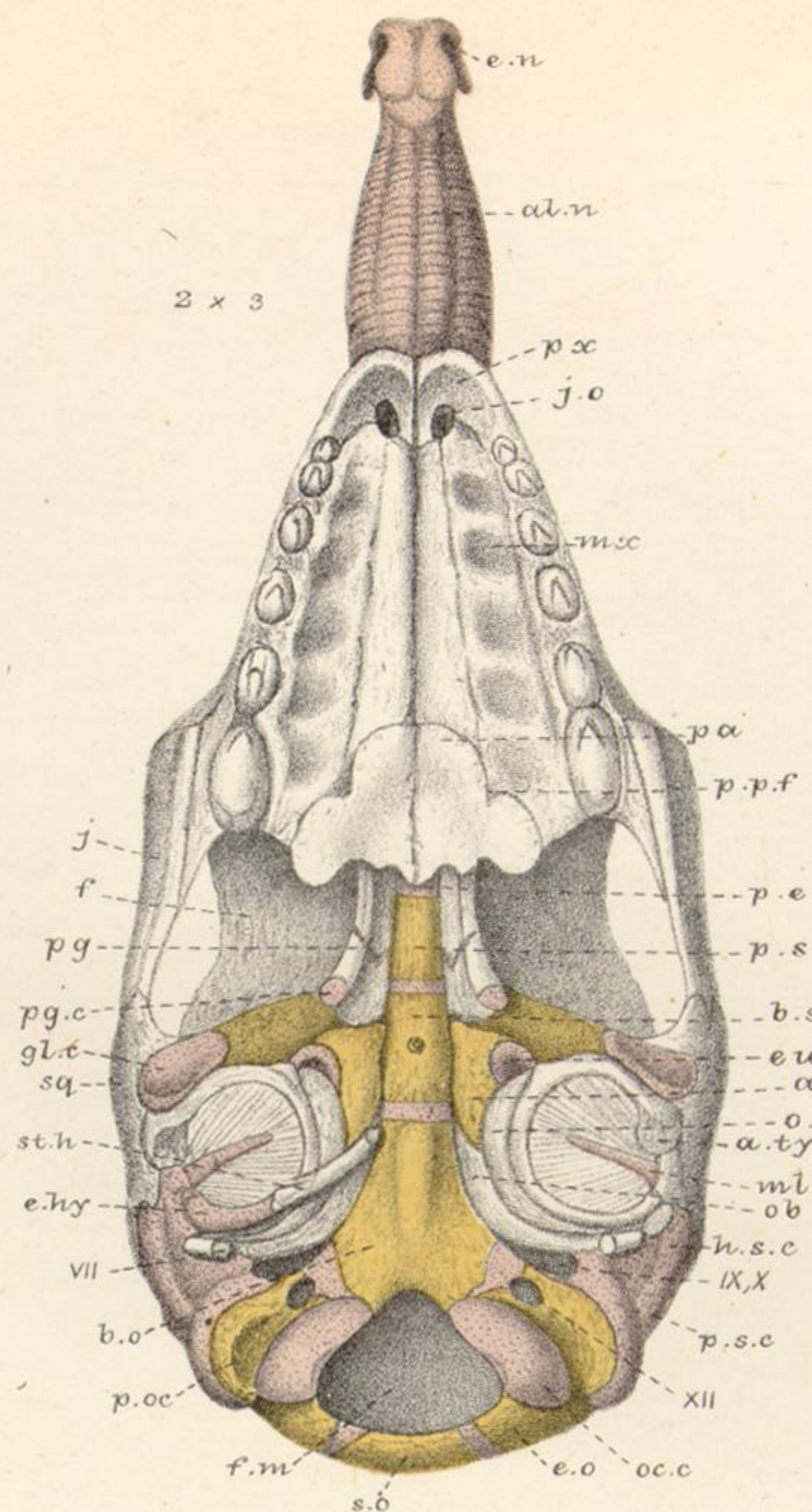
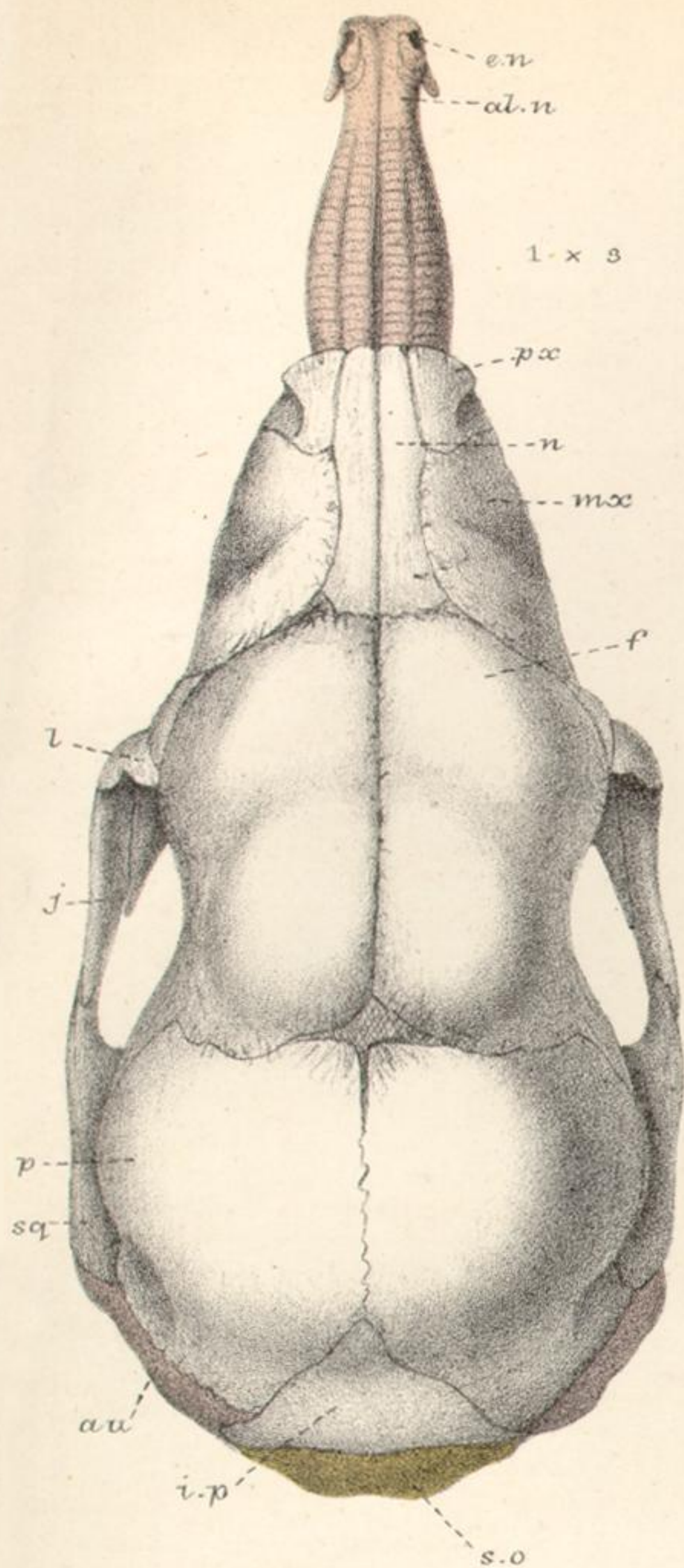


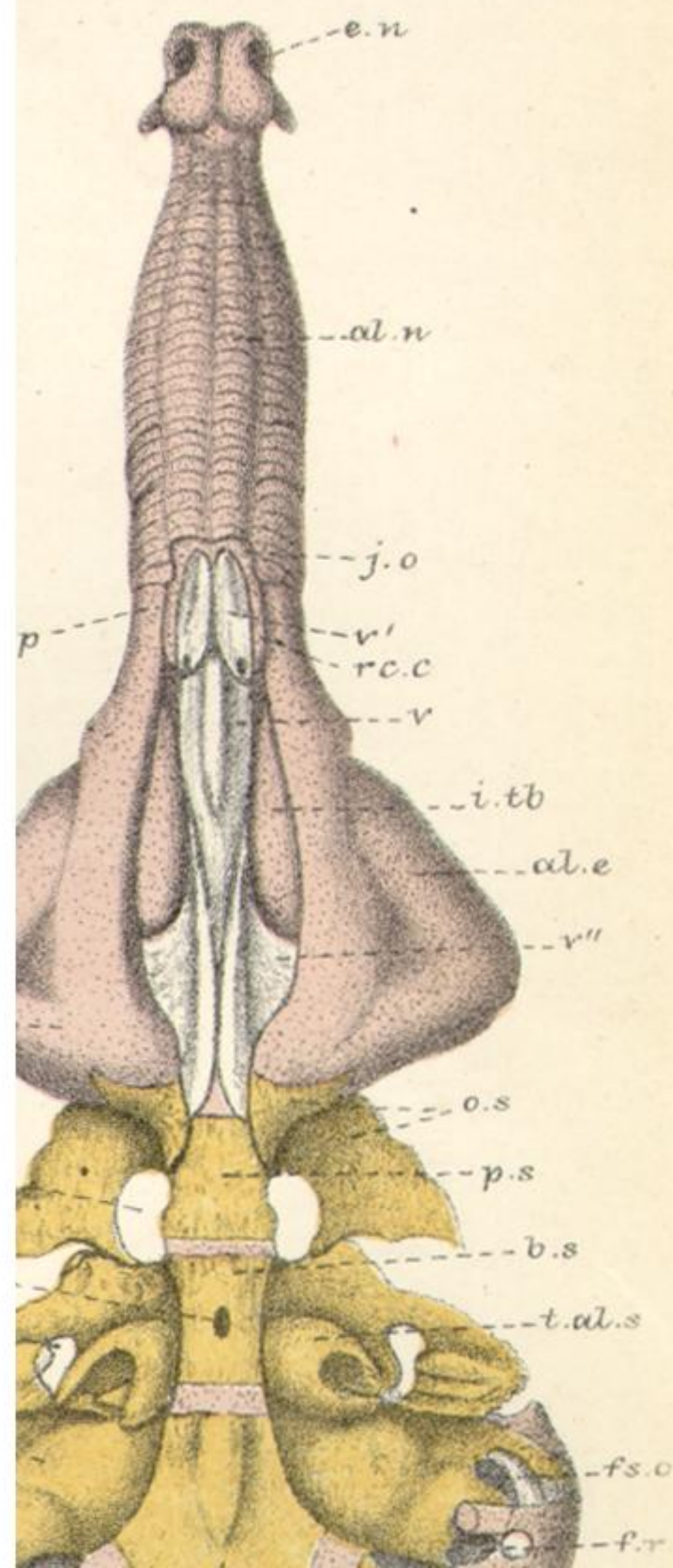
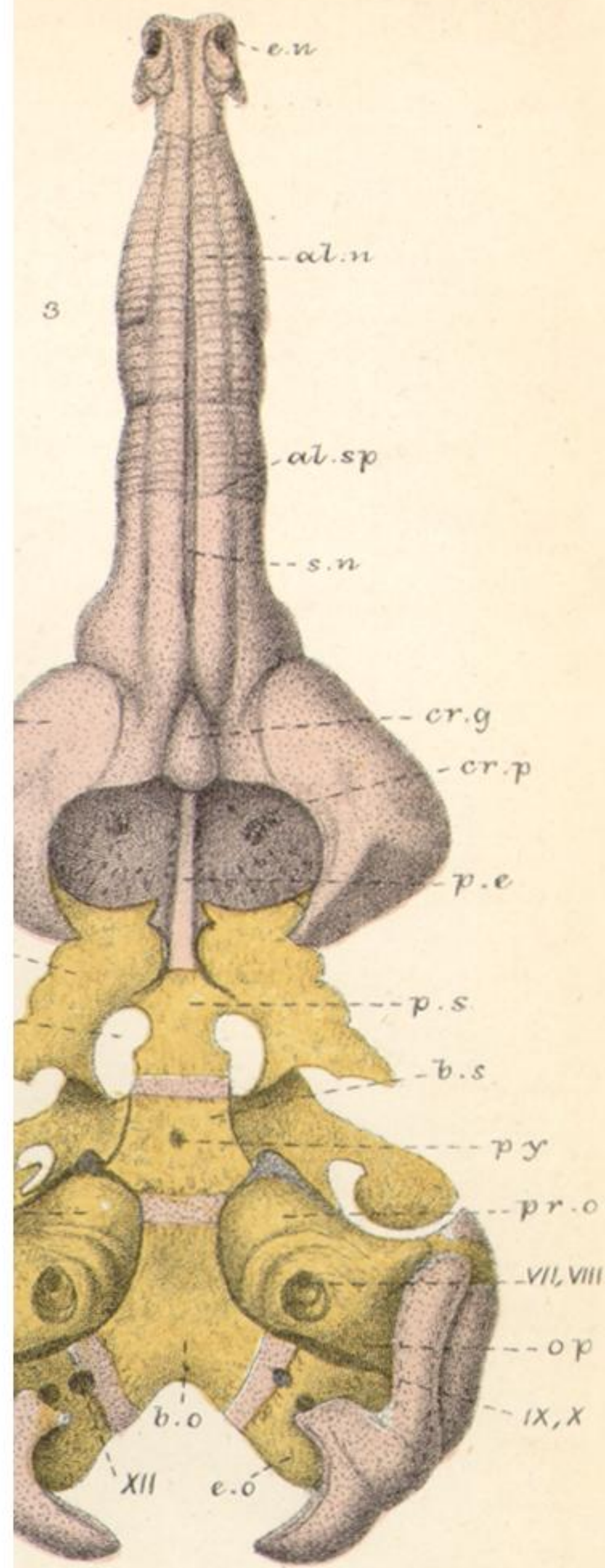
Figs.1-10. *Microgale*. Fig.11. *Ericulus*

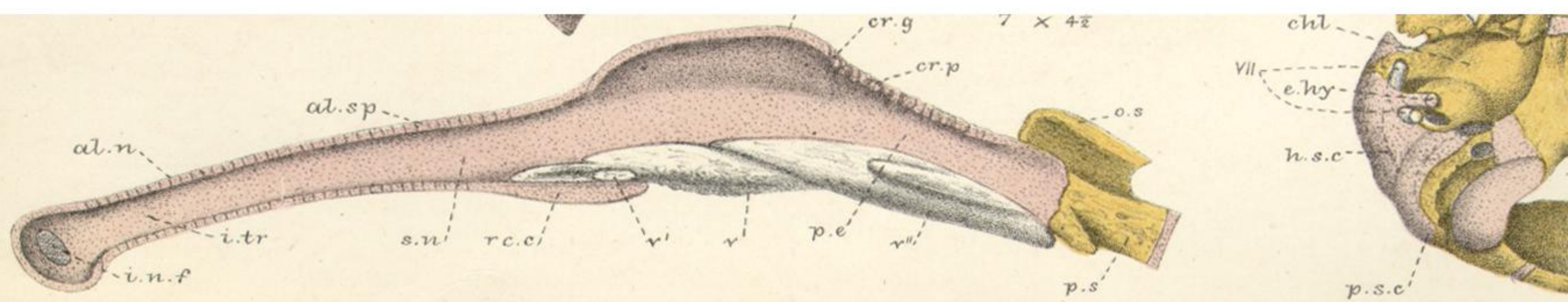
PLATE 35.

Figures.		Number of times magnified.
1	<i>Microgale longicaudata</i> ; adult; skull; lower view	5 $\frac{1}{3}$
2	The same; upper view	5 $\frac{1}{3}$
3	The same; side view	5 $\frac{1}{3}$
4	The same; end view of lower jaw	5 $\frac{1}{3}$
5	The same; skull; end view	5 $\frac{1}{3}$
6	The same; hyoid arch; inner view	5 $\frac{1}{3}$
7	The same; malleus and tympanic; inner view	21 $\frac{2}{3}$
8	The same; incus and stapes; inner view	21 $\frac{2}{3}$
9	The same; incus; outer view	21 $\frac{2}{3}$
10	The same; meatus-cartilage	21 $\frac{2}{3}$
11	<i>Ericulus nigrescens</i> ; adult; lower view of skull (part)	3 $\frac{1}{3}$



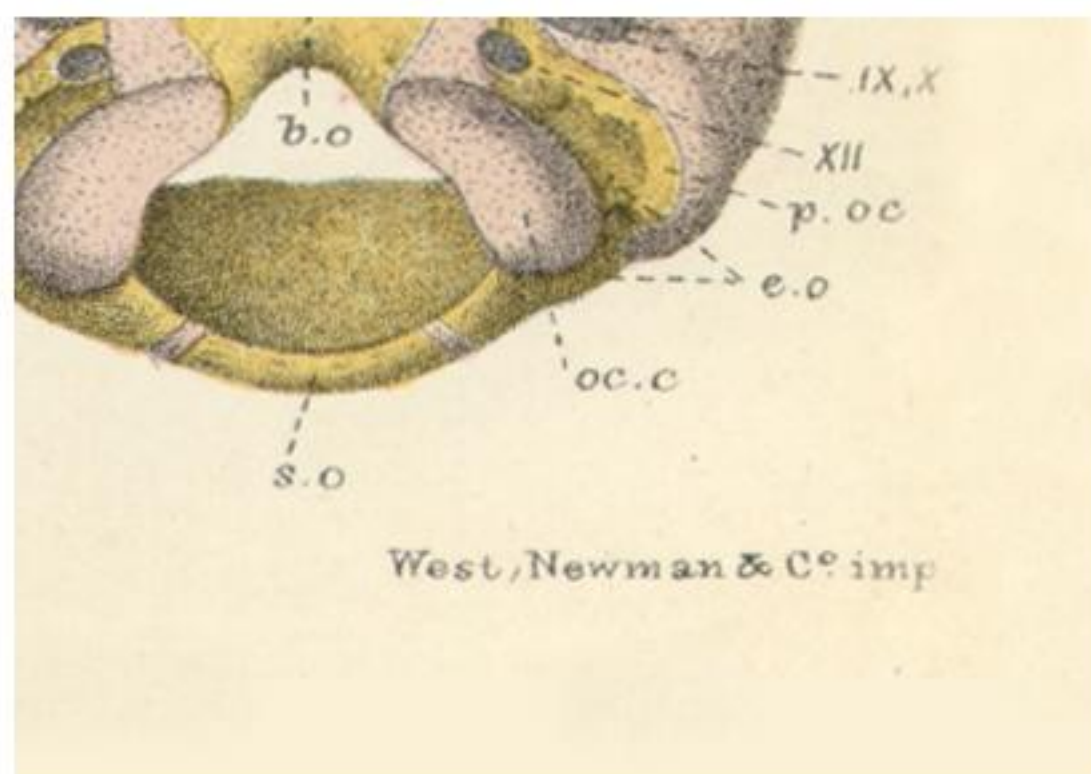


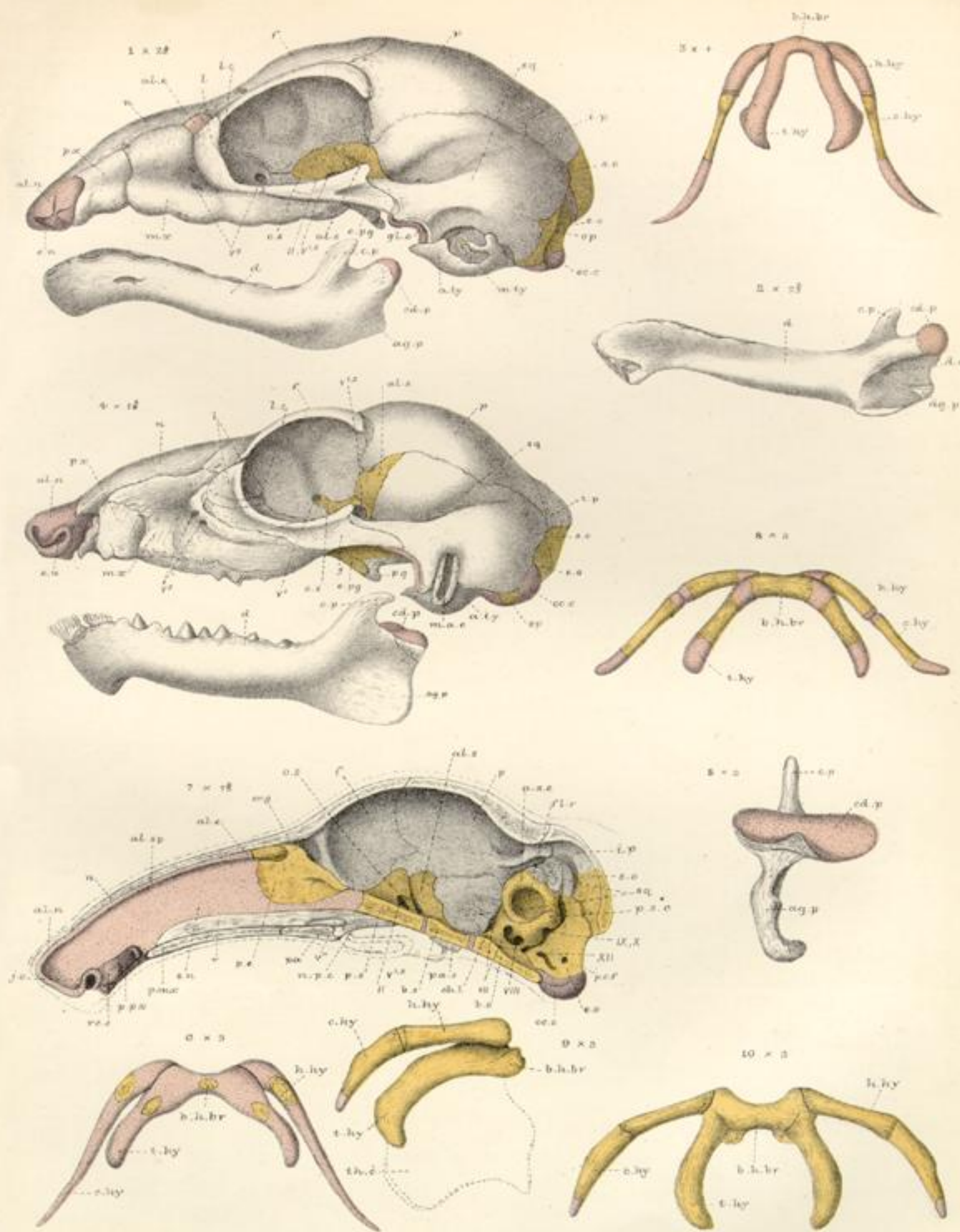




W.K.P. del. ad. nat.
Parker & Coward lith.

Rhynchoceyon.

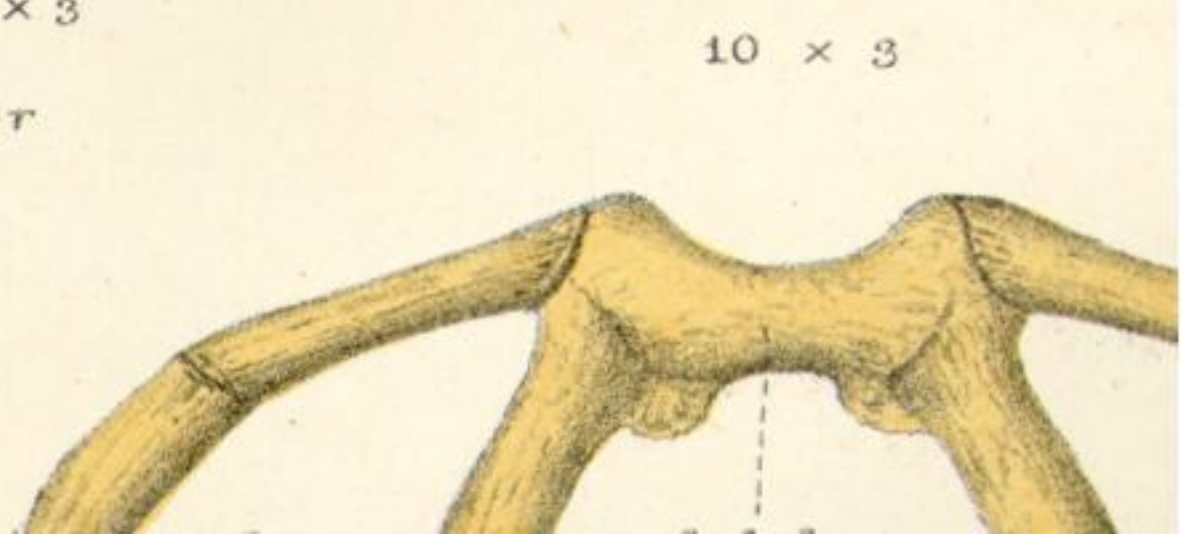
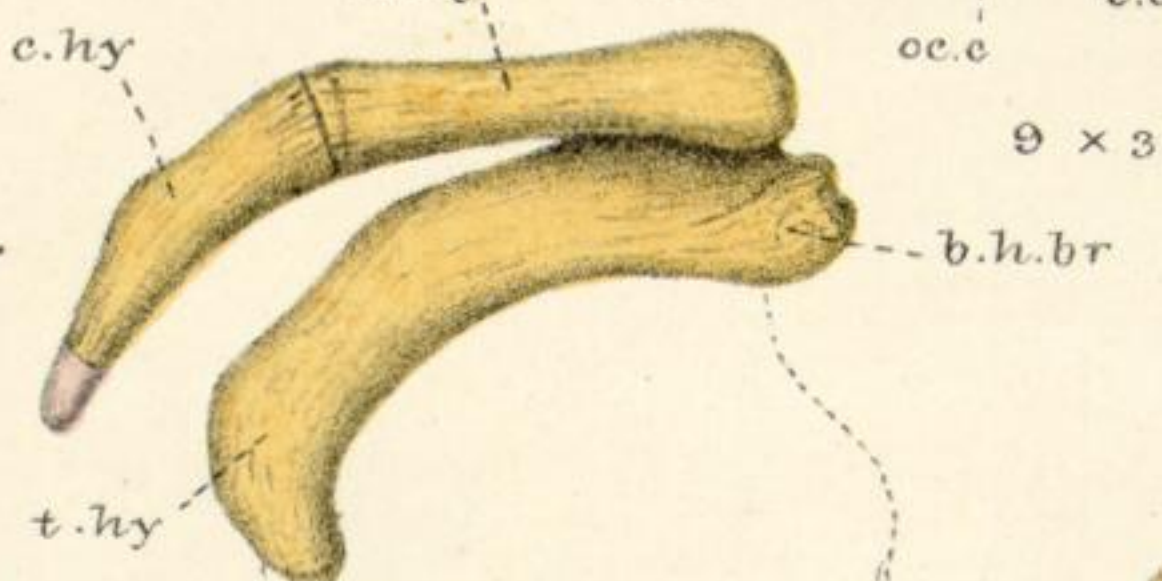
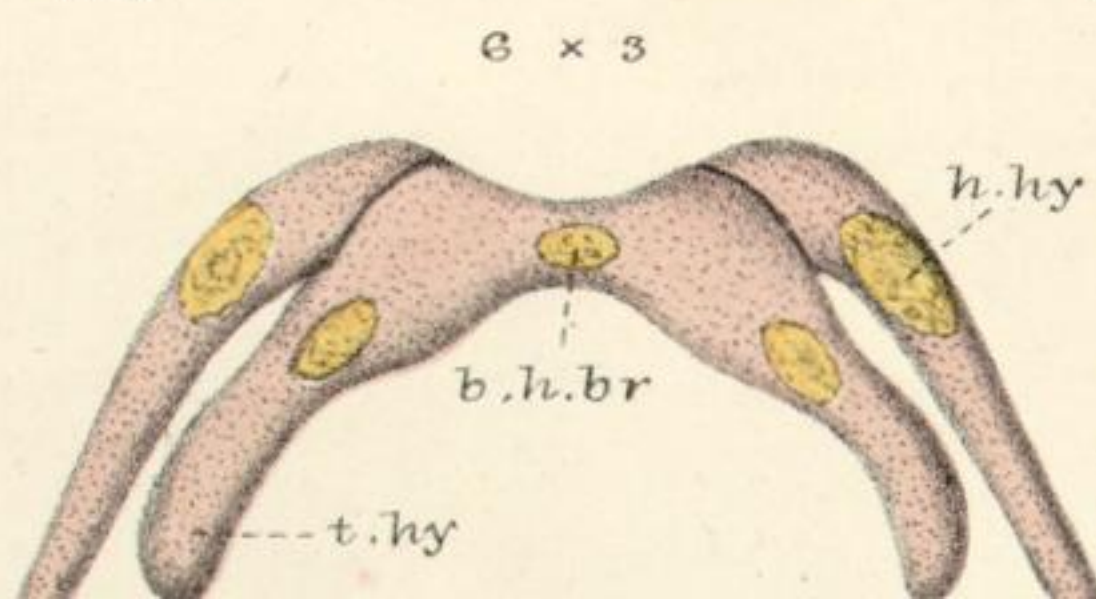
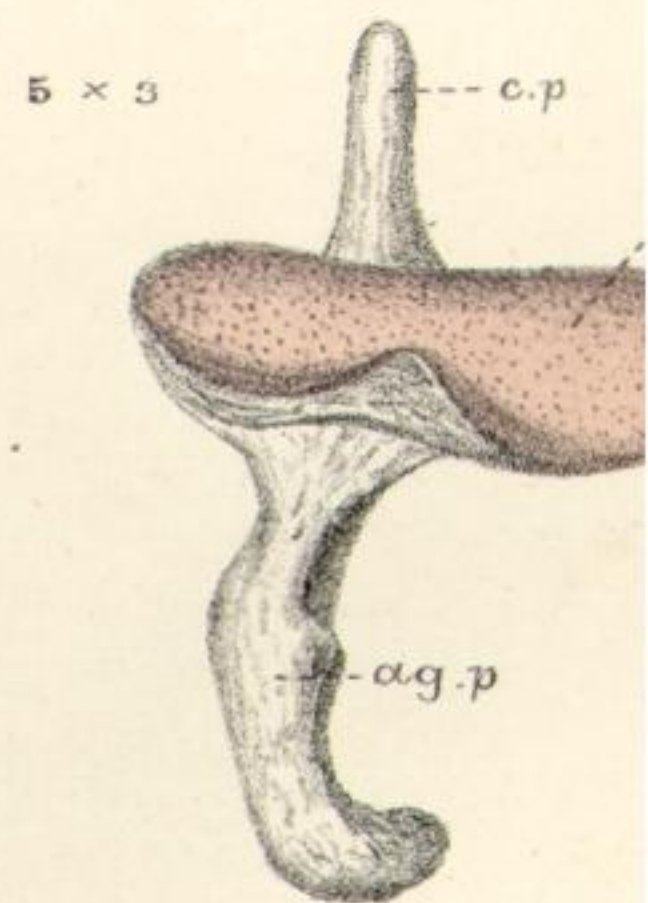
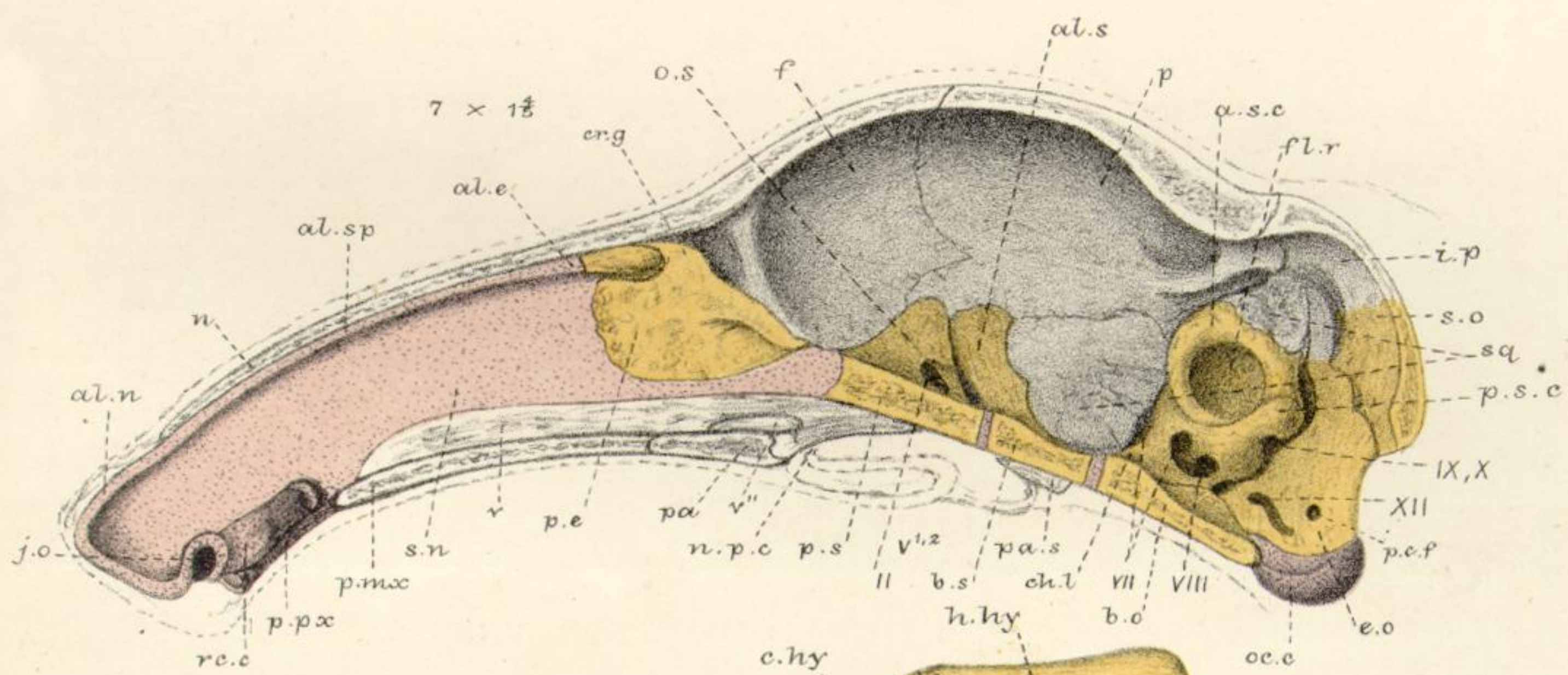
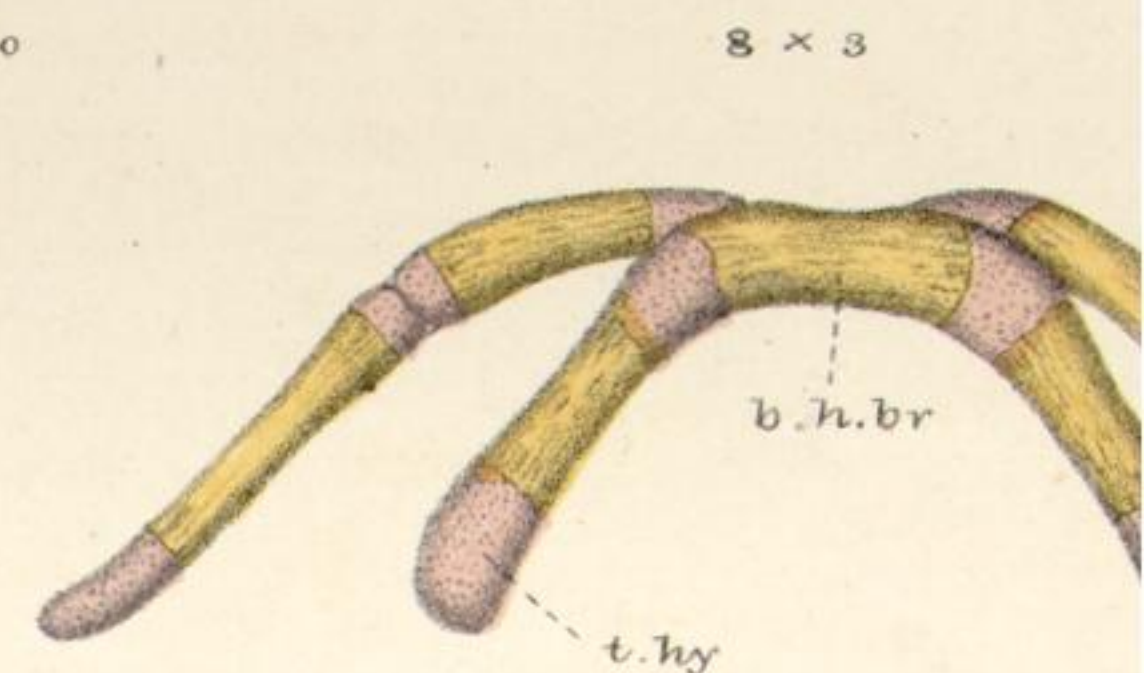
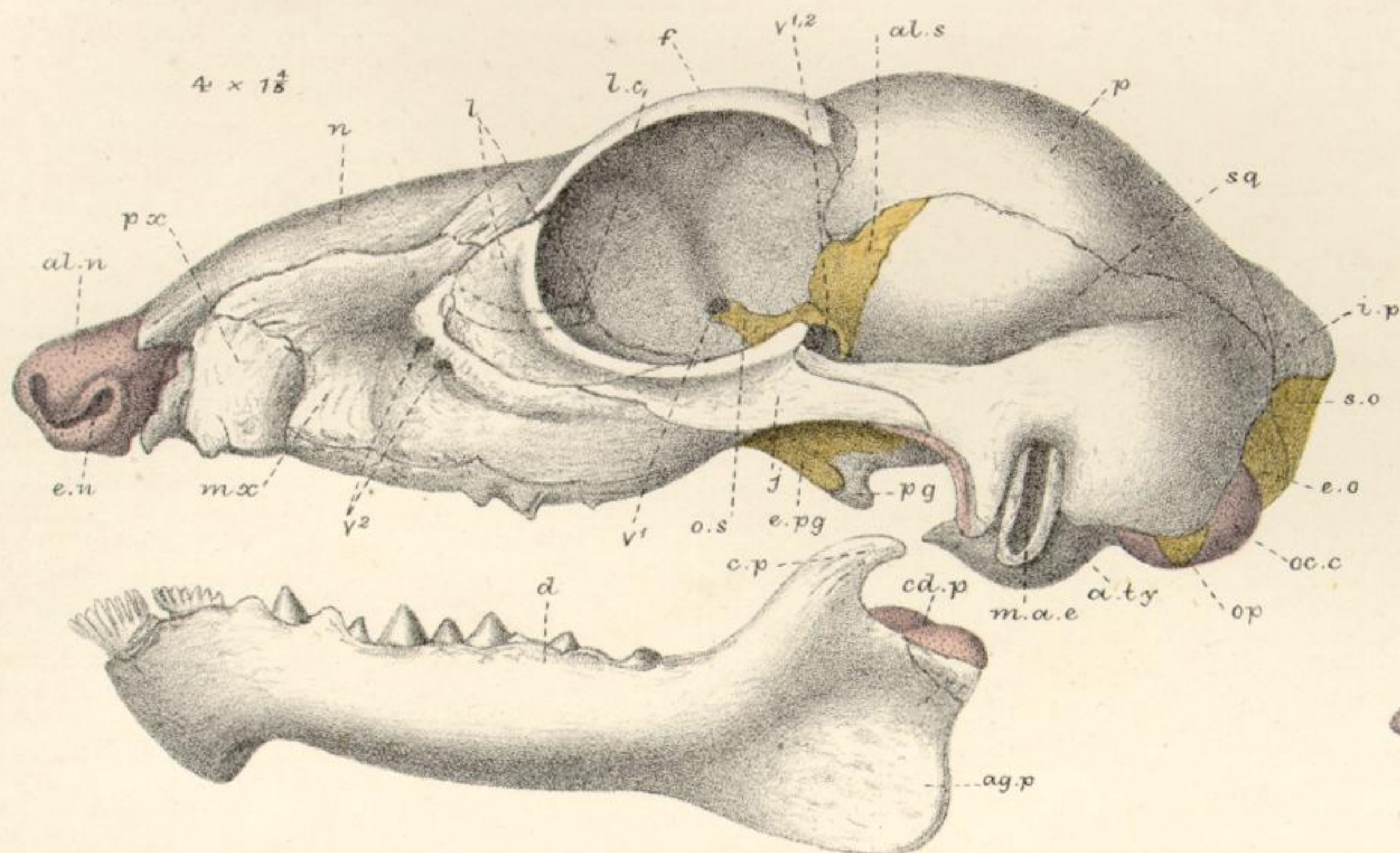
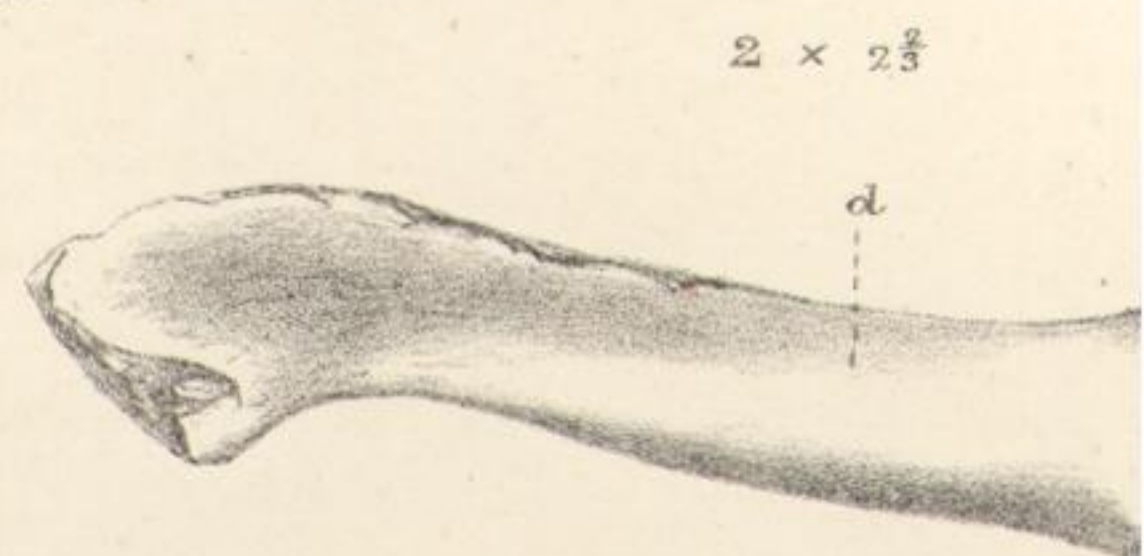
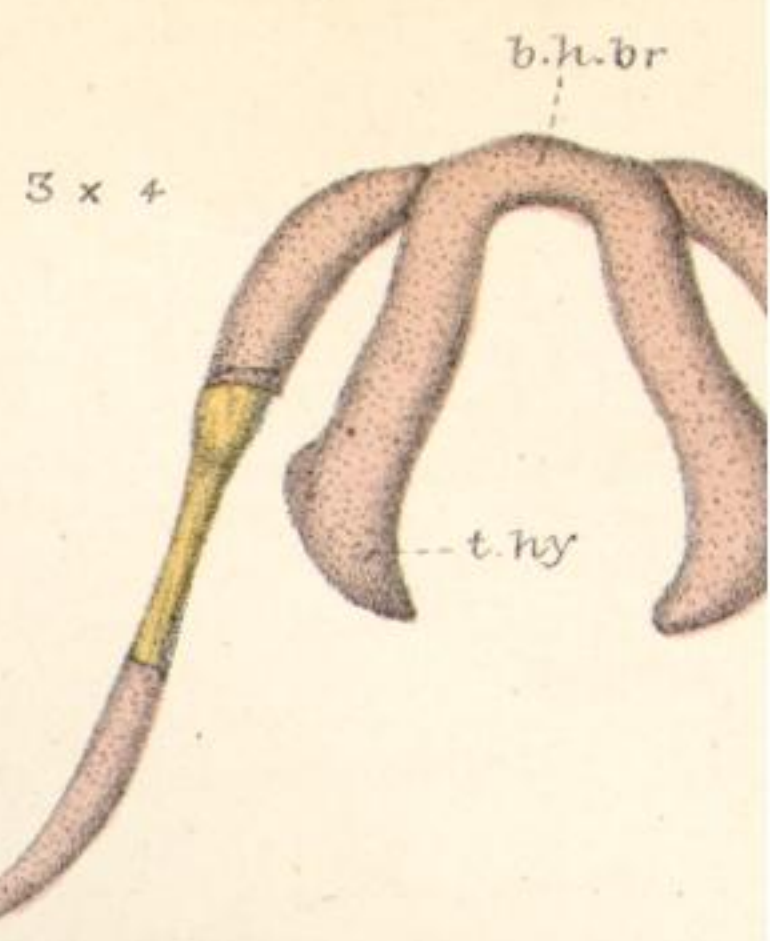
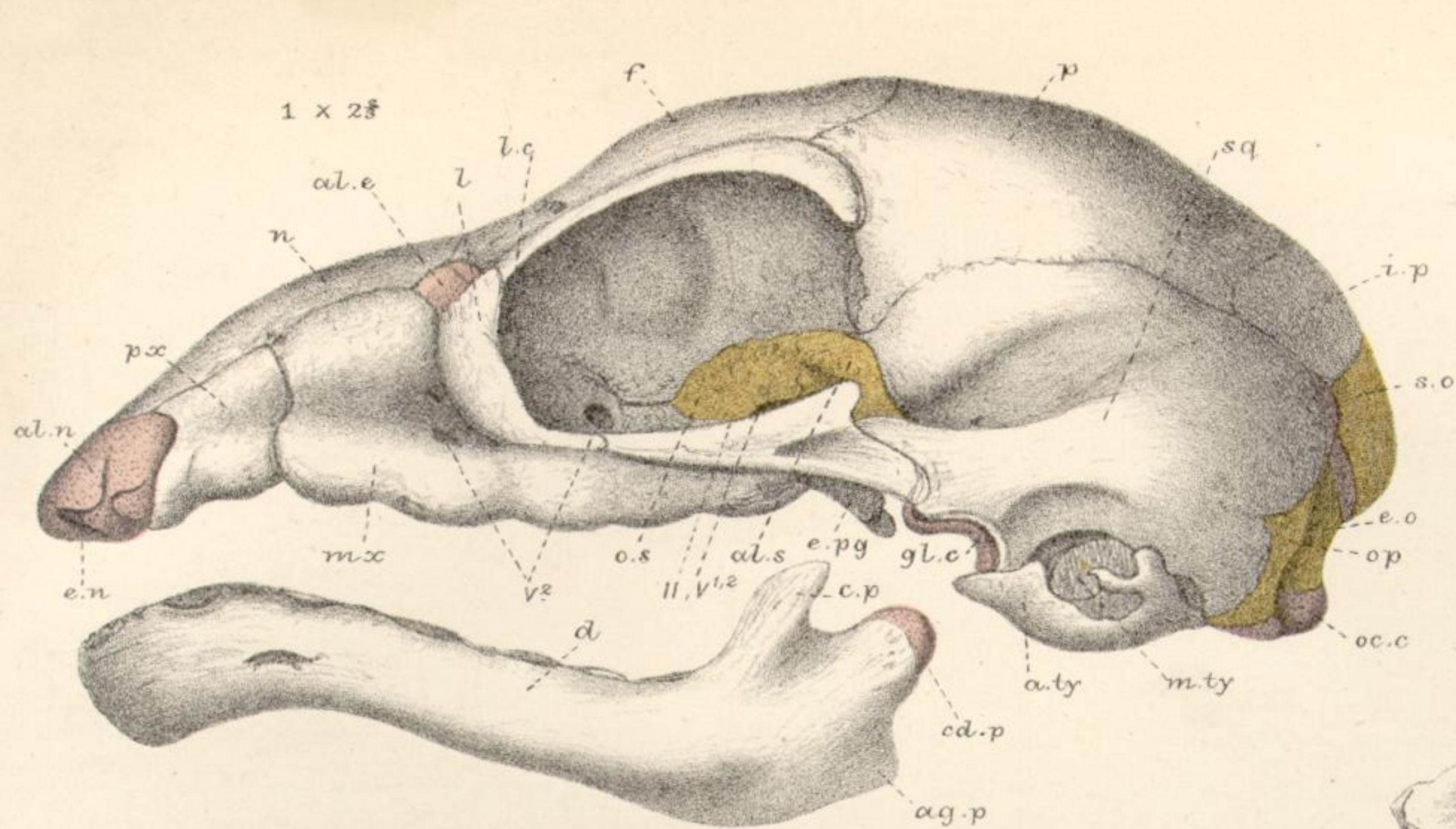


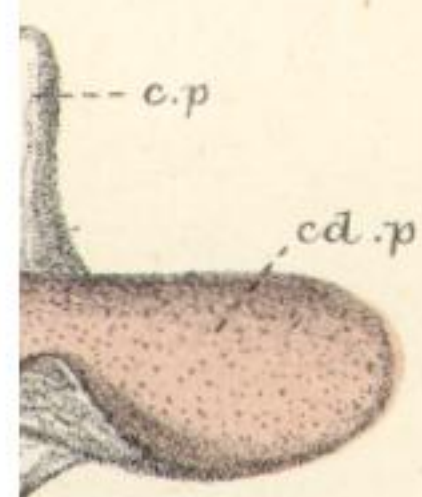
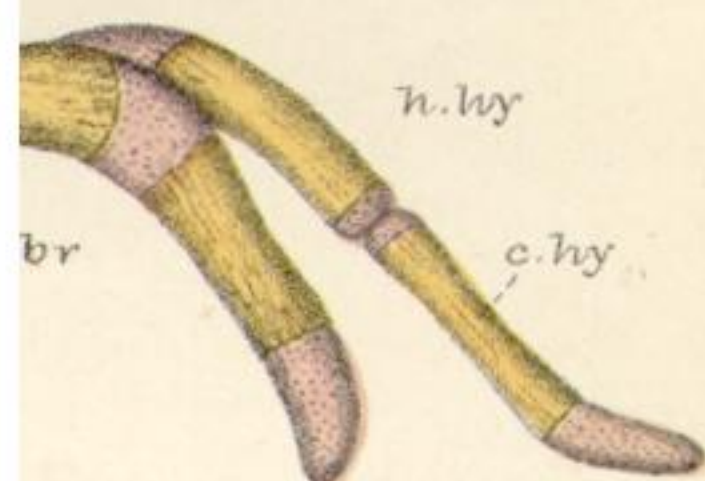
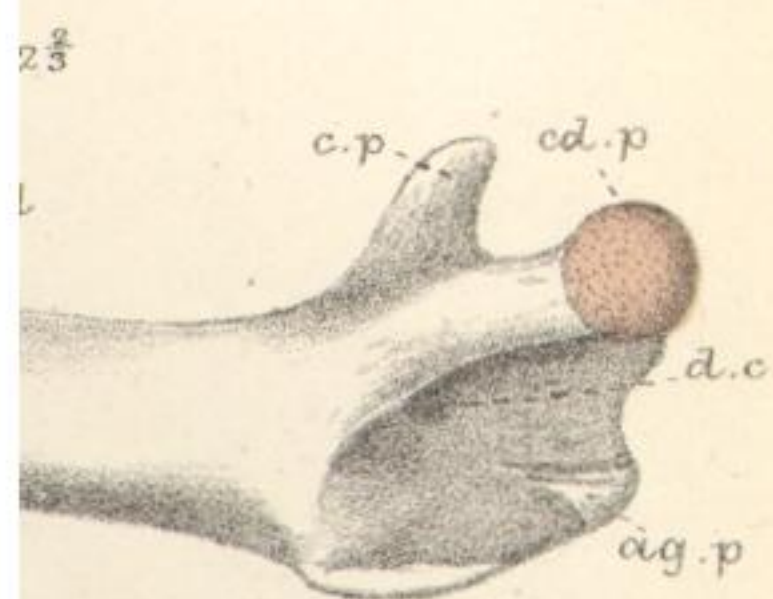
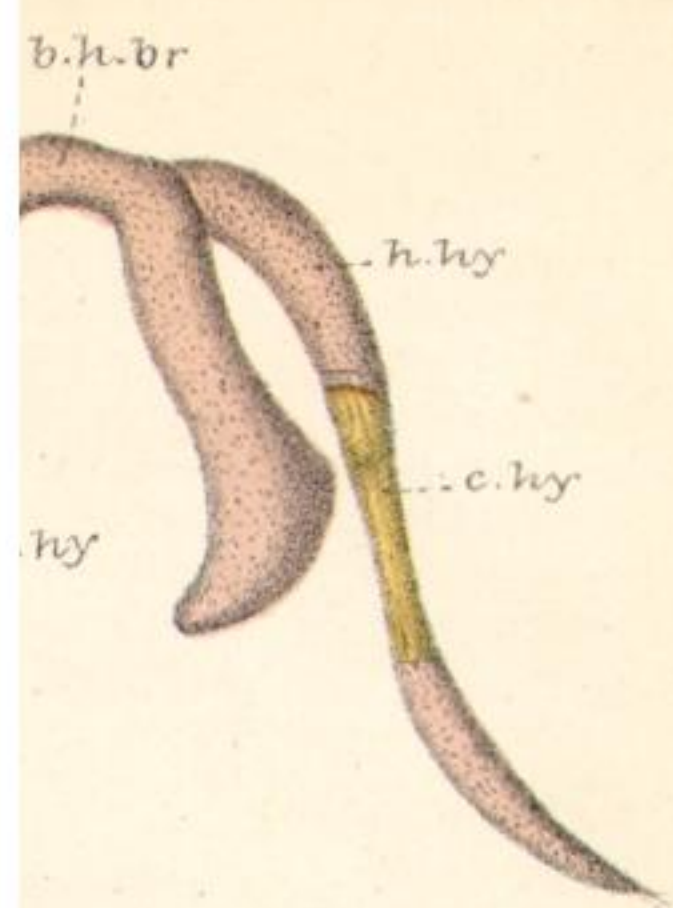


W.K.P. del. et aut.
Furness & Howard lith.

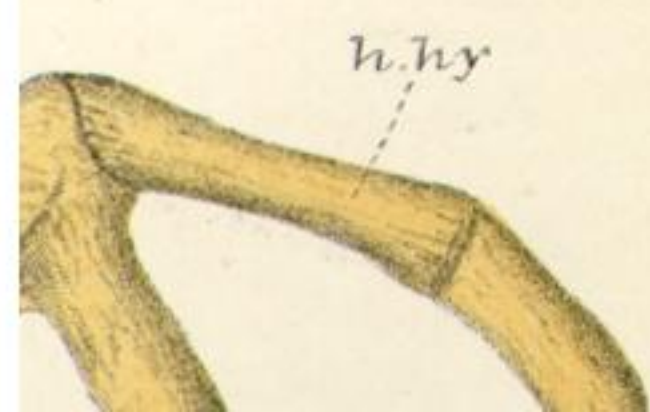
Went, H. & C. C. Corp.

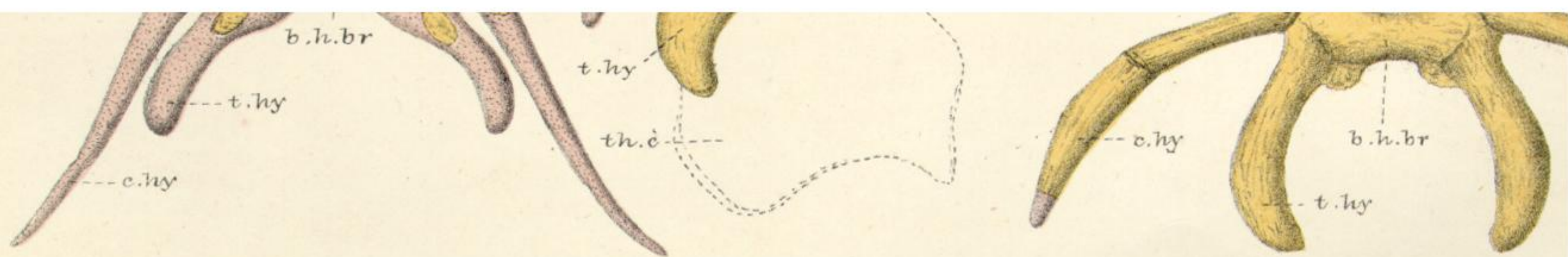Caleopithecus.





ag.p






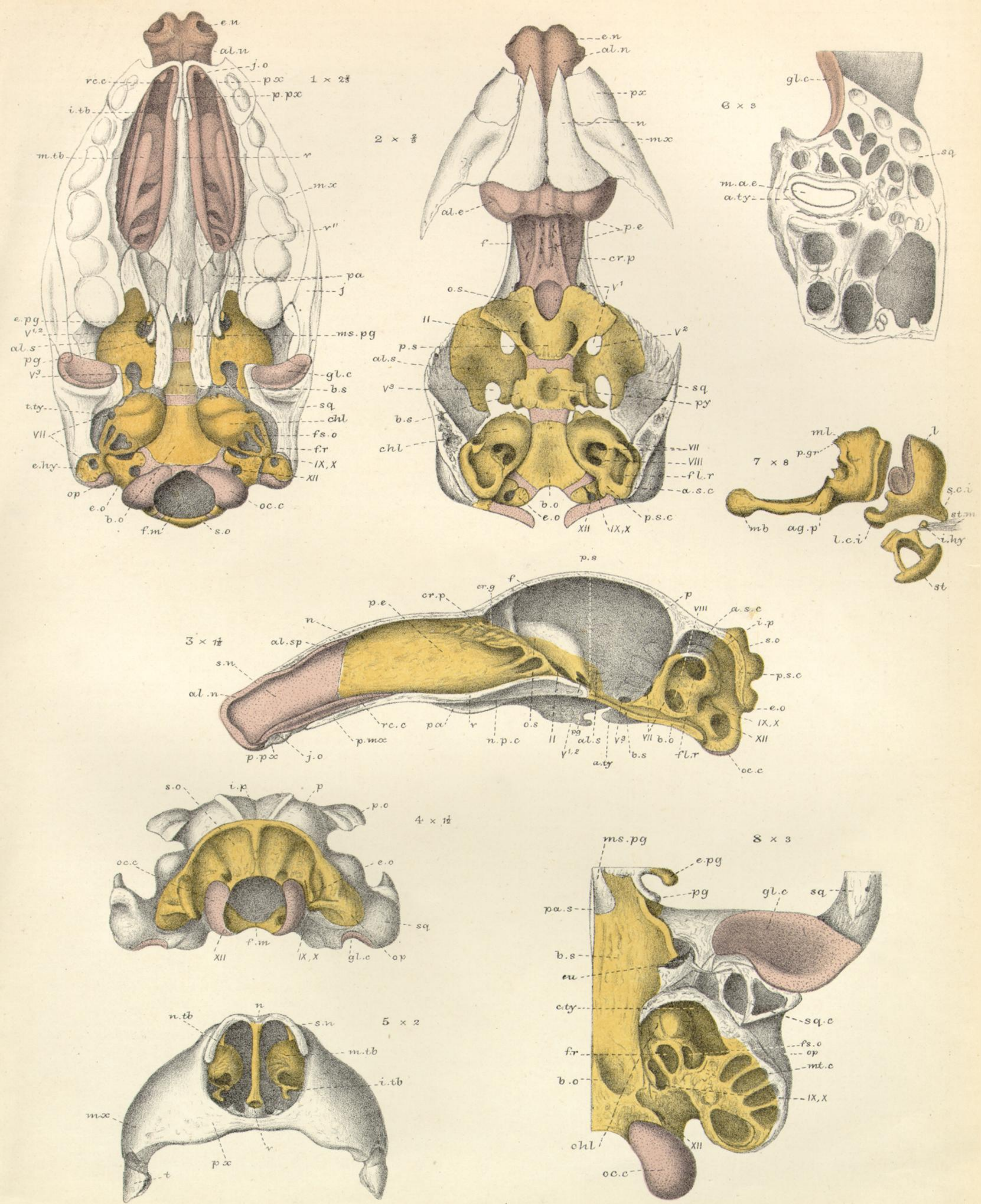
W.K.P. del. ad nat.
Parker & Coward lith.

Galeopithecus.

We



West, Newman & C^o imp.



Galeopithecus.
PLATE 39.

Figures.		Number of times magnified.
1	<i>Galeopithecus volans</i> (1st stage); endocranium; lower view	2 ² / ₃
2	The same; upper view	2 ² / ₃
3	<i>Galeopithecus philippensis</i> (4th stage); adult; section of skull	1 ¹ / ₂
4	The same; end view.	1 ¹ / ₂
5	The same; front view	2
6	The same; vertical section of temporal region	3
7	The same; ossicula auditus; outer view	8
8	The same; lower view of skull, with part sawn away.	3