

XVII. *On the Development of the Ductless Glands in the Chick.**By* HENRY GRAY, *Esq.*, *F.R.S.*, *Demonstrator of Anatomy at St. George's Hospital.**Communicated by* WILLIAM BOWMAN, *Esq.*, *F.R.S.*

Received November 12, 1851,—Read January 15, 1852.

HAVING been engaged for some period in investigating the evolution of the spleen, supra-renal and thyroid glands, and the several tissues of which each is composed, and having arrived at some conclusions which differ from those previously given, I have ventured to lay them before the Royal Society.

Development of the Spleen.

Before describing the results of my own investigations, I may mention that ARNOLD* states that the spleen arises like the pancreas from the duodenum, and exists at first as a common mass with that gland; whilst BISCHOFF† believes that it arises from a mass of blastema, at first common both to this organ and the pancreas, that forming the pancreas proceeding from the duodenum, and that of the spleen from the great curvature of the stomach.

The description which I now propose to offer, differs from either of those above mentioned.

About the seventy-second hour (Plate XXI. fig. 1), I found in the embryo of the chick that the vitelline sac had already sufficiently contracted to form two canals, of which the posterior was small, and only just observable; but the anterior one was much larger and longer, and took a somewhat tortuous course through the body of the embryo. No trace of either pancreas or spleen is yet to be observed, but a conical protrusion from the inferior part of this tube indicates the first rudiment of the liver.

At the ninetieth hour (fig. 2) the anterior of the two canals is longer and narrower than the posterior; it presents two slight dilatations, the first in the situation where the liver and pancreas are developed, the second, and larger, immediately in front of this, indicating the position of the future stomach. It is at the first-mentioned dilatation, at its upper part, and behind the stomach, that the pancreas is developed. This rudimentary gland, at this period, consists of a flask-shaped mass of dark granular blastema, connected by a broad peduncle with the wall of the intestinal tube, from which it is apparently a protrusion, being of a similar structure with it. That part connected with the intestine is narrow and tubular, its distal portion being

* F. ARNOLD, Salz. Med. Zeitung, 1831, T. W. p. 301.

† T. L. BISCHOFF, *Entwick. der Säugthiere und des Menschen.* Leipzig; 1842, p. 285.

spherical, and its surface slightly lobulated. There is no trace of any subdivision of this body into two portions, nor at its distal end can any trace of a spleen be as yet observed. Nearly the whole length of the above mentioned two canals have connected with them above a delicate fold of membrane, the "intestinal lamina," which serves to connect them with the vertebral column beneath. At the 114th hour (fig. 3) the anterior prolongation of the vitelline sac presents a double curvature, the concavity of one being directed towards the under, the other towards the upper surface of the embryo; it is in this latter that the rudimentary pancreas may now be clearly seen. This organ now appears as an elongate, dark granular, tubular mass, situated in that curved portion of the intestinal canal which is the rudiment of the duodenum; its direction is in the transverse axis of the embryo, one extremity being connected to the primitive intestinal tube, into which it may be seen to open by a distinct tubular prolongation, the other being separated from the spleen by a distinct granular blastema; its margins are not very distinct, and its contents and wall are darkly granular. The spleen makes its first appearance at this period in a fold of the "intestinal lamina," which below is continuous with the edge of the intestine, as far as the constricted portion of the vitellary sac, and above with the lower part of the rudimentary stomach. It is a small oval whitish mass, situated near to the distal end of the pancreas, but perfectly separate from this body. This separation is more evident at this period than at any other of its first stages of development; for a distinct granular membrane now divides them, whilst also the dark granular tinge of the pancreatic mass, and the lighter colour of the rudimentary spleen make this distinction more manifest. At a more advanced period of their development, the increased size of both organs causes them to approximate more closely, although not more intimately to one another, and it is this latter circumstance that has given rise to the great difference of opinion regarding the development of these parts. The organ, which has now a greyish tinge, lies parallel with the body, and tapers at both ends, the lower one being connected with the fold of the blastema, attached below to the intestine and vitellary membrane, the upper one continuous with the upper part of the same fold, which passes to the surface of the rudimentary stomach. On the fifth day (fig. 4) the pancreas and spleen may still be observed as two separate and independent masses of blastema, the former of which forms a distinct opaque transverse tract of white matter, which stretches upwards and backwards from the rudimentary duodenal loop, the spleen existing as a reddish round mass occupying its opposite extremity. The rudimentary pancreas is elongated, and presents an indistinct external margin, which is somewhat convoluted. From the end, near the centre of that curvature of the canal which would correspond to the duodenum, an offset is given off, which consists of a dark narrow tube with very distinct margins, communicating with the dark margin of the canal itself. This I believe to be the rudiment of the pancreatic duct. The spleen at this period consists of a dark mass of blastema, distinct from all the surrounding parts;

when seen with the naked eye it is of an opaque white, or slightly reddish colour ; its shape is circular or reniform, and it is situated close to the end of the pancreas below and beneath the rudimentary stomach. The organ consists of part of a tract of blastema, which at the upper and lower extremities of the spleen are continued from it, in one direction, towards the lower end of the stomach, in the other, backwards towards the intestine. It occupies the free margin of the fold of the "intestinal lamina," which presents a direction similar to what was observed on the fourth day of incubation. On the sixth day (fig. 5), the anterior prolongation of the vitelline duct forms two very considerable curves, the one nearest to the stomach, the convexity of which is directed downwards, having become completely developed into the duodenal loop, and in this loop the pancreas is plainly visible, the rudimentary spleen occupying its distal extremity. The position of these parts is now somewhat altered, passing obliquely upwards and backwards, instead of transversely, as on the fifth day. This appears to depend upon the alteration in the form and position of the intestine, which, being curved more upwards, would necessarily give to these parts a more oblique direction. The spleen is at this period distinctly visible to the naked eye, it is seen below and beneath the stomach ; its shape is reniform, being prolonged into two extremities, one at its upper, the other at its lower part ; it is situated at the edge of the fold of the intestinal lamina, which stretches from the lower end of the stomach across the intestine to the vitelline duct. The lower prolonged extremity is the more distinct of the two, and is to be traced for some little distance along the margin and in the substance of this fold, being ultimately lost in it. The other extremity, or that connected to the stomach, is more rounded, and is connected through the interposition of the same fold of membrane to the lower part of the stomach itself. Its position is now somewhat altered, it being placed above and slightly behind the stomach ; its upper edge being on a level with the rudimentary proventriculus. At the point where the spleen was connected with the pancreas, an apparent continuity of substance was found between them ; but this was not really so, for the two organs were to be observed to be separate from one another, from the great difference in their texture, the substance of the rudimentary pancreas being darkly granular, whilst that of the spleen was of a lighter colour. On the seventh day (fig. 6) the spleen is of a patchy reddish tinge, from the presence of blood in its substance ; and its position is now precisely the same as in the adult bird, occupying the space at the back part of the proventriculus, which exists now as a separate and distinct pouch ; the surface of the organ is slightly lobulated, especially towards its two extremities. It is now enclosed by a distinct membrane, and occupies the gastric surface of the distal end of the pancreas ; its shape is pyriform, the rounded end being directed backwards and upwards, and the narrow end forwards, into the interval between the commencement of the duodenum and pancreas ; these two extremities are still connected by folds of membrane with the stomach and mesentery ; they proceed from the back part of the organ, and apparently

surround it. On the eighth day the organ has increased somewhat in size, being now about as large as a small millet-seed, forming a round reddish projecting mass from the surface of the membranous fold in which it was developed, and which is now becoming more delicate and indistinct, as if in process of absorption, although its attachments still remain the same. From this period the spleen enlarges gradually, being on the twelfth day about the size of a small pea; its colour becomes of a more vivid red, and its form somewhat circular; it is held in its position by the vessels which proceed to it, and by a fold of membrane, the edge of which is cord-like, that passes from its lower end to the inferior border of the stomach, the remaining portion of the membrane in which it was developed having become completely absorbed. With the exception of a continued increase in the growth of the organ, which takes place more rapidly after the vessels supplying it are formed, its form, position and attachments remain precisely the same as in the adult bird.

From the preceding observations it is seen that the spleen is developed from the surface of a fold of the "intestinal lamina," in the form of a small oval-shaped mass of blastema, quite independent either of the pancreas or stomach; that in process of time this organ approximates more closely, although not more intimately to both these organs; and as its vessels are formed, the membrane in which it was developed becomes absorbed, with the exception of a delicate fold, which in the adult bird serves to connect this organ with the stomach.

I shall in the next place proceed to consider the development of the different tissues of the spleen, the observations concerning which, I think, are very important, as they tend to prove, not only the glandular nature of the organ itself, but the great correspondence that the development of its tissues presents, as compared with the supra-renal and thyroid glands.

On the Development of the Tissues of the Spleen.

Of the Capsule.—The first indication of the external capsule of the spleen I observed on the ninth day, in the form of a thin and delicate transparent membrane, which completely surrounded the organ; its texture consisted of a fine granular membrane, in which were observed numerous minute nucleated fibres. About the twelfth day this membrane was more distinct, and more easily separable from the surface of the organ; its texture was soft, of a greyish colour, consisting of a finely delicate granular membrane, in which numerous small nuclei, with elongated fibres proceeding from either end, were observed. On the eleventh day the capsule was more distinct, less transparent, thicker in texture, and more adherent to the parts beneath; its texture being composed of numerous nuclei, contained in a granular membrane, with delicate fibres, some of which possessed a nucleus, but in others it had completely disappeared. On the twenty-first day, the capsule, although more distinct, was intimately connected with the parts beneath, and was composed of a dense mesh of delicate fibrillæ, in most of which no nuclei could be detected.

The Development of the Trabecular Tissue.

The development of the trabeculæ commences as early as the eighth day of incubation; previous to this period the chief mass of the substance of the spleen is made up of nuclei, containing in their interior one or more dark dotted granules; at this period, however, spindle-shaped pale granular fibres, containing in their centre an oval elongate nucleus, with a nucleolus, may be observed sparingly throughout the substance of the organ. On the ninth day, similar but more numerous fibres may be observed, either separately or in delicate cylindrical, or riband-like bundles. By the fourteenth day these fibres have increased very considerably in quantity, forming innumerable fine fibrillated bands, intersecting the entire substance of the organ, much as in the adult state.

On the Development of the Blood-Vessels and the Blood.

The blood-vessels which supply the spleen, the separate vessels of this organ, and the blood, have a completely separate, though concurrent development. They are all observed about the eighth day of incubation (fig. 7). The splenic artery, which is developed a little previous to the vein, may be now observed as a delicate white tract of blastema, running from the inferior and posterior angle of the spleen to the descending aorta; on arriving at the inner side of the organ, a prolongation of the same colour may be observed passing to the upper end of the stomach, just beneath the proventriculus, and one or two to the front of the same organ; it then runs along the inner margin of the spleen, and is ultimately lost in the substance of the pancreas and in the duodenal fold. No similar tract could however be found, after repeated examination, to pass into the substance of the spleen, although at the same period capillaries containing perfectly formed discs, but as yet having no proper coats, and apparently merely formed by the walls of cells agglomerated together, were seen to be arranged in a branching manner throughout the substance of the organ. On the ninth day this vessel presents a reddish tinge, and its distribution is the same as in the adult bird. Two small branches are now observed to be given off to the substance of the spleen, from the vessel previously described, as it runs along the inner side of the organ. The splenic vein makes its first appearance on the thirteenth day, in the form of a reddish white tract of blastema, which runs forward and joins with the left side of the mesenteric vein, which is formed on the twelfth day. On the fourteenth day, the splenic vein consists of three small branches, larger than the arteries, which, uniting together, empty themselves into the mesenteric vein.

The development of the blood-globules in the spleen, as well as the various changes they undergo in the substance of this organ, are points of the very highest import, from the great difference of opinion that at present exists regarding its use,—GERLACH and SCHÄFFNER believing that the spleen is the organ in which the blood-

discs are formed during extra-uterine life, whilst KÖLLIKER, BECLARD and ECKER, suppose that the blood-globules are destroyed there. The blood-discs in the spleen, as I have already mentioned, make their first appearance in this organ about the eighth day. They are oval or circular, varying somewhat in size, and consisting of an external envelope, pale, homogeneous and indistinct, having a nucleus on its wall, which is dark, highly refractive, irregularly circular, and in some cases of a granular texture. Some of these globules may be distinctly seen in an incipient stage of formation, and consist of a dark, and at first, a somewhat irregular granular nucleus, around which a delicate cell-wall may be observed. Although I have observed this in several cases, I do not presume the spleen to be the organ in which the development of the blood-globules takes place during intra-uterine life, nor have I observed that the development of the blood-discs continues to take place in it after its connection with the general vascular system is effected. With regard to the disintegration of the blood-globules, after the most repeated and careful examinations, I have failed in detecting anything that would lead me to suppose that this organ can, during its progress of development, perform the function KÖLLIKER and others have assigned to it in its adult state.

On the Development of the Pulp.

The entire substance of the spleen at an early period of its development is almost precisely similar in structure with the supra-renal and thyroid glands, with which it may consequently be allied. As the evolution of the organ proceeds, part becomes developed into trabeculæ, part into blood-vessels and blood, whilst the greater portion remains to form the essential element of the organ, the pulp tissue. On the fifth day this substance presents the following elementary composition. It is composed of nuclei, varying in form and size. The greater majority are irregularly circular, their sides and edges being flattened at some points, so as to give them an angular form; some, however, are perfectly circular; they are pale, and their outer margins dark and well-defined, whilst in their interior may be observed, one, two, or more dark granules. These form a very considerable portion of the substance of the pulp, not only at this, but also at every other period of its development. A few nucleated spherical vesicles may also be observed, their outer margin exceedingly delicate; and on their wall may be seen a small irregular dark-edged nucleus; sometimes the nucleus is more circular, and contains a nucleolus, whilst the interior of the vesicle contains a few delicate pale granules. With the exception of a few small dark and highly refractive oil-granules, and a fine pale granular plasma, in which the above elements lie, they constitute the entire mass of the pulp tissue at this period. The next change observable takes place concurrent with the formation of the vessels which supply the organ, and which is soon followed by an increase of its size. Now, besides the elements already described as forming its structure, there may be observed nuclei, similar to those constituting the pulp at an early period, but

having a quantity of fine dark granules surrounding them in a circular form. There are also observed many nucleated vesicles, rather larger than the blood-corpuscles, the nuclei in which are circular, whilst the cavity of the vesicle contains also a few small pale granules. Some small masses of reddish brown granules may also be observed; they exist, however, very sparingly. From the time when the formation of the arteries supplying the organ is completed, up to that when the splenic vein is observed to be also constituted, these latter elements not only form a portion of the pulp, but are in fact its chief components. When, however, the splenic vein is nearly completed, a considerable change is observed to have occurred in the nucleated vesicles; those which had previously formed only a small portion of its substance, now exist as the chief element, and the majority contain a nucleus with irregular margins. Their form is chiefly circular, their outer wall in some cases very distinct, in others less so, from the cell being distended with dark granules. There is generally only a single nucleus, which has a dark outer margin, and contains either a nucleolus or two or three granules. In some the nucleus is of an irregular form, and more indistinct; the cavity of the cell in these cases containing a few granules, as the nuclei become more irregular and granular; these granules increase until at last the nucleus appears to be entirely broken up, when they all become crowded with small granules. Such is the structure the pulp tissue of the spleen presents, from the period when the splenic vein is formed, up to the time when incubation is completed.

Development of the Malpighian Vesicles.

The vesicles of the spleen are developed in a manner perfectly similar to those of the supra-renal and thyroid glands, with which they appear to bear a very close analogy; they are not developed, however, in the chick until the period of incubation is near to its completion. Between the twentieth and the twenty-first days there may be observed at the angles of division of the smaller blood-vessels, as well as upon the walls of the vessels themselves, rather large masses of nuclei and granules, arranged together in a circular form; these masses are not, however, at this period enclosed by any investing membrane, but are rather intimately connected with the walls of the vessels, as they are not removed by delicate manipulation, and only when a greater amount of force is used. A few days after incubation is completed these vesicles are observed to be partly surrounded by a faintly delicate homogeneous membrane, and in about a week the vesicles are distinctly formed, and present the same structure as in the adult bird; they are circular or oval, varying considerably in size, and consisting of an outer investing membrane, pale, homogeneous, or faintly granular in texture, and containing in their interior a mass of nuclei and numerous small dark granules.

Development of the Supra-renal Glands.

The development of the supra-renal glands being described differently by various physiologists, I shall first briefly detail the researches made by others upon this point.

ARNOLD (*op. cit.*) states that they are derived from the Wolffian bodies by means of a fissure, and that they have the same structure as these organs, a statement which has not, however, been confirmed by any other author. VALENTIN and MECKEL believed that the supra-renal bodies exist first as a single mass, which is placed above and in front of the kidneys, and which afterwards divides itself into two lateral halves; whilst J. MULLER and BISCHOFF, on the contrary, state that they have always observed them double, although no account of their origin has been given by them. Mr. T. GOODSIR is the only author, as far as I am aware, who has attempted to prove the close affinity the ductless glands (excepting the spleen) have to each other, by tracing out their gradual evolution in the embryo. He states that all of them (excepting the spleen) arise in involuted portions of the membrana intermedia, and that at an early period of embryonic life they communicate with one another. He concludes from this apparent fact, their original identity of function, which he says is that of elaborating a nutrient material, an office which the germinal membrane itself performs during foetal life.

The description that I shall now venture to offer, differs from any that has been previously given of the evolution of this gland. I trust however that I may be able to prove the close affinity that it has both with the spleen and also with the thyroid, not so much from any resemblance that it may present in its manner of evolution, but from the similitude it presents in its elementary parts, and in the development of those elements to their perfect form.

Between the sixth and seventh days of incubation, I observed that the Wolffian bodies had become contracted in their length, and more curved upon themselves than at an earlier period of their development, being somewhat reniform in shape, and attenuated at their upper extremities. Along the inner margin of these bodies was observed the ovaries, each of which consisted of a small oval mass of whitish blastema, occupying the central portion of each body, approximating, but not joining one another below, whilst they diverge from one another above. Between the Wolffian bodies may be observed the aorta, which bifurcates below into two lateral and a continuous branch. At this period the supra-renal glands, which, as will be seen, exist at a later period in the interval between the upper ends of the Wolffian bodies and the sides of the aorta, could not be observed. On the close of the seventh day (fig. 9), I observed in the interval between the sides of the descending aorta, and the upper and inner sides of the Wolffian bodies, a patchy reddish grey granular mass of blastema, without any distinct form or outline; whilst both the pointed but rounded margins of the primordial kidneys and the ovaries were plainly seen. On

tracing this granular mass upwards along the sides of the aorta, it was completely lost in the general formative mass which surrounds all these parts, and after many attempts I was unable to discover any connection between this body and the thyroid and the thymus above (as stated by Mr. GOODSIR), by means of the blastemal tract along the aorta; nor do I believe that any connection exists between them. The minute structure of the supra-renal gland at this period bears a very close resemblance to the spleen on the fifth day of incubation; it consists of nuclei about the size of the blood-discs, the majority of which are circular, pale, and contain in their interior, one, two, or even sometimes more dark granules,—nucleated spherical vesicles, their outer margin very delicate, the interior of the vesicle containing a few delicate granules. The only difference that exists between the minute structure of the spleen and the supra-renal gland, is the presence in the latter of numerous small dark granules, like fat granules, and which are in some cases accumulated in small circular masses. With this exception no difference can be observed in their minute structure at an early period. On the eighth day the supra-renal glands consist of two grayish white masses, which lie one on each side of the aorta, between this tube and the upper and inner extremity of the Wolffian bodies, and are perfectly separate. They are elongated and rounded at both ends, but they do not present any external circumscribed margin. They are situated, for part of their extent, higher than the upper extremity of the Wolffian bodies, the upper margins of which are distinct and well-defined, as contrasted with the uneven outline of the supra-renal gland. On the right side, the gland is placed completely above the corresponding ovary, but on the left a small part is hidden beneath the left ovary. The texture of the organ is opaque, and darkly granular throughout. At this period a considerable advance is observed in the development of the tissues of the gland, for they even now present an incomplete vesicular arrangement; this however is not surprising, when it is considered that its chief function is probably performed during foetal life. Its tissues have consequently a more rapid development than those of the spleen, an organ the function of which is exercised mainly in adult life. The imperfect vesicles of which this organ is partly formed, consists of a mass of nuclei, similar to those above described, amongst which are scattered a small quantity of fine dark granules; these masses of nuclei are arranged together in a circular form, without any investing membrane surrounding them; in some cases, however, a fine membrane could be observed in one part only of the circumference of the forming vesicle, whilst the remaining portion was entirely free. Some of the vesicles were formed of a mass of smaller vesicles, in which nuclei were observed. The chief majority however were composed of nuclei, fine dark granules, and small dark circular granular masses. On the ninth day the supra-renal glands are yellowish white, and occupy the same situation as on the previous day, but even at this period are not bounded by any external circumscribed margin; they are plainly separated from one another by the aorta, and although placed in

close contact with the Wolffian body, their different structures at once show them to be distinct organs; for the dark opaque granular structure of the supra-renal glands contrast most strongly with the lighter and more transparent tissue of the Wolffian bodies. The vesicles of which the organ is at this period composed are circular, or elongate oval, and their contents far more transparent than those observed at a later period of development. They now present a delicate but well-defined external investing membrane, containing nuclei and a few dark granules. On the tenth day (fig. 10) the supra-renal glands are pyriform, the broad end being directed upwards, and the apex downwards; their margins are now also distinctly circumscribed, and their tissue, although dark and opaque (when seen with a low magnifying power), is more transparent than the tissue of the gland at a more advanced period of its development. The vesicles of which they are composed at this period are not all circular, for some are elongated, and present two or sometimes three hemispherical bulgings on their wall, as if apparently formed of the junction of two or more vesicles; these contain several nuclei and numerous small dark highly refractive granules; the former are however at this period far more numerous than the latter. These vesicles vary both in size and form; they are grouped together in a mass, in which it is as yet impossible to detect any subdivision into cortical or medullary portions. On the fourteenth day (fig. 11) the supra-renal bodies have somewhat changed their position; they lie at the back part and inner side of the upper extremities of the Wolffian bodies, and in front, and at the inner side of the upper end of the kidneys; their form is of an elongated oval, and the one on the left side is like the corresponding ovary, slightly the larger of the two. At this period they are connected with the Wolffian bodies through the intervention of a delicate web of areolar tissue. The inferior vena cava is now observed passing upwards between these bodies, and closely adherent to their inner sides. On examining the organ with a low magnifying power, it is seen to consist of a mass of vesicles, which however are not equally distributed throughout the whole of its substance, being aggregated in much larger quantities at the upper, lower, and outer sides of the gland than at its inner side, where it is connected with the vena cava, and at its centre. These vesicles are large, and radiate from the circumference towards the centre of the gland, in some cases complete tubes of some length being formed by their junction, as indicated by hemispherical bulgings along their walls. They lie between the meshes of a close plexus of vessels, which run in straight lines from the centre towards the circumference of the gland. These vesicles, at this period, and up to the time when incubation is completed, consist of an external investing membrane, so delicate as to render its demonstration a matter of some difficulty; they are full, not of nuclei, as was observed during the first stages of development, but of dark and highly refractive granules, precisely like oil-globules, in such numbers as to completely distend the cavity of the vesicle, and also prevent the nuclei, a few of which still exist in small numbers, from being clearly detected. By the eighteenth day (fig. 12) the glands have enlarged considerably, and

are of a deep yellow colour; their position is now almost precisely the same as in the adult bird; numerous small vessels ramify upon their surface, and a large vein emerges from their inner sides, which empties itself into the vena cava. A complete division into cortical and medullary portions is now observed. The former consists of elongated tubes with exceedingly delicate walls, and radiating from the circumference towards the centre of the gland. These tubes, which at this period exist in greater number, are parallel with one another, and lie between a close mesh of delicate capillary vessels, having a similar direction. In some cases the simple vesicles placed end to end, but not as yet forming tubes, are disposed in a similar manner between the capillary vessels. The medullary portion of the gland consists of capillaries, which here join to form larger branches, either previous to their passage from the gland, or before passing into the cortical portion in the form of straight capillaries; numerous delicate fibres may also be observed joining them together, and forming a close mesh, in which are deposited numerous dotted corpuscles, and a quantity of fine dark granules. From this time, up to the completion of incubation, no change takes place in the structure of these glands. From the preceding observations it is seen that the supra-renal glands are developed by two separate masses of blastema, which are situated between the upper and inner extremities of the Wolffian bodies and the sides of the aorta, but which are totally independent (as far as concerns their development) of those bodies, or of each other. It is also seen that their minute structure at an early period closely corresponds with the structure of the spleen; and although the supra-renal glands attain their maximum degree of development at an earlier period than that organ, as regards the formation of its vesicles, still exactly the same process can be followed in the spleen as regards the development of the Malpighian vesicles; a fact which, I think, tends to prove the great similarity of the organs in question.

Development of the Thyroid Glands.

The evolution of the thyroid gland, like the spleen and supra-renal capsules, is involved in great obscurity.

The following are the principal accounts of its development that have yet been given.

According to HUSCHKE* the thyroid gland is developed from the anterior branchial arches; no other observer however has verified his statement, and RATHKE altogether denies it.

ARNOLD† states that it is developed from the membranous air-tube, in the situation where the larynx is formed, and that it is at first provided with an excretory duct.

BISCHOFF‡ states that they appear from a single formative mass, which is deposited

* HUSCHKE, Isis, p. 621, 1826, p. 403, 1827.

† ARNOLD, Lehrbuch der Physiologie des Menschen. Zürich, 1842, vol. v. p. 1293.

‡ Th. L. BISCHOFF, Entwick. der Säug. und des Mens. Leipzig, 1842.

on each side of the trachea. The latest researches on the development of the thyroid, appear to be those of Mr. GOODSIR, who states that it is, like the thymus and supra-renal gland, a development from the "membrana intermedia."

According to my observations, between the sixth and seventh days of incubation, the first trace of the thyroid gland becomes apparent. It consists of an exceedingly small spherical whitish mass of blastema, situated on each side of the root of the neck, close to the point where, at a later period, the carotid and subclavian arteries separate from one another. The outer margin of each mass is somewhat irregular and ill-defined, and is not apparently surrounded by any investing membrane; above each of them is seen the lower end of the rudimentary thymic tube, the outer margins of which are perfectly distinct from the thyroid. The carotid vessel runs beneath and on the outer side of the gland, to the wall of which it is somewhat adherent; and on the inner side runs the rudimentary tracheal tube, with which however it has no connection. The structure of the glands at this period approximate very closely to that of the spleen and supra-renal gland at the earliest stages of their evolution, consisting of granular matter, nuclei, and nucleated vesicles. The granular matter, which forms a large mass of the substance of the gland, is made up of innumerable minute pale granules, very similar to those observed in the structure of the spleen, but unlike those of the supra-renal glands, the particles composing which are darker and more refractive, not unlike minute fat granules. The nuclei are about the size of the red blood-discs; they are pale, perfectly circular, and contain in their interior from one to four or five small dark granules. These also form a very considerable portion of the structure of the organ. The vesicles are few in number, pale, and delicate, with nuclei on their walls, and containing in their interior a few fine dark granules. On the eighth day of incubation the organ has enlarged very slightly, occupying the same position as on the previous day; its colour is now reddish white, from the presence of blood in its structure; it is circular, and is bounded externally by a clearly defined marginal membrane, which now surrounds it. I have never been able, in tracing out the incipient development of these organs, to detect any connection between it and the branchial cleft, the trachea, or the thymus, although its position as regards these parts has probably given rise to the opinions, previously noticed, respecting the origin or connection of the thyroid from one or other of these structures. It has always appeared to me to arise as a separate mass of blastema, and unconnected, unless by simple apposition, with any other organ. From this period, up to the tenth day of incubation, the thyroid, with the exception of a slight enlargement, and a more distinct red colour, presents the same structure, and occupies a similar position as in the previous examinations. At this period they are found situated a little above the root of the neck, one on each side of the lower end of the trachea, just above its division into the bronchi, and at the point of origin of the carotid vessel. The organ is now more distinct from its reddish tinge; its form is circular, its outer margin clear and distinct; and its substance, when seen with a

low magnifying power, moderately transparent. Its minute structure also now presents a higher stage of development; for besides consisting, as at an earlier period, of granular matter, nuclei and vesicles, some of which are furnished with nuclei, there are observed numerous circular and tolerably transparent masses of nuclei and vesicles, some perfectly destitute of any investing membrane, but others presenting a fine membrane partially or completely investing them. In the interspaces between these vesicles numerous blood-discs may be observed, which are apparently not as yet contained in separate tubes.

On the twelfth day, the size of the thyroid about equals that of a millet-seed; it is bright red, and small vessels may now be traced passing into its substance. Its minute structure, however, undergoes no change until about the sixteenth day. At this period a delicate membrane, forming a complete capsule, can be removed from its external surface; it consists of numerous nucleated fibrillæ. Almost the entire mass of the organ is composed of large circular or oval vesicles, consisting of a mass of nuclei, enclosed in a faintly delicate, homogeneous, limitary membrane. On the twenty-first day the thyroid is rather smaller than the spleen, and rather larger than the supra-renal glands. It is of a reddish gray colour, and is surrounded by a complete fibrous capsule, which may be easily removed from its exterior. It consists of a mass of vesicles, which vary in size; they are chiefly circular, and their contents transparent. They consist of an external, homogeneous and transparent membrane, forming a closed cavity, which contains a mass of nuclei. In some cases, however, the vesicles, instead of being filled with nuclei, are lined with a layer of nucleated cells, and a cavity, although small, exists in their interior.

It may be seen, from the preceding observations, that the thyroid glands are developed in the form of two distinct separate masses of blastema, one at each side of the root of the neck, close to the point of separation of the carotid and subclavian vessels, and between the trachea and the bronchial clefts, but quite independent, as far as regards their evolution, of either of those parts. Their minute structure also, at an early period of their development, closely corresponds both with the spleen and supra-renal glands; and the tissues of which they are composed, at a later period, are formed in a manner precisely similar with the same parts in those organs, a fact which shows the analogy they bear to one another.

From the preceding observations, it will be seen that a close analogy exists between the glands already described; and the propriety of their classification, together with the thymus, under one group, as the "Ductless Glands," may be considered clearly proved. Now although most anatomists, excepting Mr. GOODSIR in this country, adopt such a classification, and place the spleen under the head of the "ductless glands," many of our continental anatomists, among whom may be enumerated ECKER, in a very late and highly elaborate article, has attempted to prove that this organ cannot, either anatomically or physiologically, be enumerated with them. "For," says ECKER, "though the vesicles of the spleen have a similar function with the glands

of the blood-vessels, which is not improbable, these do not form the main element of the spleen. The function that I have explained to be particular to the spleen, takes place in the pulp, and in none of the glands of the blood-vessels are the characteristic elements of this found." That the spleen, however, may be classed with these glands is I think proved,—

1st. From the manner of its evolution, which is precisely similar both to the supra-renal and thyroid glands.

2ndly. From its structure, which at an early period almost exactly corresponds with that of the other glands in question; and

3rdly. From the development of its tissues following precisely the same law as that upon which the tissues both of the supra-renal and thyroid glands are formed.

It may be thought by some that I should have made this communication more perfect had I traced out the development of the highest of the ductless glands, the thymus. The elaborate investigations, however, of Mr. SIMON upon this gland, have given all that can be desired upon this point, and the few observations I have myself made on the evolution of this organ in the chick accord so exactly with his statements, that I could add nothing but what was confirmatory of his observations.

EXPLANATION OF THE PLATES.

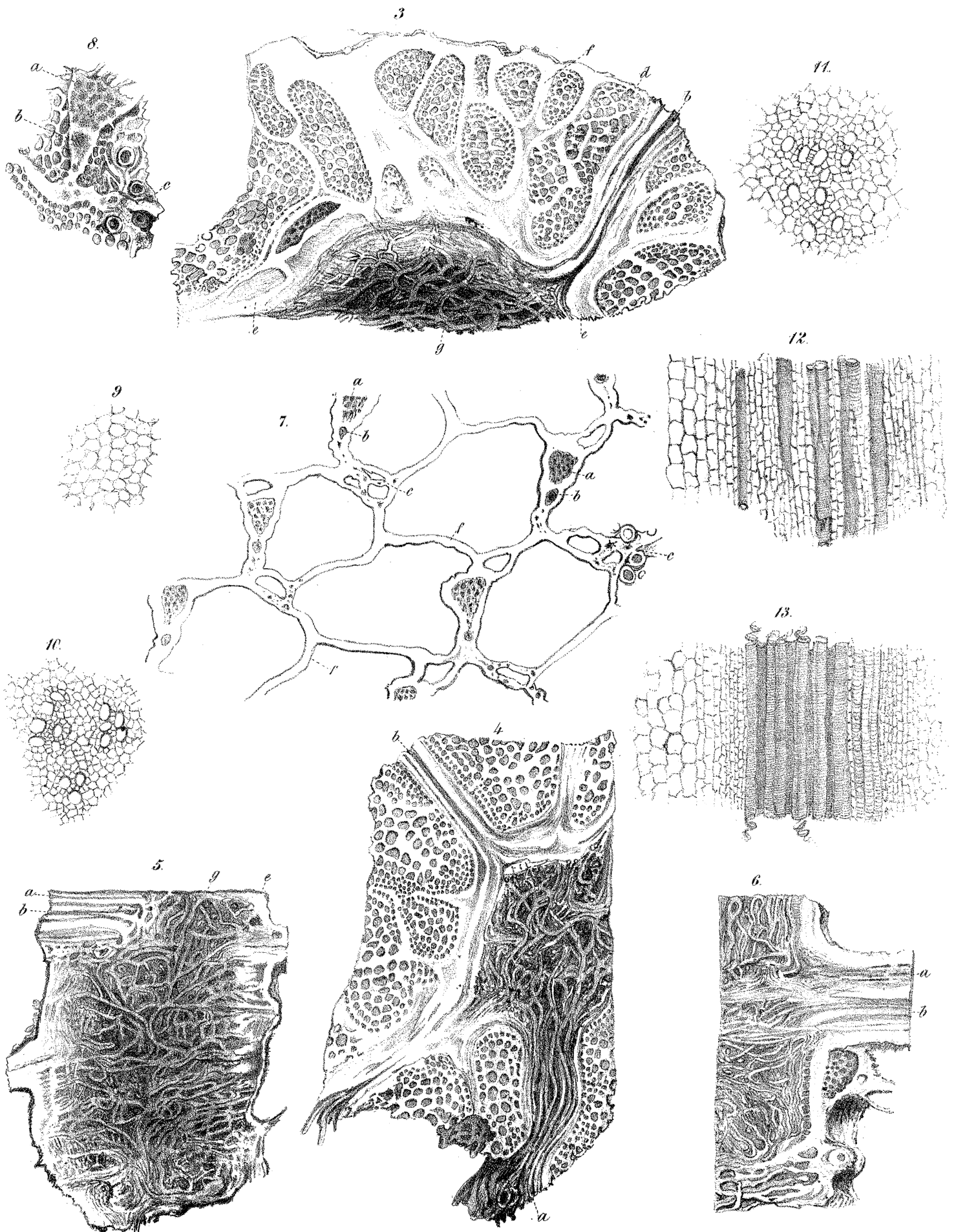
PLATE XXI.

- Fig. 1. Represents the rudimentary intestinal canal from the embryo of the chick at the seventy-second hour. V. Vitelline sac. I. Intestine. L. Liver. S. Stomach.
- Fig. 2. Represents the anterior prolongation of the intestinal canal at the ninetieth hour, with the liver and pancreas arising as protrusions from that tube. P. Pancreas.
- Fig. 3. The same parts are represented as they are observed at the 114th hour. The first trace of the spleen is here shown as a small oval body developed in a fold of the intestinal laminæ, distinct from the pancreas. Sp. Spleen.
- Fig. 4. Represents the intestinal canal, pancreas and spleen from an embryo chick between the fifth and sixth days. The spleen is now observed to have approximated close to the end of the pancreas.
- Fig. 5. Represents the same parts from an embryo chick between the sixth and seventh days. The pancreas with its duct are observed occupying the fold of the duodenum; the spleen occupying its distal extremity.
- Fig. 6. In this figure are represented the stomach, duodenum, pancreas and spleen from an embryo chick between the seventh and eighth days.
- Fig. 7. The duodenal fold is here represented with the pancreas and its duct con-

tained in it. The spleen is seen near to its distal end with blood-vessels ramifying in its substance; no branches being derived from the vessel which runs along its inner side. From a chick at the eighth day.

PLATE XXII.

- Fig. 8. The Wolffian bodies, with the diminutive and elongated ovaries lying upon them, are represented as observed in an embryo chick on the fifth day. W. Wolffian bodies. O. Ovaries.
- Fig. 9. The same parts are represented as they are observed on the seventh day. The supra-renal glands are observed lying at their upper and inner margins, one on each side of the aorta and above the ovaries. S. Supra-renal glands.
- Fig. 10. The same parts as observed on the tenth day. The ovaries now approach nearer to the supra-renal glands; the left one just overlapping the lower end of the corresponding gland.
- Fig. 11. In this figure are represented the kidneys, Wolffian bodies, ovaries and right supra-renal gland from an embryo chick at the fourteenth day. The left supra-renal gland is covered over by the left ovary.
- Fig. 12. The same parts as observed in the chick on the eighteenth day.



Victoria Regia.

Fig. 1.

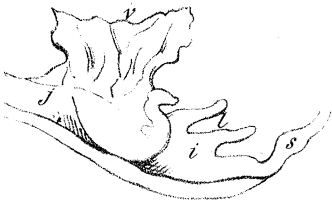


Fig. 2.

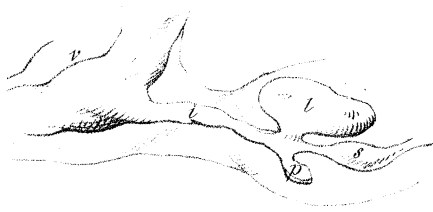

Fig. 3.

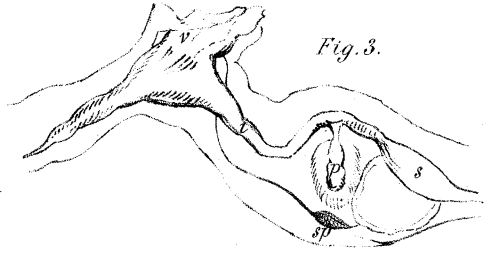


Fig. 4.

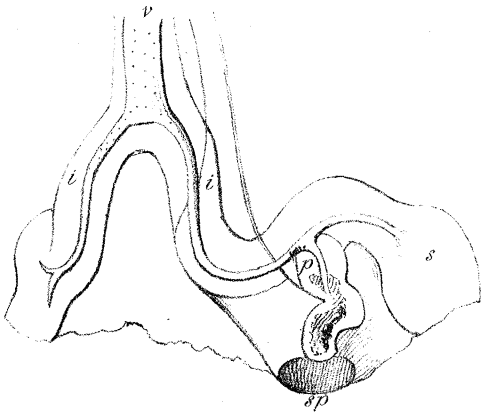


Fig. 5.

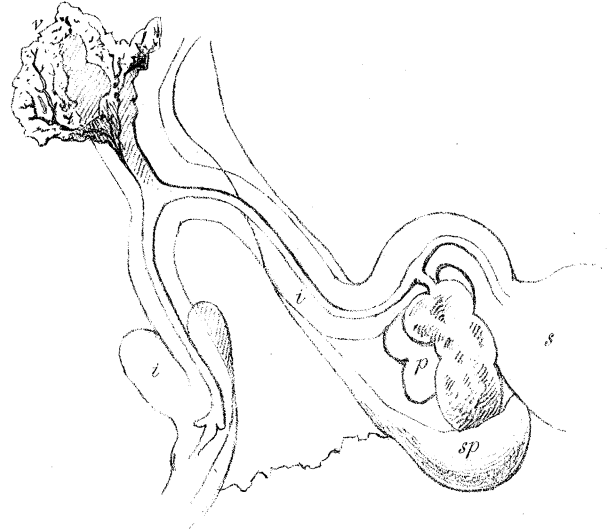


Fig. 6.

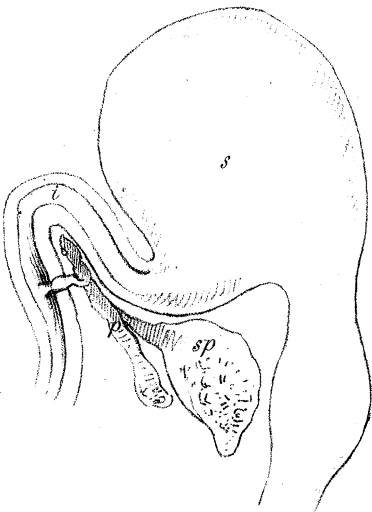


Fig. 7.

