

XVI. *On the ultimate arrangement of the Biliary Ducts, and on some other points in the Anatomy of the Liver of Vertebrate Animals.* By LIONEL S. BEALE, M.B., Professor of Physiology in King's College, London; Physician to King's College Hospital. Communicated by F. KIERNAN, Esq., F.R.S.

Received June 14,—Read June 21, 1855.

IN his valuable paper published in the Philosophical Transactions for 1833, Mr. KIERNAN describes and figures the anastomoses between branches of the duct in the left triangular ligament of the human liver. He also refers to communications existing between the ducts in other situations, as in the membranous bridge stretching over the fissure for the umbilical vein, and upon the inferior surface of the diaphragm. In the same paper, this author gives a diagram of the manner in which he supposed the ducts to terminate in the lobules of the liver, and subjoins the following remarks:—"No such view of the ducts as that represented in this figure can be obtained in the liver. The interlobular ducts are in the figure seen anastomosing with each other. I have never seen these anastomoses, but I have seen the anastomoses of the ducts in the left lateral ligament, and from the results of experiments related in this paper, I believe the interlobular ducts anastomose; I have never injected the lobular biliary plexus to the extent represented in this figure."

Since the appearance of this important communication, the subject has been much investigated both in this country and on the continent; but as far as I can ascertain, no observer has yet succeeded in *demonstrating* the manner in which the ducts terminate, or has been able to show conclusively the precise relation which the hepatic cells bear to the biliary ducts. Various hypothetical views have been offered.

MÜLLER considered that the ducts terminated in blind extremities; E. H. WEBER, under the name of "*Vasa aberrantia*," described ducts which formed a network in the transverse fissure of the liver, uniting the right and left hepatic ducts. In 1850 the same observer described ducts terminating in blind extremities upon the surface of the external lobules of the cat's liver.

KRUKENBERG, SCHRÖDER VAN DER KOLK, RETZIUS, THEILE, BACKER, LEIDY and others, have adopted the view that the hepatic cells lie within a basement membrane; but with reference to the arrangement of the cells within the tube, there is much difference of opinion among them.

LEREBoullet, in his memoir on the "*Foie gras*," published in 1853, advocates a similar view; but his representations are very diagrammatic, and for the most part taken from preparations examined by low powers.

HENLE, GERLACH, HYRTL and NATALIS GUILLLOT look upon the finest gall-ducts as

communicating with spaces between the hepatic cells into which the bile escapes, and is received by the most minute ducts.

HANDFIELD JONES and KÖLLIKER describe the hepatic cells as forming a solid network composed of columns of cells, not bounded by any basement membrane, but lying between the meshes of the capillary network.

HANDFIELD JONES thinks the ducts terminate by blind extremities, which lie amongst the cells at the peripheral parts of the lobule. The small cells lining these ducts are considered by him as the chief agents concerned in the secretion of bile, and he looks upon the function of the hepatic cells as totally distinct from this. BUSK and HUXLEY and Dr. CARPENTER concur in this view, which places the liver in the same category as the suprarenal capsules, follicles of PEYER, spleen, &c. KÖLLIKER offers the supposition that the finest ducts impinge upon the columns of the network of hepatic cells, and makes the following remarks with reference to this point:—"Often as I have sought for a direct communication of the finest canals with the hepatic networks, I have not directly observed it; which is indeed by no means surprising, if we consider the softness of the parts with which we have to do; but unfortunately the result is a *hiatus* in the minute anatomy of the parts, which can hardly be made good by hypotheses*."

The conflicting opinions of observers appear to have been based upon inference and hypothesis rather than upon direct observation, and are embodied in diagrammatic figures; some authors, agreeing with KIERNAN, regard the liver as arranged upon the type of true glands, while the latest authorities have endeavoured to establish the view that this important organ is more nearly related to the ductless glands.

My own observations have been made upon the livers of several different animals, and I have tried very numerous methods of preparation, some with considerable success. The results of the examination of injected specimens precisely accord with the observations made some months before upon uninjected preparations.

The points which I hope to establish are as follows:—

1. That the hepatic cells lie within an exceedingly delicate tubular network of basement membrane.
2. That the smallest biliary ducts† are directly continuous with this network.
3. That in favourable specimens, injection forced in from the duct, will pass into every part of the tubular network, even quite to the centre of the lobule, and that the capillary network can be injected in the same preparation.

In carrying out my investigations upon the anatomy of the ducts, I have been led

* An excellent abstract of the views upon the structure of the liver, up to the year 1852, will be found in Professor KÖLLIKER's 'Mikroskopische Anatomie.'

† In the following pages the word "duct" is used to denote the tubes which carry off the secretion, in contradistinction to the secretory tubes or "*cell-containing network*" in which the secretion is formed.

naturally to examine other points in the minute anatomy of the liver. Some of these observations accord with the notions previously entertained, while others are at variance with the opinions usually held. In this communication I wish to restrict myself, as far as possible, to the consideration of the anatomical arrangement of the biliary ducts and the relation which these bear to the secreting cells of the liver, and shall therefore only allude to some of the more general points incidentally. It may, however, be desirable to offer a few remarks upon the nature of the lobule as it occurs in the livers of different animals.

Lobules.—If by a lobule is understood a perfectly circumscribed portion of hepatic substance containing within itself all the structural elements necessary for the formation of bile, which can be separated from adjacent portions, the only livers in which such lobules are to be demonstrated, so far as is yet known, are those of the pig, and Polar bear (according to MÜLLER). In the pig each lobule possesses a distinct capsule of its own, and can be readily separated from its neighbours. The capsule is perforated by branches of the vessels and duct which are distributed in its interior. This arrangement of separate lobules would permit a considerable amount of movement upon each other, whilst the capsule would have the effect of preventing undue engorgement and distension of each individual lobule, a provision which seems to be especially needed in the pig.

There is not this division into distinct and separate lobules in the livers of other animals which I have examined. As numerous authors have described, there is a sort of mapping out of small spaces produced by the arrangement of the smallest vessels and ducts, to be seen more or less distinctly in the livers of all vertebrate animals; but it is impossible to separate these apparently isolated portions from each other, without tearing the hepatic tissue of which they are composed, thereby leaving a rough and jagged surface. In fact, while the lobules of the pig's liver are provided each with its separate capsule, and in many instances separated from its neighbours by a certain quantity of areolar tissue, and the branches of the vessels and duct for their supply, the so-called lobules of the liver of man and other animals are only separated from each other at certain points by the fissures in which the portal vessels and duct lie. There is no distinct capsule, nor areolar, nor fibrous tissue between them, and the capillaries and the cell-containing network of one lobule are continuous at various points with those of its neighbours.

Most writers seem to have regarded the pig's liver as the type of structure to which all others should be referred; but it seems more natural to look upon this beautiful liver as exceptional, and bearing the same relation in structural peculiarity to the livers of other animals, as the much-divided kidney of the porpoise bears to the corresponding solid organ of man and most other mammalia.

It may be said that in a *physiological* point of view the livers of all vertebrate animals are composed of lobules, but in a strictly *anatomical* sense this term must be restricted to the livers of the pig and Polar bear.

So also it is only in the liver of the pig that a prolongation of the areolar tissue can be demonstrated between the ultimate portions of secreting structure.

In the human liver areolar tissue is abundant in the large portal canals, but it gradually diminishes in quantity as the branches of the vessels become smaller, and their most minute ramifications are entirely free from it, as BOWMAN, HENLE, and VOGEL have previously observed. In the liver of the seal it is very sparing in quantity in the portal canals, but in some of the rodent animals it seems to be reduced to a minimum (rabbit, rat, mouse). In the rabbit a very little areolar tissue is found even in the largest portal canals.

In subjecting sections of uninjected specimens to examination, the smallest branches of the vessels are inevitably stretched and torn by manipulation, and thus a striated appearance, closely resembling that of fibrous tissue, is produced.

As is well known, the vessels of the kidney and of other glands at their point of entrance, are invested with a covering of areolar tissue, which is gradually lost as they divide into smaller branches in the glands. A similar arrangement occurs in the case of the liver, but from the large size of the gland this investment is prolonged for a considerable distance into its interior.

Method of preparing Specimens.

In consequence of the softness of the liver, I have been unable to demonstrate the arrangement of the minute ducts and their connexion with the cell-containing network without previous hardening. This hardening may be effected in several different ways. By soaking small pieces of liver in strong syrup for several weeks, they become so firm, that very thin sections can be readily obtained. The liver may also be hardened in alcohol, and afterwards rendered transparent by soda. I have also succeeded in obtaining good sections from pieces which had been soaked in the mixture of alcohol and acetic acid, recommended by Mr. L. CLARKE in investigating the structure of the cord. The fluid, however, which has afforded the most satisfactory results, consists of alcohol, to which a few drops of solution of soda have been added. In this mixture the liver becomes perfectly firm and transparent at the same time*.

In my investigations I have employed several other solutions, but the above are most worthy of notice. Some of the livers were hardened in the state usually obtained from dead animals, others were partially injected from the duct in order to force the bile into the smaller ducts before they were hardened, and in some instances the bile duct was tied some hours before the death of the animal.

* The advantage of this solution seems to depend upon the opposite action of the two fluids. The alcohol precipitates albuminous compounds, and renders them hard and opaque. The soda, on the other hand, softens and dissolves them, rendering them transparent. In conjunction, these operate in rendering the tissue quite *hard and transparent* at the same time. I am still prosecuting experiments with this fluid. Large preparations have been preserved in the alkaline fluid with advantage. I have succeeded in making some most beautiful preparations, showing the ossification of the bones in the embryo at different periods in this manner.

Method of injecting the Ducts of the Liver and the Cell-containing Network.

Although I felt certain of the correctness of my observations upon various uninjected specimens examined two years since (in 1853), it appeared to me that it must be possible to inject both the minute ducts and the hepatic cell-containing network, if they were really continuous, and for a long time past I have been endeavouring to effect this object. It would be useless here to describe all the different plans I have resorted to, and I shall therefore only refer to the method which succeeded. After failing many times to drive the injection into the smallest ducts, it occurred to me to try to empty the ducts of their bile before injecting them. This object was at last readily obtained by forcing water into the portal vein, and causing the vessels to become distended. In consequence of this distension, the ducts were compressed, and the bile was forced from the small into the larger branches. After continuing the injection of the water for a short time, bile trickled from the duct and the gall-bladder became filled—soon bile ceased to escape, and almost pure water flowed. After the liver had been thoroughly drained, by being placed in soft cloths for some hours, the duct was injected with Prussian blue*. The injection passes readily with slight force, and can be seen entering the lobules upon the external surface of the liver. It does not appear gradually round the circumference of the lobule as when the portal vein is injected, but it forms small roundish points, almost like extravasations, here and there at the outer part of the lobule, and it spreads from thence towards the centre.

After the duct has been injected in this manner, it becomes necessary to distend the capillary vessels with injection, otherwise a thin section has a confused appearance. For this purpose plain clear size is the best. The portal vein is injected with it, and the injection continued until the whole organ is fully distended. The vessels

* Before resorting to Prussian blue I had tried numerous different substances. Opaque injections always caused the preparation to look confused under high powers, and it was impossible completely to remove the adhering particles of injection from the section by washing. In consequence the specimen never looked clear. Transparent injections seemed likely to afford more favourable results, and several were tried. Most of them passed through the walls of the ducts, colouring all the adjacent tissues, and afforded no better success than opaque injections. Carefully prepared Prussian blue combines the advantages of an opaque injection with those of a coloured solution. The particles will not pass through basement membrane, and at the same time they are so minute, that when suspended in fluid, the appearance of a solution is produced. Injections of Prussian blue may be examined by reflected or by transmitted light.

The Prussian blue is prepared in the usual manner, by adding a solution of ferrocyanide of potassium to a dilute solution of perchloride of iron. The mixture should have the appearance of a dark blue solution, and should contain no flocculi. It should not form a deposit until it has stood for some time. About a third of its bulk of spirit should be slowly added and the mixture well stirred. The advantage of the spirit is, that it hardens the delicate walls of the finer ducts as it comes in contact with them, and thus tends to prevent their rupture. The mixture must be strained through two or three layers of fine muslin before use. The Prussian blue may be injected by means of a small half-ounce syringe, or by the pressure of a column of fluid about four feet in height placed in a long tube.

are then stopped and the liver allowed to become cool. When the size has set, very thin sections can be obtained without difficulty. The section must be carefully washed before examination, in order to remove loose cells, &c. from the surface which would interfere with its definition. It may be placed in thin syrup, glycerine or dilute alcohol, and will bear examination with a quarter, or with an eighth of an inch object-glass (400 diameters).

By injecting the ducts, the lymphatics are also injected. If the duct does not burst, colourless fluid returns by the lymphatics, which may thus be injected with plain size, while the colouring matter remains in the duct. If a small duct ruptures, the injection often enters the abundant plexus of lymphatics in the portal canals, and may even reach the thoracic duct, as occurred to KIERNAN, and once to myself, in the case of a rabbit.

A human liver which has afforded many excellent specimens, has been injected with four colours, two transparent, and two opaque; as follows, artery with vermilion; portal vein with flake-white; hepatic vein with lake, and the duct with Prussian blue.

Evidence of the existence of a Tubular Basement Membrane in which the Liver-cells are contained.

It is not uncommon to find cells with shreds of delicate membrane attached to them in specimens which have been slightly hardened in dilute alcohol. A drawing which has not been published shows a cell from the rabbit's liver enclosed in a membrane, which can be traced beyond it for some distance as a very narrow contracted tube.

This delicate basement membrane is also well displayed in certain specimens in which a curious chemical change has taken place in the contents of the tube. In a section of dog's liver, which had been soaking for some time in a weak solution of soda, most of the cells appeared to have been dissolved at their outer part, and in consequence, a fusion of the matter of which they were composed had taken place, causing the formation of a highly refracting mass within the basement membrane, the outline of which was rendered very distinct. This preparation is represented in Plate XV. fig. 18, and at *a* one of the tubes, separated and drawn out with its contents contracted within it, is shown.

I have a drawing of a somewhat similar change in the liver of a flounder which had been treated with soda, and afterwards by acetic acid, causing the precipitation of some of the constituents of the bile which had been previously dissolved by the soda. By pressure some of these highly refractive masses were broken, and by examination with a very dull light, the continuity of the delicate basement membrane could be traced between them.

When sections of liver have been soaked for some time in strong syrup or glycerine, the cells in the interior of the tubes shrink from exosmosis, and the delicate

tubular membrane contracts upon its contents. The tubes therefore become much narrower, and, except in the highly refracting nature of the contents, the altered cell-containing network closely resembles that of the capillaries.

In a properly prepared liver, it is often possible to show the cell-containing network in one section and the capillary network in another. When the vessels are distended with clear size, the meshes of the *cell-containing network* are seen; but if a section be well washed and placed in glycerine, the sharp well-defined outlines of the *capillary vessels* are brought into view. In such a section from which the cells have been removed, I have seen in some places, just at the thin edge of the specimen, stretched across the space between two capillary vessels, the exceedingly delicate basement membrane of the tube in which the cells lie, recognizable rather from the small quantity of débris and granular matter which adheres to it, than from any positive characters distinguishable in the membrane itself. This appearance can only be seen under the influence of a very dull light.

The network is capable of being distended to a considerable extent in every part of the lobule without rupture. Often the injection accumulates to such an extent as completely to obscure the cells, and in consequence of the pressure thus caused, the vessels are rendered invisible. Even in such specimens the appearance cannot be mistaken for extravasation or vascular injection. In tubes which are only partially injected, the injection often accumulates a little on each side, gradually shading off as it were towards the centre, while towards the adjacent capillary vessel it forms a distinct, well-defined and dark line.

The cells which escape into the surrounding fluid from an injected specimen have portions of injection adhering to them, or are deeply stained with it.

A portion of the cell-containing network of the human subject injected is shown in Plate XV. fig. 19. The cells represented in the drawing are much altered from the mode of preparing the specimen. Their position, however, is shown. In the pig, portions of the cell-containing network, in different states, are represented in Plate XV. figs. 23, 24, 26, 28. In the seal, in Plate XIV. figs. 15 & 16. In the rabbit, in fig. 11 c. In the dog, in Plate XV. fig. 18. In the human foetus, in Plate XV. fig. 17, and in Plate XIV. fig. 12.

If a section be made through the hepatic tissue exactly at right angles to a small branch of the intralobular vein, the cells are seen to form rows which radiate from the centre towards the circumference of the lobule, as has been noticed by MÜLLER, VALENTIN, BOWMAN, THEILE, GERLACH and others. In sections made in many other directions this radiated arrangement is not to be shown. The drawing in Plate I. fig. 1 (not published) is an exact copy of a section of horse's liver, and is the most beautiful specimen of this arrangement which I have seen. The rows increase in number as they pass from the centre. They are connected at irregular intervals by oblique or transverse branches, often much narrower than a cell, and containing only nuclei and granular matter. These communicating branches are best seen in injected specimens.

The cells of which these rows are composed, for the most part form single lines, although here and there, where the tubes are wider than usual, two cells may be seen lying transversely across the tube. In a specimen in which these radiating tubes had been injected, not only was the existence of a basement membrane proved, but one distinct from, and not adhering to the walls of the capillary vessels. Although the meshes of the capillary network are slightly elongated towards the centre of the lobule, such an arrangement could not produce the appearance observed. If the cells lay promiscuously in the meshes of the capillaries without being circumscribed by any basement membrane, the radiating lines would necessarily be connected transversely by very numerous cells.

Some of these tubes from the human liver are represented in a drawing not published, which was copied from an injected specimen*.

The contents of the cell-containing network are liable to considerable alterations in volume, a change which can be readily effected artificially. In the same specimen the diameter of the network varies to a limited extent, according to the size and number of the cells within the basement membrane. It is usually about $\frac{1}{1000}$ th of an inch in diameter in most mammalian animals, and is considerably wider than the narrowest part of the small ducts with which it is immediately continuous.

The width of the spaces between the tubes of the network, or in other words, the diameter of the vessels, varies much in different parts of the lobule of the human liver, being much wider at the portal surface, where the small branches of the vein enter, than at a greater depth where capillaries are alone found.

This point is shown in sections from different parts of the lobule of the liver of the foetus in Plate XV. fig. 17.

In some situations, then, it is demonstrable that the basement membrane of the cell-containing network is distinct from the walls of the capillaries; but in the greater part of the lobule, where the two membranes come into close contact, they are incorporated, so that really the majority of the liver-cells are nearly surrounded with blood, from which they are only separated by one thin layer of delicate structureless membrane.

In the foetus there is a distinct interval between the wall of the tube in which the secreting cells lie, and that of the capillary vessels; so that when a good section is obtained, two distinct lines are seen between the liver-cells and the cavity of the capillaries. These two lines are separated by a transparent, apparently structureless substance, in which no trace of fibres can be detected, as represented in fig. 17.

These circumstances impress me with the notion that the liver is originally composed of two distinct networks which intimately interdigitate with, or fit into, each other,—one containing the secreting cells, the other the blood. The walls of these

* I have not been able to demonstrate the presence of caecal tubes connected with the branches of the network in the lobules of the liver, but from the arrangement of those of the "vasa aberrantia," presently to be described, and from other appearances which I have observed, I think it likely that such exist in small number.

two sets of tubes gradually become incorporated, except in those situations where the capillary network is less dense, or where the meshes of the cell-containing network are more widely separated from each other; in which cases a distinct limitary membrane to the tubes containing the liver-cells can be demonstrated even in the adult. The cell-containing network and the vascular network can be alternately distended. The membrane is very permeable to water in both directions, as I have proved by first forcing fluid from the vessels into the duct, and afterwards in the opposite direction. Subsequent injection proved that no rupture had taken place. The greatest force which can be applied will not cause the bile to pass through this delicate membrane into the capillary vessels. It is permeable to bile only in one direction.

Of the contents of the Tubular Network of Basement Membrane, and of the Arrangement of the Liver-cells within it.

Within the tubular network lie the hepatic cells, with a certain quantity of granular matter and cell débris, and in some instances, free granules of yellow colouring matter and free oil-globules. The liver-cells have been described by many writers. They are not arranged in any definite or regular manner within the tubes of basement membrane. Their form appears to be determined to a great extent by mutual adaptation and pressure. In adult animals they usually contain one nucleus, and within this is a bright point (nucleolus) and faint granules; rarely cells containing two nuclei are found. In the embryo, however, the cells contain two nuclei very commonly, and often cells are met with which contain several (from two to six). Besides the nucleus, the liver-cell contains, as is well known, coloured granules and oil-globules, apparently suspended in a viscid albuminous material. The coloured granules are not constantly present. Often they are numerous in cells near the centre of the lobule, and entirely absent in those near the margin, while the reverse is usually the case with reference to the oil-globules. On some occasions, cells which contained no coloured granules when first examined, were found to contain several after having been allowed to soak for some time in dilute acetic acid. The granules of colouring matter are, however, not unfrequently present in the cells near the centre of the lobule, as well as in those containing much oil at the circumference. In some instances I have observed that the cells near the centre of the lobule were smaller and were surrounded with a greater quantity of granular matter than those nearer the margin.

Many observers have endeavoured to show that the cells of the liver are arranged in a definite manner. Professor LEREBoullet, one of the latest writers on this point (1853), describes the cells as arranged in double rows, between which injection can be forced so as to separate them, and he gives two diagrams to illustrate his views on this point. I have never seen anything like this arrangement, and, as I have before remarked, injection passes very readily at the outer part of the tubes. In mammalia,

for the most part, the cells form a single row within the basement membrane (human subject, pig, dog, cat, rabbit, horse, seal, Guinea-pig and others). In some situations the tube contains two cells lying transversely across it, but this appearance is often produced by two tubes being placed in close juxtaposition. Sometimes, when the ducts have been injected, two cells may be forced across the tube by the pressure of the injection, Plate XV. fig. 24. The cells do not completely fill the tubes, neither are they always placed quite close together, but a certain quantity of granular matter is seen to intervene. The action of certain reagents in causing the fusion of the contents of the cells has been alluded to, but it is doubtful if these so-called cells in all instances have a distinct membranous wall. Injection runs sometimes on one side and sometimes upon the other side of the tube. Often it entirely surrounds the cells, and not unfrequently presses them to one side and separates them a little from each other, Plate XV. fig. 23.

From these circumstances it would appear that the cells are not firmly adherent to the walls of the tube; indeed many of them often appear to lie free within its cavity, but exhibit a tendency to cohere to each other when set free.

In the only embryos of mammalia which I have examined, there is often more than one row of cells within the tubes, frequently two or three (human subject, calf), Plate XV. fig. 17. The cells are smaller, but in many situations the diameter of the tubes is greater than in the adult.

In birds, the tubes in some parts are wide enough to contain two or three rows of cells, but in others there is only room for one row (duck, linnet, turkey, starling, fowl). In the chick several rows of cells lie within the tubes of the network, Plate XV. figs. 29 & 30.

In those reptiles which I have examined, for the most part several cells are seen lying across the tube (frog, adder, field-snake, newt).

In fishes also the tubes are wide and contain several in the transverse direction (flounder, frog-fish, sturgeon, herring, cod), Plate XV. figs. 36 & 37.

It may be remarked generally that the cell-containing network is widest among fishes, and most narrow in mammalia. The similarity of the arrangement of the cells in the tubular network in the embryos of the higher animals with that existing in the adult, as well as in the embryonic condition of the lower, is a point of interest, of which there are many analogous examples in the case of other organs.

The changes in volume which the hepatic cells so readily undergo, renders it very difficult to ascertain their dimensions with accuracy.

OF THE DUCTS OF THE LIVER.

The duct, like the artery, lies close to the portal vein in the portal canals, and usually on the same side. In the large portal canals the external coats of the duct and artery are incorporated with that of the vein, a point well seen in the horse when the duct is very large. The position of the vessels remains nearly the same in the

smaller canals, but they often change the side upon which they lie. Usually, one branch of the duct and artery accompanies the portal vein, but not unfrequently there are two or more branches of these vessels around the vein.

Anastomosis of the ducts near the trunk from which they come off.—The anastomosis between the larger ducts and of the larger branches of the interlobular ducts with each other in the human liver is pretty numerous, but they are confined to the trunks near their origin. In some animals the branches resulting from the division of the small ducts communicate with each other at a distance from the parent trunk at the margin of the lobule. These communications may be very few in number, or so numerous as to form a network upon the surface of the lobule.

The anastomoses of different interlobular ducts with each other round the lobules, according to my observations, are very rare; and out of numerous injections, I have been able to satisfy myself of its actual occurrence only in one instance.

KIERNAN observed, that if the left hepatic duct were injected with size or mercury, the injection returned by the right duct. It seems not improbable that this may have resulted from the numerous communications between these ducts in the transverse fissure of the liver, rather than from the union of interlobular branches. Not only do the right and left hepatic ducts anastomose by the intervention of small tortuous branches in the transverse fissure of the human liver, as E. H. WEBER many years ago demonstrated, but the branches which come off from these trunks are connected by smaller ones which arise not far from the point at which they are given off. Many of my preparations show a most complete and intimate network at a short distance from the parent trunks in the transverse fissure, and to a less extent in the portal canals. This curious and beautiful network is shown in Plate XIII. figs. 2, 3 & 5. The smallest of these branches seem to have no fibrous coat, and in the larger ones this is much thinner than in the ordinary ducts. In the portal canals these anastomosing branches connected with the ducts are much less numerous, and some of the small communicating branches lie in the thick coats of the ducts, Plate XIII. fig. 6 *a*.

In the foetus the communications are less numerous and the branches less tortuous, but they are to be shown more readily than in the adult, in consequence of their being surrounded by a much less quantity of areolar tissue. In the dog and in the calf I have seen similar communications (Plate XIV. fig. 13 *a*), but they are less numerous than in the human subject.

In the instances above referred to, an irregular network of ducts, more or less extensive, is to be demonstrated near the trunks, but the arrangement is not constant in all animals, nor, so far as I can ascertain, are these communications numerous enough to entitle them to the name of interlobular plexus or network. I have not been able to demonstrate such a network, although I am not prepared to say that it is absent, in the pig, seal, rabbit, horse, cat and monkey. If these communications exist in these animals, they can only be present in a limited extent.

Of the Sacculi of the Ducts.—The so-called “glands” of the ducts have been recognized by KIERNAN and subsequent observers, but the attention of most anatomists has been directed to those which surround the large ducts, rather than to those which are found in the walls of ducts of smaller size.

The so-called “glands” are small cavities of a rounded or oval form, or more or less branched, communicating with the cavity of the duct by a very constricted neck. A very simple sacculus is represented in Plate XIII. figs. 7 & 8, from a small duct of the pig’s liver. These glands are for the most part situated in the coats of the duct, and when injected scarcely project beyond its external surface. The larger branched glands, however, usually extend for some distance from the duct. The glands are usually situated all round the tube (pig, dog, monkey, cat, seal). In the smallest ducts in which they occur in the human subject, they are generally confined to two lines on opposite sides of the tube, but not unfrequently a few may be found between these lines of orifices. These orifices, which were described by KIERNAN, and which lie tolerably close together, forming a straight row of openings on each side of the duct, are best seen when the small duct is laid open. They are, however, almost all of them the openings of small branches of ducts, many of which anastomose in the fibrous coat of the branch to which they belong, and probably very few only should be regarded as sacculi or glands, which are scarce in the small ducts of the human liver. The little dilatations connected with the ducts shown in Plate XIII. fig. 6 *b*, are examples of these so-called “glands” upon some of the smallest ducts in which they occur in the human liver. In the largest ducts in the human subject they are found all round the tube, but in unopened ducts many may escape notice in consequence of the pressure of the glass cover, by which the glands on the upper and lower surfaces are rendered almost invisible, while an undue prominence is given to those at the sides of the tube.

The largest sacculi in the pig are branched, and are situated at the point where a smaller duct leaves the large trunk.

In the human subject, at the point where the smaller ducts open into the large one, the lining membrane is so arranged as to form a valve which would tend to prevent the passage of the bile from the large into the small ducts, more especially as these latter run obliquely for some distance in the coats of the larger duct.

In the pig, glands are numerous upon ducts from the $\frac{1}{125}$ th to the $\frac{1}{100}$ th of an inch and more. They are situated all round the tube, and are rarely seen upon ducts below the $\frac{1}{200}$ th of an inch in diameter. They are not present upon the small interlobular ducts, the walls of which are very thin. In the human subject, in the seal, and in the monkey, they are rare upon ducts below the $\frac{1}{100}$ th of an inch in diameter. In the foetus they are common upon ducts $\frac{3}{500}$ ths of an inch in diameter. They are rarely met with upon ducts in the cat’s liver less than $\frac{3}{200}$ ths of an inch, and in those of the hedgehog below $\frac{9}{1000}$ ths of an inch.

Vasa aberrantia.—The most curious appendages to the ducts are the “*vasa aber-*

rantia," originally described by WEBER in the transverse fissure of the liver. They have been previously alluded to when the anastomoses of the ducts were described. THEILE regarded these ducts, so well named by WEBER, as irregular and branched mucous glands. Some observers, and lately LEREBoullet, have altogether failed to discover these curious branches. The cæcal appendages connected with these ducts are very numerous and of uniform size. Their coats are much thinner than those of the ordinary gall-ducts. They are lined with epithelium, principally of the sub-columnar form.

These curious ducts are most numerous in the transverse fissure, but are also found in the upper part of the umbilical fissure. I have seen these ducts in all the large portal canals, and in those not more than a quarter of an inch in diameter, they are found occasionally. Many of the smaller ducts at their origin from a larger trunk in a portal canal have cæcal appendages like a branch of the vasa aberrantia, and on the other hand straight branches may be traced from these aberrant ducts in some instances in the transverse fissure, to the hepatic tissue, Plate XIII. fig. 4 a.

The vasa aberrantia are always closely surrounded by areolar tissue, in which lymphatics are very numerous, and adipose tissue not unfrequently abundant.

The arrangement of the vessels is peculiar. The arteries and veins form a network, in the meshes of which the vasa aberrantia lie. Each small branch of the artery is accompanied by two branches of the vein, lying one on each side of it, which communicate by numerous transverse branches, some of which pass over the artery, and others under it. It is interesting to observe that this peculiar arrangement of the arteries and veins exists in the coats of the *gall-bladder*, in the *transverse fissure* of the liver, and in the *portal canals*. It is only to be seen in good double injections; but when the vessels are thoroughly injected with different colours, a most beautiful appearance is produced. The veins pour their blood into large branches of the portal vein. This peculiar arrangement of the veins doubtless has the effect of ensuring free circulation through them under different circumstances, and admits of their being compressed or stretched to a great degree without obstruction to the passage of blood through them. Some of these vessels are represented in Plate XIII. fig. 1 a.

In the transverse fissure of the adult human liver the vasa aberrantia lie nearer to the trunk of the portal vein than to the hepatic tissue, and they can be removed without cutting into it. In the liver of the fœtus, on the other hand, the quantity of areolar tissue is much less, and the vasa aberrantia lie so close to the hepatic tissue, that it is impossible to remove them without a thin layer of the latter, into which they enter at numerous points. In the fœtus these ducts are less numerous than in the adult, and their course is less tortuous. They occur in small patches in which the branches are seen to be very numerous, and the anastomoses very frequent. The epithelium is more abundant, and the cells large and of a dark colour, and the injection does not run so readily as in the adult.

These facts appear to me to militate strongly against the notion of these ducts being modified and anastomosing mucous glands, as THEILE supposes. From their arrangement it seems not improbable that they are really altered secreting tubes, and at one time formed a part of the secreting structure of the liver. As the portal vein increases in size at the termination of intra-uterine life, it is not unreasonable to suppose that some of the hepatic tissue close to it would be removed to some extent, to make room for the enlarged vein; in such a case, many of the vessels would degenerate into fibrous tissue, and the branched and anastomosing vasa aberrantia would represent all that remains of the hepatic tubular network.

In the very thin edge of a horse's liver which was composed principally of fibrous tissue, I have been able to trace the gradual alteration of the ducts and the ultimate complete disappearance of secreting cells.

Spread out, as it were, upon the surface of the portal vein in the rabbit, there is a very thin layer of hepatic tissue, and I have been enabled to trace the different stages between the vasa aberrantia and the cell-containing network, most distinctly, in a specimen in which the ducts were injected, and the vein distended with plain size.

Function of the glands and vasa aberrantia.—To the sacculi of the ducts, the office of secreting the mucus in the bile has been assigned, but cavities opening into a tube by a narrow neck, not the $\frac{1}{5000}$ th of an inch in diameter, seem ill-adapted for pouring out a viscid tenacious mucus; neither is it easy to suppose how this mucus, secreted at certain points, would become thoroughly mixed with the mass of the bile as it flowed through the ducts. If these cavities were filled with mucus, one would hardly expect that injection would enter them so readily as it does. The complicated and highly tortuous vasa aberrantia possess no characters which would lead to the inference of their being mucous glands.

Again, the bile of the rabbit, in which animal these glands are very few in number, and only found upon the largest ducts, affords as bulky a precipitate of mucus upon the addition of alcohol as that of the pig, in which these glands are so numerous and so distinct.

It seems highly probable that these little cavities, as they are found in the adult liver, are to be looked upon as reservoirs for containing bile, whilst it becomes inspissated and probably undergoes other changes. The numerous vessels and lymphatics which surround them, and the similarity of arrangement of those around the vasa aberrantia, and of the vessels of the gall-bladder, still further strengthen this view of their office. I have not yet minutely investigated the arrangement of the glands of the ducts in many different animals, nor have I been able to ascertain if ducts, corresponding to the vasa aberrantia, are usually present. I have preparations showing them in the pig, in the rabbit, and in the monkey.

Of the finest branches of the Ducts, and of their connexion with the cell-containing Network.

Mammalia.—In well-injected preparations the smallest branches of the duct can be readily traced up to the secreting cells, Plate XIV. fig. 10. The walls of these ducts are composed of basement membrane only, lined with delicate epithelium. In the human liver, and in that of most mammalia, except the pig, a few of the finest branches of the duct can be followed for some distance beneath the surface of the lobule, and are seen apparently lying amongst the secreting cells.

In many animals, particularly in the rabbit, and to a much more limited extent in the dog and in the human subject, these smallest branches of the duct are connected together so as to form a network of ducts, distinguished by their diameter being much less than that of the network in which the liver-cells lie, and by the character of their epithelium. These branches appear to lie in the most superficial part of the cell-containing network, without being connected with the cells which surround them; but they join, or are continuous with, a portion of the cell-containing network at a deeper part of the lobule. The most superficial portion of the cell-containing network is connected with small ducts which do not penetrate amongst its meshes. This arrangement is shown in a very simple form in Plate XIV. fig. 16, which represents a section from a seal's liver, in which the ducts and cell-containing network were both well injected with transparent blue injection: at *c*, some of the superficial branches of the duct, and at *d*, branches which penetrate beneath the surface of the lobule, are represented. Some of these branches, which appear to lie amongst the secreting cells at the peripheral part of the lobule, have been figured by GERLACH, and are, as he justly observes, much narrower than the cells amongst which they lie. He makes them terminate by open mouths, into which the bile is poured from the cells. The narrowness of these tubes has been advanced as an argument against the possibility of the cells lying within tubes, but from the description just given it will be seen that this objection does not apply.

In the pig, numerous fine branches of the duct are, as it were, applied to the surface of the capsule of the lobule (Plate XIII. fig. 9), which is perforated at frequent intervals by many very narrow short branches, which are immediately connected with a network which partly lies amongst the fibres of the capsule. This network may be looked upon as the most superficial portion of the cell-containing network, and the narrow tubes of which it is composed are found to contain oil-globules, granular matter, and a few very minute cells, Plate XV. fig. 25. When the liver is very fatty, however, this most superficial portion contains numerous secreting cells filled with oil-globules, Plate XV. fig. 28. I have not been able to trace any ducts passing amongst the meshes of the most superficial part of the cell-containing network, as I have described in animals in which the distinct lobules do not exist. In the last figure, the very narrow ductal portion of the tube is seen to dilate considerably at the

point where the secreting cells commence. This drawing is an exact copy of a beautiful preparation of a very fatty pig's liver which had been injected, and the parts which were injected in the preparation are represented in the drawing by the dotted shading. The continuity of the narrow duct with the wide tubes in which the secreting cells lie is well shown, in consequence of this part being accidentally separated from the adjoining portion.

The extremely delicate nature and narrowness of the ducts will readily explain the difficulty of demonstrating their continuity with the cell-containing network, particularly in the pig's liver, for they almost invariably break at this constricted portion, especially as this partly lies in the substance of the capsule of the lobule. I have seen the same anatomical point in many specimens, but in none more distinctly than in the preparation referred to, which still preserves its essential characters (June 9th, 1856).

In Plate XV. fig. 19, the connexion between the small ducts and the cell-containing network is shown in an injected specimen of human liver. The duct is greatly distended with injection, and the hepatic cells have been much altered in preparing the specimen. The communications between the finest branches of the duct are few in the human liver; a branch can often be followed for some distance amongst the meshes of the peripheral part of the cell-containing network, until it is seen to become continuous with it at some distance from the surface. These branches can only be seen in injected specimens.

In Plate XV. figs. 20 & 21, the connexion between the ducts and secreting network is shown in an uninjected liver, which had been treated with soda, and kept for some time in strong syrup. The liver-cells have been destroyed by the mode of preparation. The narrow duct is well seen at *a*, fig. 21. The other specimen has been subjected to considerable pressure.

In the human foetus, the connexion between the duct and cell-containing network is shown under the influence of a low power in Plate XIV. fig. 14 *a*, and also in figs. 12 & 13.

In a seal's liver which I injected, the hepatic cells were small, and the injection very readily passed into the cell-containing network. The small ducts are comparatively few in number, but their course was very easily traced. Often they could be readily followed upon the thin wall of a small portal vein, as shown in Plate XIV. figs. 15 & 16. In the latter figure, small branches of the duct are seen passing amongst the superficial branches of the cell-containing network to join some of those at a deeper part. At *c*, two or three branches are seen, which were connected with that portion of the network nearest to the large duct.

Fig. 11 is a drawing of a section of a rabbit's liver, taken from a very thin and emaciated animal, in which the cells were much smaller and more granular than in health. The tubes of the network were shriveled, and in many situations contained only granular matter. In a thin section of this liver, narrow granular lines,

communicating at intervals with each other (cell-containing network), were seen separated by wide clear spaces (capillaries) intervening between them. In this liver the very fine ducts were injected to a greater extent than can be effected usually, and a network of anastomosing branches round the portal vein is shown in the drawing. Even in this specimen the injection has not entered many of the small branches of the duct. The injection ran very readily, and in some places distended the tubes of the cell-containing network to a very great extent, in which case of course the clear intervening space (capillary) was obliterated.

Birds.—In the fowl and in the turkey, the ducts form a network continuous with the network in which the liver-cells lie; but the tubes are of much less diameter than those of the latter. I have been able to trace the continuity in the livers of the two birds above referred to, by injection. The abundance of epithelium in the ducts of most birds forms a great obstacle to the passage of the injection, and the excessive thinness of the capillary vessels prevents the preliminary injection of much water without rupture.

In the chick of the fifteenth and also in that of the twenty-first day, the continuity between the ducts and cell-containing network is shown in Plate XV. figs. 29 & 30.

Reptiles.—In the newt (*Triton cristatus*), the course of the ducts, in an uninjected specimen, is shown in fig. 31. The tubes in which the hepatic cells lie were much stretched and pressed in these specimens. I have not yet been able to inject the ducts of the newt or frog.

I have succeeded in making a good injection of the ducts of the adder, and was enabled to trace their continuity with the wide tubes containing the liver-cells. The large branch of the portal vein is surrounded with a plexus of ducts.

Fishes.—The greatest difficulties presented themselves in the investigation of the anatomy of the ducts in this class. The ducts become exceedingly narrow before they join the very wide tubes of the network containing the cells. I have not been able to harden the liver sufficiently to obtain very thin sections, and in tearing out the finer ducts they always break off in the narrow part.

Numerous attempts at injecting the liver failed altogether in consequence of the vessels rupturing when the water was thrown in. Another source of great inconvenience is the frequent occurrence of entozoa and their ova. In consequence of the tubes being almost always full of cells containing oil, and free oil-globules, it is difficult to obtain a specimen for examination which is not rendered obscure by the escape of numerous cells into the fluid in which the preparation is placed.

In the common flounder, the connexion between the ducts and cell-containing network has been demonstrated in an uninjected specimen. In this specimen the secreting tubes were much shrunken and of less diameter than usual, a circumstance to which the distinctness of their outline is due.

I have injected the ducts and a part of the cell-containing network of the sturgeon

and Lophius. In Plate XV. figs. 32, 33, 34 & 35, some of the ducts and portions of the network are represented. The mode of branching of the ducts, and an anastomosis, is shown in fig. 33. Even in the very fatty liver of the cod, I once traced the continuity of the ducts and the wide tubular network distended with cells containing oil and free oil-globules.

In injecting the livers of fish it is necessary to dilute the injecting fluid with weak spirit, or it will not penetrate to the finest branches. Often the particles of the injection accumulate in some of the finer ducts, forming what appears to be a rounded and slightly dilated extremity, for the further continuity of the tube cannot in all cases be seen. Indeed so perfect is the resemblance, that it is only by examining numerous different specimens that one becomes convinced of the fallacy.

In all four classes of vertebrata, I have seen both in injected, and also in uninjected specimens, the communications between the finest ducts and the cell-containing network. Of the nature of this continuity there can, I think, be no doubt. I cannot conceive any other explanation of the facts I have observed, or of the appearances I have copied from my preparations. The observations upon uninjected specimens, shown in Plate XV. figs. 18, 20 & 21, were made in 1854, many months before I had succeeded in injecting the ducts.

In all vertebrate animals which I have examined, the duct becomes much narrowed just before it becomes continuous with the tubes of the network in which the secreting cells lie. The arrangement of the most minute ducts varies somewhat in different animals, as has been described. In some they form a network of very narrow tubes, continuous with those in which the liver-cells are contained; in others these communications are excessively few in number; while in some, I do not think they exist at all. But I would not express myself positively upon this point, for I feel persuaded that in the most perfect injection which I have yet made, the minute ducts have not all been injected, and from a cursory examination of these preparations alone, only a very imperfect idea of the number of the ducts or of the beauty of their arrangement and relation to the other structural elements of the liver in the natural state of the organ, can be formed.

Diameter of the finest ducts.—The diameter of the finest ducts can only be obtained approximatively; for when not injected, they can only be demonstrated distinctly in fortunate specimens, and are probably somewhat narrower than during life. When injected, on the other hand, they are usually distended, and sometimes to a very considerable extent.

In the pig, the smallest branches containing a little injection are not more than the $\frac{1}{3000}$ th of an inch in diameter; in the human subject, about $\frac{1}{2500}$ th; in the seal, $\frac{1}{3000}$ th; in some fishes, not more than $\frac{1}{5000}$ th.

The diameter of the cavity of the tube and the total diameter of ducts of different sizes are shown in the following Table:—

		External diameter.	Internal diameter.
Pig	{	·008	·004
		·006	·003
		·001	·001
Human subject	{	·01	·0045
		·002	·002
Human foetus		·01	·0045
Cat		·015	·0075
Monkey		·02	·01
Seal	{	·001	·001
		·0003	·0003

The diameter of the ducts from which my drawings were taken can be readily determined by reference to the scales appended to the Plates.

The narrowing of the excretory duct, just before it becomes connected with the secreting tube, is seen in other glands; thus the straight and ductal portion of the renal tube is narrower than the convoluted and secreting portion. It must, however, be borne in mind, that although the excretory portion of the tube is so small, its cavity, through which the secretion passes, is wider than in that part in which the secretion is separated. In the liver, where the secretion is highly elaborated and slowly removed in a more concentrated form, we should naturally expect to find the contrast between the ductal and secreting portions of the gland still greater than in most other secreting organs.

Epithelium of the small ducts.—As is well known, the larger ducts have a thick lining of columnar epithelium, the cells of which become shorter and altogether smaller in the finer ducts. In the narrowest tubes the cells of epithelium are somewhat flattened, and usually of a circular form. Sometimes they are oval or angular, depending probably upon being stretched. They have a faintly granular appearance, and rarely a nucleus can be seen within. The quantity of this epithelium varies very much; sometimes it completely lines the tube. In some instances it is so abundant as apparently to leave no distinct cavity in the duct, while it is not uncommon to find some of the finest ducts containing only a very few cells scattered at irregular intervals over the basement membrane, of which the coats of these small ducts are alone composed. In a perfectly normal condition, when the minute ducts are undisturbed by manipulation, and are examined in a proper medium, they are generally seen to be lined by epithelium; but from the extreme minuteness of these ducts and tender character of their walls, it is scarcely surprising that one should fail in making out distinctly the epithelium in every instance. The epithelium of the small ducts presents very similar characters in all the animals in which I have been able to demonstrate it. In the human subject it is shown in Plate XV. figs. 20 & 21, and in the seal in Plate XIV. fig. 16, at *b*.

This ductal epithelium does not pass by insensible gradations into the secreting

hepatic cells, but usually ceases at the point where the narrow duct expands into the wide secreting tubes of the network. In a few instances I have seen tubes containing liver-cells lined with this delicate epithelium, observations which confirm those of Mr. WHARTON JONES, who has seen hepatic cells in the smaller ducts. In these cases the cells may have accidentally entered the ductal portion of the tube.

The arrangement above described is very similar to that which occurs in the gastric gland. It is only in the lower part (stomach tube) that the cells of spheroidal epithelium (which alone there is every reason to believe take part in the secretion of the gastric juice) are found. The upper portion or duct (stomach-cell) is lined with columnar or subcolumnar epithelium*. The secreting cells are not arranged with any order or regularity round the basement membrane of the tube, as in the kidney, but appear to fill its cavity; so that the secretion having escaped from the cells with or without their liquefaction, must pass off by the slight interstices between them. As I have before remarked, the same irregularity occurs in the arrangement of the secreting cells in the tubular network of the liver, and as may be observed in a less remarkable degree, in the secreting portion of many other glands, as the pancreas, lacteal glands, sebaceous and sweat glands.

The conclusions to which I have been led from my observations, may be summed up as follows:—

1. That the liver of vertebrate animals essentially consists of two “solid” tubular networks mutually adapted to each other. One of these networks contains the liver-cells, the other the blood.

2. The cell-containing network is continuous with the ducts. The small delicate epithelial cells lining the latter channels contrast remarkably with the large secreting cells, which are not arranged in any definite manner within the tubes of the network.

3. The duct is many times narrower than the tubular cell-containing network at the point where it becomes continuous with it.

4. Injection passes sometimes on one, and sometimes on the other side of the tube, or between the cells, where two or more lie across the tube. As injection can thus be made to pass readily *from* the ducts into the network and around the cells, it follows that there can be no obstacle to the passage of the bile along the same channels in the opposite—its natural direction.

5. In some animals, the most minute ducts are directly connected with the tubes of the cell-containing network. Of these branches, some pass amongst the most superficial meshes to join the network at a deeper part. In other animals the finest ducts form a network which is continuous with that in which the liver-cells lie.

6. The interlobular ducts do not anastomose, but the branches coming off from the trunk are often connected with each other, as well as with the parent trunk, near their origin from it, by intervening branches.

* TODD and BOWMAN'S Physiology, vol. ii.

7. The walls of the smallest ducts are composed of basement membrane only. The thick complex coat of the larger ducts contains within it small cavities (the so-called glands of the ducts), by which the bile in these thick-walled tubes would be brought into close proximity with the arteries, veins and lymphatics, which are very abundant wherever the ducts ramify.

8. The office of the vasa aberrantia, which are so numerous in the transverse fissure of the human liver and in the larger portal canals, appears to be similar to that of the cavities in the walls of the ducts. It is worthy of remark, that the network of vessels ramifying so abundantly in the coats of the gall-bladder, in the transverse fissure, and in the large portal canals, is arranged in a similar manner, each branch of artery being accompanied by two branches of the vein.

9. The liver is therefore a true gland, consisting of a formative portion and a system of excretory ducts directly continuous with it. The secreting cells lie within a delicate tubular network of basement membrane, through the thin wall of which they draw from the blood the materials of their secretion.

EXPLANATION OF THE PLATES.

The dotted shading in the Plates corresponds to the Prussian blue injection represented in the drawing. By tracing this shading, the extent to which the injection had penetrated in the preparation is shown.

To ascertain the diameter of any object represented, it is only necessary to compare it with one of the scales at the foot of the Plates, the divisions of which are *magnified in the same degree as the drawing*.

PLATE XIII.

Fig. 1. Vasa aberrantia, from the transverse fissure of the human liver, injected with Prussian blue. *a*. Branches of portal vein injected with white lead. *b*. Branches of hepatic artery injected with vermilion. *c*. Branches of duct or vasa aberrantia, in some places only partially injected.

Figs. 2 & 3. Ducts with vasa aberrantia, from the transverse fissure of the human liver, injected with Prussian blue.

Fig. 4. Dilated portion of duct from the transverse fissure of the human liver, giving off long straight branches to secreting structure.

Fig. 5. Vasa aberrantia and parietal appendages of ducts from the transverse fissure. This drawing represents the portion of fig. 3 marked *a*, magnified 8 diameters.

Fig. 6. Interlobular duct with lateral appendages and one or two irregular branched ducts or vasa aberrantia. The greater number of the lateral channels are seen not to project beyond the outer surface of the fibrous coat of the duct, *a*.

Fig. 7. *b*. Interlobular duct with parietal sacculi of the pig, injected with Prussian blue. *c*. Branch of artery.

Fig. 8. One of the sacculi marked *a*, fig. 10, magnified 215 diameters. *a*. Fibrous coat of duct. *b*. Cavity of sacculus filled with injection. *c*. Epithelium.

Fig. 9. A very small lobule of the pig's liver, showing the ducts dividing into branches upon the surface of the capsule.

PLATE XIV.

Fig. 10. Transverse section of human liver, showing the general arrangement of the ducts in the interlobular fissures. *a*. Branches of portal vein injected with white lead. *b*. Small branches of intralobular vein, injected with lake. *c*. Capillaries of lobule, represented only in a few situations. *d*. Branches of duct injected with Prussian blue passing towards the lobules, and giving off few branches in their course. The imperfect manner in which the lobules are mapped out in the human subject and in most other mammalian livers, is shown in this figure.

Fig. 11. Interlobular duct of the rabbit, injected with Prussian blue. *a*. Trunk of duct. *b*. Small branches passing off to cell-containing network, and anastomosing with each other. *c*. Commencement of cell-containing network at the margin of the lobule, showing its continuity with the finest ducts. In this specimen the liver-cells were much disintegrated from disease. The tubes of the cell-containing network were occupied with granular matter in which very few liver-cells could be detected. The injection consequently penetrated very readily for a considerable distance, as shown by the tinting.

Fig. 12. Interlobular duct, parietal sacculi, and branches of communication (*a*) from the human foetus. At *b* small branches of the ducts are seen passing off to, and becoming continuous with, the cell-containing network of the lobule. Injected with Prussian blue.

Fig. 13. A corresponding preparation from the foetal calf near the full time. The sacculi are large and distinct. In this figure the outline of the portal vein, which was injected with plain size, is shown. *a*. Branches of duct passing to cell-containing network of lobule.

Fig. 14. Interlobular ducts and smaller branches from the human foetus, showing their anastomoses, and, at *a*, their continuity with the cell-containing network at the margin of the lobule. *b*. Section of a small branch of the portal vein with ducts around it, which have been cut across in making the section. In this preparation the ducts were injected with carmine.

Fig. 15. A small portal canal from the liver of the seal. The portal vein injected with plain size, and the duct with Prussian blue. *a*. Artery. *b*. Duct.

Small branches of the duct upon the transparent portal vein are seen to be continuous with the network of tubes in which the liver-cells lie, and into which network a little injection has passed from the duct. The part of the cell-containing network represented in this figure is situated immediately round the portal canals, which contain but little areolar tissue in the seal.

- Fig. 16. Small ducts from the seal injected with Prussian blue, showing their continuity with the cell-containing network of the lobule. At *a*, the outlines of a few capillaries of the portal vein injected with colourless size are seen. *b*. A small branch of the portal vein. The narrowest portions of the duct in this preparation have been distended considerably by the injection.

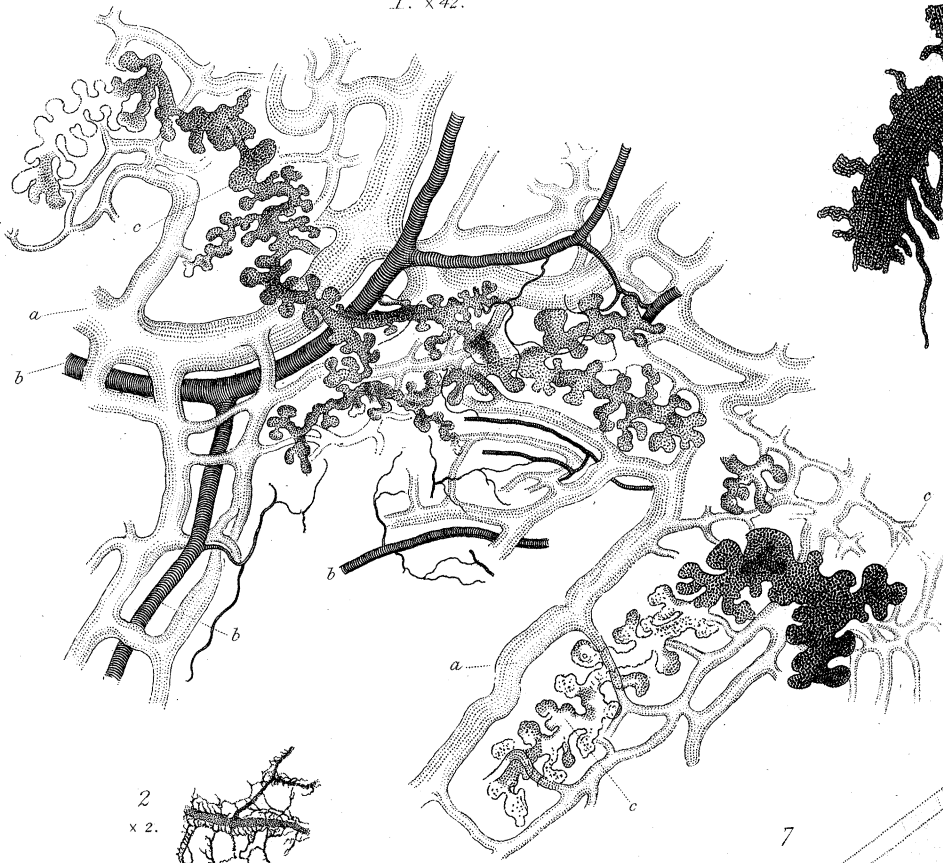PLATE XV.

- Fig. 17. Portion of cell-containing network of human fœtus at the point of entrance of a small branch of the portal vein which is about to divide into capillaries. The meshes of the cell-containing network at this point are much wider than at a greater distance from the circumference of the lobule, in consequence of the vessels being larger. The outlines of the tubes of the network and of the walls of the capillaries are seen to be separated by an intervening, perfectly transparent material.
- Fig. 18. Part of the cell-containing network of the dog's liver where its branches are parallel, altered by being soaked for some time in dilute caustic soda. A few cells are seen, but the greater number are fused together, and the tubes are chiefly occupied by a yellow, transparent, highly refracting substance, in which numerous oil-globules are contained. *a*. A tube stretched and separated from its neighbours, showing its basement membrane and contents.
- Fig. 19. A small duct from the human liver at the point where it becomes continuous with the cell-containing network. The cells are much altered in character from the mode of preparing the specimen. The duct is very much distended with injection.
- Fig. 20. Section of the liver of a man, aged 43, which had been hardened. Uninjected. This preparation shows the continuity of the most minute ducts with the cell-containing network. The epithelium of the smallest ducts is seen in this specimen. The hepatic cells are destroyed by the action of soda. This preparation has been subjected to great pressure between the glasses.
- Fig. 21. A similar preparation, not so much flattened by pressure. *a*. Finest ducts. *b*. A venous capillary cut across. *c*. A small artery.
- Fig. 22. An interlobular duct dividing into smaller branches upon the surface of a

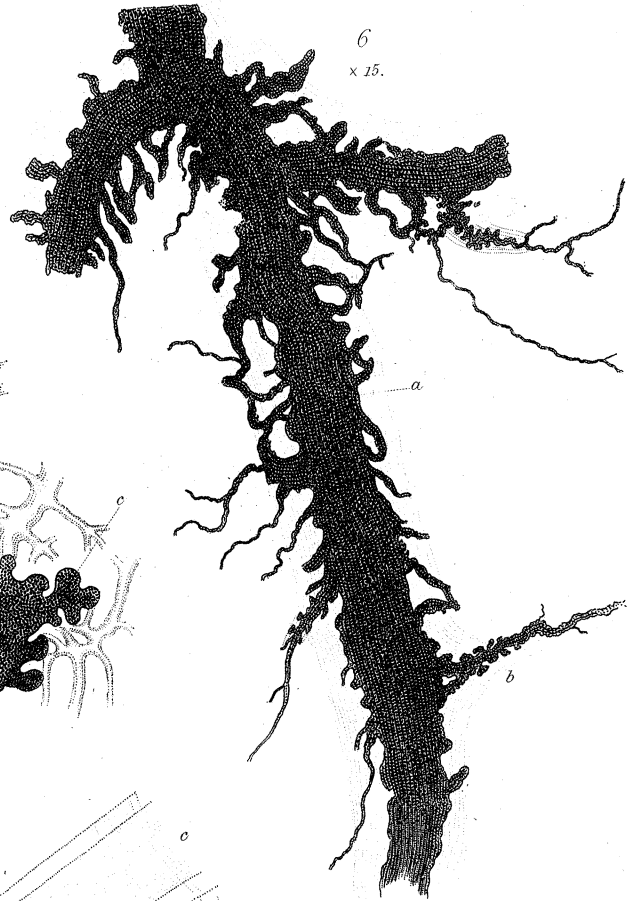lobule of pig's liver: injected with Prussian blue. The injection has entered the superficial portion of the cell-containing network, producing the mottled appearance represented.

- Fig. 23. A portion of cell-containing network near the surface of a lobule from the pig's liver, injected and isolated. The injection has pressed the cells towards one side of the tube, and partially separated them from each other, and has thus prevented the thin wall of the tube from being in close contact with them.
- Fig. 24. Part of cell-containing network (pig), showing liver-cells, granular matter and oil-globules in the interior of the tube. In one part the tube is somewhat dilated.
- Fig. 25. Most superficial portion of the cell-containing network (pig), lying partly in the fibrous capsule of the lobule, and partly within the capsule. The tubes contain a few small cells, free oil-globules and granular matter. Partially injected.
- Fig. 26. Portion of cell-containing network within the capsule of the lobule, injected with Prussian blue. Pig.
- Fig. 27. A small portion of fig. 25 distended with injection.
- Fig. 28. Connexion of duct with cell-containing network from a fatty liver of the pig: injected. The small trunk *a* gives off several smaller branches, *b*, not more than $\frac{1}{3000}$ th of an inch in diameter, although distended by the injection which has reached the cell-containing network. The tubes of the latter are four or five times wider than the smallest ducts.
- Fig. 29. Part of cell-containing network and finest ducts of chick on the 15th day of incubation, from a preparation which had been hardened in alcohol and soda.
- Fig. 30. A similar preparation on the 21st day. The tubes contain much oil.
- Fig. 31. Branches of duct of newt (*Triton cristatus*). At *a* the commencement of the tubes of the cell-containing network.
- Fig. 32. Ducts and their connexion with the cell-containing network. Sturgeon. Injected.
- Fig. 33. Ducts of *Lophius piscatorius*; injected. Natural size.
- Figs. 34, 35. Finest ducts of *Lophius* and their connexion with cell-containing network; injected.
- Fig. 36. Part of cell-containing network. *Lophius*.
- Fig. 37. A similar preparation with branches of capillary vessels, *a*.
- Fig. 38. Portion of a large duct (*Lophius*), with a branch, showing epithelium in the interior, an internal coat composed of circular muscular fibres, and an external thicker coat consisting of longitudinal fibres.

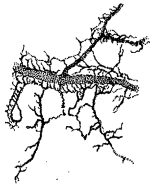1. x 42.



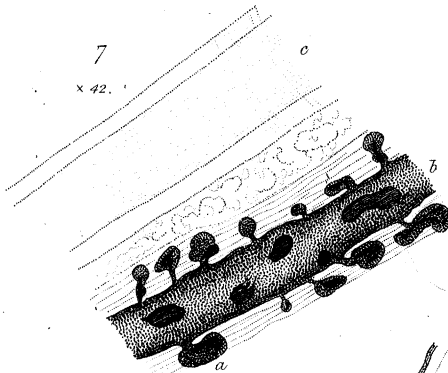
6
x 15.



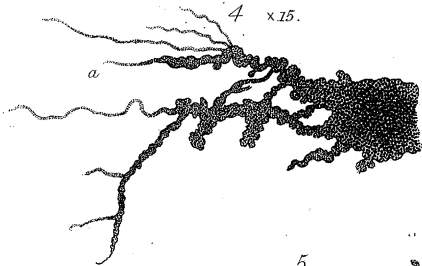
2
x 2.



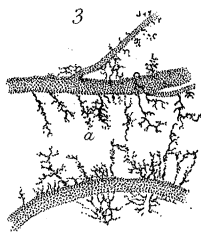
7
x 42.



4 x 15.

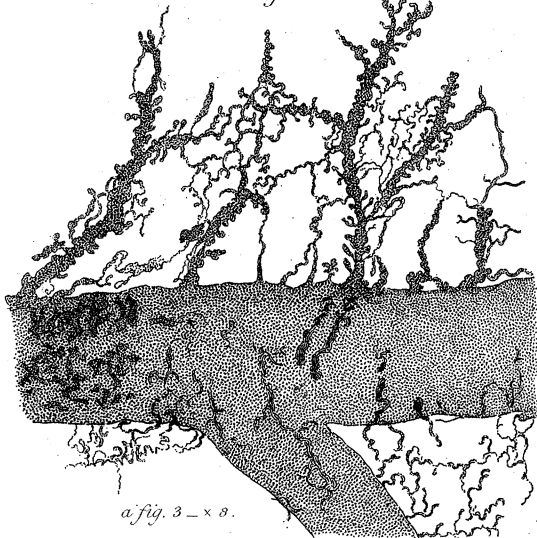


3



nat. size.

5

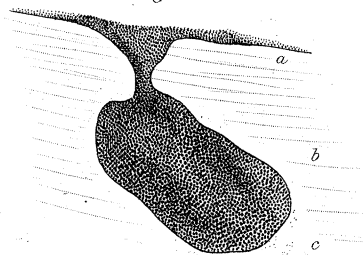


a fig. 3 - x 8.

9
x 42.

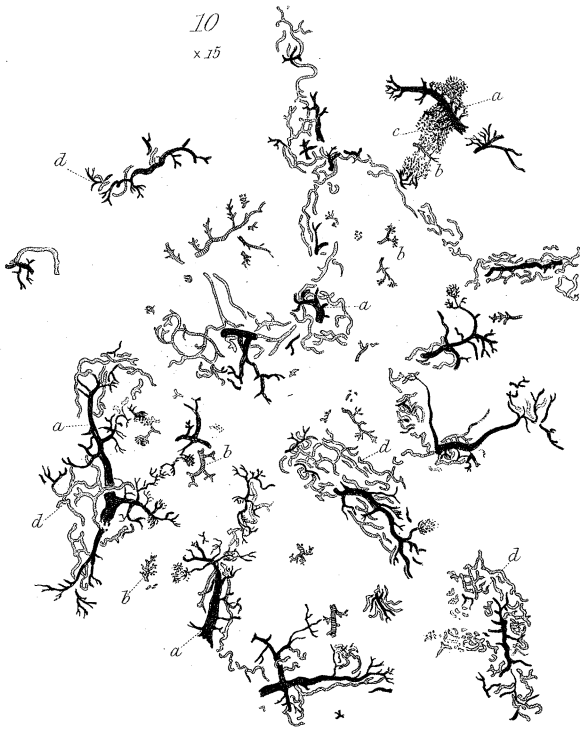


8

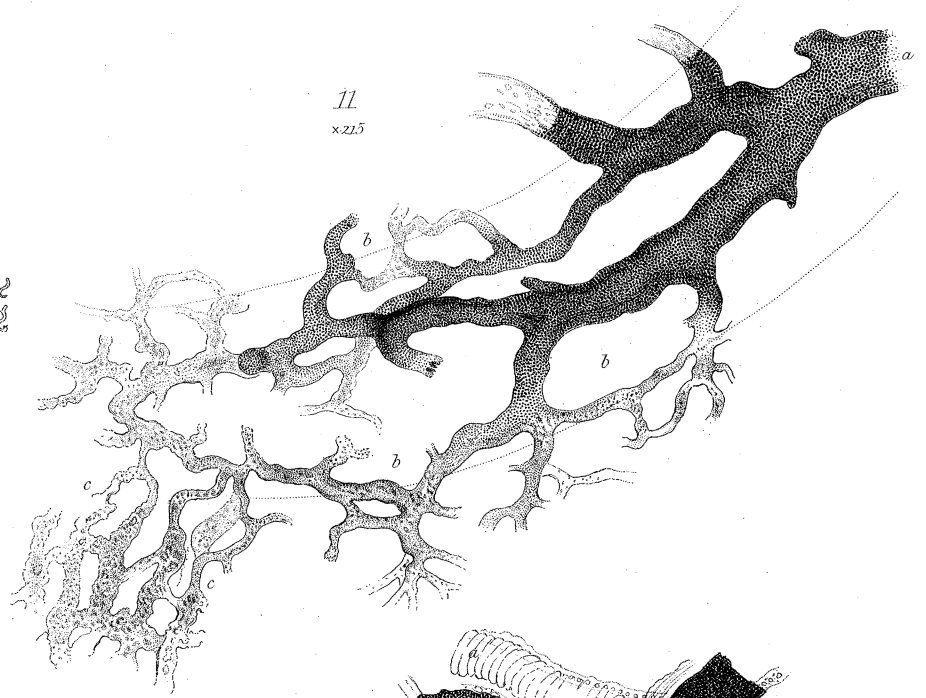

a fig. 10 x 215.

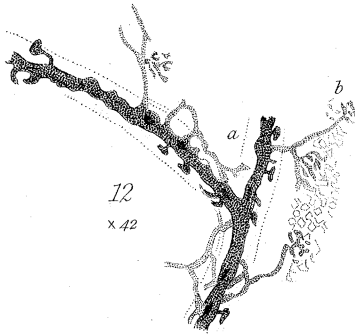
10
x 15



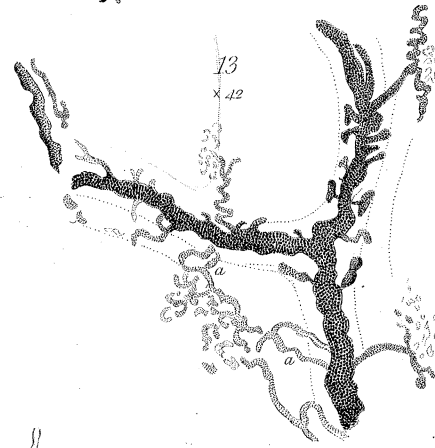
11
x 215



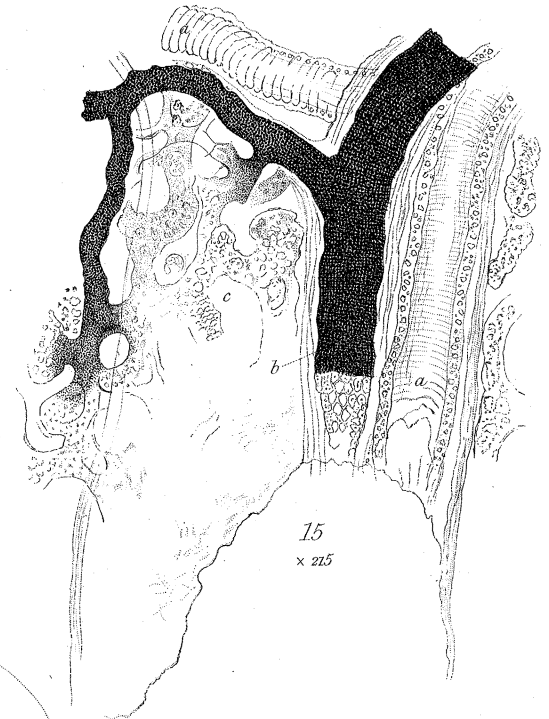
12
x 42



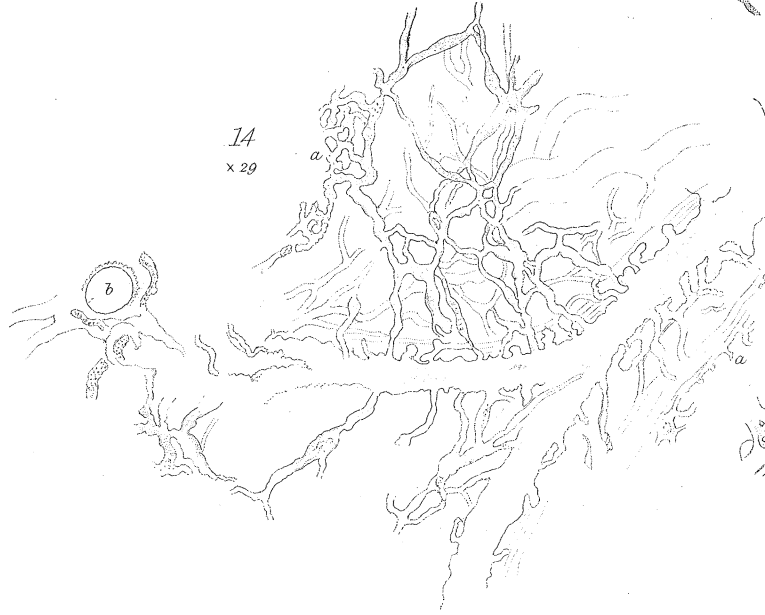
13
x 42



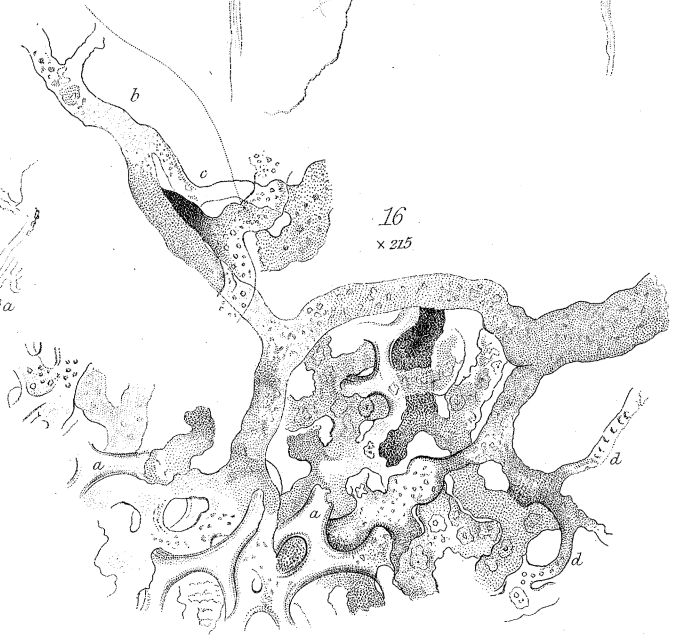
15
x 215



14
x 29

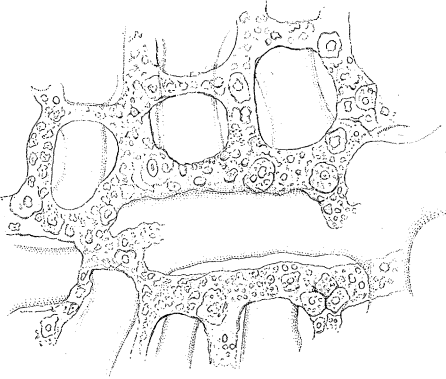


16
x 215

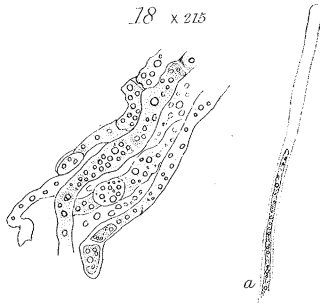


Scale. 100^{ths} x 15
100^{ths} x 20
100^{ths} x 42
Parts of an English Inch. 1000^{ths} x 215

17 x 215



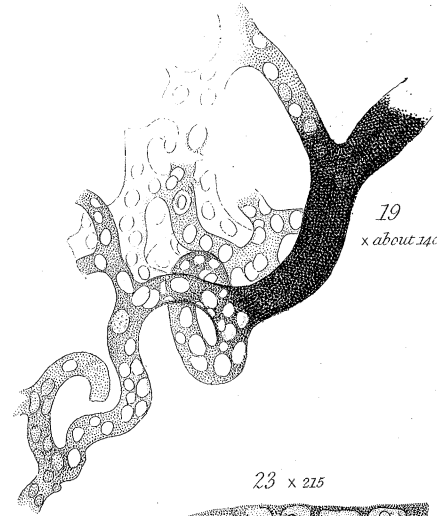
18 x 215



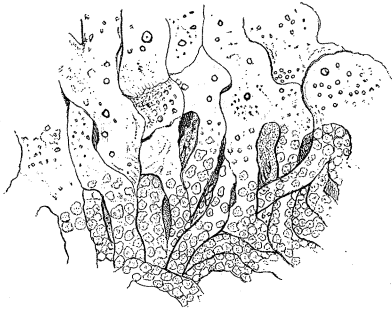
a

19

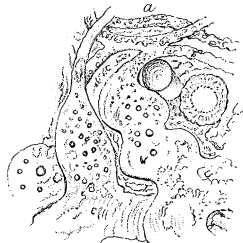x about 140



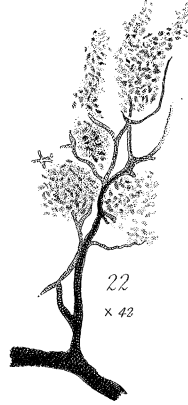
20 x 215



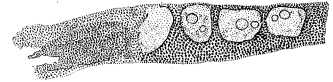
21 x 215



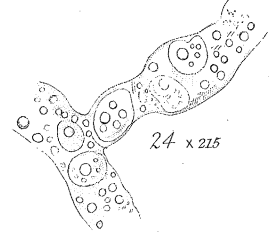
22
x 42



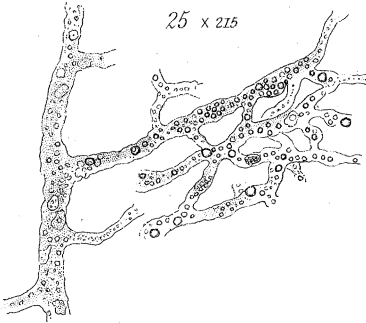
23 x 215



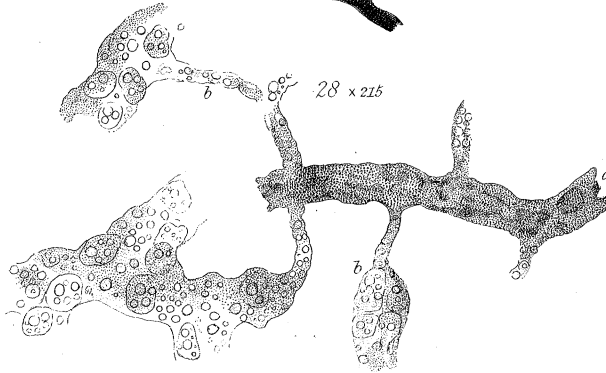
24 x 215



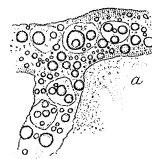
25 x 215



28 x 215



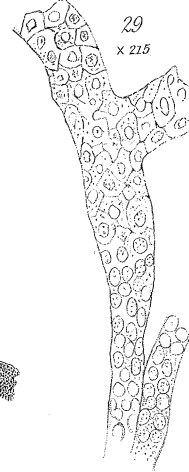
37
x 215



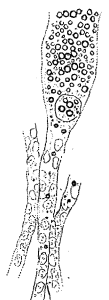27



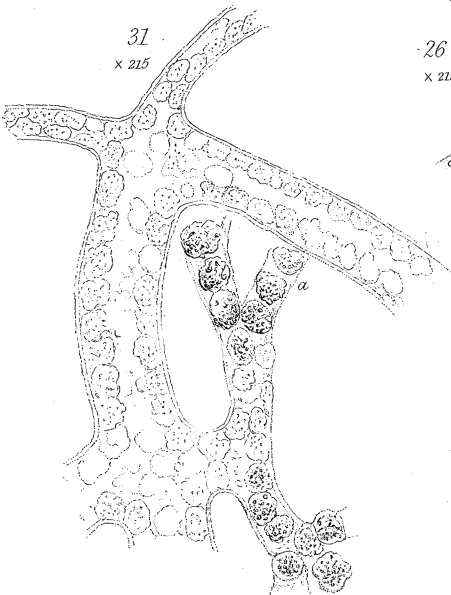29
x 215



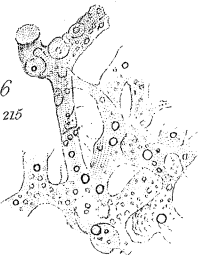
30
x 215



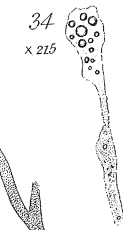31
x 215



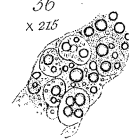26
x 215



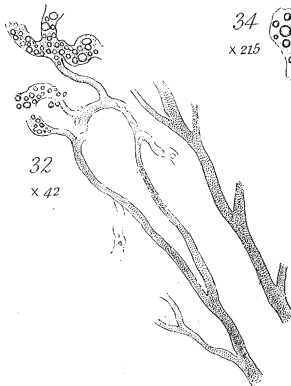
34
x 215



36
x 215



32
x 42

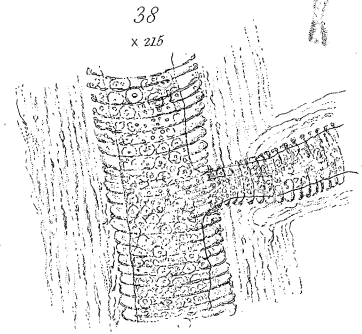


33

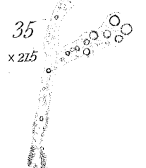

nat. size.

38
x 215



35
x 215



Scale.
Parts of an 100^{ths} x 42
English Inch 1000^{ths} x 215