

X. *On the Skeleton of the Marsipobranch Fishes.*—Part II. *Petromyzon.*

By WILLIAM KITCHEN PARKER, F.R.S.

Received January 10,—Read January 18, 1883.

[PLATES 8, 10, 14, 15, and 18–26.]

IN this Second Part the Marsipobranch type of skeleton will be described in several stages, as far as my materials go ; afterwards, I hope to be able to show in a Third Part some of the organs in the act of transformation, the specimens for which I am now expecting.

In the present paper I shall describe :—

- A. The skeleton after transformation.
  - a. In the adult *Petromyzon fluviatilis*.
  - b. In one-third grown *P. marinus*.
  - c. In newly metamorphosed *P. marinus*.
  - d. In very small (not quite transformed) young of *P. marinus*.
- B. The early embryo of *P. planeri*; and
- C. The larval form (or *Ammocæte*) of *P. fluviatilis*, ready for transformation.\*

These stages give most of the facts we are looking for, but it will be a satisfaction to be able to explain every step in this remarkable metamorphosis.†

The friends to whom I am indebted for materials for the present paper are Professor HUXLEY, F.R.S., FRANCIS DAY, Esq., F.L.S., the late FRANK BUCKLAND, Esq., Professor RAY LANKESTER, F.R.S., the late Professor F. M. BALFOUR, F.R.S. (in conjunction with OSBERT SALVIN, Esq., F.R.S.), F. G. PENROSE, Esq., and Dr. ALBERT GÜNTHER, F.R.S.

\* Since this paper was read I have received figures of the early embryo of *Callorhynchus* from my son, Prof. T. J. PARKER, who has succeeded in finding an early stage of this important type on the shores of New Zealand. I am now satisfied that the Chimæroids are *not* nearly related to the Petromyzoids.

† The Bibliography has been given in the First Part.

A.—*The skeleton of the Lamprey after transformation.*

I shall at once take up the permanent form of the skeleton, that it may link itself on to that of the Myxinoid form described in the First Part.

a. *Dissections of the young (one-third grown) of Petromyzon marinus.*

The substance of which the skeleton of the Lamprey is composed is mainly the two kinds of true cartilage, soft and hard. The latter is the densest kind of hyaline cartilage seen in the Vertebrata; greenish, when looked at by reflected light, it is of a clear amber colour when seen in the mounted transparent sections; in the early embryo both kinds are similar, having very little intercellular substance. The *vacuolar* tissue is in the Lamprey confined to the notochord, the sheath of which, as in the Myxinoids, is a strong web of white fibrous tissue.

1. *The post-cephalic part of the axial skeleton.*

Here we have, after metamorphosis, roughly conical patches of hard cartilage (Plate 18, fig. 1; and Plate 22, figs. 7–9, *n.a.*) ascending the sides of the *theca vertebralis*, mounting above it, and having their bases attached to the side of the sheath of the notochord, which maintains its size and its cylindrical form between these paired rudiments, the beginnings of neural arches. This is almost the only part of the post-cephalic region in which anything but fibrous tissue is found as a skeletal structure, for the huge pharynx is supplied with, and dominated by, a cranial nerve, right and left, the *vagus*. Yet cartilage is continued backwards, as the pharyngeal and pericardial skeleton, as far as the 13th pair of vertebral arches (Plate 18, fig. 1, *ex.br.*, *pcd.c.*, *v.a*<sup>13</sup>).

2. *The cranio-facial apparatus—cranium, proper, and ventral or intra-visceral outgrowths (rudimentary arches).*

This continuous growth of hard cartilage (mainly) has a much less antero-posterior extent than in the Myxinoids, only part of the hyoid, and none of the *intra-branchial* bars, being developed inside the temporary embryonic head-cavities and persistent aortic arches.

Nevertheless, such evident rudiments of visceral arches as can be found, albeit merely seen as basi-cranial “outgrowths” growing downwards, will be spoken of in familiar terms, the adult Myxinoids, larval Anura, and the larva of *Lepidosteus*, giving us some boldness in the determination of these ventral growths of the head.

For in all these types we have a more or less *continuous* cartilaginous growth of the

cranio-facial skeleton; the facial parts being such as are developed inside the remnants of the pleuro-peritoneal space, which for a time remain as the "head-cavities."

The cranial part of the notochord (Plate 18, fig. 4, *nc.*) is twice as long as in the Myxinoids (Plates 9, 10, 16, and 17), for the invested apex can be seen projecting into the small sagittiform pituitary space ("basi-cranial fontanelle," *b.c.f.*), so as to be further forwards than the hind margin of the sub-ocular fenestra (*s.o.f.*). The apex turns upwards (fig. 5, *nc.*), and this part is invested by the hardened parachordals, which end as hard cartilage in front of the hind face of the auditory capsules (fig. 4, *iv.*, *au.*), but send backwards, below, paired spurs up to the point where, in a Tadpole, the occipital condyles would be formed. The cranial notochord becomes invested by cartilage equally above and below (Plate 22, figs. 2-6), and thence, outside, the cartilage thickens and extends right and left, until, reaching the auditory capsules, it, for a considerable extent, underfloors them. Here, however, there is no facial bar growing out from their outer sub-auditory edge as in the Myxinoids (Plates 9, 10, 16, and 17, *au.*, *iv.*, *hm.*). Where the investing mass (parachordals) passes into the trabeculæ (*iv.*, *tr.*), there the basi-cranial cartilage does extend itself into a facial outgrowth—the pedicle (*pd.*).

In front of these outgrowths the basis cranii has an elegant, narrow waist (fig. 4), bounded by the narrow hind part of the trabeculæ (*tr.*), which have a membranous tract right and left of them, and also between them (*s.o.f.*, *b.c.f.*). The middle or "pituitary" space has opened to let out the posterior nasal canal (Plate 23, fig. 1, *p.n.c.*), which passes, widening towards its enlarged *blind* end, under the cranial notochord.

From this point the trabeculæ diverge, and the space left between them is filled in by the hind intertrabecula (Plate 18, fig. 4, and Plate 10, fig. 5, *p.i.tr.*), which is everywhere confluent with them, except where vessels pass through.

The proper basis cranii is finished in front by the confluence of these three bars, and this solid ethmoidal region has a convex outline in the middle, which outline is made sinuous by a retreat of the edge, right and left, where the ethmo-palatine bars have grown on to the trabeculæ (*ep.a.*, *tr.*). This whole floor is concave below, although its middle plate was convex at first, for the pterygo-palatines, like "flying buttresses," drop down, rather suddenly, and thus form an arched, or roof-like structure. A narrow sinuous band of soft cartilage runs along the front of the skull (ethmoidal region, *eth.*), and then hard cartilage breaks out again, in the form of a large shield, which is hollow below, sinuously convex above, notched in front, and at the middle as wide as the skull with its flying buttresses. No one familiar with the skull of Tadpoles can for a moment hesitate to call this the common "trabecular cornu." In the huge Tadpole's skull (*Pseudis*, my first stage, Phil. Trans., 1881, Part I., Plate 2), the cornua are united in their hinder half, but in an older Tadpole (Plate 11, figs. 1-3) they are only separated by a notch in front, sharper, but no larger, than the emargination on the fore-edge of this so-called "posterior dorsal cartilage" of the Lamprey.

The *side* walls of the chondrocranium of the Lamprey are well developed (Plate 18, figs. 1-5), but, as in Tadpoles, and adult Anura also, the optic and trigeminal nerves (II., V.), pass out of considerable *fenestræ*, and not out of mere foramina. The orbito-sphenoidal region (fig. 5, *o.s.*) is wider than the alisphenoidal (*al.s.*), but the latter mounts up into the roof, and the two sides meet round the middle, and fore part of hind, brain (Plate 18, figs. 3, 5, *t.cr.*) The occipital *ring* does not exist, and the hard part of the basi-occipital, as we have seen, is abortively developed.

In front of the posterior sphenoidal "tegmen" there is a large pyriform fontanelle, the broad fore part of which is largely covered by the hinder part of the *double*, mammilliform nasal capsule—(*na.*) an independent structure, as in the Tadpole, larval Urodele, and Elasmobranch; this is composed of soft cartilage.

The facial outgrowths of the Lamprey's skull are confusing, because of their extreme simplicity, and because of the absence in them of the normal segmentation from the basis cranii. Yet the Lamprey is not alone in this peculiar and generalised state of the cranio-facial cartilage; it occurs in so many other Ichthyopsida, especially in the more *archaic* types, that I am strongly induced to look upon it as the retention of an *ancient* condition of the skull of the *Craniata*.

Except in the basal (ventral) region, there is no segmentation, and there the parts are so unlike those of other Fishes that some of these *basi-visceral* cartilages are of doubtful morphology; the question being whether they belong to the *deep* or *superficial* category.

Of parts formed *inside* the "head-cavities" there are only representative *regions* of the 1st and 2nd post-oral arches, and it is evident that the 1st or *maxillo-mandibular* is abortively developed below, and the hyoid abortively developed above; the basal part of the latter, as well as its sides, are clear, but the mandibular region is very doubtfully represented at all.

The only tract that can be said to belong to the proper branchial region (of "intra-branchials") is the hind part of the great lingual cartilage, behind the setting on of the lateral "cornua" of the hyoid arch.

In coming to details, I shall have to refer freely to other work of mine, in other Ichthyopsida, and also to the views written, or expressed to me in discussion, by my esteemed fellow-workers; *from one of the chief of these I can get no more counsel or help.*\*

\* I have not felt myself able to stir a step without the help of Professor HUXLEY's admirable paper already referred to, on the nature of the "Cranio-facial Apparatus of *Petromyzon*" (Jour. of Anat. and Phys., vol. 10, plates 17, 18, pp. 412-429). I say this the more freely because I feel satisfied that the author of that paper will give me credit for having thrown some useful additional light upon the subject, thus necessitating a considerable divergence of opinion between us as to the meaning of some of the parts. The manner in which the late Professor BALFOUR always demanded incontrovertible proof of any view I might be holding at the time of discussion has served to make me work with extreme caution. With regard to one difficulty mentioned by Professor HUXLEY in the paper just referred to (p. 423), as to the distribution of the branches of the 5th nerve, I may mention that in two or three years after its publication



The subocular bar should be compared with that of a Tadpole during transformation, when the hinge of the mandible is below the emerging trigeminal nerve (see Phil. Trans., 1881, Plate 4, figs. 8, 9,) that is when the quadrate condyle has left the front of the head and has retreated to the postorbital region. In the adult Lamprey we have the pedicle (*pd.*) growing forwards as the pterygoid cartilage (*pg.*); these two regions form the hinder, and half the lower, boundary of the subocular fenestra (*s.o.f.*); the rest of the lower boundary is the postpalatine region (*pt.pa.*), and the front boundary the ethmo-palatine (*e.pa.*), from which grows the prepalatine spur (*pr.pa.*).

But there is no quadrate condyle, that is completely suppressed; in the Myxinoids (Plate 9, fig. 2; and Plate 16, fig. 1, *q.*) there is a rudimentary quadrate tract, but without any condyle; in these it is still further back than it would be, if developed, in the Lamprey. The slight elbowing of the subocular bar under the hind margin of the fenestra is the only sign of it in this Fish (Plate 18, fig. 1). That which, for some time, kept me from seeing this matter fairly was a comparison of the Lamprey's skull with that of a Tadpole before transformation; I then mistook the prepalatine spike for a rudimentary quadrate tract. Now if these parts in the Lamprey and the Myxinoids be compared with those of the transforming Tadpoles of the species of *Rana* (*op. cit.*, Plate 4), we shall see that it is the subservience of the free mandible (Meckelian rods) in the Tadpole to the suctional function—they are mere carriers or supporters of the incomplete “annulus”—that makes the necessity for the forward position of the condyle of the quadrate. Indeed, nothing in morphology is more marvellous than the behaviour of those condyles, which, lying at first in the front of the head, gradually swing themselves round, and, in the Bull-frogs, come to project some distance behind it (*op. cit.*, Plate 8).

Here, in the Lamprey, the perfect *annulus*, or suctional disk, is functionally free from cranio-facial trammels, and, being so huge, causes the once short, backwardly-placed *lower lip* to project in front of all the other structure; in the Tadpole (see in the huge *Pseudis*, *op. cit.*, Plate 1) it is almost as forward as in the Lamprey; but in the other kinds it is more under the face.

The forward position of the large quadrate condyles in the Tadpoles of the “Anura Phaneroglossa” masks the prepalatines for a time, turning them *inwards*, as a boundary to the internal nostrils. (See the various figures in my 3rd Memoir “On the Batrachian Skull.”)

In *Dactylethra* (“Batrachian Skull,” Part II., Plates 56, 57,) the condyle of the quadrate, although well in front of the head, is a small, sessile, selliform condyle on the edge of the enormous suspensorium, and the prepalatine is confluent with the cornu trabeculæ.

But in the larva of the other *Aglossal* Batrachian (*Pipa*, same memoir, Plates 60, (namely, Nov., 1880), he himself worked out this subject afresh, and found that there was no difficulty, as a true 2nd branch of the trigeminal does pass over the subocular arch. My later dissections confirm this important discovery.

61,) that spike (*pr.pa.*) is free, and thus, from the first, has the directly forward position of its counterpart in the Marsipobranchs. Moreover, in the young of *Lepidosteus* (Phil. Trans., 1882, Part II., Plates 30–38, *p.pg.*) we have a prepalatine quite like that of the Myxinoids, and in this case it is the *fore-end* of the subocular bar which is primarily continuous with the basis cranii, but *afterwards* free, whereas it is the *hind part* in the embryo of the Lamprey (Plate 25, fig. 7, *pd.*, *pg.*, *tr.*)\*

If we thus determinet† that the Lamprey has a subocular arch like that of a transforming Tadpole, *minus* the quadrate region and condyle, we have still the question as to whether the distal (*cornual*) part of the first arch has any existence.

In the first place, it is to me a great satisfaction to find Professor HUXLEY (*op. cit.*, p. 421) saying of the “annular cartilage” that—“although its halves are united dorsally” [it] “would seem to be essentially a post-oral structure;” it certainly is, if it be homologous with the *divided* imperfect “annulus” of the Tadpole.

Now, there is a T-shaped median cartilage, whose transverse part lies directly behind the great labial ring (Plate 10, fig. 6; and Plate 18, figs. 1, 2). After determining (to *my* heart’s content) the nature of the “styliform,” “cornual,” and lingual cartilages, as the hyoid arch, lateral and basal, Professor HUXLEY asks—“What is the *median ventral cartilage* which MÜLLER regarded as the body of the hyoid? The hyoidean arch is complete without it, and has no special connexion with it, the bent up anterior end of the lingual cartilage simply playing over it. I conceive it to be a median ventral element of the mandibular arch, notwithstanding that, in the higher Vertebrates, such an element, though the analogy of the other arches would lead us to expect its presence, is not known to occur. The third division of the trigeminal nerve passes over the expanded anterior end of this cartilage, traverses the ventral half of the annular cartilage, and runs along the anterior edge of the latter to its dorsal extremity” (p. 421). But if we look again at these cartilages in the transforming young of the great Lamprey (Plate 10, fig. 6), we shall see that the paired styloid cartilages of the lower lip are attached by their broader inner ends to the annular cartilage and are curved at their free and outer ends, so as to resemble very closely the form and relations of the small mandibles of the Tadpole (see my 3rd Paper “On the Skull of the Batrachia,” Plates 2, 3, 4, 11, 15, 17, 22, 30, and 38).

Now, it occurred to me some time ago that these were the true Meckelian rods, but the late Professor BALFOUR assured me that I had no proof sufficient to sustain this view.

Then as to the median T-shaped cartilage; such a thing as a median mandibular element, well formed, but not segmented off from the Meckelian rods, does exist in “the higher Vertebrates.” I have already shown it in the Green Turtle and the

\* The pharyngo-hyal element or hyomandibular is developed continuously with the skull in *Lepidosteus*, thus throwing light on the second arch of the Myxinoids.

† The difficulty with regard to the relation of the branches of the trigeminal nerve to the subocular bar and fenestra has been dealt with in the First Part (pp. 401–403).

Crocodile (see "Challenger Reports," vol. i., part 5, plate 3, fig. 6, *mk.*; plate 9, fig. 5, *mk.*; plate 10, fig. 6, *mk.*; and plate 11, fig. 2, *mk.*; also Trans. Zool. Soc., 1882, plates 63, figs. 7, 8; 65, figs. 3, 8; 66, fig. 5).

Moreover, I have recently made a large number of preparations of the visceral arches of embryo Mammals—Edentata, Insectivora, Rodentia, &c.,—and in these I find a still more developed basal rudiment to the primary mandibular arch, namely, a large, well-formed terete rod, lying on the symphysis of the "rami," and well marked as a true "basi-mandibular."

Now, considering the morphological feats performed by these Marsipobranchs, notably the two *distinct* "intertrabeculæ" of the Myxinoids, and the marvellous development and sub-division of the basi-hyal, I think it is not a great extravagance on the part of Professor HUXLEY and myself to ask them to show one "sign" more, and give us *three distinct*, rudimentary, distal mandibular elements.

I shall simply call them median and lateral distal mandibular cartilages (*m.d.m.*, *l.d.m.*), and leave their *deep* or *superficial* nature an open question.

Like the annulus they have no existence in the Ammocœte, but this is true, also, of the fore half of the subocular arch, and of all the hyoid arch.

It is evident that the Petromyzine type of skull is a great and important modification (metamorphosis) of the Myxinoid, for the larval Lamprey represents *Myxine*, just as the larval frog represents the Lamprey.

But the enormous development of the lower lip in the Lamprey has affected the jaws, half aborting them, and the hyoid arch, also, in its upper part, and causing its basal part to undergo extreme hypertrophy. The hyoid arch presents fewer difficulties than the maxillo-mandibular, but there are some remarkable modifications of this region, which are, however, greatly elucidated by what we see in the "Anura." It has no "pharyngo-hyal" element; nor has the Tadpole, at first; its distal part, which becomes the "columella auris," does not appear in our Common Frog and Toad until *two* or *three* months after metamorphosis (see my 2nd Paper "On the Batrachian Skull," pp. 622–624)—a fact discovered by Professor HUXLEY. But the *position* of the "epi-hyal" region of the hyoid arch, and its continuity with the back of the pedicle and pterygoid, is only explicable by reference to transforming and transformed "Anura."

The large broad "epi-cerato hyal" of the Tadpole is articulated to a *special* facet by a *special* condyle below the ethmoid in the antorbital region, and it is only after the swinging back, so to speak, of the quadrate region that the *epi-hyal point* is carried under the exit of the facial (*its own*) nerve (see in *Pseudis*, "Batrachian Skull," Part III., Plates 11, 12); this position is a good landmark, and shows that the quadrate of the Lamprey *should have been* post-orbital.

The epi-cerato hyal (Plate 18, fig. 5, *hy.*, *c.hy.*; and Plate 19, figs. 1–3, *e.hy.*) grows out from the back of the pedicle and pterygoid (*pd.*, *pg.*) at a right angle; a projection, the beginning of this part, is seen in the *Ammocœte* (Plate 19, figs. 4, 5, *pd.*). In the adult stage, in some Tree Frogs (*Acris Pickeringii* and *Phyllomedusa bicolor*)

(see my 3rd Paper, Plate 30, fig. 2; and Plate 34, fig. 8), the epi-hyal end of the long hyoid "tape" when it has got under the emerging 7th nerve, does not, as usual, unite with the skull, but with the back of the pedicle, behind the part where the pterygoid is given off in front.

Here, as a *secondary* development, we get exactly what we have from the first in the Lamprey; and I could give numerous instances of cases of this kind; homologous parts being *continuous* with some neighbouring cartilage in one type, and becoming *confluent* in another.

The rather thick styliform (epi-cerato hyal) bar of the Lamprey curves gently upwards, as it passes downwards and backwards; it ends below in the *cornual part* or cerato-hyal (Plate 18, figs. 1 2, 5, 6, 7, *c.hy.*). This part is not segmented from the epi-hyal region; but it is quite distinct from the basal bar (*b.hy.*).

The latter bar is strongly clamped by these two horizontal growths, each of which is roughly hatchet-shaped, the blade being turned outwards from the hind part, and the handle growing forwards as a strong styloid process. The thickish blades are convex below, concave above, and a notch is seen between them and their handles; the epi-hyal grows into the top of the outer angle of the blade, which latter part is obliquely perforated in front of its middle.

The facial nerve (Plate 18, figs. 1, 5, VII.) emerges behind the pedicle (*pd.*), and then passes to the inside of the forking cartilage.

The median hyoid bar passes from the circular opening of the mouth to a point half-way between the 1st and 2nd branchial clefts (fig. 1, *b.hy.*); when dissected out it presents the appearance shown in figs. 6-8,—lower, upper, and side views. This rod is not straight, but bent sinuously from side to side, and is upturned both before and behind; it is oval in section, and has an irregular, half soft, keel in the hinder part, where it is clamped by the cerato-hyals. Narrowing into a neck towards the front part, it enlarges at the end into a head, the hind part of which is soft cartilage, and the fore part hard. That hard part is in three pieces, separated by soft synchondrosial tracts. The side pieces form a short trough, and are uncinat blades, united by the convexo-concave lower piece. These parts, which look like the mandibles of a Beetle, have a pair of supra-lingual cartilages over them (Plate 14, fig. 10); and also between the cerato-hyals there is a curious framework to the "lower velum" (Plate 18, fig. 7 *i.v.s.*); these parts I shall describe soon.

### 3. On the extra-branchial basket-work.

In the Myxinoids the only trace of *extra-visceral* cartilage found was in the "ductus œsophago-cutaneus" of *Bdellostoma* (Plate 16, fig. 7); *Petromyzon*, on the contrary, is remarkable in having the largest and most perfect framework of this kind known.

In Tadpoles, behind the three branchial openings, and in front of the first, there

are "extra-branchials;" the first and last are pouches, like the bowl of a spoon, the second and third are broad bands. But these have inside them, and growing from large hypo-branchials, four pairs of short and slender cerato-branchials, *inside* the arched branches of the main branchial artery ("Batrachia," Part III., *var. loc.*). Also in Sharks (not in Skates), outside the rays of each branchial septum there is a long band of cartilage, pointed above and pedate below; there are four pairs of these, which are of the same nature as the pouches of the Tadpole and the basket-work of the Lamprey (see Trans. Zool. Soc., vol. x., plate 38, figs. 1, 2, *e.vs.*). In the Shark the typically-jointed intra-branchial arches, with their "rays," dominate; in the Tadpole the extra-branchials; in the Lamprey these latter, alone, exist. The huge development of the seven pairs of branchial pouches in the Lamprey, with their openings—2nd to 8th *clefts*—carries the fore part of the first pouch away, backwards, from the hind margin of the hyoid; but this is a very slight displacement compared to what we saw (Part I.) in the Myxinoids.

Each main extra-branchial bar is seen to be *behind* the corresponding cleft or aperture (figs. 1, 2, *e.b.a.*<sup>1-7</sup>, *ex.br.*<sup>1-7</sup>); but in the adult, there is an additional bar, in front, belonging to the hyoid region, and another behind, enclosing the heart and its bag (*ex.hy.*, *pcd.c.*)\* These *nine* pairs of main bars are all united below (fig. 2) into one complex cartilaginous "crate." The cartilage is of the soft kind. Above, on each side, the seven main bars run into each other, being united by a continuous growth, attached by fibrous tissue to the sheath of the notochord. Opposite the apertures each bar bends inwards, and, above and below, the inbent part gives off a crooked bar, both over and under the apertures. These cross bars join the next in front at a considerable distance from the aperture, each being strongly elbowed, and each giving off a snag, the one upwards and the other downwards. But the *cervicorn* character of these united bars is increased still further by the development of two snags in front and one behind, on each main bar, both above and below the cross bars. Then, both above and below, a common headland of cartilage unites the whole together. Nor is this all, for the lower marginal band (Plate 18, fig. 2), uniting the main bars below, bends towards the corresponding part of the other side, and coalesces with it at its convexity. This being done, again and again, there is left a row of small oval fenestræ between the junctions—*six* in all. But the hyoid part of the basket-work, the "extra-hyal" (*ex.hy.*) did not exist till after the metamorphosis (see Plate 25, fig. 8, basket work of *Ammocæte*) and the cross bars of the 1st extra-branchial (*ex.br.*<sup>1</sup>) form a loop independently of the extra-hyal. This loop, however, sends down, now, an elbowed band, which runs into the extra-hyal below its middle. The extra-hyal helps to form the grooved and perforated *quasi-sternum* on the lower face of this great respiratory pharynx (fig. 2, *ex.hy.*) and above its junction with the 1st extra-branchial (*ex.br.*<sup>1</sup>) runs upwards and forwards, and is united with its own arch (epi-cerato hyal, *e.hy.*, *c.hy.*) over its junction

\* The Tadpole has no gill belonging to either the first or the second arch; therefore its three gill-slits answer to the 2nd, 3rd, and 4th gill openings of the Lamprey, whose 1st gill opening is the 2nd cleft.

with the pterygo-palatine (fig. 1). Just at its shoulder, below the emerging facial nerve (VII.), the extra-hyal sends upwards a free snag. The last extra-branchial (*ex.br.*<sup>7</sup>) sends off no cervicorn processes, except from the transverse bars. It is shorter also than the rest. Behind, it joins the *extra-pericardial* (*pcd.c.*) by *three* bands, the lower being the broader (fig. 2), and each of the *two* fenestræ thus formed is made into a U-shaped space by a snag from the extra-pericardial, which also sends forwards, above them, a larger free dentate snag; the rest of the pouch is thin, roundly notched, and ends above in another similar process. Below (fig. 2), instead of a small oval fenestra, the 7th extra-branchials help the double extra-pericardial to form a large fenestra, which becomes elegantly trilobate through the growth of a right and left snag from behind. From that fenestra, up to the pair of upper processes, right and left, the two extra-pericardials are completely united together, and form a *bowl*, whose cavity is pitched forwards and a little upwards. I trust that the reader, with this description of the figures here given, will see what the writer sees, and that, seeing, he will agree with him that nothing more remarkable, and nothing more exquisite, has been revealed by the labour of Anatomists.

#### 4. *Subsidiary cartilages in the mouth and between the mouth and pharynx.*

##### a. *The supra-lingual cartilages.*

Over and between the curious *quasi-mandibles* that grow upwards from the head of the basi-hyal (Plate 18, figs. 6–8, *b.hy.*) there is a thick pyriform cushion, right and left, with its base looking backwards. Between these two cushions, in the margin of an elliptical *supra-lingual* valley, there is a pair of rows of small, yellow, pointed, lanceolate teeth, looking inwards and backwards, a dozen or more in each row (Plate 14, fig. 9). There is a groove along the mid-line, between them, and behind this the dorsum of the tongue has crescentic cross ridges. Across the arched, broad end of the tongue there is a row of *cyclodont*, beaded, horny teeth, fifteen in all, lessening outwards, and with the middle tooth much the larger. These show themselves inside the *annulus*, on the floor of the small oral opening (Plate 8, figs. 10, 11), and are a very important part of this suctorial apparatus. But these terminal teeth of the tongue, and the radiating teeth of the annular disk, have no counterparts in the Myxinoids (Plate 8, figs. 7–9). The two small rows of sharp, supra-lingual teeth have, however, very notable counterparts, in the double rows of large teeth, in that lower group (see Plate 12, fig. 7; and Plate 16, fig. 4). The large complex supra-lingual cartilage of the Myxinoids is represented in the Lamprey by a small cartilaginous plate (Plate 14, fig. 10, *s.l.c.*), which is exposed by section in the cushion above the ascending lobes of the great basi-hyal (*b.hy.*).

*b. The skeleton of the fimbriated valve between the mouth and pharynx.*

This peculiar structure, formed during metamorphosis, is figured, as seen in a vertical section of the adult *P. fluviatilis* (Plate 23, fig. 1); from above, *in situ*, in a head cut through horizontally (Plate 23, fig. 2); and as removed from most of its surroundings and seen from above (Plate 14, fig. 8).

The skeleton of this valve is shown in the upper view of the basi-hyal (Plate 18, fig. 7, and in Plate 10, fig. 7), and sections of it will be described anon. This part is a fringed median projection, uniting the right and left *vela* (*vl.*), parts that are found in the newly-hatched embryo, dividing the "stomodæum" from the "archenteron" (BALFOUR, 'Comp. Emb.' vol. ii., p. 74, fig. 42, *v.*). I have given a diagrammatic figure of the velum in the *Ammocæte* (Plate 25, fig. 10, *vl.*). For a description of these parts the reader is referred to Professor HUXLEY's paper ("Cranio-facial Apparatus of *Petromyzon*," p. 420). This curious little frame is composed mainly of two *crura* of hard cartilage, united in front by a band of soft cartilage, which sends out three pairs of filaments, and an odd one in the mid-line. These are all sinuous or *f*-shaped; the two outer threads pass across and are attached to the cerato-hyals (*c.hy.*), in front of their junction with the epi-hyals (*e.hy.*); these latter are seen as cut across in the figure.

The inner of the paired threads is the longest, right and left; the others are nearly of the same length.

The hard *crura* are bent out, like *knees*, and these are pedate behind, with a *heel* of soft cartilage.

*5. The labial cartilages.*

The upper lip, which was a *hood* in the embryo and larva (Plate 8, figs. 1-6), overlapping and far outreaching the short, transverse lower lip, has grown very much, but not in the same degree as the lower lip (Plate 8, figs. 10-16; Plate 18, figs. 1, 2, 3; and Plate 23, fig. 1).

The upper lip has acquired a skeleton, such as we find in all the Tadpoles of the "Phaneroglossal Anura." There are five *upper labials* in this type, and the median is a shield-shaped piece, hollow below, convex above, and overlapped by the cornu trabeculæ (*u.l.*, *c.tr.*); these two parts are the so-called "anterior" and "posterior dorsal cartilages." Under the lower edge of the great median upper labial, right and left, there is a small, bent, bluntish style, the "antero-lateral upper labial" (*u.l.*). Behind the large piece, right and left, there is a reniform plate of cartilage, much larger than the styloid piece, which, lying obliquely, helps to fill up the space between the two dorsal cartilages and the prepalatine; this is the "postero-lateral upper labial" (*u.l.*).

In the larva of the "Anura" (see Phil. Trans., 1881, Part I., *var. loc.*) these cartilages never *quite* agree with those of the Lamprey, although they are manifestly homologous. There may be *one*, *two*, or *four*, and they are evanescent in those types,

becoming absorbed during metamorphosis, whilst *two new pairs* appear, homologous with the "adrostral cartilages" and "nasal valves" of the *Elasmobranchs*.

I have already described the cartilages that are attached to the *great ring*, doubting whether they belong to the *superficial* or the *deep* category.

There remains, now, the great *annular* cartilage to be described (Plate 18, figs. 1-2, *l.l.*<sup>1</sup>), and the lesser pieces in the disk (*l.l.*<sup>2-4</sup>). There can be no difficulty in identifying this huge, single, complete ring with the lesser, double, incomplete ring of the Tadpole, nor in determining that they are both distal superficial cartilages of the post-oral or mandibular region. I have traced the development and decadence of this suctorial structure through all its stages, *up* and *down*, in the Anura ("Skull of Batrachia," Parts I.-III.), but in this type I find no traces of it in the largest *Ammocete* of *P. planeri* and *P. fluviatilis*. But in a very minute young of *P. marinus*, 4 inches long, (Plate 10, fig. 6, *l.l.*<sup>1</sup>)\* with the cranial elements still distinct, the chondrification is equally perfect all round, and the thickness of the ring equal. At that stage, if it had been composed of two pieces, even for *a day or two*, some signs of division would have been apparent. The actual form in the larger young (one-third grown) of the same species (Plate 18, figs. 1, 2, *l.l.*<sup>1</sup>) is a semi-ellipse, with rounded corners at the truncated part; the narrow end is in front.

It has a thick lower edge (fig. 2) and thence is scooped upwards; the fore part (fig. 1) is much higher than the hinder; the narrow end projects much less in front of the large upper labial than it does beyond the cornu trabeculæ (Plate 18, figs. 1, 3, *l.l.*<sup>1</sup>, *u.l.*<sup>1</sup>, *c.tr.*). In the side view (Plate 18, fig. 1) the larger teeth, round the opening of the circular mouth, are shown *in situ*; in the dissected skull in the under view (fig. 2), the head of the tongue (lingual or basi-hyal cartilage) is seen with its teeth in the hinder part of the opening. Also in the undissected head, when seen from below (Plate 8, fig. 10), the same part is seen as a squarish mass, largely occluding the aperture; the teeth of the disk are strong and crowded behind the aperture.

In the thick edge of the disk, right and left, there are three small, hard cartilages of an irregularly oval shape (Plate 18, fig. 1, *l.l.*<sup>2-4</sup>).

#### 6. *The sense-capsules.*

The eye-balls, which are very small and obscure in the *Ammocete* (Plate 8, figs. 4, 5) are large in the adult (figs. 11-13); in the middle species (*P. fluviatilis*) the relative size of this organ will be shown in the sections. Unlike the eye-ball of Fishes, generally, the *sclerotic*, even in *P. fluviatilis* where the eye-ball is relatively largest, is not cartilaginous but fibrous, merely, as in the Mammalia.

The auditory capsules (Plate 18, figs. 1, 3, 4, *au.*) are very similar to those of the Myxinoids (Plates 9, 10, 16, and 17), being strong, hard, oval capsules, retaining the simple form found in the newly-hatched embryo of the Anura. For in these types the

\* In that figure the distal mandibulars are lettered *l.l.*<sup>2</sup>, *l.l.*<sup>3</sup>.



anterior and posterior semicircular canals are short, wide tubes, and the horizontal canal is arrested. The meatus auditorus internus (Plate 18, fig. 5, VIII.) is scarcely larger than the optic fenestra (II.), so that, for a Fish, the capsule is very perfect inside; the space for the entrance of the auditory nerve is much more vertical than in the Myxinoids (Plates 10 and 17). The long axis of these elliptical boxes is accurately parallel with the axis of the skull; above, they stand out well from the skull, but below we see a bridge of cartilage, derived from the parachordal (*iv.*), thrown across the interspace between the capsule and the cranial floor. This scooped thin edge of the parachordal, which has become confluent with the capsule, is very distinct, for a time, in Tadpoles ("Batrachian Skull," Part III., *var. loc.*); it is continuous with the pedicle (*pd.*) in front, and in the Myxinoids (Plates 9, 10, 16, and 17) with the uppermost part of the hyoid arch.

That the *nasal capsule* (Plate 18, figs. 1, 3, 5, *na.*) is essentially double, like the trabecular cornu (*c.tr.*) is evident; it is a very exact likeness of the dilated crop of a Pigeon; its halves are a little less than the auditory capsules; they are composed of *soft* cartilage. Behind the aperture (*e.n.*) there is an emargination, followed by a widish, shallow groove; behind, the median cartilage is somewhat produced as a lobe. The cartilage runs three-fourths of the way round (Plate 21, figs. 3-5) up to the posterior nasal canal, and only forms a perfect floor behind; the aperture (*e.n.*) is membranous. These things will be best explained by the transverse sections (Plate 21). The roof is pierced by vessels, near the middle, at its hinder third (Plate 18, fig. 3, *na.*); in that figure the olfactory nerves (I.) must be supposed to be seen *through* the fontanelle (*fo.*).

*Cranio-facial skeleton of newly-metamorphosed young of Petromyzon marinus.*  
(5 inches long).

These were about half the length of the specimen whose skeleton has just been described; and, in development, an intermediate one between that stage and the one next to be described.

Compared with the larger specimens, we see that the cranial notochord is longer, being half as long as the cranium proper, so that the *para-* and *pro-*chordal regions are equal in length. The notochord (Plate 19, figs. 1-3, *nc.*) projects somewhat into the oval pituitary space (*b.c.f.*), which is twice as large as in the larger specimens. The inner edge of the parachordals is soft both above and below; the two are united for a short space below. The outer edges, confluent with the auditory capsules (*au.*) are of less extent, there being a considerable notch fore and aft under the outgoing trigeminal, facial, and vagus nerves (V., VII., X.). The hard cartilage is continued back, as far as the hinder outline of the auditory capsules, and is then replaced by narrowed bands of the soft kind, further than in the last stage. Behind, the *pro-*chordals (*tr.*) are narrower than the *para-*chordals (*iv.*), but they broaden out forwards; their larval form is traceable in the upper view (compare Plate 19, figs.

1 and 5, *tr.*), for the basi-cranial fontanelle (*b.c.f.*) is bounded by a thick cartilage, which thins out in the orbito-sphenoidal and ethmoidal regions (*eth.*, *o.s.*)—*post-transformation* structures. The floor in front of the basi-cranial fontanelle is due to the hind intertrabecula (*p.i.tr.*). A large round notch separates the ethmoidal and orbito-sphenoidal regions; the ethmoidal plate in front of this notch and of the thick-ribbed primary trabeculæ, is a two-winged structure, pointed in the middle, gently concave right and left, convex above, and concave below. It thickens beneath at its fore margin. There is a curious rudiment of the wall and roof, right and left; the base of the orbito-sphenoidal wall (*o.s.*) is only half the breadth of the *optic fenestra* (fig. 3, II.). The top of the wall is spiked in front, and then notched and sinuous; it bends inwards over the optic fenestra, and is thick above. The appearance, from above (Plate 19, fig. 1) of these partial walls, is like that of the pterygo-palatines (*pg.*, *pa.*) outside, but much smaller. The optic fenestra is kidney-shaped, the *hilus* being above, and the nerve (II.) passes out at the hinder third. The base of the alisphenoidal band (fig. 3, *al.s.*) is only half as large as the orbito-sphenoidal (*o.s.*), and a large uncinatè foramen for the 5th and 7th nerve (V., VII.) intervenes between that band and the auditory capsule. Then the cartilage mounts over the skull cavity beyond the middle of the auditory capsules, forming a leafy blade, that grows, by its fore corner, towards its fellow of the other side, but does not meet it by a considerable space. The hind corner lies on the capsule, furthest from the mid-line, and a fenestra is seen between the *foramen ovale* (fig. 3, V.), the ear capsule, and the hind margin of the rudimentary “tegmen” (*t.cr.*).

The front outgrowth of the cranium—the great leafy hollow cornu trabeculæ (*c.tr.*)—is more than two-thirds the size of the rest of the cranio-facial structure; it is emarginate at both ends, and at its hinder part it is joined on to the ethmoid (*eth.*) by a very definite tract of soft cartilage; at that part it is slightly grooved, above.

At the junction of the *pro-* and *para-chordals* (*tr.*, *iv.*), and also at the outer margin of the ethmoid, a stout band of cartilage passes out; these are united outside, as a sort of “flying buttress,” which sends forwards a free snag, and downwards, at a somewhat greater distance from the skull, a band of cartilage, equal to the size of the root; this is drawn as cut across at a little distance from its origin. The hind root is the pedicle (*pd.*); the front root the ethmo-palatine (*e pa.*); the spur is the pre-palatine (*pr.pa.*); the bar cut across is the epi-hyal (*e.hy.*), with no distinct inter-hyal tract; and the main outer wing is the post-palatine (*pt.pa.*), passing into the pterygoid (*pg.*). There is the merest convexity at the junction of the two last-mentioned regions, where the *quadrate region* and *condyle* should be.

I have not figured the nasal capsule in this stage; the auditory (*au.*) is large, sub-reniform, and has a large pyriform *meatus internus* (fig. 3, VIII.), with the fundus below.

*Cranio-facial skeleton of nearly metamorphosed young of Petromyzon marinus.*  
(4 inches long.)

This stage is still more instructive than the last, as the metamorphic state was not over,—the *Petromyzine* skull was still in formation, and was caught in what may be called a *Myxinoid stage* (Plate 10, figs. 4, 5). Yet the suctorial (labial) cartilages were perfect (fig. 6); these have already been described, and the skeleton of the *intervelar shelf* (fig. 7), which was almost as much developed as that of the larger individuals of the same species (see Plate 18, fig. 7).

If the reader will compare this minute chondrocranium with that of *Myxine* (Plate 10, figs. 1–3), with the *larva* (Plate 19, figs. 4, 5), and with that of the transforming Tadpole of the East Indian Bull Frog (Phil. Trans., 1881, Part I, Plate 4, figs. 8, 9), he will not fail to see its true morphological signification—both *those* skulls are twice the size of *this*, yet this belongs to the largest species of Lamprey.\*

Another skull which comes near to, and throws light upon this, is that of the transforming Tadpole of *Pseudis* ("Batrachian Skull," Part III., Plates 11, 12). Here the primary basal bands—*para*- and *pro*-chordal (Plate 10, figs. 4, 5, *iv.*, *tr.*), have their *larval* outline (see Plate 19, figs. 4, 5) perfectly distinguishable throughout. The chondrification creeps backwards, as in the early Tadpole's skull, for here the hard cartilage is seen to end some distance in front of the hind margin of the ear-capsules (*au.*); the soft cartilage runs back along the spinal notochord for some distance. The sub-auditory wings of the parachordals are less than in the last stage and are very thin; the space under the gasserian ganglion between the pedicle (*pd.*) and the capsule (*au.*) is much larger and more open than in the larger young (Plate 19, figs. 1–3). The basi-cranial fontanelle (*b.c.f.*) is now pointed in front—*sagittate*; and narrower than it will be in a few weeks.

The trabeculæ (*tr.*) in front of the pedicle (*pd.*) become half the size of the parachordals, and then widen out, both in thickness and distance, to form the *Ammocæ-tine loop*. The depth of the floor is made by the thickness of the trabeculæ and its own concavity; and the bands are oval in section, the long axis of the oval looking upwards and inwards (see Plate 26, figs. 7–9, *tr.*). The interspace of the *loop* is accurately fitted with a cartilage, like the bowl of a spoon, but with two points, behind, instead of a handle; this bifurcation gives the lanceolate form to the basi-cranial fontanelle (*b.c.f.*).

This thin shell-like median element is the "posterior intertrabecula" (*p.i.tr.*); although only transitorily distinct, and composed of hard cartilage, it is the true counterpart of the very distinct ladle-shaped, soft cartilage, seen in the adult Myxinoids (same Plate, figs. 2, 3, *p.i.tr.*). This element is more distinct, as a rule, in the

\* I shall describe the larval skull last (Plate 19, figs. 4 and 5); yet that simple platform of a chondrocranium must be kept in sight, if the more advanced condition is to be understood. I have thought it better to take the metamorphosed skull first, as Anatomists are most familiar with it.

"Amniota" than in the "Anamniota;" especially, as I have noticed, in the Turtle and Crocodile; its outline, as distinct from that of the paired trabeculæ, can be traced in embryo Mammals, especially *Marsupials*. Here, its presence, *even for a few days*, as a distinct element, is very instructive, showing that, in some respects, the Petromyzoids lie between the Myxinoids and the Anura. *In some respects*;—but the larval Anura (see "Batrachian Skull," Part III., Plate 30, figs. 10, 11, *p.e.*) show very clearly the independence of the "anterior intertrabecula," which has no existence in *Petromyzon*, but is so remarkable in the Myxinoids (same Plate, figs. 2, 3, *a.i.tr.*). In those forms it supports the *prenasal proboscis*; in the larval Anura, with symmetrical nasal capsules, it forms the wall of partition between them, whilst the short narial passages acquire, each, a crescentic valvular cartilage, representative of the series of imperfect rings in the Myxinoids.\*

In spite of the difference of form and of the character of its tissue (*hard* instead of *soft* cartilage), and of its very temporary separateness, no one can fail to see its morphological identity with that of the Myxinoids (Plate 10, figs. 2, 3, and figs. 4, 5, *p.i.tr.*).†

This small, scarcely transformed skull of the Lamprey shows exactly what has been built upon the *Ammocetine* foundations (see Plate 19, figs. 4, 5; and Plate 10, figs. 4, 5). Outside the newly floored fore part of the skull, a flange or wing of cartilage has been added, which widens from behind forwards, until it shoots out right and left, as the ethmo-palatine (*e.pa.*) This flange runs round the looped trabeculæ in front, and thus the ethmo-palatines have an elegant, narrow, arched commissure running concentrically round the front of the early trabecular commissure.

This peculiar structure explains what was to me very anomalous in the transforming skull of the huge Tadpole of *Pseudis* ("Batrachian Skull," Part III., Plates 11, 12) where these bands are seen to pass into each other, under the ethmoidal region of the skull, and to have a distinct margin, marking the commissure off from the basis cranii, behind the transverse band. Here, however, there has been *coalescence of the basi-cranial flange with the ethmo-palatines*, for in the *Ammocete* (Plate 12, figs. 4, 5), the subocular band of cartilage is only developed in its hinder third; in the Tadpole these parts are primarily continuous.

The *secondary* character of the cornu trabeculæ (*c.tr.*), is shown in this little skull,

\* In retaining the old *human-anatomy* names, for descriptive purposes, in special districts or regions, the morphologist is saddled with a double nomenclature. For as our conception of the development of the parts becomes more and more clear, there must of necessity arise a number of *general terms*, each of which may include several special descriptive terms. Thus, the general morphological term "intertrabecula," which I have added to RATHKE's term "trabeculæ," includes the perpendicular ethmoid, and the septum nasi; the prenasal rostrum; and the median part of the anterior and posterior sphenoidal regions.

† It is due to the late Professor F. M. BALFOUR to state that the determination of the cranial nature of this peculiar median cartilage of the Myxinoid skull is due to him, and that this was seen independently of the peculiarly conclusive instance of it in the young Lamprey. It seemed to me, for a while, to be a *median palatine* cartilage, forming a floor to the "posterior nasal canal," and putting this view forward to him, as a suggestion, his immediate answer was, "No; it is your intertrabecula."

and also its essentially double nature. It is, now, separated from the ethmoidal flange by a narrow tract of soft cartilage, which, however, expands at the median line, thus giving *two roots*, as it were, to this large leafy tract. The fore edge is ragged, and there are points of cartilage, where broad lobes will be in a week or two (see also Plate 19, figs. 1, 2, *c.tr.*). At this stage the "flying buttress" is much more like that of the late Tadpole of the Bull Frog (*op. cit.*, Plate 4, figs. 8, 9), than in the next stage (Plate 19, figs. 1, 2), for the whole framework is more outspread, and the prepalatine (*pr.pa.*) points forwards, leafy and flat.

The subocular fenestra (*s.o.f.*) is made reniform by the basi-cranial flange; its more arched outer boundary is made by the postpalatine (*pt.pa.*) passing into the pterygoid (*pg.*), which runs upwards into the pedicle (*pd.*), and downwards into the epi-hyal (*e.hy.*), without a trace of the quadrate lobe and condyle, and without a sign of segmentation. If we compare these stages of the skull of *P. marinus*, one-third grown (Plate 18); 5 inches long (Plate 19, figs. 1-3); 4 inches long (Plate 10, figs. 4, 5), we shall see that the auditory capsules are relatively larger the younger the specimen. Also that they are short-oval in the youngest, then reniform, and then short-oval again. At first the semicircular canals make no difference in the outer form; then the two wide tubes bulge the capsule out; and this is lost, afterwards, by the thickening of the walls of the capsule. The meatus internus (Plate 18, fig. 5, VIII.), is pyriform and smallish in the largest of the three, then relatively large in the next (Plate 19, fig. 3), and in the smallest (Plate 10, fig. 4), it is a large, gaping space. In making these comparisons we have to keep the particular *species* in view, for in *P. fluviatilis*, the capsules of the *Ammocæte* (Plate 19, figs. 4, 5) are already reniform.

My work has been done according to what was possible with the materials at hand, first one species and then another; the reader must make the proper *specific equation*.

*Solid sections of the head and branchial region of the adult Petromyzon fluviatilis.*

#### A.—Vertical sections.

The various sectional views have purposely been made bald and diagrammatic, for the skeletal parts are very complex, and their relations to the surrounding parts very manifold and confusing; an exhaustive memoir on the anatomy of this type would have to be tenfold the bulk of this selected piece of work.

In the large vertical section (Plate 23, fig. 1) the segmental muscles and their deciduous septa are seen to have mounted up and overlapped the cranium as far as the external nasal opening (*e.n.*); below, the ventral muscular bands are merely indicated in the figure. The myelon and cerebrum (*my.*,\* C<sup>1-3</sup>.) are seen enclosed in their fibrous sheath (*theca vertebralis* and *dura mater*), and below them is the

\* The line from *my.* is too low in this figure.

large notochord (*nc.*) enclosed in its thick fibrous sheath; it is cut through along its axial fissure (Plate 23, figs. 4-7, *nc.*), and its apex reaches to the part where the posterior nasal canal (*p.n.c.*) emerges from the skull cavity.

Below the notochord the special, narrow, long *food-pharynx* (*phx.*), is laid open; near the head this passage bends downwards *under* the nasal canal, and *over* the frimbriated shelf (see fig. 2, *i.v.s.*) the "intervelar shelf," or fringed floor. Then, enclosed in connective tissue, we see the special branchial diverticulum of the pharynx, the *branchial bronchus*, perforated by seven erect, oval, valvular apertures or clefts, each of which opens into a branchial pouch (see fig. 2, *i.b.a'*). Below this large perforated tube, a *cul de sac*, another similar but smaller perforated tube, is seen; this is the great branchial artery (or *aorta*) (*br.a.*), giving off its secondary branchial arteries to the pouches. Below these parts we see muscles and inter-muscular septa, the structure of which does not concern us now. In front of the structure just described, where the mucous membrane is lined with cells derived from the *hypoblast*, we see the large oral or buccal involution, the epithelium of which is epiblastic. This is divided into two regions, the *labial*, or region of the *disk*, and the proper mouth cavity (*m.*), expanding into a *buccal* space right and left of the vela and intervelar valve. The first space is a low, highly ornate dome, pierced above to form the proper oral opening (see Plate 8, fig. 11), which is reduced to an arched fissure by the broad dentate end of the tongue. The oral cavity is very extensive, but it is partly taken up in front by a peculiar shelf, containing the great upper labial (*u.l.*), and, behind, its height is lessened by the pouched end of the posterior nasal canal (*p.n.c.*). That canal is seen to emerge from the cranial cavity in front of the notochord, and then to end between the notochord and the depressed part of the food-pharynx (*phx.*); it has a right and left diverticulum near its end. Narrowing in its intercranial tract, we see it widen again, under and in front of the nasal sac (*na.*), where it opens with the nasal opening (*e.n.*); its general form, in outline, is bracket-shaped.

The skeletal parts displayed in this section are as follows:—

The tegmen cranii (*t.cr.*) over the junction of the mid and hind brain ( $C^2$ ,  $C^3$ ); the nasal roof (*na.*) and a sigmoid tract under and in front of the skull; this is intertrabecula behind, ethmoid in the middle, and cornutrabeculæ (*c.tr.*) in front; the investing mass shows a little where it is cut through, over and under the apex of the notochord.

In the base of the mouth and throat the large basi-hyal (*b.hy.*) is halved, its soft and then its hard part, in front, is shown; it reaches behind to the second branchial opening. The thickest part of the annular cartilage (*l.l.*) is above, the narrowest is below, the thin arched cartilage above and behind the upper section is the great median upper labial (*u.l.*), forming the skeleton of the shelf under the cornu trabeculæ. Below the basi-hyal, the median distal mandibular (*m.d.m.*), is seen close inside the proper chin, behind the fissure between the chin and the great sucking disk. The small

points of cartilage cut through where the two systems of extra-branchials conjugate, below, were only figured in three places, in front (fig. 1, *ex.br.*).

Two *partial* vertical sections are figured, one (Plate 15, fig. 9) near the mid line, the other (fig. 8) more to the side. In the one nearest the middle (fig. 9) the fore part of the notochord is shown bent upwards, the cephalic part being enclosed in hard cartilage. The posterior nasal canal (*p.n.c.*) ends beneath its front spinal region; that pouch is seen to have a valvular fold inside it.

Under the pouched end of this canal, the buccal cavity is partly shown, with a small tract of the facial cartilage between it and the branchial canal; and another small point of cartilage is caught in this region, namely, part of the skeleton of the "intervelar shelf." The fore part of the branchial canal (*br.c.*) is exposed beneath the valvular end of the posterior nasal canal, and in it two oval internal branchial passages, and a *small valvular pouch* in front, at a lesser distance from the first opening than from the second. These are, in truth, the first three clefts, but the foremost, or hyomandibular opening (*cl.*), does not pass through the wall of the head, and has developed very little since it first appeared. Evidently, *it never quite closed up, or, if it did, it opened again* during metamorphosis. In the more lateral section (Plate 15, fig. 8) the investing mass shows more in the cranial end of the notochord (*nc., iv.*), and beyond it, in front of the posterior nasal canal (*p.n.c.*), the basis cranii is seen. Here we have the same openings—the first *closed*, and the two next *open* clefts, and in front of these the folds of the velum (*vl.*), and part of the frimbriated "intervelar shelf." Between the lateral and sub-lateral filaments of the shelf there is seen a deep pyriform recess, this is the *lateral buccal pouch* (to the right of *b.p.*), a diverticulum of the oral mucous membrane in front of the pharynx. It will be seen that the food-pharynx is not figured in these two sections, they were made beyond or outside the wall of this narrow tube (see Plate 23, figs. 1 and 4, *phx.*). The main crus of the one side of the *intervelar* skeleton is cut through (fig. 8, *vl.*).

#### B.—Horizontal sections.

These sections help us to understand this peculiar type of cranio-facial skeleton. In the higher of the two (Plate 23, fig. 3) we see the eye-balls (*e.*) cut through their middle, and also the auditory capsules (*au.*) in which the multilocular membranous labyrinth of each side is laid open. In front, the ethmoid (*eth.*) is cut across in its most solid part, and behind it, we see the outer nasal opening (*e.n.*) cut down close to the capsule (*ol.*), and in front of the ethmoid, part of the 2nd lateral labials are seen. Behind the nasal capsule we see the fore brain (*C.*) and the cranial side walls (*o.s.*), which are sinuous and out-turned at each end, with the orbital muscles and eye-ball (*e.*) attached. Part of the pedicle is seen confluent with the auditory capsule (*au.*); the latter is open on the inner side for the entrance of the auditory nerve. The

first pair of neural arches of the spine (*n.a.*<sup>1</sup>) are cut across, some of the notochord, and part of the first pair of branchial pouches.

In the next section, taken at a lower plane (Plate 16, fig. 2) the lower part of the eye-balls is shown, and the oral cavity is exposed with the intervelar fringed shelf (*i.v.s.*), the two-leaved "vela (*vl.*)," and the fore part of the branchial bronchus (*br.c.*) The first (arrested) cleft, and the first proper branchial opening are hidden under the folds of the "velum," but the 2nd and 3rd branchial apertures are shown clearly, and also the cavities of the three foremost pairs of pouches (*br.p.*) Both the ceratohyal (*c.hy.*) and the stem of the intervelar skeleton (*i.v.s.*) are cut across. In front, the annulus (*l.l.*<sup>1</sup>) is cut across, right and left, and also the labial distal mandibular cartilages (*l.d.m.*). Then close to the floor of the mouth the highest part of the basihyal (*b.hy.*) is caught; outside it, the lower edge of each 2nd lateral upper labial (*u.l.*<sup>3</sup>); and close under the eye-ball the pterygo-palatine bar (*pp.g.*). [In this figure for *i.b.a.*<sup>1</sup> read *i.b.a.*<sup>2</sup>, and for *br.p.*<sup>1</sup> read *br.p.*<sup>2</sup>.]

*Vertically-transverse sections of the head of the adult Petromyzon fluviatilis.*

In one rather small specimen nearly six scores of thin sections were made, stained with *eosin*, and mounted as transparent objects, in Canada balsam; of these rather more than one in four were drawn (Plates 20–22; and Plate 23, fig. 4). These reached from the sucking disk to the 2nd branchial pouch. Other sections were made by hand (solid) from the hind part of the branchial region of a very large specimen, which had been solidified in a solution of chromic acid (Plate 23, figs. 5–7). In these latter sections the muscular masses are more accurately shown than in the thin specimens that have been interpenetrated with *oils* and *resin*. These parts, however, are drawn in the figures merely to indicate the relation of the skeletal parts; it does not enter into my plan to describe them. As they appear in the figures they will be easily understood by the Anatomist. It is utterly impossible for any figures to give an adequate idea of the beauty of the transparent sections.\*

*1st Section* (Plate 20, fig. 1).—This section is through the fore part of the suctorial disk,† and this, and the next, are in front of the trabecular cornu. The median upper labial (*u.l.*<sup>1</sup>) is cut across in its narrower fore part, and beneath it the annular labial—the azygous element of the lower series (*l.l.*<sup>1</sup>)—is seen cut across right and left of the high arched space shown by section of the great disk. This is near the front part of the annular cartilage; it is highest and thinnest at this part, and is bent upon itself below the middle. Hence in the outer view (Plate 18, fig. 1, *l.l.*<sup>1</sup>) the upper part of the side seems to be bevelled. Below this, at a small distance, there is a somewhat lesser section of cartilage, which is not curved; this has suctorial teeth on its inside, and it lies opposite the

\* The *thin* sections were made by one of my sons, and the *camera-drawings* by another.

† To follow the meaning of the parts displayed by these sections it is necessary to keep the form of the head of the undissected Lamprey before the eye (Plate 8, figs. 11–13) and also the structure of the cranio-facial apparatus as displayed by the *dissections* and *solid sections* (Plates 18 and 23).



middle of the large labial muscular mass outside the cartilage (*s.d.*), the section of which is crescentic; the annular cartilage gives attachment to these fibres, above; its upper edge, only, is free. The lower cartilage is called by SCHNEIDER (see his plate 8, fig. 1, *Cd.*) "*Cartilago-dentalis*" ("*Knorpel für die seitlichen Zähne*"). I have not, elsewhere, seen this cartilage noticed, and my sections created for a time a difficulty: *dissection* of the suctorial disk, both of the young *P. marinus* and of the adult *P. fluviatilis*, gave the explanation. There is not merely *one lateral lower labial* on each side, but *three* (Plate 18, fig. 1, *l.l.<sup>2-4</sup>*); they are small, irregularly oval patches of hard cartilage, lying in a profusion of large-celled simple cartilage, quite like that seen in the larva of *Dactylethra* and intermediate between the "vacuolar tissue" of the notochord (and of the huge basi-branchial bar of the Myxinoids), and the ordinary soft cartilage of Marsipobranchs generally. This large-celled simple cartilage fills the cavities of the horny teeth, and is, indeed, the kind of pithy connective tissue which goes to fill the interspaces of the higher kinds of tissue in this large spongy disk.\*

*2nd Section* (Plate 20, fig. 2).—The first "*lateral upper labial*" (*u.l.<sup>1</sup>*) is now cut across under the median plate (*u.l.*); the annular cartilage (*l.l.<sup>1</sup>*) is now lower and more bent outwards, and the lateral lower labial (*l.l.<sup>3</sup>*) is smaller. The fore end of the tongue and its teeth (*tg.*, *l.t.*) is shown in the arched oral opening; here the *roof* of the oral opening is seen to be formed by the great upper labial, but the *disk* grew some distance in front of this part.

*3rd Section* (Plate 20, fig. 3).—In this section the remarkable imbrication of the cartilages is shown, and, looking at the side view (Plate 18, fig. 1), we see what parts have been cut across. The large overlapping trabecular cornu (*c.tr.*), the great size of which seems more remarkable in the sections than in the dissections, is thin here at its fore edge, well arched, and is much wider than the great azygous labial. That cartilage (*u.l.*) is very similar in its sections for some distance; it is too much arched to be quite concentric with the great cornu, and its edge is thickened or ribbed, and turned slightly inwards. Following the line of its incurvation below, we see the small front lateral style (*u.l.<sup>1</sup>*), sharp above and rounded below. Here, in the upper part of this large portico, under the median labial, we see again the front outline of the great broad-ended tongue (*tg.*), which widens upwards, and has a concave upper outline. On each side of the severed part of skin, at the base of the tongue's tip, the annular cartilage (*l.l.<sup>1</sup>*) is cut through as it thickens towards its hind part; its section is lobu-

\* Whilst describing these sections of the disk, it may be well to say that it is formed by a great hypertrophy of the *lower lip*, which grows forwards, closes over the narrowed oral opening, and unites above that opening with the upper lip (see Plate 8, figs. 11-13). Hence the cartilages behind the disk lie in the substance of the *chin* and *throat*, and evidently do not belong to the labial category. The cartilages now referred to are the "*distal mandibulars*," single and paired. The five cartilages under the cornu trabeculæ are formed in the upper lip, which is a large hood from the first (Plate 1, figs. 1-3). The upper and lower lips of the Lamprey are now seen to be much more (vertically) symmetrical than they seemed to be; above, there is one main azygous piece and two pairs of lesser pieces; below, one main azygous piece and three pairs of subsidiary pieces.

late above, and sharp below, the sharp part being invested with yellow horn—part of the dental series.

*4th Section* (Plate 20, fig. 4).—Both the cornu trabeculæ (*c.tr.*) and the median upper labial (*u.l.*) are broader than in the last, and the first lateral cartilage (*u.l.*<sup>2</sup>) is cut through obliquely lower down. The annular cartilage (*l.l.*) is cut across in front of its hind margin, and shows the concavity along its upper half. The hinder teeth (*l.t.*) are shown in the hollow of the divided labial disk. At the upper edge of the annular cartilage, right and left, there is a reniform tract of cartilage; this is the head of the lateral distal mandibular (*l.d.m.*). The skeleton of the tongue (*tg.*, *b.hy.*) is now cut across, it is a thick slab of cartilage, with both surfaces slightly concave, and the lower face of less extent than the upper.

*5th Section* (Plate 20, fig. 5).—This is from behind the annular cartilage, and through the hinder third of the great disk (*s.d.*). The two great roof cartilages (*c.tr.*, *u.l.*) are very similar to the last, and the first lateral upper labial (*u.l.*<sup>2</sup>) is cut through near its lower end, and the foremost point of the second (*u.l.*<sup>3</sup>) is cut across. The lateral distal mandibulars (*l.d.m.*) are now flat, with their upper edge turned outwards; between them, and near to them, arching over the hind part of the disk, two plates of cartilage are cut through, thick in the middle and thin outside; these are the two sides of the fore part of the “median distal mandibular” (*m.d.m.*), which is notched in its broad fore edge (see Plate 10, fig. 6) in the young *P. marinus*. Several cartilages are seen in the fore end of the tongue (*tg.*); of these the four larger tracts belong to the basi-hyal (*b.hy.*, see also Plate 18, figs. 6–8); the short anterior median (*b.hy.*'), with the pair of short ascending pieces (*b.hy.*'), and behind and under the middle piece the fore end of the main long bar (*b.hy.*), which is elliptical in section in front, and placed with its long axis upwards. This section shows, what the general view of these parts does not, namely, that when these curious *quasi-mandibles* are cut through obliquely, their common basal piece is arched a little upwards. In the curious lingual *cushions* there is a small “supra-lingual” cartilage, right and left (*s.l.c.*); its point is cut across here.

*6th Section* (Plate 20, fig. 6).—The use of these various sectional figures will be seen by comparing this with the last; there seems to be but little difference between them, but we miss some things seen in that, and find some new ones in this. The great leafy cornu (*c.tr.*) is wider and flatter, the median upper labial (*u.l.*) is very similar; the first lateral upper labials are gone, the section was made behind them, and the second (*u.l.*<sup>3</sup>) are larger points of cartilage between the two roof-plates. The flattened distal lateral mandibulars (*l.d.m.*) are vertical here, and the median cartilage (*m.l.m.*) is a single plate, slightly bent downwards where the basi-hyal rests on it. The main basi-hyal (*b.hy.*) is now much flatter and somewhat higher; the front short middle piece is not seen, but the erect pieces (*b.hy.*') are cut across in their hind lobe, so that there is a considerable space between them and the main bar. The little cartilages inside these (*s.l.c.*) are larger, are elliptical in section, and in the valley

between the cushions that contain them, sharp yellow teeth are seen—the “supra-lingual” teeth (*s.l.t.*) (see Plate 14, fig. 9).

*7th Section* (Plate 20, fig. 7).—In this, the same parts are cut through as in the last, but they are different in form and position. The great cornu (*c.tr.*) is but little changed, but the median labial plate (*u.l.*) is considerably contracted, at this, its hinder margin. We see the wedge-like point of the second lateral upper labial (*u.l.<sup>2</sup>*) above, and the paired distal mandibulars (*l.d.m.*) below; these are getting further apart. The median piece (*m.d.m.*) is now much narrower, being severed behind its dilated part; the main basi-hyal is as in the last, but its wings (*b.hy'*) are vertical in this section, and so are the small supra-linguals (*s.l.c.*) between them; we still see the teeth (*s.l.t.*) between the cushions. The section of the great disk is lessening towards its hind margin.

*8th Section* (Plate 20, fig. 8).—The oral opening is now becoming very contracted, the great roofing cornu (*c.tr.*) is of undiminished size, but the large median labial (*u.l.*) only shows its postero-inferior angles, right and left. The second lateral pair (*u.l.<sup>2</sup>*), which wedges in between the two roof-pieces, is now trilobate in section, and larger; the distal mandibulars (*m.d.m.*, *l.d.m.*) and main basi-hyal (*b.hy.*) are much as in the last section, but the paired lobes of the basi-hyal are gone; only a small part of each supra-lingual (*s.l.c.*) is seen.

*9th Section* (Plate 20, fig. 9).—The roofing cornu (*c.tr.*) is narrower here, and its lower edges are thickened instead of being sharp. The upper median labial is not seen, but the second lateral piece (*u.l.<sup>2</sup>*) is now a large slab; it is *f*-shaped in section, vertically placed, thick edged above and thin below. The distal mandibulars (*m.d.m.*, *l.d.m.*) are smaller, and so are the supra-linguals (*s.l.c.*); the main basi-hyal (*b.hy.*) keeps its form. This section is through the last fold of the suctorial disk, which is here seen to be quite free from the rest of the section, and to have lost its lower gap.

*10th Section* (Plate 20, fig. 10).—This section is behind the lips, and only one pair of labials, the second upper lateral (*u.l.<sup>2</sup>*) are cut across; they are thinner here than in the last. The great cornu (*c.tr.*) is one-third narrower; the distal mandibulars (*m.d.m.*, *l.d.m.*) are getting less and less; the main basi-hyal (*b.hy.*) is much the same, and the tongue (*tg.*) is cut through behind the cartilages and teeth.

*11th Section* (Plate 20, fig. 11).—The great cornu (*c.tr.*) is gaining in thickness, but losing its width; the second lateral labials (*u.l.<sup>2</sup>*) are cut through their hind margin; the other parts are much as in the last section. The small elevation at the top is the beginning of the nasal opening (*e.n.*).

*12th Section* (Plate 20, fig. 12).—In this section the outer nasal opening (*e.n.*) is laid open above the proximal part of the cornu trabeculæ (*c.tr.*). Here the oral cavity (*m.*) is a large oblong space, partly occluded, below, by the lingual apparatus, in the base of which we see the vertical basi-hyal (*b.hy.*). Opposite the middle of that bar the postero-inferior angle of the large lateral labial (*u.l.<sup>2</sup>*) is cut across, and the points of the three distal mandibulars (*m.d.m.*, *l.d.m.*) are still seen in section.

*13th Section* (Plate 21, fig. 1).—This is also through the outer nasal opening (*e.n.*) and the proximal part of the cornu (*c.tr.*); the other sections are like the rest, except that the lateral distal mandibulars are no longer seen.

*14th Section* (Plate 21, fig. 2).—The outer nasal passage (*e.n.*) is a flattened tube, vertically placed, here, for this is close in front of the nasal capsule, and through the junction of the cornu (*c.tr.*) with the solid pre-cranial plate or ethmoid; the cartilage lies over the large oral cavity (*m.*) as a thick beam, slightly arched upwards, and a little hollowed in the middle, above. The other points of cartilage are like the last.

*15th Section* (Plate 21, fig. 3).—This section is through the front third of the nasal capsule (*ol.*), showing its *nine pairs* of radiating folds or lobes, each having its own fissure, and lined with mucous membrane; the interspaces of the folds are filled with black pigment. The lower folds are shorter than the upper and lateral, and the posterior nasal canal (*p.n.c.*) is distinct; it is seen as a transversely oval space between the capsule and the ethmoid (*eth.*). The capsule itself (*na.*) is not so distinctly bilobed as in the young of *P. marinus* (Plate 18, fig. 3, *na.*), for its top is flat, and it is somewhat angulated at the sides. The cartilage of the capsule is of the softer kind, but approximates to the general hardness of the skeleton in the hind part; it does not meet below in the sections that cut through the folds,—only behind (fig. 6). It is not a mere *grating* as in the Myxinoids (Plates 10 and 17), but is a continuous sheet, dipping in towards the deeply pigmented interspaces of the folds. The cranium is cut through so as to show the continuity of the ethmoid (*eth.*) with the *ethmo-prepalatine* tract (*e.pa.*), running almost to the front spike. The whole of this arched, but flat-topped, tract is of nearly uniform thickness; the palatine bars bend a little inwards above, and then outwards below, and are rounded at their edge. Under the oral cavity (*m.*) the only cartilages cut through are the basi-hyal (*b.hy.*) and the tip of the median distal mandibular (*m.d.m.*)

*16th Section* (Plate 21, fig. 4).—This is through the middle of the nasal capsule (*na., ol.*) and the fore part of the eye-ball (*e.*). The wheel-like appearance of this organ is most perfect here, the lower folds being larger; and the lower face of the capsule, which is membranous for a slight extent, is not pushed up by the posterior nasal canal (*p.n.c.*). On each side of the ethmoid (*eth.*) there is a low wall, the beginning of the orbito-sphenoidal region, and in the middle of the descending plate of cartilage there is a fissure,—this is the fore margin of the “subocular fenestra” (*s.o.f.*); the pterygo-palatine bar (*pt.pa.*) is thickened at its lower edge. The lining of the mouth (*m.*) is quadrilobate; under it is the only other cartilage seen in this part—the basi-hyal (*b.hy.*). The third branch of the 5th nerve (*V<sup>3</sup>*) is seen in section between the subocular fenestra and the oral cavity.

*17th Section* (Plate 21, fig. 5).—This is through the back of the nasal organ, and only two pairs of upper folds are laid open, the rest of these folds being covered here by the highly pigmented stroma; the cartilaginous capsule (*na.*) reaches below to the lowest fold, right and left. The cranium at this part is four-winged, for the

ethmo-palatine (*e.pa.*) is much less here, because of the large space—the subocular fenestra—(*s.o.f.*), and the orbito-sphenoidal wings (*o.s.*) are rising and diverging; in the hollow between them runs the posterior nasal canal (*p.n.c.*, outline not figured in this section). The post-palatine and pterygoid at their junction form a moderately high and thickish band; inside this, near its top, is the third branch of the trigeminal ( $V^3$ ); below the oral cavity (*m.*) is the basi-hyal (*b.hy.*).

*18th Section* (Plate 21, fig. 6).—Here we see that the apiculate hind part of the nasal capsule (see also Plate 18, fig. 3) grows vertically downwards for some extent, and that the walls, which underlaid the capsule to some degree, further forwards, have now united to form a perfect floor. The median cartilage is partly hard; it does not correspond with the *ethmo-septal* partition of higher types, but with so much of the nasal roofs as are developed downwards, back to back, to unite with the true septum. The posterior nasal canal (*p.n.c.*) is seen in the bottom of the deep cranial trough, whose orbito-sphenoidal walls (*o.s.*) are high and diverge so as to make a wide space for the olfactory lobes ( $C^{1b}$ ), and the curious limited partition and floor of the nasal capsule (*na.*). Here the *waist* of the skull is well pinched in, and the orbits and eye-balls (*e.*) are large; large, also, is the shelving floor of the orbits, which is cartilage above and below, the intermediate space being equal in extent to both of the tracts; the upper is now trabecular (*tr.*), and the lower pterygoid (*pg.*); the space, or suborbital fenestra (*s.o.f.*), is split into two laminae, and between them the 3rd branch of the fifth ( $V^3$ ) passes to the lower and front parts of the face.

The oral lining (*m.*) has now become five-lobed; below it, we see the vertical basi-hyal, and close to it a pair of cartilaginous points—the fore ends of the ceratohyals (*c.hy.*) (see also Plate 18, figs. 1, 2, 6, 7).

*19th Section* (Plate 21, fig. 7).—This is through the middle of the eye-balls (*e.*), behind the nasal capsule, where the olfactory lobes ( $C^{1b}$ ) arise from the fore brain. The dura mater (*d.m.*) is thick, and still retains the form of the back part of the nasal capsule, and below this membrane's roof we see that the side walls (*o.s.*), which are gently out-turned above, are segmented below their middle, opposite the top of the posterior nasal canal (*p.n.c.*). This is the beginning of the orbito-sphenoidal fenestra (*o.s.f.*), which membrane is perforated further backwards for the optic nerve (see Plate 18, fig. 5). The subocular flange of the trabecula (*tr.*) is smaller than in the last; the remaining parts are quite similar in both sections (*pg.*, *s.o.f.*,  $V^3$ , *b.hy.*, *c.hy.*).

*20th Section* (Plate 21, fig. 8).—Here the section is through the optic nerves and the fore brain (II., see also fig. 9,  $C^1$ ), where the orbito-sphenoidal fenestra (*o.s.f.*) is wide. The dura mater (*d.m.*) is still thickened in the middle of the roof, and the orbito-sphenoids (*o.s.*) now turn in above. The trabecular flange (*tr.*) is very thin, right and left, and so also is the trabecular floor, now behind the intertrabecular region. This is the last section figured in which we shall see the posterior nasal canal (*p.n.c.*) fairly lodged *inside* the cranial cavity. The remaining parts are like what

was shown in the last, but the pterygoid band (*pg.*) is broader. The fibres of the 3rd branch of the 5th nerve ( $V^3$ .) have not escaped the layers of the floor at this part.

*21st Section* (Plate 21, fig. 9).—The whole cranio-facial frame is here seen as mere patches of cartilage, three pairs of small convexo-concave tracts above, with one large trilobate, and two small pyriform, sections below. Here the cranial cavity is large, but the cerebrum ( $C^1$ .) is small; the orbito-sphenoids (*o.s.*) are separated from the trabeculæ (*tr.*) by a space (*o.s.f.*) wider than the bars themselves. These are bent in the opposite direction, the upper are convex outside and the lower concave. The pterygoid (*pg.*) is a gently-arched band; between it and the trabeculæ (*tr.*) the 3rd branch of the 5th ( $V^3$ .) is seen lying on the fenestra, ready to enter. The posterior nasal canal (*p.n.c.*) is now without a cartilaginous floor, ready to escape into the pharyngeal space; the cartilages below the buccal cavity (*m.*) are the basi- and cerato-hyals (*b.hy.*, *c.hy.*). Above these the rising floor of the mouth contains the *fimbriated intervelar shelf* (see Plate 18, fig. 7; and Plate 14, fig. 8).

*22nd Section* (Plate 22, fig. 1).—This shows a pyriform cranial cavity containing the fore brain ( $C^1$ .) at its junction with the mid brain. Here the back part of the eye-balls (*e.*) and the orbital muscles are seen, and the posterior nasal canal (*p.n.c.*) escaping through the pituitary space between the trabeculæ, which form at this part the high alisphenoidal walls (*al.s.*), in section like a pair of callipers, bent outwards, above, like blades, which are connected across the roof by the convex dura mater (*d.m.*). This section is through the hind part of the subocular fenestra; the pterygoid (*pg.*) is here thick above; the 5th nerve is not figured in this drawing. Below the lobulated oral (or *buccal*) cavity (*m.*), and between that space and the hyoid apparatus, there is a plate of hard cartilage cut across—a thinnish, sinuous tract. This is the “*intervelar shelf*” (*i.v.s.*), cut across behind the fimbriations. Here the cerato-hyals (*c.hy.*) are much deeper than in the last section.

*23rd Section* (Plate 22, fig. 2).—Here, if anywhere, we have an instructive section, made in the pre-auditory or post-pituitary region. The mid and hind brain ( $C^2$ ., see also fig. 3,  $C^3$ .) meet here, and the latter is giving off the great trigeminal nerves ( $V$ .), with their huge gasserian ganglia. These parts are seen in the foramen ovale, under the fore face of the auditory capsule (*au.*) which is surmounted by the alisphenoid (*al.s.*), now turning inwards on to the roof of the skull. Looking at this figure and that of the dissected skull (Plate 18), we see that the razor has cut through the investing mass (*iv.*) enclosing the fore part of the notochord (*nc.*), the pedicles (*pd.*), the back part of the pterygoid (*pg.*), that part of the suspensorium (or *pterygo-palatine arcade*) which gives off the epi-hyal from its hinder margin (see Plate 18, fig. 1, *e.hy.*). Below the basis-cranii, the posterior nasal canal (*p.n.c.*) has nearly doubled its “*bore* ;” at some distance below that tube we see, now, not a wide quinquelobate *buccal cavity*, but the plicated opening of the narrow food-pharynx (*phx.*), having under it the cartilaginous core of the intervelar shelf. Below that shelf we see the hyoid apparatus; the fissures between that musculo-cartilaginous structure and the shelf form the

valvular entrance to the *branchial canal* (or "bronchus;" see also Plate 23, fig. 1). Here the cerato-hyals (*c.hy.*) are seen to be obliquely-placed plates, sinuous in form, and bent upwards, both externally and within, where they are tied to the carinate basi-hyal (*b.hy.*) (see also Plate 18, figs. 2, 6, 7).

*24th Section* (Plate 22, fig. 3).—The cranial cavity is nearly surrounded by cartilage in this part, for the alisphenoids nearly meet as a *tegmen cranii* (*t.cr.*) over the hind part of the mid brain ( $C^2$ ). The hind brain ( $C^3$ .) is also cut across in its fore part, and the hind part of the 5th nerve (V.) is still to be seen in the foramen ovale. The auditory capsules (*au.*) have here an inner wall in front of the meatus internus. The section of the notochord (*nc.*) is larger; there is a fissure between the two parachordal plates (*iv.*) above; these plates pass, with but little thinning out, directly into the pedicles (*pd.*) The section is made through them into the hyoid bar (*e.hy.*), which is gently bowed outwards, enlarges, and again lessens before it is turned forwards and inwards, as the cerato-hyal. Just above its middle an *elbow* is seen; this is the back of the pterygoid bar (*pg.*), whence the *quadrate lobe and condyle should have grown outwards and downwards*. The cerato-hyal region is suddenly bent upwards with its convex face downwards; each bar ends at a moderate distance from the median carinate rod (*b.hy.*). The posterior nasal canal (*p.n.c.*) is still larger than in the last section, and is sub-pentagonal in outline. Below it is the very narrow pharynx proper (food-pharynx, *phx.*), with its puckered, contracted lining, and below this is the body of the cartilage in the "intervelar shelf" (*i.v.s.*). The space below, right and left, is where the buccal cavities are passing into the branchial canal (see also Plate 23, fig. 1).

*25th Section* (Plate 22, fig. 4).—This is through the meatus internus, and shows the 8th nerve and its ganglion (VIII.) The capsule (*au.*) is continuous above, as in the last, with the alisphenoidal tegmen (*t.cr.*) over the hind brain ( $C^3$ .), and also, below, with the thick parachordals (*iv.*), which have now a larger notochordal section (*nc.*) within them. The basal cartilage is cut through here, behind the pedicle, but the corresponding region of the hyoid arch is suppressed, for there is no hyomandibular tract, such as we see in the Myxinoids; beyond this point there is no more *endoskeletal* cartilage in the side walls. The lower part of the epi-hyal and the cerato-hyal (*e.hy.*, *c.hy.*) are cut through, and also the basi-hyal (*b.hy.*) Above the cerato-hyal we see the crura of the intervelar shelf (*i.v.s.*) cut across the pedate end, so that the *toe* and the *foot* are separate points of cartilage (see Plate 18, fig. 7, *i.v.s.*) The section of the posterior nasal canal (*p.n.c.*) is mutilobate and large; under it the food-pharynx (*phx.*) is very small, with its mucous lining corrugated, and in the space below it we have the beginning of the special branchial canal (see also fig. 5, *br.c.*).

*26th Section* (Plate 22, fig. 5).—This is behind the meatus internus and the alisphenoidal roof; the hind brain is seen to be very small as compared with the cranial cavity. As in the last, the notochord (*nc.*) is roofed by the investing cartilage (*iv.*), but the floor is imperfect. The fore part of the vagus, with its ganglion (X.), is

seen, and below it, that part of the extra-hyal (*ex.hy.*) which fastens on to the top of the epi-hyal bar is cut across, and, lower down, the main bar of this superficial soft band. The angle of each cerato-hyal (*c.hy.*) is cut across and the basi-hyal in its *basi-branchial region* (*b.br.*). Three cavities are severed, lined with mucous membrane, one above another, in the mid-line—these are the posterior nasal canal (*p.n.c.*), the pharynx, proper (*phx.*), and the opening of the branchial canal (*br.c.*).

*27th Section* (Plate 22, fig. 6).—This is through the hind face of the auditory capsule (*au.*) and the main mass of the vagus nerve (X.) Here the notochord (*nc.*) is floored, but not roofed, and the limited investing cartilage (*iv.*) does not reach the auditory capsule, but leaves a space for the vagus to pass through; thus the roof of the skull is gone, and most of the side walls. The extra-hyal is cut across as it goes back to join the general basket-work; the basi-hyo-branchial region is cut through (*b.hy.*), and the angles of the cerato-hyals (*c.hy.*). The posterior nasal canal (*p.n.c.*) is lessening; below it we see the food-pharynx (*phx.*), below it the branchial canal (*br.c.*), and right and left of these passages the branchial folds of the first pouch (*br.p.*)

*28th Section* (Plate 22, fig. 7) is from the fore part of the spine, and through one of the foremost pairs of neural arches (*n.a.*), which are seen to be large wedges of hard cartilage, with their upper end thick, and their lower end sharp, the section not reaching to their base. The notochord (*nc.*) has now its average size; its sheath is a thick laminar membrane, like the cornea of the Mammalian eye-ball. The other part of the endoskeleton is the basi-branchial bar (*b.br.*) imbedded in the lingual muscles; above these masses are the branchial canal (*br.c.*), the proper pharynx (*phx.*), and the posterior nasal canal (*p.n.c.*) Outside the gill pouch (*br.p.*, 1st or 2nd) the extra-branchial basket-work (*ex.br.*) is cut across in *nine* places; above, near the notochord, the longitudinal band uniting the arches above; then, on the upper convexity, one of the spurs; at a distance below this the upper, and then the lower, cross band defending the aperture; and then, below, one continuous tract of cartilage belonging to the lower part of a right and left arch, at their junction.

*29th Section* (Plate 22, fig. 8).—This is very similar to the last section, and was taken not much further back. Here in a complete section of the neural cartilages (*n.a.*), we see that they are thickened at both ends. The posterior nasal canal (*p.n.c.*), is much folded; this is its last appearance in the sections figured; the other passages are as in the last section. The upper band of the basket-work (*ex.br.*) is cut across, also one of the snags, and one of the cross bars; the other must have been cut through, but was hidden beneath the other tissues. Below, the common junction of the bars is cut across, between the bars, and between the median fenestræ.

*30th Section* (Plate 22, fig. 9).—Here we see the neural cartilages (*n.a.*) resting upon the sheath of the notochord (*nc.*); below this the great artery (*ao.*) is cut across, but there is no posterior nasal canal between it and the pharynx (*phx.*), which is well marked off from the branchial canal (*br.c.*) The lingual apparatus and the basi-branchial (*b.br.*), is still present; this is at about the *first third* of the great branchial



apparatus. Here the upper extra-branchial bands (*ex.br.*) are cut across; the uniting bands above and under the aperture; and the median inferior junction of the arches.

*31st Section* (Plate 23, fig. 4).—This is the last of the thin sections figured, and is from the beginning of the *second third* of the branchial region; both the external apertures (*e.b.a.*) are laid open. The neural arches (*n.a.*) are not so wide apart above, and they have crept some distance down the side of the notochord; under these hard tracts the soft upper bands of the basket-work (*ex.br.*) are cut across, then two of the lesser bars, then a main bar, bending inwards behind its own aperture (see Plate 18, fig. 1), and then a common inferior band at a very narrow part. The passages between the pouches are the great artery (*ao.*), the pharynx (*phx.*), and the branchial canal (*br.c.*); the median basi-hyobranchial bar is not seen, but the hind part of its huge muscular lingual apparatus is shown.

*32nd Section* (Plate 23, fig. 5).—This is the first of the transversely-vertical solid sections, made a little obliquely so as to show the external branchial aperture, the last, on one side (only) with a few of the folds (*br.p'*). The small flat myelon (*my.*) is seen in the canal formed by the theca vertebralis (*th.v.*), and under it the notochord (*nc.*) is at its largest size. The heart (*h.*) is cut through in its fore-part, with the basket-work of the pericardial region (*pcd.c.*) cut across. The pharynx (*phx.*), at the end of the branchial canal, is larger, but is pushed out of the mid-line by the heart. This section is between two pairs of neural arches.

*33rd Section* (Plate 23, fig. 6).—The second of these solid sections is through the middle of the heart (*h.*), and shows the extra pericardial (*pcd.c.*), as an almost perfect girdle; here the opposite face of the section has been drawn, so that the pharynx (*phx.*) is seen on the other side; the tips of two neural arches (*n.a.*) have been cut through.

*34th Section* (Plate 23, fig. 7).—Here we see the fundus of the tilted *bowl*, the pericardial cartilage (*pcd.c.*); the pharynx is in the figure on the same side as in fig. 5, the same *face* of the section being drawn; only the tips of a pair of neural arches are cut across. The muscular masses in these three figures are shown in their full (uncontracted) bulk.\*

*On the skeleton of the embryo of Petromyzon planeri, 7·8 mm. to 9·5 mm. in length.*

These small, delicate, worm-like embryos, the larger of which only, namely, those about  $\frac{1}{3}$ -inch long, were worked out by me, came to me through Professor F. M. BALFOUR, who was enabled to breed them (by artificial impregnation) through the kindness of OSBERT SALVIN, Esq., F.R.S. The sections were lent me by Professor BALFOUR, and what I have to show with regard to them may be added to his excellent account of

\* SCHNEIDER (plate 10, fig. 1) shows the cartilages of the tail-fin: these parts do not enter into my plan.

the development of this type in the 2nd vol. of his 'Comparative Embryology' (pp. 68-83, figs. 37-49).

My figures are from one of the larger of these embryos (Plate 8, figs. 1-3); in the full-figure, the side view, about *eighty* myotomes are shown; its great approach, in form, to the proper larva (or *Ammocæte*) is seen by comparing the next figures (4-6) in the same plate.

*Dissection of the skull of an embryo of Petromyzon planeri, 7.8 mm. long.*

As this is the lowest kind of primordial skull worked out at present by me, I shall compare it with that of (A) the Ray;\* (B) the Sturgeon; (C) the Lepidosteus; (D) the Salmon; (E) the Axolotl; and (F) the Larval Frog and Toad.

The large notochord (Plate 25, fig. 7, *nc.*) is almost straight; in an earlier stage (BALFOUR'S 'Embryology,' pp. 74, 75, figs. 42, 43) it is turned downwards at its fore end, and this bend is retained throughout life (Plate 23, fig. 1); it now reaches further forwards, relatively, than afterwards, and gradually lessens to a blunt point. Further than the hind margin of the pituitary space (*py.*) it does not go. Taking the hind margin of the auditory capsules (*au.*) as our place of measurement, behind, and the fore end of the trabeculæ (*tr.*) as another, in front, the notochord reaches exactly half way.

Measured thus some time after transformation (Plate 18, fig. 4, *nc., tr.*) the notochord is about two-fifths the length of the basis cranii; thus we see that it remains as an important basi-cranial structure, but in its earliest development it shows nothing of the *cephalo-chordal* character of *Amphioxus*. The membranous sheath of the notochord is very thick at this early stage; at no stage have I found true cartilage in it, such as we see in the Elasmobranchs. The primary basi-cranial cartilages (*iv., tr.*) are *para-chordal* for their hinder three-fifths, and *pro-chordal* for their front two-fifths, but the front part is thick and wide, whilst the hind part attenuates gently to a fine, pointed end; these two ends are, however, far back behind the ear-capsules; two-fifths of the parachordal length of the cartilage is behind the ear. Considering the size of the region supplied by the branches of the vagus nerve, it is not unreasonable to take all the parachordal region of the notochord as properly basi-cranial; the fact is, the head and spine are not divided off sharply—there is no joint; afterwards, when the neural arches appear in the transformed Fish, the first pair of cartilages give us the beginning of the spine.

These parts cling close to the sides of the notochord, so as to be crescentic in section (see Plate 25, figs. 3, 4, *iv., nc.*) nearly to the middle of the auditory capsules (*au.*); thence they diverge further and further from the axial rod. In front of that rod, in their *pro-chordal* part, the bars (trabeculæ) are separated by a tract thrice their greatest

\* (A) Trans. Zool. Soc., vol. x., plate 35; (B) Phil. Trans., 1882, Plate 14; (C) Phil. Trans., 1882, Plate 30; (D) Phil. Trans., 1873, Plate 2; (E) Phil. Trans., 1877, Plate 22; (F) Phil. Trans., 1876, Plates 55, 56, and 60; and 1881, Part I.

width. At this part they embrace the lower part of the front of the membrano-cranium, in front of the pituitary space.

The basal bars in their pro-chordal region (*tr.*) are thickest in their middle, but do not lessen much in front, they are, in form, like a pair of *callipers*, and end in a blunt point which is turned a little towards its fellow. The bars are tilted upwards and outwards (Plate 24, figs. 1-4, *tr.*; and Plate 25, fig. 2, *iv.*).

A little in front of the auditory capsules we see on each side a small blunt hook of cartilage, turned forwards at its free end, but growing directly outwards from the trabeculæ without any sign of segmentation; these are the primordial rudiments of the pedicle and pterygoid (*pd.*, *pg.*). These *first, continuous* rudiments of the face are of great interest, as we shall see by comparing them with their counterparts in other Ichthyopsida.

So also is the condition of the primary basi-cranial bars or trabeculæ, which on their hinder part embrace the notochord as parachordals (or investing mass), but *from the first* are rather related to the fore brain as its proper supporting skeleton, than to any other part. Their union in front of the trabeculæ, and their continuation forwards, as *cornua*, are secondary matters, and vary very much in different types, but their most important character is their *continuity*, for they show no signs of being under the influence of any segmentation that may be developing in the head. Here, the basal bands are longer, but much narrower, in their parachordal than in their prochordal regions, but in the nearest relations of these *Petromyzoids*, the "Anura," they only embrace the apex of the notochord by their hinder end, and form their cornua before they unite at the mid-line. In those Amphibia the parachordal region is developed as a backward extension of the trabeculæ, but in the Urodela that part is developed independently, and the cornua trabeculæ may appear first as *ongrowths* of the trabeculæ, or afterwards as *outgrowths*. Then, as to the facial part of the skull, or upper jaw, (the upper part of the 1st branchial or visceral arch), which is greatly developed forwards over the mouth in all known Vertebrata, we see that in the Lamprey the pedicle with its hooked end or rudiment of the pterygoid cartilage is developed from the first as an outgrowth of the trabecula, and the rest of the arcade—its palatine portion growing on to the ethmoidal end of the trabecula—does not appear until after transformation.

In the Anura the whole arcade is primary, and is primarily one with the trabeculæ, both the pedicle and the ethmo-palatine tract being continuous with the basal bar.

In the Urodela nothing of the sort exists; the pedicle and its ascending process are developed as the bifid free top of the suspensorium; afterwards both unite with the skull in some kinds; in others only the ascending process. In them the palatine with its ethmo-palatine process, is an *early* free cartilage; the pterygoid process of the suspensorium is a *late* outgrowth, and only in one kind known (*Ranodon sibiricus*\*) does the subocular arcade *become* continuous. On the other hand in the genus *Bufo*,

\* See WIEDERSHEIM, 'Kopfskelet der Urodelen,' 1877, plate 5, fig. 69.

amongst the Anura, after being a mere wing or flying buttress of the skull during the larval period, it becomes, in metamorphosis, broken up into separate parts, like that which is primary in the Urodela.

In the Rays there is a *pedicle*, but it is a primarily independent cartilage, the foremost of the "pharyngo-branchial" elements; in Sharks there is merely *one, two, or three* "interbranchial rays" in this part, and in all the normal "Elasmobranchs" the palatine region—which has a distinct segment in Rays but not in Sharks—is suspended to the skull by a ligament. In these types the trabeculæ are flat and wide, and chondrify first; afterwards, the parachordals become cartilaginous, but this condition runs on into the spinal region without any break, until the *occipito-atlantal* joint is formed.

In *Acipenser*, a low type of Ganoid, the whole basi-cranial region is chondrified at about the same time, but in form is similar to what is seen in the Elasmobranchs. But the upper jaw is developed quite independently of the basis-cranii; its upper part, answering to the pedicle (or metapterygoid region), is a mosaic of cartilaginous pieces, with a median row, such as is seen in the *ventral aspect*, only, of the arches, in other types.

*Lepidosteus*, a high Ganoid, comes nearer to the Suctorial Fishes and the Tadpole, for the palatine end of the upper jaw (palato-quadrato) is from the first continuous with the fore end of the trabecula, and so also is the pier (or *pedicle*) of the hyoid arch. In that type I find no precedence of the prochordal tracts (trabeculæ) in their chondrification; they, and the parachordal tracts, are one, and show no signs of distinction from the first.

It is therefore evident that there is to be seen, in the early chondrocranium of the various *Ichthyopsida*, a mixture of the *non-essential* and the *essential*; these have to be winnowed apart by the Morphologist. I must return to this subject in my summary; but it is manifest that the primary cranium exists merely as a pair of supporting bands from which, without segmentation, the *facial* skeleton may grow. The cartilages that arise in the intermuscular septa, in the spinal region, as rudiments of vertebræ, are a *late* product in the evolution of a Vertebrate; they possibly had no existence in countless types, the brain of which had appeared in its three main vesicles, which, becoming larger and heavier, acquired *pro-* and *para-chordal* supporting balks.

We saw (in Part I.) that one type of Fish, the Hag, more than a foot long, and as thick as a finger, with a highly complex cranio-facial apparatus, has no vertebral rudiments. This is true, also, of another (*Bdellostoma*), as thick as the wrist, and almost a yard long.

This *Myxinoïd* condition remains throughout larval life in the Lampreys, and exists for a time, after the development of the basi-cranial bars, in the other *Ichthyopsida*.

In the figure given of the embryo Lamprey's skull (Plate 25, fig. 7; V., X.) I have shown the huge size of the ganglionic mass belonging to the 5th nerve (possibly that of the 7th included in this mass), and of the 10th or vagus.

The auditory capsules (*au.*) are evenly oval in form, and except where the 8th

nerve enters, are covered with a thin layer of true cartilage, which, however, like the rest, is *soft*, at present.

The only skeletal part formed inside the head cavities and branchial arteries is the pedicle, with its hooked pterygoid rudiment (*pd.*, *pg.*); this state of things continues until the time of transformation.

But the extra-branchial basket-work is one of the first parts to be developed, as the sections now to be described show; the pattern of the basket-work is figured from a later stage (Plate 25, fig. 8), but it merely differs from that of these embryos in size and a somewhat increased density and strength of the cartilage. The sections now to be described will be better understood by reference to a figure of BALFOUR'S (vertical section of an embryo half the size of those from which these transverse sections were made) (see 'Comp. Embryol.,' p. 75, fig. 43).

*Vertically transverse sections of the head and branchial region of embryos of P. planeri, 7.8 mm. and 9.5 mm. in length. Magnified 150 and 300 diameters.*

*1st Section* (Plate 24, fig. 1, 150 diams.; see also Plate 8, figs. 1-3).—This is through the fore brain (*C<sup>1</sup>*) and upper lip (*u.lp.*) of the larger embryo. Here the huge relative size of the brain is shown, filling the membrano-cranium. The parts which concern us at this part are the thin tilted ends of the trabeculæ (*tr.*), which are lanceolate in section, and are connected together by a definite tract of soft cells. In part of a similar section of the smaller embryo (Plates 24, fig. 1*a*, 300 diams.) we see that the cartilage is two cells thick in the middle, and that the intervening soft tract is in two layers near the cartilage, ready to form the trabecular commissure (see Plate 19, figs. 4, 5, *tr.*).

*2nd Section* (Plate 24, fig. 2, 150 diams.).—This is still through the upper lip (*u.lp.*), the fore brain (*C<sup>1</sup>*) is somewhat smaller at this part, the trabeculæ (*tr.*) are now oval in section, and the special layer of indifferent cells, ready to become a transverse band of cartilage, is not seen. In a partial section of the lesser embryo at this part (Plate 24, fig. 2*a*, 300 diams.), the young cartilage (*tr.*) is three cells thick.

*3rd Section* (Plate 24, fig. 3, 150 diams.).—This is through the fore brain (*C<sup>1</sup>*) behind the upper lip, and therefore through the chin (see Plate 8, figs. 1-3); the tilted trabeculæ (*tr.*) are broader than in the last section.

*4th Section* (Plate 24, fig. 4, 150 diams.).—In this section, through the hind part of the fore brain (*C<sup>1</sup>*) and the pituitary region (*py.*), the trabeculæ (*tr.*) are thicker and less tilted; this is immediately in front of the Gasserian ganglion.

*5th Section* (Plate 24, fig. 5, 150 diams.).—This is through the mid brain (*C<sup>2</sup>*); the fore part of the Gasserian ganglion is cut across, and also the stem of the 5th nerve (*V.*) as it passes over a tract of cartilage growing directly from the cartilage (*iv.*). The notochordal apex (*nc.*) is cut across close behind the pituitary region. Another figure (Plate 25, fig. 1, 300 diams.) shows the basis-cranii and its facial outgrowths on a larger scale. The oval section of the cartilage (*iv.*) lies in a nearly horizontal position and

is three cells thick, whilst the hooked rudiment of the pedicle and pterygoid (*pd.*, *pg.*) is two cells thick, with an intercalary cell or two at its bulbous end; its cells are smaller than those of the trabecular bar, but they are only a slight degree behind them in development, and there is no segmental line between them. What appears to be such a line is due to the difference in the size of the cells in the main and secondary bars. The notochord (*nc.*) is cut across; the mouth cavity (stomadæum) is very large.

*6th Section* (Plate 24, fig. 6, 150 diams.).—This is through the mid brain ( $C^2$ .) and the massive Gasserian ganglia (*V.*); the notochord (*nc.*) is enlarging, and the basal bars or parachordals (*iv.*) are much nearer the notochord than in the last, and they are circular in section. Here, right and left, there is a curtain hung across the back of the *stomadæum* (*m.*), partly dividing it from *the archenteron*. This is the “velum” (*vl.*), (see also Plate 25, fig. 10, *vl.*).

In a partial section, intermediate between this and the last (Plate 25, fig. 2, 300 diams.), the cartilages (*iv.*) are further from the notochord, still oval in section, and three cells thick in their middle.

*7th Section* (Plate 24, fig. 7, 150 diams.).—This is in the fore part of the hind brain ( $C^3$ .) and the fore third of the auditory capsules (*au.*); it is in front of the meatus internus; the capsules are oval in section, are a little flattened on their inner face, and slightly tilted outwards, above.

This is between the large *pre-* and *post-*auditory nerve-ganglia. The narrow terete parachordals (*iv.*) are midway between the capsules and the enlarging notochord. The space below is now *pharyngeal* (*phx.*).

A similar, but partial, section made behind the entrance of the auditory nerve (Plate 25, fig. 3, 300 diams.), shows that the membranous labyrinth (*au.*) is covered with a thin (single) layer of cartilage cells. Here the moieties of the investing mass (*iv.*), or parachordal tracts, are crescentic, and cleave close to the membranous sheath of the notochord (*nc.*).

*8th Section* (Plate 24, fig. 8, 150 diams.).—The hind brain ( $C^3$ .) is becoming smaller, for this is at the back of the auditory capsule (*au.*). Below, between the membranocranium and the capsule, the ganglion of the vagus (*X.*) is cut across. Here, also, the investing mass is in crescentic sections, cleaving close to the enlarging notochord (*nc.*).

Part of a similar but partial section (Plate 25, fig. 4, 300 diams.) shows the relations of these parts, and the form of the double row of cartilage cells, right and left.

*9th Section* (Plate 24, fig. 9, 150 diams.).—This is a very instructive section, made through the first pair of branchial pouches and their openings at the end of the hind brain ( $C^3$ .) behind the auditory capsules, but through the vagus ganglia (*X.*). There is still a definite tract of parachordal cartilage (*iv.*) embracing the notochord (*nc.*), and considerable tracts of the first extra-branchial (see also Plate 25, fig. 8, *ex.br<sup>1</sup>*.) come into view. On one side the top of the arch is cut through, where it runs in the longitudinal upper band, and the section of that band lies close to, but is independent of the investing mass (*iv.*). Part of the arch, above, is seen on the other side and on both

sides the bounding bars of the external branchial opening—on one side directly across, and on the other obliquely; in the former (the left side of the figure) the inturned middle part of the main arch is seen for some extent, and then some of its lower part. The inner wall of the first pair of branchial pouches is cut through somewhat irregularly, a thing not to be wondered at, considering the *size* of the fish sectioned.

*10th Section* (Plate 25, figs. 5 and 6, 150 and 300 diams.).—This is through the *third* or *fourth* pouch and the middle of the thyroid involution (*th.*), at the junction of the hind brain ( $C^3$ .) with the myelon. The notochord (*nc.*) is very large, and has no investing cartilage on its sides. Considerable tracts of a pair of extra-branchials come into view in this section, which is only deficient by losing the bend at each shoulder and the lowest part of each bar in the region of the thyroid body (*th.*). This section shows well what a mere lateral figure (fig. 8) cannot so well, namely, the curious inflexion of the main band immediately behind the aperture; this, however, is clearly indicated in the figure of the transformed Lamprey's basket-work (Plate 18, fig. 1). This section shows that the junction of the main bar with the upper longitudinal band takes place close to the notochord, but is quite independent of it; where the shoulder is cut across (fig. 6), there the rod shows four cells, more or less overlapping each other. The other or upper end of the bar (fig. 6) must be considered as severed obliquely (see fig. 8), taking in both the longitudinal and the descending bar at once; the edge of the sectioned part passes a little into the interspace between the notochord and aorta (*nc., ao.*).

If anything remains obscure after this description, I hope to make it plain in what follows, namely, an account of the cephalic and branchial skeleton of the fully-formed and full-sized larva or *Ammocæte*.

*On the skeletal structure of large larvæ of Petromyzon fluviatilis.*

In following these descriptions the reader is referred to the external figure also of the *Sand-pride* or *Ammocæte* (larva of *P. fluviatilis*, Plate 8, figs. 4–6).

*A.—Vertical section through head and branchial region of a larva 6 inches long.*

In this *diagrammatic figure* (Plate 25, fig. 10) we see the hooded pouch of the mouth (see also fig. 8, *m.*) formed by the upper lip (*u.lp.*), with its moss-like growth of *inner barbels* (*bb.*). Then there is the velum (*vl.*) separating the oral cavity (*stomacæum*) from the general pharyngeal space (fore part of *archenteron*); this velum, or right and left vertical curtain, is attached above under the fore part of the auditory capsule, and is, so to speak, a production of the inner edge of the hind part of the 1st visceral fold; and behind and external to it, in the re-entering angle between it and

the cheek, is the rudimentary *non-perforate 1st cleft*.\* Behind this part the seven branchial pouches (*br.p<sup>1</sup>.-br.p<sup>7</sup>.*) are laid open, and their main folds shown; behind them is the heart (*h.*); this section is just *beyond* the mid-line below, for it exposes the cavities of the pouches of the *right* side. Under the muscular segments we see the myelon (*my.*) in its theca, but the brain has been removed to show the auditory capsule (*au.*) and its meatus. In front of the capsule the trigeminal (V.) passes out, and behind it, the vagus (X.). In the middle of the space between the auditory capsule and nasal sac (*ol.*) the optic nerve (II.) escapes. There is only cartilage in the mid-line in front—the trabecular commissure or ethmoid (*eth.*); over it is the nasal sac (*ol.*) with its cartilaginous roof, and a pouch is growing downwards and backwards as the beginning of the “posterior nasal canal” (*p.n.c.*); the sac opens above as the external nasal aperture (*e.n.*). The notochord (*nc.*) bends downwards in front, and reaches to the pituitary region a little in front of the ear-capsules.

This sectional *plan* will enable us to understand what follows.

#### B.—Dissected head of larval *P. fluviatilis*, 6 inches long.

The *larva* is now eighteen times the length of the *embryos* just described, and that which strikes the eye at once is that the trabeculæ (Plate 19, figs. 4, 5) have united in front to form the rudimentary ethmoid, and that the cartilage is nearly all, in the cranium proper, of the hard kind—it has passed insensibly into this sort.

The cranium is now a long loop or *staple* of cartilage; the points of which, behind the ears, are soft, but the rest all hard cartilage. The fore end turns round by a sudden convexity (*eth.*), and the sides (*tr.*) are pushed in twice, first a little, where the optic nerves (II.) emerge, and then a second time, where they clamp the notochord (*nc.*) *near*, but not *at*, its narrow bluntly-pointed end. The lanceolate space thus enclosed is only properly *pituitary* just in front of the notochord, and under the greater, fore part, of this space a floor is formed, notched, behind, under which the posterior nasal canal is beginning to creep (see Plate 25, fig. 10, *ol.*, *p.n.c.*). The lesser oval space, behind, lies lower than the front part of the proper membrano-cranium, and this hind part is the pituitary region. The under surface of the conjoined trabeculæ (Plate 19, fig 4, *tr.*) is convex, but above (fig. 5), the bars, in their fore half, are tilted, and the upper edge is growing into a low crest. This crest becomes the ethmoidal and orbito-sphenoidal walls (see Plate 19, fig. 1, *eth.*, *o.s.*); it is not well seen except in ripe larvæ (Plate 19, fig. 5); in younger specimens (Plate 26, figs. 5, 6) there is merely a tilting of the bars which have a concave upper edge.

These rudiments of cranial walls are not seen in the alisphenoidal region, here the *walls* are entirely membranous before transformation. In the parachordal region

\* Professor HUXLEY (Proc. Roy. Soc., Vol. xxiii. (1874), p. 129) speaks of an external opening to this cleft, but neither BALFOUR, SCOTT, nor I can find it.



(*iv.*) the notochord is exposed both above and below, and rapidly enlarging, carries the attenuated bars at their soft ends far out from the mid-line.

Beneath the meatus auditorius internus each parachordal (fig. 4, *iv.*) gives off a small wing or flap which is continuous with the middle of the infero-internal face of the capsule (*au.*); fore and aft of these flaps there is a considerable chink, or *foramen lacerum*, over which the large ganglionic masses of the *pre-* and *post-*auditory nerves (*V.*, *X.*) lie.

The chinks in front of the flaps are bounded by the outgoing *pterygo-pedicle* (*pd.*, *pg.*). This is, now, a notable narrow wing of hard cartilage, right and left, with a broad proximal part, a dilated sub-bilobate terminal part growing forwards and downwards, and a narrow arcuate stalk.

Compared with the recently transformed skull (same Plate, figs. 1-3), we see that this is the pedicle, with the pterygoid region *free*, as in a Salamandrian, but with a small bud of the future epi-hyal growing from its fore lobe, behind.

The olfactory roof (*na.*) is a broad semicircular plate, convex above and concave below, and with the external aperture (*e.n.*) in the round notch; it is composed of soft cartilage.

The auditory sacs (*au.*) are reniform with the *hilus* opening as the meatus internus; they are somewhat pinched in on both sides, but most on the inner, and their long axis is parallel with that of the skull; as before mentioned, they are fastened to the basal plate by a band of cartilage, right and left—the sub-auditory wings of the parachordals (*iv.*). The capsule has a small perforation under the Gasserian ganglion (fig. 4, *au.*, *V.*).

#### C.—Dissection of a large larva of *P. fluviatilis*, showing the branchial basket-work.

The preparation here figured (Plate 25, fig. 8) had the superficial parts moved from the branchial region, so as to show the whole basket-work of one side, and the heart. If this figure be compared with that showing the same parts in the young of *P. marinus* (Plate 18, fig. 1) we shall see the changes produced by metamorphosis in this part. Here there is no extra-hyal,\* and no extra-pericardial skeleton, but seven sinuously-vertical bars, each passing behind a cleft or external branchial passage, and each united to its fellow, before and behind, by four longitudinal tracts. The whole structure is composed of soft cartilage, now much more consistent, and with larger cells, than in the embryo. The cartilage is of a peculiarly light and spongy kind, much like that described by me some years ago in the Tadpole of *Dactylethra*.

The *cervicorn* outgrowths seen in the transformed young are not present; the upper connecting band is nearly straight, the lower is formed of a series of small arches, and these are placed right and left, back to back (Plate 25, fig. 9).

The principal bends of the main arches are, *inwards*, behind each aperture, and

\* The loop of cartilage round the 1st gill-opening is lettered *ex.hy.* by mistake.

*forwards*, above and below it. The first bar encloses its aperture by a simple loop of cartilage; in the skin in front of this loop we see the fore end of the *branchial groove*, in which place I have, many a time, searched in vain for the *1st cleft*, the hyomandibular; the first open passage is the hyobranchial, and thus the fore half of the first branchial pouch must be accredited to the hyoid region. In the Tadpole the hyoid has no gill, and its three clefts answer to the second, third, and fourth of the Lamprey; the former has *three* pouches, *four* extra-branchials, and *four* rudimentary ceratobranchials inside, which form an imperfect fringed floor or septum between the food-pharynx and the respiratory cavities (see Phil. Trans., 1881, Plate 1, fig. 4).

D.—*Vertically-transverse sections of the head and branchial region of a large (but not ripe) larva of P. fluviatilis.*

*1st Section* (Plate 19, fig. 6).—The first of these sections (see also Plate 8, figs. 4–6) is through the external nasal opening (*e.n.*), and the upper lip (*u.lp.*) with its undergrowth of mass-like barbels (*bb.*); the lips are of great depth, and the top of the face is concave.

*2nd Section* (Plate 19, fig. 7).—In this the nasal roof (*na.*) is cut across behind the opening. The top of the face is still more concave than in the last, and the whole section is deeper.

*3rd Section* (Plate 26, fig. 1).—The roof (*na.*) of the nasal capsule is cut through here so as to miss the median part. The capsule is more vertical than could be shown in the dissections (Plate 19, figs. 4, 5, *na.*), and the bilobate organ of smell (*ol.*) is laid bare; the other parts are similar to what is seen in the last.

*4th Section* (partial; Plate 26, fig. 2).—Here the hinder angles of the capsule (*na.*) are cut across, and the olfactory lobes (*C<sup>lb.</sup>*) are seen in section; barbels are still seen under the hood-like upper lip. The fore part of the nasal canal (*p.n.c.*) is shown.

*5th Section* (partial; Plate 26, fig. 3).—This is very similar to the last, but further back: this shows the angles of the nasal cartilage (*na.*) for the last time, and the large olfactory crura (*C<sup>lb.</sup>*) are cut across their middle.

*6th Section* (partial; Plate 26, fig. 4).—The fore brain (*C<sup>l.</sup>*) and pineal body (*pnl.*) are here severed, and the skull in its front region; the section is through the fore part of the ethmoid (*eth.*), behind the nasal sacs; the barbels (*bb.*) of the upper lip (*u.lp.*) are becoming folds. The proximal part of the posterior nasal canal (*p.n.c.*) is circular at this point.

*7th Section* (partial; Plate 26, fig. 5).—This is close behind the last, and shows the fore part of the cranial trough formed by the ethmoidal commissure of the trabeculæ. The posterior nasal canal (*p.n.c.*) is now crescentic in section, with the concavity above.

*8th Section* (Plate 26, fig. 6).—Here the fore brain (*C<sup>l.</sup>*) rests upon the trabeculæ

(*tr.*), now distinct, but tilted, ready to begin the side walls of the skull in the ethmo-presphenoidal region. The hinder blind end of the budding "posterior nasal canal" (*p.n.c.*) is cut across; in fig. 6<sup>a</sup>, (36 diams.), the lining of this pouch is shown to be composed of round cells.

*9th Section* (partial; Plate 26, fig. 7).—This section is through the fore brain (*C*<sup>1</sup>.), and the fore part of the eye-balls (*e.*). The trabeculæ (*tr.*) are now short-oval in section, and are tilted inwards, above.

*10th Section* (partial; Plate 26, fig. 8).—This is through the middle of the eye-balls (*e.*), and is quite similar to the last.

*11th Section* (partial; Plate 26, fig. 9).—This is through the mid brain (*C*<sup>2</sup>.), the back of the eye-balls (*e.*), the fore part of the Gasserian ganglia (*V.*) and of the notochord (*nc.*). Here the trabeculæ (*tr.*) are sharp above, and inturned; they are a considerable distance from the apex of the notochord (see Plate 19, figs. 4, 5).

*12th Section* (partial; Plate 26, fig. 10).—This is the first section through the hind brain (*C*<sup>3</sup>.); it also passes through the fore part of the auditory capsules (*au.*), just behind their front face. There is here a rudiment of the alisphenoidal wall cresting the capsules on the inside, and their inner wall is complete, as this is in front of the "meatus;" externally, part of the shell of the fore face of the capsule is drawn. The cartilages (*iv.*) now approach the notochord (*nc.*), and they are winged at this point; the wings are the *pterygo-pedicles* (*pd.*, *pg.*), which arch gently over the buccal cavity and thicken, externally.

*13th Section* (partial; Plate 23, fig. 8).—Here we lose the alisphenoidal crest, and the transverse facial outgrowths; the inner wall of the capsule (*au.*) is still perfect; the basal plates or parachordals (*iv.*) are oval in section.

*14th Section* (partial; Plate 23, fig. 9).—This is through the *meatus internus* or internal auditory fenestra through which the 8th nerve passes. It also shows the partial junction of the capsules with the parachordals (*au.,iv.*); those bands are now of a considerable height, and are nearer the enlarging notochord (*nc.*).

*15th Section* (Plate 26, fig. 11).—By comparing this section with the dissected skull (Plate 19, figs. 4, 5) and basket-work (Plate 25, fig. 8), everything skeletal can be identified. It is close to the back of the head, the ganglia of the vagus (*X.*) are cut through, and also the narrow tracts of the basal plates (*iv.*) lying against the large notochord (*nc.*); the hind brain (*C*<sup>3</sup>.) still comes into view. This shows the 1st branchial pouch (*br.p*<sup>1</sup>.) in simple outline—the 1st branchial opening (*e.b.a.*) and the loop of cartilage (*ex.br.*) enclosing it in front of the 1st extra-branchial.

We are now in the front region of the "archenteron," which is a generalised pharynx (*phx.*) permitting the passage of both the food and of the water currents into the pouches.

*16th Section* (Plate 26, fig. 12).—This is through the back part of the 1st branchial pouch and the extreme end of the hind brain (*C*<sup>3</sup>.). There is no parachordal cartilage at this part, and the top of the 1st extra-branchial arch (*ex.br.*)

is shown on each side; the sinuities of the bar cause it to be severed at many points,—*six* on each side. The enclosing bars, and the inbent form of the main bar behind the aperture, are well seen.

*17th Section* (Plate 26, fig. 13).—This is through the forepart of the myelon (*my.*), a curiously flat structure, convex above and concave below. This, which may be through the second or third pair of pouches, shows the thyroid body (*th.*) below. Under it the lower part of an extra-branchial (*ex.br.*) is cut across, and at the apertures the cross bars and part of the inbent main bar is seen. The theca vertebralis is much larger than is necessary for the myelon (*my.*), but it is not much greater in diameter than the notochord (*nc.*), with its thick membranous sheath. Under it we see the aorta (*ao.*), and outside it other large vessels.

### *Summary and Conclusion.*

The remarks now to be made must be considered to be a continuation (with some repetition) of those given at the end of my 1st Part.

These Fishes appear to have been given up in despair by most recent Anatomists, and yet JOHANN MÜLLER laid a solid foundation for all his successors to build upon. Anyone may be proud to become a continuator of, and a commentator on, that great and almost unerring observer.

A continuator and a commentator worthy of him has, from time to time, thrown light upon these types. I refer, of course, to Professor HUXLEY, whose researches, however, needed, what they have now to a great degree obtained, namely, the corroborating and also the correcting light derived from Embrology. Following in the footsteps of the lamented CALBERLA, Mr. W. B. SCOTT has done, and is still doing, excellent work in this way, but (before our great loss) Professor F. M. BALFOUR had shed most welcome light upon this subject.

The problem of the morphology of this group has been to me for years an irritating opprobrium, on account of its apparent insolubility; and I have again and again made advances upon it, sideways, or crabwise, fresh from the contemplation of more normal types. Those *Ichthyopsida* that undergo metamorphoses after hatching, and thus have a *larval stage* during a longer or a shorter time, are of the most service in this matter. Hence I infer that the Marsipobranchs belong to a low grade, and that even supposing the Myxinoids to be degenerate descendants of some more developed form, yet I feel quite certain that such an *archaic non-degenerate Myxinoid* would lie far below our known existing Fishes, such as the Elasmobranchs, Ganoids, and Teleosts. But the three groups just mentioned lie far out of the way of the Marsipobranchs. The early stages of the *Anurous Batrachia* give us the best clue to them, and far off as they are from them, they are indeed their nearest existing relatives. What the early stages of the “Chimæroids” and “Dipnoi” would show, it is impossible to say; unfortunately, their early stages are not known.\* With

\* See Note to p. 411.

regard to the question as to what a truly Archaic Vertebrate would be like, I feel confident that the early stages of a Myxinoid would yield us the most trustworthy evidence. Those Fishes (*Myxine* and *Bdellostoma*) are not, even in their adult condition, Vertebrata, if we speak by the letter. They are mere "*Craniate Chordata*," for, throughout life, they, like the temporary *Ammocete*, or larval Lamprey, show no traces of cartilage in their *spinal region*, although they have a solid, complex, generalised, but rudimentary cranium. It is easy to see that the Ammocetine form of Fish is the platform, so to speak, on which both the Myxinoids and Petromyzoids are built, and although the former rise to a lesser height above that platform, yet they do undergo a large amount of metamorphosis and are marvellously specialised in their own peculiar way. So true is this, that in the burden now, at last, laid upon me, namely, the interpretation of the Mammalian skull and the searching out the pattern of the *Prototheria* or primary Mammalia (and, if the thing be possible, getting some light upon their ancestors, the imagined *Hypotheria*), I know of no types among the *Ichthyopsida* so likely to help me in this dark work as these same Myxinoids.\*

This we may say, namely, that the Myxinoids, Petromyzoids, and Tailless Amphibia, are three groups more nearly related to each other than to any known *Ichthyopsida*, and yet are far apart, in reality.

Roughly speaking, in spite of the gap made by the extinction of possibly many hundreds of *genera*, the adult Myxinoid may be said to represent a larval Petromyzoid, and the adult Petromyzoid a larval Batrachian (Frog or Toad). Indeed, these three groups might be studied in their special structure and in their structural relations to each other without the other *Ichthyopsida* once coming into mind. A knowledge of the latter does, indeed, help in this business, but they lie far out of the way, and have a specialisation and a *finish* in their structure for which we look in vain in the *permanent* and *temporary* Marsipobranchs.

Even the *Chimæroids* come so near the ordinary Elasmobranchs as to suggest that their embryology would not be so helpful as one might imagine, especially if their solid upper face has been acquired as a *secondary* modification and not a *primary* condition such as we see in the Tadpole, which is especially solid and largely continuous with the basis cranii, in the larval Aglossal types, *Dactylethra* and *Pipa*.†

*Sharks*, not *Skates*, retain *remnants* of the bars of the extra-branchial basket-work of

\* The reader will see that I am thinking of Professor HUXLEY's masterly paper—"On the Application of the Laws of Evolution to the arrangement of the Vertebrata, and more particularly of the Mammalia" (Proc. Zool. Soc., 1880, pp. 649-662). The author of that paper has unconsciously set the writer his work for some years to come; the "one thing" for him is to become the *continuator* of, and *commentator* upon, him who made that daring outline.

† The interposition of those remarkable Sharks, *Cestracion* and *Notidanus*, between the ordinary kinds and the Chimæroids, makes the likelihood of the solidity of the upper jaw being *primary* a very doubtful thing; I once thought otherwise, but found Mr. BALFOUR strongly set against me in this suggestion.

the Lamprey; Tadpoles show *rudiments* of the intra-branchial arches of Sharks and Skates. By far the most generalised condition of the branchial skeleton is seen in the Tadpole of the Aglossal *Dactylethra*, and the cartilage of which it is composed is similar to that of the embryo Lamprey, 7 or 8 millims. in length. In that type and in the other Aglossal form, *Pipa*, the membranous space between the *palato-quadrate arcade* and the *trabecula* is almost absent. Yet in these, as in all the Anura, there is in the 1st visceral arch a cerato-branchial element, a free Meckelian (mandibular) cartilage. Professor HUXLEY and I agree in thinking that we have found a true mandibular rudiment in the Lamprey after transformation; certainly there is none in the Myxinoids; and the *quadrate region (and condyle)* is quite suppressed in both the types of the Marsipobranchs (Myxinoids and Petromyzoids). Moreover, the place where this tract *should* be, is not where we find it in the larval condition of the Frog or Toad, namely, at the fore part of the face; but under the exit of the 5th nerve, where we find it in transforming Tadpoles, whose tail has become a mere stump.

This is easily accounted for; in the Tadpole the small divided suctorial (lower labial) cartilage is carried by the mandibles—it is fixed between them; these are its *arms*. During transformation, the lower lip of the Lamprey shoots forwards, and instead of lying back, as it did, under the hood-like upper lip, grows to the forefront, and has the upper lip merely lying on the top of its upper rim in front; thus this production of the *post-oral* lip becomes the foremost part of the head.

Hence anything corresponding to mandibles in the Lamprey are carried far away from their *pier* or “suspensorium;” thus the hinge part of that pier is suppressed. The labials of the Lamprey correspond to the *temporary* labials of a Tadpole; the cartilages that appear in that region (above), during transformation, correspond to what is seen in the upper fore-face of a Shark or Skate.

The palato-quadrate arcade, with no *quadrate lobe*, and the distal cartilages attached to the suctorial disk, are all that can be accredited to the 1st visceral arch of the Lamprey. Its 2nd has no “pharyngo-hyal” element, but the lower part grows directly out of the back of the arrested suspensorium (part of the 1st arch); yet the lateral, sub-distal, and basal parts are well developed as the lingual skeleton. The only rudiment of an *intra-branchial*, behind the hyoid, is the hinder part of the large continuous basal bar (“lingual cartilage”); all the rest is *extra-visceral*, and after transformation the hyoid arch acquires an outer band of this nature. How the Myxinoids differ in these respects I have already shown, but their *intra-visceral* basket-work is dissociated from their branchial pouches, which are carried far back under the spine. Then, in their mouth, not circularly suctorial, as in the Lamprey, the dental armature, and its *special buccal skeleton*, is a huge development of parts, the like of which are feeble and subsidiary in the Lamprey.

The Myxinoids do transform beyond the Ammocetine stage, but they appear to have suffered some deflection during the process, and to have been stopped in their attempts

to rise to a higher platform; yet, full of metamorphic force, they have spent their energy on the old low level; they are, as it were, highly modified Ammocœtes, doomed to much morphological arrest, and to some degree of degradation of parts, once promising a higher development.

A study of their development will show whether these suggestions are true or untrue.

## LIST OF ABBREVIATIONS.

N.B.—Many of the abbreviations are the same as in Part I. ; the following are additional.

<i>ao.</i>	Aorta.	<i>l.lp.</i>	Lower lip.
<i>al.s.</i>	Alisphenoid.	<i>l.t.</i>	Lingual (and labial) teeth.
<i>b.p.</i>	Buccal pouch.	<i>m.d.m.</i>	Median distal mandibular.
<i>br.a.</i>	Branchial artery.	<i>n.a.</i> (and <i>v.a.</i> )	Neural (or vertebral) arch.
<i>br.c.</i>	Branchial canal.	<i>or.m.</i>	Orbital muscles.
<i>br.p'.</i>	Branchial folds.	<i>o.s.</i>	Orbito-sphenoid.
<i>c.tr.</i>	Cornu trabeculæ.	<i>o.s.f.</i>	Orbito-sphenoidal fenestra.
<i>e.ba.</i>	External branchial aperture.	<i>py.</i>	Pituitary space.
<i>ex.br.</i>	Extra-branchial.	<i>s.d.</i>	Sucking disk.
<i>ex.hy.</i>	Extra-hyal.	<i>tg.</i>	Tongue.
<i>i.b.a.</i>	Internal branchial opening.	<i>th.</i>	Thyroid body.
<i>i.v.s.</i>	Intervelar shelf.	<i>u.l.</i>	Upper labial.
<i>l.d.m.</i>	Lateral distal mandibular.	<i>u.lp.</i>	Upper lip.
<i>l.l.</i>	Lower labial.	<i>v.a.</i> (and <i>n.a.</i> )	Vertebral (or neural) arch.

## DESCRIPTION OF THE PLATES.




Plate.	Fig.		Number of times magnified.
18	1	<i>Petromyzon marinus</i> ; one-third grown; cranio-branchial skeleton; side view . . . . .	$3\frac{1}{5}$
„	2	The same; lower view . . . . .	$3\frac{1}{5}$
„	3	Fore part of same; upper view . . . . .	$3\frac{1}{5}$
„	4	The same; lower view . . . . .	$3\frac{1}{5}$
„	5	Vertical section of the same object . . . . .	$3\frac{1}{5}$
„	6	Lingual cartilage of the same specimen; lower view .	$6\frac{2}{5}$
„	7	The same; upper view . . . . .	$6\frac{2}{5}$
„	8	Part of the same; side view . . . . .	$6\frac{2}{5}$
19	1	<i>Petromyzon marinus</i> ; recently metamorphosed (5 inches long); skull; upper view . . . . .	12
„	2	The same; lower view . . . . .	12
„	3	The same (section); inner view . . . . .	12
„	4	<i>Petromyzon fluviatilis</i> ; large larva (6 inches long); skull; lower view . . . . .	15
„	5	The same; upper view . . . . .	15
„	6	<i>P. fluviatilis</i> ; a younger larva, but of nearly the same size; <i>first</i> of a series of vertically-transverse sections through fore part . . . . .	12
„	7	The same; <i>second</i> section . . . . .	12
20	1	<i>Petromyzon fluviatilis</i> (adult); <i>first</i> of a series of vertically-transverse, thin, transparent sections . . . .	5
„	2	The same; <i>second</i> section . . . . .	5
„	3	The same; <i>third</i> section. . . . .	5
„	4	The same; <i>fourth</i> section . . . . .	5
„	5	The same; <i>fifth</i> section . . . . .	5
„	6	The same; <i>sixth</i> section . . . . .	5
„	7	The same; <i>seventh</i> section . . . . .	5
„	8	The same; <i>eighth</i> section . . . . .	5
„	9	The same; <i>ninth</i> section . . . . .	5
„	10	The same; <i>tenth</i> section. . . . .	5
„	11	The same; <i>eleventh</i> section . . . . .	5
„	12	The same; <i>twelfth</i> section . . . . .	5

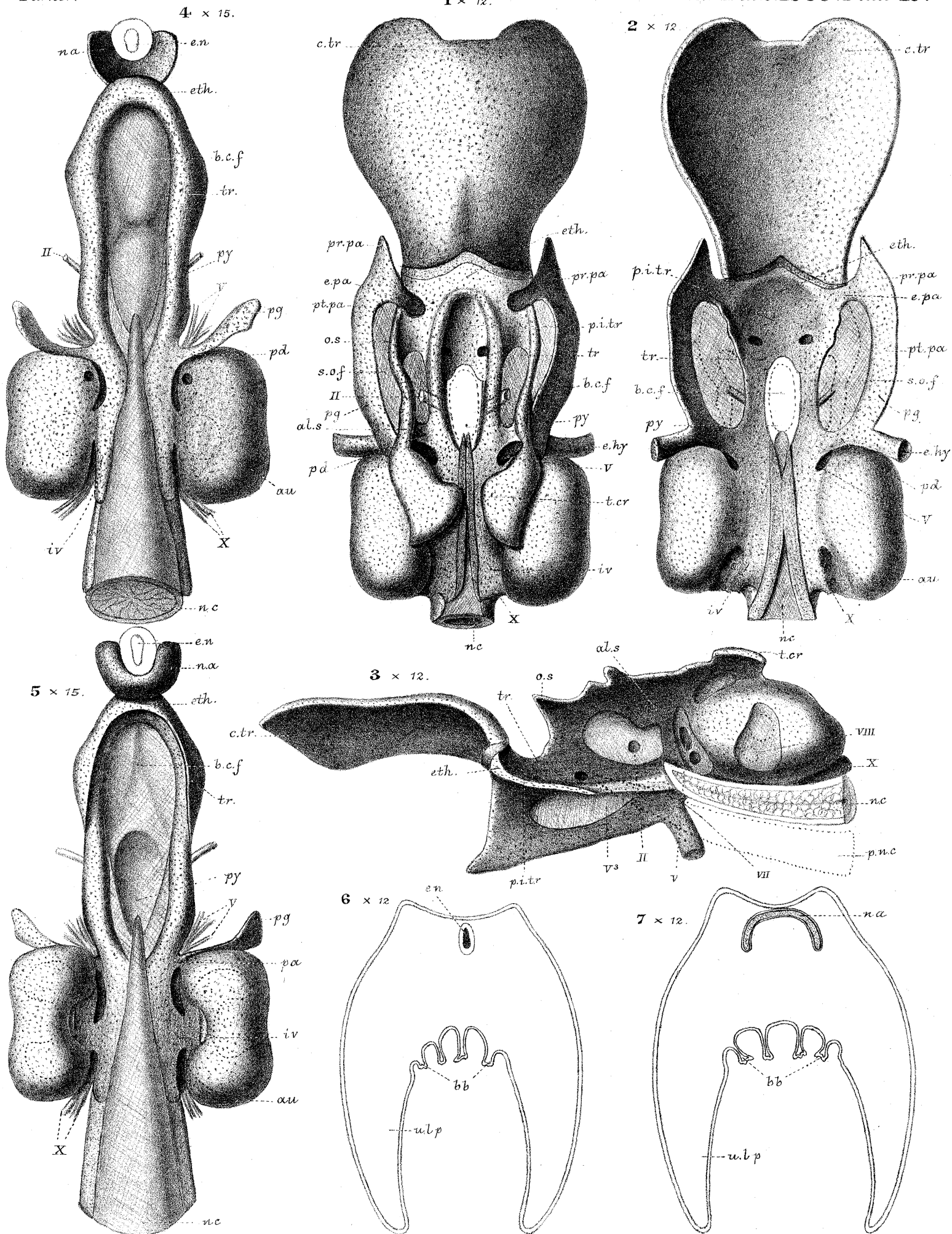


Plate.	Fig.		Number of times magnified.
21	..	(As in last Plate.)	
„	1	The same; <i>thirteenth</i> section . . . . .	5
„	2	The same; <i>fourteenth</i> section . . . . .	5
„	3	The same; <i>fifteenth</i> section. . . . .	5
„	4	The same; <i>sixteenth</i> section . . . . .	5
„	5	The same; <i>seventeenth</i> section . . . . .	5
„	6	The same; <i>eighteenth</i> section . . . . .	5
„	7	The same; <i>nineteenth</i> section . . . . .	5
„	8	The same; <i>twentieth</i> section . . . . .	5
„	9	The same; <i>twenty-first</i> section. . . . .	5
22	..	(As in last Plate.)	
„	1	The same; <i>twenty-second</i> section . . . . .	5
„	2	The same; <i>twenty-third</i> section . . . . .	5
„	3	The same; <i>twenty-fourth</i> section . . . . .	5
„	4	The same; <i>twenty-fifth</i> section . . . . .	5
„	5	The same; <i>twenty-sixth</i> section . . . . .	5
„	6	The same; <i>twenty-seventh</i> section. . . . .	5
„	7	The same; <i>twenty-eighth</i> section . . . . .	5
„	8	The same; <i>twenty-ninth</i> section . . . . .	5
„	9	The same; <i>thirtieth</i> section. . . . .	5
23	1	<i>Petromyzon fluviatilis</i> (adult); solid vertical section of fore part . . . . .	2½
„	2	The same; solid horizontal section of head. . . . .	2½
„	3	The same; another similar section made on a higher plane . . . . .	2½
„	4	<i>Thirty-first thin</i> section (as in Plates 20–22) . . . . .	5
„	5	<i>First</i> similar solid section of a larger specimen . . . . .	3
„	6	The same; <i>second</i> section . . . . .	3
„	7	The same; <i>third</i> section. . . . .	3
„	8	<i>Petromyzon fluviatilis</i> (larva, 6 inches long); <i>thirteenth</i> section (as in Plate 26) . . . . .	12
„	9	The same; <i>fourteenth</i> section . . . . .	12

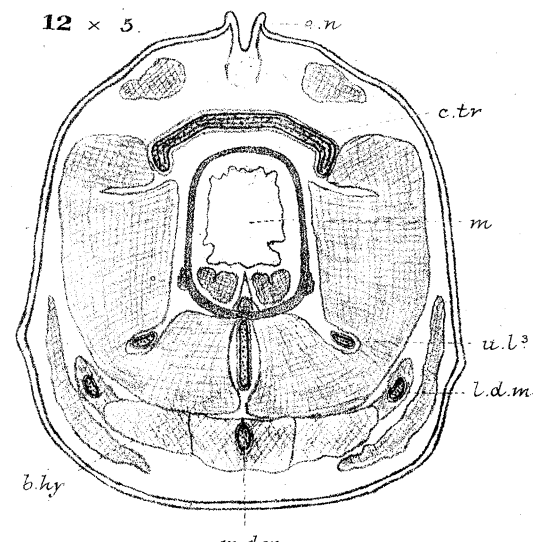
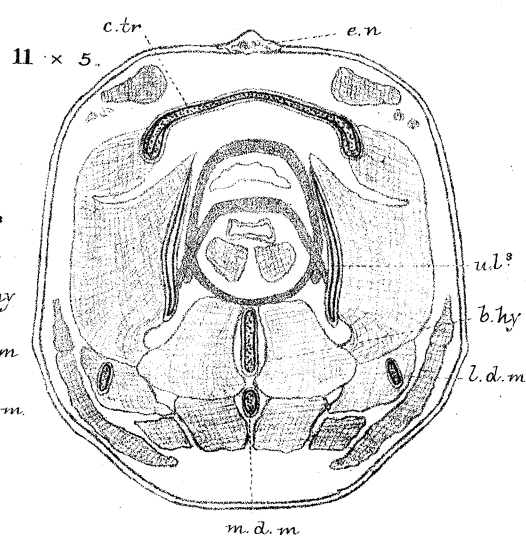
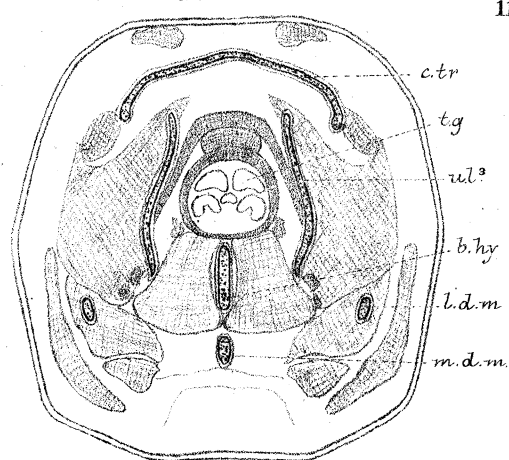
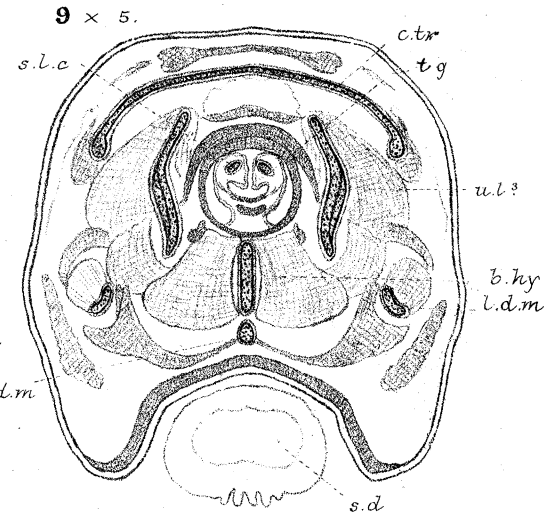
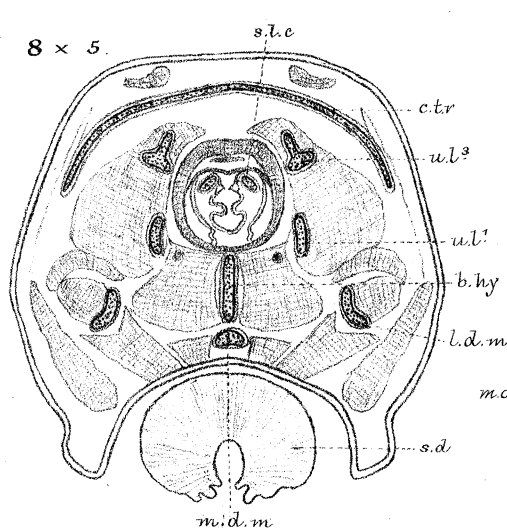
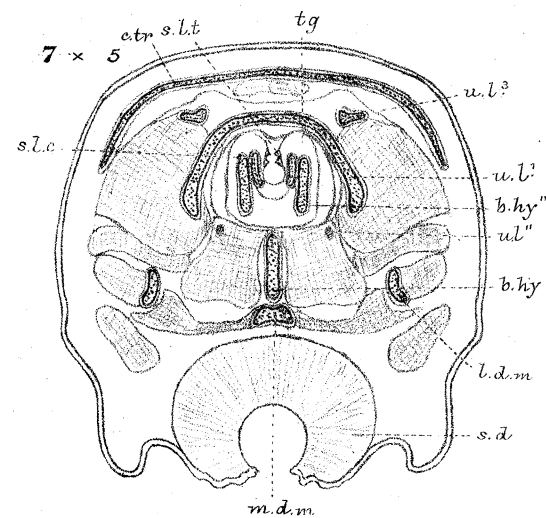
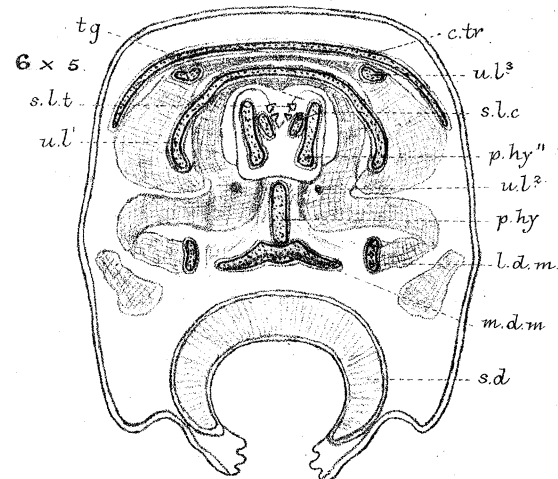
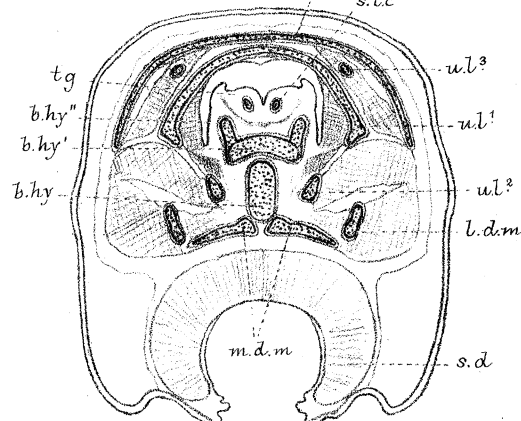
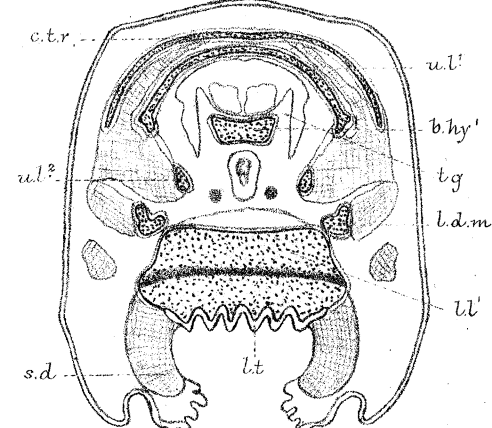
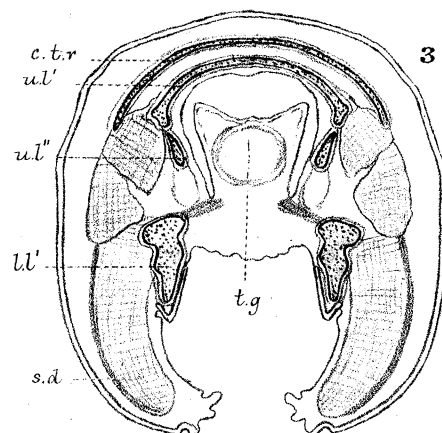
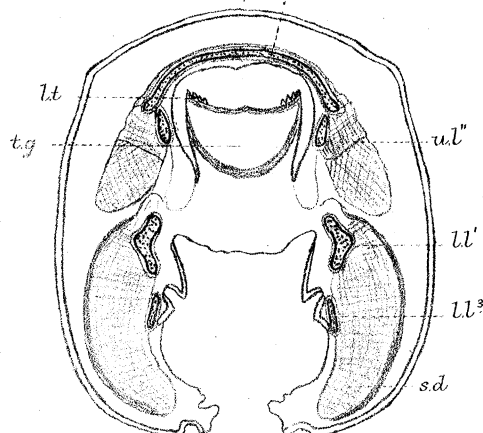
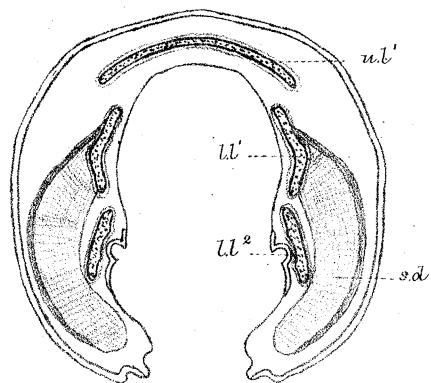
Plate.	Fig.		Number of times magnified.
24	1	<i>Petromyzon planeri</i> (embryo, 9·5 millims. long); <i>first</i> of a series of vertically-transverse sections of cephalic and branchial regions . . . . .	150
„	1A	Part of a similar section of an embryo 7·8 millims. long . . . . .	300
„	2	<i>Second</i> section of larger embryo . . . . .	150
„	2A	A similar section of smaller embryo . . . . .	300
„	3	<i>Third</i> section of larger embryo . . . . .	150
„	4	The same; <i>fourth</i> section . . . . .	150
„	5	The same; <i>fifth</i> section . . . . .	150
„	6	The same; <i>sixth</i> section . . . . .	150
„	7	The same; <i>seventh</i> section . . . . .	150
„	8	The same; <i>eighth</i> section . . . . .	150
„	9	The same; <i>ninth</i> section . . . . .	150
25	..	( <i>Partly as in last Plate.</i> )	
„	1	Part of the same section as in Plate 24, fig. 5. . . . .	300
„	2	Another partial section from the same series between figs. 5 and 6 of Plate 24 . . . . .	300
„	3	Another partial section between figs. 7 and 8 of Plate 24 . . . . .	300
„	4	A similar section near fig. 9, Plate 24 . . . . .	300
„	5	Same series; a complete section through branchial region and thyroid body . . . . .	150
„	6	Part of last section . . . . .	300
„	7	Skull of smaller embryo (7·8 millims. long) of <i>P. planeri</i> ; lower view . . . . .	150
„	8	<i>Petromyzon fluviatilis</i> (larva, 6 inches long); dissection of branchial region; side view . . . . .	5
„	9	Part of same; lower view . . . . .	5
„	10	The same; vertical solid section of head and branchial region . . . . .	5

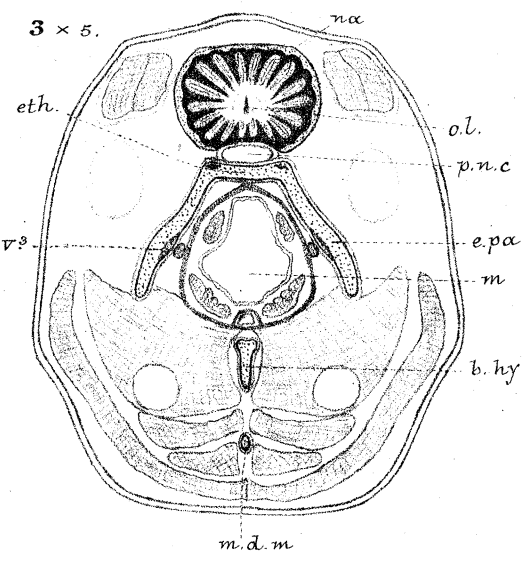
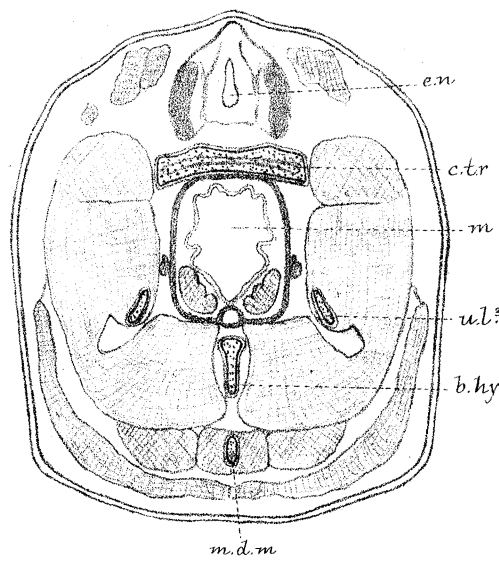
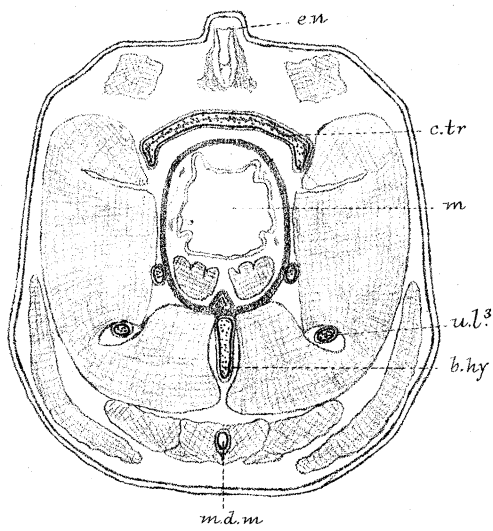
Plate.	Fig.		Number of times magnified.
26	..	<i>Petromyzon fluviatilis</i> (larva, 6 inches long)	
„	1	<i>Third</i> of a series of thin vertically-transverse sections through head and branchial region . . . . .	12
„	2	The same; <i>fourth</i> section . . . . .	12
„	3	The same; <i>fifth</i> section . . . . .	12
„	4	The same; <i>sixth</i> section . . . . .	12
„	5	The same; <i>seventh</i> section . . . . .	12
„	6	The same; <i>eighth</i> section . . . . .	12
„	7	The same; <i>ninth</i> section. . . . .	12
„	8	The same; <i>tenth</i> section. . . . .	12
„	9	The same; <i>eleventh</i> section. . . . .	12
„	10	The same; <i>twelfth</i> section . . . . .	12
„	11	The same; <i>fifteenth</i> section. . . . .	12
„	12	The same; <i>sixteenth</i> section . . . . .	12
„	13	The same; <i>seventeenth</i> section. . . . .	12



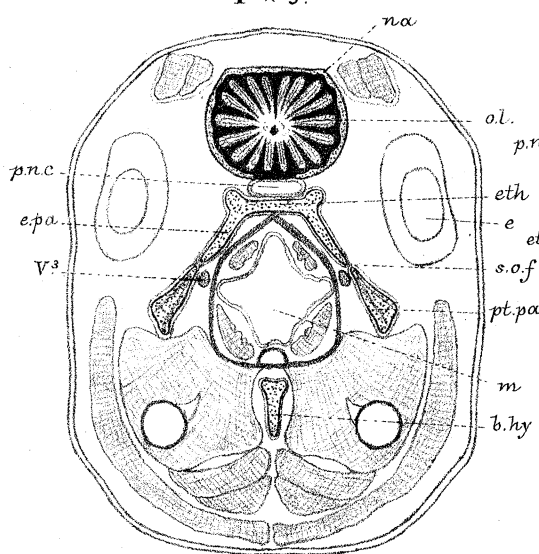




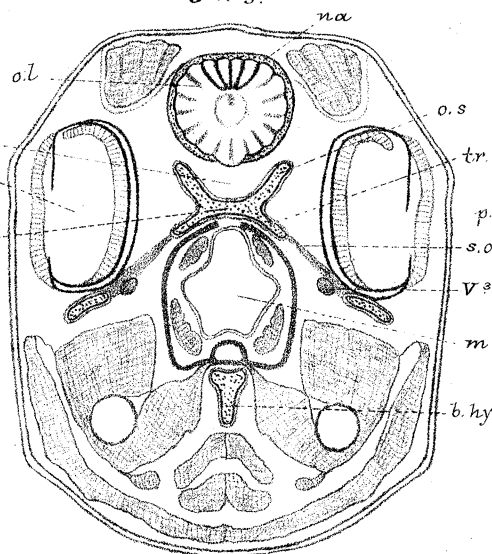




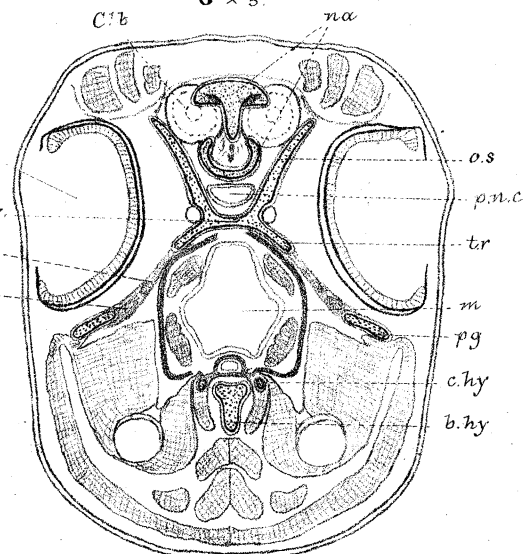
4 × 5.



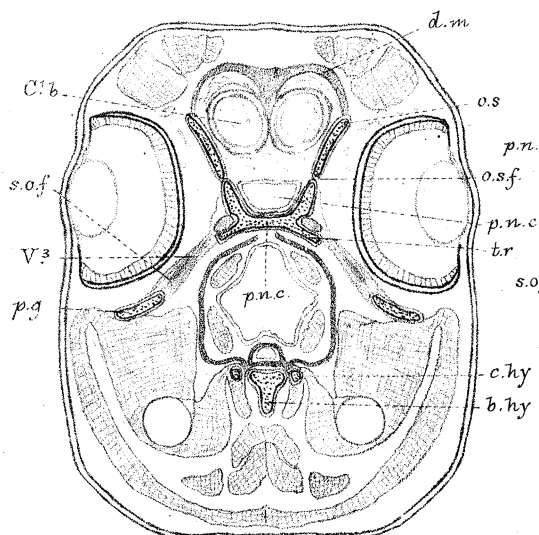
5 × 5.



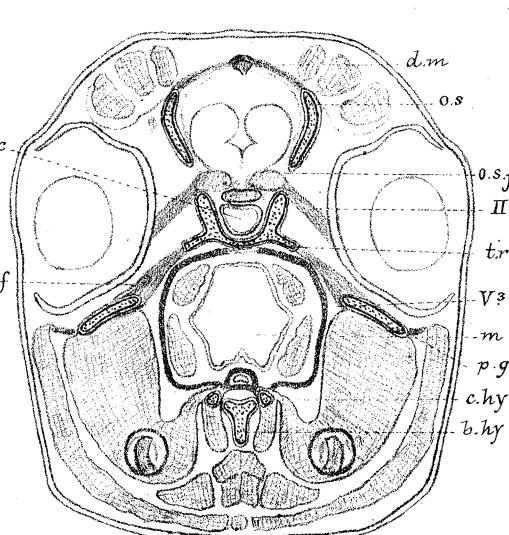
6 × 5.



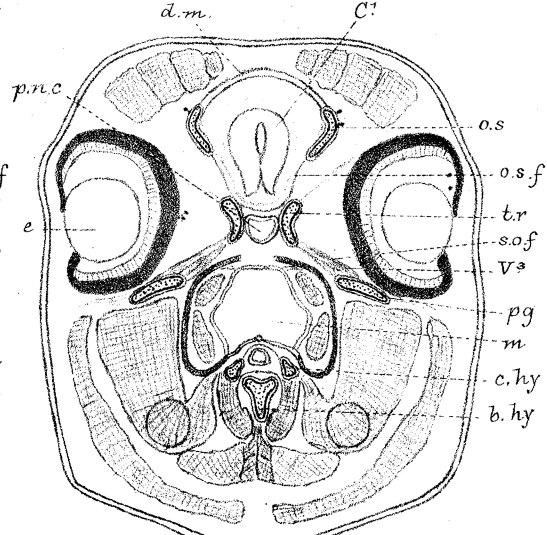
7 × 5.

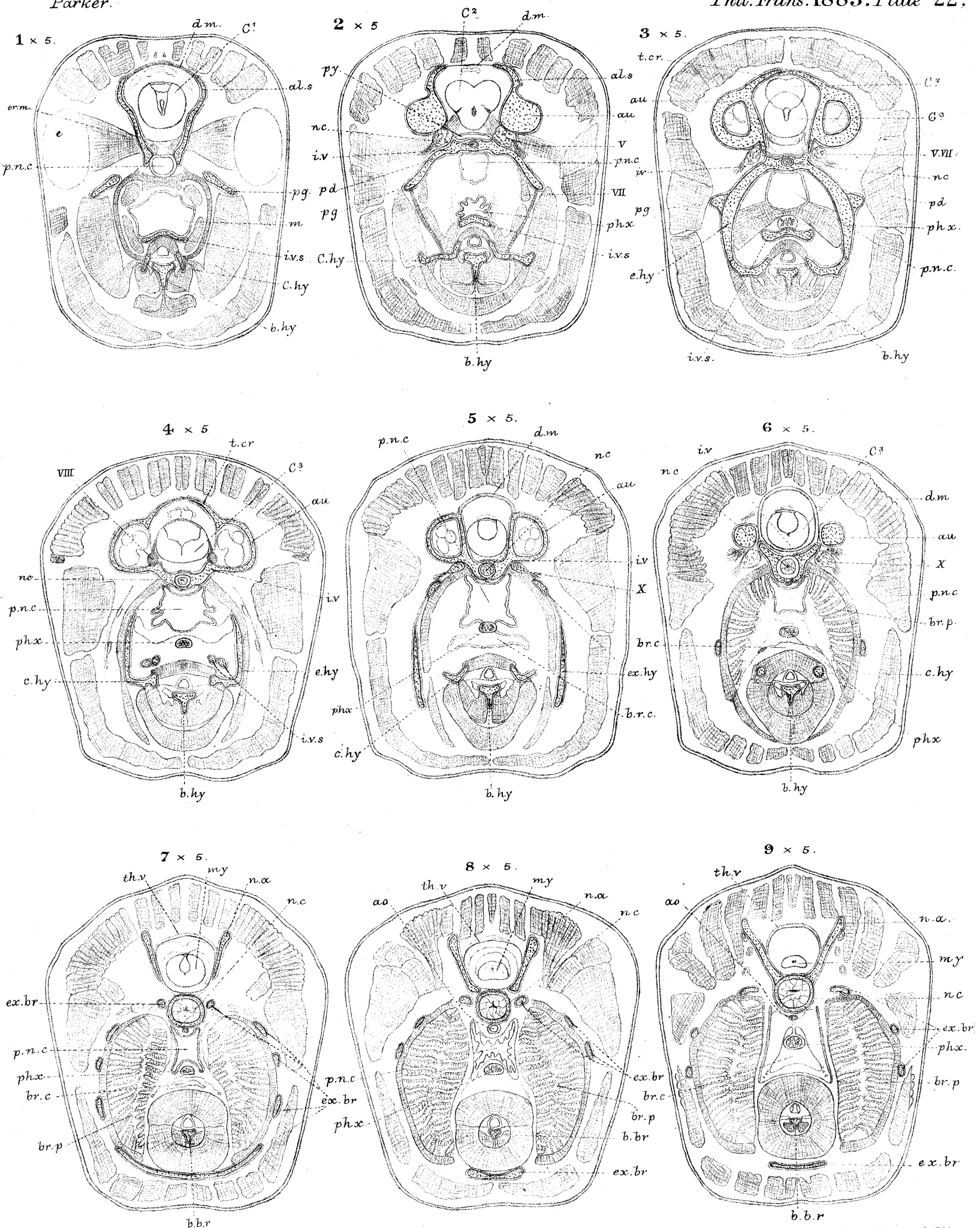


8 × 5.

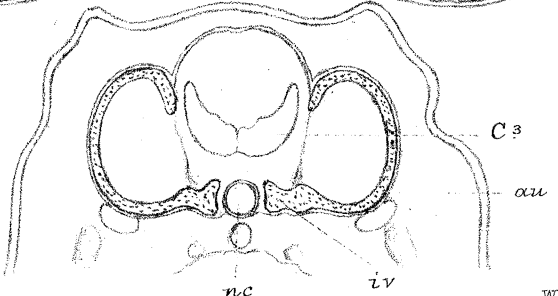
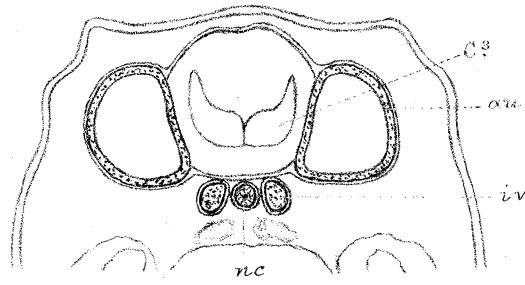
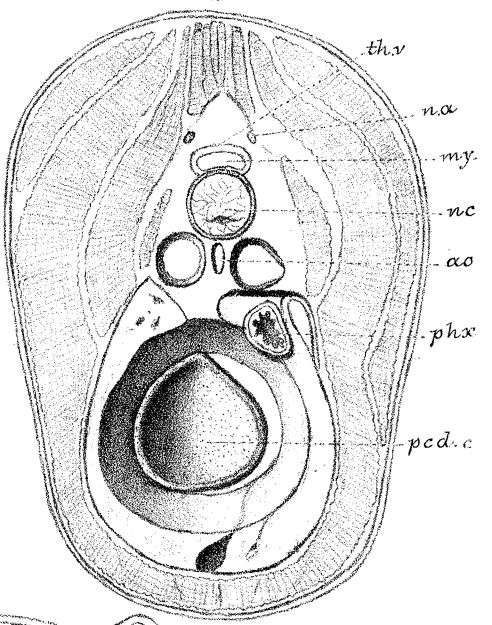
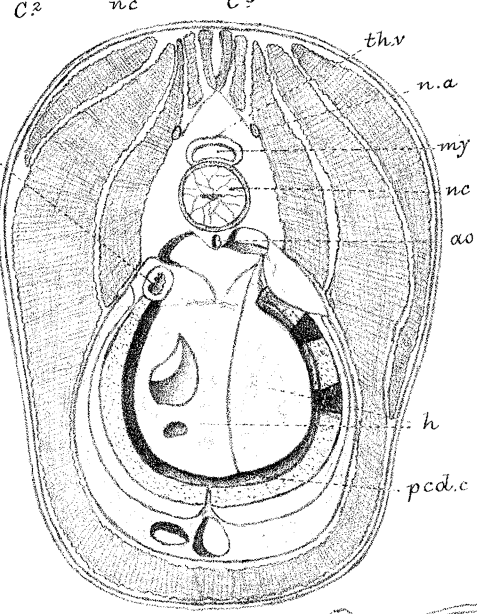
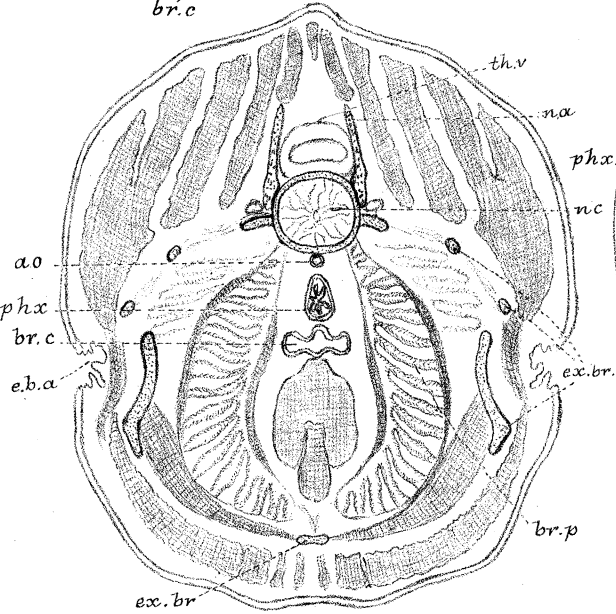
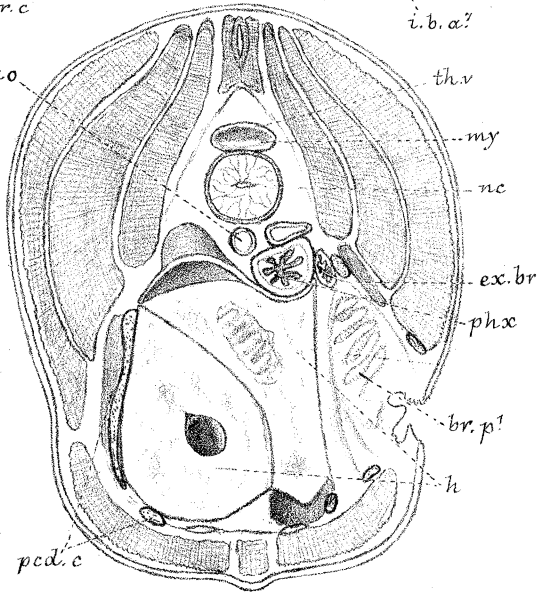
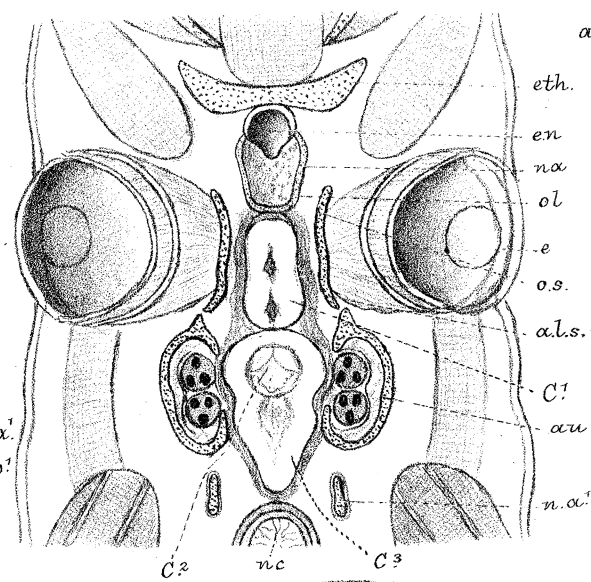
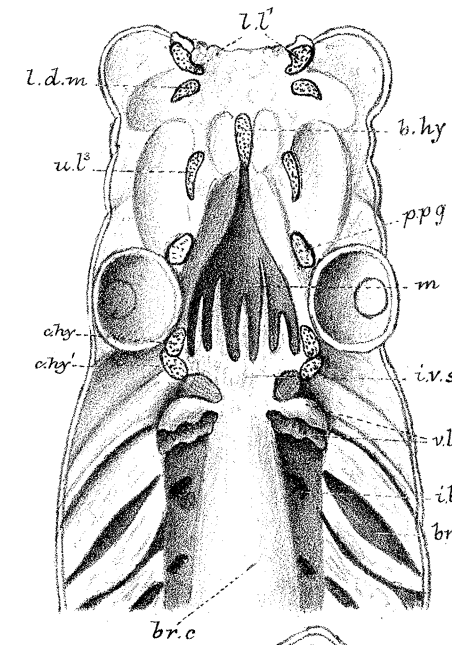
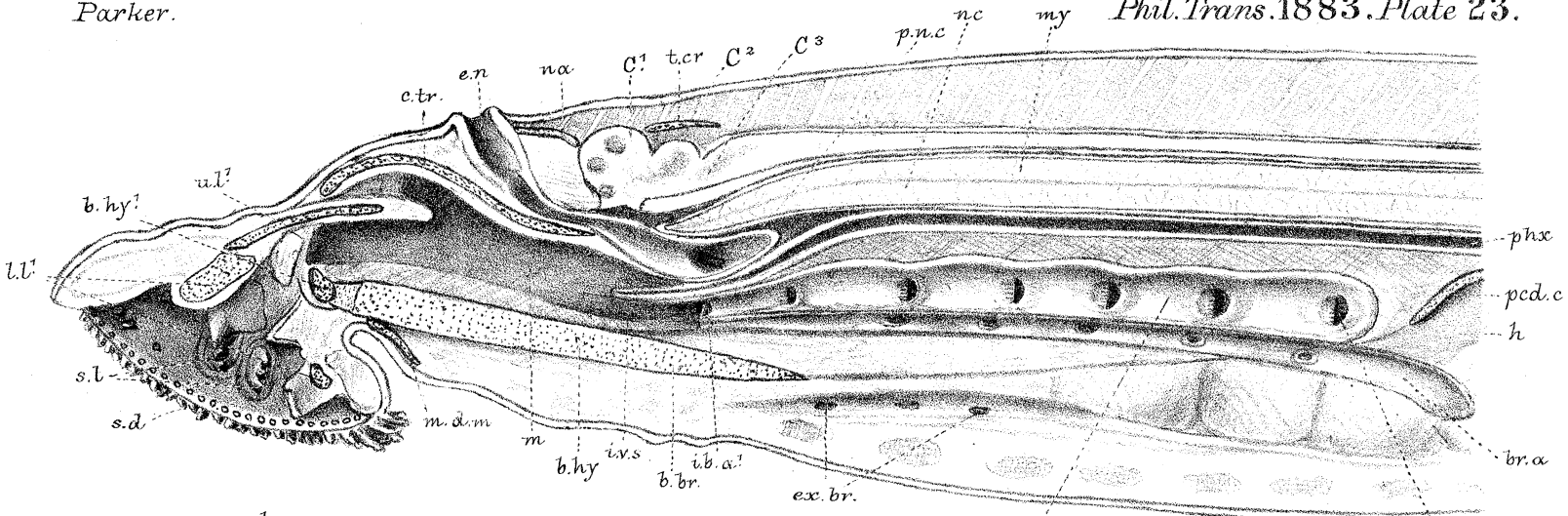


9 × 5.





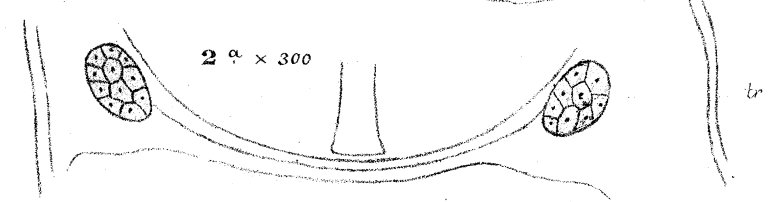
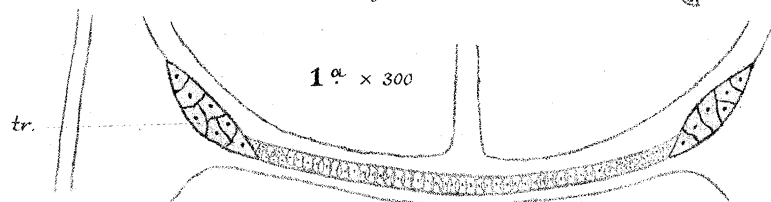
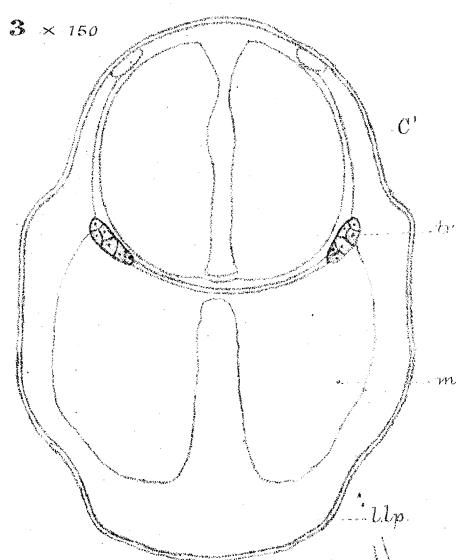
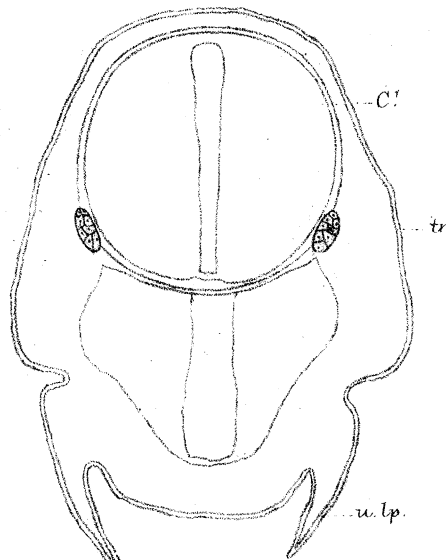
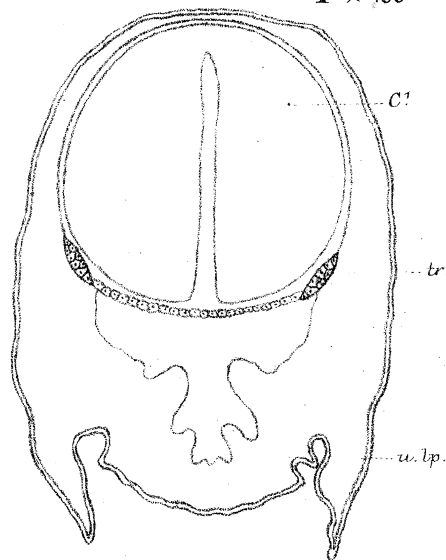




1 × 150

2 × 150

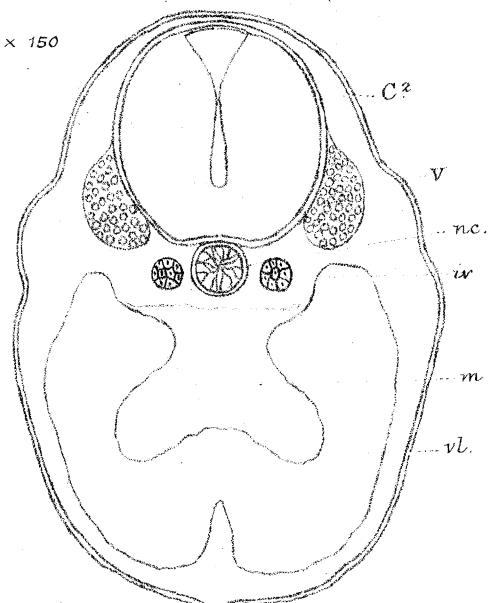
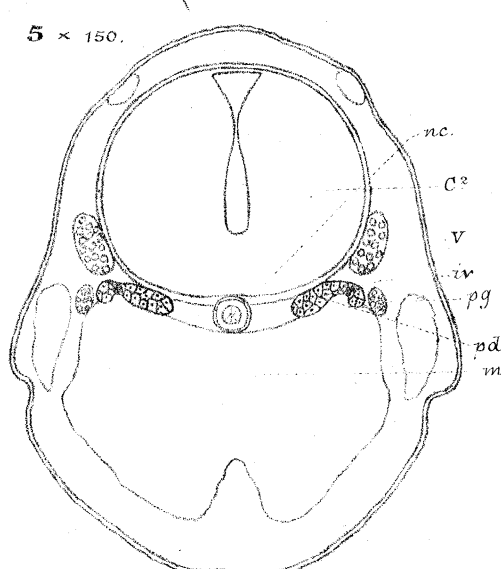
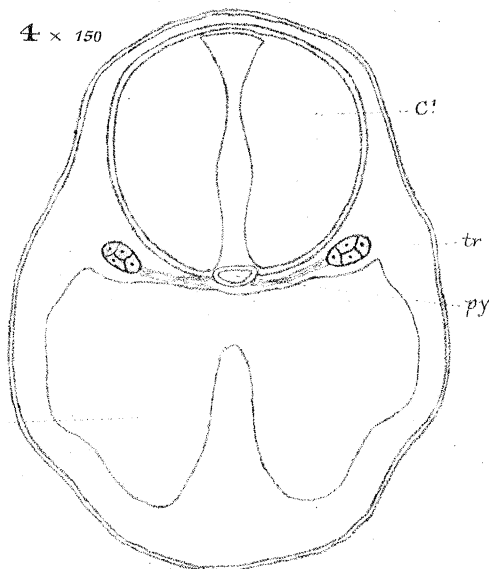
3 × 150



4 × 150

5 × 150.

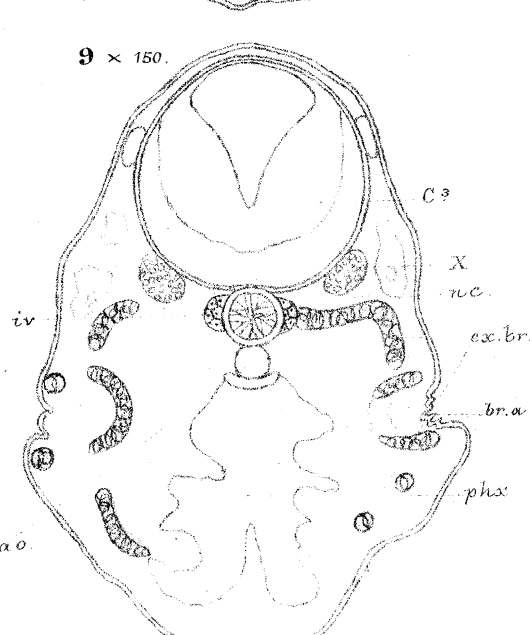
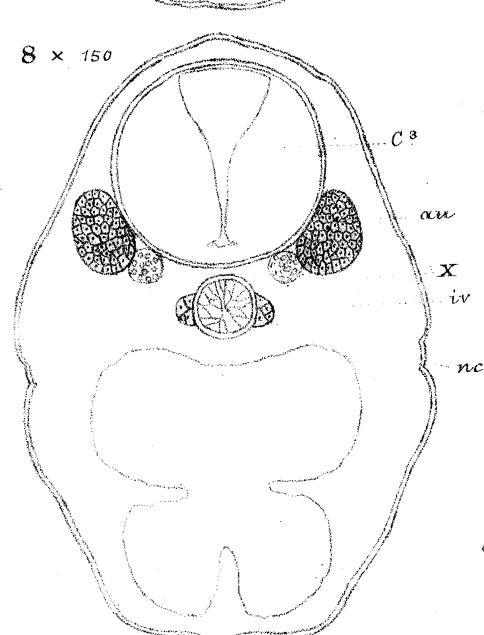
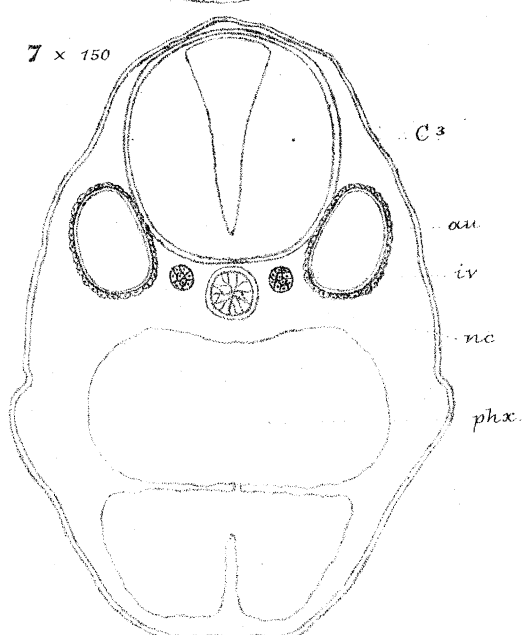
6 × 150

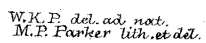


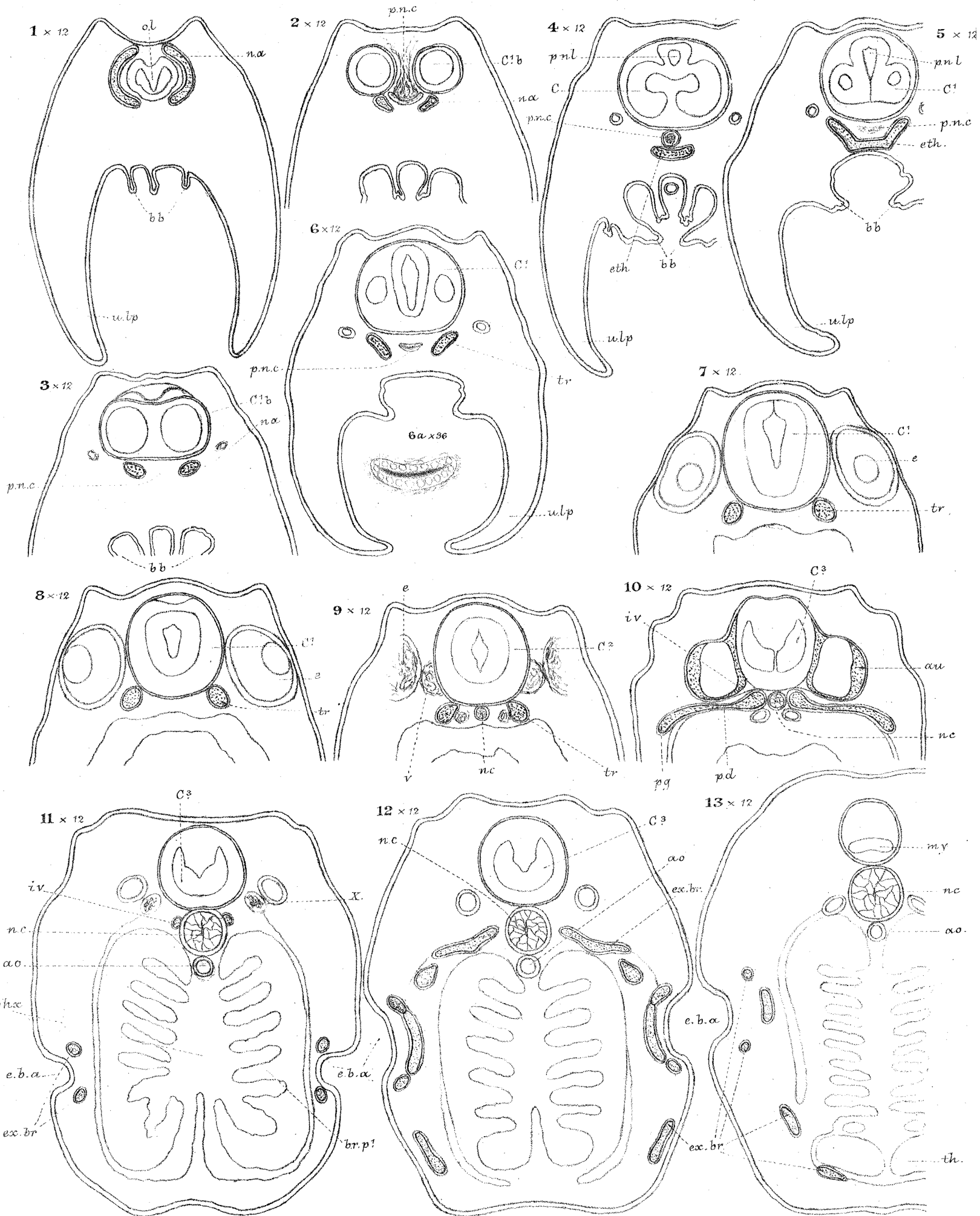
7 × 150

8 × 150

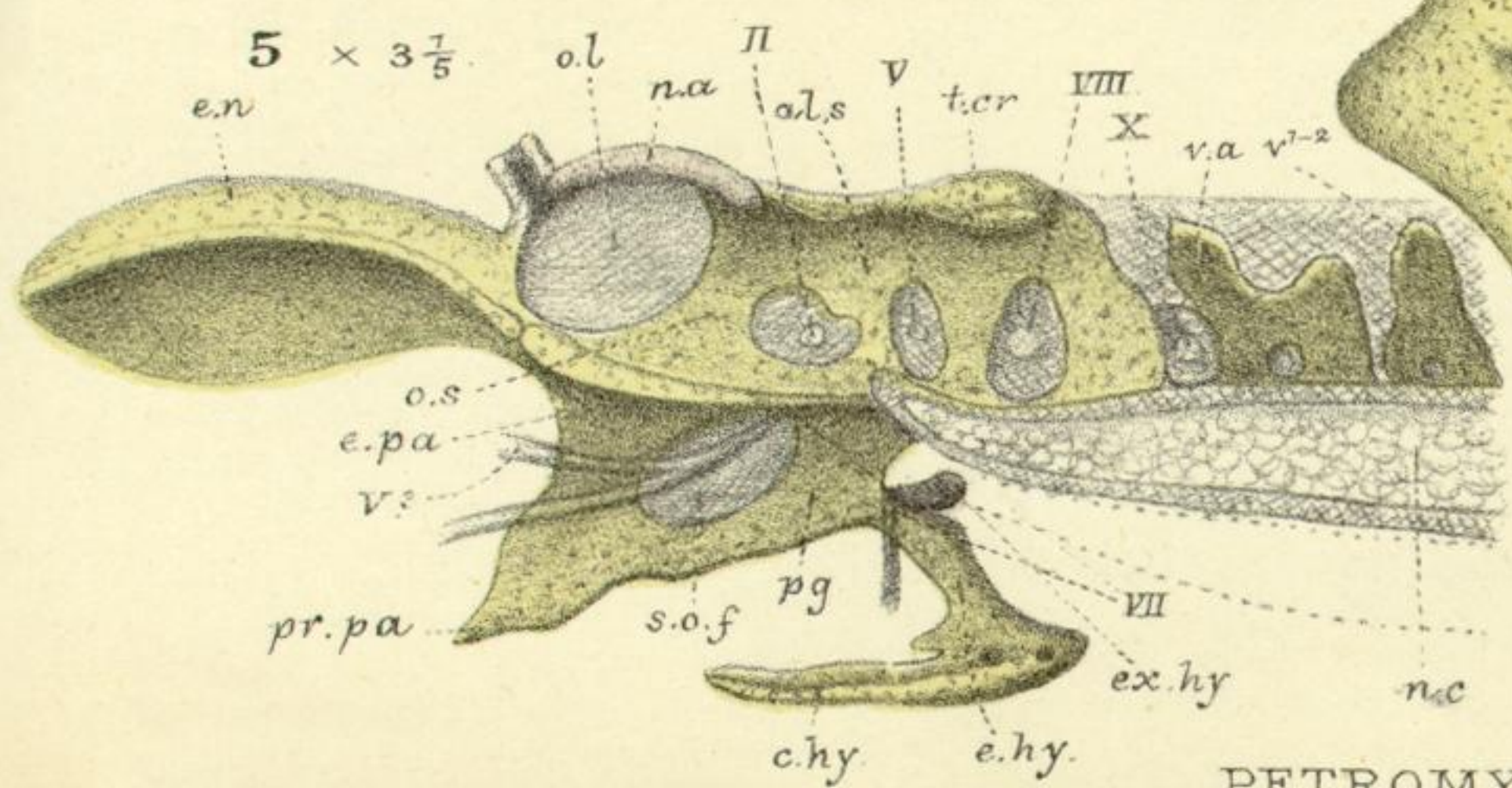
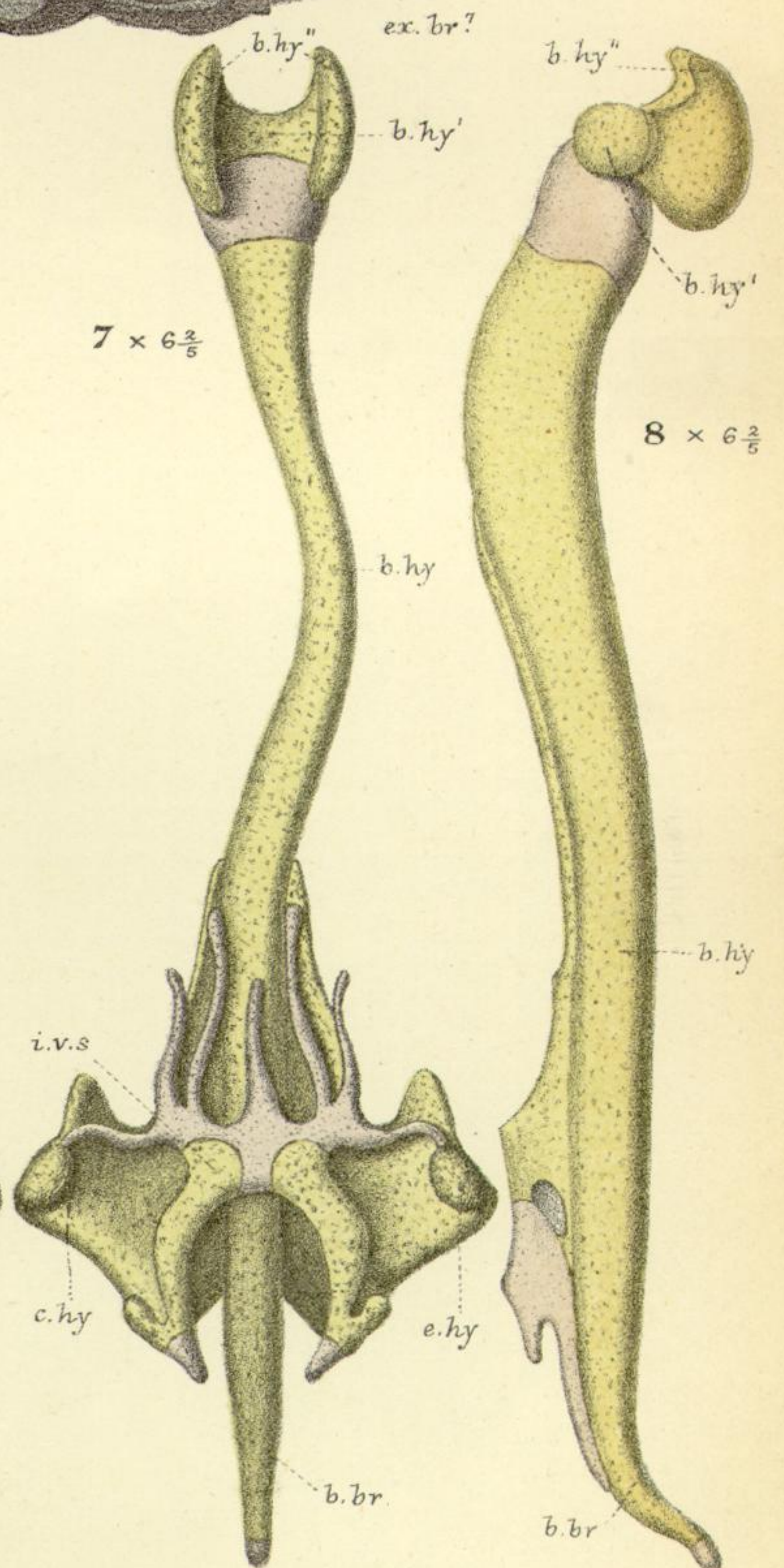
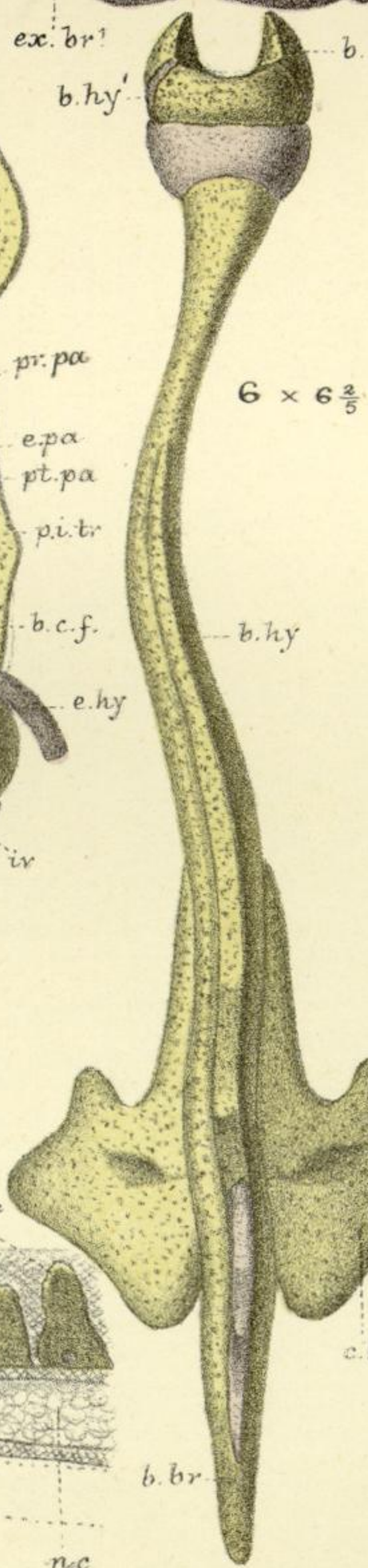
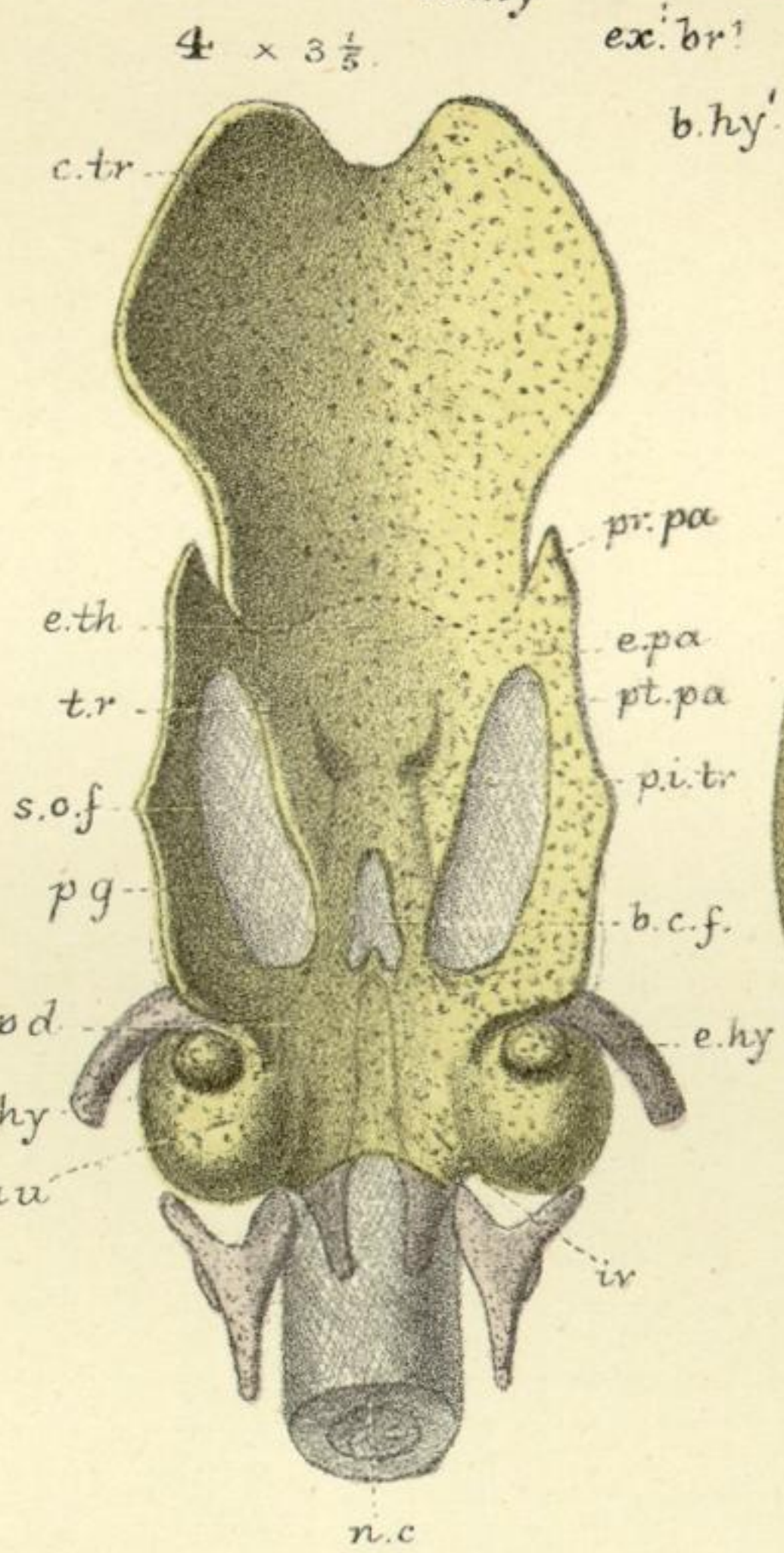
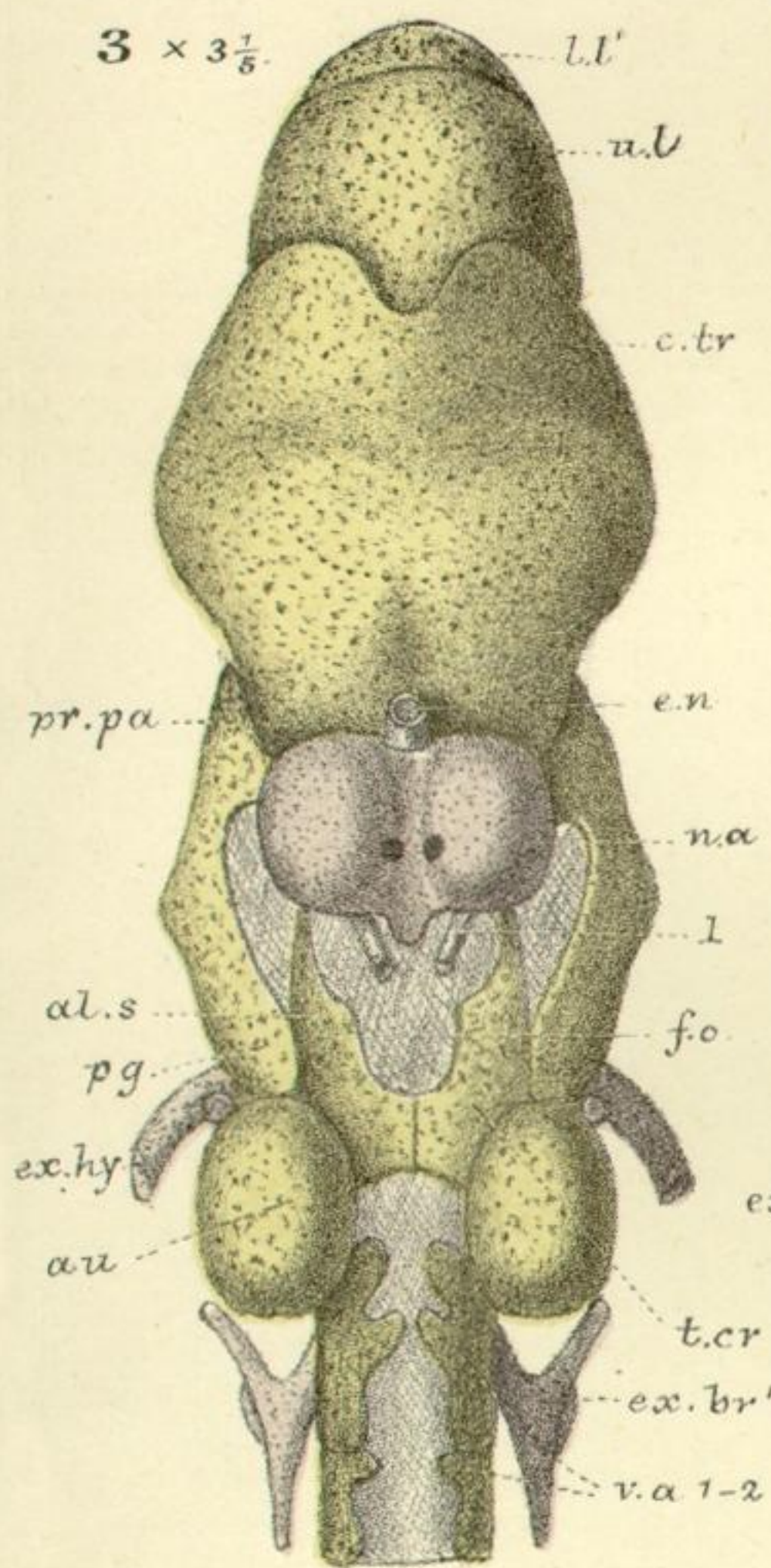
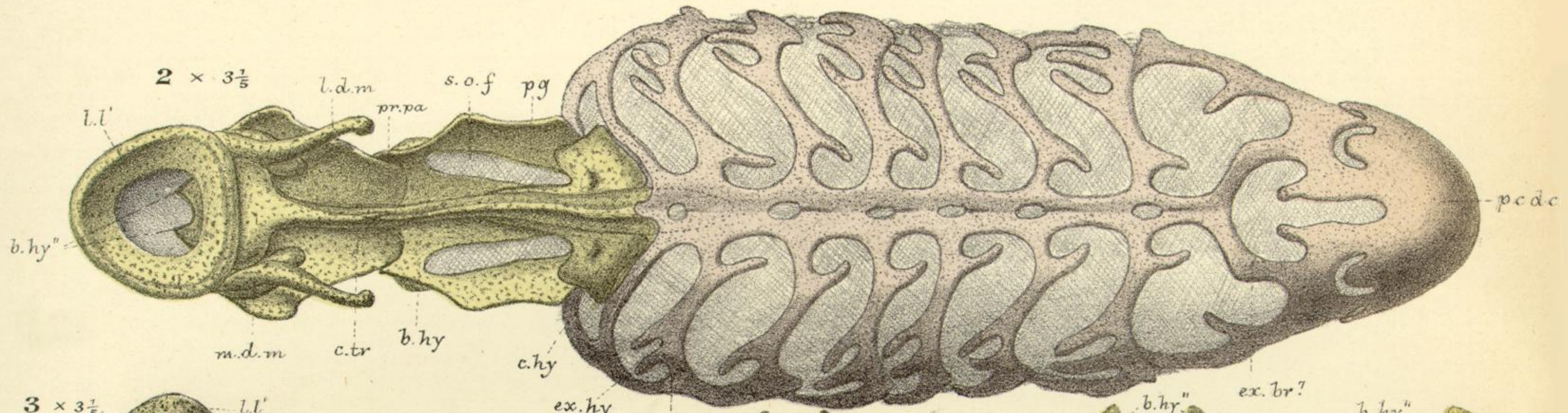
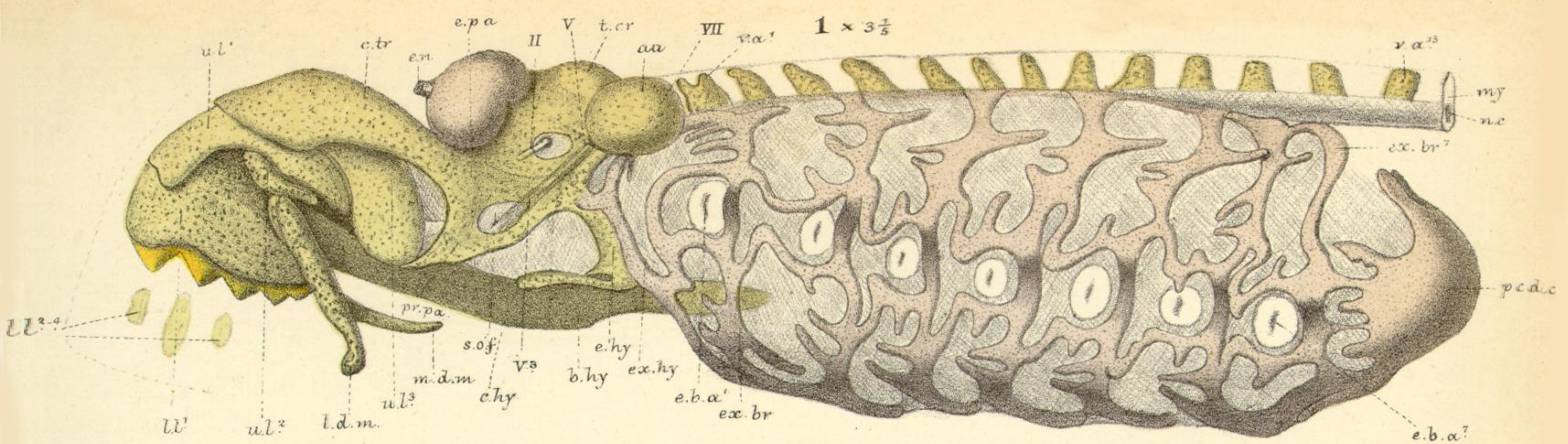
9 × 150.



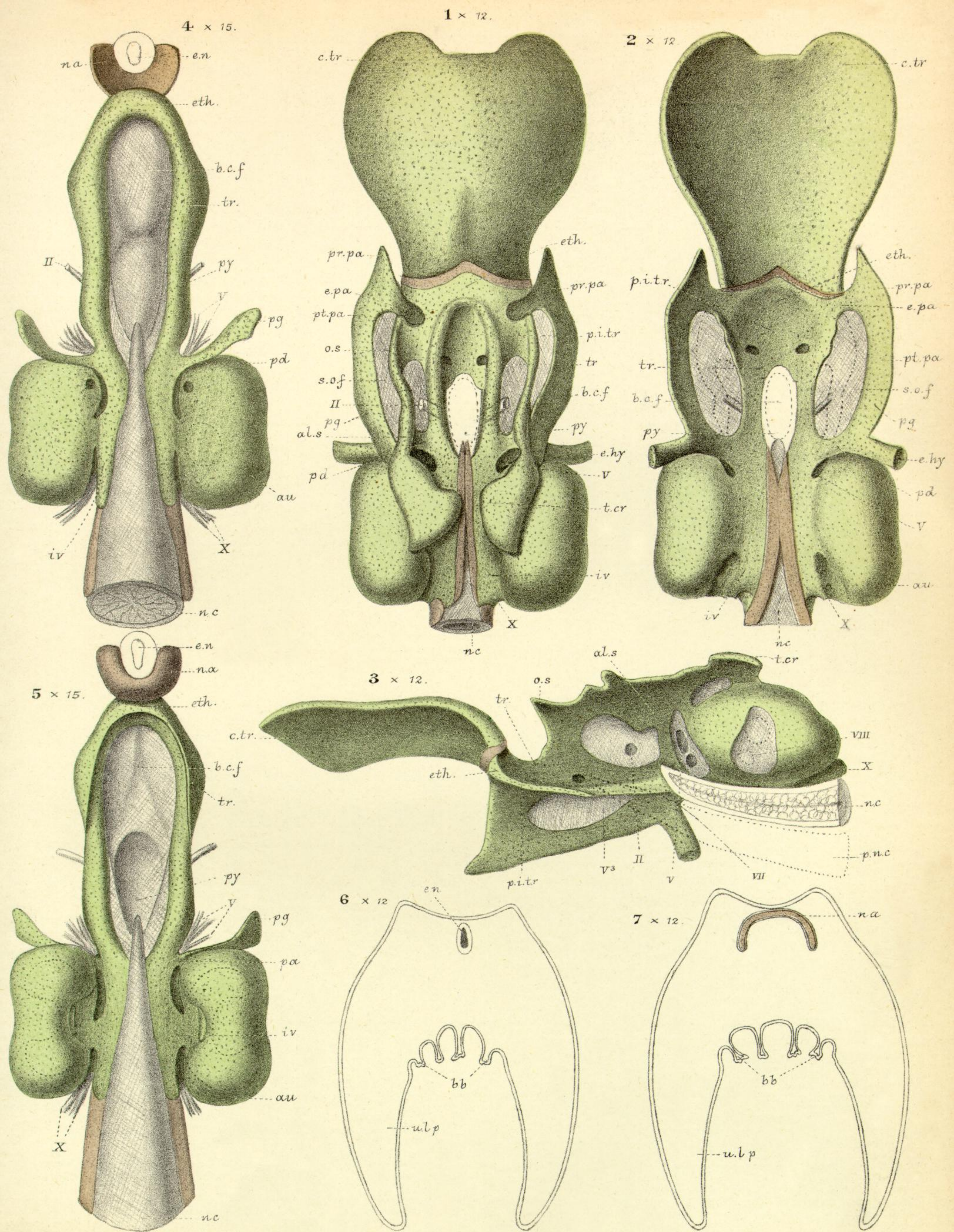






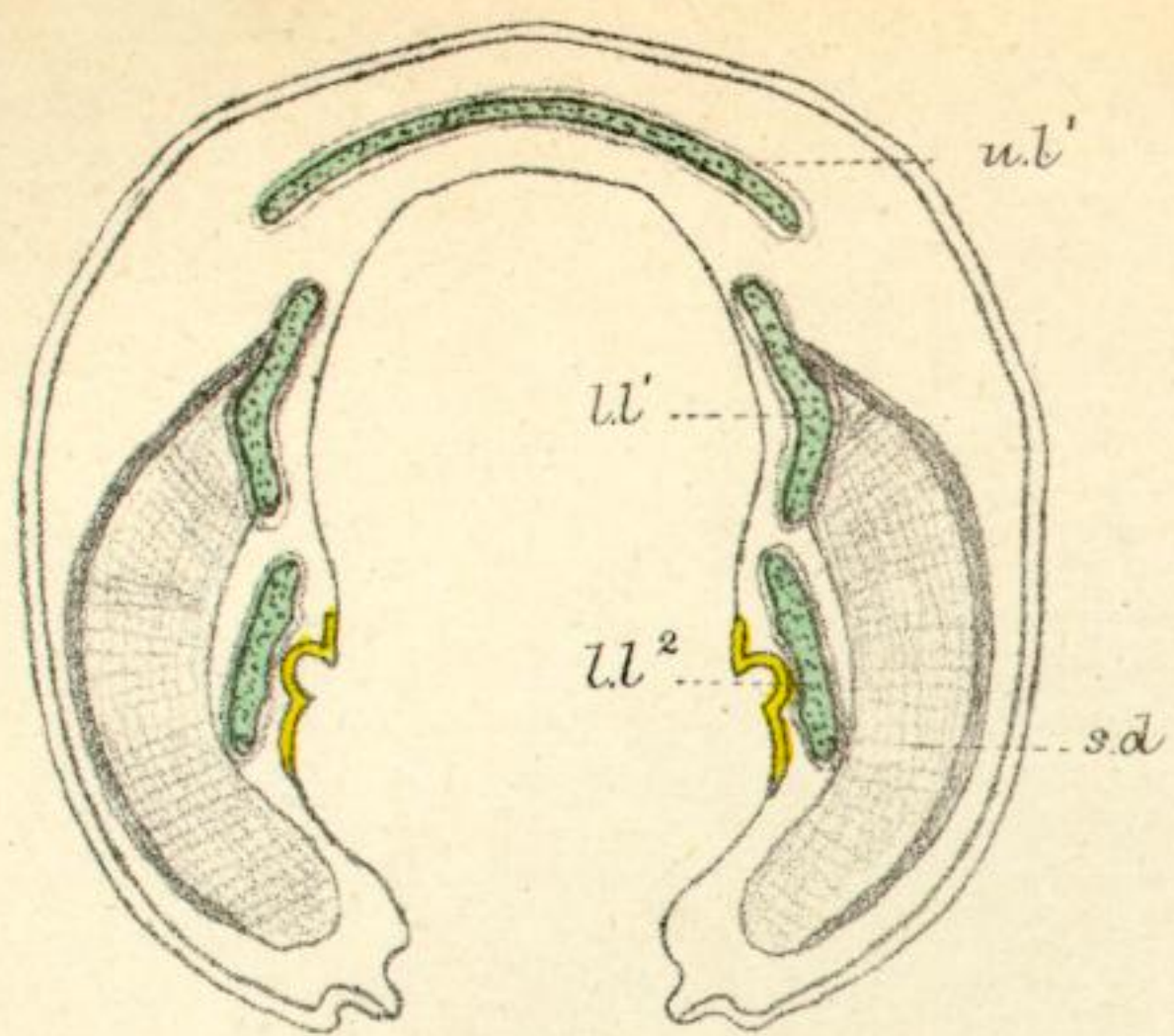




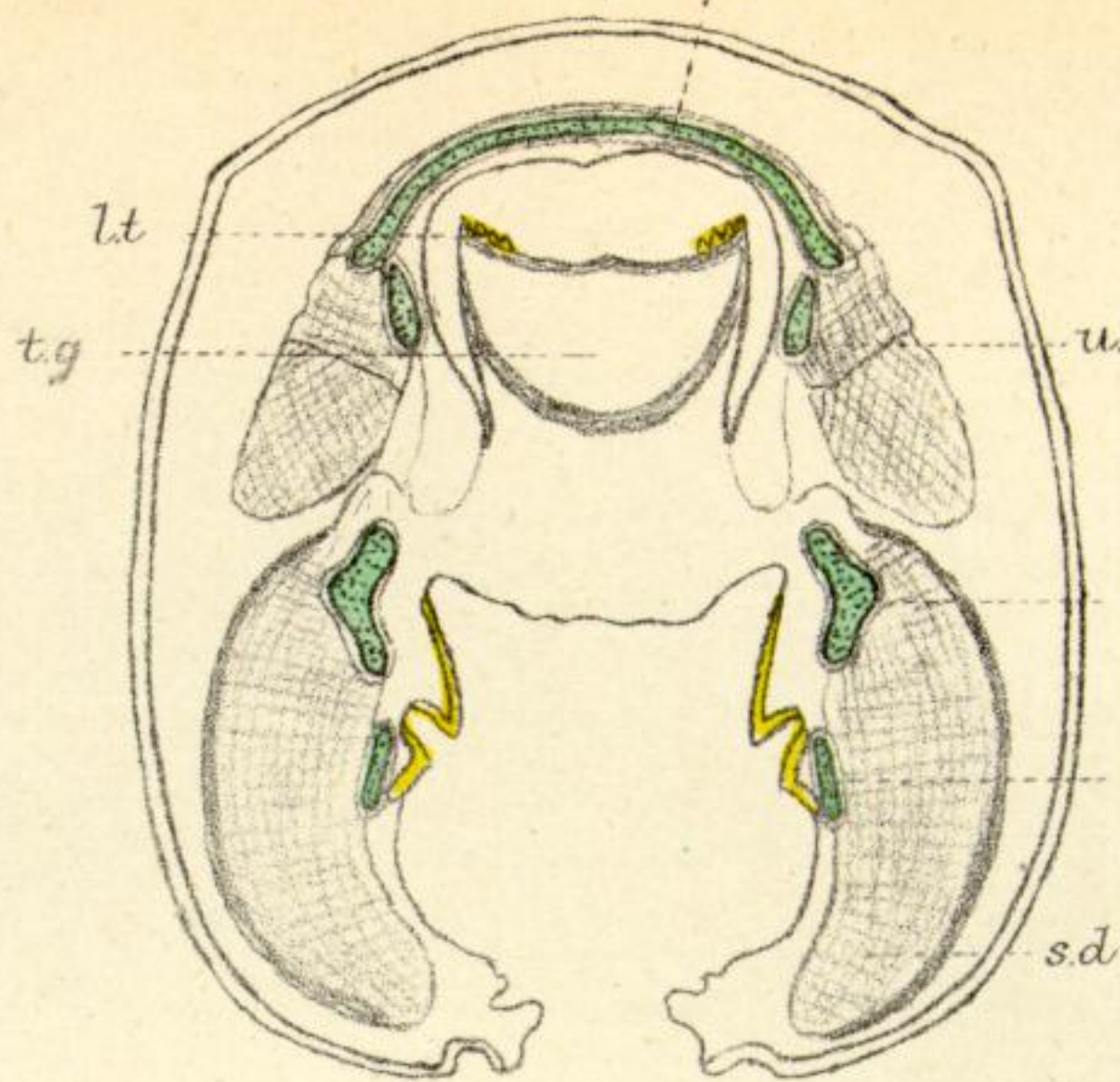




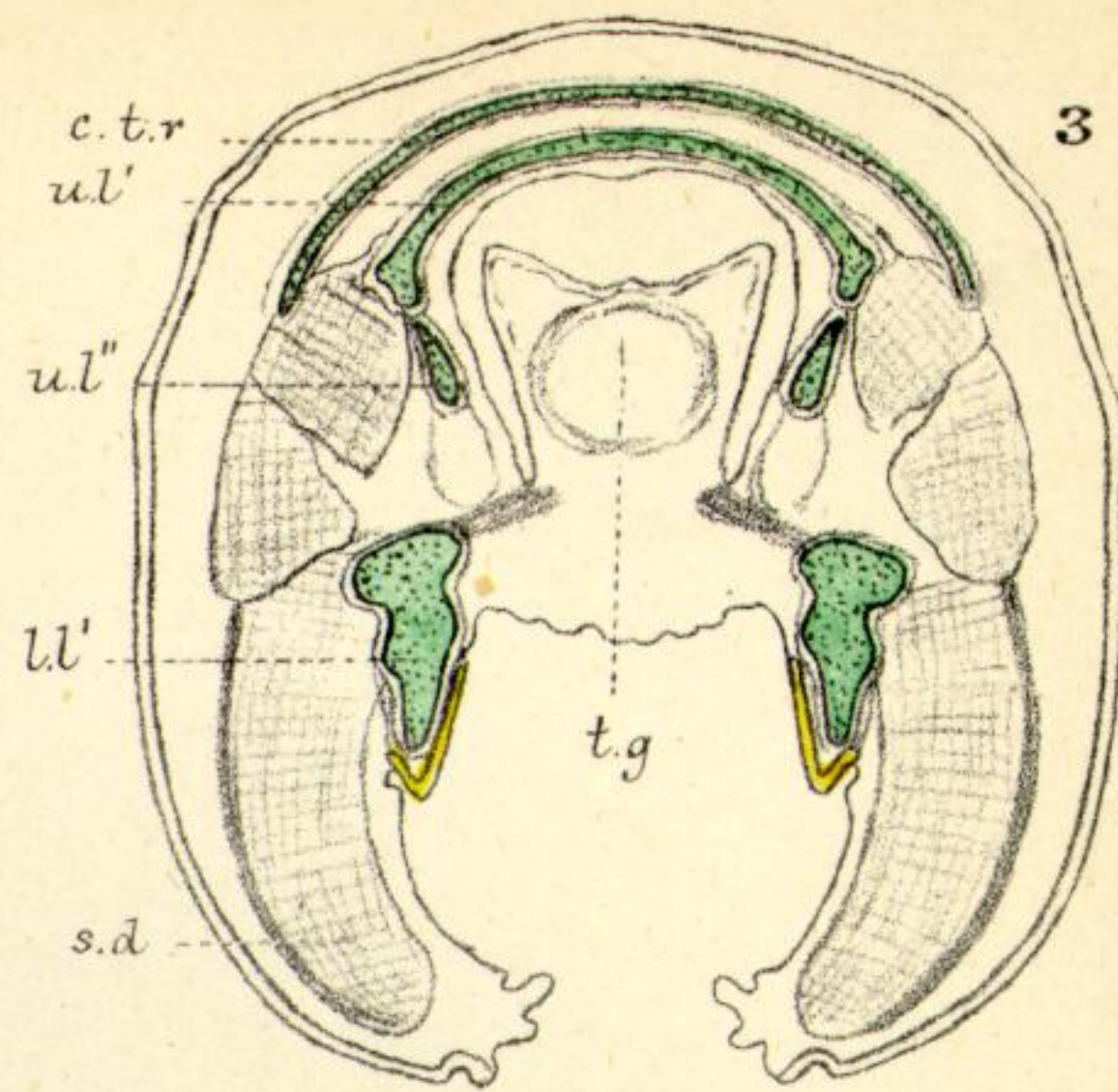
1 x 5.



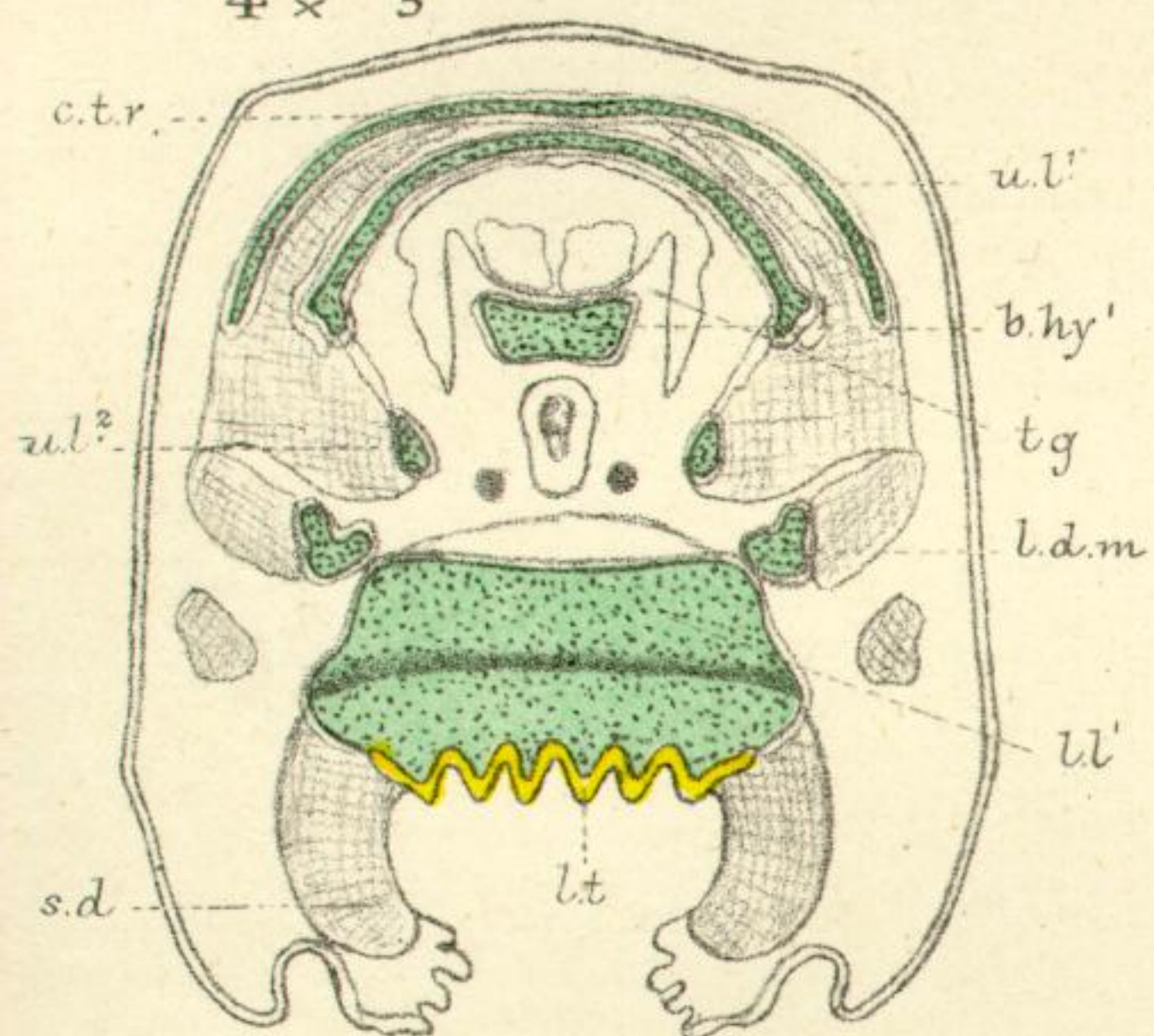
2 x 5



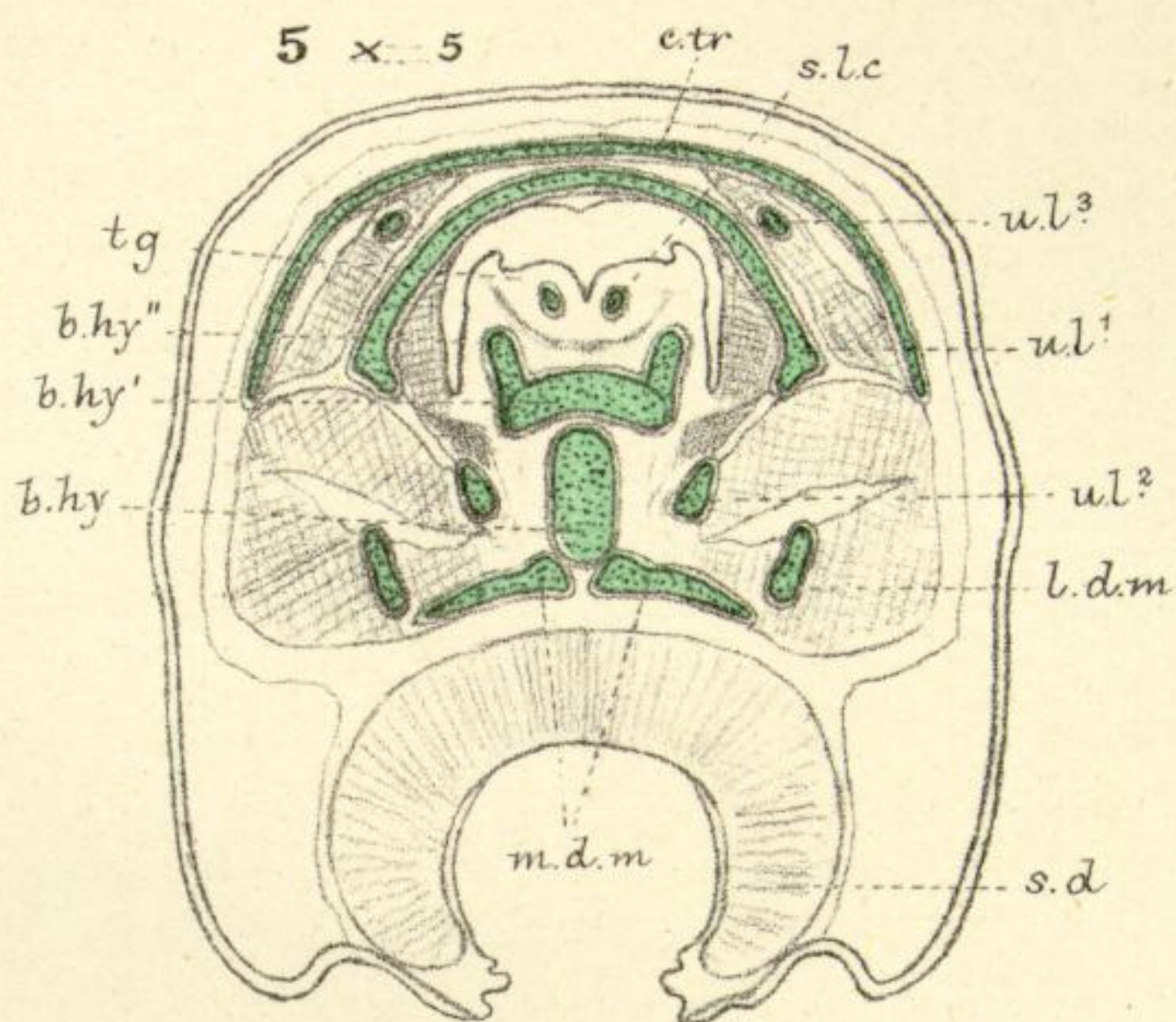
3 x 5.



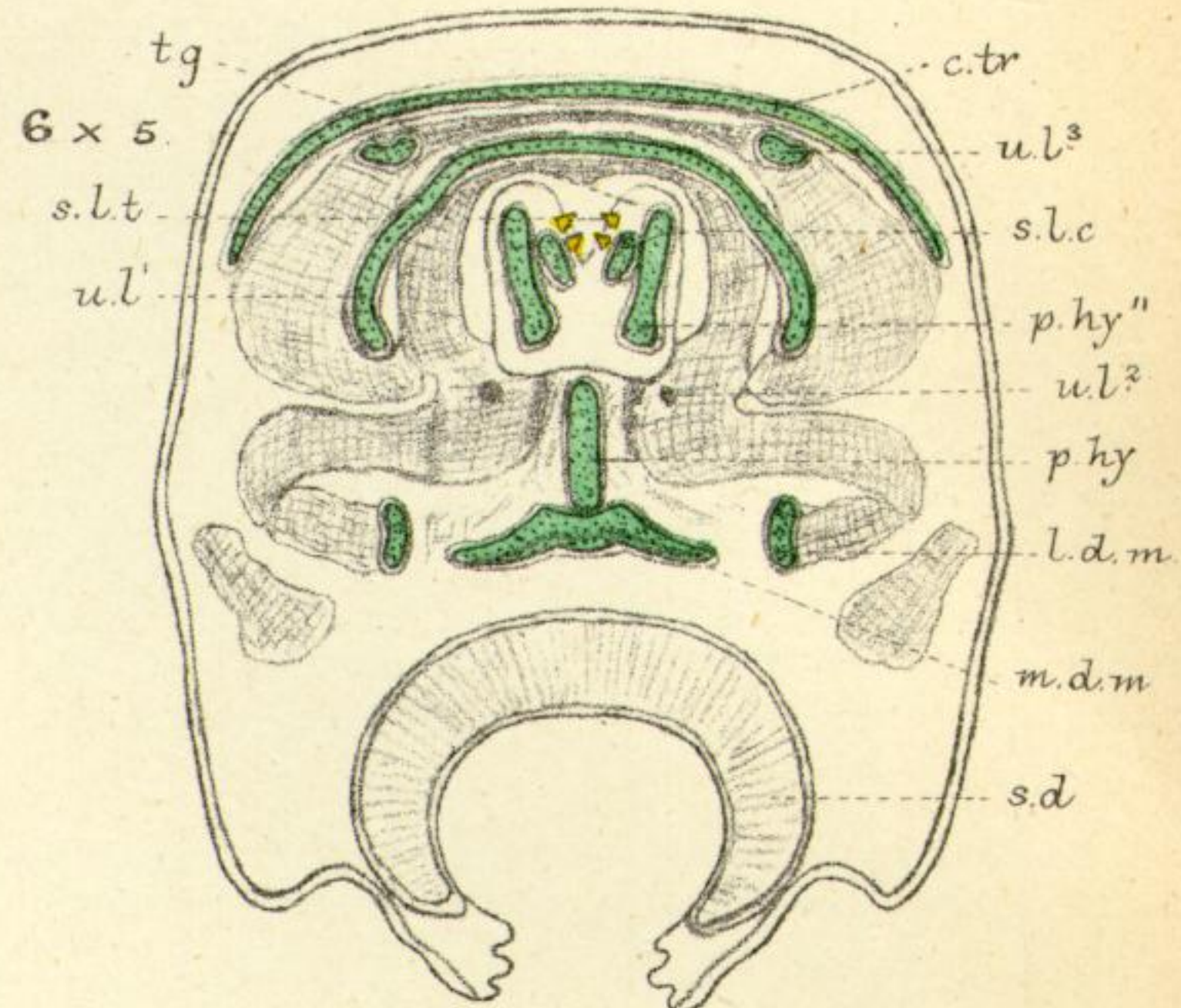
4 x 5



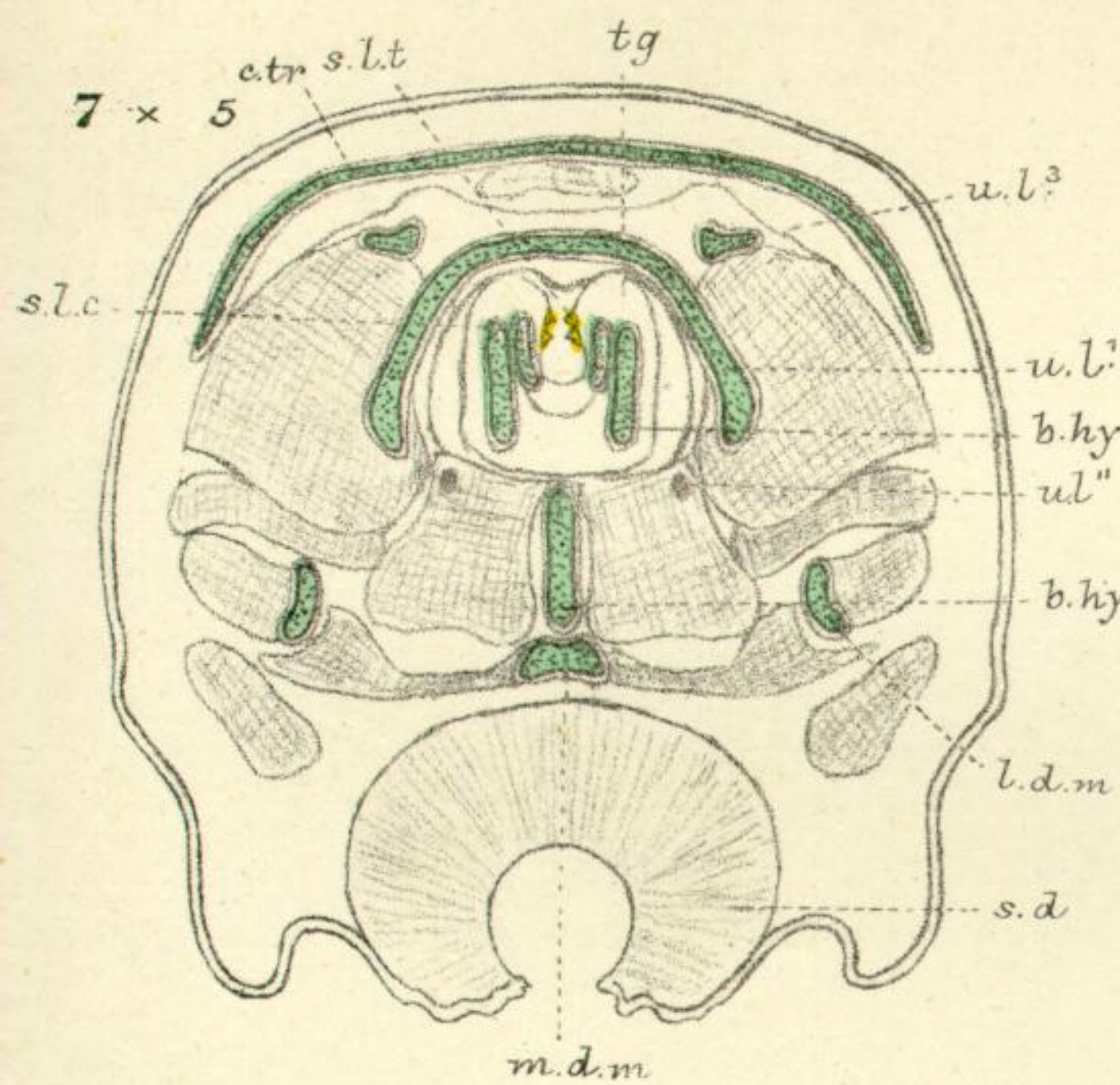
5 x 5



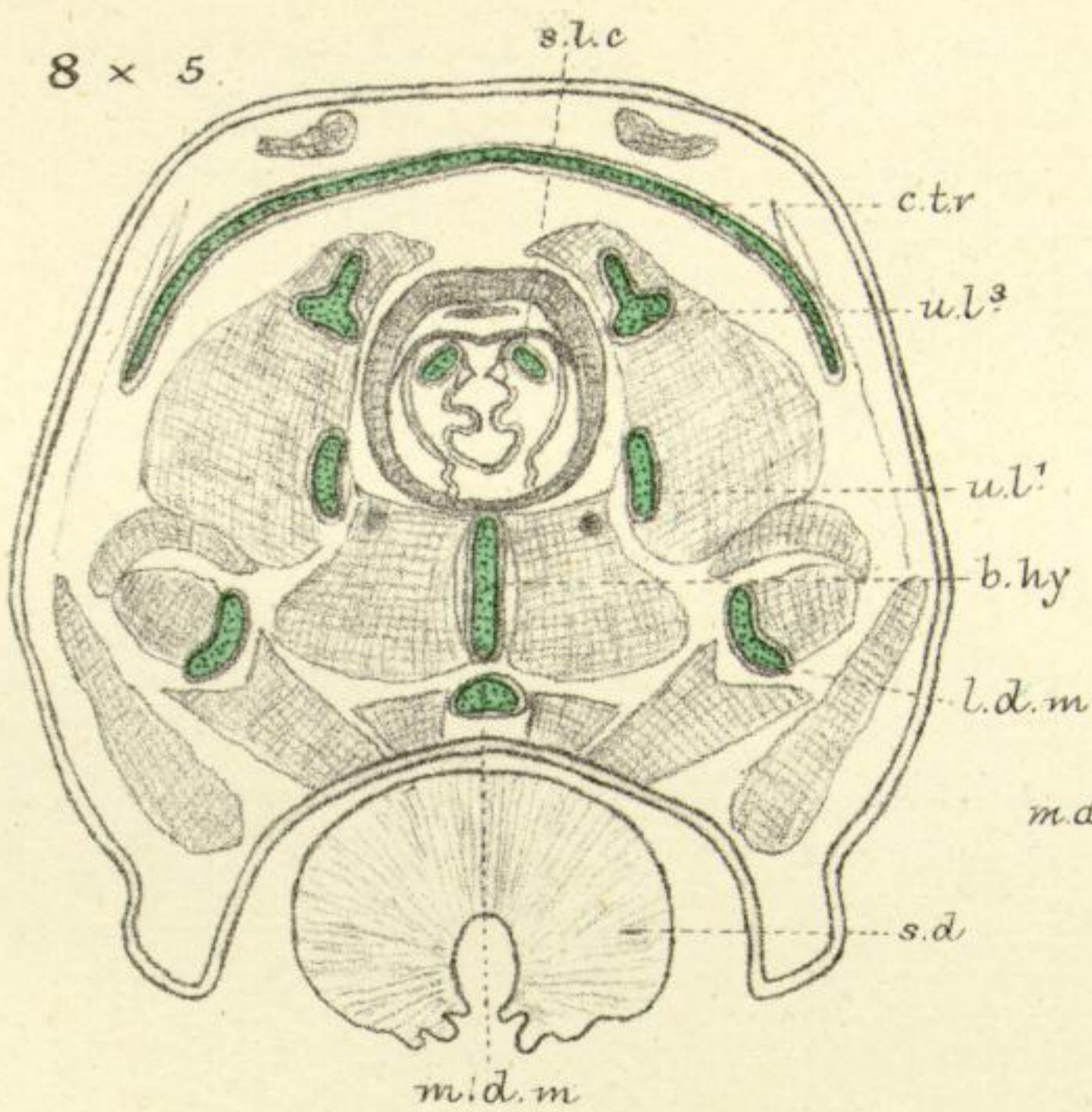
6 x 5



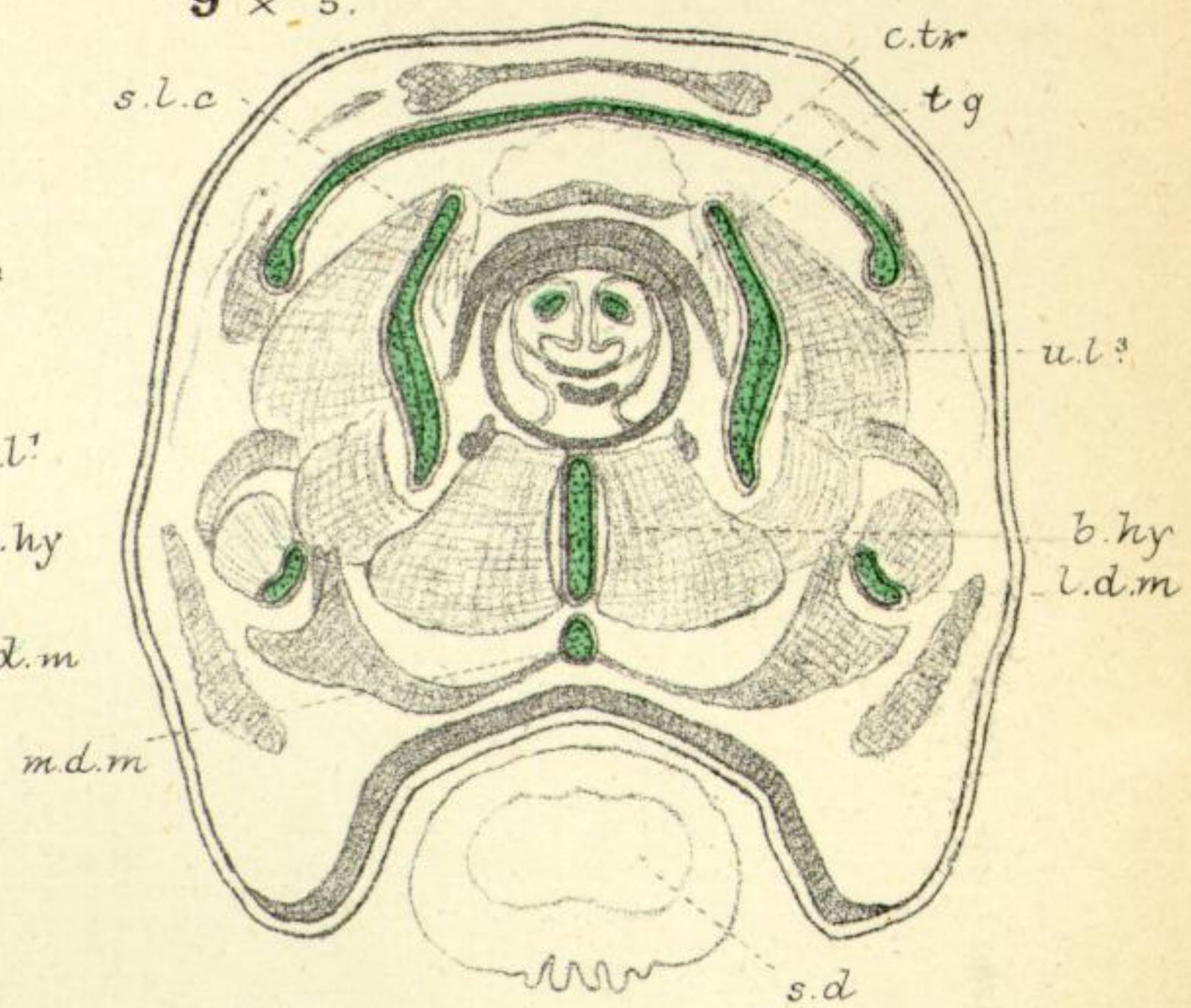
7 x 5



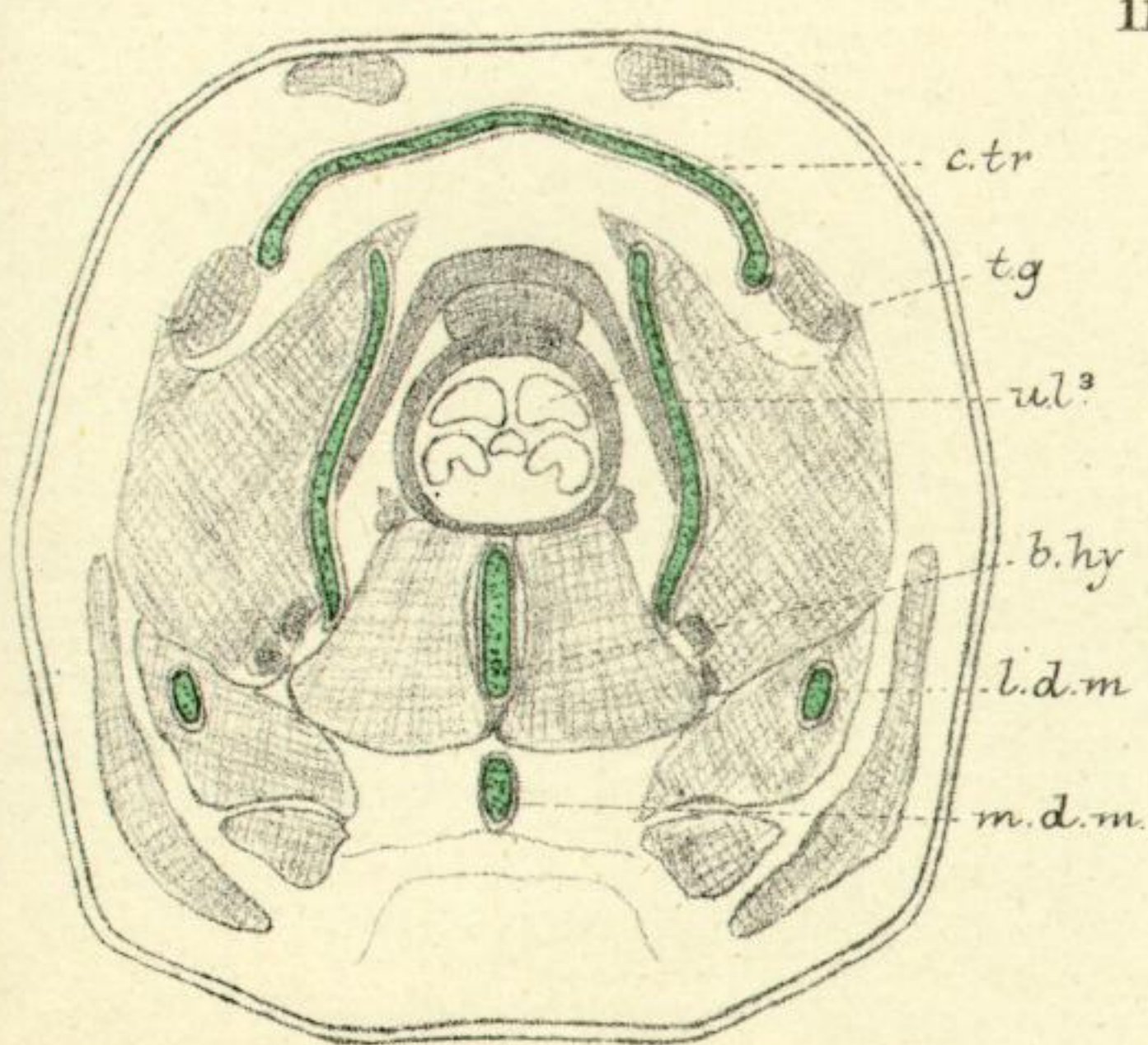
8 x 5



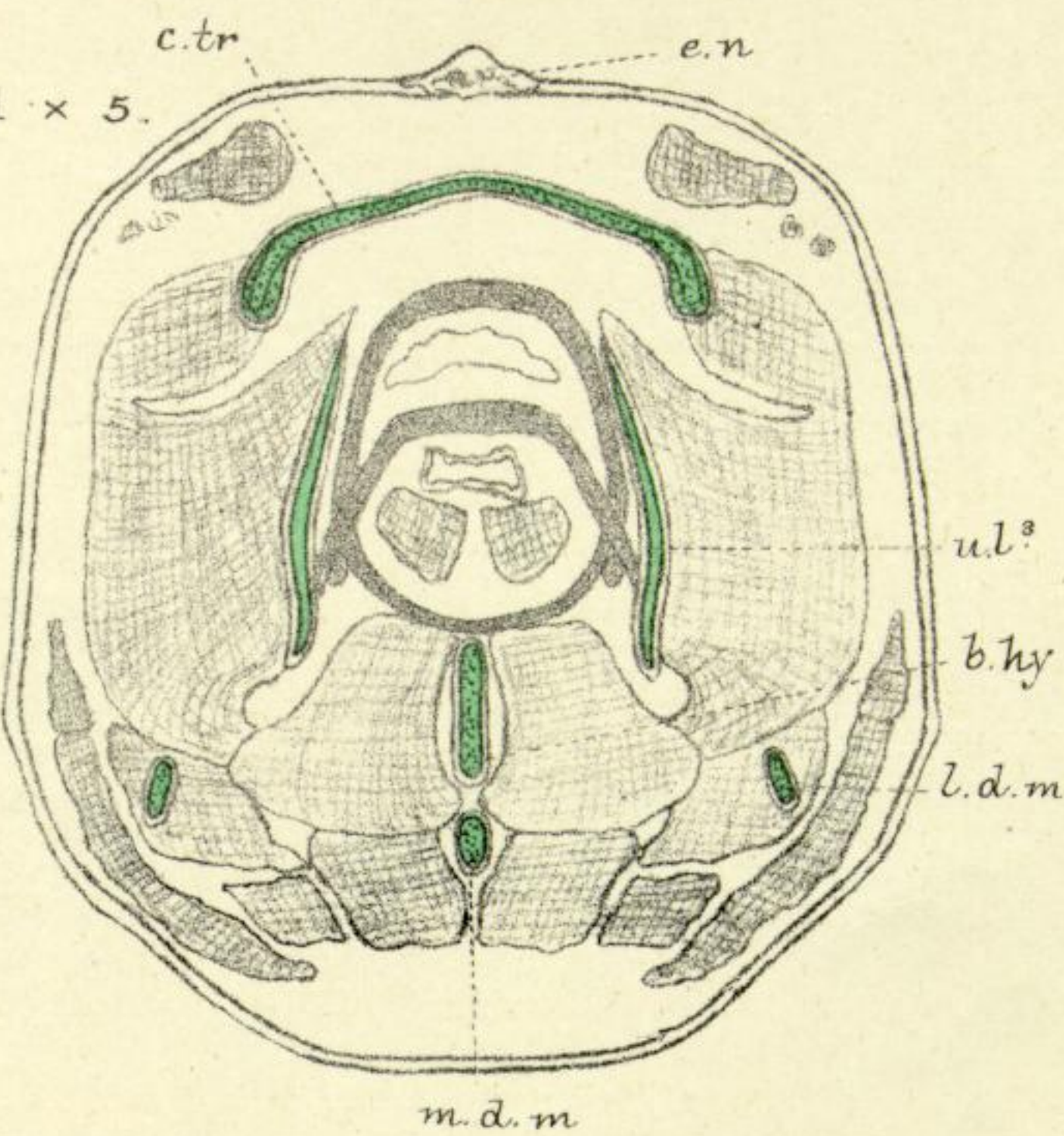
9 x 5.



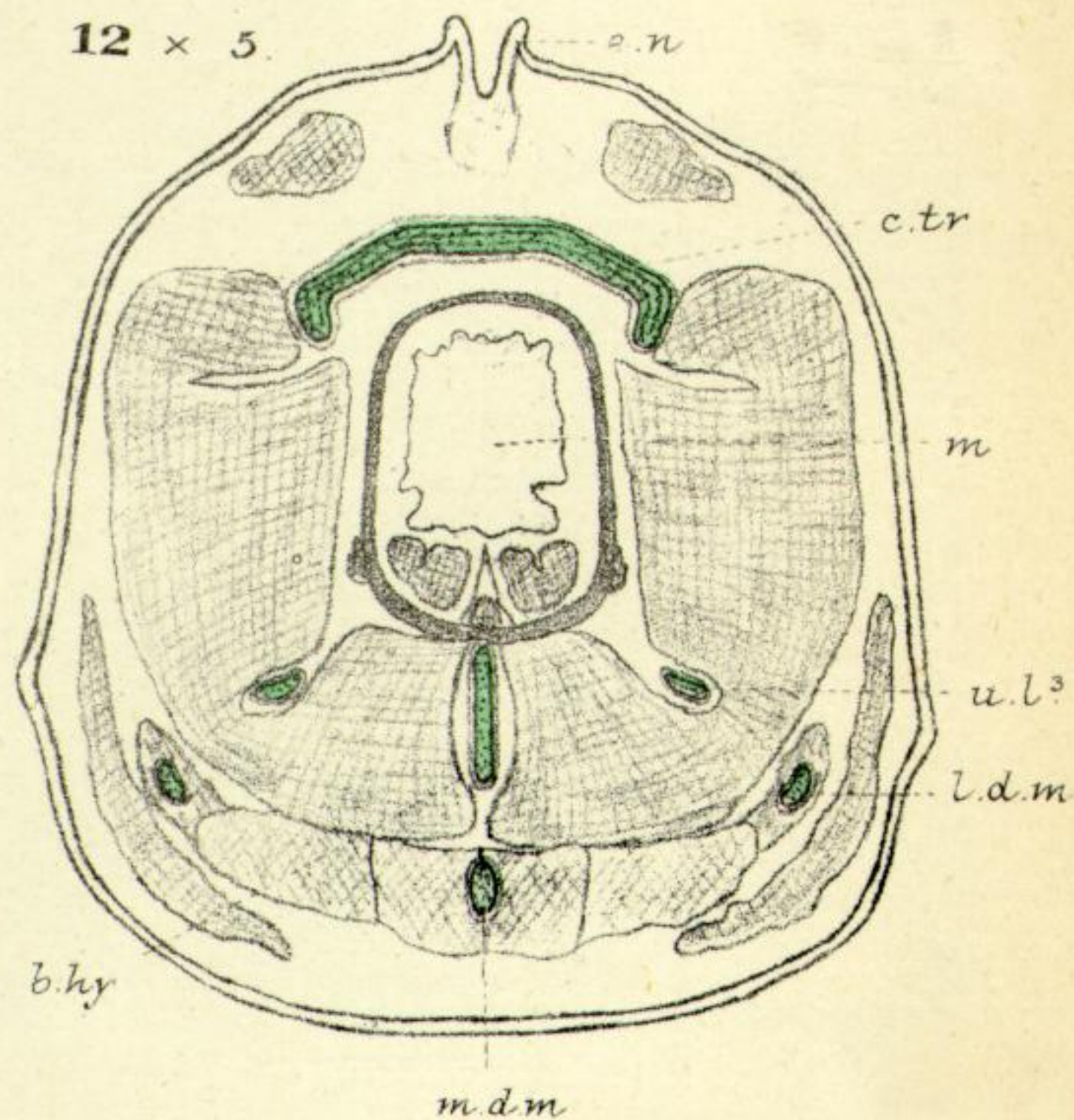
10 x 5.



11 x 5.

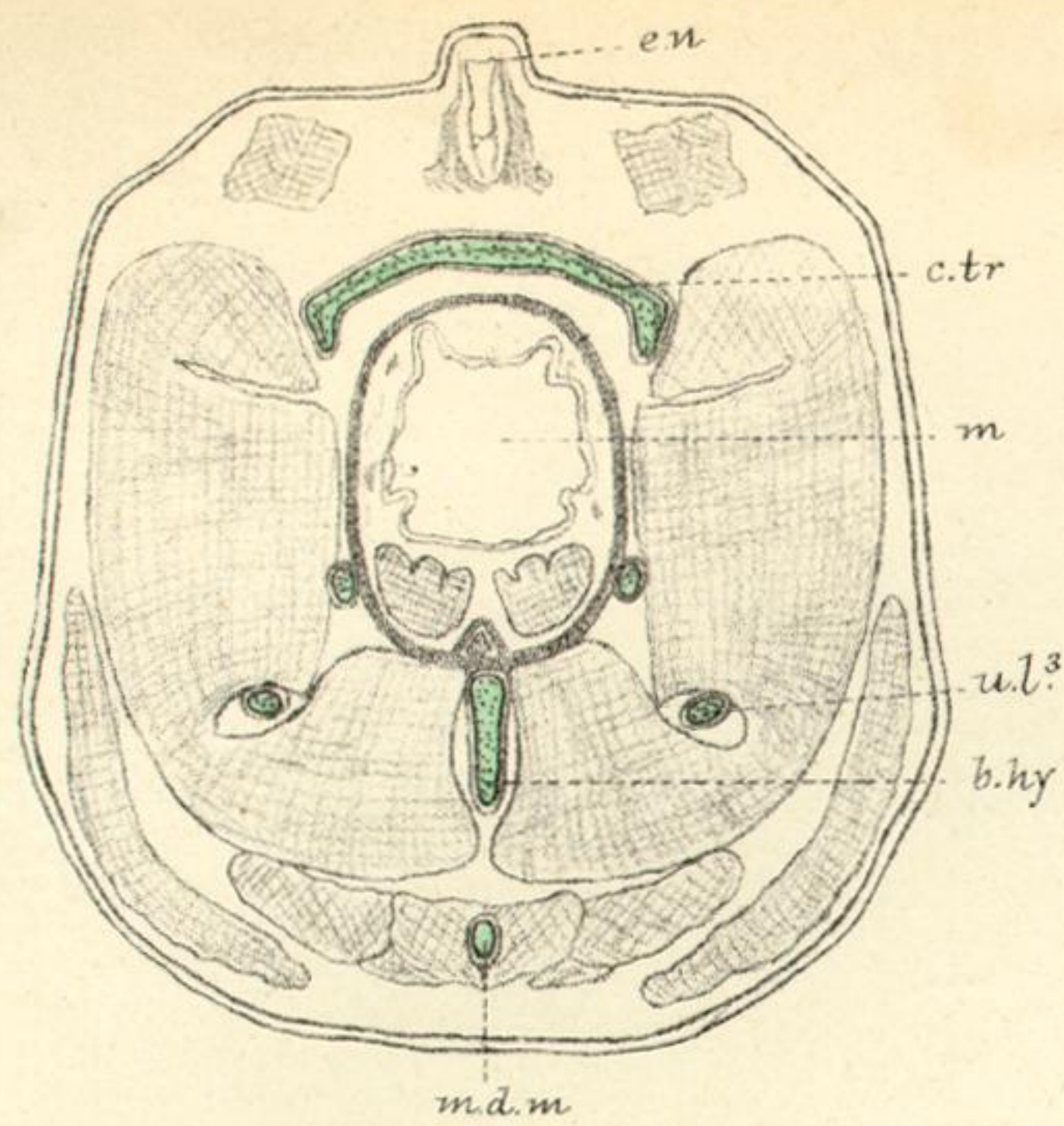


12 x 5

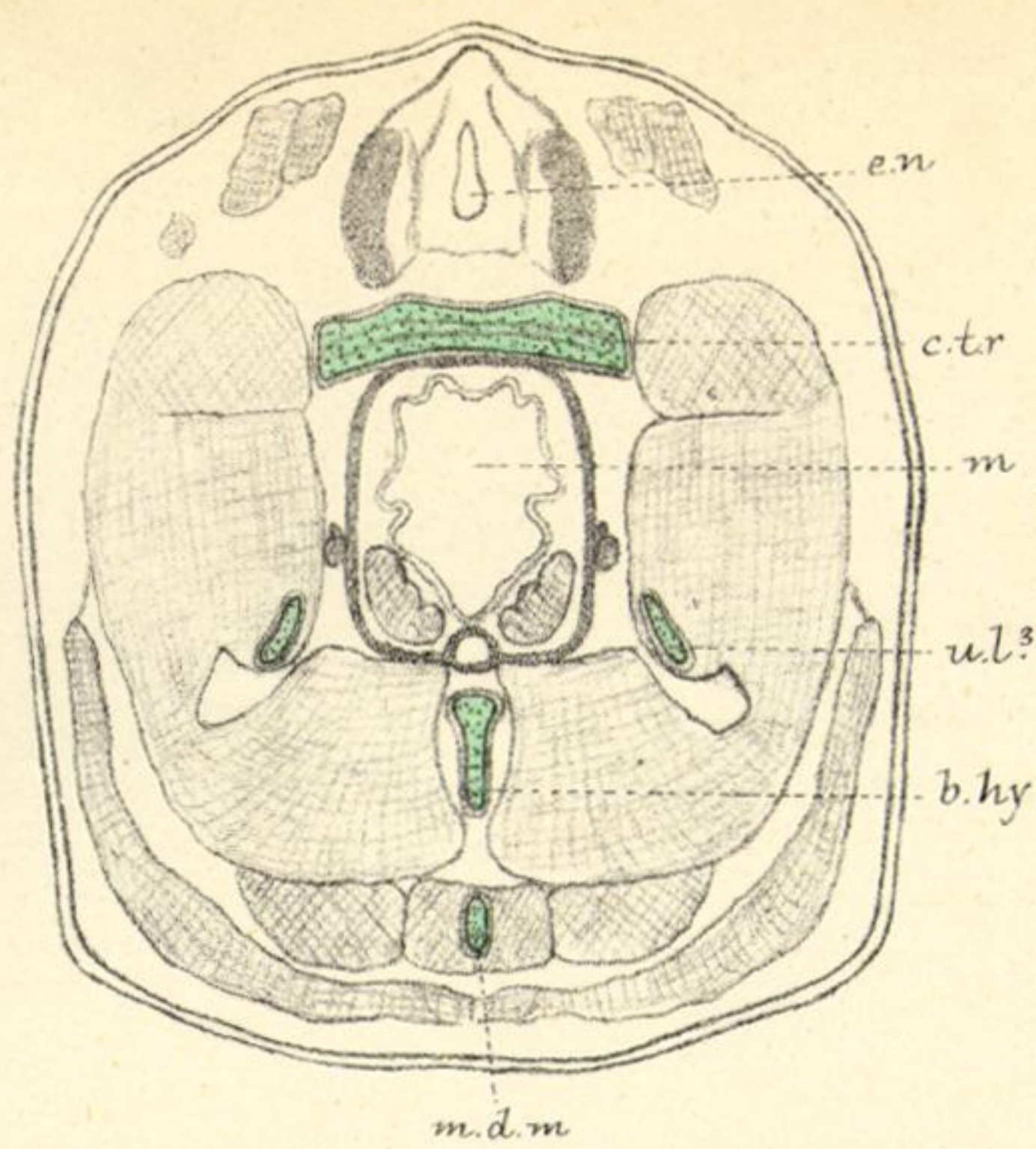




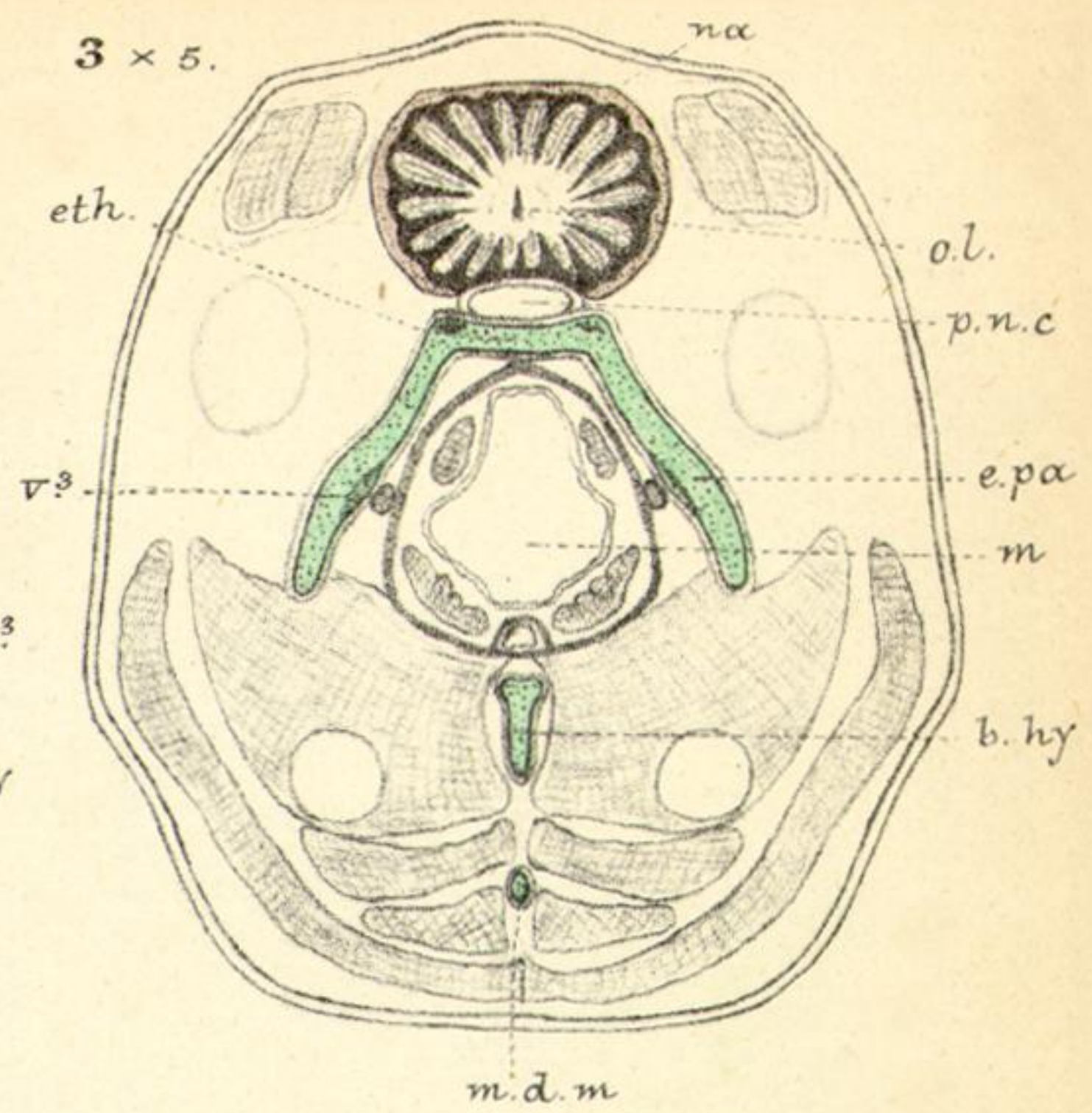
1 x 5.



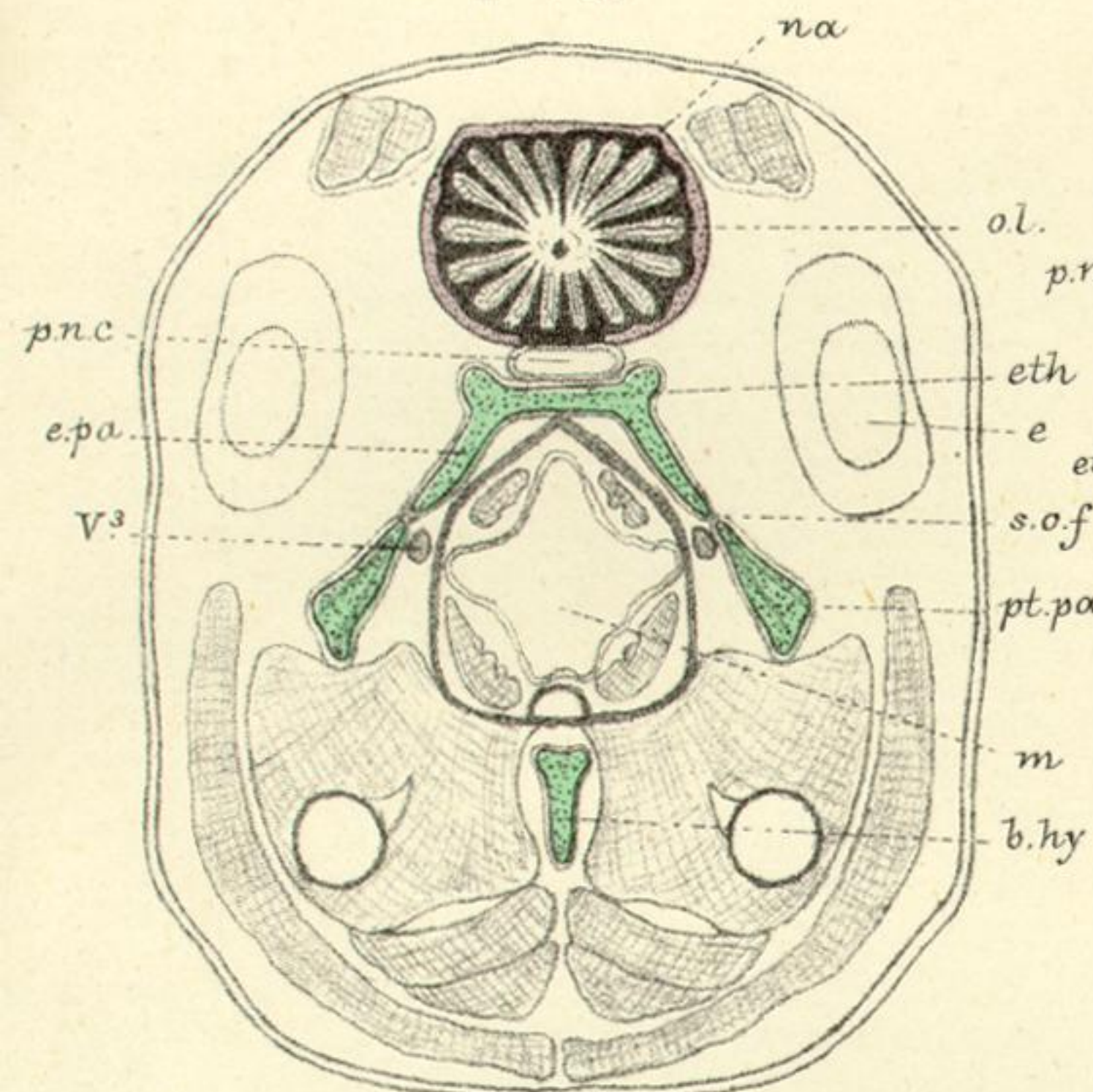
2 x 5.



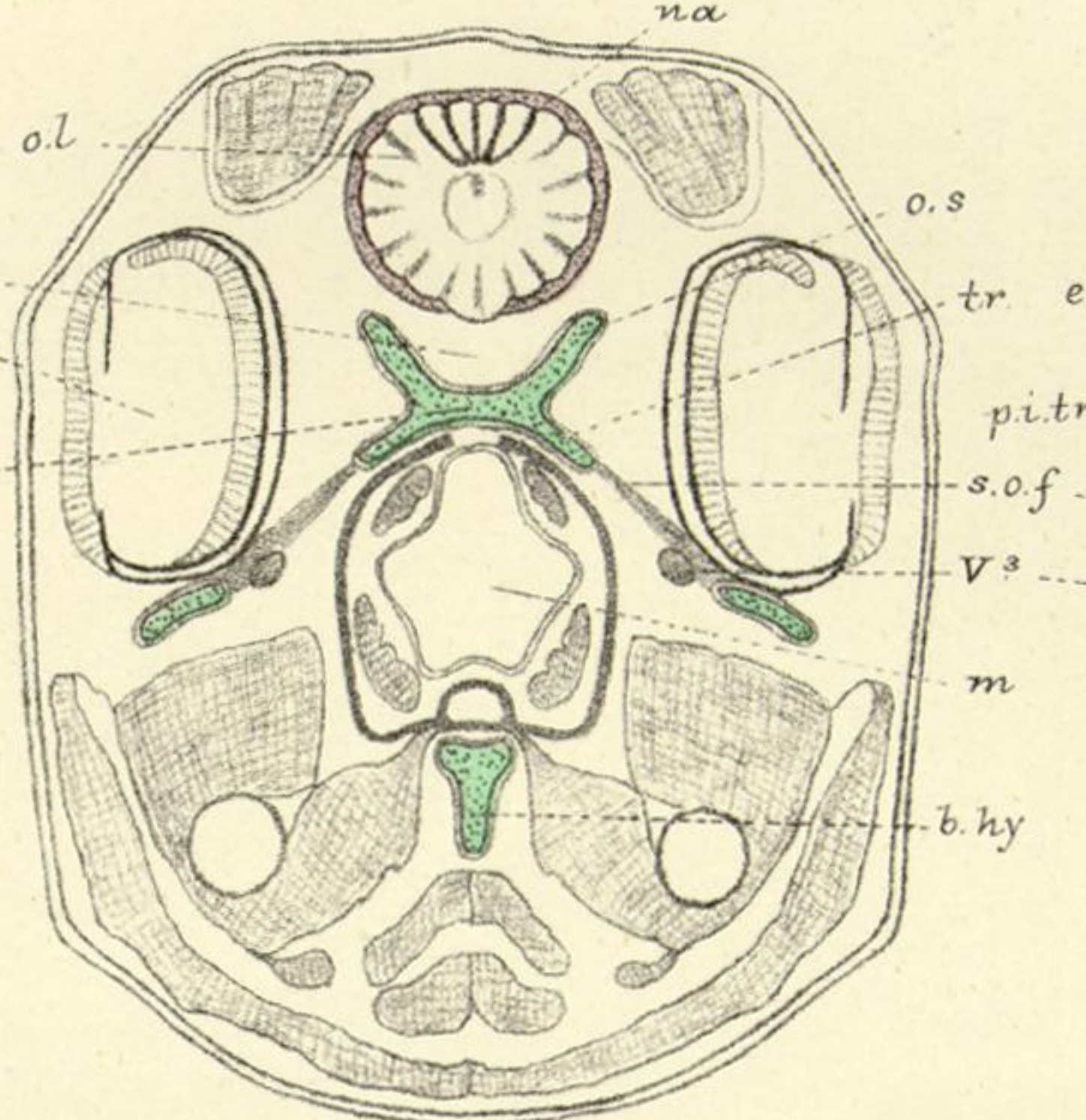
3 x 5.



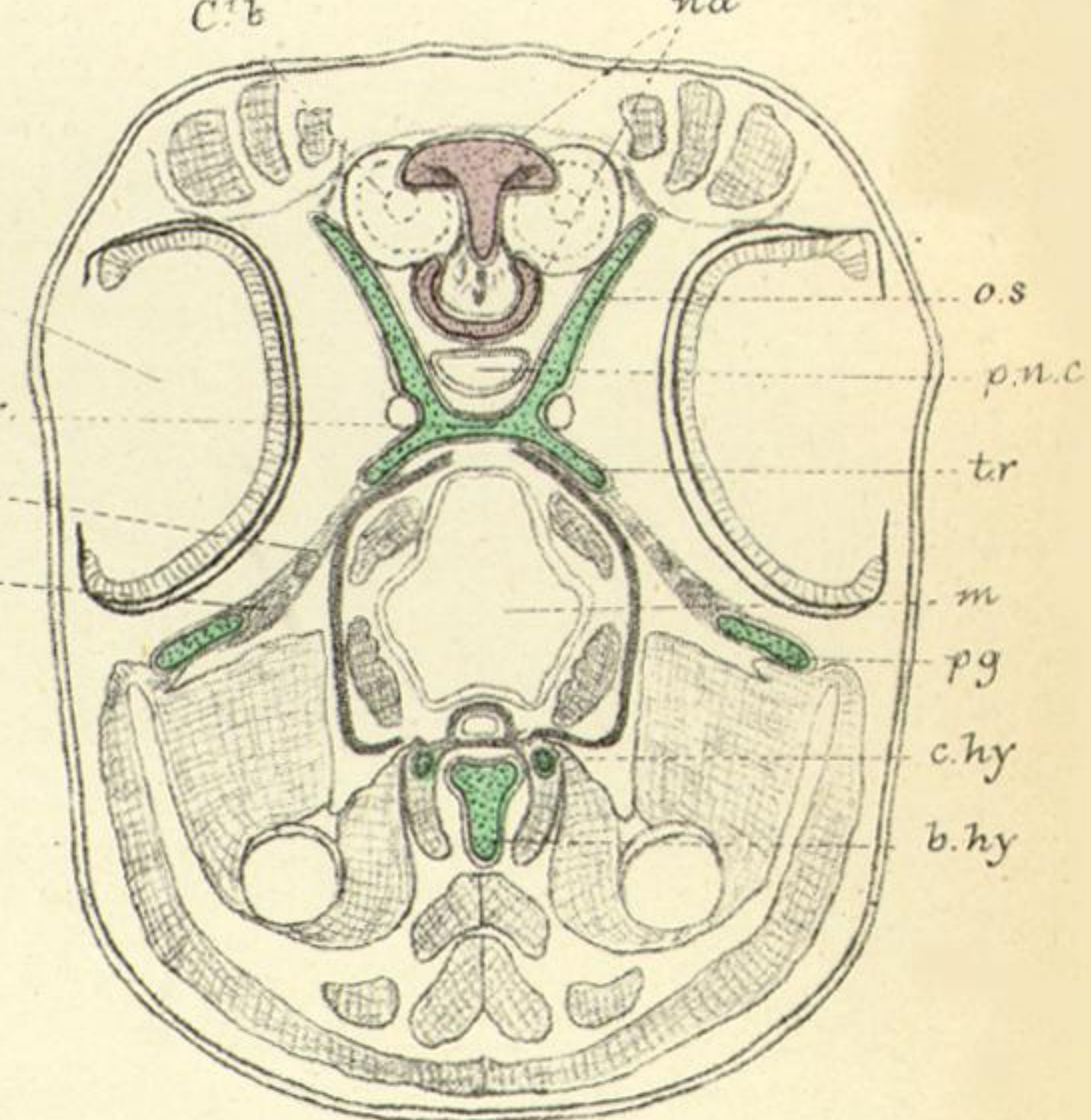
4 x 5.



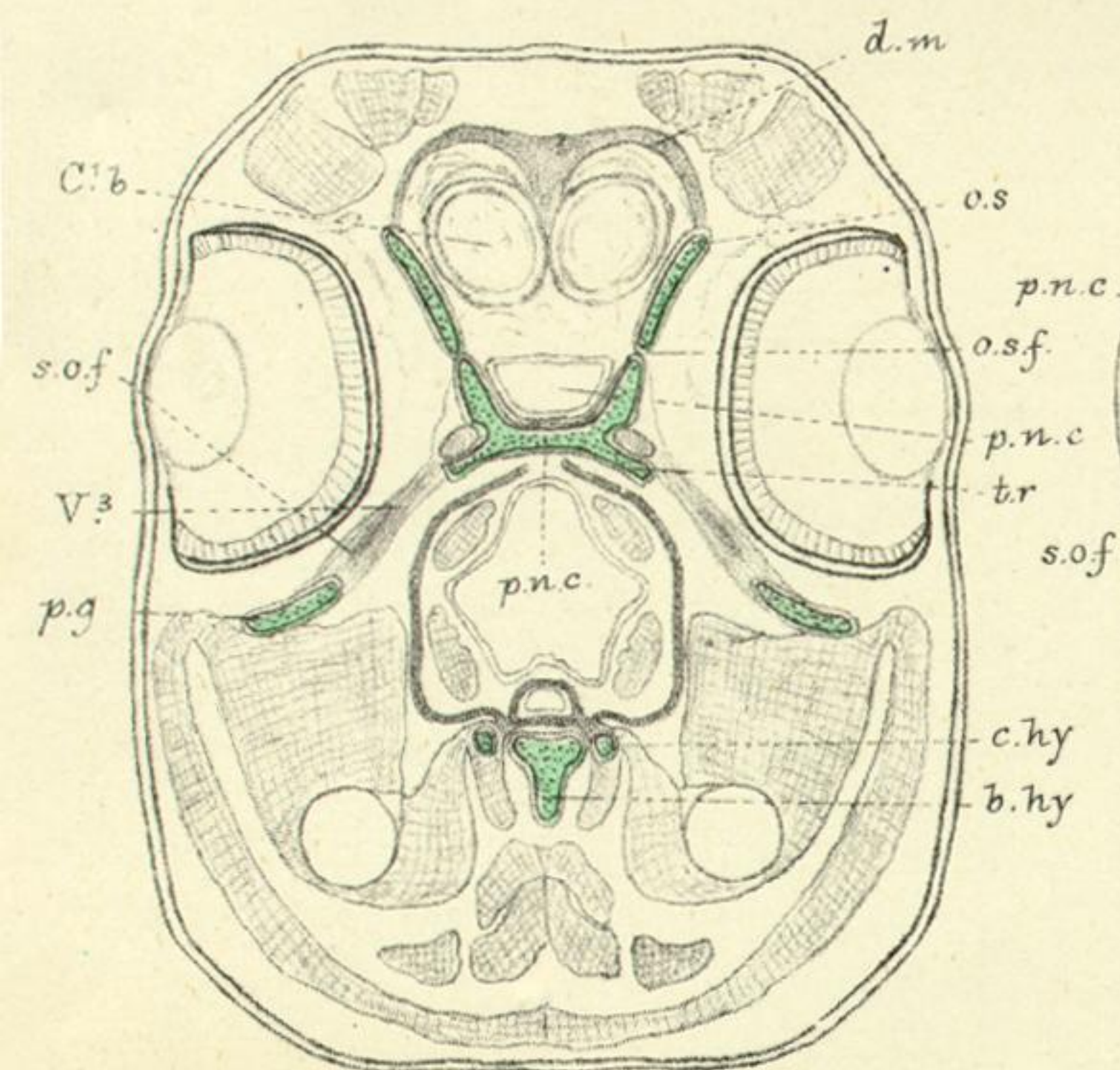
5 x 5.



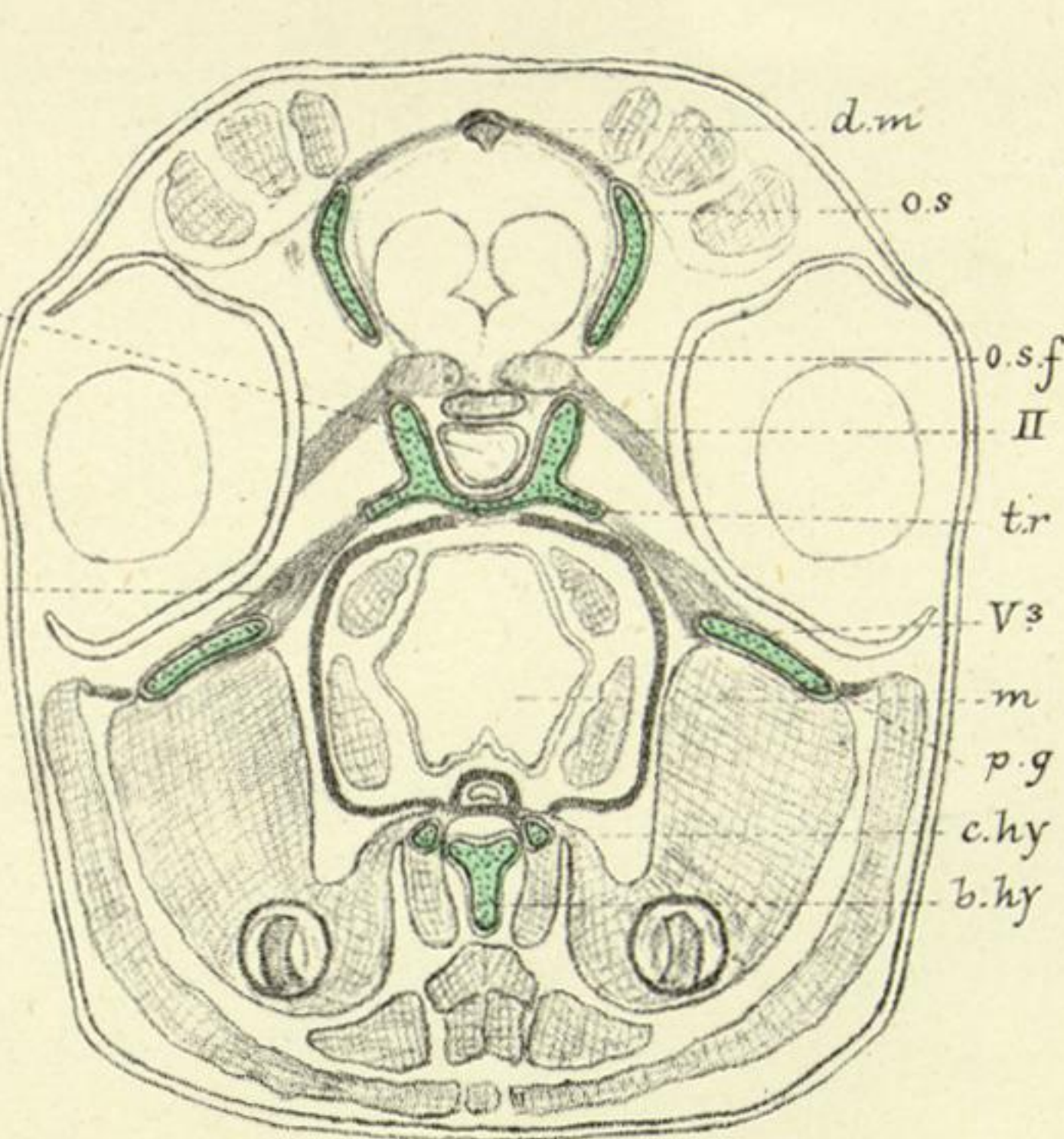
6 x 5.



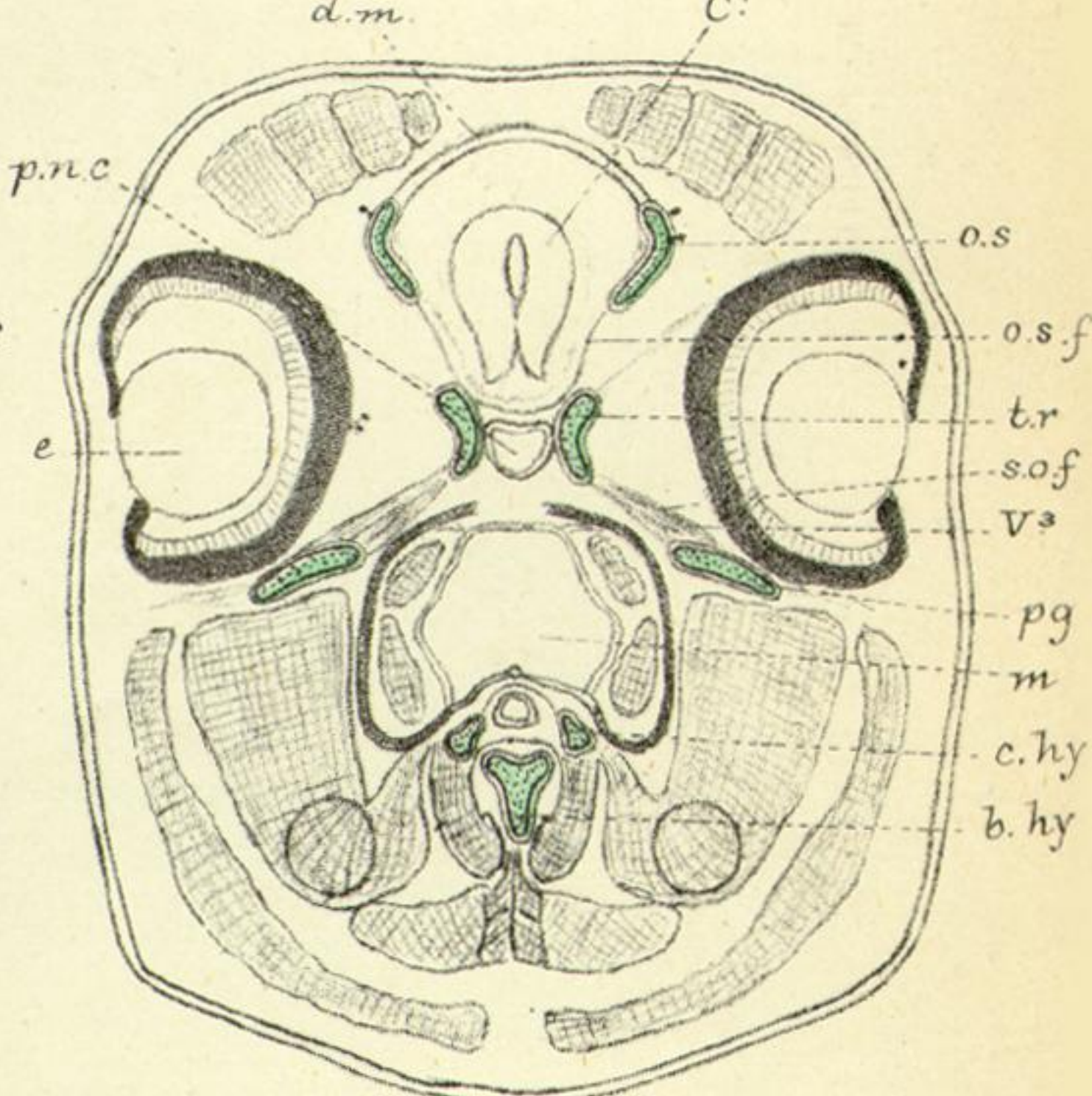
7 x 5.



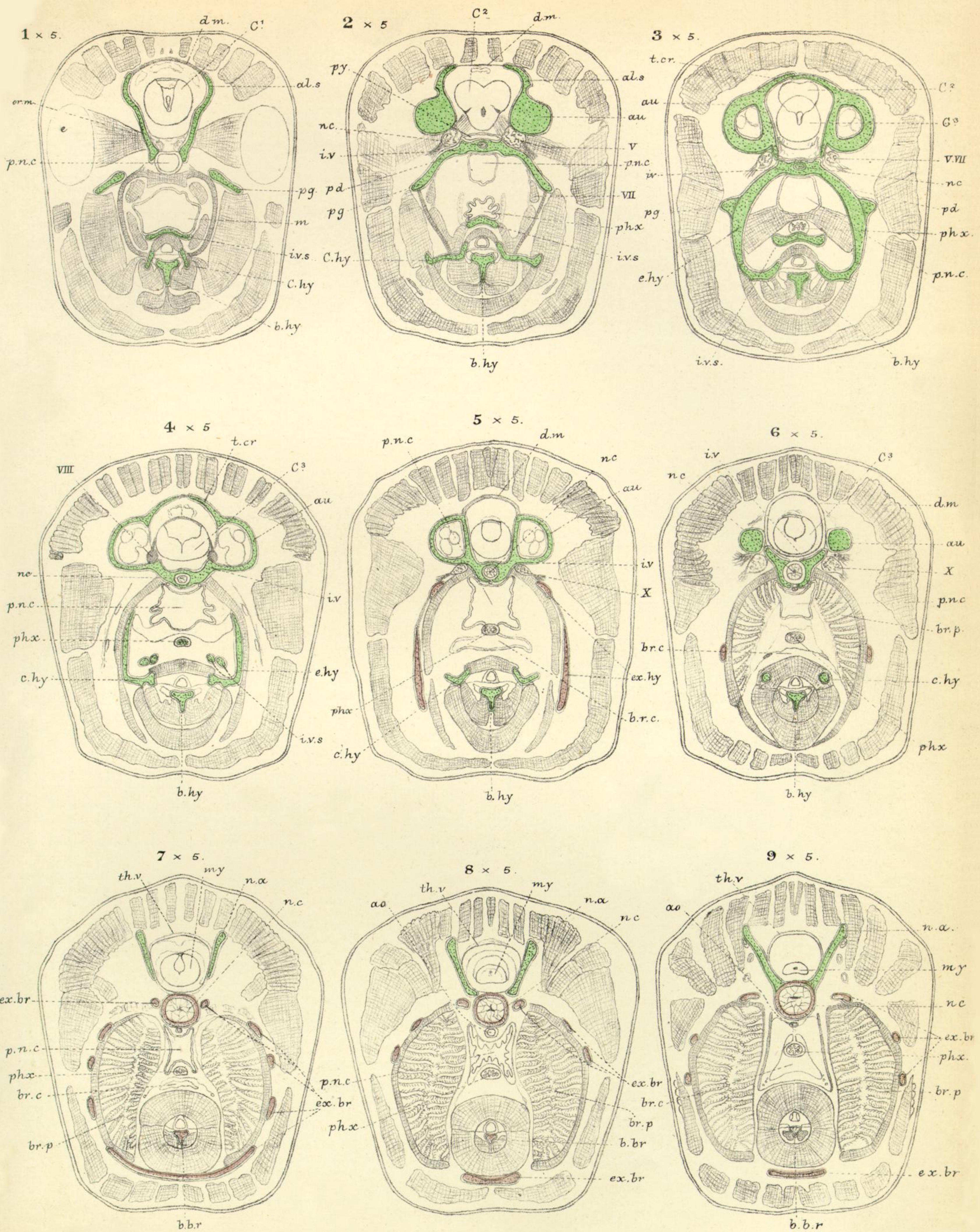
8 x 5.



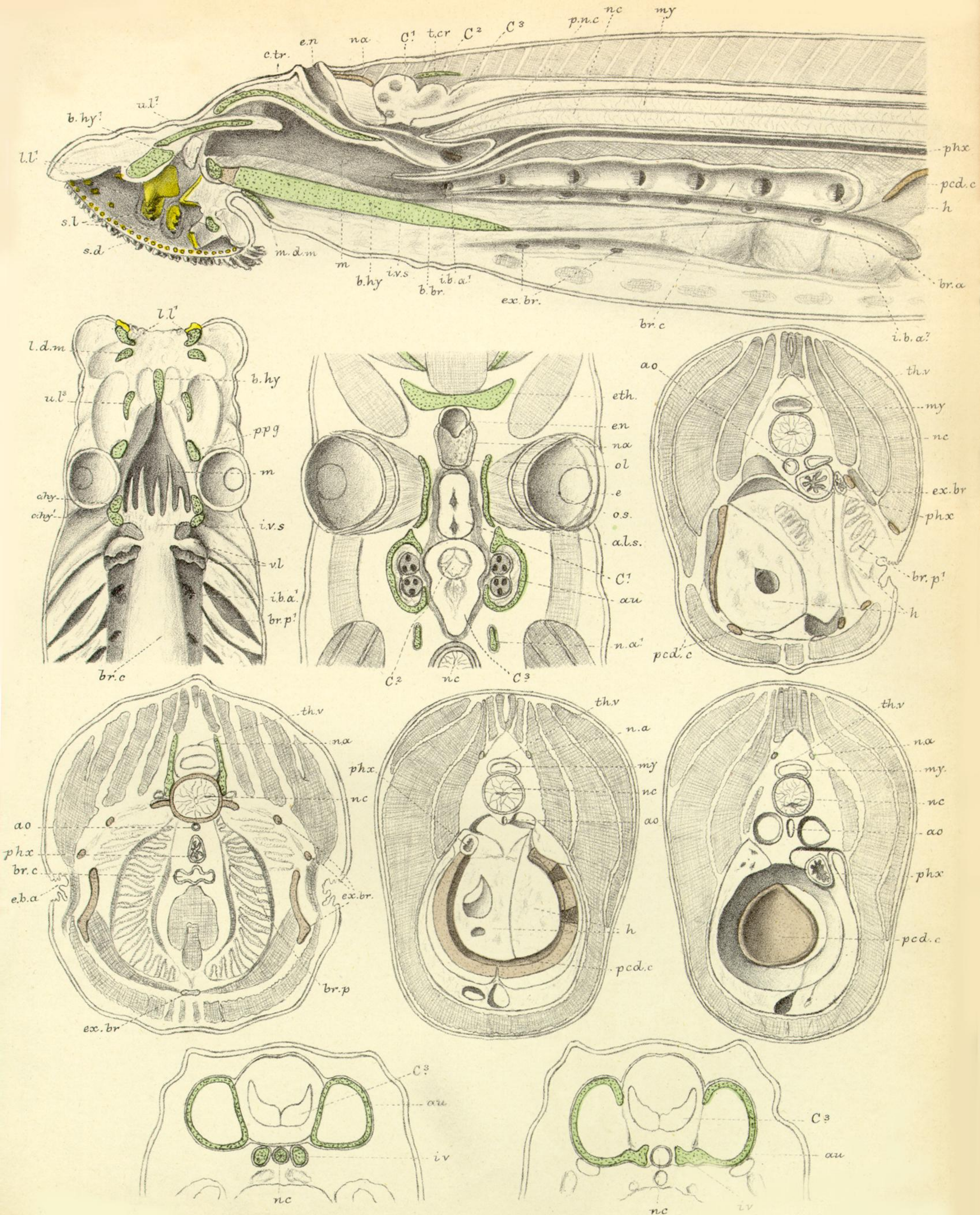
9 x 5.







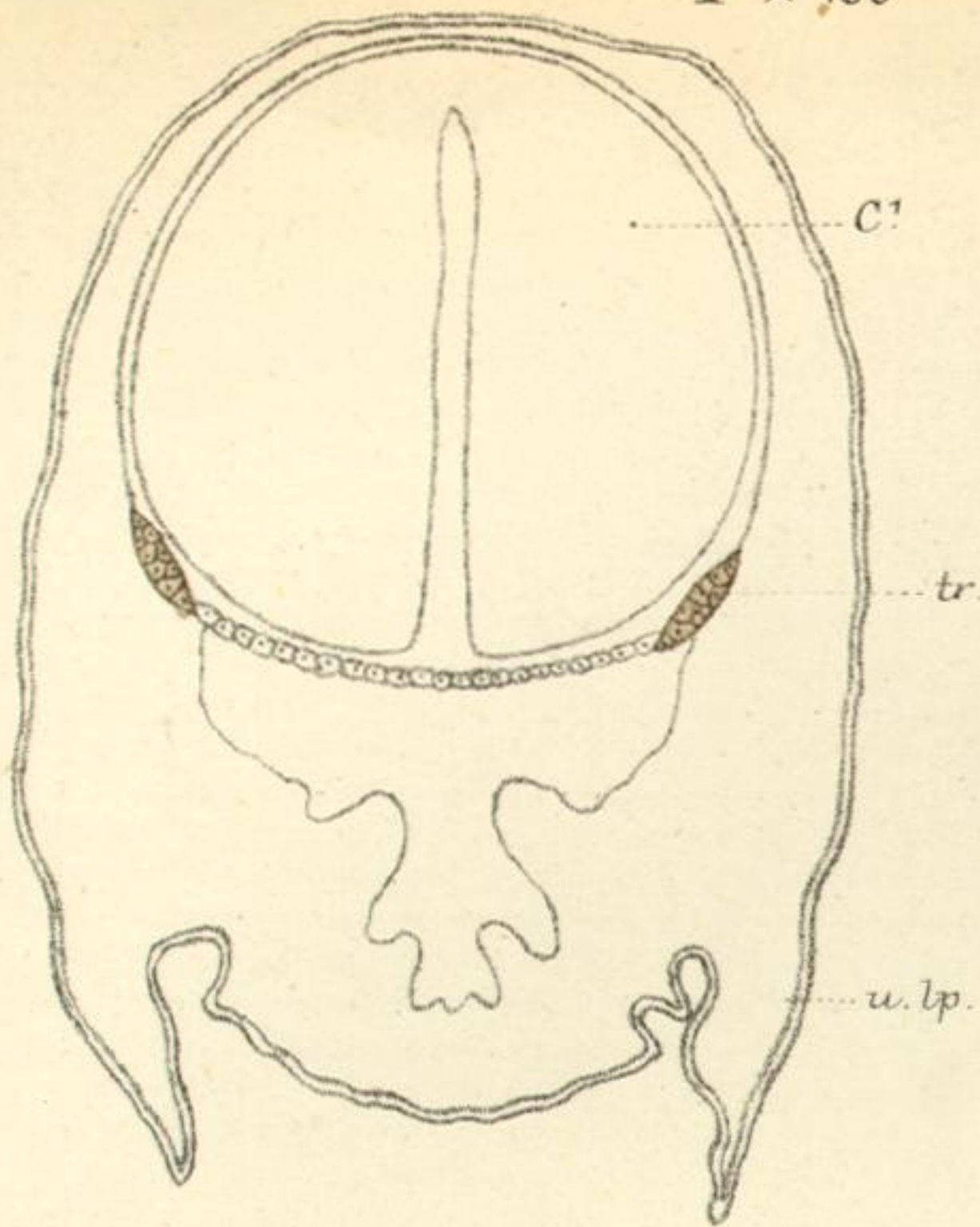




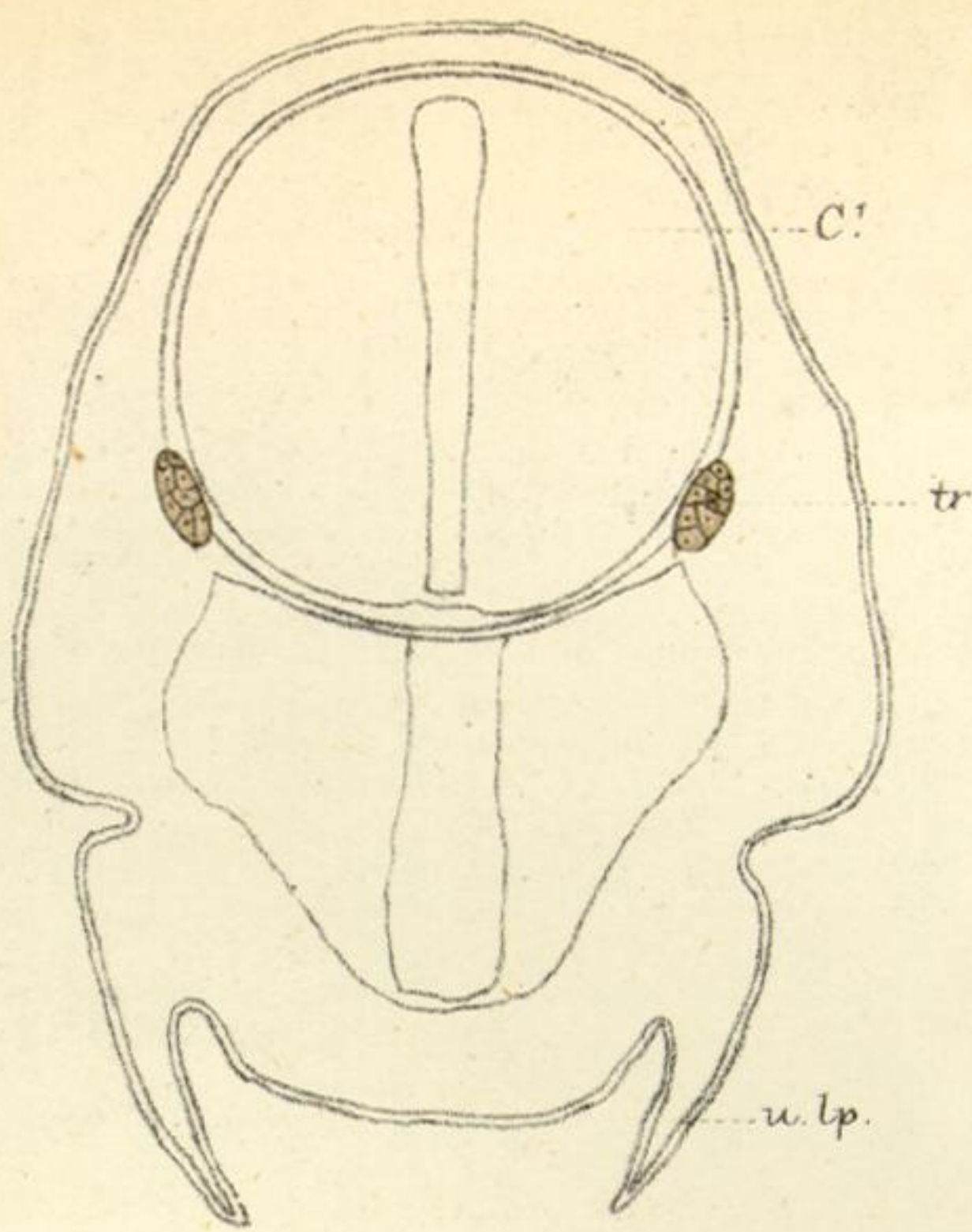
PETROMYZON FLUVIATILIS.



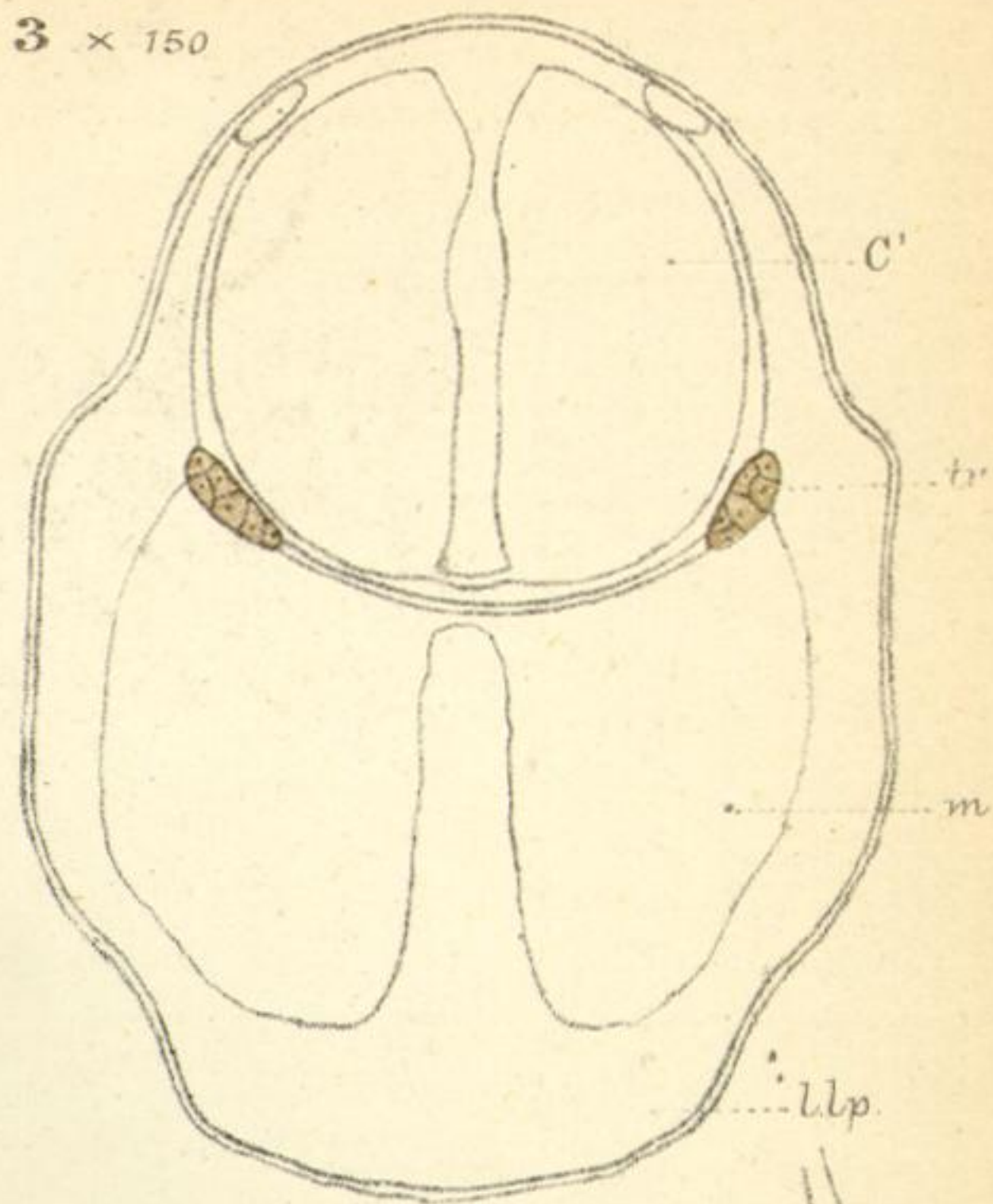
1 × 150



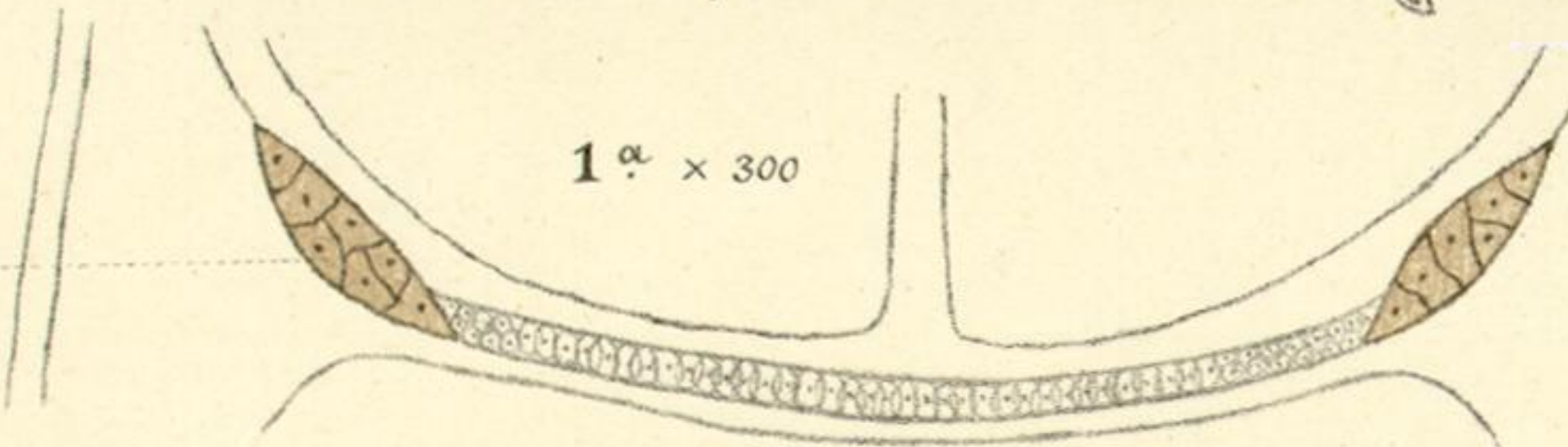
2 × 150



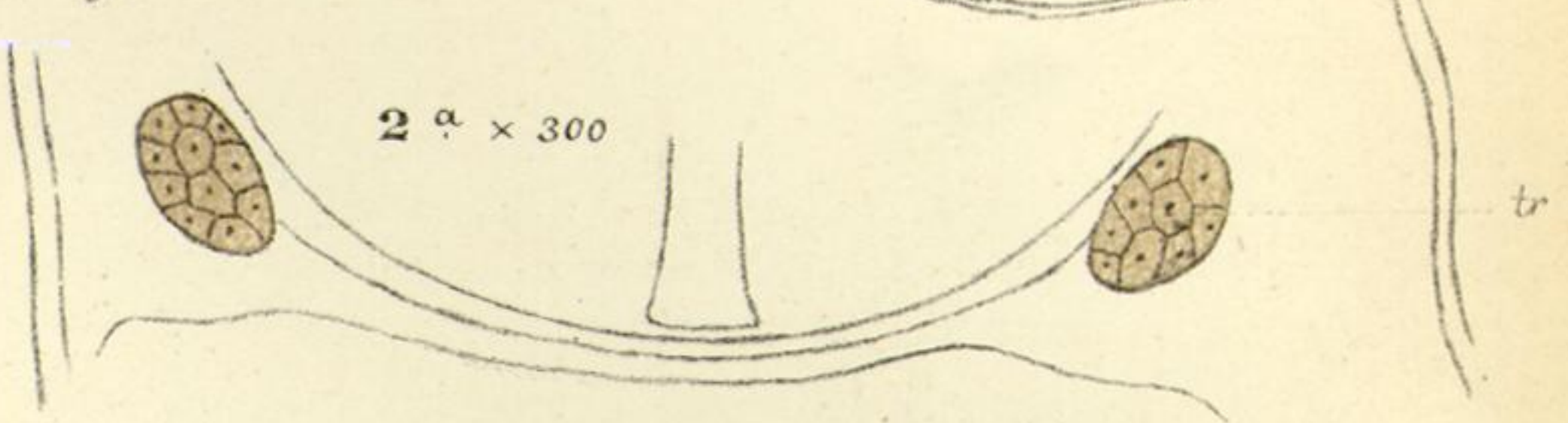
3 × 150



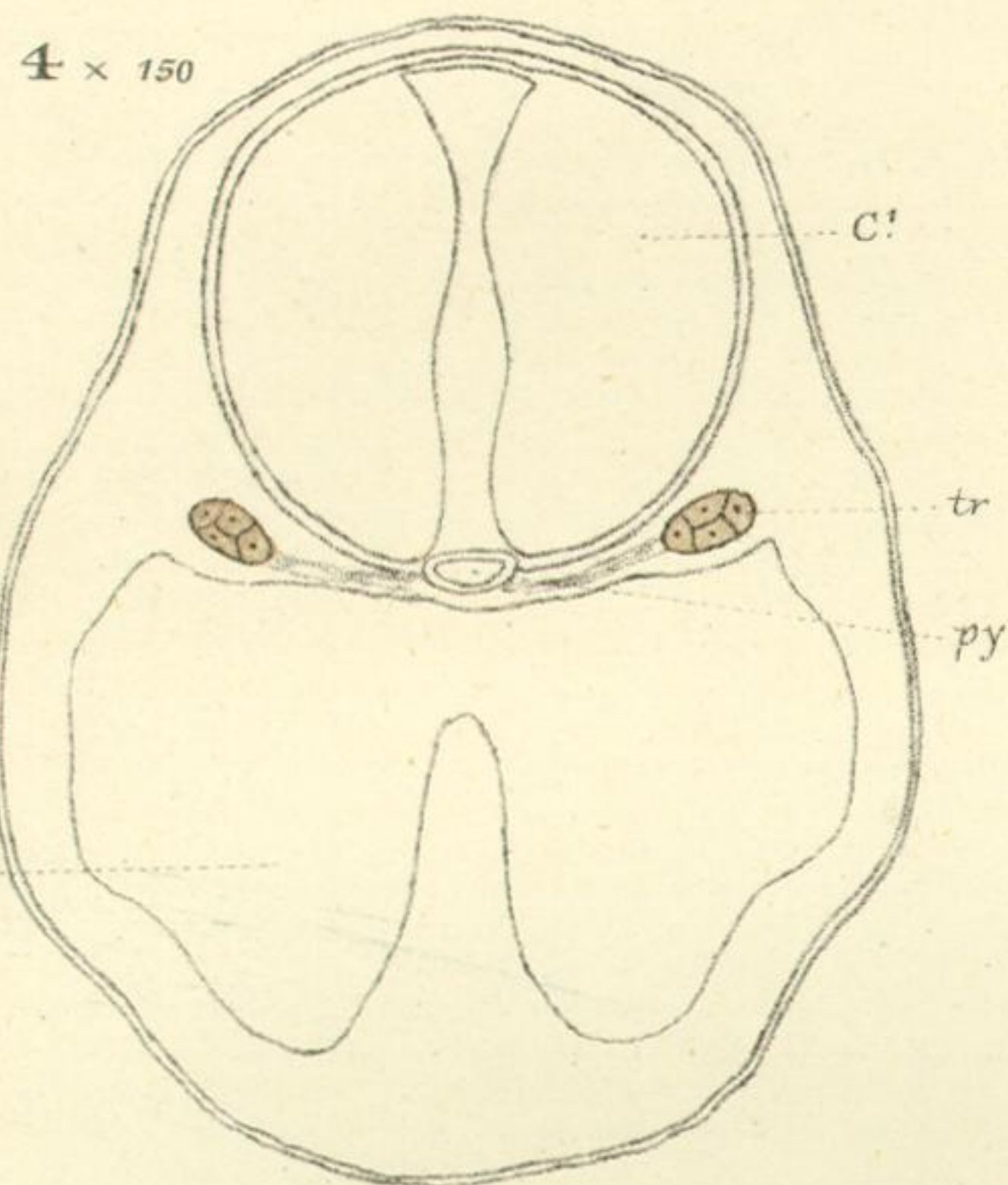
1<sup>a</sup> × 300



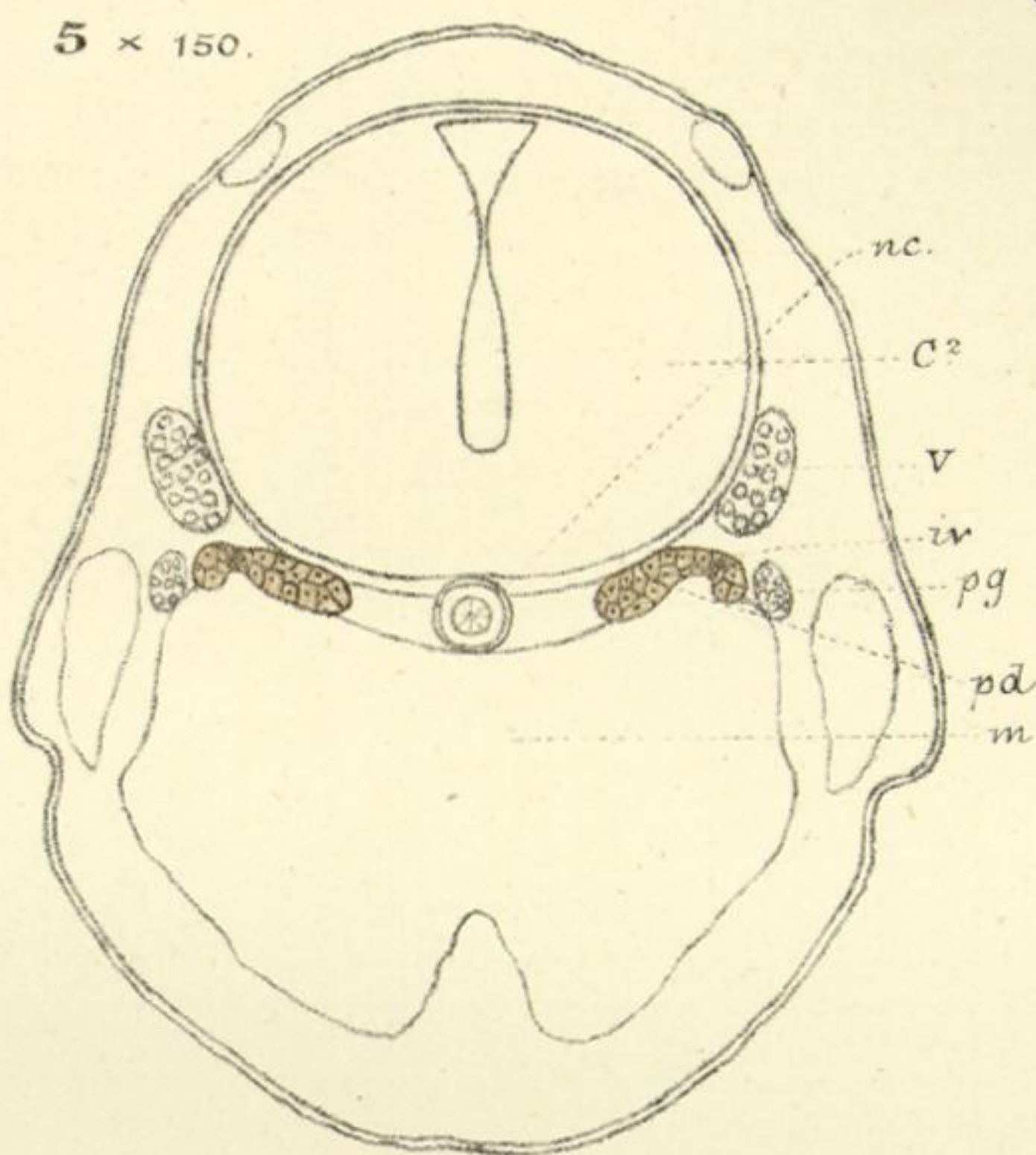
2<sup>a</sup> × 300



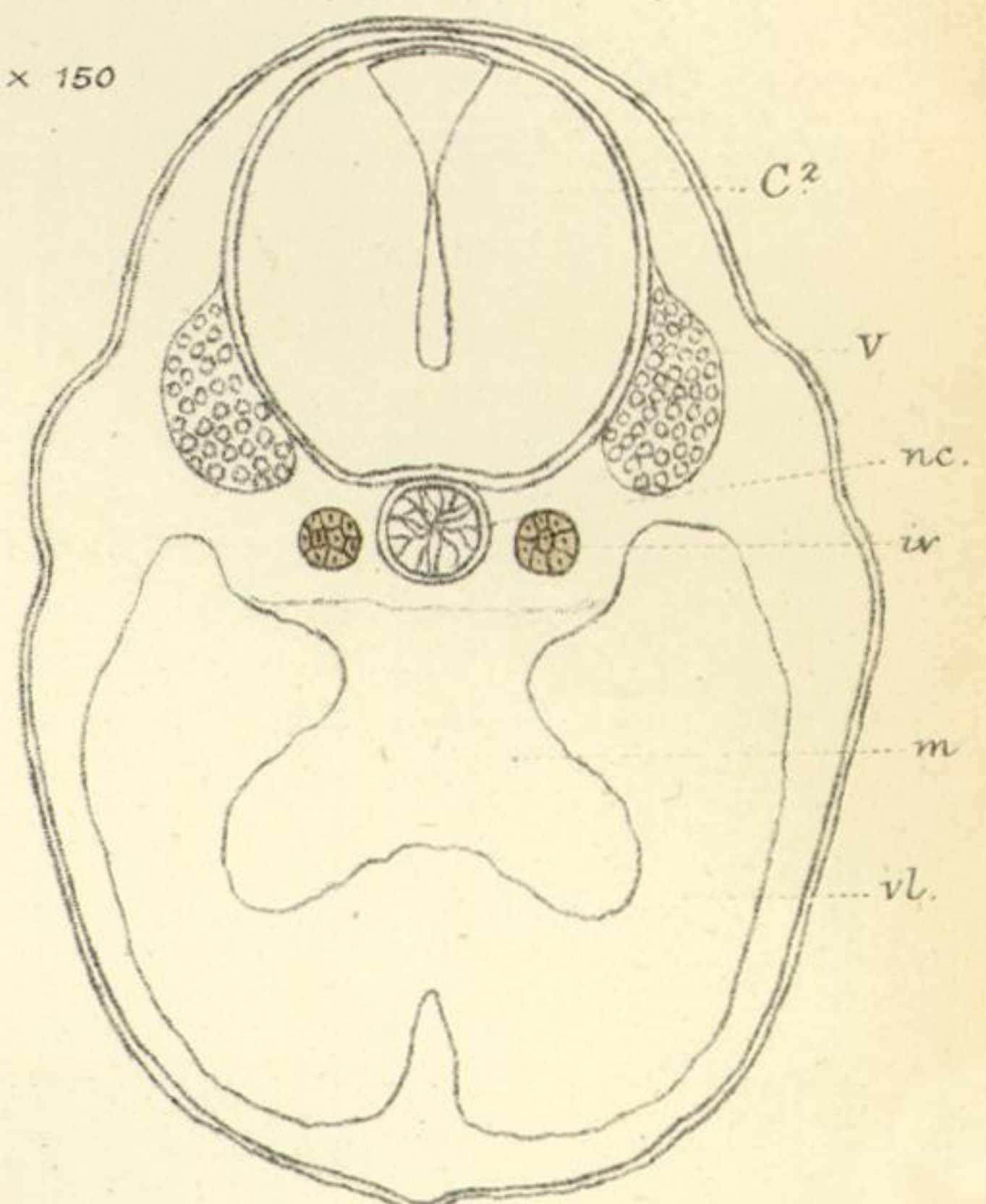
4 × 150



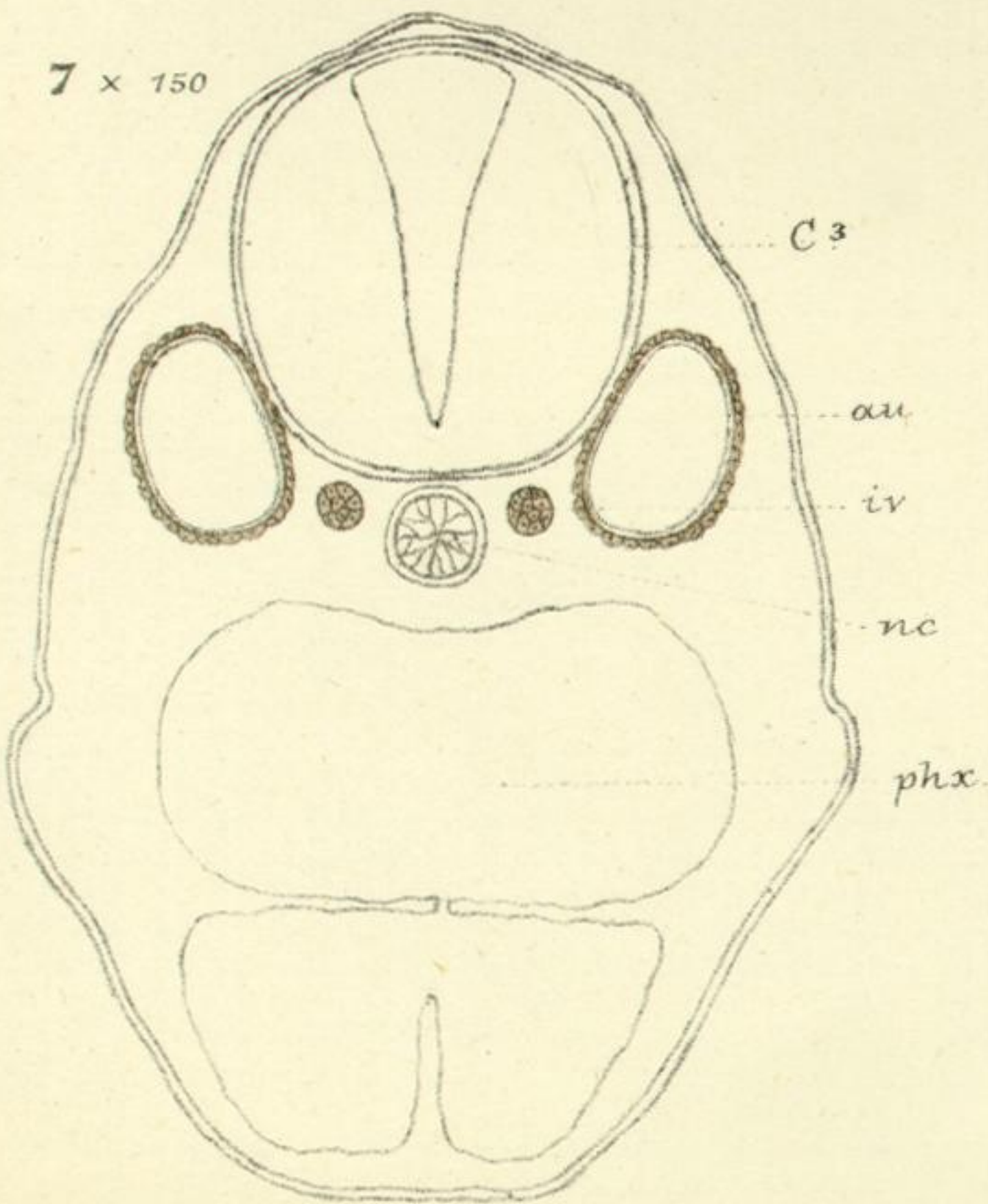
5 × 150



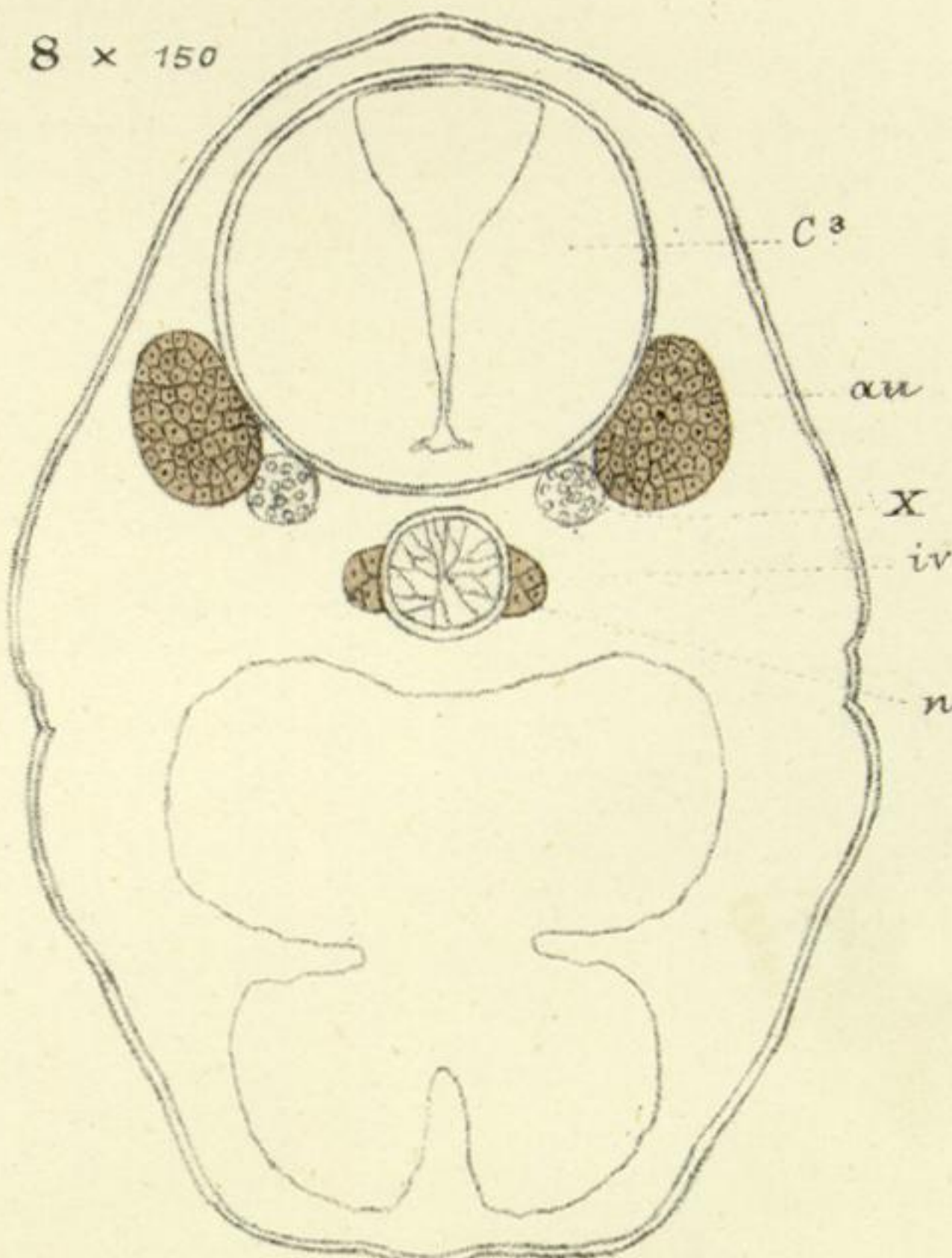
6 × 150



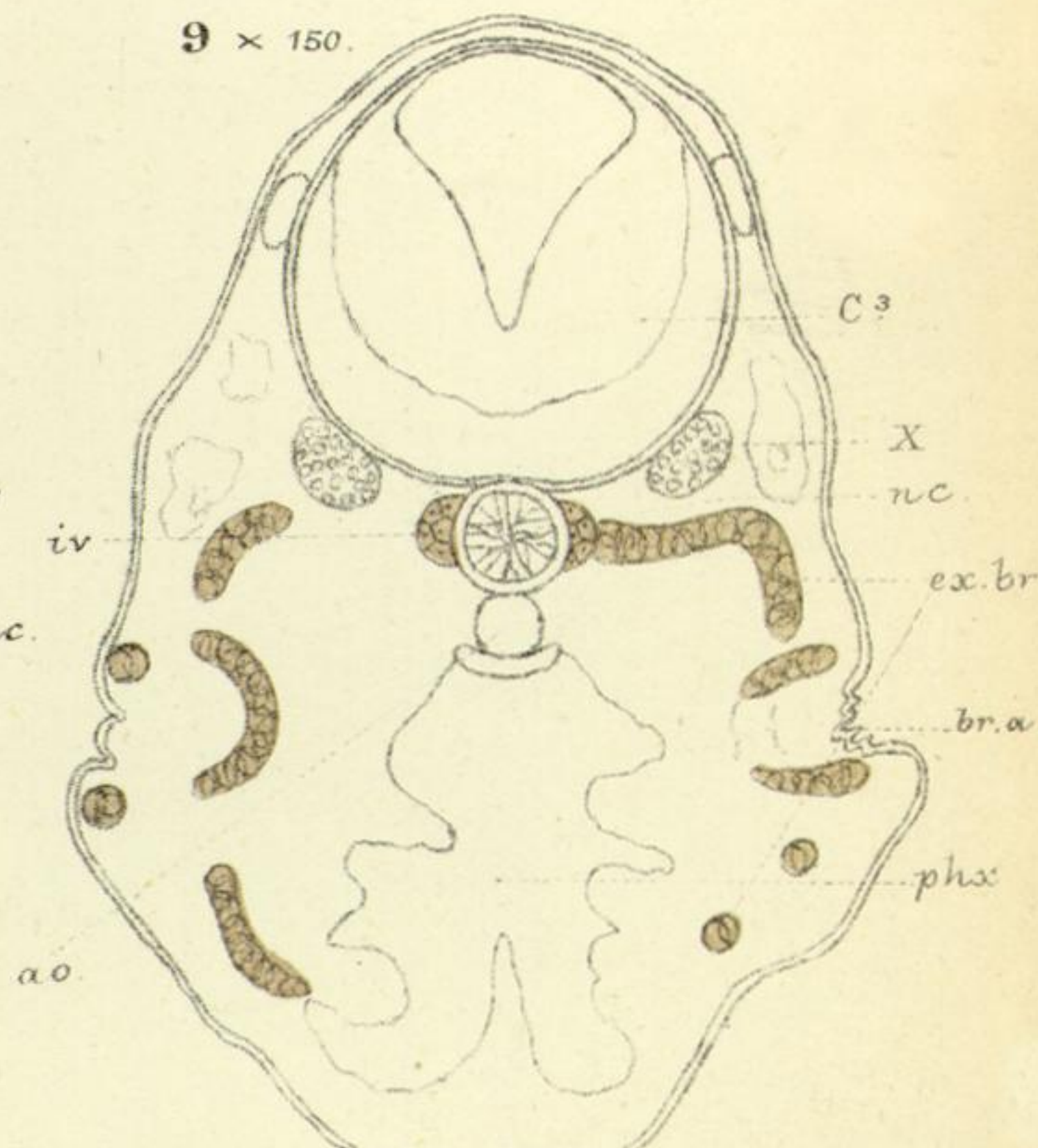
7 × 150



8 × 150



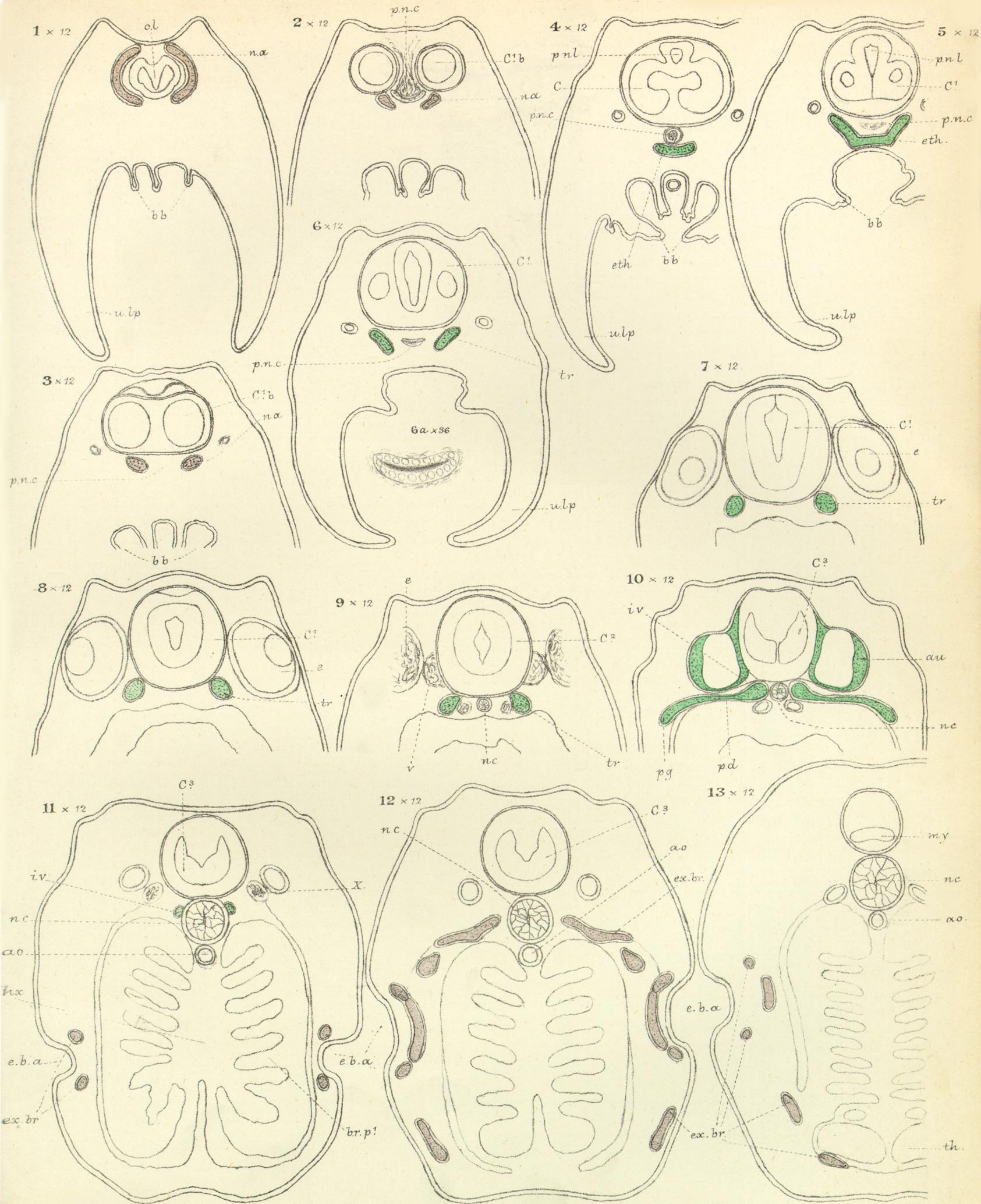
9 × 150











PETROMYZON FLUVIATILIS.