

PHILOSOPHICAL TRANSACTIONS.

I. *On the Structure and Development of the Skull in the Mammalia.*—

Part II. *Edentata.*

By WILLIAM KITCHEN PARKER, *F.R.S.*

Received May 26,—Read June 19, 1884.

[PLATES 1-15.]

INTRODUCTION.

SINCE my first attempt to work out the Mammalian type of skull, the greater part of my time has been spent upon Cold-blooded Vertebrata—Fishes, Amphibia, and Reptiles. But between the early part of 1873, when my paper on the skull of the Pig was presented to the Royal Society, to the beginning of 1882, when I was able to take up this Class once more, no time or chance was lost as far as materials for work go; during those nine years a very large collection of embryos and of early young of the various types of Mammalia was made.

This collection of materials is still going on, and will I trust go on for years to come. No work lies before me of greater importance; and if the skull, in the Orders of this, the highest Class, can thus be illustrated, it will give some roundness and shape to the efforts and labour of the whole life of a never-weary worker.

I am very grateful to the friends that have so kindly and zealously helped me by presents of specimens; in this present piece of work I have had the greater part of my materials from the following well-known Biologists; viz., Professor W. H. FLOWER, F.R.S., Dr. GÜNTHER, F.R.S., Professor St. GEORGE MIVART, F.R.S., Dr. P. L.

MDCCCLXXXV.

B

SCLATER, F.R.S., and H. M. WARD, Esq. (who lost no opportunity during his Botanical work in Ceylon of procuring valuable specimens for Professor HUXLEY and me).

The order in which these materials are worked depends upon their fulness in any particular group; the Edentata are worked out, and the Insectivora are almost finished; then will come the Marsupials; this is not the "order of Nature," but of "necessity;" and those who are interested in these matters must classify the data, when they have been collected.

Nevertheless, I shall aim at bringing the Monotremata forward as soon as possible; thanks to Dr. BENNETT, of Sydney, and to Professor MOSELEY, I am able to begin at the *Ornithorhynchus* and the *Echidna*. But my hopes, in that quarter, largely rest upon the results to be obtained by those whom the liberality of the Royal Society has put into a position for finding such treasures as the early stages of those archaic forms of Mammalia.

As to the "Order" now under consideration, the Edentata, I have worked out the skull in one or more embryos, as well as young, in all but the Anteaters;* happily, of that type I have the young in a very instructive stage.

My richest materials are in the family "Dasypodidæ," or Armadillos. With this type I shall begin; it is perhaps, on the whole, the best, as it is not so intensely specialised as the rest, and thus is fittest for comparison with the Insectivora; the forms that are found on the highway of Mammalian life, and not in a bye-path, like the Edentata.

The Insectivora will be described in my next, or third, part.

BIBLIOGRAPHY.

a. On the Zoology, Embryology, and Morphology of the Edentata, and of the Mammalia, generally.

ALBRECHT, P.

1. 'Mémoire sur le Basiotique.' Bruxelles, 1883.
2. 'Sur la Fossette Vermienne du Crâne des Mammifères.' Avec une planche. Bruxelles, 1884. (Contains Marsupials, Edentates (*Dasypus novemcinctus*), Sloths, Orycteropus, Tatusia, Myrmecophaga.) Fig. 1, Halmaturus; fig. 2, Dasypus.
3. 'Sur les os intermaxillaires.' Bruxelles, 1883.
4. 'Sur la Valeur morphologique de l'Articulation mandibulaire du cartilage de MECKEL et des osselets de l'Ouïe.' Bruxelles, 1883.
5. 'Sur la Valeur morphologique de la Trompe d'Eustache,' &c. Bruxelles, 1884. (Important for Mammalian homologies.)

* I have since received from Professor TREVES an embryo of *Cycloturus* that has not yet been worked out. An account of its skull will be given as an Appendix to the present paper.

- ALLEN, HARRISON, M.D. "On a Revision of the Ethmoid Bone in the Mammalia." Bulletin of the Museum of Comparative Anatomy at Harvard College, Cambridge, Mass., U.S. Nov., 1882; plates 1-7, pp. 135-164.
- BALFOUR, F. M. 'A Treatise on Comparative Embryology.' Vol. 2. London, 1881.
- BERGMANN, C. 'Einige Beobachtungen und Reflexionen über die Skelettsysteme der Wirbelthiere, deren Begrenzung und Plan.' Göttingen, 1846.
- BETZ, F. "Über den Primordialschädel des Menschen." 'FRORIEP's Notizen,' December, 1848.
- BIDDER, A. "De cranii conformatione ratione imprimis habitu Jacobsonii de cranio primordiali ejusque ossificatione sententiæ." Dorpat, 1847.
- BLAINVILLE, DE. 'Osteographie,' 1835-54.
- BOETTCHER, A.
1. "Bau und Entwicklung der Schnecke." Denkschriften d. Kaiserl. Leop. Carol. Akad. d. Wissens., vol. xxxv.
 2. Several papers on the structure of the ear in VIRCHOW's Archiv., Band xvii. and xix.; 'Archiv für Anatomie und Physiologie,' 1869; 'Archiv für Ohrenheilkunde,' Band vi., 1871.
- BORN, G. "Die Nasenhöhlen und der Thränennasengang der Amnioten Wirbelthiere." 'Morphologisches Jahrbuch,' Bd. ii., 1876; Bd. v., 1879; and Bd. viii., 1882.
- BRONN'S "Klassen und Ordnungen des Thierreichs." Abtheilung Säugethiere, von C. G. GIEBEL, 1874-79.
- COPE, E. D. "On the Foramina Perforating the Posterior part of the Squamosal Bone of the Mammalia." Read before the Amer. Phil. Soc., Feb. 6, 1880.
- DECKER, FRIEDRICH. "Über den Primordialschädel einiger Säugethiere." 'Zeitschrift für wissenschaftliche Zoologie,' 1883, pp. 190-233, plate 9.
- DOLLO, J. "On the Malleus of the Lacertilia, and the Malar and Quadrate Bones of the Mammalia." Quart. Jour. Micr. Sci., xxiii., 1883. This paper contains a complete list of the literature on the ear, and a tabular arrangement of the views held by previous authors.
- DORAN,* A. G. H. "Morphology of the Mammalian Ossicula Auditûs." Trans. Linn. Soc., Ser. 2. Zool., vol. i., pp. 371-497, plates 58-64.
- DURSY, E. "Zur Entwicklungsgeschichte des Kopfes des Menschen und der höheren Wirbelthiere." Tübingen, 1869.
- EDWARDS, HENRI MILNE et ALPHONSE MILNE. 'Recherches pour servir à l'histoire naturelle des Mammifères' (2 vols.). Paris, 1868-1874.
- FLOWER, W. H.
1. "On the Development and Succession of the Teeth in the Armadillos (*Dasypodidae*)." Proc. Zool. Soc., 1868, pp. 378-380.
 2. 'An Introduction to the Osteology of the Mammalia,' 1885.
 3. "On the Mutual Affinities of the Animals composing the Order *Edentata*." Proc. Zool. Soc., 1882, pp. 358-367.
 4. Art. "Mammalia." Encyc. Brit., 9th edition, 1883.
 5. "On the Orders and Families of the Mammalia." Proc. Zool. Soc., April 17, 1883, pp. 178-186.
- FORBES, W. A. "On some points in the Anatomy of the great Anteater (*Myrmecophaga jubata*)." Proc. Zool. Soc., 1882, pp. 287-302.
- FRASER, A. "On the Development of the Ossicula Auditûs in the Higher Mammalia." Phil. Trans., 1882, Part III., pp. 901-925, Plates 54-58.

* Mr. DORAN gives a copious Bibliography of these special parts.

- GARROD, A. H. "Notes on the Anatomy of *Tolypeutes tricinctus*, with remarks on other Armadillos." Proc. Zool. Soc., 1878, pp. 222-230.
- GEGENBAUR, C.
1. "Ueber primäre und secundäre Knochenbildung, mit besonderer Beziehung auf die Lehre von dem Primordialcranium." 'Jenaische Zeitschrift,' vol. iii., 1867,
 2. 'Comparative Anatomy.' Translated by Professor E. RAY LANKESTER and JEFFERY BELL. London, 1878.
- GRAY, J. E.
1. "Revision of the Genera and Species of the Entomophagous Edentata." Proc. Zool. Soc., 1865, pp. 359-386.
 2. "Notes on the Species of *Bradypodidae* in the British Museum," Proc. Zool. Soc., 1871, pp. 428-449, plates 34-37.
- HANNOVER, A.
1. "Primordial brusken og dens Forbening i det Menneskelige Kranium fer Fødselen." Kopenhagen, 1880.
 2. "On the Formation of Vertebrae in the Human Skull." Transact. Internat. Med. Cong. London, 1881; 'Anatomy,' vol. i.
- HASSE, C. "Die vergleichende Morphologie und Histologie der häutigen Gehörorgane der Wirbelthiere." Leipzig, 1873.
- HEAPE, WALTER. "The Development of the Mole (*Talpa Europæa*)." Quart. Journ. of Microscop. Sc. for July, 1883.
- HENSEN, V.
1. "Zur Morphologie der Schnecke des Menschen und der Säugethiere." Zeits. f. wiss. Zool., vol. xiii., 1863.
 2. "Bemerkungen gegen die Cupula terminalis." 'Archiv für Anatomie und Physiologie,' 1878.
- HUNT, DAVID. "A comparative sketch of the Development of the Ear and Eye in the Pig." 'Transactions of the International Otological Congress,' 1876.
- HUSCHKE. "Ueber die erste Bildungsgeschichte des Auges und Ohres beim bebrüteten Kücklein." 'Isis,' 1831, and MECKEL'S 'Archiv,' vol. vi.
- HUXLEY, T. H.
1. "On the Theory of the Vertebrate Skull."—Croonian Lecture. Proc. Roy. Soc., Nov. 18, 1858.
 2. 'Elements of Comparative Anatomy.' London, 1864.
 3. 'A Manual of the Anatomy of Vertebrated Animals.' London, 1871.
 4. "On the Representatives of the Malleus and Incus of the Mammalia in the other Vertebrata." Proc. Zool. Soc., 1869, pp. 391-407.
 5. "On the Application of the Laws of Evolution to the Arrangement of the Vertebrata, and more particularly of the Mammalia." Proc. Zool. Soc., Dec. 14, 1880, pp. 649-662.
- HYRTL, J.
1. "Vergleichend-anatomische Untersuchungen über das innere Gehörorgan." Prag, 1845.
 2. "*Chlamydomorphus truncatus*." 'Denkschriften der Wiener Akademie,' ix., 1855.
- KÖLLIKER, A.
1. "Mittheilungen der Naturforschenden Gesellschaft in Zurich," 1847.
 2. "Berichte von der Königl. Zootomischen Anstalt zu Würzburg." 2. Berichte f. d. Schuljahr 1847-48; Leipzig, 1849.
 3. "Allgemeine Betrachtungen über die Entstehung des knöchernen Schädels der Wirbelthiere." Berichte v. d. Königl. Zoot. Anstalt zu Würzburg, 1849.

4. "Die Theorie des Primordialschädels." Berichte v. d. Königl. Zoot. Anstalt zu Würzburg, 1850, II. Bd., p. 281.
 5. "Entwicklungsgeschichte der Menschen und der höheren Thiere." Zweite Auflage. Leipzig, 1880.
- MECKEL, J. W. "Ueber die osteologischen Differenzen der Igelarten." Beitrag zur vergl. Anat., Heft I., pp. 34-56; 1808.
- MEYER, H. "Der Knorpel und seine Verknöcherung." MÜLLER's 'Archiv,' 1849, p. 292.
- MOLDENHAUER, W. "Zur Entwicklung des mittleren und äusseren Ohres." 'Morphologisches Jahrbuch,' vol. iii., 1877.
- MURIE, JAS. "On the Habits, Structure, and Relations of the Three-banded Armadillo (*Tolypeutes conurus*)." Geoff. Is. Trans. Linn. Soc., vol. xxx., pp. 71-132, plates 20-26.
- OWEN, R. "On the Anatomy of the Great Anteater." Part I., Trans. Zool. Soc., iv., pp. 117-140, plates 37-40; Part II., *ibid.*, pp. 179-181, plates 51-53.
- PARKER, W. K. "On the Structure and Development of the Skull in the Pig (*Sus scrofa*)." Phil. Trans., 1874, pp. 289-336, Plates 28-37.
- PARKER, W. K., and BETTANY, G. T. "The Morphology of the Skull." 1877.
- POUCHET. "Mémoire sur le Grand Fourmitier." Paris, 1874.
- RAPP. "Anatomische Untersuchungen über die Edentaten." 2te Auflage; Tübingen, 1852.
- RATHKE, H. "Vierter Bericht über das Naturwissenschaftliche Seminar zu Königsberg, nebst einer Abhandlung über die Entwicklung des Schädels der Wirbelthiere." Königsberg, 1839.
- REICHERT, K. B.
1. "Vergleichende Entwicklungsgeschichte des Kopfes der nackten Amphibien, nebst den Bildungsgesetzen des Wirbelthierkopfes." Königsberg, 1833.
 2. "Zur Kontroversa über den Primordialschädel." MÜLLER's 'Archiv,' 1849, p. 448.
- REISSNER. "De auris internæ formatione." Inaug. Diss., Dorpat, 1851.
- SALENSKY, W. "Beiträge zur Entwicklungsgeschichte der knorpeligen Gehörknöchelchen bei Säugethieren." 'Morphologisches Jahrbuch,' Bd. vi., pp. 415-432, plate 20.
- SPONDLI, H. "Über den Primordialschädel der Säugethiere und des Menschen." Zürich, 1846.
- STEIFENDSAND. "Das Gehörorgan der Wirbelthiere." 'Archiv für Anatomie und Physiologie,' 1835.
- STANNIUS, H. MÜLLER's 'Archiv,' 1849, p. 532.
- SUTTON, J. B.
1. "The Ossification of the Temporal Bone." Jour. of Anat. and Phys., vol. 17, pp. 498-508, plate 18.
 2. "Development of the Inferior Maxilla." Reprinted from Trans. Odont. Soc., 1883.
- TUTTLE, ALBERT H. "The Relation of the External Meatus, Tympanum, and Eustachian Tube to the first Visceral Cleft." Proc. Amer. Acad. Sc., 1883-84, pp. 111-132, plates 1, 2.
- URBANTSCHITSCH, V. "Ueber die erste Anlage der Mittelohres und des Trommelfelles." Mittheil. a. d. Embryol. Institut, Wien, Heft i., 1877.
- WEBER, L. "De aure et auditu hominis et animalium." Lipsiæ, 1820.
- WHITE, E. W. "Notes on *Chlamydophorus truncatus*." Proc. Zool. Soc., 1880, pp. 8-11.
- WIEDERSHEIM, ROBT. "Lehrbuch der vergleichenden Anatomie der Wirbelthiere." Jena, 1883.

b. On JACOBSON'S Organ.

BALOGH. "Das JACOBSON'sche Organ des Schafes." *Sitzungsber. d. Kais. Akademie der Wiss. zu Wien*, vol. xlii, p. 449.

BORN, GUSTAV.

1. "On JACOBSON'S Organ." *Sitzung d. Naturw. Section*, August, 1877, d. Schlesischen Ges. f. Vaterl. Cultur.
2. "Ueber die Nasenhöhlen und den Thränennasengang der Amphibien." *'Morph. Jahrbuch,'* Bd. ii., 1877, plates 39-41, pp. 577-646.
3. "Die Nasenhöhlen und der Thränennasengang der Amnioten Wirbelthiere." *'Morph. Jahrb.,'* Bd. v., 1879, und Bd. viii., 1882.

FLEISCHER, R. "Beiträge zur Entwicklungsgeschichte des JACOBSON'schen Organs und zur Anatomie der Nase." *'Sitzungsberichte der physikalisch-medizinischen Societät für Erlangen,'* 1877.

GRATIOLET. *'Recherches sur l'organe de JACOBSON.'* Paris, 1845.

JACOBSON, L. MÜLLER'S *'Archiv für Anatomie, Physiologie und wissenschaftliche Medicin,'* 1844.

KLEIN, E.

1. "Contributions to the Minute Anatomy of the Nasal Mucous Membrane." *'Quarterly Journal Microscopical Science,'* vol. xxi, new ser., pp. 98-113, pl. 7.
2. "Histological Notes." *Ibid.*, pp. 114-118.
3. "The Organ of JACOBSON in the Rabbit." *Q. J. M. S.*, xxi., 1881.
4. "A further Communication to the Minute Anatomy of the Guinea Pig." *Q. J. M. S.*, 1881.

KÖLLIKER, A.

1. "Ueber die JACOBSON'schen Organe des Menschen." *'Gratulationschrift der Würzburger Medicin-Fakultät für F. von RINECKER.'* Leipzig, 1877.
2. *'Verhandlungen der physikalisch-medizinischen Gesellschaft zu Würzburg,'* xvii. (1883), pp. 229-257 (four plates).*

LEBOUCQ, H. "Le Canal naso-palatinal chez l'Homme." *'Archives de Biologie,'* vol. ii., 1881.

LEGAL, E. "Die Nasenhöhlen und der Thränennasengang der amnioten Wirbelthiere." *'Morphologisches Jahrbuch,'* Bd. viii., 1882.

LEYDIG. *'Lehrbuch d. Histologie,'* p. 218.

LOEWE. *'Beitrag zur Anatomie der Nase und Mundhöhle.'* Berlin, 1878.

PARKER, T. J. *'Zootomy'* (pp. 334-336, fig. 64; Rabbit). London, 1884.

WIEDERSHEIM, R.

1. "Das Kopfskelet der Urodelen." *'Morphologisches Jahrbuch,'* Bd. III., 1877.
2. *'Die Anatomie der Gymnophionen.'* Jena, 1879.
3. "Die Stammesentwicklung des JACOBSON'schen Organs." *'Tageblatt der 54. Versammlung deutscher Naturforscher und Aerzte in Salzburg,'* 1881.

* For an abstract of this important paper, "On the Development of the Optic and Olfactory Organs of Human Embryos," see *Jour. Roy. Micros. Soc.*, 1884, pp. 201-203.

DASYPODIDÆ.

First Stage. Embryos of *Tatusia hybrida*, $1\frac{2}{3}$ inch long, measured, in these, and the rest, from snout to root of tail (see Plate 1, figs. 7, 8).

Second Stage. Embryos of *Tatusia hybrida*, 2 inches long.

Third Stage. Embryos of *Tatusia hybrida*, 3 inches long.

Fourth Stage. Embryos of *Tatusia peba*, 3 inches long.

Fifth Stage. Embryo (ripe) of *Tatusia hybrida*, 4 inches long. Ripe young of *Dasypus villosus*, $3\frac{2}{3}$ inches long.

Sixth Stage. Young (new born ?) of *Tatusia peba*, $4\frac{1}{2}$ inches long.

First Stage.—*Tatusia hybrida* ($1\frac{2}{3}$ inch long).

In this, the youngest specimen obtained, I shall describe the chondrocranium with its commencing bony centres and visceral arches, as seen in dissection, and then give its structure in detail, as illustrated by a series of vertically transverse (transparent) sections.

Afterwards, in the second stage, the investing bones will be described in their form, as well as in their relations.

General remarks upon the early skull of the Mammal.

So great is the uniformity of the early chondrocranium in the Eutheria, or Placental Mammals, that this drawing (Plate 2, fig. 1), made from the skull of an outlying and low type, might serve as a diagram wherewith to illustrate the skull, at this stage, of the types of this Order, and of all the Orders above it.

The figure of a chondrocranium like this, but a little less advanced, before the osseous centres have commenced in it—that of the Mole—will be given in my next paper; and such a skull comes very near to that of a Shark or, still better, of a Skate.

The parts, or rather *regions*, of which it is composed, correspond very exactly with what is seen in those generalised, but not *low*, Fishes; and in this specimen, with bony centres appearing, the level is obtained which is permanent in the skull of the Dipnoi, and of such a low Ganoid as the Paddle-fish (*Polyodon*).*

As in Cartilaginous Fishes and Amphibians, the chondrocranium may be compared to a basin or a boat, the upper part being unfinished, leaving a membranous fontanelle of greater or less extent; this is only partially filled in, at present, by the investing bones, the frontals and parietals (*f., p.*).

The outline of this sectional view is very elegant, and quite similar to that of a vertical section of a Bird's skull at a like stage, except that the nasal roof-cartilages

* See BRIDGE, "On the Skull of *Polyodon folium*," Phil. Trans., 1878, Plates 55–57, pp. 683–733.

run on along the whole extent of the median keeled bar—the intertrabecula ; in the Bird they stop short, leaving a free cartilaginous rostrum, like that of a Shark or Skate, which, however, only lasts until it has served as a model on which the huge premaxillaries of the Bird are formed.

In the sides of this hollow cartilaginous structure, near the hind part, the large oval auditory capsules (*a.s.c.*, *chl.*) are seen to have great distinctness; they are, however, confluent with the chondrocranium proper, at various points—above, behind, and below, as the sections will show. These are the only sense-capsules displayed in a preparation of this kind, for the eye-balls are quite free from the solid cranial structure (and are, indeed, outside, in such a view as this), and the left nasal labyrinth has been removed.

Before describing this figure in detail, there is one remark to be made, namely, that here we have, clearly shown, the true *diagnostic mark* of a Mammalian skull. This mark is the *rupture* of the side walls, due to the pressure of the large lateral masses of the cerebrum. In front of the auditory capsules there is a large elegantly semi-circular opening, the crown of the arch looking upwards and forwards.

Only the lower half of the wall has thus broken outwards ; this “fault” forms the alisphenoid (*al.s.*), whilst the orbitosphenoid (*o.s.*), the so-called “lesser wing,” is many times its size, and is continuous, over the archway, with the cartilage that runs on, backwards, into the supraoccipital region (*s.o.*)

There is nothing similar to this in that Sauropsidan skull which comes nearest to that of the Mammal ;—the skull of the Crocodile (see *Trans. Zool. Soc.*, vol. xi., plate 65), whilst in Birds the orbitosphenoids are very small even when they are most developed, as in *Struthio* (see *Phil. Trans.*, 1866, Plate 7), and in that Class the alisphenoids almost finish the cranial cavity, being turned inwards towards each other, on each side of the back part of the orbital septum.

I lay especial stress upon this rupture, outwards, of the alisphenoid, and of the fact that the nasal roofs utilise the whole of the huge high-crested intertrabecula, because these are the most distinctive marks of the Mammalian skull, and they arise out of two things in which the Mammal shows its great superiority to even the highest Sauropsida, namely, the huge volume of the cerebrum, and the tenfold complexity of the nasal labyrinth.

A third clear diagnostic is seen in this very figure ; this is the peculiar development of the antero-inferior part of the oblique auditory capsule, due to the development of the coils of the cochlea (figs. 1, 6, 8, *chl.*).

So that, at once, correlated with the sudden expansion, so to speak, of the cerebrum, we have these *new* and most important improvements in the organs of smell and of hearing.

At first sight, seeing how large the median bar (intertrabecula) is, with its inter-nasal crest (perpendicular ethmoid and septum nasi,—*p.e.*, *s.n.*), it might be supposed

that the Mammalian skull was of the *high* kind, like that seen in many Teleostean Fishes, in Lizards, and in Birds.

It is not so, however, but belongs to the *low* kind, seen in Selachians and Amphibians ; and, like theirs, is hinged on to the spine by a pair of occipital condyles.

Hence the eye-balls are kept far apart, instead of coming very near each other as in most Birds, where, often, nothing but a membranous fenestra is found between the right and left capsules, and their special muscular apparatus.

But the *face*, as well as the *skull*, of the Mammal shows marks of excellence, such as are not seen in the Sauropsida, even in the higher kinds, as Crocodiles and Birds.

The great development of the nasal organs is correlated with a most remarkable growth of the bones of the upper jaw and the palate to form the "hard palate."

This is found in rudiment even in the Chelonia and in Birds ; but especially in the Crocodilia, where, however, its excessive development—as in certain Edentata, *e.g.*, *Myrmecophaga*—is not dependent upon, or correlated with, any great improvement in the organs of smell, but has to do with the peculiar manner in which these monsters take their prey.

But that great improvement just spoken of as appearing in the organ of hearing in the Mammal has wrought a change in the hinder face that has *two* most important bearings.

From the first promise of an ear-drum in the tailed Amphibia, to its highest fulfilment in the noblest of the Oviparous tribes—the Birds that nestle on high ("Aves Altrices"),—the only element from the visceral arches that is used for carrying the vibrations of the air inwards to the organ of hearing is the uppermost part of the hyoid arch—the "pharyngobranchial" element of the 2nd postoral arch, to speak morphologically.

From the Salamandroids to the Singing Birds, all through the Amphibia and Sauropsida, the 1st postoral arch—which forms both the upper and lower jaw—is only segmented *once*, that is, into an epibranchial and a ceratobranchial element, or joint.

The upper piece is specially termed the "quadrate," and the lower the "articulo-Meckelian;" the one forms the swinging piece, hinge, or pier, to the compound lower jaw, and the other its axis or pith, the part which becomes covered with more or fewer "investing bones."

In these low "Eutheria," and also in both the "Metatheria," and the "Prototheria" (Marsupials and Monotremes), the modified visceral rod that runs through the drum cavity has *two* new elements added to the *one* (single or variously segmented) element derived from the hyoid arch.

This is an apparently *sudden* change, for we have it in the lowest or teatless Mammals; their *ancestry*, that should show us the earlier steps of the change, are, unfortunately, all extinct.

In this dilemma not only Zoology, but Palæontology also, fails us utterly, but Embryology comes in with every stage and every link.

I have worked out the early condition of these parts in several kinds of Marsupials, and in the young of *Ornithorhynchus*; but even in the lower Eutheria, the Edentata, now to be described, and in the large and varied group of the Insectivora, I have been able to trace every step in the transformation of these parts.

I am now satisfied that the *incus* is the upper element of the first or mandibular arch; both Professor SALENSKY'S and Professor FRASER'S researches put this, I think, beyond doubt; and my own attempts, for a long time, to make the hyoid theory of this part agree with facts, only kept the subject in hopeless confusion.

The new elements of the ear-chain are, then, the arrested quadrate or incus, and the arrested and *amputated* articular region of the articulo-Meckelian rod, or primary lower jaw. The bony part of the "ramus" is the well-known dentary, with the coronoid and splenial bones in a sub-distinct state; the cartilage for the *new articulation* of the lower jaw is derived from a large superficial slab—a "lower labial"—the like of which is not found again until we get as low down as the Chimæroids.

From this is derived the hinder half of the ramus, by transformation of its substance into bone; and from this we get the cartilage, both of the condyle and the glenoid cavity, and also of the intervening "meniscus."

Of course the drum cavity is the "first cleft;" and the concha auris, with its segmented *meatus-tube*,—the tympanic bone, the tympanic bulla, and the cartilaginous lining of the Eustachian tube,—all these are parts of a curiously specialised opercular growth belonging to the hinder edge of the first visceral fold and arch.

This last assertion has not been made as a stride across the types, from the Mammal to the Elasmobranch, but is the result of a very slow, step by step process, made during many years, "along all the lines" of Vertebrate morphology.

Vertical section of the skull of Tatusia hybrida.—First Stage (embryo, 1 $\frac{2}{3}$ inch long).

The chondrocranium is now at its highest development; after this it will begin to decline, for osseous centres are already developing in it; these are the basioccipital, exoccipital, supraoccipital, basisphenoid, and alisphenoid (Plate 2, fig. 1, *b.o.*, *e.o.*, *s.o.*, *b.s.*).

The notochord (*nc.*) is still to be seen in the basioccipital region, it is hooked downwards in front. The basioccipital bone (*b.o.*) occupies the middle half of the cartilage between the foramen magnum and the posterior clinoid elevation; this latter is a moderately high ridge running crosswise.

The cartilage of the base of the skull becomes thicker in front of that ridge, and rises gently until it reaches the beginning of the great olfactory fossæ; the basisphenoid (*b.s.*) already occupies the hinder half of this more elevated tract of cartilage.

The rest of the base of the skull forms a low triangle whose base is somewhat longer than the lower part which reaches backwards to the foramen magnum.

The postero-superior side of this triangle is developed into two rounded lobes, the upper or fore lobe is the larger of the two. The hinder lobe is the top of the perpendicular ethmoid (*p.e.*), behind the olfactory fossa with its cribriform plate (see Plate 5, fig. 1); whilst the front or upper enlargement is the *crista galli*, in solid cartilage.*

The longer upper side dips down gently to the snout, and is a little concave; the *triangle* does not end in a point, but in a rounded lobe. The lower part of all this nasal fore half of the basis cranii is a thick beam of cartilage, carrying a much thinner crest on its upper edge, which is continuous with it.

Embryologically, the "investing mass" may be said to reach to the posterior clinoid wall; but the notochord has retreated relatively from that point; the rest of the cartilage is "trabecular."

But the paired trabeculæ, themselves, only reach as far as to the middle of the proper olfactory region, the septum of which bears the name of "perpendicular ethmoid" (*p.e.*); the filling in between these, behind, and all the rest of the middle part is formed by an azygous growth, the "intertrabecula."

The sides of the cartilaginous basin, whose narrow elongated floor has just been described, are formed by a very large sheet of cartilage, right and left. This just reaches the roof, or cover of the basin, in the hinder half, and the sides are imperfect in two places.

The occipital region, only, forms a complete belt or ring of cartilage.

The postpituitary region of the skull, for two-thirds of its horizontal, and for two-thirds of its vertical, extent, is occupied by the intruded auditory capsules (*a.s.c.*, *chl.*), which, above, below, and behind, have coalesced with the cartilage of the proper chondrocranium.

A more than semicircular space in front of these large capsules is occupied by a large fenestra whose very accurate arched outline looks forwards and upwards. The sinuous cartilaginous wall round this space is the orbitosphenoidal region, passing by a band, equal in width to the fenestra above, into the large supratemporal (or *sub-parietal*) tract (*s.t.c.*), which in turn runs into the crown of the occipital arch.

Half the preauditory fenestra is imperfectly occluded by the alisphenoid (above *b.s.*),

* In my paper on the Ostrich's skull (Phil. Trans., 1866, Plate 7) the counterpart of this crest is lettered *cr.g.*, or *crista galli*, and is described as such in the text (p. 118). But in the paper on the Fowl's skull (Phil. Trans., 1869, Plate 83) this part is not lettered, for I had been reminded by a friendly critic that the *crista galli* of Man is formed by ossification of fibrous tissue in the fore part of the falx cerebri. It is, however, preformed in cartilage in many Mammals, notably in these Edentata, and my lettering in the figures of the Ostrich's skull is correct. In the same paper (p. 120) the quadrate cartilage is identified with the incus; that view of it is, I feel satisfied, now, quite correct.

or free, outstanding wing, not of cartilage now, but of bone. This fan-shaped tract has its broad part ossified separately, from the lower part or stem (see fig. 6, *al.s.*)*

At a distance from the basioccipital equal to the width of both the basal and lateral bony centres, the exoccipitals (*eo.*) have appeared, they form part of the selvedge round the foramen magnum. Above another equally large space of cartilage we see the supraoccipital (*so.*): it has a right and left half (see also fig. 6, *so.*); each half is ear-shaped, the broad end being near the mid-line.

A considerable fossa runs between the occipital arch and the auditory capsule; this is occupied by the "lateral sinus" (*s.c.*), which communicates with the outer veins through a large hole, both above and below.

The foramina for the postauditory nerves are seen in this view; that for the hypoglossal (XII.) in the middle of the space between the exoccipital and basioccipital, and the double space for the vagus and glossopharyngeal (X., IX.) in the interspace or fissure between the auditory capsule and the front side of the occipital arch.

The multiperforate "meatus internus" for the 7th and 8th nerves (VII., VIII.) has, beneath and in front of it, the projecting cochlea (*chl.*); and above it the arches of the anterior and posterior semicircular canals (*a.s.c.*, *p.s.c.*), meeting in one common sinus; these can be seen shining through the cartilage.

The lower alisphenoidal centre is deeply notched (above *b.s.*) to form an imperfect foramen ovale (*V³.*) for the third branch of the trigeminal; the second and first branches (*V^{1,2}.*) escape through the sphenoidal fissure—between the bulging alisphenoid and the concave posterior margin of the stem of the huge orbitosphenoid (*o.s.*). The lesser cranial nerves (3rd, 4th, 6th) escape also through this space, but the optic foramen (II.) is an oval hole pierced through the orbitosphenoidal stem. No part of the anterior sphenoid is ossified at present, nor any part of the nasal region.

The turbinal outgrowths of the proper olfactory region shown by the slicing away of the cartilage (fig. 5, *u.tb.*) are very numerous; above and behind them, in the huge recesses for the olfactory lobes, the numerous branches of the 1st nerve are seen to be escaping through a membranous floor, which is having bands of cartilage formed in it (*cr.p.*), that pass round the various fissures through which the nervous bands escape.

The cartilage of the roof of the nasal labyrinth is shown in the main figure (fig. 1) as cut away from the large partition wall. In front, the alinasal region, behind the opening and near the mid-line, gives off a curious "recurrent cartilage" (*rc.c.*) of a lanceolate shape, and scooped along the outside, except in front, where it forms a tube.

These cartilages (right and left) protect "JACOBSON'S organs," which are partly encapsuled by them; these parts are related to two small bones and to the vomer, as I shall show soon. In the figure of this vertical section the frontals and parietals (*f.p.*) are shown, helping to fill in the great fontanelle; the nasals (*n.*) are seen over

* In Birds, generally, and in many Rodents, the alisphenoid is formed from two osseous centres, but in a manner very different to what is shown here.

the septum nasi (*s.n.*); the vomer (*v.*) under it, and the palatine plates of the maxillaries and palatines (*mx.*, *pa.*) are shown as forming the hard floor to the shallow naso-palatine canal. The "fault" in the skull wall, where the small alisphenoid is thrust out, is partly filled in externally by the squamosal (*sq.*).

First Stage (continued).—Visceral arches of Tatusia hybrida.

This stage, although more advanced than some I have been able to work out in certain Insectivora, is yet very valuable and instructive; the two mandibles—the *outer* and the *inner*—are now well developed, but the peculiar Mammalian transformation of the inner mandible has not yet taken place.

The superficial ramus (Plate 2, fig. 3, *d.*) is full four times the bulk of the primary articulo-Meckelian rod (*mk.*), and reaches backwards nearly to the thick articular region.

A row of small alveoli is seen in front of the coronoid process (*cr.p.*), which is peculiarly long and slender, and forms an acute angle with the condyloid part (*cd.p.*), a semi-oval mass of cartilage. The tip of the coronoid process is also cartilaginous, and so is the edge of the feebly developed angular process (*ag.p.*).

MECKEL'S cartilage—the inner or primary mandible—is a very uniform terete rod, lying all along the inner face of the ramus, near its lower edge; it follows the sinuosities of the ramus up to the "mentum," where it is confluent with its fellow (fig. 2, *mk.*).

At this confluence there is developed a tongue-shaped non-segmented rudiment of a basimandibular element (*b.mn.*); this is more distinct in the Insectivora than in the Armadillos. There is no appearance, at this stage, of a distinct splenial, or of a distinct coronoid, bone inside the ramus, in this type. There is, however, here, as everywhere in the Mammalia, a very large tract of cartilage on which the hinder half of the dentary is formed, and out of which the *new articular facet*, that on the lower edge of the squamosal, the "glenoid" facet, is also developed.

This subcutaneous slab of cartilage is manifestly the homologue of the lower labial of cartilaginous Fishes, as much as the bone itself corresponds with the antero-external splint of MECKEL'S cartilage in Ganoids and Teleostei, the Amphibia and the Sauropsida—the well-known "dentary."

A preparation of the whole auditory and articular region of the skull shows many things in their proper relations (fig. 4). Part of the squamosal (*sq.*), with its glenoid facet (*gl.f.*), is figured, and the condylar (*cd.p.*) and angular part of the ramus or lower jaw, with its solidly cartilaginous hinder margin.

MECKEL'S cartilage, large and solid, is seen running along a groove on the inner face of the ramus, and in the other direction shows itself as a large *pars articulare*, with its sinuous condyloid face for articulation with a remarkable form of quadrate—now, evidently, the "incus," before ossification.

As in the Fowl and many other Birds, there is a long "internal angular process" to

the articular region, and a rudiment of the well-known avian "posterior angular process;" in Mammals the former is called the "manubrium of the malleus." Under the proximal part of MECKEL'S cartilage, where it becomes the massive articular region, there is an ectosteal deposit—the well-known bony tract which develops into the articulare in oviparous types, often having an endosteal centre added to it; it is the "articulare externum" (Plate 2, fig. 4). Here it forms the outer rudiment of the bony malleus; it is partly hidden by the "annulus" (*a.ty.*).

In comparing the next or proximal segment of the first visceral arch with that of the Bird—the quadratum—there are two things to be noticed: first, that the "orbital process" is suppressed; and secondly, the head of the segment is articulated with the cranium *further forwards* than in most Birds.*

There is a neat head to the upper crus of this cartilage, called in human anatomy the "short crus of the incus" (*s.c.i.*), and this fits into a neat cup in the cartilage of the ear capsule, above, just between the ampullæ of the anterior and horizontal canals (*a.s.c.*, *h.s.c.*). Below and behind the saddle-shaped condyle, the body of this segment narrows into the "long crus" (*l.c.i.*), and this part acquires an inturned "neck," very slender, which carries a discoid head—the pars orbiculare.

This is another and *new*, or Mammalian, character; here the top of the first visceral arch keeps *outside* the top of the second, as in Fishes, generally, and amongst the Sauropsida in the Chameleon (see Trans. Zool. Soc., vol. xi., plate 16, figs. 4 and 7); whereas in many Amphibia and Sauropsida the topmost hyoid element—the columella—rides over the quadrate.

The great specialisation which these parts have undergone, which they show so early in the embryo, is seen in the tilted position of the semicircular canals (*a.s.c.*, *h.s.c.*, *p.s.c.*); for in relation to the axis of the skull, the horizontal canal is almost vertical, and the two vertical canals are quite oblique in position. Thus the hinder part of the "tegmen tympani" (*t.ty.*) forms a recess for the stapes (*st.*) and its muscle (*st.m.*); this is quite like the recess formed by the paroccipital wing in the Bird's skull.

The form of the stapes (which will be shown in the next stage) is quite normal; it is a short, flat, perforated column, the oval base of which fits accurately into the fenestra ovalis. In this figure it lies in the shade, within the incus, and the stapedius muscle (*st.m.*) is seen arising, tendinous, from its neck, and enlarging, backwards, to be inserted, fleshy, in the bottom of the recess at the back of the tympanic cavity.

As the parts in this early stage were newly, but completely, chondrified, I had a good chance for seeing the exact relations of the parts of the hyoid arch.

The stapes, as the counterpart of the Skate's hyomandibular, chondrifies separately; it is the only pharyngobranchial element developed in the walls of the Mammalian

* I lay stress upon *further forwards*; no one has ever dreamed of putting the Bird's quadrate into the hyoid category, notwithstanding that its articulation with the occipital arch is partly *behind the auditory capsule*.

throat. In the Skate (*Pristiurus*, see Trans. Zool. Soc., vol. x., plate 35, fig. 4) all the pharyngobranchials are developed (chondrified) independently of the rest of the arches to which they belong, which for the most part undergo secondary segmentation into more or fewer joints.

Here the segmentation of that part of the arch which in Fishes carries the gills is more than normal; the feebly developed epihyal (*e.hy.*) is in two imperfectly divided joints, and the strong ceratohyal (*c.hy.*), which is imperfectly segmented from the lower epihyal, is completely cut across at its lower third.

Below this part there is the normal (ichthyic) hypohyal (*h.hy.*), the shortest of the segments.*

The basal part is a trifoliate basi-hyobranchial (*b.h.br.*), to the fore angles of which the hypohyals are articulated, and which gives off a pair of hypobranchial rudiments, and a free retral rudiment of the long, segmented basibranchial bar of Fishes.

I found only one inner segment of the opercular growth round the first cleft; the "concha auris" becomes tubular in the meatus externus, and partly segmented; the innermost segment in this case forms an imperfect ring, and its softish cartilage is rapidly becoming ossified to form the normal annulus tympanicus (*a.ty.*), in a groove of which MECKEL's cartilage lies at its proximal end. The upper end is most ossified, the membrana tympani (*m.ty.*) is inserted into its inner face, and the radiating fibres of this membrane start from the internal angular process of the primary mandible (the manubrium mallei). The tensor tympani muscle (*t.t.m.*) is manifestly the counterpart of one of the "adductor muscles" of the hinder part of the mandible of a Reptile or Bird.

This muscle, and the "stapedius," want tracing downwards; they are the accurate muscular correlates of the curiously specialised skeletal elements of this part of the skull.

Vertically-transverse sections of the head of Tatusia hybrida.—First Stage.

The figures given in Plates 3, 4, and the following descriptions must be compared with the figures and descriptions of the bisected and dissected chondrocranium; the latter is of a later stage (Plate 5, fig. 1).

Before going into details, I may remark that the huge nasal capsules that take up half the sections selected to be figured lie under the fore part of the skull, so that the floor on which the olfactory lobes lie is the roof of the hinder and more important part of the nasal labyrinth. The septum between the two halves of this labyrinth is mainly formed of the intertrabecula, but the thicker part of the septum, where it is becoming lower behind, has the cornua trabeculæ confluent with the azygous bar.

* In this, as in my former papers, the "hyomandibular," in all its modifications, is treated of as part of the hyoid arch. In *ancestral forms* it may have been a distinct arch (see ANTON DOHRN's 'Studien,' 1885).

There is no complete nasal floor, except close behind the external nostrils, in front, and in the blind end of each capsule, behind, where the presphenoid lies between each space: the cavities, there, right and left, being the embryonic form of the "sphenoidal sinuses."

To make these numerous and complex figures more intelligible, the related parts are merely indicated; the skeletal structures are the parts to be brought into prominence.*

1st Section (Plate 3, fig. 1).—This section is through the end of the snout at the opening of the nostrils and in front of the lower jaws. The broad upper part passes sinuously into a narrower lower part, which has a concave outline below. The septum nasi (*s.n.*) is complete, and has two narrow wings below, that belong to the floor (*n.f.*), and wide arched wings above (*al.n.*), bifid at their lower edge. The section of the prenarial cavity (*n.p.*) is lunate, for there is here the beginning of the thick valvular cushion of the nostril.

2nd Section (Plate 3, fig. 2).—This section is from behind the nostrils, but close to them; here the palatal hollow begins.

The septum (*s.n.*) is thin in the middle at this part, and the alinasal roof-tracts are sharp at their lower edge. The two dilatations of cartilage below the septum are confluent here, and right and left of the solid foot there is a large pouch-shaped recess to the nostril (*n.r.*); this narial recess runs through several sections, showing that it is of considerable width. At the top, the septum is beginning to dilate, and a valvular wing of the lining membrane is seen in this dilatation.

The narial valve (*n.v.*) is very large here, and contains a section of a finger-shaped process of the alanasal. In the following sections this passes into the general cartilage, so that it is not a separate segment.

The nasal bones (*n.*) come into view as far forwards as this section (see also Plate 2, fig. 1), for they run well over the snout.

3rd Section (Plate 3, fig. 3).—This is through the whole fore face, for it takes in the top of the tongue (*tg.*) and the beginning of the lower jaws, where MECKEL'S cartilages (*b.mn.*) are confluent. The septum nasi (*s.n.*) is very thin in the middle, but is expanded above; below, it stretches into a limited floor, flat below, and not far from the wide proximal part of the valvular process, which supports the many-lobed valve (*n.v.*). The nasal bones (*n.*) only are seen in this section.

4th Section (Plate 3, fig. 4).—In this section the Meckelian rods (*mk.*) are separate, the dentaries (*d.*) are cut across, and a tooth-socket (*t.*) is seen above each bone; above, the nasals (*n.*) are seen. The septum nasi still thin below, is winged above, and these wings are the skeleton of a large upper narial lobe. The lower valve is smaller, but the whole passage is narrowed by folded thickenings of the lining

* These sections, and the rest of the thin transparent stained preparations of this kind, were made for me by one of my Sons, and the camera drawings of them by another; about one-sixth of the 163 sections made of this one head were drawn; only *three-fifths* of each drawing has been engraved.

skin. The valvular process of cartilage is seen here to be merely a part of the wall, and there is but a small space between this and the oblique floor-tract attached to the bottom of the septum. Two of the foremost of a series of glandular crypts (*gl.c.*) are cut across, the larger of these is lodged between the side and floor.

5th Section (Plate 3, fig. 5).—About six of the sections made at this part show a complete double nasal tube, for here the wall, valvular process, floor, and septum, are all confluent. Here the septum (*s.n.*) is much thicker throughout; it still retains the winged growth above, and the valvular folds of the lining skin are very numerous. Here the thickened septum is of less vertical extent, and the thick ends of the floor drop from their point of union with the septum. There is a crypt (*gl.c.*) here under the valvular process, and another at the upper third of the wall, between it and the lining membrane. The nasals (*n.*) are wider here.

6th Section (Plate 3, fig. 6).—At this part the floor of the alinasal fold has again become free from the base of the septum (*s.n.*), which is of small vertical extent, but thick—thickest in the middle. The upper alate enlargement is gone, but the fold of skin is still large, and runs out transversely. This is the last section showing the fold in the narial valve (*n.v.*), and there is a wide and hollowed space between it and the part forming the inner floor. That part is now tubular, the top of the tube (*rc.c.*) being sharp and fitting against the base of the septum. Besides the two pairs of glandular crypts (*gl.c.*), there is, in each tube of cartilage, an apparently glandular body; this is "JACOBSON'S organ" (*j.o.*), a structure which will appear in several of these selected sections.*

Small points of bone are now apparent beneath the nasal canal, right and left, these are the premaxillaries (*px.*); the nasals (*n.*) are still seen above.

7th Section (Plate 3, fig. 7).—This section is behind the alinasal, in the fore part of the aliseptal region. The thickening which showed itself in the middle of the septum in the last section is now at the base; it is due to the fact that the intertrabecula is essentially a roundish and somewhat compressed bar of cartilage, which has shot up into a thick crest to join the roofs of the nasal capsule (*al.sp.*). The middle valvular fold has now sunk down so as to be opposite the base of the septum; between it and the

* For accounts of the structure and meaning of this part the reader is referred to the "Bibliographical List." In my earlier papers on the skull my attention had not been directed to this part, and I was not then aware of the curious modification of the fore part of the skull caused by it. In the paper on the Pig's skull (Phil. Trans., 1874, Plates 28-37) the supporting cartilage is figured and described as the "recurrent cartilage"—a name I shall retain. In the more recent papers on the skull of the Snake (Phil. Trans., 1878, Plates 27-33), and in that on the skull of the Lizard (Phil. Trans., 1879, Plates 37-45), I have called the pair of JACOBSON'S organs by RATHKE'S term, namely, "nasal glands;" this, however, is a misleading term, as they have nothing to do with the *nasal glands* of Birds. In the Snake and Lizard these parts are protected by cartilage derived from the alinasal region, but they are actually encapsuled in a pair of curious bones; these are the paired vomers, which form the "dish" and the septomaxillaries that form its "cover." The *anterior paired vomers* are very constant in Mammals; but I have not yet found the septomaxillaries in any member of this Class.

outer fold the nasal canal is deep. The outer fold is not the same as in the last section; it is not a valvular fold of the external nostril, but the beginning of the "inferior turbinal" (*i.tb.*), and is formed as a pedate enlargement of the upturned wall. The cartilages protecting "JACOBSON'S organs" (*j.o.*) are no longer tubular, but form half a tube, open externally, the organ lying in the outer hollow. But the cartilages themselves have an osseous counterpart protecting them on the inner side, and having their shape and direction; these are the "anterior paired vomers" (*v'*), bones well known for their large development in the Ophidia and Lacertilia; they do not represent a divided "vomer," proper, which in nearly all Mammalia is well developed also, and begins *above* these bones, as the next section well shows. Two pairs of "crypts" are seen still, in section, and besides the large section of the nasal bones (*n.*), we have the hinder edge of the premaxillaries (see Plate 2, figs. 6 and 8, *px.*).

The palatal vault is very high here, it is partly occluded by the tongue (*tg.*), below which the lower jaws are seen each with its Meckelian rod (*mk.*), its dentary bone (*d.*), and its tooth socket (*t.*).

8th Section (Plate 3, fig. 8).—This is through the angle of the mouth and the middle of the inferior turbinal. The septum nasi is here one-third deeper than in the last, and is more definitely bulbous below. The roof passes into a deep wall which ends in the inferior turbinal; this is two-lobed, now, and each lobe is convex in its inner and upper face; the wall of the nose is sharp below the turbinals.

The recurrent cartilage (*rc.c.*) is largest at this part, and so are the small anterior paired vomers, but JACOBSON'S organ has the same diameter, nearly, as in the last section. Here the bifid fore end of the true vomer is cut across, close beneath the intertrabecular cartilage. The crypts (*gl.c.*) still appear, so that there are two rows of them on each side. Here the section of the nasal (*n.*) is large, and the fore part of the maxillary (*mx.*) is cut across on each side; this bone appears in two parts; this is because of the beginning of the alveolar groove, which runs between the lateral and palatine portions of the bone (see Plate 2, fig. 6).

The section of the tongue (*tg.*) is large here, and the dentary bone (*d.*) outside MECKEL'S cartilages (*mk.*) is in several laminae.

9th Section (Plate 3, fig. 9).—This section, of which more than half is figured, and drawn on a smaller scale than the first eight, brings us into an increased complexity of the nasal labyrinth. The septum (*s.n.*) is like that of the last section, but the roof of the labyrinth is much flatter, and besides the more developed inferior turbinal, there is now the nasal turbinal (*n.tb.*), which runs obliquely from the roof to the side wall, enclosing a long oval space. In the main channel, inside this space, there is a free section of cartilage, it is triangular, and has its apex looking upwards, this is a "precurrent process" of the middle turbinal (see also fig. 9A, *pc.c.*); it is equally developed in these types, and in the Insectivorous Hedgehog—its largest growth is seen in the Aard-Vark (*Orycteropus*, Plate 15).

This section is near the end of JACOBSON'S organ and its related cartilages; but the

proper vomer (*v.*) is now a large trough of bone composed of several laminae. The nasals and the maxillaries (*mx.*) are still seen in section, and below we have the dentary with its increasing laminae, and MECKEL'S cartilage (*mk.*).

10th Section (Plate 3, for fig. 9A. read 10).—This is from a very slight distance behind the last, it is given to show how soon the nasal turbinal (*n.tb.*) becomes free below. In both this and fig. 9 the glandular crypts (*gl.c.*) are seen to be increasing in number, and to be crowding between the Schneiderian membrane and the cartilage.

11th Section (Plate 3, fig. 11).—Here we see that the most complex part of the nasal labyrinth lies beneath the cribriform plate; the olfactory fibres (*I.*) are here seen entering from the olfactory lobes or "rhinencephala" (*C^{1b}*). The septum here is the perpendicular ethmoid (*p.e.*); it is thinnish above, and very bulbous below; the crest above is the "crista galli."

The floor of the fore part of the cranium is here only perfect near the septum; but the cartilage increases, laterally, so that the olfactory nerves then pass through holes, and not through chinks as at present (see Plate 2, fig. 5). Here the upper part of the labyrinth answers to the upper turbinal in Man, and the lower part to his middle turbinal. The cartilage at this part encloses a large oblique oval cavity, round which a perfect ring of glandular crypts are packed. The inner process of cartilage, which runs free from that ring, is the hinder or proximal part of the free precurrent cartilage seen in the last two figures (see fig. 9A, *pc.c.*).

Here we see that, behind, the recurrent cartilage (*rc.c.*) protecting JACOBSON'S organ overlaps this curious fore-growth of the middle turbinal, for its section is still seen above the edge of the vomer (*v.*).

The bones seen above the labyrinth are no longer the nasals, but the frontals (see Plate 2, fig. 7, *f.*), which are very large plates in this type, whilst the nasals are rather short. The maxillaries (*mx.*) are very large, and have many laminae at this part, and the palatine plates (above *m.*) nearly meet at the mid-line. But between the frontals and maxillaries there is the huge lacrymal (*l.*; see also Plate 2, fig. 8), which has a facial as well as an orbital plate.

MECKEL'S cartilages (*mk.*) are seen below, with their protecting dentaries (*d.*) which are developing a considerable amount of diploë, here, at the middle of the ramus (see Plate 2, figs. 3 and 8, *d.*).

12th Section (Plate 3, fig. 12).—This is through the fore part of the hemispheres (*C^{1a}*.) and of the eye-balls (*e.*). The nasal roof is cut through behind the cribriform plate (see Plate 5, fig. 1), and this part of the nasal labyrinth is sub-cranial, and the proper cranial walls are above, and external, to this part of the turbinals which are reduced to two folds. The outer of these folds of the middle turbinal (*m.tb.*) is fixed, both above and below, the inner is free, above; they are both turned inwards and upwards. This part of the capsule has, in some degree, coalesced with the septum (*p.e.*) both above and below; its very bulbous form at the base is well shown; this is the last figured section that shows only the intertrabecula. Indeed, even here, it is

possible that the foremost part of the paired trabeculæ may have helped to thicken the bulbous part.

At a short distance from the nasal wall the fore part of the orbitosphenoid is shown in section; but further forwards (see Plate 5, fig. 1, *o.s.*) that wing is continuous with the nasal wall. Over these parts the frontal shows itself twice, above, where it lies over the flattish hemispheres (*C^{1a}*), and laterally, where the orbital plate protects the orbitosphenoid over the eye-ball (*e.*).

The nasal channels are almost reduced to two sub-oval naso-palatine canals, for here the skin covering the vomer (*v.*) lies very near the skin covering the halves of the hard palate.

Four bony sections are seen here; the two small upper pieces are the hinder forks of the vomer (*v.*), the outer and larger plates are the palatine bones (*pa.*), which extend round the passage, above and below. Below, these bones soon meet at the mid-line, like the maxillaries, carrying on the hard palate (see Plate 2, fig. 6, *mx.*, *pa.*); above, they nearly touch the forks of the vomer. Under each eye-ball there is a bony section, flattish and upturned externally; this is the jugal (*j.*). Nearer the mid-line the large high dentary (*d.*) is seen, and inside its lower part MECKEL's cartilage (*mk.*).

13th Section (Plate 4, fig. 1).—This partial figure shows a very long part of the frontal bone (*f.*) and a larger amount of orbitosphenoidal cartilage (*o.s.*), confluent, here, with the outside of the narrowing nasal labyrinth, but at a distance from its own root, the presphenoid. The median cartilage is still the perpendicular ethmoid (*p.e.*), and its shape here is very instructive; the extension of the cartilage below the nasal labyrinth is due to the addition, right and left, of a wedge-shaped tract—the cornu trabeculæ to each side of the bulbous, crested intertrabecula.*

The cavity of the nasal labyrinth is now reduced to three small recesses, the outer nearly obsolete; and the folds of the middle turbinal (*m.tb.*) are confluent with both wall and floor, and look inwards and upwards. Here the top of the intertrabecula has lost the crest (*crista galli*); the cartilage here, behind the cribriform plate, is lowering towards the presphenoidal region.

In the last section the upper part of the mucous membrane lining the naso-palatine canals almost rested upon the lower so as to divide them imperfectly. Here these folds are more separated in the middle, and the canal (*n.p.c.*) is single, shallow in the middle and deeper at each end. Outside this common canal the pterygoid bone (*pg.*) is seen merely hooking round the passage in a crescentic form.

The high coronoid region of the mandible (*d.*) is here cut across, and MECKEL's cartilage (*mk.*) is seen lying on the inturned lower edge; the jugal (*j.*) still comes into section under the eye-socket.

14th Section (Plate 4, fig. 2).—This is through the widest part of the orbito-

* This part is explained by what is seen in the early chondrocranium of the Turtle and the Crocodile (see 'Challenger Reports,' Zoology, vol. 1, plate 5; and Trans. Zool. Soc., vol. 11, plate 64, fig. 5; and plate 65, figs. 2, 3, 7).

sphenoid (*o.s.*), which appears in the figure to be cut off from its base; this is due, however, to the fact that this section is through the sphenoidal fissure. Here the basal part (*p.s.*) is spindle-shaped in section; this is due to the fact that the trabeculæ are here adding their thickness to the solid intertrabecula, and that they are giving off the orbitosphenoids, which, here, are not continuous with their root. The frontal (*f.*) is broad, and curls round the orbitosphenoid, into the orbit. Here the pterygoids (*pg.*) are very solid, and protect a transversely elliptical space, the naso-palatine canal (*n.p.c.*). Above and outside each pterygoid, a small V-shaped section of bone is seen; this is the foremost part of the *lower* alisphenoidal centre (see Plate 2, fig. 6, *al.s.*). The jugal (*j.*), dentary (*d.*), and Meckelian rod (*mk.*), are very similar in this to the last section.

15th Section (Plate 4, fig. 3).—Here the presphenoid (*p.s.*) is far separated from the large upper band of the orbitosphenoid (see Plate 2, fig. 1, *o.s.*); its *triple* form answers to its compound nature, formed as it is from a bulbous middle, and two wedge-shaped, lateral, pieces—the intertrabecula and the trabeculæ. The Mammalian type of skull is seen here, for the alisphenoid (*al.s.*) overlaps the lower part of the orbitosphenoidal region, and lies a good distance outside it. There is a thick core of cartilage at this part, with an ectosteal deposit on its upper edge, the foremost part of which was seen in the last section. The naso-palatine canal (*n.p.c.*) is kidney-shaped in section here, the “hilus” being above. On each side of this passage the pterygoids (*pg.*) are seen to be very thick in this their hinder part. Laterally, the point of the zygomatic process of the squamosal (*sq.*) is seen riding over the hind part of the jugal (*j.*), and, inside this, the ramus of the mandible is seen to be composed of a mass of hyaline cartilage, besides the bony dentary (*d.*) which protects MECKEL’S rod (*mk.*).

16th Section (Plate 5, fig. 4).—We are here in the widest part of the hemispheres, and the fore part of the pituitary body (*py.*) is cut through. Beneath, the basal cartilage is composed of the beginning of the trabeculæ (*tr.*), and it is seen to be double not triple.*

This prepituitary part of the basisphenoid (*b.s.*) is cut across close in front of the narrow pedicle of the alisphenoid (see Plate 5, fig. 1, *al.s.*, *b.s.*), in the innermost part of the sphenoidal fissure, so that the cartilage appears in two pieces on each side of the basal mass. The alisphenoid is not merely *calcifying*; it is being rapidly converted into bone, within, and, externally, has two thick ectosteal plates on it, an upper and a lower alisphenoidal bone (see Plate 2, fig. 6, and Plate 5, fig. 1, *al.s.*’, *al.s.*). The parts of the mandible and face are like what are seen in the last section; but the naso-palatine canal (*n.p.c.*) has now opened into the fauces. The upper band of

* In these decalcified sections the lime-salts were removed, but the cartilage cells were becoming calcified (see Plate 2, fig. 1, *b.s.*) as the basisphenoidal bone. In the 19th and 20th Sections (Plate 4, figs. 8, 9) the same is true of the middle of the basioccipital region.

cartilage (*o.s.*) running from the orbitosphenoid to the auditory capsules still retains its breadth, and is protected by the frontal bone (*f.*).

17th Section (Plate 4, fig. 5).—This section is through some very notable parts of the skull and its contents. The hemispheres are here at their widest part, and, below, the pituitary body (*py.*) is cut through. Here is the wide spheno-auditory fissure (see Plate 2, fig. 6, and Plate 5), over which the large Gasserian ganglion (*V.*) lies.

The frontal (*f.*) still protects the posterior band of the orbitosphenoid (*o.s.*), and below this an infero-lateral bone comes into section, namely, the squamosal (*sq.*), just where it is forming a broad part for the hinge of the lower jaw (*cd.p.*). Here this bone helps to form the cranial wall, in the re-entering angle between the frontal and parietal (see Plate 2, fig. 8; *f., p.*). The dentary bone (*d.*) and MECKEL'S cartilage (*mk.*) are seen below that mass of superficial cartilage. The dentary (*d.*) at its angular part here comes close to the pyriform cavity exposed at this part—the tympanic cavity (*c.ty.*); the broad end of this open section is below, and the narrow upper end turns a little outwards.

Below this space the epiphyal cartilage (*e.hy.*) is cut across. Here the faucial passage is very narrow below; above it, the basis cranii is near the basioccipital region close behind the postclinoid elevation. The notochord (*nc.*) lies below, in the primary chink between the two parachordal tracts; and its end is hooked downwards (see also Plate 3, fig. 13, *nc.*), a state of things first shown by BALFOUR in the Shark ('Elasmobranchs,' p. 209, Plate 14, figs. 9A and 16A); and then by me in the Green Turtle ('Challenger' Reports, Zoology, vol. i., plate 8, figs. 6 and 6A).*

The interauditory part of the basis cranii is, here, twice as wide as it is thick; it is hollow above, and convex below; the latter part being split, and having the notochord in the fissure. The bulbous end of the cochlear part of the auditory capsule (see fig. 6, *chl.*) is here cut across, just exposing the spiral cavity, and showing the apiculated fore end.

18th Section (Plate 4, fig. 6).—The hemispheres (*C^{1a}*), the mid-brain (*C²*); the infundibulum, and the pituitary body (*py.*) are still seen (for the sections are a little oblique, and they incline downwards and backwards), but the basis cranii is cut through close behind the postpituitary wall or elevation. The hinder part of the Gasserian ganglion (*V.*) is cut through, and under this the cochlea (*chl.*) has its cavity exposed; the notochord (*nc.*) is seen in the chink below, in the solid basioccipital cartilage (*b.o.*).

The backward extension of the orbitosphenoid (*s.a.c.*) is still seen, overlapped here by the parietal (*p.*). The squamosal (*sq.*) is cut across behind the glenoid cavity, and below and within this part, at a moderate distance, MECKEL'S cartilage (*mk.*) is still seen in section. Under and inside it there is a small crescentic tract of bone; this

* Whatever theory may turn out to be true as to the nature of the prepituitary part of the skull—the trabeculæ and intertrabecula—we have here a most valuable landmark, for the down-turned end of the notochord is certainly the cephalic termination of the axis of the vertebrate creature.

is the "articulare externum"—here the rudiment of the bony malleus (*ml.*). Opposite these parts the outer skin is somewhat enfolded; this is the beginning, or fore margin, of the external auditory meatus (*m.a.e.*). The tympanic cavity (*c.ty.*) broadens towards MECKEL'S cartilage, and has a concave upper border; it is very large at this part, and has the epihyal (*e.hy.*) below its lower, inturned recess.

19th Section (Plate 4, fig. 7).—This is from a short distance behind the last, and is through the posterior clinoid wall, which is low and indistinct. The cochlea (*chl.*) is laid open at its anterior third, and the cartilaginous capsule is perforated above, and notched laterally, for the facial nerve (VII). Through the obliquity of the section the pituitary body (*py.*) is still seen from behind; the internal carotid arteries (*i.c.*) are entering, right and left.

The basis cranii is here at its narrowest part; this is the region of occipito-sphenoidal synchondrosis. The wall-cartilage is here of great depth; this may be called the supra-auditory tract of the chondrocranium (*s.a.c.*) between the hinder orbito-sphenoidal band and the completed occipital roof (Plate 5, fig. 1). The squamosal (*sq.*) and the parietal (*p.*) are here seen cut through; the latter also reappears opposite the involution of the skin forming the outer ear. MECKEL'S cartilage is here seen where it is giving off the "manubrium mallei," and the bulbous form it has at this part gives the section the appearance of discontinuity between the head and the handle; this is corrected by the figure of the dissection (Plate 2, fig. 4).

This internal angular process of the lower element of the first arch is seen to push the lining of the drum cavity before it, in its growth downwards and inwards. Under and outside the cavity patches of cartilage are seen; these are parts of the annulated meatus, and the inner ring, on which the "os tympanicum" or *annulus* is forming.

Below the cavity, the epihyal is seen cut across; below it the *chorda tympani* branch of the facial nerve was seen in section, and from the manubrium mallei the tensor tympanic muscle (*t.tm.*) is seen passing inwards and upwards.

20th Section (Plate 4, fig. 8).—The supra-auditory cartilage is not continuous, here, with the capsule; this tract is protected by the parietal (*p.*), and below the parietal a part of the squamosal (see fig. 7, *sq.*) is cut across. The large lateral lobes of the hemispheres are seen to cover the mid-brain; below this the basilar artery (*b.a.*) is seen, and right and left of the basis cranii the internal carotids (*i.c.*) are entering. Here the basioccipital cartilage (*b.o.*) is like a thick warped plank whose convexity is below. The space between the capsule and the basal part, which was slight in the last section, is widened here, and will become considerably wider where the 9th and 10th nerves emerge.

On this left side the cochlea (*chl.*) is cut through at its widest or proximal part, and the tegmen tympani growing out from it covers the emerging facial nerve (VII.). Here the malleus (*ml.*) is sectioned so as to show a continuous growth of cartilage from the head down to the end of the manubrium, the inturned end of which lies on that part of the infolded skin which becomes the membrana tympani. Under the crescentic

cavum tympani the meatus (*m.a.e.*), at its proximal part, is cut through and is cartilaginous and partly bony; this is the "annulus;" below this is the epihyal (*e.hy.*), and below this the chorda tympani.

21st Section (Plate 4, fig. 9).—In this section the inner wall of the capsule is broken up into three tracts, for here the related nerves (VII., VIII.) enter.

On its inner face the capsule appears very solid, this is partly due to the obliquity of the section, here, as we are at the proximal part of the cochlea, where it opens into the general vestibule (*vb.*). The outer face of the capsule is very broken up here, and there are several small tracts of cartilage to be accounted for. Below the narrowed end of the inner wall of the capsule the tympanic cavity (*c.ty.*) is seen as a large oval space, enlarged a little upwards; below this the annulus is still seen, and outside that one of the imperfect rings of the meatus (*m.a.e.*); further outwards at the edge of the section the folds of the outer skin, at the passage of the ear, are shown.

Two fenestræ are cut through in the infero-external wall of the capsule, these are the fenestra rotunda (*f.r.*) below, and the fenestra ovalis (*fs.o.*) above; the latter is partly occluded by a cartilaginous plate, the stapes (*st.*), which, being perforated by the stapedia artery (*st.a.*), appears in two pieces, these are the base and neck of the stapes; to the latter a short nucleus of cartilage is seen to be articulated, and a joint cavity exists between the two. Here we have the intumed, orbicular part of the long crus of the incus (*l.c.i.*)

Under the lessened tegmen tympani (*t.ty.*) we see a round tract of cartilage; this is the short crus of the incus (*s.c.i.*).

22nd Section (Plate 4, fig. 10).—This is from a part close behind the last section, and the description just given may serve, on the whole, for this. The head of the malleus is hidden by the short crus of the incus, and the cartilage is deficient in some degree. The facial nerve (VII.) is seen passing into its canal beneath the tegmen. The cartilaginous matrix of the "annulus" is shown for half its extent, and part of what seems to be another annulus belonging to the meatus is seen, both are lettered as meatus-cartilages (*m.a.e.*).

The three main openings of the capsule are still seen, namely, the meatus internus for the 7th and 8th nerves (VII., VIII.), the fenestra ovalis (*fs.o.*) with part of the base and one of the crura of the stapes (*st.*) in it; and, below, the fenestra rotunda (*f.r.*). Only the top of the incus (*s.c.i.*) is seen on the outside of the capsule, and over the stapes the facial nerve (VII.) is passing out. The flattening basioccipital cartilage (*b.o.*) is coalescing with the capsule on this side.

23rd Section (Plate 4, fig. 11).—This is a very instructive section, showing the relation of the visceral cartilages to the auditory capsule. That capsule is laid open in the fore part of the internal meatus, and the facial nerve (VII.) is seen from behind as it enters the capsule, burrowing through it, and then reappearing over the incus (*i.*) under the tegmen tympani. Its chorda tympani, or mandibular branch (VII.), is seen below the epihyal before it crosses over (outside) it to join the

third branch of the trigeminal. On the inside the capsule and basioccipital cartilage are largely confluent at this part, but this is only for a short distance, between the ingoing of the internal carotid and the outgoing of the 9th and 10th nerves. The huge, swelling cochlea (see Plate 2, fig. 6, *chl.*) causes part of the floor of the capsule to appear, in this section, to be seen below the junction of the capsule with the base. Outside this part the fenestra rotunda (*f.r.*) is cut across, and then, above it, the fenestra ovalis (*f.s.o.*), plugged with the base of the stapes which is cut through, so as to show the stapedia artery (*st.a.*) in its hole. Here the incus (*i.*) is severed through its body and long crus, so as to show it entire. The annulus and a large part of the meatus (*m.a.e.*) are seen here as cartilaginous bands. The tympanic cavity (*c.ty.*) is lessening. (This section is in front of the last two (figs. 9 and 10) for the supra-auditory cartilage (*s.a.c.*) is separate from the capsule; it should have been described before them).

24th Section (Plate 4, fig. 12).—Here we are behind the cavum tympani, in the hinder part of the junction of the capsule with the basioccipital, for the 9th and 10th nerves are here cut through (but not lettered). Under the ascending cartilaginous wall, where the cartilage has thickened into the wall of the capsule, the anterior semi-circular canal (*a.s.c.*) is cut across.

A large, irregular, open space is seen, the vestibule (*vb.*), and in the wall behind it, on the outside and below, the facial nerve (VII.) is seen emerging *behind* the epihyal, which is seen here in its union with the capsule. The front face of this section has been drawn; the small recess, here, is the back of the tympanic cavity, and the insertion of the stapedius muscle is seen below the hole for the escaping facial nerve (VII.).

Part of the meatus externus (*m.a.e.*) is laid open, and in the wall of that tube one of the imperfect rings of cartilage is shown. The parietal (*p.*) and the squamosal (*sq.*) are cut through laterally, and, below, the fore edge of the atlas (*vt.*) comes into view, where it is overlapping the basis-cranii.

25th Section (Plate 4, fig. 13).—This section is somewhat oblique, both laterally and vertically. The mid and hind brain are cut through; the razor has passed close behind the basioccipital below, and in front of the supraoccipital above; hence the chondrocranium appears as two distinct tracts, right and left.

The supra-auditory cartilage (*s.a.c.*) is very deep here, and below its thick base we see the arch of the anterior canal (*a.s.c.*). This canal is also seen on the inner side of the capsule where it joins the posterior canal to form the common sinus; on the left side the horizontal canal (*h.s.c.*) is also cut across, and below it the ampulla of the posterior canal (*p.s.c.*; see also Plate 2, fig. 1). The foramen for the two larger post-auditory nerves shows part of the glosso pharyngeal (IX.), and of the vagus (X.) *in situ*, and that for the hypoglossal (XII.) does the same; the meatus-cartilage is cut across.

In my first Paper on the Mammalian skull—that of the Pig (Phil. Trans., 1874, Plates 28-37), the lateral internal view of the chondrocranium of the 3rd Stage

(Plate 33, fig. 3) shows the high orbitosphenoid as separate from the auditory capsule. It is so, afterwards, and in the 4th Stage (Plate 34, figs. 5, 6) I have given perfectly correct figures. In the 3rd Stage the sections show the continuity of these tracts (Plate 32, fig. 6), but this upper tract was considered by me as part of the supraoccipital roof. On the left side of the figure referred to, the cartilage (*s.o.*) should have been lettered *s.a.c.*—"supra-auditory cartilage;" on the right that tract also lettered *s.o.* shows where the cartilaginous wall is passing into the occipital roof. My views as to the morphological meaning of some of the parts will be seen in this Paper to have undergone some change; I give here my last deductions.

I have not cumbered my description with mere details, although the actual sections tempted me to give a much more detailed account of the structures displayed in them. A comparison of the figured sections with the figured dissections will make everything plain, as every part may be identified and compared in the two sets of figures.

Dissection of the skull of Tatusia hybrida.—*Second Stage (embryos, 2 in., and 2½ in. long).*

This skull was dissected so as to leave all the investing bones *in situ* (Plate 2, figs. 6–8); part of it is shown as dislocated to display the hinder end of the mandible and the tympanic region (Plate 6, fig. 8). The endocranium may be considered as altered very little since the last stage; the embryos, dissected, measured, *not including* their tail, the one 2 inches, and the other 2½ inches in length.

This somewhat more advanced stage is very valuable, however, with regard to the endocranium, for the bony centres formed in the cartilage are more perfect—not mere calcified tracts.

The lower view (Plate 2, fig. 6) shows the peculiar position of the outer nostrils (*e.n.*), namely, quite on the ventral aspect of the face; the Armadillos are terricolous in their habits. Behind and between the coiled valvular processes (*al.n., n.v.*) the basal part is bilobate; from the back part of the double tract the protecting cartilages of JACOBSON'S organ (fig. 1, *rc.c.*) arise. In this figure they are hidden to some extent by two small bones lying one on each side of the mid line (*v'*.; see also Plate 3, figs. 7, 8). These are the anterior paired vomers; they are thin, long shells of bone, concave within and above. Outside these the small premaxillaries (*px.*) are seen; they are notched below, and have no palatine process.

These parts lie in an angular space formed by the fore part of the huge maxillaries (fig. 6, *mx.*); these latter bones have several well-marked regions; they extend from the premaxillaries to the zygomatic arch (*j.*), and then fork, behind, so as to enclose the fore margin of the open orbital floor. A long suture unites the two bones at the mid line, and outside this there are two parts of bone divided by a furrow which runs almost parallel with the median suture. Thus the palatine part is sub-distinct from the flange that grows from the alveolar region, with its double wall, its intervening imperfect tooth-sockets, and developing teeth. The maxillaries are scarcely seen from

above (fig. 7), and, lying prone on the under part of the face, the infero-anterior orbital foramen, through which a large branch of the maxillary nerve (V^2 .) passes, is well seen in the lower view.

The palatine bones (*pa.*) are well developed, and they form two-fifths of the hard palate; their suture continues that of the maxillaries up to the front edge of the basisphenoidal region.

In general form they, together, suggest the shape of the human thorax as seen from the front, and are overlapped by the maxillaries that form their shoulder. In front, they interdigitate with those bones, and then have each a foramen in their front fourth; their "waist" is succeeded by a pair of small "haunches;" these are the pterygoids (*pg.*), smallish, thick shells of bone, which partly floor the naso-palatine canal, but do not meet in the middle. The ascending processes of the palatines and pterygoids are not seen in this view, but they have been described in the sections (*1st Stage*).

The orbital plates of the frontals (*f.*) are seen in this view, and also the bones that form the zygomatic arch; these are the moderately large, but simple, jugal (*j.*), and the squamosal (*sq.*).

Besides showing the crescentic, hollow glenoid facet (*gl.f.*), this view gives us a good idea of the secondary, splint-like character of the latter bone, stretching from the jugal nearly to the occipital arch; it is beginning to be scooped out where it overlies the tegmen tympani (*t.ty.*). The hinder half of the endocranium is well shown in this view, obscured by no investing bones. In the openings of the orbits, below, we see the lateral ethmoidal masses containing the turbinals, and behind these the orbitosphenoidal cartilage (*o.s.*), perforated by the large optic nerve (*II.*). Overlapping that wing, and itself overlapped above and outside, we see the alisphenoid (*al.s.*), a half-opened fan of thick cellular bone, the handle of which is separately ossified. Between the handle and the orbitosphenoid we see the sphenoidal fissure through which pass the orbital and maxillary branches of the 5th nerve ($V^{1,2}$.), and the 3rd, 4th, and 5th orbital nerves.

In the hinder margin, behind the suture of the two centres of ossification, there is a large notch, becoming a foramen; this is for the 3rd branch of the 5th nerve (V^3 .), and will be the foramen ovale.

The basis cranii is winged here, for the lower bone, forming the handle of the fan-shaped alisphenoid, does not ossify close up to the median beam; in that part, a little further backwards, a median bony centre, small and transverse, is seen; this is the basisphenoid (*b.s.*); it is below and in front of the postclinoid wall (see fig. 1).

The organs of hearing are highly developed in the Armadillos; here, right and left of the basis cranii, we see the huge cartilaginous capsules, with the special cochlear enlargement (*chl.*), larger, relatively, than I remember to have seen it in any Mammal of a moderate size; of course it is, relatively, very large in the smaller kinds of Bats.

In this view the cochlear bulbs (*chl.*), the tegmen tympani (*t.ty.*) outside each, and

the lesser bulb forming the mastoid (opisthotic) region (*op.*) are all displayed ; in the latter, the ampulla of the posterior, and the end of the horizontal canals (*p.s.c.*, the latter is not lettered ; it is in fig. 4) shine through the cartilage.

In the interspaces between these large ear-balls and the hind skull, the vagus and glossopharyngeal nerves (X., IX.) emerge, partly through the fissures, and partly in enclosing cartilage. The internal carotids enter the cranium between the cochleæ and the basisphenoidal beam (*b.s.*). Under the tegmen the facial nerve (VII.) makes its first exit, and then burrows the cartilage again, over and behind the junction of the epihyal (*e.hy.*) with the capsule. Postero-externally, the auditory capsule shows two large perforations, the foremost of these lies inside the hind part of the tegmen, and opens into the vestibule ; this is the fenestra ovalis (*fs.o.*) ; the other, the fenestra rotunda (*f.r.*), opens into the cochlea (*chl.*) in the postero-lateral face of the first turn of the three-coiled "helix."

The basis cranii for the rest of the skull is half cartilage, spheno-occipital, and half bone, basioccipital (*b.o.*) ; this "centre" is oval, but truncated in front. Outside it, at a distance equal to its width, right and left, the hypoglossal nerve (XII.) burrows the solid cartilage of the base of the exoccipital wall. Behind this, at a like distance, the semi-oval condyles are seen (*oc.c.*), margining the huge sub-circular foramen magnum (*f.m.*), at its antero-inferior edge. The paroccipital thickenings outside the condyles are not large ; the exoccipitals (*e.o.*) are beginning to harden the walls ; and over the foramen magnum two tracts of bone are seen, the two supraoccipitals (*s.o.*).

In the *upper view* (Plate 2, fig. 7) the parts seen are mainly superficial ; the huge occipital roof, with its two ear-shaped bony centres (*b.o.*) are seen behind the great fontanelle (*fo.*). In front, the roof of the alinasal region (*al.n.*) is but little shown, on account of the very forward position of the nasal bones (*n.*). These bones are nearly oblong, they project at the mid-line, in front, and are cut away, equally, behind ; then they widen slightly. This region of the skull is like the narrow end of a gourd, and the rest may be likened to its bulbous part.

The frontals (*f.*), together, give a broad-waisted outline, being gently pinched in over the orbits ; the parts there marked off are each as large as the parietals (*p.*), behind. Outside, the maxillaries, jugals, and squamosals (*mx.*, *j.*, *sq.*) are just seen ; the lacrymal (*l.*) also slightly. The fontanelle (*fo.*) is still large and cruciform ; it is pointed in front, and dilated behind.

But the *side view* (Plate 2, fig. 8) brings out the form and relations of the investing bones best ; it also displays more of the inner skull ; and with it the arches of the face are given. In front the alinasal cartilage and external nostril (*al.n.*, *e.n.*) are seen ; between the frontal and maxillary, the wall of the upper turbinal (*u.tb.*), and inside the orbit, at the bottom, in front, the wall of the middle turbinal (*m.tb.*).

Below the squamosal we see part of the capsule of the ear (*chl.*) where the tympanic should be ; behind the squamosal, the opisthotic region with the enclosed posterior

canal (*p.s.c.*) shining through; below and behind it the occipital condyle (*oc.c.*); and above that the occipital arch and one of the supraoccipital bones (*s.o.*).

In this view the peculiar forward position of the nasals (*n.*); the small infero-lateral premaxillary (*px.*); the large maxillary (*mx.*), with its long nasal suture, its deficient upper facial plate, and its notched jugal process, are seen. The infraorbital foramen (*V².*) is very low down; at a moderate distance above it is the large, shell-like lacrymal (*l.*), with an antorbital and a facial region, and the canal (*l.c.*) between. Here, as well as in the upper view, we see what a large amount of space is covered by the frontals (*f.*). The preorbital part of each bone is swelling, to fit over the huge, complex nasal capsule, and then, behind the supraorbital "waist," the bone swells again to cover the hemispheres. The orbital plate is also very large, and hides most of the large orbitosphenoidal plate; the optic nerve (*IL.*) can just be seen emerging from its stem. The parietals (*p.*) are roundish shells, like the halves of a "bivalve;" they nearly reach the frontals in front, and rest upon the squamosals (*sq.*) below. These latter bones are nearly as large as the parietals, but of a very different shape. They reach nearly as far back, and much further forwards, but are not so deep. A large triradiate space separates the three main bones, here, below which the temporal fossa passes directly into the wide, gaping orbit. The zygomatic process of the squamosal is strong, and is clamped by the straight, thickish jugal (*j.*), behind which we see the edge of the glenoid cavity. The postglenoid process is hollow, and of a triangular form; the posttemporal process is rounded.

The lower jaw is very elegant, with its arcuate general ramus (*d.*) and its slender coronoid process separated by a narrow notch from the articular condyle, and the latter by a smaller notch from the angular process (*ag.p.*); much solid cartilage still remains in these parts.

The endoskeletal part of this arch (Plate 2, fig. 8; and Plate 5, fig. 4) is of great interest. MECKEL'S cartilage (*mk.*) is full-sized, a long and solid rod, passing inwards and forwards to melt into its fellow in front. Behind the massive condyloid cartilage (Plate 5, fig. 4, *cd.p.*) the bony plate of the malleus is seen, under the dilating part of this primary jaw. The head of the malleus (*ml.*) has a very deeply scooped saddle-shaped condyloid surface for articulation with the incus (*i.*); below this, the cartilage grows in a right angle to the main bar, and then forms the manubrium (*m.mb.*) by growing forwards again, as a slender terete rod. This is the "internal angular process" of the Ovipara; but the posterior process (*p.ag.*) is also to be seen as a tubercle above and behind the elbow of this long process. On the inside, one-third the way up, we see the tensor tympani muscle (*t.tm.*). The incus (*i.*) has no ectostosis at present; its articular surface is a deep, oblique saddle; its short crus (*s.c.i.*) is a solid cone, and its long crus (*l.c.i.*) is large, long, somewhat constricted proximally, and supplied with a large inturned discoid facet for articulation with the head of the stapes (*st.*).

That top piece of the hyoid arch (Plate 5, fig. 4, *st.*) is a solid little "stirrup," with

a small round hole, a large face above for the incudal facet, and a thick dilated base; the neck, with the stapedius muscle (*st.m.*), and interhyal (*i.hy.*) attached to it, is short.

Two changes have appeared in the arch of the hyoid; one is the complete fusion of the epihyal with the auditory capsule (see, also, Plate 2, figs. 4 and 8, *e.hy.*); and the other is the degeneration of the lower sub-segmented part of the epihyal into a ligamentous tract. The fused upper part has thickened; over it the chorda tympani (VII¹.) passes from the facial nerve (VII.), behind.

The ceratohyal (*c.hy.*) has a larger upper, and a shorter lower, segment; then comes the thick ovoidal hypohyal (*h.hy.*), articulated to the trifoliate basihyobranchial (*b.h.br.*); the median lobe, here, is a rudiment of the long basibranchial series of the Ichthyopsida; the lateral processes are the "thyrohyals" (*t.hy.*).

The annulus tympanicus (Plate 5, fig. 4, *a.ty.*) is forming out of a ligulate, U-shaped tract of softish cartilage.

Endocranium of Tatusia hybrida.—Third Stage (embryo, 3 inches long).

Although this embryo is one-third longer than the last, it has altered but little except in the size of the parts; yet some new osseous centres have appeared, and the others are more perfect. The endocranium, as seen from above (Plate 5, fig. 1), is a remarkable and a very complex structure. The basal line is occupied for the front two-thirds, by the huge nasal labyrinth; a large space, right and left of the remaining third, is taken up by the organs of hearing; the eye-balls occupy a considerable space, but they have dominated the cranial growths but little; the sockets are very imperfectly marked out.

The nasal labyrinth, with its right and left galleries confluent with the great median middle wall, is naturally divisible into three regions—the alinasal, aliseptal, and aliethmoidal (fig. 1, *al.n.*, *al.sp.*, *al.e.*). The first two of these regions are supplied with the ophthalmic (orbitonasal) branch of the 5th nerve; the hinder region with the olfactory or 1st nerve. So that, although these parts run into each other, there is an important difference between them; of course the alinasal region is merely vestibular.

The alinasal region (*al.n.*) is but little seen from above (compare figs. 1 and 5); there it runs across in front of the symmetrical, imperfect cylinders of the aliseptal region (*al.sp.*) as a narrow arched band. The last fourth of the long convex roofs of the labyrinth belong to the aliethmoidal region (*al.e.*), and have the inner part of the upper turbinals (*u.tb.*) growing within, and from them. Where this region begins, there the whole capsule spreads out, suddenly, into two widely divaricating, ovoidal masses, marked with the backs of the bifurcating turbinal outgrowths.

A large valley, in shape like a Butterfly, with its head backwards, lies between the large upper turbinal masses; the "body" between the "wings" is the top of the perpendicular ethmoid (*p.e.*), whose highest, crested part is the cartilaginous crista

galli (*cr.g.*). The diverging rows of spots, right and left, are the holes of the unossified cribriform plate (*cr.p.*), which extends some distance under the lateral masses. A much lesser region, shaped like a Butterfly, but with the head forwards, is seen behind the cribriform plate; its body or septum is low and thick, and the markings on each side, caused by the folds of the middle turbinal (*m.tb.*), diverge backwards and outwards, like the rows of the nerve passages. The septum, there, is the end of the perpendicular ethmoid (*p.e.*); thence the presphenoid (*p.s.*) begins; it is hollow along the mid-line, for the roots of the huge, leafy wings are bulbous. Yet these swollen parts belong to the basal region, which, however, has no median bone in these types; they are formed by the trabeculæ cranii. All these winged parts may be aptly compared to Insects; here, the orbitosphenoids, growing outwards and forwards behind the nasal labyrinth, and the alisphenoids, growing out behind them, have a similar general form.

Where the swollen trabecular bars have grown up into wings, there the width lessens a little; it then increases, gently, and then suddenly becomes a large, dilated band, confluent with the alioethmoid in front, and continuous with the supra-auditory and supraoccipital cartilage (*o.s.*, *s.a.c.*, *s.o.*) behind. This tract has lessened very little since the first stage (Plate 2, fig. 1). The narrowish stem of the great lateral cranial band is ossified in its upper half, and this bone—the orbitosphenoid (*o.s.*)—runs along the front part of the root; the optic foramen (II.) lies on the lower edge of this new bony centre, midway between the two margins.

The next dipterous growth has a bony median body—the body of the posterior sphenoid (*b.s.*). This ossification fits in between the swellings of the presphenoid, and is convex in front; it is short at present, and has a concave hinder margin reaching to the slightly elevated postclinoid wall. The proximal part of each wing is ossified by the basisphenoid; and the alisphenoid (*al.s.*) is double on each side, for the rounded, outer free part is separately ossified from the narrow inner portion. This narrow part is concave at its lower margin, to enlarge the sphenoidal fissure, through which the 1st and 2nd branches of the 5th nerve pass (V^1 , V^2), besides the 3rd, 4th and 6th nerves. The inner bone is also notched at its outer part behind, and the bony matter is beginning to convert the notch for the 3rd branch of the 5th nerve (V^3) into the foramen ovale.

The cartilage formed by the moieties of the investing mass (parachordals) becomes very narrow behind the postclinoid wall, between the large cochleæ (*chl.*), and then it expands again as the threshold of the great occipital passage (*f.m.*). The sub-pentagonal basioccipital (*b.o.*) reaches halfway to the basisphenoid (*b.s.*) leaving a long synchondrosis. The basioccipital is notched in front, and has a concave hind margin, of less extent than its oblique sides. The sinuous margins of the proximal part of the exoccipital region have their larger concavity in the front, to let out the glossopharyngeal and vagus nerves (IX., X.); and behind and outside these passages the thick square tract of cartilage is perforated for the hypoglossal (XII.).

Then comes a short exoccipital bone (*e.o.*) right and left, and then a considerable tract of cartilage between these and the supraoccipital bones (*s.o.*) above. The cartilage in which these latter centres lie is continuous with the broad, sinuous supra-auditory and orbitosphenoidal belt (*s.a.c.*, *o.s.*). Seen from above, the huge auditory capsules, with their apiculated helical cochleæ (*chl.*) are seen to be confluent with the proper chondrocranium both in front of and behind the passage for the 9th and 10th nerves. A notch separates each cochlea from the upper mass of the capsule, and a well-formed archway is formed by the proximal coil of the cochlea over and in front of the compound meatus internus (VII., VIII.).

The *end view* of the chondrocranium (fig. 2) shows what a large occiput these types possess. The supraoccipital centres (*s.o.*) are still distinct, and meet over the foramen magnum (*f.m.*), which is ovoidal in form, with the narrow end above; they occupy less than half their own region, at present. The exoccipitals (*e.o.*) are largely hidden in this view by the ear-shaped condyles (*oc.c.*); in front of these, the cochlea (*chl.*) can be seen, below, and in the distance. The paroccipital elevations outside the condyles are but little developed; the cartilage is nearly convex. A lozenge-shaped tract of the ear-capsule is seen above their convexities, right and left, and all the three canals (*a.s.c.*, *h.s.c.*, *p.s.c.*) can be seen shining through it, so great is the obliquity of the capsule in its cranial setting; the *large* inner (IX., X.) and the *lesser* outer (XII.) nerves are also seen (the dotted line is wrong).

The *tympanic region*, from the outside, has been separately worked out and figured (fig. 3) on a larger scale. The annulus (*a.ty.*) is fast becoming bony, especially in the end of the upper crus, where it is partly bifid, above, to form a rest for the processus gracilis of the malleus (*ml.*). That element is still a perfect mandible in itself; the stem (*mk.*) is drawn as cut across, in the figure.

The depth of the sinuous selliform condyle for the incus (*i.*) explains why the malleus shows *a hole* at this part in the section (Plate 4, fig. 7). The styloform ectostosis is now expanding and embracing the under face of the head of this bar; below and inside this bony tract the tensor tympani muscle (*t.tm.*) can be seen arising by a narrow and short tendon, and then passing upwards and inwards, solid and fleshy. The posterior angular process behind the internal, or manubrium, is very indistinct; the latter is nearly parallel with the main bar. The sinuosities of the condyle of the well-formed but unossified incus (*i.*) correspond with those of the malleus; the short crus (*s.c.i.*) is thick, and fits into a neat cup in the auditory capsule, close over the ampulla of the horizontal canal (*h.s.c.*). The thick, long crus is almost parallel with the elbowed part of the malleus; it has a well-formed orbicular facet on its inturned end. The unossified stapes (*st.*) is also large and well formed; here it is figured looking outwards, inside the incus; its ovoidal base has the narrow end looking upwards and forwards, according to the shape of the fenestra ovalis (*fs.o.*). The tendon of the stapedius muscle (*st.m.*) shows in its substance a considerable nucleus of cartilage, the interhyal (*i.hy.*) or infrastapedial. The slice of

cartilage here drawn as taken off the auditory capsule shows the horizontal and most of the posterior canal (*h.s.c.*, *p.s.c.*) exposed in the tube of cartilage. Winding round the inside of the incus, where it has been cut off from its proximal part in the cranial wall, we see the facial nerve (VII.) forming an elegant arch nearly parallel with that of the horizontal canal. In front of its imbedded part in the figure there is an oblong tract of cartilage, this is the part where the epihyal (*e.hy.*) has coalesced with the capsule, and from this it has been cut away in this slice. Below this the facial nerve is seen to send upwards a fork, suddenly; this is considerably smaller than the stem of the nerve, and in the uninjured skull rides over the epihyal to get inside the manubrium mallei; this is the "chorda tympani" nerve (VII'), forking over the visceral cleft to join the hindmost division of the 5th nerve.

Dissection of the Skull of Tatusia peba.—Fourth Stage (embryo, 3 inches long).

The dissected skull of *Tatusia peba* shows some differences from that of *T. hybrida* that are specific, yet most of the changes now to be described are due simply to advanced growth.

Here the alæ nasi, nostrils, and narial valves (Plate 5, fig. 5, *al.n.*, *e.n.*, *n.v.*) are like what I have just described, but the bones just behind these cartilages are larger than we should find them in a species of *T. hybrida* of the same age; these are the premaxillaries (*px.*) and the foremost paired vomers (*v'*). Still they are all distinct and characteristic, the premaxillaries being small, oblique, notched, lateral shells of bone, with no palatine portion, only with their lower edge curled in. The front paired vomers (*v'*) are twice as large as in the last, and are long shells of bone, with their oblique hollow face turned outwards, towards "JACOBSON'S organ."

Interdigitating with these four bones we see the two maxillaries (*mx.*), large, inferiorly placed tracts of bone, showing the infraorbital foramina (*V²*.) on their under surface, halfway from their swollen shoulder to their suborbital notch.

I find several alveoli, with their teeth, on the hinder two-thirds of their lower margin, and then a flange from the inner alveolar wall growing into the palatal region, as wide as the rest of the hard palate, but separated from it by a very distinct multi-perforate groove. The jugal process is wide, and is clamped by the angular fore part of the jugal (*j.*) which widens, inwards, at its middle part, and then becomes narrow where the zygomatic process of the squamosal rides upon it.

A very long sutural line runs along the palate from the alæ nasi (*al.n.*) to the presphenoid (*p.s.*); in front this is formed by the front paired vomers; in the middle by the maxillaries; and behind by the palatines (*pa.*). Their mutual suture is two-fifths the length of that formed by the palatine plates of the maxillaries; the palato-maxillary suture is arched forwards. The palatines do not narrow in so much behind, as in the last (Plate 2, fig. 6), and they also are grooved to, and beyond, their foramen. The thick half-coiled pterygoids (*pg.*) also do not run so far under the skull, and they

form a more gaping space for the "posterior nares;" they are notched behind, and have the "hamular process" suppressed.

The squamosal (*sq.*) with its crescentic glenoid facet (*gl.f.*) is seen to run from its overlapping jugal part on the jugal to the hinder face of the opisthotic region (*op.*). The postjugal elevation is followed by a pneumatic foramen (*pn.f.*) which opens into a definite air cavity. The semiosseous annulus tympanicus (*a.ty.*; see also fig. 7) is left on one side; on the other the capsule is exposed.

Along the middle, behind the posterior nares, the presphenoidal region (*p.s.*) is a thick roundish beam, quite free from bony deposit. But, laterally, in the fundus of the orbit, the roots of the orbitosphenoids (*o.s.*) are ossified, and the optic nerves (II.) are seen emerging. Behind the pterygoid, and opposite the last coil of the cochlea (*chl.*) the basisphenoid (*b.s.*) is seen to be a short broad tract; the cartilage between it and the basioccipital (*b.o.*) is half the extent of the basisphenoidal bone. Outside the pterygoids, the alisphenoid (*al.s.*) can be seen; in front of these is the sphenoidal fissure ($V^{1,2}$), and at their junction, near the hind margin of the wing, is the foramen ovale for the 3rd branch of the trigeminal nerve (V^3).

On one side the malleus (*ml.*) is seen stretching the membrana tympani (*m.ty.*), radiating to the annulus, and on the other the cochlea (*chl.*) and tegmen tympani (*t.ty.*) are seen; also the two fenestræ (*fs.o.* and the large hole behind it). On both sides the epihyal and the facial nerve (*e.hy.*, III. read VII.) are shown, and also the passage for the 9th and 10th nerves (IX., X.).

The occipital arch has a good bony threshold, now, the six-sided basioccipital (*b.o.*), which has one side in the foramen magnum (*f.m.*). The large trilobate condyles (*oc.c.*) have the exoccipital bony centres (*e.o.*) creeping round them; they are still a long way from the basal bone, and the cartilage near them is perforated by the 12th nerve (XII.), and over this passage there is now one large supraoccipital centre (*s.o.*).

The *end view* (fig. 7) shows how large this bone is, now that the two centres are fused together (see in the younger specimen—*T. hybrida*, fig. 2). The occipital cincture, in its upper part, is a large shield of bone and cartilage overlapping the opisthotic part of the auditory capsules (*op.*), with their included posterior canals (*p.s.c.*) seen endwise; the skull is roofed-in by the parietals (*p.*), and flanked by the squamosals (*sq.*).

The *sectional view* of this older specimen (Plate 5, fig. 6) shows what changes have taken place since the first stage (Plate 2, fig. 1); during this time the young have not doubled their size.

The arched line formed by the lower edge of the basis cranii is but little elevated; the main part of the internasal septum has almost a straight base. The prepituitary part is three and a half times as long as the postpituitary; the thickening of the great middle wall (*p.e.*, *i.tr.*), just in front of the presphenoid, has been caused by the flattened and pressed cornua trabeculæ; the rest of the thickening, below, is due to the intertrabecula, which is there seen to be a long prochordal tract.

The snout is turned downwards, so that its lower angle projects but little beyond its upper; from that angle the scooped recurrent cartilages (*l.s.c.*, *read rc.c.*) are seen to arise. The highest part of the partition—the crista galli (*cr.g.*)—is nearly mid-way between the bottom of the sella turcica (*b.s.*) and the projecting end of the snout. From the septum, in front of that crest, the nasal roof has been cut away; behind, for some distance, the cribriform plate (*cr.p.*) grew from the sloping crest near its top. The lowering median cartilage becomes presphenoidal; it is quite unossified at present; the basisphenoid (*b.s.*) and the basioccipital (*b.o.*) are seen, in section, with the lowish, thick postclinoid wall between them; the former is twice as thick and half as long as the latter. The large side-wall of cartilage reaching from the nasal capsule to the supraoccipital roof (*o.s.*, *s.a.c.*) has lessened since the first stage (Plate 2, fig. 1) to one-half its relative size. Yet the band, even over the protruding alisphenoid, is still of considerable thickness. The fore corner of the orbitosphenoid is becoming free, outside the cribriform plate; its main part is only ossified in the narrow stem below; the upper outline is sinuous. The fontanelle between the frontals and parietals (*f.*, *p.*) is nearly filled in by these bones, and the retreating cartilage exposes the squamosal (*sq.*) somewhat, at the base of the coronal suture. The alisphenoid (above *b.s.*) is now a single bone, and the foramen ovale (*V³.*) is finished by bony growths behind.

The supratemporal cartilage (*s.a.c.*) is still two-thirds the width of the tilted auditory capsule, which is continuous with the band for some distance, hiding the fore part of the great sinus canal (*s.c.*). Below, and in front of that canal, the elevation for the anterior and posterior semicircular canals (*a.s.c.*, *p.s.c.*) is not great, and the hollow for the “flocculus” is shallow. There is a difference of size in the whole capsule, and especially in the cochlea, as compared with what we have just seen in an embryo of *T. hybrida* of the same size (fig. 1), that is very remarkable. This species also either has a smaller embryo, or its bones develop much earlier than in the other.

The whole capsule has a well defined, definite outline, often widened into a chink, marking it out from the rest of the endocranium. There is a large porch over the actual openings of the meatus internus (*VII.*, *VIII.*); and in front of these the cochlea swells up into the cavity of the skull. The occipital cincture is narrower than the oblique capsule, and has a very large keystone piece, the supraoccipital (*s.o.*). The exoccipital (*e.o.*) is nearly twice the depth of each interspace of cartilage; it is notched for the hypoglossal (*XII.*), and has a concave face against the emerging vagus and glossopharyngeal (*X.*, *IX.*).

Besides the large frontal and parietal (*f.*, *p.*), and the angle of the squamosal (*sq.*), the nasal (*n.*), the palatine plate of the maxillary and palatine, and the small pterygoid (*mx.*, *pa.*, *pg.*) are all seen edgewise. In this section, detached from the skull, the lower jaw and its related parts are shown from the inside; it has the same elegant shape as the other species; its processes are still cartilaginous at their extremities. MECKEL's cartilage (*mk.*), fused with its fellow, is still complete along

the inner face of the ramus (*d.*); but the malleus (*ml.*) and incus (*i.*) are now three-fourths of them bony; their shape is very similar to that of the other kind (fig. 3), but the head of the malleus (fig. 8, *ml.*) is heavier, and its handle smaller. A similar difference may be seen in the incus (*i.*). The stapes also (*st.*) differs in having a larger hole, a longer neck, and a larger nucleus of cartilage—the interhyal (or infrastapedial; *i.hy.*) in the tendon of the stapedius muscle. These differences are partly due to age and are partly *specific*.*

Dissection of the skull of Tatusia hybrida.—Fifth Stage (ripe embryo, 4 inches long).

My most mature skulls of this type were those of ripe young; they are all that is needful, now, for the interpretation of the highly anchylosed skull of the adult.

The outer parts of the skull, as seen in a dissection of this specimen (Plate 6, figs. 1–4), give a good idea of the peculiarities of the Dasypodian type. The lower view (fig. 1) still shows the nostrils and alæ nasi (*e.n.*, *al.n.*) on the under surface, but the bones have encroached on the cartilage, here. The premaxillaries (*px.*) are larger and they have, now, a definite palatine tract; they fit, now, well into the notches of the maxillaries (*mx.*).

The palatine part is not alike on the two sides, being more notched, and hooked on the left than on the right.

These parts do not meet in the middle, but space enough is left to expose the overlying front paired vomers (*v.*) The palatine portion of the maxillaries (*mx.*) only forms a narrow tract, gently widening backwards.

The alveolar region has teeth on all but the front fourth. In front of this tract the bone is notched for the premaxillary, and, behind, it bends round the palatine (*pa.*). The flange from the alveolar region is on a higher plane than the submesial part of the hard palate; these two tracts are separated by a perforated sulcus, and the inner and higher bony tract is marked by the transverse ridges of the palatal skin. Outside these parts the maxillaries spread into large shells of bone, the under and inner part of which forms a tunnel for the infraorbital nerve (*V*²). Behind the short floor of this tunnel the whole bone has a notched outline, the rounded concavity of which makes the fore and inner border of the imperfect orbit. The jugal process is broad and notched for the jugal or malar bone (*j.*). Inside these parts the penthouse formed by the orbital plates of the frontals (*f.*) can be seen. The rest of the hard palate is about half as long as that formed by the maxillaries; it is mainly made by the palatines (*pa.*).

* The remarkable differences just shown between these two closely allied specimens of the sub-genus *Tatusia* (or 9-banded Armadillos) suggest the great importance of careful zoological (Taxonomic) work. Forms that to the eye of an observer not well trained in zoological work might easily be mistaken for unimportant varieties, may, to the eye of an expert, show very important modifications. Moreover, any really important external specific character is almost sure to be correlated with some curious and instructive modification of deep-lying structures.

They, together, look like the opened shells of a Bivalve, their fore margin is rounded and the hind part somewhat cut away; their sides are pinched in.

Behind them come the pterygoids (*pg.*); these bones have grown considerably on to the palate since the early stage (see Plate 2, fig. 6).*

This addition to the hard palate is rare in Mammals, even; and in this small degree is instructive, linking on these types to the Anteaters, where it takes place to the greatest degree. Their thickness also is worthy of note, for in another Neotropical Family of Edentata—the Sloths—the pterygoids are often curiously enlarged.

Behind the short, thick, jugal (*j.*) the squamosals (*sq.*) are seen to be of great length, reaching as far to the back as the occipital condyles.

They strongly clamp the auditory capsules over the tegmen, and opposite the manubrium mallei (*m.ml.*) they show the pneumatic foramen, leading into their air-cell. A pair of superficial bones are seen at their inner border; these are the “annuli,” finished crescents of bone, now; they are more than semicircular, hollow within, and convex on their outside. Yet at present they do not ossify any part of the tube of the meatus externus, but when that segmented cartilaginous tube is removed, the membrana tympani (*m.ty.*) is well exposed in this surface view. The endocranium is largely exposed behind the hard palate, and the bony centres of the posterior sphenoid and occipital arch are seen, as well as some parts of the auditory capsule. A very small part of the orbitosphenoid (*o.s.*) is seen, where the optic nerve (*II.*) emerges. Behind these parts the alisphenoid is seen as one centre, right and left, confluent with the basal piece (*al.s.*, *b.o.*, read *b.s.*). The sphenoidal fissure and foramen ovale (*V¹.*, *2.*, *V³.*) are not well seen. There is a considerable synchondrosis between the basisphenoid and the six-sided basioccipital (*b.o.*), and also between that bone and the exoccipitals (*e.o.*) below, and between them and the large shield-shaped supraoccipital (*s.o.*), above. The emerging post-auditory nerves (*IX.*, *X.*, *XII.*) have their passages exposed, and the facial (*VII.*) is seen escaping from the stylo-mastoid foramen, behind the epihyal (*e.hy.*). The tympanic annulus fails to cover the inner side of the cochlea (*chl.*), which is partly ossified.

The peculiar form of the Armadillo's skull is shown in the *upper view* (fig. 2). Three pairs of investing bones, the nasals, frontals, and parietals (*n.*, *f.*, *p.*) cover nearly the whole of the top of the skull; the maxillaries, lacrymals, jugals, and squamosals (*mx.*, *l.*, *j.*, *sq.*) are just seen at the sides; at the end, the convex top of the supraoccipital is seen, and in front, a small tract of the alæ nasi (*al.n.*). The nasals form,

* I am now satisfied that my oldest (ripe) young of this kind of Armadillo belonged, like the smaller specimens, to the species *hybrida*. For my second stage (Plate 2, fig. 6) shows the pterygoids with a larger palatine tract than is seen in *T. peba*, one third longer (Plate 5, fig. 5). That skull is also longer and slenderer, whilst that of the older is like the skull of my second stage (Plate 2, fig. 6); both these are very broad in relation to their length. I feel sure that this ripe young is really *T. hybrida*, although given to me as *T. peba*.

in the outline of the top of the skull, a small neck to a large flask; they are half the length and one-fourth the greatest width of the frontals. These latter bones swell over the huge turbinals, and are elegantly concave at the middle of the orbit. The parietals are about the size, now, of the hinder, dilated two-thirds of the frontals.

The *side view* (Plate 6, fig. 3) displays many parts, and corrects the visual appearance of the other aspects.

There is considerable deflexion of the snout, the nasals reach nearly to the end, above, and the nostrils look downwards.

The premaxillaries now form a squarish tract, followed by the maxillaries which overlap them; these latter bones are half as long as the skull, they rise high, midway between the orbit and the end of the snout, have their infraorbital foramen (*V²*.) very low, and their jugal process notched to let in the jugal. The large lacrymal (*l.*) has a roughly triangular outline, externally, the orbital margin, where it has its hole (*l.c.*), and its antorbital flange, is concave. It covers in the upper turbinal region, which was exposed in the second stage (Plate 2, fig. 8); its upper suture, with the frontal, and its lower, with the maxillary, are nearly equal; both of those margins of the lacrymal are gently convex. The frontal (*f.*) swells over the lacrymal; it is then somewhat notched where it runs inwards as the orbital plate, which hides nearly all the orbitosphenoid; the whole bone is rounded where the roof passes into the orbital wall.

The large rounded parietal (*p.*) helps but little towards forming the temporal fossa; it has a slight concavity, besides, near its hind border, where it just overlaps the supra-occipital (*s.o.*). From that part, behind, but not quite so far back, the squamosal (*sq.*) reaches to the orbitosphenoid in front. Its three regions, the post-temporal, post-orbital, and jugal are all nearly of equal length; the last of these is stout, and the pre- and postglenoid processes are well marked, the latter being the larger of the two.

In the postorbital region it forms a large triradiate suture with the frontal and parietal; these bones so united do nothing towards enclosing the orbital space, which is only marked out well in its antero-inferior half. Part of the palatine, pterygoid, and alisphenoid can be seen in this view, and also the annulus (*a.ty.*), the manubrium mallei (*m.ml.*, line directed wrong), the epihyal (*e.hy.*), the facial nerve (*VII.*), the opisthotic region and the parts of the occipital arch (*s.o.*, *e.o.*, *oc.c.*).

The lower jaw (figs. 3 and 3A) has retained its elegant shape; it has still some cartilage on its projections, especially for the condyle (*cd.p.*). The splenial and coronoid regions hang well over MECKEL'S cartilage (*mk.*), which is still perfect. The malleus (figs. 3A and 6, *ml.*) and incus (*i.*) are almost ossified, and the stapes (*st.*) now a slenderer and more elegant "stirrup," has the lower part of its crura, and the centre of its base, bony. The little module of cartilage in the stapedius (*st.m.*) is now a mere projection on the neck of the stapes. The upper ceratohyal (fig. 5, *c.hy.*) has a small ring of bone near its base; the rest of the hyoid arch is still cartilaginous, and is little altered since the last stage.

The *end view* of the skull (fig. 4) shows a very large orbicular supraoccipital (*s.o.*), divided vertically by two shallow sulci into three convexities. The lateral elevations have a large selvedge of cartilage, half their breadth, which has to be ossified by this large post-cranial shield of bone.

The paroccipital ridges are very obscurely marked off from the mastoid region (*op.*); but the exoccipitals (*e.o.*) are getting near to the upper centre (*s.o.*), over the large convex condyles (*oc.c.*); these latter are wide apart, and show the basioccipital (*b.o.*) between them. The parietals, squamosals, and tympanics (*p.*, *sq.*, *a.ty.*) can be seen, end-wise, in this view, as also the epihyal and facial nerve (*e.hy.*, VII.).

The auditory capsules were removed and figured separately on a larger scale (Plate 6, figs. 7, 8).

The inner view (fig. 7) shows a very large squarish part above the bulbous cochlea (*chl.*), and having in it the canals, only the anterior and posterior marking this aspect, where they meet in one common sinus.

The antero-superior part runs forwards as a curved process, which is, indeed, the anterior part of the tegmen tympani (see also fig. 11). The meatus internus, with its various foramina (VII., VIII.), is very large; another small hole is seen under the arch of the anterior canal (*a.s.c.*), which has no recess for the "flocculus," but only a gentle scooping at this part. Another larger passage is seen, postero-inferiorly, inside the stylomastoid foramen (see fig. 8).

In the outer view (fig. 8) the large square top of the capsule has a sinuous outline postero-superiorly and antero-superiorly; but the mastoid margin, which contains most of the posterior canal (*p.s.c.*), is straight. It is deeply notched below for the facial nerve (VII.), the notch is the stylomastoid foramen, whose lower border is the epihyal spur (*e.hy.*), now separated from the ceratohyal.

Within and in front of these parts we see the fenestra rotunda (*f.r.*), and at a distance equal to its width, the fenestra ovalis (*f.o.*). Over these openings the tegmen tympani forms an arch, continued forwards in the free spur; over the tegmen the horizontal canal (*h.s.c.*) is seen shining through the cartilage. The ossification of the capsule is very low and generalised as in certain anurous Amphibia, *e.g.*, *Pseudis* (see Phil. Trans., 1881, Plates 2, 10, 11, 12). The bony matter, which is formed endosteally, is showing itself everywhere on the convexity of the cochlea, on the spur of the tegmen, along the sinus of the anterior and posterior canals (fig. 7), and on part of their arches and their interspace.

Endocranium of Tatusia peba.—*Sixth Stage* (young specimen, apparently new-born, $4\frac{1}{2}$ inches long).

These drawings (Plate 6, figs. 9–11) were made from dissections of a large ripe embryo or new-born young of *Tatusia peba*; this, and that figured in Plate 5, figs. 5–8, were the only long-headed specimens in my collection; I am satisfied that all

the rest belonged to *T. hybrida*, for their skulls were all much wider and more bulbous in form, they had much larger cochleæ, and were far less ossified in proportion to their size.

In a figure of the *lower view* of the endocranium, with the auditory capsules removed, and the vomers kept *in situ*, we get things that are very instructive (fig. 9).

The alæ nasi (*al.n.*) are seen folding over the external nostrils (*e.n.*), which are inferior in aspect. The base of the septum, in this fore part, is alate and lobed where it gives off the recurrent cartilages (*rc.c.*); over them the aliseptal walls (*al.sp.*) are seen. Below, and overlapping the recurrent cartilages, we see the inferior turbinals (*i.tb.*), now, endosteally ossified. The rest of the nasal labyrinth (*al.e.*, *ll.tb.*, *n.tb.*, *read u.tb.*, *m.tb.*) shows no bony deposit, externally, although the turbinals are beginning to harden within; these enfoldings are seen on the outer wall. The vomerine series of bones is half as long as the entire skull, the principal vomer (*v.*) being very large—a trough in which the solid intertrabecular beam rests. In front, that bone half overlies the anterior paired vomers (*v'*), which are only one-fourth of its length and of its width, and are like miniature Razor shells (*Solen*), wide open; their concavity is above. Widening backwards, the main vomer send off a short snag, right and left, at its hinder third; its hinder fourth is in two sharp forks, that expose the perpendicular ethmoid, and the presphenoid (*p.e.*, *p.s.*) in their angle. From the side spur to nearly the end of the fork, there is, on each side, a lanceolate scale of bone, one-fourth larger than the anterior vomers (*v'*), these are the posterior paired vomers (*v''*, the line, by mistake, is carried to the left inferior turbinal), bones that help, afterwards, to bind the middle vomer to the ossifying ethmoidal masses.

Just overlying the forks of the vomer we see the forepart of the base of each orbitosphenoid (*o.s.*); the base of each of these bones is nearly equal to the extent of the basisphenoid (*b.s.*) behind; but there is no presphenoid between them, only the hind part of the great median cartilaginous beam.

These wings are now *lesser* than those behind them, the alisphenoids (*al.s.*); they are only two-thirds their breadth, and reach out, laterally, not quite so far. They are free, and emarginate above, the whole of that large cartilaginous band seen in young embryos having disappeared. The orbitosphenoids run forwards, as well as outwards, binding, obliquely, upon the great turbinal masses (*m.tb.*). Besides the upper notch, their whole hind margin is sinuous; and their base is thick, and perforated. The anterior margin, below, is carinate up to the outer fourth; behind this ridge, midway outwards, we see the optic foramen (II.).

The thick alisphenoids (*al.s.*) have their wide roof perforated, and the fore part of it binds upon the thick base of the corresponding orbitosphenoid. The basal part of each wing is confluent with, but does not reach back so far as, the basisphenoid (*b.s.*). The anterior margin is concave, and the outer convex; the posterior margin projects backwards as an upper and a lower tooth—the latter being a process from the thick ribbed part behind the larger foramen ovale (*V³*), which is, now, in

the middle of this plate. The thick basisphenoid (*b.s.*) is almost as long as wide; it is emarginate, a little, both before and behind.

The synchondrosis has only half the extent shown in the last stage (fig. 1), and the basioccipital (*b.o.*) is now a large six-sided bone, having lessened cartilaginous interspaces between it and the exoccipitals (*e.o.*). These large centres of ossification are concave on the inner, and lobate on their outer, side; they are notched, below, by the hypoglossal nerve (XII.), and above are separated by a definite cartilaginous tract from the large shield-shaped supraoccipital (*v.s.*, *read s.o.*). The broadly reniform condyles (*oc.c.*) are now mere caps of cartilage on the exoccipitals.

In the *detached hyoid arch* (fig. 10) the upper and lower ceratohyals and the thyrohyals (*c.hy.*, *t.hy.*) are rapidly becoming ossified.

The *auditory region* (fig. 11), removed from the rest of the skull, and seen from the outside, shows a great increase of the bony deposit, which now runs round the large, squarish mass, and is especially developed over the tegmen tympani. The ossicula are now ossified; the processus gracilis of the malleus (*pr.g.*) is a large spatula, with no MECKEL'S cartilage left, and lies in a groove in the upper crus of the well-developed shell-like annulus tympanicus (*a.ty.*). The stout incus (*i.*) is shown *in situ*, with the head of the stapes seen inside; that bone is also shown, detached, and it is now high, and narrow, and has a tubercle on its neck in the tendon of the stapedius. The epihyal (*e.hy.*) still shows a point of cartilage in front of the facial nerve (VII.); it is fibrous below.

Dissection of the Skull of a ripe embryo of Dasypus villosus (4 $\frac{2}{3}$ inches long).—

Fifth Stage (continued).

This was the largest, but not the oldest, of my specimens of young and embryo Armadillos; its centres of ossification were not, however, so much developed as in the specimen of *Tatusia peba*, which forms my fourth stage (Plate 5, figs. 5–8).*

This is a much more massive kind of skull than that of a *Tatusia*, and the upper parts do not so completely overlies the lower; it is more generally outspread; evidently the genus *Tatusia* comes nearer to *Myrmecophaga* than does the genus *Dasypus*.

The *lower view* (Plate 7, fig. 1) shows a very wide and very short snout, with the nostrils (*e.n.*) almost obliquely below. The base of the septum at this part is alate, and the valves of the openings (*n.v.*) very large, and coiled upon themselves. The whole space occupied by these cartilaginous growths is transversely oval, and is neatly rimmed with bone. The nasals are only just hidden in this view by the cartilage (see fig. 2, *n.*, *al.n.*); two-thirds of the rim is formed by the premaxillaries (*px.*), which are twice as large as in *Tatusia*. Much of the facial plate of these bones can

* These three kinds are all I have been able to obtain in their early stages; yet they show a most extraordinary amount of variation, and suggest to me, that it would be well worth while to work out the various stages of every species in the Family.

be seen in this view, for they converge in a very curious manner to form the fore end of the hard palate.

This fore part of the hard palate is semi-oval, and forms the beginning of the very elegant palatal roof which, altogether, would be a long ellipse if the pterygoids had closed in instead of keeping at the sides. The toothless dentary margin is curiously drawn inwards; and the higher palatal tract of each bone is concave, and has a large semicircular notch where it should meet its fellow; thus the even suture is cut into two short tracts. The suture between these bones and the maxillaries is sinuous, the latter pushing forwards externally and in the middle.

In the subcircular space between the premaxillaries the front paired vomers (*v'*.) are seen; they are convexo-concave styles as in *Tatusia*.

The broad hard palate (*mx.*) with its convex sides and teeth running up to the premaxillaries, and back beyond the palatine suture, is much more normal than what we see in *Tatusia*, and the alveolar region is thicker. The teeth, six on each side, are still in one groove, and they give it a moniliform appearance. Inside this arcuate cavity the bone is thick and cross-grooved by the palatal skin; a row of holes, instead of a chink or fissure, separates the sides from the inner higher part of the hard palate. The great pinching-in of the fore part of the bone seen in the nine-banded kinds is not seen here, yet the infraorbital foramen (*V*².) is inferior, not lateral; its floor is much larger.

The jugal process instead of going beyond the alveolar region does not reach so far, and is smaller. The palatal region of the palatine bone (*pa.*), instead of being very unlike that of the maxillaries, is very much like that tract. The two bones have a **W**-shaped hind margin, in front of which the bones are thick and rough as at the sides, just contrary to what the other kinds show; the palatines are widest where the pterygoid bones fit on to them; these latter bones (*pg.*) fit obliquely to the outer half of the palatine edge, leaving its median notch free; they then run outwards and forwards.

They have a thick, ascending, or cranial part, and a retral inferior hamular process, which has a concave outer and a convex inner margin, and a slight inclination to the mid-line. Each bone is tipped with true cartilage as in the Hedgehog and Mole (as I shall show in my next part). Yet, notwithstanding the merely lateral position of the pterygoids, the hard palate hides the presphenoidal cartilage, which it does not in a *Tatusia* of the same age (Plate 6, fig. 1), and this great bony floor occupies the foremost two-thirds of the basal part of the skull. The jugals (*j.*) are altogether larger than in the other genus, and they are much further apart, through the width of the skull. The squamosal (*sq.*) carries a much larger glenoidal cartilage (*gl.f.*), and it lies at the beginning of the hindmost fourth, instead of the hindmost third of the skull's length. Also the annulus tympanicus (*a.ty.*) does not cover, in this aspect, the inner part of the squamosal, as in *Tatusia*; in this type that part is very large. Behind the condyloid lunule the bone forms a thick obtuse process with a pneumatic foramen in its postglenoid process.

Inside the glenoid condyle the squamosal runs across and forwards, binding strongly on the solid alisphenoids (*al.s.*); with their help, an oblique thick ridge of bone is formed, which runs, with a concave outline, outwards and backwards, from the pterygoid to the opisthotic corner of the ear-capsule (*op.*). There the broad thick basis cranii also has a concave margin which runs outwards and backwards, and thus a large, oblique, oval space is left in the floor of the cranium; this is filled in by the auditory capsule, mainly by its cochlear region (*chl.*). On the inside the fissure is filled with fibrous tissue until we come to the opening for the vagus and glossopharyngeal nerves (X., IX.). In the front of this fissure the internal carotid artery enters. Outside we see the higher part of the outer lamina of the squamosal helping to enlarge the tegmen tympani, and, in front, the facial nerve (VII.) escapes from the skull, and gains the hollow of the tegmen. It then runs along that arched way, and before escaping through the stylomastoid foramen burrows through the cartilage formed by the fusion of the auditory capsule with the epihyal (*e.hy.*).

Near this tunnel, on the side of the capsule, we see the fenestra ovalis (*fs.o.*), and at the fenestra rotunda (*fr.*) the outside of the proximal coil of the cochlea (*chl.*). The optic nerve (II.) can be seen emerging from the orbitosphenoid, and behind it an oblique tract of the alisphenoid is seen; it is very thick, has the foramen ovale (*V³.*) in its middle, and a suture appears right and left of this hole, due, I have no doubt, to a primary division of the bony deposit as in *Tatusia*, but with the suture more oblique.

Like the other structures, the parachordal region is much more outspread; the basisphenoid (*b.s.*) has a rounded outline, and does not yet reach the edges of the great cartilaginous beam. The basioccipital (*b.o.*), also, lies in a large tract of cartilage, reaching the sides nowhere; it is oval, with the long diameter median. A widish tract of cartilage exists between the basal and lateral bones—the exoccipitals (*e.o.*), on the edge of which, in front, the hole for the hypoglossal (XII.) is seen. The unossified capsules, in their opisthotic region (*op.*), run almost directly inwards, with scarcely any paroccipital elevation between them and the condyles (*oc.c.*). Instead of being in front of the general lower face of the skull, the large ovato-reniform condyles are behind it, and instead of the supraoccipital tract (*s.o.*) being largely seen in this view, it is only apparent at the hinder outline of the foramen magnum (*f.m.*).

Hence the setting on of the head in these two types is very different; here, it is much more terminal than in *Tatusia*, where it is almost as much under the head as in the Primates. On one side of my dissection the ear-drum was left *in situ*. The annulus (*a.ty.*) is only half as broad as in the other kind, although quite ossified; a considerable space, filled with fibrous tissue, exists between the annulus and the basis cranii. The malleus, MECKEL'S cartilage, and the membrana tympani (*ml.*, *mk.*, *m.ty.*) are shown in this view, these will be better understood by reference to other figures (figs. 3A and 6).

The *upper view* (Plate 7, fig. 2) shows the great breadth and shield-like form of

the skull, with its more outspread zygomatic arches, and its more definite orbital waist. The premaxillaries, maxillaries, lacrymals, jugals, and squamosals (*px.*, *mx.*, *l.*, *j.*, *sq.*) are all fairly in view in this aspect. Right and left of the median suture the three main roof bones, nasal, frontal, and parietal (*n.*, *f.*, *p.*), finish the roof; here, as in *Tatusia*, there is no interparietal, so large in the Insectivora. Both the nasals and the parietals are relatively about one-third larger in this kind, so that the frontals do not cover so large a proportion of the roof, nor are they specially swollen over the lateral ethmoids. Postero-laterally, the temporal fossæ, which open freely into the orbit, are well seen from above, and the squamosals form a rounded angle, behind, over the opisthotic cartilage (see fig. 1, *op.*). Mesial of those elbows, the hind margin of the skull forms a neatish quadrant, the inner half of which is the ossified supra-occipital (*s.o.*), which turns over the roof to an extent equal to half the sagittal suture; the lambdoidal suture is gently sinuous, the convexity of the line looking forwards in the middle and backwards at the sides.

If the *side view* be compared with that of the other kind (Plate 7, fig. 3; and Plate 6, fig. 3) the general likeness and the special differences of the two kinds will be seen.

Here, the premaxillaries (*px.*) are twice as large, and the lacrymals (*l.*) only half the size of those of *Tatusia*; then the frontals (*f.*) being flatter, the maxillaries (*mx.*) are larger behind; their infraorbital foramen (*V*².) is higher up and more exposed. The smaller lozenge-shaped lacrymal (*l.*) has its canal (*l.c.*) nearly in the middle of the facial part, and this bone, with the jugal (*j.*) and frontal (*f.*) form a more rounded and neater orbital rim, two-thirds round the space. But the orbit and the temporal fossa do but form one general valley, reaching from the lacrymal to a point over the head of the malleus (*ml.*).

The coronal suture is formed by the sinuous line of union of the thick edged frontals and parietals; it ends, below, on the squamosal, at its front third, opposite the end of the jugal, which bone (*j.*) is flat, thick, and especially enlarged both before and behind, where it rests on the maxillary, and where the jugal process of the squamosal rests on it. If the squamosal (*sq.*) shows more in the upper, it shows less in the side view; its pre- and postglenoid processes are small, but the post-temporal part grows well down over the hinder tympanic recess.

Looking under the jugal, we see a small part of the orbitosphenoid, with its optic foramen (see fig. 1, 2), the chink for the 1st and 2nd branches of the 5th nerve (*V*^{1,2}.), and the alisphenoid, with its foramen ovale and the suture across it (*V*³.). Beneath these parts the palatal elements—maxillary, palatine, pterygoid (*mx.*, *pa.*, *pg.*)—are seen. The hamular process of the pterygoid is seen to look downwards, and to be capped with cartilage. The tympanic region is well seen in this side view of the skull; the annulus, MECKEL'S cartilage, malleus, incus, and membrana tympani (*a.ty.*, *mk.*, *ml.*, *m.ml.*, *i.*) are all seen, and above them a considerable tract of the squamosal. The epiphyal (*e.hy.*) is still continuous with the opisthotic cartilage (*op.*), and behind it the facial nerve (*VII.*) is emerging; these parts are very near the end of the skull,

and between them and the condyle (*oc.c.*) there is a very inconspicuous paroccipital tract. The exoccipital and supraoccipital (*e.o.*, *s.o.*) are seen in the midst of large tracts of solid cartilage.

It is impossible to look at the end view (fig. 4) without being reminded of low Ichthyopsidan types of skull; the cartilage is as solid as in them, and the osseous centres are mere patches in it. The general form of the occipital end-wall is transversely oval; it overhangs a little above (see fig. 3), and then curls over, above, where the bony centre (*s.o.*)—single now, but undoubtedly double once—is somewhat trilobate. This supraoccipital centre is thus like a sessile leaf with a trilobate upper outline, and a concave petiolar attachment; this is the lower margin over the foramen magnum (*f.m.*). What looks in the side view (fig. 3) like a large epiotic swelling is, in reality, seen here to be the thick convex edge, right and left, of the great supraoccipital shield. Here we see the whole line of demarcation between the auditory capsule and the back wall of the skull proper, converted into an arcuate chink, which becomes a triangular recess, below. Outside this, the epiotic and opisthotic regions (*op.*)—to the latter of which the epihyal (*e.hy.*) is fused, and through which the facial nerve (VII.) passes—is but a narrowish convex, lateral tract, thinning out below, where it flanks a very indefinite paroccipital tract (*p.oc.*). Inside that tract, and over and within the condyle (*oc.c.*), we see the orbicular, exoccipital (*e.o.*), only one-tenth the size of the once double upper bony tract (*s.o.*).

Like the rest of the skull the occipital basal margin and condyles are a very wide structure, the bony basioccipital does not reach the foramen magnum; this passage is lower than in *Tatusia* (Plate 6, fig. 4), it inclines upwards and backwards (see figs. 1 and 3). The parietals (*p.*) and squamosals (*sq.*) are hardly seen in this view.

The mandible (figs. 3, 3A) has the same general shape as in *Tatusia*, but it is heavily built, and not at all like the elegantly slight structure seen in the other kind; the teeth also run further forwards, and are larger. Altogether this type is further from the Anteaters than the others, and on the whole less modified from the average Mammalian type.

A little cartilage is still seen in the coronoid and angular processes as well as in the articular; MECKEL'S cartilage (*mk.*) is still quite perfect. The malleus (figs. 3A and 6, *ml.*) is unlike that of *Tatusia*, the head is more solid, and the posterior angular process is more distinct, but high up, almost close to the articular condyle. The manubrium forms an acute angle with the main bar instead of being parallel with it, and having its "elbow" low down; it is also longer, and is dilated at its end.

The small, hooked ectosteal plate has only just begun to graft itself on the under face of the malleus. The incus (*i.*), which is quite unossified, is like that of *Tatusia*, and so is the stapes (*st.*); it also shows a small "interhyal" (*i.hy.*) in the tendon of the stapedius muscle (*st.m.*). The hyoid arch is quite normally Mammalian, and not like that of *Tatusia*; the epihyal (figs. 4 and 5, *e.hy.*) lingers on as part of the general arch, which is thus tied to the skull; the partly ossified upper ceratohyal (*c.hy.*), not

yet segmented from it, thickens downwards, then comes the shorter ceratohyal (*c.hy.*) not ossified, and the hypohyal (*h.hy.*) the same. The body (*b.h.br.*) has no retral process, and is unossified at present; the thyrohyals (*t.hy.*) are partly ossified, and are in this type segmented off from the body.

In these things *Dasypus* shows itself more as a normal Mammal, whilst *Tatusia* is very low and abnormal.

BRADYPODIDÆ.

This second and only other group of Neotropical Edentata with imperfect teeth is in as great a contrast with the first as can be well imagined, and yet I quite agree with Professor FLOWER in looking upon all the Edentata from that region, toothed or toothless, as being suckers from one common root-stock (see Proc. Zool. Soc., 1882, pp. 358–367; and Art. “Mammalia,” Encyc. Brit., 9th edit., vol. 15, p. 384). I shall describe the South American forms first, and then take up the Palæotropical kinds; in both the extreme diversity of the existing forms, and in some cases their almost extinct condition—just one or two species of an extremely isolated type—suggest, powerfully, the great losses this group has suffered since its evolution.

If any one doubts that the short-faced Sloths are intrinsically of the same stock as the long-faced Anteaters of the same region, I would refer him to my figures and descriptions of the scapula in these curiously dissimilar forms (‘Shoulder-girdle and Sternum,’ Plates 21–23, pp. 199–207).

My materials for working out the skull in this group were as follows:—

First Stage. Embryo of Unau (*Cholopus didactylus*),* $3\frac{1}{4}$ inches long (Plate 1, figs. 1, 2.)

Second Stage. Embryo of Ai (*Bradypus*) (*Arctopithecus*), (—? sp.) 5 inches long.

Third Stage. Young of Unau (*Cholopus Hoffmanni*), 8 inches long.

Fourth Stage. Young, half-grown, of Ai (*Bradypus tridactylus*, Linn.).

I have just given reasons for supposing that the Tatous (*Tatusia*) are less typical than the species of the genus *Dasypus*, so I shall now give reasons for considering the Bradypodidæ, generally, as inferior to the Dasypodidæ, as a whole. CUVIER’s insight was never better shown than when he classed the heterogeneous Edentata together—both the Old and New World forms; and the same instinct, which led him to put the Monotremes with them, was not so far out as seems at first sight. I am satisfied that the Edentata in becoming “Eutheria” never utilized the Metatherian stage, but passed rapidly—at a bound, so to speak—from the Prototherian stage, into the basal region of the highest group. There, however, they have stayed; they are just equivalent, in their fullest development, to the lowest and most generalized of the Insectivora, some of which, very probably, are modified and improved “Metatheria,” or Marsupials.

* This Embryo has seven cervical vertebræ; *C. Hoffmanni* has only six.

Skull of embryo of Choloepus didactylus ($3\frac{1}{4}$ inches long).—*First Stage.*

In this type the nostrils, as seen in the *lower view* (Plate 8, fig. 1, *e.n.*), are not inferior, but lateral; and the alinasal floor (*al.n.*) shows but a small distance in front of the premaxillaries (*px.*); the basal alæ reach to these openings, as the roofs do, above (fig. 2, *al.n.*). The premaxillaries are as small as in *Tatusia*, but they have each a well-formed palatine process, nearly as large as the narrow, anterior, or dentary tract. The pointed ends of these submesial spurs do not reach the inner part of the maxillary palatine plates (*mx.*), for these retreat considerably, leaving a considerable angle of membrane exposed; this, and the two round notches between the inner and marginal parts of the premaxillaries, form a cordiform tract, in the anterior lobes of which we see the openings of JACOBSON'S organs (*j.o.*). In this early embryo, about one-third ripe, the palatine plates of the maxillaries (*mx.*) are only just approximating even in the middle; in the hind part, as in front, there is a considerable angular space, enclosed by these ingrowths of bone. The whole of this double tract is nearly square; the breadth across the foremost alveoli is greater than the length in the middle; at the sides, the last pair of alveoli overlap the palatines (*pa.*), and there make the side measurement the longer of the two. Already the foremost alveoli, with their teeth, project most, whilst the last pair project least; there is room for two sockets, with their teeth; between the first and second, a shallow groove is seen along this edentulous space. The inter-alveolar flange is separated from the inner part of the bone by a less distinct groove than that seen in *Tatusia*; behind, it forms, at its palatine end, a definite and widish space. In this view, the facial part of the maxillaries is seen, as a right and left wing; in this space the infraorbital foramen (V^2), is well shown; its bridge, or floor, is narrow. The rest of the palate is very peculiar, it is quite a rough, generalized structure, the palatines (*pa.*) themselves being not so much developed in this region as the pterygoids are in *Tatusia hybrida*, at a somewhat later stage. There is an angular space between the palatine plates of these bones, in front, and behind; they do not meet at the mid line. They then, like the pterygoids of *Tatusia hybrida*, diverge, so as to leave a semi-oval space, in which the broad basis cranii is seen, or all its presphenoidal region (*p.s.*). The ascending or cranial part of the palatines is very limited; the wall formed by the bone is extremely thick and rough, and behind the last tooth socket each bone forms a rounded boss, from which the rest of the bone diverges gently.

But all this roughness is seen in a double degree in the pterygoids (*pg.*), which have a very reptilian simplicity of form, and independence of the basis cranii, to which their attachment is very limited. Each bone is like a rough *nut*, in miniature; it is somewhat scooped postero-laterally, and at its end has a cupped cavity, filled with hyaline cartilage; the remnant of the Ichthyopsidan cartilaginous "upper jaw."

The whole palate is very generalized, and therefore very instructive; it improves afterwards (see Plate 9, fig. 1), and yet in the large young of this genus the palatine

plate of the palatines is as arrested as in the very open palate of a Rabbit, or the most closed ("desmognathous") palate seen in Birds, namely, in *Podargus* (see Trans. Linn. Soc., ser. 2, Zool., vol. i., Tab. 23, figs 6-8).*

In the distance, the large orbital plates of the frontal are seen, and laterally, on the level of the palate, the jugals and squamosals (*j.*, *sq.*); these lateral parts have a peculiar independence of each other. Such is not seen again until we are down among the Lizards and Serpents. Here the large jugal (*j.*) is articulated to the maxillary in front, but has its bifurcated hind part free. Answering to this structure, the zygomatic process of the squamosal (*sq.*) is aborted, and the large crescentic glenoid saddle (*gl.f.*) lies between two thick ridges of bone, its concavity looking forwards. These ridges meet behind the facet as a low, arched postglenoid tract, and then the rest of the bone, as seen in this aspect, runs outside the tegmen tympani (*t.ty.*), largely helping by its concavity to increase the size of the chamber in which the ossicula auditûs (*m.ml.*, *m.k.*) lie, and along which the facial nerve (VII.) runs. A very small tract of skull-wall is seen between the pterygoids and the glenoid region, right and left, but the basis cranii is seen up the fore end of the presphenoidal region (*p.s.*).

That is all cartilaginous, and in this marvellously stout little skull the whole beam has twice the thickness it has in *Tatusia*. The basisphenoidal region is more than equal to the presphenoidal in extent, but its middle two-thirds only is ossified; this basisphenoidal bone (*b.s.*) has all its four subequal sides concave; its outer sides are pressed upon by the pterygoids. Then comes a tract of cartilage which is longer than the bone, but narrows, backwards, for its hind margin is between the most bulging part of the large cochleæ. The basioccipital (*b.o.*) is lozenge-shaped, with the front and hind angle truncated; it is larger than the basisphenoid, and, like it, reaches the edges of the basal cartilage. The occipital arch is less by far than the auditory region, and the paroccipital region is but little marked—as in the Dasypodidæ. The large condyles (*oc.c.*) are partly under the skull, yet they are well seen behind (fig. 4); they are obliquely reniform and enclose a large, subcircular foramen magnum (*f.m.*). The exoccipitals (*e.o.*) are separated by a tract equal, nearly, to their own width from the other occipital centres (*b.o.*, *s.o.*); the hypoglossal (XII.) notches the bone in its lower or anterior edge on the right side, nearer to the auditory capsule than to the condyle. Still further forwards the 9th and 10th nerves (IX., X.) pass out, the basal cartilage being notched for them behind the capsules.

These latter parts are very large, and wholly cartilaginous, at present; the cochlea has the appearance of being composed of only two coils, for the proximal part is one large curved convexity, the distal or hemispherical mass lying in its concavity. Both the fenestræ (*fs.o.*, *f.r.*) are seen in this view, and also the facial nerve (VII.), both along the tegmen, and at its exit behind the thick epihyal (*e.hy.*), which it notches.

* The Unau comes very near the extinct *Cœlodon* in the structure of its palate; compare these figures (Plate 8, fig. 1, Plate 9, fig. 1) with REINHARDT'S admirable illustrations of that type ("Kæmpedovendyrslægten CœLODON." Copenhagen, 1878).

This somewhat *lemurine* skull, seen *from above* (Plate 8, fig. 2), shows in this early stage some promise of the stony solidity of the skull of the adult. The roof-bones are forming rapidly, and only a lozenge-shaped fontanelle (*fo.*) remains in the vertex. The premaxillaries (*px.*) are scarcely seen in this aspect; but the facial plate of the maxillaries (*mx.*), and the great front alveoli, come into view; between them the nasals (*n.*), behind the short snout (*al.n.*), are seen as short, wide bones, only one-third longer than broad, and having their fore edge cut away on the inside. The maxillaries and nasals form a convex margin to unite with the concave fore margin of the frontals (*f.*). Outside their narrow fore end the smallish lacrymals rest on the jugal process of the maxillaries, and behind these the jugals (*j.*) come into view. Even now, in their narrow fore part, the frontals show that *pitting* which is a sure sign of a dense and solid bone in its early stage. The remainder of these bones is radially fibrous, like the parietals (*p.*), and these plates are about equal, the fore part of the frontals being left out of consideration.

The supraorbital rim is better formed than in the Armadillos; its terminal or postorbital process is well defined. From it, forwards, the edge of the bone has a gently concave outline, so that, although the frontals narrow in, forwards, they form everywhere a large roof over the fore brain. The postorbital part of the frontals is one-third the extent of the whole, and it nearly reaches as far outwards as the large convex parietals (*p.*). In their re-entering angle, behind, we get a view of the upper half of the occipital arch (*s.o.*), which is ossified *very early and very rapidly*; much more so than in the Dasypodidæ, although in neither of these types is there any "interparietal" or additional membrane bone, or bones.*

This cartilage bone shows the *pitting*, which is seen in the fore part of the frontals. The occipital condyles (see, also, fig. 1, *oc.c.*) can just be seen from above.

In the side view (fig. 3) we get a display of parts, the figure of which might serve as an elementary diagram of a Mammalian skull. The short, depressed snout shows

* There is something which has to be accounted for, here; the interparietal, which is formed nearly always from two primary centres, and which figures so largely in Marsupials and Insectivores, and in the Eutheria above them, is totally absent in the Neotropical Edentates, and in the Pangolins of the Old World. In *Orycteropus* it is as large as in the Insectivorous *Rhyncocyon* from the neighbouring region—(Zanzibar, East Coast)—a type, the skull of which I shall compare, in my next paper, with what I am able to show of *Orycteropus* in this; for the Cape Anteater lies somewhere between the Armadillos and that most perplexing, most generalized Insectivore. Looking at the Mammalia, generally, and bearing in mind that Birds with the largest skulls (Crows and Songsters) have no interparietal, it seems evident that that bone comes in to help the parietals in roofing in the enlarging brain of the Mammal. In a young *Ornithorhynchus*, the size of a new born kitten, with the hairs just appearing, the parietals form one thick continuous mass, as in the Ophidia, and the large bilobate ossification of the supraoccipital cartilage, is fast growing to its hind margin. I see, also, the same thing in the *Echidna* at a little later stage. Some things, no doubt, in the Edentata are due to *degeneration*, or suppression, but I feel sure that they were never higher in the scale of the Mammalia, on the whole, than they are now, and strongly suspect that they are a sort of metamorphosed Monotremes, in which the Marsupial stage was got through rapidly.

the nostrils with a rounded rim, and a small valvular process; they open laterally. The premaxillaries (*px.*) can be seen in this view, on their outer edge, without any ascending or facial plate, looking no larger than the 1st maxillary tooth.

The maxillaries (*mx.*) are small relatively to the skull, generally, and they have their infraorbital foramen (V^2 , see fig. 1) rather inferior than lateral; there is a small hole in front of the main passage; the bone generally is curiously ribbed and wrinkled.

Over it we see the edge of the nasal (*n.*), and under the contiguous parts of the nasal, frontal, and maxillary, the smallish, thick, perforated lacrymal (*l.*) comes in to form the foremost part of the orbital margin; the canal (*l.c.*) opens on its edge. The jugal (*j.*) has as well-formed an orbital margin as the frontal, above, and they with the lacrymal make a rim about the eye-socket for all but its hinder fourth. Even there the postorbital process of each bone is thick and tends to cover in this part; we shall see that this nascent perfection of the orbital rim is only temporary (see Plate 9, fig. 3), so that the early skull, only, can be said to look towards that of a *Lemur*; here, it is evident, we find signs of degeneracy, or retreat, from the more normal Mammalian type of skull. That the great peculiarity of the jugal bone is not something new in the existing, dwarfed Bradypodidæ is evident, for in this species this early stage shows its great peculiarities best; they are softened down afterwards.*

Below the neat orbital rim of the jugal, the bone is obliquely attached to the maxillary; thence it is free, and ends in a postorbital, a zygomatic, and an infrajugal process; together, these processes give a great depth to the bone; behind the middle and lower snags we see the coronoid process of the mandible.

Over the orbit the frontal rises—until at the vertex it is very high—as the roof of a very large skull cavity. The orbital plate of the frontal is large, but is imperfect below at present. The parietal (*p.*) is larger than would seem from the upper view, for it runs well down behind the auditory capsule, between it and the supraoccipital. The lower margin forms a sinuous line over the inside of the huge, open temporal fossa, and only at its middle, most projecting part does it reach the top of the squamosal (*sq.*). Besides the fontanelle at the vertex (*fo.*) there is another on each side, where the frontals and parietals diverge behind the orbits. This is, at present, several times as large as the upper open space, and as far as superficial bones are concerned, it reaches from that divergence above, and the junction of the squamosal and parietal behind, forwards, to the bottom of the orbit in front. In its fore half it exposes the large orbitosphenoid (*o.s.*), and in its hinder half the long band of cartilage (*s.a.c.*), which runs on to join the top of the auditory capsule,

* If this figure of the skull of the early embryo of the Unau be compared with REINHARDT'S splendid plates of *Cœlodon* (Copenhagen, 1878), and *Gryptotherium* (Copenhagen, 1879), it will be seen how remarkably the jugals correspond. In the latter (plate 1) there is the appearance of a small hole above and in front of the infraorbital foramen, which evidently corresponds with what I have figured in the embryo of the Unau; this small hole is also to be seen in the half-grown Ai.

is seen passing upwards and backwards along the middle of this hinder membranous tract.

We shall see, afterwards (Plate 9), how completely this space is filled in by the frontal and squamosal; the latter is now a large ear-shaped scale of bone with a thick horizontal part, capped with the glenoid facet (see fig. 1). The temporal fossa, widely opening into the orbit, is but slightly walled in externally by the projecting articular part, and its small zygomatic process. The inner plate of the squamosal reaches further forwards than the outer; behind, the bone ends in a round post-temporal lobe, which overlaps the massive ear-capsule up to the junction of the anterior and posterior semicircular canals (*a.s.c.*, *p.s.c.*). The occipital plane is very wide and transverse (see fig. 4); here, in the side view, little save the edge of the arch, with its ossifications (*s.o.*, *e.o.*), and the condyle (*oc.c.*), are seen. At present, the mandibular ramus (*d.*) is very slender, not much stouter than that of *Tatusia*; the absence of teeth makes the fore part narrow (Plate 8, fig. 3; and Plate 9, fig. 9). But the coronoid, articular, and angular processes are large, and largely cartilaginous; the first of these is long and distinct, the next solid and wide, the next a large rounded lobe.

The annulus tympanicus (*a.ty.*), although narrow and simple, is quite ossified already; MECKEL's cartilage (*mk.*) is seen in front of it; the head and manubrium of the malleus (*m.ml.*), are seen between its obliquely placed crura; and behind the head of the malleus the cartilaginous junction of the ear-capsule with the epihyal is seen, behind which the facial nerve (VII.) is emerging. The hyoid arch is short, and the segmentation below what is normal even for a branchial arch; not only is the ceratohyal (*c.hy.*) not re-segmented, but it is continuous with the epihyal. The hypohyal (*h.hy.*) is a longish curved tongue-shaped piece, pointed in front, where it nearly meets its fellow, and articulated loosely with the fore parts of the U-shaped basal piece (*b.h.br.*), for the thyrohyals (*t.hy.*) are not segmented off from it. The only bony deposit is a sheath to the main part of the ceratohyal.

The *end view* (Plate 9, fig. 4) is roughly oval, the long diameter being across, and the lower margin least convex and with several sinuosities. The upper view (fig. 2), which fails to show the full size of the parietals (*p.*), is corrected by the side and end views (figs. 3 and 4). Here they are seen with gently sinuous margins, and meeting at a right angle to overlap the upper margin of the occipital arch and the hind part of the auditory capsules. Below these, right and left, just the thin slightly inturned hind edge of the squamosal (*sq.*) comes into view, binding over the place where, within, the ampullæ of the anterior and horizontal canals lie. For so early an embryo the supraoccipital (*s.o.*) is a very large osseous centre; it has, recently, become one by the union in most of its lower half of two centres of bony deposit; much of the suture is seen above, and a little of it below. The part next the two parietals is nearly a right-angled triangle; on each side the lower angles lie on the auditory capsules. Below them the bone, keeping to its own proper chondrocranial field, has a short concave

edge, touching the top of the two united canals (fig. 4, *p.s.c.*). The angle between this short oblique side and the concave line of the base of the bone dips somewhat into the oblique deep fossa, which at this part divides each capsule from the proper occipital cartilage. The projecting points of each bone, on each side of the lower remnant of the suture, come within a short distance of the neatly circular, large foramen magnum (*f.m.*). Between the convex, ear-shaped condyles (*oc.c.*), below, the basioccipital is seen (*b.o.*), and over, and outside the condyles, the squarish exoccipitals (see fig. 1, *e.o.*) are seen, creeping upwards towards the supraoccipital and outwards into the quite inconspicuous paroccipital region. Outside that tract the epihyals and facial nerves (*e.hy.*, VII.) are shown, and above them the oblique, massive, unossified auditory capsule, swelling with the large canals (*op.*, *p.s.c.*). Already, so rapid is the ossification, the broadest part of the supraoccipital bone (*s.o.*) is marked by an arched ridge for muscular attachment right and left of the mid-line; these ridges are parallel with the lower margin of the bone.

A *vertically longitudinal section* of this most instructive skull (Plate 15, fig. 5) shows the height of the skull cavity, whilst the embryo is still very immature, and the continuity of the marginal part of the cartilaginous skull-basin is still complete. As in the side view, the frontals, parietals, and squamosals (*f.*, *p.*, *sq.*) are seen, just meeting in their most projecting parts, but they fail to wall-in the skull. Already, in front, the frontals are very thick, and the nasals (*n.*) also; the middle vomer (*v.*) is short and stout, and the anterior paired vomers (*v'.*) are small, thin, curved, clavate bones.

The septum nasi and perpendicular ethmoid (from *a.l.n.* to *p.e.*), together, form but a small, low, triangular wall, whose blunt apex is a little behind the middle, and scarcely rises into a cartilaginous crista galli. Altogether, this part of the skull is less developed than in the Armadillos. Between the partition of the snout and the proper septum nasi, there is a small oval fenestra (*i.n.f.*), with its long axis lengthwise.

The thick hind margin of the vertical ethmoid (*p.e.*) is grooved for the olfactory nerves, but the cribriform plate (*cr.p.*) is but little seen in this view; between it and the orbitosphenoidal band (*o.s.*) there is a semicircular fenestra. The roof-cartilage is cut away (*al.n.* to *al.e.*), and also the alinasal (*al.n.*) itself, but its thickness is shown; the base of the whole septum is thickened below by the great intertrabecula. This is shown as cut away from the presphenoidal region (*p.e.*, to *b.s.*), for in the hind half the section is in the middle, but in the fore half the basal part is left complete.

Where the alinasal region ends, there the cartilage gives off a curious spoon-shaped retral process, the recurrent cartilage (*rc.c.*); this is concave outside and convex towards the septum nasi; it protects JACOBSON'S organ, and so, also, does the little additional vomer (*v'.*) seen on each side in this region. These parts are better seen below (Plate 15, fig. 6), which shows the broad, symmetrical floor of the snout and the lateral nostrils (*n.f.*, *e.n.*). The floor is elegantly alate behind, and from each

ala, on its inner edge, arises a recurrent cartilage. Together, in this view, these look like a lanceolate leaf, with convex halves, like that of *Magnolia grandiflora*. The walls are developed into the inferior turbinals (*i.tb.*; see also Plate 8, fig. 9, in *Bradypus*); the inner part of the floor is developed behind them. Between the halves of the nasal floor the middle vomer (*v.*) is seen; it is short, notched behind, carinate, and has its fore end, which is blunt, hidden by the recurrent cartilages; behind the vomer, the widening basis cranii is seen where the vertical ethmoid passes into the presphenoid (*p.e.*, *p.s.*). This latter region (fig. 5) is still unossified; it passes insensibly into the perpendicular ethmoid in front, and on each side grows into a large wing, the orbitosphenoid (*o.s.*), which is perforated at its base by the optic nerve (II.). In this stage the cartilage ascends and becomes a large plate, continuous by its fore corner with the margin of the rhinencephalic fossa, floored by the cribriform plate (*cr.p.*). Below that junction there is a crescentic fenestra between the two regions, then the orbitosphenoid rises inside the orbital plate of the frontal (*f.*), and then dips again beneath the hind lobe of that bony plate. Across its widest part the orbitosphenoid is nearly equal to the great internasal partition. After a little irregularity of margin the cartilage runs on, rising upwards again as a narrow band, and then loses itself in the wide supratemporal lamina, which, in its turn, passes into the supraoccipital (*s.a.c.*, *s.o.*); the upper edge of the supratemporal tract is crenate, and so is its front margin, where it forms the postero-superior margin of the huge oval lateral fontanelle. That space is as wide as the auditory capsule, and wider than the orbitosphenoid; it is covered in, externally, all but its anterior and upper margin, by the alisphenoid (*al.s.*) below, and the squamosal (*sq.*), still further outwards, above.

That peculiarly Mammalian character, the out-thrust of the alisphenoid, is well seen here; this "ala" is now ossified as a thick bilobate mass, which leans backwards on to the tilted auditory capsule; it is still separate from the basisphenoid (*b.s.*); this bony deposit does not reach the low, transverse postclinoid wall. At present, I see no proper foramina in the alisphenoid (*al.s.*), but the branches of the 5th nerve ($V^{1,2}$, V^3) evidently pass through mere fissures. Over the notched top of the alisphenoid we see part of the squamosal (*sq.*), and the 3rd branch of the 5th nerve (V^3) escapes, at present between that bone and the alisphenoid (*al.s.*), in the chink between its lobes, whilst the 1st and 2nd branches ($V^{1,2}$) emerge through the sphenoidal fissure; this bone is very rudimentary at present.

The rest of the endocranium, proper, is well distinguished from the auditory capsule, which is tilted back at an acute angle to the basis cranii. The whole capsule is one-third larger in outline than the fenestra in front of it; the cochlear portion is jammed in between the basal beam and the infero-lateral walls (see also Plate 8, fig. 1), whilst the upper and hinder margin is ribbed all round by the thickening outside the anterior and posterior canals (*a.s.c.*, *p.s.c.*); this thickening is increased and turned downwards where the two canals are fused into one "sinus." Behind the ampullar region of the anterior canal there is a notable aperture, seemingly for the facial nerve (VII.), but

it is in front of the great archway for the branches of the facial and the auditory nerve (VII., VIII.). There is a lesser aperture under the anterior canal, where the concavity is shallow, as in the Dasypodidæ, and not deep, as in the Insectivora and many other Eutheria; hence the "flocculus" must be but little developed in these Edentata. The endocranial "setting" of the capsule is about two-thirds the breadth of the imbedded sense-organ which bulges, inwardly, and is, although confluent with the capsule here and there, yet everywhere well marked off from it.

The relation of the three osseous centres—the basi-, ex-, and supraoccipital (*b.o.*, *e.o.*, *s.o.*) is well seen; the basal piece is one-third longer than the cartilage in front of it, twice the length of the basisphenoid (*b.s.*) in front of that. There are four holes in the short exoccipital; the largest of these, behind, is evidently the posterior condyloid foramen, the rest would appear to let out the hypoglossal (XII.) in three strands; externally (Plate 8, fig. 1), it only has one passage for its exit. The deep oblique passage for the larger post-auditory nerves (IX., X.) is shown in this figure.

The *inner view* of the double mandible (Plate 9, fig. 9) shows some extremely important morphological points. The *primary* mandible runs from a point near the fore end of the *secondary* ramus to a point considerably behind it; it is therefore the longer of the two; moreover, it is in two parts, a short proximal, and a long distal, segment. The true swinging point of the primary mandible—the "pedicle" or "orbital process," such as we see in the Ovipara—is suppressed in the Mammal; hence the *incus* (or quadrate) has merely the secondary or hinder point of attachment, above, the *short crus* (*s.c.i.*) or "otic process." The line of segmentation or condyloid face is sinuous or saddle-shaped, and the *specialty Mammalian process*—the *long crus* (*l.c.i.*), with its inturned neck and flat orbicular head for articulation with the topmost segment of the hyoid arch—is well developed. The solid condyloid region of the main or distal segment, the head of the malleus, overlies the scooped tract that gives off the blunt "posterior," (*p.ag.*), and long foreturned "internal angular process" (*manubrium mallei*, *m.ml.*); this latter part is slender, pinched in the middle and pointed at its end. The main shaft or MECKEL'S cartilage (*mk.*) is pinched on its inner face proximally and then runs its course, gently arching downwards, and thickening in the middle as a strong terete rod. Where it joins its fellow, there a small basal rod (*b.mn.*) is given off which lies in the symphysis of the superficial *rami*. The outside part (*d.*) has already been described as seen from its outer side (Plate 8, fig. 3); here, in front of the dentary canal, a flange of bone is given off from the alveolar wall, which overlies MECKEL'S cartilage; this tract is the continuous counterpart of the distinct splenial and coronoid of the Ovipara.

The *stapes* (Plate 9, fig. 9, *st.*) or topmost segment of the hyoid arch is shown as dissected away with the double mandible; its oval proximal head is seen sideways as a thick rim to this short flat rod. The length of the rod (not a *stapes* but a "columella") is equal to the breadth of this proximal plate; its hind margin is concave, and its front convex. There is a short distal neck, with a circular flat head,

for articulation with the incus, and in the tendon of origin of the stapedius muscle (*st.m.*) there is a round "interhyal" (infrastapedial) nucleus of cartilage (*i.hy.*).

Besides the superficial dentary bone (*d.*), with its splenial and coronoid tract, there is only one other osseous centre shown in this figure; that is the first rudiment of the malleus (*ml.*)—as a bone—and it is the homologue of the "articulare externum" of the Ovipara.

Skull of an embryo of Bradypus (Arctopithecus) —? sp. (5 inches long).—Second Stage.

We must in these comparisons keep in view the fact that we are dealing with modifications of growth in the individual, and also with specific, and even generic differences; these latter are not very great, and can easily be allowed for.

This skull of an embryo, almost twice as advanced as the last, looks more embryonic than it, for the face is shorter, and the cranium swells up above, giving it an almost Simian character (Plate 8, figs. 5 and 6).

The lower view (Plate 8, fig. 5) is curiously like, and yet in several things unlike, that of the earlier embryo of the Unau (Plate 8, fig. 1). The nostrils and alinasal region (*e.n.*, *al.n.*) are quite similar in both, but behind them the premaxillaries (*px.*) are smaller, but have longer palatine processes. The anterior palatine foramina, exposing the openings of JACOBSON'S organs (*j.o.*), are better enclosed as two lanceolate spaces, for the maxillaries (*mx.*) have closed in, in front, and bind on both the palatine processes behind, and the feeble dentary tract of the premaxillaries.

The hard palate is not a squared oblong tract here, but is elegantly *urceolate*, for the fore half forms an outline of more than half a regular ellipse, then it narrows gently, and then widens again, to grow out into handles or horns, where the palatine bones (*pa.*) take their part in its formation.

The whole maxillary region is well flattened out; a pair of middle palatine foramina end the submedian grooves, which bend outwards near their fore end. One-fourth further back the palatine plates are cut away, in a semi-oval manner, to make room for two wedges of bone, the fore part of the palatines. The rounded end of the alveolar tract of each maxillary rests against the thick outer part of the palatine, and the sockets, with their teeth, scarcely enlarge from the fifth, forwards, to the third; the second is the largest tooth, and swells the bone out there to its greatest convexity. The first tooth is less than a fourth the size of the second, and lies midway between it and the front convergence of the bone.

Outside the second and third teeth the maxillary enlarges outwards, so as to hide the infraorbital foramen in this aspect; this squarish outgrowth gives a horned appearance to this part of the skull, so viewed. The hind part of this tract articulates with the jugal (*j.*), being rugged where that bone fits in, and then there is a rounded notch between this short jugal process, and the outer alveolar wall. Each large jugal (*j.*) stretches outwards and backwards to its free but notched end; the

right is larger than the left. Longitudinally, in the hard palate, the palatines (*pa.*) are half as long as the maxillaries, but their semicircular hind margin is but a short distance from the end of the alveolar tract of the maxillary. The thick outer part, forming a wall to the naso-palatine passage, projects outwards, and is notched behind for articulation with the pterygoid (*pg.*). The upper transverse flange of the palatine, which articulates with the presphenoidal cartilage (*p.s.*), is followed by a similar plate, belonging to the pterygoid, which binds upon the bony basisphenoid. The descending part of the pterygoid is nearly parallel with its fellow; the two continue the naso-palatine wall, but are not so solid—in *this species*—as the corresponding tract of the palatines; the hook or “hamular process” is blunt, free, and capped with hyaline cartilage.

Through the badly-enclosed orbital space the orbital plate of the frontal can be seen, but much less than in the Unau embryo (Plate 8, fig. 1). Outside, the large squamosals (*sq.*) flank the greater part of the hind skull; they have a considerable temporal tract binding on the alisphenoids (*al.s.*), outside which there is a large glenoid facet (*gl.f.*), protected externally by a thickish zygomatic process, which projects forwards more, and is sharper than that of the other kind (Plate 8, fig. 1). Behind the glenoid region the squamosal bulges outwards, greatly increasing the strength of the auditory region; it reaches, behind, to a point over the stylomastoid foramen (VII.). Abutting against this posterior tract of the squamosal are seen the two backwardly-turned horns of the large annulus tympanicus (*a.ty.*), a bone which, even now, is a broadish shell, with a dentated inner margin. Both really and relatively, these “rings” are much larger than in the other kind; in both they are large, relatively to the size of the skull; but in this kind they cover the cochlea (*chl.*) much better. Much of the endocranium is visible in this aspect. In the fundus of the orbit the unossified top of the orbitosphenoid and the optic nerve (*o.s.*, II.) are shown, then the sphenoidal fissure (*V^{1,2}.*), followed by the large, thick, ossified alisphenoid, notched, above, for the third branch of the 5th nerve (*V³.*). In the middle, the broad basisphenoid (*b.s.*), notched in front and concave behind, lies behind a tract of cartilage, which narrows forwards; this is the presphenoid (*p.s.*). The synchondrosis is less than half the extent of the basisphenoid; then comes the basioccipital (*b.o.*), one-third larger than that bone, imperfect in front, and alate and sub-triangular behind. The apex of the triangle is notched, for there the bone forms a small part of the outline of the foramen magnum (*f.m.*). The rest of the occipital arch is but little seen in this aspect; but the large condyles (*oc.c.*), the postauditory and condyloid foramina (IX., X., XII.), the interspace of cartilage between the basioccipital and the exoccipitals (*b.o.*, *e.o.*), as large as these centres, right and left, and the edge of the supraoccipital cartilage (*s.o.*), behind the foramen magnum, are clearly shown.

A widish crescentic tract of cartilage, the inner face of the cochlea (*chl.*), is seen inside each “annulus;” and, opposite the fore end of the basioccipital, the Eustachian opening (*eu.*), a lipped, crescentic slit in the inner and front face of the tympanic

cavity, is also shown. MECKEL'S cartilage (*mk.*) is cut off where it is ready to enter the Glaserian fissure, and obliquely across the membrana tympani the manubrium mallei (*m.ml.*) runs inwards and forwards, stretching the drum parchment.

The *side view* (Plate 6, fig. 6) shows a skull still more in contrast with that of the long-faced Edentata than that of the Unau (fig. 3). The *simian* shortness of the face, as compared with the bulk of the swelling skull, is very noteworthy; for the *Ai* has gone off on one way, as far as the Ant-bear on another.*

The small snout, with its rounded lateral external nostril (*e.n.*), surrounded by a valvular growth, is followed, in this view, by the maxillary below, and the nasal above (*mx.*, *n.*), for the premaxillary is too small to be seen laterally.

The short broad nasals (*n.*) just overlie the facial plate of the short but broad maxillary (*mx.*); at the postero-superior angle, however, the frontal (*f.*) comes in, and below its angle the lacrymal (*l.*) lies in a notch on the maxillary; it is a small seed-like bone perforated on its most projecting part (*l.c.*). A little below the lacrymal, another notch in the hind margin of the maxillary receives the large falcate jugal, which forms the lower margin of the orbit. This bone sends downwards a spur behind its middle, where it broadens considerably; the free hind part ends opposite the lower angle of the parietal (*p.*). The bone on the *right* side (fig. 7) is larger than that on the left (fig. 6), and has a deeper and wider descending process; its postero-superior part is also notched in a shallow manner. Even on this side the descending process is not equal to that of the embryo Unau (fig. 3, *j.*).

Measured along the lower border, the frontal is found to be one-fourth shorter than the parietal (*f.*, *p.*), but the depth of the frontal exceeds that of the parietal on account of the large size of its concave orbital plate. The upper fontanelle is not quite covered, the lateral membranous space seen in the embryo Unau (fig. 3) is in this covered by the meeting together of the frontal, parietal, and squamosal (*sq.*).

The large roof-bones are very convex above, their suture—the coronal—is sinuous, the frontal margin being convex above and below and concave in the middle, and the parietal the contrary to this. The squamosal, beginning even now to form its large air-cavity, forms a roughly oval, convex shell of bone. It has a stout zygomatic process, behind and within which is the glenoid facet (*gl.f.*, see also fig. 5); the cranial plate runs further forwards than the zygomatic spur, which latter part is some distance from the end of the jugal.

The upper margin of the squamosal, in the large open temporal fossa, is convex, the lower is sinuous, dips downwards, and is somewhat notched, behind, where it overlaps

* If Nature, who "innovateth gently," can show us such results as these—can in process of time grow the *Ai* and the *Ant-bear* from one common "root-stock"—we need have no misgivings about the divergence of any primary radical type, whatever. As to sudden variations which may develop into important modifications, divaricating this way or that, I shall be able, when I come to the Insectivora, to show polymorphic types that suggest possibilities of all sorts.

the opisthotic region (*op.*). An oblique view is had, also, of the annulus tympanicus (*a.ty.*) with its related parts.

The mandible (*fig. 6*) is shorter and stouter than in the embryo Unau (*fig. 3*), the coronoid process (*cr.p.*) is not so sharply divided from the articular or condyloid process (*cd.p.*), and the angular (*ag.p.*) is much deeper, further forwards, and has a larger crescentic notch between it and the condyloid part; the middle of these processes, only, is still capped with cartilage.

Of the parts of the endocranium to be seen in this view, the snout (*al.n.*) has already been described. Inside the orbit, the orbitosphenoid (*o.s.*) is partly seen, with the optic nerve (*II.*) emerging; the upper border of this plate is indicated by dots along the orbital plate of the frontal. MECKEL'S cartilage and the manubrium of the malleus (*mk.*) are seen, and behind the large investing bones the massive occipital arch. The large supraoccipital (*s.o.*) looks like a continuation of the roof plates; below it, the tract of cartilage is large, for the exoccipitals (*e.o.*) are small at present, they are creeping round the outside of the projecting condyles (*oc.c.*). Where the epihyal passes off from the opisthotic region (*op.*) there some bony deposit has begun; then the bar suddenly lessens and ossifies as the ceratohyal (*c.hy.*), which is short, one-jointed, and is articulated to a shortish, thick, unciform hypohyal (*h.hy.*). That segment is attached by its narrow distal end to the front of the U-shaped unossified basal pair; the thyrohyals (*t.hy.*) are mere spurs, the crura, of the U-shaped piece, as in the Unau.

The *end view* of the skull (Plate 13, *fig. 10*) is much like that of the younger embryo of the Unau (Plate 8, *fig. 4*), and as in the latter the ossification is nearly as far advanced as in this much older embryo, it follows that the ossification is more rapid and intense in the other kind—the Unau.

Signs of median subdivision are still evident in this large, roughly semicircular centre (*s.o.*), which has thoroughly ossified all the upper part of the large occipital plane. The lower angles are cut away, as it were, the shortened outline then running inwards and downwards; thence the lower outline, sharply marked off from the cartilage, has a small median and two large lateral concavities. Here the foramen magnum (*f.m.*) is pyriform, the narrow part being above; the condyles (*oc.c.*) project well, and are flanked by the small exoccipitals (*e.o.*); a very small tract of the basioccipital (*b.o.*) is seen in the fore margin of the great opening. The epihyals (*e.hy.*), as they pass inwards and forwards, cover part of the shallow and narrow paroccipital region; above, and outside them, the opisthotic region (*p.s.c.*, *h.s.c.*) is seen from behind. Covering the whole top and sides we see the parietals and squamosals (*p.*, *sq.*).

Part of a *vertical section*, taken left of the great septum (Plate 8, *fig. 8*, *p.e.*), shows this wall as a short low triangle, shorter than in the Unau, but higher (Plate 15, *fig. 5.*). A small fenestra (*i.n.f.*)—very common in low Eutheria—appears near the end of the snout, dividing the septum nasi, proper, from the septum of the snout, where the alinasal tract (*al.n.*) ends below; thence the cartilage grows backwards as the

spatulate recurrent cartilage (*rc.c.*), right and left ; it is hollow on its outside, convex within, and hides the fore part of the short median vomer (*v.*). The whole septum (*p.e.*) is moderately thick, and has the roof (*al.sp.*, *al.e.*) cut away. Behind, the outline of the septum is arched, but there is no special crista galli. Further back, and below, the presphenoidal cartilage (*p.s.*) passes into the basisphenoidal (*b.s.*), which is ossified. The naso-palatine canal is rather deep, and is divided along the mid-line for some extent into two channels by the vomer (*v.*) About this time the small hinder lateral vomer appears right and left of the forks of the vomer : it was not noticed in this specimen. Part of the frontal, nasal, maxillary, palatine, and pterygoid are seen in this view. The small front paired vomers (see in the Unau, Plate 15, fig. 5, *v'*.) are probably already fused with the palatine processes of the premaxillaries. A large tract of the other half of this *vertical section* (Plate 8, fig. 9), with the orbito-temporal wall-bones—frontal, parietal, and squamosal (*f.*, *p.*, *sq.*), partly drawn, shows, also, the inside of the nasal labyrinth, with the lower, nasal, middle, and upper turbinal folds (*i.tb.* line wrong, *n.tb.*, *m.tb.*, *u.tb.*). The orbitosphenoid (*o.s.*) has lost its front and hinder fastening bands (see Plate 15, fig. 5), but it is still much larger than the alisphenoid (above *b.s.*), its angles, from which the bands have been absorbed, are rounded, and the upper margin is concave. Less than the antero-inferior fourth of this tract is ossified, and this centre lies in front of the optic foramen (II.), which is bounded behind by a very narrow tract of cartilage, *soon to be absorbed!* The lesser alisphenoid, and also its base (*b.s.*), is quite ossified ; it is a roughish, thick bilobate wing of bone, the hinder narrow lobe being separated from the broad front part by a deepish notch, under which is a small foramen ; the notch is the beginning of the foramen ovale (*V³*), not finished on its outer side (see the Unau, also Plate 15, fig. 5). The internal carotid artery enters in at the notch between the alisphenoid and its base, and the 1st and 2nd branches of the 5th nerve (*V^{1,2}*), pass out of the sphenoidal fissure between the two “*alæ* ;” afterwards a bar of bone divides the passage for the second branch of the 5th nerve from the sphenoidal fissure, thus anticipating the *human* foramen rotundum,—a very inconstant passage in the Mammalia, generally. The solidity of the bones at this part is shown by a *transverse* section of the alisphenoid, basisphenoid, and pterygoid (Plate 13, fig. 11, *al.s.*, *b.s.*, *p.g.*).

An *inner view* of the double mandible instructively follows that already described in the Unau (Plate 9, figs. 8 and 9). Here the superficial “*ramus*” (fig. 8, *d.*), shows a great difference between the two types, as already described ; but the endoskeletal or more archaic parts are not so much unlike ; part of the difference here, namely, the lessening of MECKEL’S cartilage (*mk.*), and the ossification of the “*ossicula*,” is due to age. The splenio-coronoid region of the ramus has thrust MECKEL’S cartilage down to the lower edge of the mandible, and bent it into a curiously sinuous rod. The basal rod (*b.mn.*) is large and quite perfect yet. The malleolar portion (*ml.*) has a less lobular head, and a more dilated manubrium (*m.ml.*) than in the other kind, for there is well seen, from the inner side, a consider-

able flange or crest to the thick lower edge of this "internal angular process." The incus (*i.*) and the stapes (*st.*) are much alike in both species; the latter is seen edgewise in this, and flat in the other. There is a definite cartilaginous nucleus—the interhyal (*i.hy.*), in the beginning of the tendon of the stapedius muscle (*st.m.*).*

Skull of young Unau (Cholopus Hoffmanni), 8 inches long.—Third Stage.

Taking such materials as come to hand, I now get a third stage in a very young Unau of the species that has only *six* cervical vertebræ. In interpreting the adult skull of this type, this stage alone is of great importance, the ankylosis of that massive skull being so intense.†

A *lower view* (Plate 9, fig. 1) of this strongly built skull, already very solid, shows, in front, a very small tract of the snout, with its lateral openings (*al.n.*, *e.n.*). Behind it, the two wings of bone, meeting in front at a very obtuse angle, are the edentulous dentary regions of the premaxillaries (*px.*); they are quite inferior (see fig. 3) in position. They slightly overlap the maxillaries (*mx.*), and close to the mid-line send backwards a small styloid palatine process; between the two there is a rounded notch, and this forms the front border of the anterior palatine foramen, with the aperture of JACOBSON'S organ (*j.o.*) seen in it; each maxillary is cut away, as it were, obliquely, to form the hind margin of this space; the two foramina open into each other, behind.

The whole of the bony palate, solid from side to side in the first three-fifths, and then strongly enclosed, right and left, but exposing a spatulate tract of the endocranial base, is a most remarkable architectural growth. The huge first tooth—a doubtful "canine"—is fixed in a large swelling socket; thus this part of the face and palate is greatly widened. There is then a rounded interspace, large enough for another tooth equal to those that follow; there are four of these, the second is the largest, and the last the smallest of the series. These curious mammillate teeth, resembling the degenerate teeth of the Walrus, but devoid of enamel, make their outer alveolar wall sinuous; it draws in, backwards. The alveolar "flange" in the hard palate is one-third wider than the submesial part of each bony plate; the ragged groove, right and left, is nearly straight, and the two are almost parallel.

The zygomatic process of the maxillary, opposite the second tooth, projects further outwards than the socket of the first, an oblique suture with few "teeth" is seen running backwards and inwards, between this process and the jugal bone (*j.*). The palatines (*pa.*) scarcely form a tenth part of the hard palate; they run in, behind

* If these two mandibles, belonging to such closely related types, be compared with those of the Dasypodidæ, already described, and with that of the lesser Ant-eater (Plate 10), and of its huge relative the Ant-bear, then the most easy passage is seen from type to type; during growth, the mandibles of the two sorts of Sloth approximate very considerably (see Plate 9, figs. 3, 8, and 9).

† I owe this specimen, and many others, to my lamented friend, Mr. W. A. FORBES.

and between the palatine plates of the maxillaries, which together have a convex margin outside and a concave margin at the middle, answering to the curved line of the fore edge of the palatines. The notch bounding the naso-palatine canal—as seen in the skull—is rounded, but each palatine projects a little where it meets its fellow. Outside, the palatines do not form a third of the wall, which is finished by the pterygoids (*pg.*); both of these bones are dilated into a subcranial flange above. The pterygoids look like short clubs; they are, in reality, rough shells of bone, and open in front into the naso-palatine canal. Being so large, they hide much of the alisphenoids, which are clamped by them up to their antero-inferior margin, and are, themselves, notched to let the 3rd branch of the 5th nerve (V^3 .) pass out of the foramen ovale. Behind that passage they unite by suture with the squamosal, inside and in front of the glenoid facet (*gl.f.*). Along this line of junction with the squamosals the pterygoids are grooved; inside that groove they swell into a large bilobate mass, which reaches further backwards than the fore edge of the basioccipital (*b.o.*), close in front of the Eustachian openings (*eu.*).

Outside the hard palate, in the distance, we see the orbital plates of the frontals (*f.*), and nearer the eye, the jugals (*j.*). These latter bones are large shells, convex infero-externally, and concave above; the inferior margin is cut away in its hinder two-fifths, and ends as a free rounded lobe some distance in front of the aborted jugal process of the squamosal (*sq.*); the *right* jugal reaches much further backwards than the left. This want of facial symmetry I have already described in the *Ai*, also (Plate 8, figs. 6, 7, *j.*). The great extension of the squamosals, fore and aft, is seen in this figure, as well as in the side view (fig. 3.); for these bones bulge forwards, under the parietals, close to the back of the orbit. Hence a considerable tract of each bone is seen inside in front of the large uncinatè, reniform glenoid facet (*gl.f.*), with its protecting stump of a zygomatic process. Binding obliquely against the side of the hinder half of the skull, each bone forms an eave over the tegmen tympani, between which and the top of the ear-drum there is a large fissure, the postglenoid passage into the pneumatic cavity of the bone (see also fig. 3, *sq.*). The imperfect annulus (*a.ty.*) surrounding the exposed drum-membrane is fastened, like a horse-shoe, under this eave of the temporal bone; it is less developed than in the *Ai*, but is a strong bone notwithstanding.*

Outside the palatine, the exposed part of the orbitosphenoid (*o.s.*) can be seen with the optic nerve (II.) emerging. Then the alisphenoid, with its special Mammalian out-thrust is seen behind the orbital wing and the sphenoidal fissure (V^1 .); close to the edge, the foramen rotundum (V^2 .) can be seen. Then this thick outstanding wing

* Many and most instructive parts of the endocranium come into view here, and this skull, so like that of the extinct Megatheroids (see REINHARDT, *op. cit.*), can be seen to have a most remarkable conformity with that of the great Ant-eater—the little *Cycloturus* serving as an interpreter between these two skulls, whose outward form is so dissimilar. No one, however, who is familiar with the structure of Birds—especially the Ratitæ, and the Carinate Grallæ—will be surprised at this.

binds down upon the fore part of the squamosal, and its oval hole (V^3 .) can be seen, where the pterygoid also underlies the alisphenoid. Between the palatines and pterygoids the basal parts of the two sphenoids are shown. At their base the orbitosphenoids ($o.s.$) are fast meeting each other, presenting each to each a convex edge; there is no bony presphenoid. The interspace of cartilage here enlarges into a roundish tract, bounded, behind, by the basisphenoid ($b.s.$), the descending ribbed margins of which touch the orbitosphenoidal bones by their fore ends. The suture between the alisphenoids and their basal piece can be seen outside these crests.

From the presphenoidal cartilage ($p.s.$) to the foramen magnum ($f.m.$) the basis cranii is scooped, or concave, and widens, gradually, to the end. The basisphenoid ($b.s.$) is one-third longer than wide, and is notched in a rounded manner at both ends. The cartilage between it and the basioccipital ($b.o.$) is a transversely oval tract, and the two bones nearly touch by their outer margins. The rudimentary crests growing down from the edges of the basisphenoid are the homologues of the wings, so familiar to us in the Insectivora, that assist in the formation of the ear-drum. The much larger, thick, diverging ridges that grow from the edges of the basioccipital, are the exact counterparts of the ridges to which the elongated pterygoids are attached in the Ant-eaters (see in *Cycloturus*, Plate 10). Here the shortness of the palatines, and the arrest of the dilated pterygoids in front of the basioccipital, makes all the real difference there is in these parts between this Sloth and an Ant-eater (*Myrmecophaga*, *Cycloturus*). These outgrowths of the basioccipital of the Unau might have served the same purpose as the tympanic wings of the basioccipital in the Insectivora, or the alisphenoidal outgrowths in the Marsupial.* Here they serve no auditory purpose, but are used as strong points of attachment to muscular bands. Narrowing, again, from the ends of these ribbed edges, the basioccipital runs now nearly to the convex condyles ($oc.c.$), and has a deeply emarginate hind margin against the foramen magnum ($f.m.$). In front of the reniform condyle there is an oval mass of cartilage, and beyond it the exoccipital, pierced by the 12th nerve (XII.), and forming a low paroccipital ridge ($p.oc.$) against the auditory capsule. As the occipital plane leans forward, above, the supraoccipital ($s.o.$) is only seen at its lower edge, bounding the foramen magnum, behind. Right and left of the basioccipital the auditory capsule is seen here and there, hidden largely by the drum-ring and membrane. Here the ossified manubrium ($m.ml.$) is seen, and opposite it is found the long-lipped Eustachian opening ($eu.$). The opisthotic region ($op.$) is seen outside the paroccipital, and running from, and through it, the epihyal, and facial nerve ($e.hy.$, VII.).

The *upper view* (Plate 9, fig. 2) shows a strong, smooth, oval roof, composed mainly of three pairs of bones that lessen, forwards: these are the nasals, frontals, and parietals ($n., f., p.$). Together, the nasals have somewhat of an hour-glass shape, but they are pointed in front and spread out behind, at their frontal suture. The

* The root of the "tympanic wing" in the Marsupial is a direct outgrowth of the alisphenoid; the hinder part is the "os bullæ," ankylosed to that root.

frontals begin wider than the nasals at the suture, and then are cut away gently in an arcuate manner over the orbits. This crescentic rim is rounded, and beyond it there is, towards the frontal suture, a gentle crescentic hollowing of the surface. The postorbital process is rounded and short, and the last third of the bone behind it widens up to the parietal. Longer than the nasal suture, the frontal and saggital sutures are nearly equal, and the wide swelling parietals (*p.*) gently dip towards the temporal and supraoccipital regions. In the latter place, from above, the endoskeletal keystone of the back skull (*s.o.*), is just seen as a transversely spindle-shaped tract. Laterally, the squamosals (*sq.*) can just be seen flanking the parietals.

In front the alinasal porches (*al.n.*) can be seen, more than from below ; and, in the distance, the top of the dentary region of the premaxillaries (*px.*) comes into view. But behind, and outside these parts, the maxillaries and nasals (*mx.*, *n.*) meet with no premaxillary process intervening ; thus there is a deep triangular notch right and left. Outside that notch is the swelling first tooth-socket, then a deep rounded indentation, and then a hinder swelling of the maxillary, where it binds upon the small burrowed lacrymal (*l.*, *l.c.*) ; these strong round knuckles of the maxillaries give the skull a remarkable form. Behind these parts, in the distance, the jugals (*j.*) show their scooped upper or suborbital face, with their thickened outer edge.

The *side view* (Plate 10, fig. 3) shows many parts with their relations not well seen in the other aspects. The circular narial cartilage and hole (*al.n.*, *e.n.*) is seen in front of the recess caused by the suppression of the facial process of the premaxillary (*px.*), which is just seen, below. The nasals are seen, now, to be, not one-fourth shorter than the frontals (fig. 2, *n.*, *f.*), but only one-seventh ; the outer and hinder lobe of the bone, also, shows well, wedging in between the frontal and maxillary, over the lacrymal (*l.*) of which we have got, here, the best view. It is not so small as the other aspects suggest, but has a good oblong facial tract, thus forming a thick perforated rim to the orbit, and it runs inwards as a small antorbital plate. Then, the maxillary (*mx.*) below, also, takes a good piece from the fore edge of the scooped orbital plate of the frontal by running up inside the fore rim, and joining the small antorbital plate of the lacrymal. This tract appears to me to be a very unusual antorbital growth of the maxillary, preventing any appearance of the lateral ethmoid as a "pars plana."

The outer part of the maxillary is a large high plate, worked well in to the lateral notch of the nasal, and carrying on its scooped descending hind edge the lacrymal and jugal. Its last tooth-socket and tooth can be seen, here, inside the notched jugal ; three more teeth are seen, in their convex sockets, and then a gap before we come to the swelling socket of the large tusk. About two-thirds of the orbit is rimmed with bone, and the lower half of the rim is formed by the free-ended notched jugal (*j.*). Over its margin is seen the orbital plate of the frontal, under the short thick supraorbital eave ; it is notched twice, below, and the ophthalmic nerve (*V¹.*) takes its remarkable course under the front notch, below which some unossified orbitosphenoid (*o.s.*) is still to be seen. Under and in the other notch that plate is ossified, and deep in, under the

jugal, the optic hole (II.) can be seen. The temporal region of the frontal is gently marked off from the orbital, and here a large triradiate suture can be seen; it is formed by the squamosal running backwards and forwards from the coronal suture; both of these are very long seams.

The coronal suture runs downwards and forwards, and the squamosal backwards and downwards; these plates of bone, thus stitched together, swell towards the temporal space and muscle, and that space is but little enclosed, outwards, by the stunted zygomatic process of the squamosal. Over those parts the parietal forms a larger front, and a lesser hind, convexity, and ends against the supraoccipital in a straightish line—half the lambdoidal suture (see fig. 4). The squamosal is two-thirds the size of the parietal; it is a roughly oval plate, narrowing backwards.

Before and behind its edge is fretted away, or toothed, below; between its ends the bone grows outwards, swelling behind into an air-cavity of unusual size, in front it grows out into the condyle and small zygomatic spur (*gl.f.*).

Under the notched fore edge we see the alisphenoid standing out from the orbitosphenoid, and between the two sphenoidal fissure (V^1). Close under and behind this notch the enclosed foramen rotundum (V^2) is seen, and peeping out between the lower edge of the squamosal and the upper edge of the pterygoid (*pg.*) the foramen ovale (V^3).

Between the latter rough, hollow bone, and the last tooth-socket (*mx.*), we see the edge and ascending part of the limited palatine (*pa.*).

The annulus, manubrium, and membrana tympani (*a.ty.*, *m.ml.*) come into view under the postglenoid part of the squamosal, and under its hinder toothed part, the opisthotic region (*op.*) with the confluent epihyal (*e.hy.*), unossified, and under and behind the junction, the facial nerve (VII.). Just the edge of the occipital arch with its condyles (*s.o.*, *e.o.*, *oc.c.*) are seen in this aspect.

The external view of the mandible (fig. 3, *d.*) shows what development has taken place since the first stage (fig. 9, *d.*). I spoke of the first tooth or tusk as *doubtfully canine*; in the upper jaw, in the first stage (Plate 8, fig. 1), it is the first tooth, but in the lower jaw there is one in front of the rudimentary lower tusk—five in all; it is very small, prematurely developed, and early lost (see Plate 9, figs. 3 and 9). Thus the tusk, at most, can only represent the first premolar of the normal Mammalian dentition.

The coronoid process (*cr.p.*) is now separated by a large semicircular notch from the condyle (*cd.p.*), and that by a shallow notch from the angular (*ag.p.*), which is not very deep in this genus.

The fore end of the mandibles is narrow (figs. 3 and 5) and the sutural symphysis of a considerable extent; seen from below, the mandibles are as curiously swollen to form the socket of the tusk, as the face is above; the sockets of the hinder teeth are directed strongly inwards. Here we see how soon the dentition affects the form of the mandible (figs. 3 and 9), and the *loss of teeth* is taking place, here, before one's eyes.

The *end view* of the skull (Plate 10, fig. 4), shows the strength of the wide and high occipital arch. The foramen magnum (*f.m.*, see also fig. 1) is round above, notched below or in front, and it widens out over the condyles.

The supraoccipital (*s.o.*) is roughly semicircular and extends, without an "interparietal" over it, from the well-arched parietals to the foramen magnum. A hook-shaped wedge of cartilage still separates it from the exoccipitals (*e.o.*). The muscular impressions in the main piece are well marked; the outer and lower edge of the bone is flanked by the squamosals (*sq.*), and the lowest corner is pierced by a vessel. The exoccipitals (*e.o.*) are roundish, and in this aspect are separated by a considerable band of cartilage from the opisthotic bone out of which we see the facial nerve (VII.) proceeding, and to which the epihyal (*e.hy.*) has grown. Below, the annuli (*a.ty.*) are seen in the distance. The proper or anterior condyloid foramen (fig. 1, XII.) must be seen from below; here, the posterior condyloid foramen (*p.c.f.*) is seen outside each condyle.

An *inner view* of the ossicula auditûs, removed, and freed from the remains of MECKEL'S cartilage (fig. 6), and an *outer view* (fig. 7) of those parts attached to the capsule, and with the tympanic remnant of the primary bar, show some very instructive things.

The main part of MECKEL'S cartilage has been used up—partly ossified and lost in the ramus, and partly absorbed. The head of the malleus, the osseous matter of which runs forwards as the styliform "processus gracilis" (*p.gr.*), has, in front of it, yet, a large tract of the primary mandible. This thick semiosseous hook (*mk.*) curves itself, after it becomes detached from the rest of the main bar, round the front of the tympanic cavity. The distal third is still unossified; this bony tract is, essentially, a second "articulare internum," such as is seen in the Holostean Ganoids, *Lepidosteus* and *Amia*; (see BRIDGE "On the Skull of *Amia*," Journ. of Anat. and Phys., Vol. 11, Plate 23), and the writer's paper "On the Development of the Skull in *Lepidosteus*," Phil. Trans., 1882.

But this tract has a greater interest for the morphologist even than this, for such a further remnant of the *normal mandible* is often present in adult Marsupials (see DORAN, 'Ossicula Auditûs,' plate 64), and for a time—during the first autumn—the Mole has a similar malleus, as I shall show in my next Part.

More than that—in a similar malleus of a young Koala (*Phascolarctos cinereus*) of the same size, nearly, as this young Unau—I find two smallish, but well-defined membrane bones in this *premalleal* tract; these are seen at once to be the same as the "supra-angulare" and the "angulare" of the Oviparous types. One such bone is seen in this case, the angulare (Plate 9, fig. 7, *ag.*), an oblong splint, pointed at both ends.

When this *temporary* mass is removed (fig. 6) then the processus gracilis (*p.gr.*) is seen to be no larger than the manubrium (*m.ml.*) and parallel with it, but pointed and grooved, above, instead of being terete like that process. There is an evident elbow, or posterior angular process (*p.ag.*), to this masked and arrested proximal end of the mandible. The lamina uniting the manubrium to the head of the bone is thin and

splintery, and hollow on the inside (fig. 6). Over this plate the head of the malleus grows like the hood of the Monkshood flower, a remarkable semioval growth of bone. The sinuous, saddle-shaped condyloid facets of the malleus and incus form, as the figures show, a very strong joint, and the latter bone is equal in size to the head of the former.

Both the crura of the incus are short, but well formed, the short crus (*s.c.i.*) has an oval facet for articulation with the cupped space in the tegmen tympani, and the long crus (*l.c.i.*) has a nearly circular and flat facet for the head of the stapes (*st.*). This latter bone is shown *in situ* from the outside (fig. 7), and, detached and dislocated, from the inside (fig. 6). The little nucleus of cartilage representing the interhyal (*i.hy.*, see fig. 9) is now a small spur on the neck of the short columella; now by absorption of the centre of the flat stem, a veritable stapes. Here again we are on the *Metatherian level*; the Marsupials have a "pharyngohyal" which, in different types, oscillates between the columella and the stapes (see DORAN, 'Ossicula Auditûs,' plate 64). The *secondary* perforation of the "columella," making it into a sort of stapes, is seen also in Birds (see DORAN, plate 64, figs. 44-46). In this figure (fig. 7), little except the cochlear part of the auditory capsule is drawn, with the fenestra ovalis (*fs.o.*) occupied by the stapes, and the fenestra rotunda (*f.r.*). This well ossified mass must be considered as a thick section, cut off from the part that contains the canals, and from the opisthotic angle, behind (figs. 1, 3, 4, *op.*).

I am satisfied that in the Sloths the periotic bony deposit is generalized, as in the Armadillos—and in certain anurous Amphibia.

The epihyal (fig. 3, *e.hy.*) is still cartilaginous, and is followed by a single ossified ceratohyal segment (*c.hy.*), and then by an unusually long hypohyal (*h.hy.*), now largely ossified. The U-shaped basal piece (*b.h.br.*) is also getting a bony centre in each thyrohyal horn (*t.hy.*).

Skull of half-grown Common Three-toed Sloth (Bradypus tridactylus, Linn.).—Fourth Stage.

A *dry skull* of the half-grown young of this species has served to make many things plain to me in this type.

The *side view*, with the olfactory, auditory, and most of the occipital, region removed (Plate 13, fig. 5), shows the roof bones (*n., f., p.*), the nasals, frontals, and parietals, supported behind by the large supraoccipital (*s.o.*), and below by the sphenoids (*V^{1.} to V^{3.}*) and the superficial squamosal (*sq.*). The nasals (*n.*) are short, the frontals (*f.*) have but an indefinite supraorbital rim, and the parietals have a sinuously swelling general surface. The squamosals (*sq.*) are less produced forwards and backwards than in the Unau (Plate 9, fig. 3, *sq.*), but have a more well-marked postglenoid process; the zygomatic process also is longer.

The thick short palatine (*pa.*) and the long swollen pterygoid (*pg.*) are seen *in*

situ; over them, the orbitosphenoid and alisphenoid ($V^1.$ to $V^3.$) are partly seen. Many nerve passages are shown in this part, namely, the optic (II.), which opens into the sphenoidal fissure, through which, besides the orbital nerves, the ophthalmic or 1st branch of the 5th nerve ($V^1.$) passes. This also *enters the skull again* by one of the more marked orbital foramina ($V^1.$), in the anterior angle of the orbital plate of the frontal (*f.*). Behind the palatine (*pa.*), the foramen rotundum ($V^2.$) is seen close to the sphenoidal fissure, and where the alisphenoid, squamosal, and pterygoid meet, the foramen ovale ($V^3.$) is seen.

This latter is really a foramen; in this disarticulated skull, a thin, narrow, post-neural lamina of the alisphenoid lies on the top of the hind part of the pterygoid; the 2nd branch of the 5th nerve burrows the alisphenoid in front of the foramen ovale for the 3rd branch, runs over the top of the pterygoidal sinus or "antrum," and then escapes through its very forwardly placed foramen rotundum. As far as I can see, this is the behaviour of the branches of the 5th nerve in this type; but this is not all. I mentioned that the optic foramen (II.), opened into the sphenoidal fissure; this is clearly shown in the *hinder end view* of this preparation (Plate 13, fig. 7, *o.s.*). In this aspect the orbitosphenoids are seen to be quite ossified, and nearly confluent; but the *post-neural* band of cartilage (Plate 8, fig. 9, *o.s.*), still larger in the much younger embryo of the Unau (Plate 15, fig. 5), has not been ossified, but has been absorbed.

Here, again, we are on the level, so to speak, of the Marsupials; this is a *third Metatherian character*; and it is acquired by osseous degeneration, correlated with degeneration and loss of the dental series.

The alisphenoids (*al.s.*) are seen in this end view, bulging out beyond the orbital plates; the end view of the basisphenoid (*b.s.*), shows a middle part, faced with the cartilage of the spheno-occipital synchondrosis, and, outside this, the rough ends of the ridged sides of the bone, notched for the internal carotid artery (*i.c.*) on their outside.

In the distance, below, the two palatines (*pa.*) are seen to meet at the mid-line; and outside these, nearer the eye, the swollen pterygoids (*pg.*). Outside and above these the squamosals (*sq.*) show their large pneumatic opening.

The under view (fig. 6) shows the lower face of the nasals (*n.*), and the frontals (*f.*) with their approximating orbital plates resting upon the ascending process of each palatine (*pa.*, see also fig. 5). A very small tract of the parietals comes into view here in the postorbital region, but these bones (*p.*) and their "lambdoidal" suture with the huge supraoccipital (*s.o.*) are seen behind. Externally, the squamosals (*sq.*), with their pneumatic foramen, hollow glenoid facet, and short zygomatic process, are seen. In the middle we have, at a distance from the eye, the fused orbitosphenoids forming a presphenoidal *region* (*p.s.*) by their confluence.

This part is underfloored and flanked by the ascending parts of the palatines (*pa.*), in front, and by the like parts of the pterygoids (*pg.*), behind. The proximal region of each alisphenoid ($V^1.$ – $V^3.$), is hidden in this view by the pterygoid, but the base (*b.s.*)

can be seen with its thickened sides, growing backwards as rudimentary "tympanic wings," and wedging forwards under the uniting orbitosphenoids. The distal part of the alisphenoids comes into view outside the pterygoids, and the foramen ovale, foramen rotundum, and common passage for the orbital and optic nerves (V^3 , V^2 , V^1 , II.) can all be distinguished in this aspect of the skull.

Here the large unique pneumatic pterygoids show their communicating passage with the great naso-palatine canal, and therefore, also, with the whole system of air-galleries in the nasal labyrinth.

I have mentioned the parallelism of the Unau and the Mole in the peculiar temporary pretympanic process of the malleus; here in the Ai (Plate 13, figs. 8, 9), the outer and inner aspects of the tympanic annulus are almost precisely like those of the Hedgehog, and of the young Mole; they have a considerable concavity, a large amount of ossified floor, and strong, incurved cornua, the front horn being deeply and obliquely notched for the processus gracilis.

MYRMECOPHAGIDÆ.

Young of Cycloturus didactylus; one with head $1\frac{1}{4}$ inch long, and another $4\frac{1}{2}$ inches long from snout to root of tail, and head $1\frac{1}{2}$ inch long.

I shall treat these as one stage; they correspond well with the larger specimens of the Armadillos, and with the third stage of the Sloth. This small arboreal Anteater comes in well after the Sloths; the difficulty of comparison of these two Families is lessened considerably in this case.

Once well understood, the same stage in each type—Sloth and Anteater—can be put side by side, and then the special adaptive modifications may be accounted for and the true radical kinship of these two, apparently so diverse, forms, can be demonstrated. I have found that by putting them alongside of each other, and carefully removing their special "marks," the evidence for a common descent is very great. We have a similar comparison to make between the toothed and toothless Anteaters of the Old World—*Orycteropus* and *Manis*—and also, indeed, between the *Ornithorhynchus* with its horny "sucedanea" for teeth, and the absolutely edentulous *Echidna*. Nowhere can the modifications produced by the gradual abortion, and the complete suppression, of teeth in the higher Vertebrata be better seen than in the Edentata or Bruta. In the Chelonia the massive horn-covered jaws are less modified than might have been expected; the strong shears that serve as a makeshift for teeth, ask for as strong a setting as the normal teeth of a Reptile.

So also in Birds, to a greater or less degree, as may be seen by comparing the skulls of the toothed Birds (so ably described and exquisitely figured by Dr. MARSH) with those of the existing toothless types.

But, in the Mammalia, we are so familiar with the huge dental apparatus seen in this or that high Eutherian—jaws answering to teeth, and teeth to jaws—that any

perfectly toothless type of Mammal seems to be a monster; and to be *sans* teeth is to be *sans* everything.

In the Snapping Turtle or the Macaw the massiveness of the face makes no difference in the morphology of the type; here also, in this little toothless arboreal Anteater, the bird-likeness of the face is a very thin mask to its true nature as a low Eutherian Mammal; the whole result is but a faint and feeble imitation of the face of the feathered and winged *Edentate*.

Yet the result of this slow secular "drawing" of the teeth is very curious and instructive (see Plate 10), and the result in this *quasi-senile* creature is to form a skull like a small *gourd* or a *flask*. But this lageniform skull is flat on one side, and bent downwards towards that flattened side. That is the *under* surface (Plate 10, fig. 1); here we see a small, short snout, with lateral nostrils (*al.n.*, *e.n.*), quite like that of the Sloths, but more slender.

The basal part of the premaxillaries (*px.*) is a small subtriangular tract; the right and left bones are separated by the width of the base of the nasal septum (fig. 7, *s.n.*). Where they diverge, behind, there the maxillaries (*mx.*) begin to converge; in the fore part of their palatine plate there is then left a lozenge-shaped interspace, and here we see the two front paired vomers, small pyriform ossicles (fig. 10, *v'*.), lying parallel with their pointed end forwards. The hard palate is very much sculptured and perforated, two-thirds of it belongs to the maxillaries, and one-third to the palatines (*pa.*) This under region widens a little backwards, and narrows again towards the end of the perfect floor. That perfect part runs to the middle of the skull, the rest is indeed well marked off and hedged in with solid bone, but the floor is merely a strong "aponeurosis," and not a bony tract right across, as in the large *Myrmecophagidæ*; the naso-palatine canal, however, is quite perfect in this little kind, and opens close under the junction of the head and neck.

The sharp-edged, toothless alveolar region of the maxillary (*mx.*) sends inwards the usual flange, and this only leaves a small tract for the higher submesial part; the two tracts are separated by a deepish groove. About three-fifths of the underview of the maxillaries is palatine, the rest belongs to the facial walls, which spread out on each side of the *inferior* infraorbital foramina (*V²*.) into an ear-shaped lobe, and then the bone contracts suddenly, and runs inwards to bind on to the middle of the side of the rest of the hard palate. This part answers to the socket of the upper "wisdom tooth" in man.

Fine threads of bone are seen extending backwards into the jugal region from the outer lobe of the maxillaries; these are the starved, abortive jugals (*j.*).

The orbits are less enclosed than ever in this type; in this aspect the inturned orbital plate of the frontals (*f.*), and the antero-inferior cornu of the parietals (*p.*) can be seen, folded over the two pairs of wings of the "sphenoid bone." The palatine hinder third of the hard palate is quite like the part in front of it, and at the line of junction of the two palatines, behind, this floor is emarginate, angularly.

This takes up three-fifths of the large palatines, the remaining part merely helps to wall in the great naso-palatine canal. Each bone diverges backwards and leaves an interspace wider than each bar, at the top of which, on the inner side of each, the palatine bone is seen to clamp the basis cranii by a dilated plate.

Then the pterygoids (*pg.*) begin; they run forward, a little, inside the palatines, and these, in turn, run backwards outside them, fastening together, obliquely.

Each bone has, away from the eye in this view, an upper plate embracing the skull, a flange, as in the palatines—which runs on to the last fourth of the basioccipital (*b.o.*). Up to the spheno-occipital synchondrosis (*b.s.*, *b.o.*), the two pterygoids form the margin to a lanceolate space, the sides diverging and then converging; but in their last third the pterygoids diverge again, and then their upper plate is well seen. At their middle these bones spread out, doubling their breadth and becoming rugged and notched; they thus form an angle which wedges strongly in between the innermost part of the squamosal and the foremost part of the annulus tympanicus (*sq.*, *a.ty.*). In the angle, here, the foramen ovale (figs. 1 and 9, V³.) is seen. At their rounded ends, which are cut away somewhat, externally, the pterygoids are capped with cartilage, as in the embryos of most of the lower Eutheria, which have this sign or remembrance of the great pterygo-quadrate bar, or endoskeletal upper jaw of the Ichthyopsida.

The double sphenoidal region is largely displayed in this view; outside the unfloored part of the palatines, the orbitosphenoids and optic nerves (*o.s.*, II.) are seen, and behind these a large, lozenge-shaped tract of each alisphenoid (*al.s.*), behind the sphenoidal fissure, through which both the 1st and 2nd branches of the 5th nerve (V^{1,2}.) pass. Opposite the junction of the pterygoids and palatines there is a semi-oval tract of cartilage, separating the presphenoidal region from the basisphenoidal bone (*p.s.*, *b.s.*), for here the orbitosphenoids (*o.s.*) meet and coalesce, and the cartilage has, necessarily, a convex form at their junction. In front, where it runs on over the hard palate, it becomes the unossified perpendicular ethmoid (fig. 7, *p.e.*). The large, and unusually long basisphenoid (*b.s.*) has a small *pituitary hole* at its front third, and is longer, contrary to rule, than the basioccipital, that is, measured along the mid-line.*

This is correlated with the great length of the pterygoid bones (*pg.*), which are one-third the length of the bony cranio-facial base, and even in the Unau (Plate 9, fig. 1) are only one-fourth, with its relatively much shorter skull. The external descending ridges of the basisphenoid (*b.s.*), like those in the Unau (Plate 9, fig. 1), are hidden by the junction with those of the backwardly extended pterygoids. Only the pre-pituitary part of the basis cranii is convex along the middle, in the notochordal region;

* In the Unau at the same stage (Plate 9, fig. 1) the basisphenoid is one-third shorter than the basioccipital; here the bony basal tracts, measured along the middle in my younger specimen, are as follows:—presphenoidal region 2 millims.; basisphenoidal 4.5 millims.; basioccipital 4 millims

behind the middle of the basisphenoid, it is gently concave, as the roof of the hind part of the very long naso-palatine canal.

The rest of the basal region, formed by the basioccipital (*b.o.*) is very large, and between pentagonal and orbicular in shape; and like that of the Unau (Plate 9, fig. 1) has a very *Sauropsidan* form and size, but still more so than in the Sloth. As in that type, the bone has strong "basipterygoid processes" (figs. 4 and 9, *b.pg.*), which functionally correspond to the parts so named in the Sauropsida, but are, here, the outgrowths of a hinder bone. Here they reach within a short distance of the rim of the foramen magnum (figs. 1, 4), and are, indeed, as strong and well-developed as any of their *analogues* in Reptiles or Birds.*

In the sides of the hind skull, as seen in this under aspect, the parietals (*p.*) come into view, outside the squamosals (*sq.*), a rare character, and one that can only occur in such a curious gourd-shaped skull as this, or in the similar skull of the Pangolin—next to be described. Inside them, the abnormally small squamosals (figs. 1 and 9) make a better figure in this under face of the skull than they do as seen from the outside (fig. 3). The zygomatic process is very stunted, and behind it we see the small pyriform gently concave glenoid facet (*gl.f.*), with its narrow end forwards and a little turned outwards.

The postglenoidal part of the bone curls inwards, but is notched in the middle, just in front of the tegmen tympani and ossicula auditûs, and where the hollow bone has its pneumatic passage opening into the cavum tympani. A large sinuous under and inner flange runs from the convex outer part of the squamosal, and strongly undergirds the alisphenoid; it almost reaches the basicranial plate of the pterygoid (*pg.*), and is, in turn, itself undergirt by the fore horn of the large bony annulus (*a.ty.*), and also by the large spatulate processus gracilis of the malleus (fig. 9, *p.gr.*).

A small vascular foramen is seen at the posterior angle of the squamosal (see also fig. 3, *sq.*).

The tympanic annuli (*a.ty.*) are quite comparable to those of the embryo of the Ai (Plate 8, fig. 5), as to their large, relative, size. The side view (fig. 3) shows them, but not so well as this; their aperture is wide, and obliquely turned outwards and forwards, and is occupied by the manubrium and ear-drum skin (*m.ml.*, *m.ty.*). The part round the rim of the opening is smooth, convex, and is taking on the well-marked *bulliform* character seen in the adult. All round the horns and convexity, externally, they are notched, or toothed, in a remarkable manner. Behind these bones, the ossified auditory capsule (*op.*) comes into view, with the opening for the 9th and 10th nerves (IX., X.). This skull is somewhat more advanced as to its

* The *quasi-embryonic* arrest of the hinder hard palate in this kind is very instructive; a little more energy of growth would have given this dwarfed, arrested, Anteater, with its long pretensile tail for the service of its timid, arboreal life, a palate equal to that of its larger congeners (compare fig. 1 with Professor FLOWER's figure of the basal view of the skull in the Ant-bear; 'Osteol. of Mammalia,' fig. 65, p. 206).

lower arches than that of the young Unau (Plate 9), for the fixed part of the hyoid arch (epihyal, *e.hy.*) has formed a "tympanohyal" ossification (fig. 9, between *f.r.* and IX., X.) in front of the stylomastoid foramen (VII.), separate from the opisthotic (*op.*); the rest of the arch (fig. 6) has become free.

The occipital arch, the base of which has already been described, is here seen, showing a *semi-inferior*, almost circular foramen magnum (*f.m.*), convex sub-reniform condyles (*oc.c.*), exoccipitals with a low par-occipital ridge, and the lower edge of the large supraoccipital (*s.o.*). All the bones, here, are separated by a moderate tract of cartilage; in front of that which runs sinuously inwards and forwards, between the basal and side pieces, we see the hole for the hypoglossal nerve (fig. 9, XII.) lying in a notch of the exoccipital (*e.o.*).

The *upper view* (Plate 10, fig. 2) shows the form of the skull best, in its resemblance to a small gourd, the nasal labyrinth merely forming the neck to the bulbous cranium.

Here an unossified endoskeletal tract of the snout (*al.n.*) finishes the upper end, and an ossified tract, the wide superoccipital (*s.o.*), finishes the lower; all the rest, as seen in this view, is composed of paired investing bones.

The emarginate space in front of the nasals shows a considerable amount of the double narial tube, ending near the fore end in the lateral nostrils (*e.n.*).

The nasals (*n.*, line too short), notched in front, widen, wing-like, at their frontal end, and are somewhat pinched at their sides. Just the top of the feeble facial plate of the premaxillaries (*px.*) can be seen here, followed by the ascending part of the maxillaries (*mx.*), into which is set the small perforated lacrymal (*l.*, *l.c.*), and from which grow the feeble threads that remain of the jugals (*j.*).

The frontals (*f.*) are notched at their fore angle by the lacrymal wedge; they then expand a little, and contract again, to finish the "neck" of the "gourd."

From this neck, or waist, at the front third of the badly enclosed orbits, the whole cranium swells into its bulb, with but little injury to its neatly oval form, until we come to the gentle median projection of the supraoccipital.

There is but little difference in the length of the frontal and sagittal sutures (see also fig. 3, *f.*, *p.*); but these bones are not finished where they should pass into each other; there the sutural teeth are large enough for a very much larger type, just as we find in the Caducibranchiate Salamandrians (see. Trans. Linn. Soc., ser. 2, vol. 2, plate 18, *Cynops*; plate 21, *Spelerpes* and *Desmognathus*). Here, in this dwarfed arboreal type, the fontanelle (*fö.*) is bilobate, and fills in slowly, reminding the observer of the numerous dwarfed arboreal kinds of Anura (Tree-frogs) that abound in the same primæval forests, the companions of this very type.

But the *side view* (fig. 3) shows some of the most remarkable things in this arrested type of skull; this may be compared with the similar figure given of the embryo Unau (Plate 8, fig. 3); such a comparison will show a likeness between the two that is very remarkable.

One thing may be stated here, namely, that the length of the basifacial axis, from

the front of the presphenoidal region to the end of the snout, and of the basicranial, from the former point to the foramen magnum, are nearly equal; so they are in the embryo, and in the new-born, Unau.

But in the great Ant-bear the front measurement is about three times the length of the hinder; hence I call this little skull *quasi-embryonic*—the *Myrmecophagine* specialization of the face is arrested, and it is, very probably, the descendant of a much larger type, with a much longer face.

The fore part of the face is bent downwards in a manner that is abnormal for this advanced stage, although it would be quite normal for an early embryo. The snout (*al.n.*) is compressed and the nostrils (*e.n.*) lateral; the premaxillaries (*px.*) are very small angulated bones just touching the nasals above, and followed by the maxillaries, which for them, have a starved appearance; they are wrinkled, and hollow externally, without much convexity in the alveolar region. The infraorbital foramen is oval, and the bone over this passage swells somewhat, but has a notched upper margin where the lacrymal (*l.*) rests upon it. The maxillary is notched again, twice, in its sub-orbital region, and then ends in an ear-shaped jugal process, with fine threads of bone—remnants of the jugal (*j.*)—attached to it.

The lacrymal (*l.*) is a thin shell of bone, perforated for the duct (*l.c.*), and hollow towards the eye-ball; it has both a facial and an antorbital region. The frontals are almost *Ophidian*; together they nearly form a cincture by the large development of their orbital plates, which leave no space for any “pars plana” of the ethmoid, or allow more than a small patch of the low orbitosphenoids (*o.s.*, see fig. 7) to be seen in the base of the orbital region.

These orbital plates come down to rest upon the palatines (figs. 1 and 3, *pa.*), and form a moderately concave wall to the very indefinite orbit. The supraorbital region is marked by a convexity having the shape of an hour-glass, the “waist” of which is part of the general constriction of the skull round the enclosed ethmoids.

The greatest concavity of the deep orbital plate is just below the second supra-orbital swelling; it is then a little convex, and then hollows out backwards and downwards, the hollow ending in the principal orbital foramen, for the ophthalmic (orbitonasal) nerve (*V¹*). There the orbitosphenoid (*o.s.*) is exposed, and in it the optic passage (*II.*) is seen.

Behind the sinuous imperfect coronal suture the parietal (*p.*) stretches backwards to the occipital arch, and, below, comes down towards the floor of the skull nearly as well as in the Snake.

Thus the temporal fossa is merely a part of the general face of the skull, infero-laterally, the parietal being scarcely at all hollowed to form it; here, at the lowest front angle, the parietal sends forwards a large round lobe that binds down upon both the wings of the sphenoid just over the sphenoidal fissure (*V¹, ²*).

Looking towards the mid-line, below, we see the undergirders of the skull—the palatines and pterygoids (*pa.*, *pg.*); they show, from this aspect, their ribbed edge, and

the manner in which the infero-lateral parts of the endocranium are built upon them. Over their junction, and over the exposed part of the pterygoid, the alisphenoid is seen, partially, with its foramen ovale (V^3 .) in its middle, far forwards from the primary normal place for the escape of the hinder division of the trigeminal nerve.*

The squamosal (fig. 3, *sq.*) is a very narrow, low-lying scale, a lateral or temporal scute, differing but little from that of the Frog, but specialized in another manner. In that Amphibian the outer or obliquely descending process binds upon a massive quadrate region, the hind part of the endoskeletal upper jaw. In this case, that of the Mammal, the outer process binds over the much arrested quadrate (=incus) at its proximal part, but the free end acquires a cartilaginous facet for articulation with the detached fore part of a *compound mandible*. The upper edge of the squamosal is gently convex, there is a small notch near the end, and the bone then forms a small angular process which fits in between the parietal and opisthotic (*op.*).

Below that junction, in front of its squared end, the bone is perforated for a vessel; it is then lobate, then notched over the front crus of the tympanic (*a.ty.*), and, in front, on the inside of the short jugal process and glenoid hollow, it ends as a rounded angle behind the descending lobe of the parietal (see also figs. 1 and 9). The obliquity of the annulus (*a.ty.*) is well seen here, and the large size of the drum-membrane and the manubrium (*m.ty.*, *m.ml.*). A convex, roughly pentagonal mastoid region (*op.*) is displayed in this side view, and over it the edge of the huge supraoccipital (*s.o.*), dovetailed by the lateral occipital (*o.*), behind which the condyle (*oc.c.*) is hardly visible. The projection of the crown of the occipital arch is well shown in this view; the general relation and direction of these parts is very similar to what is seen in the early embryo of the Unau (Plate 8, fig. 3), whose squamosal (*sq.*) is probably very much like that of the little Anteater at the same stage. In the latter the parietal overgrows the squamosal; in the Unau (Plate 8, fig. 3; Plate 10, fig. 3) it is the squamosal that becomes so greatly developed, becoming *half* the size of the parietal, whereas in this case it is about *one-tenth* the size.†

In the Unau, whilst the teeth are thin caps of dentine on small rudimentary pulps (Plate 8, fig. 3), the mandibular ramus is not more unlike that of this edentulous type (Plate 10, figs. 3, 3A) than it is to that which it will become in the ripe embryo (Plate 9, fig. 3). The edge of the ramus is curiously denticulated where the outer and inner laminae should form the alveolar walls. This is very similar to what is seen in

* The position of the foramen ovale in the Mammalia is correlated with many remarkable specializations that are diagnostic of the skull in this class; one of these is the extreme obliquity, or tilting, of the auditory capsules, and another is the out-thrust of the alisphenoids, themselves, which now in the Mammal, for the first time, are pushed clean outwards from the general endoskeletal wall.

† I am satisfied that if a perfect series of embryonic Unaus and Anteaters—small or large—could be obtained, we should find that these two extremely specialized forms of low Eutheria would be found to approximate more and more when thus studied *downwards* and *backwards*; thus they would be seen to repeat, in their prenatal state, their secular birth and growth.

other edentulous types, as for instance in a remarkable Neotropical Passerine Bird--*Phytotoma rara* (Trans. Zool. Soc., vol. 10, plate 46, figs. 8-10); and in a gigantic Toad (*Bufo agua*, Phil. Trans., 1881, Plate 36, fig. 2) from the same region, whose palatines (normally edentulous in existing Anura) show signs of an old tooth-surface in the form of sharp osseous denticulations.*

In this slender mandible, decurved like the snout end of the upper jaw, the coronoid process (*cr.p.*) is a good wide hook, separated from the round condyloid process (*cd.p.*), with its clearly marked neck, by a large semicircular notch; a shallow notch separates the latter from the less marked angular process (*ag.p.*), which is slightly incurved. The inner face of the ramus (fig. 3A) shows tracts or regions of bone that correspond most accurately with the coronoid and splenial bones of the Oviparous Vertebrata; the rapid ossification of the ramus from the main bone, or dentary, does not allow of distinct centres for these parts; at least, as far as I have seen, they are only partially distinct.

The *end view* of this skull (fig. 4) is as important as the other aspects, which have to be corrected, visually, by this. The fundus of this flask-shaped skull is subcircular and gently convex; the perfect semicircle, above, is finished in its outline by the deep parietals (*p.*); the rest of the outline is made more irregular than it would be by the appearance, in the distance, of the hinder swellings of the tympanics (*a.ty.*). The supraoccipital (*s.o.*) is reniform, with a concentric muscular ridge, but the lower edge, besides its "hilus" over the large, nearly circular foramen magnum (*f.m.*), is notched, right and left, by the squared upper end of the exoccipitals (*e.o.*); the upper and outer junction of these bones is sinuous, the outer and lower margin fitting against the opisthotic (*op.*) is rounded. A notch separates the outer lobe, with its thick paroccipital edge, from the reniform condyle, and between the right and left condyles the basioccipital comes into view. Here we see the extraordinary development of the "basipterygoids" of the basioccipital (*b.pg.*) like those of the Unau (Plate 9, fig. 1), but larger, and carrying the ends of each pterygoid bone (*pg.*). The lower face of each pterygoid is flat, but oblique, the outside being the deeper part; the interspace between the two bones is not greater than the width of each; this is floored by a strong membrane, and thus the circular hind part of the naso-palatine canal (*n.p.c.*) is completed, a little in front of the foramen magnum. A membranous interspace is seen between each tympanic and the opisthotic (*a.ty.*, IX., X.); outside the broad outer opisthotic part we see the hind margin of the narrow squamosal (*sq.*), and over the tympanic the epihyal (*e.hy.*), and right and left in this region the nerve passages for the facial, glossopharyngeal, vagus, and hypoglossal (VII., IX., X., XII.).

The external views (figs. 1-3) were taken from the smaller *dry* skull, with the help of the larger *spirit-specimen*; the *sectional views* (figs. 7 and 8), the hyoid (fig. 6), and

* The embryology of the Myrmecophagidæ and of the Manidæ would possibly show us rudimentary teeth in both families.

the vomerine bones and cartilages (fig. 10) are from dissections of the latter, more developed, young; this will account for some differences of form in the parts.

The complete *longitudinally vertical section*, made a little to the left of the mid-line, shows almost perfect ossification of the endoskeletal part of the skull, proper, with no appearance of bone in the internasal region. That region is very short in proportion to the long cranial cavity, which, itself, is remarkable for the large development of the supraoccipital (*s.o.*) and for the peculiarly low position of the whole of the double sphenoid, reminding the observer of the skull of Serpents. The delicate decurved snout has the familiar fenestra (*i.n.f.*) in the fore part of the septum nasi (*s.n.*) between the external nostrils. The JACOBSON'S, or recurrent, cartilage (*rc.c.*)* is cut across on the left, but that of the right side is seen under the septum nasi (see also fig. 10). The whole septum (*p.e., s.n.*) is rather high in proportion to its length; its thick intertrabecular base has an arched or concave outline, but the top of the crest or partition is convex for some distance, and then drops rather suddenly towards the snout. The descending margin of the middle ethmoid (*p.e.*) is somewhat crested (the *crista galli*) and grooved by the olfactory filaments; the cribriform plate (below *cr.p.*) cannot be seen in this view; the partition hides it. Here the presphenoidal bony tract (*p.s.*) is now almost complete through the fusion of the orbitosphenoids, which have long ago lost their large upper cartilaginous tract joining on to the supratemporal crest, and the supraoccipital.

The upper part of the orbitosphenoid only can be seen, and half the optic foramen (II.); that wing has its margin first descending and then rising into a short lobe in front of the sphenoidal fissure ($V^1, 2$). The alisphenoidal (*al., read al.s.*) lies still further out of sight, being thrust outwards as well as downwards (see fig. 1); its upper edge is notched gently, here, and the foramen ovale (V^3) is below the angular process that divides the notches (see also fig. 9).

The cartilage between the pre- and basisphenoids (*p.s., b.s.*) is longer than that between the basisphenoid and basioccipital (*b.o.*); and the latter tract is high, being part of the postclinoid wall. This is thick now, being composed of part of two bones and the intervening cartilage, but in the adult the "sella" becomes more scooped, and the postclinoid wall is thin and curls forwards. The shorter presphenoidal tract of bone is twice as thick as the basal pieces behind; the basisphenoid is the longest of the three. The internal carotid artery (*i.c.*) enters the skull nearer to the mid-line than in Eutheria, generally, but its entrance is normal; its internal continuation, forwards, is large, and lies in a very definite groove over the junction of the base and ala.

The exoccipitals (*e.o.*) have a considerable parting of cartilage, yet, between them and the basal plate (*b.o.*); the latter is notched in a crescentic manner, twice, first for the cochlea, and then for the exoccipital. A definite tract of cartilage still separates

* The line from *rc.c.* is wrongly directed to the premaxillary; the anterior vomer (see fig. 10, *v'*.) is not lettered.

the latter bone from the great keystone piece (*s.o.*), which is notched in a triangular manner for the upper angle of the exoccipital.

The rounded, projecting, rather obtuse angle of the great supraoccipital is not in the middle, but below it, for the bony section along the top is one-fourth longer than that which leans over towards the spine, behind. Here, as in the Monotremes, the hind brain lies in a great hollow recess, formed by the ossified chondrocranium, and does not simply lean against a moderately concave wall. If the fore angle of the supraoccipital had been sharply pointed, and the frontals more developed backwards, we might have had what is seen in the highest physoclystic Teleostei, namely, lateral parietals, and the supraoccipital meeting the frontals. Here, the cut edge of the occipital "tegmen" is longer than the inner edge of the parietal, where it meets its fellow to form the sagittal suture.

The tilting of the auditory capsules has been so great that their hind border lies almost flat upon the exoccipitals and basioccipital. The capsule is rather small, well ossified, and from the smallness of the space, and its immaturity, the form or the exquisite labyrinth within has been retained in the bony capsule. The anterior canal, with its ampulla (*a.s.c.*), is seen arching over a very definite recess for the flocculus; and also its junction with the posterior canal (*p.s.c.*). Over both these canals the bony capsule becomes angular, to fit into the interspace of the neighbouring bones. Across, below the swelling of the vestibule, where the ampullæ open, the archway of the meatus internus shows the normal passages (VII., VIII.) and, antero-inferiorly, below these, the coils of the cochlea.

A part of the exposed lower surface (fig. 9, *chl.*) shows a very tumid proximal coil, with no definite mark of the further turns of the helix. This figure clearly shows how the squamosal, where it opens into the air cavity of the drum, helps the "tegmen," forming an eave over it, and that under this eave the top of the 1st and 2nd visceral arches are sheltered. The *secondary* fenestra ovalis, and the *primary* fenestra rotunda (inside *st.*, and *f.r.*)* are here shown, the former closed by the proximal part of the hyoid arch, or stapes (*st.*). The sub-proximal part of that arch, the epihyal (*e.hy.*), is confluent with the opisthotic region (*op.*), and has formed the bony "tympanohyal" of FLOWER—the proximal endoskeletal part of the so-called "stylohyal."

The remainder of the hyoid arch is shown separately (fig. 6); the ceratohyal (*c.hy.*), as in the Sloth, is undivided, and is followed by a longish hypohyal (*h.hy.*); this is pointed at its distal end, and joined, lightly, to the basal piece; it is slightly ossified. The ceratohyal is largely ossified; flattened above, and united, there, by fibrous tissue to the epihyal; below it is thick, and presents a flat face to the flat face of the hypohyal, where there is a joint cavity.

The basihyobranchial (*b.h.br.*) is U-shaped; the median part is a thick wedge of cartilage; the diverging horns are solid, round, bony rods, tipped with cartilage—the thyrohyals (*t.hy.*).

* According to the excellent researches of Professor ALEXANDER FRASER.

The structures seen under the tegmen (fig. 9) are the incus, malleus, and stapes (see also fig. 5), where they are shown as detached, and from the outside, the stapes dislocated from the incus. The malleus has a large manubrium (*m.ml.*), with a strong elbow (posterior angular process, *p.ag.*), turned towards the membrana tympani. The whole of the process is set on to the head of the malleus at more than a right angle; but, from the round bulbous fore part of the head, the processus gracilis (*p.gr.*) is continued straight forwards; that part is a long spatula, dilating forwards as it runs towards the Glaserian fissure. It has been much larger, I have no doubt (see in the Unau, Plate 9); afterwards it is absorbed up to its root (see DORAN, plate 64, fig. 13).

The mutual sinuities of the two bones at their junction give the hinge of the malleus with the incus an angular appearance (fig. 5, *i.*, *ml.*); a good face of cartilage remains at this part. The top of the short process and the disk of the long process of the incus (*s.c.i.*, *l.c.i.*), are still unossified; the long process is well elbowed before it turns inwards, near its dilated end; this part is quite normally Mammalian.

But the stapes (*st.*) is not normal; the hole is absent; this element is a short flat "columella," with apex and base still unossified; afterwards (DORAN, *op.*, *cit.*) a feeble vertical fossa forms along the shaft where a groove is shown. Now and then this bone becomes almost a "stapes." Here we are on the level, or height, so to speak, of the Metatheria. There is a small interhyal (*i.hy.*) on the neck of the stapes.

Returning to the large vertical section (fig. 7) and its partial counterpart (fig. 8) we see that the nasal labyrinth is quite normal and not badly developed; the nasal, inferior, middle, and upper turbinals (fig. 8, *n.tb.*, *i.tb.*, *m.tb.*, *u.tb.*) are all well formed, although the complication of the last two regions—parts of the true olfactory region—is not great; these coils of cartilage are quite unossified, so that my largest specimen must have been very young.

In the main section (fig. 7) the roof bones (*n.*, *f.*, *p.*) are shown to be rather solid; the nasals overlap the frontals, which cover the olfactory region by their fore part (see also fig. 2). But the orbital region of the frontal, and the temporal region of the parietal bones are developed downwards in an almost Ophidian manner, so that a little further ingrowth of the former would have given us a perfect frontal cincture—a state of things not absent from some of the high Eutheria. The parietal comes down and lies on the low alisphenoid (*al.s.*) by a broad emarginate process, behind which a small oval intercranial tract of the squamosal (*sq.*) is seen; as small as in the average Bird. The right jointed palatine beam is seen reaching from the back of the snout to the front of the foramen magnum, the series forming this many-pieced "balk" of bones is as follows: the premaxillary, maxillary, palatine, and pterygoid (*px.*, *mx.*, *pa.*, *pa. read pg.*); these form the floor of a continuous canal, which opens freely into that of the other side, all along.

There is a small bone, the front paired vomer (figs. 7 and 10, *v'*.), right and left over the fore part of the double channel—the naso-palatine canal, and behind it a grooved bone, the vomer (*v.*), as long as the palatine plate of the maxillary; right

and left of the hind part of the vomer there is a bony plate; these are hind paired vomers (fig. 10, *v.*"); they serve to unite the vomer, proper, with the ossifying ethmoidal masses, afterwards; the principal or proper vomer is not carinate below either in this type, in the Armadillo, or in the Sloth (see Plate 2, fig. 1; Plate 3, fig. 9; Plate 5, fig. 6; Plate 6, fig. 9; Plate 8, fig. 8.).

When it is carinate below, the vomer, resting upon the hard palate, keeps up the subdivision of the nasal passages, so far back; whereas in these Neotropical Edentates these passages open into each other close behind the snout. Now this state of things is not seen in the Palæotropical kinds, as I shall soon show, and as these latter agree in this respect with the Insectivora, and also, as in one of their Old World forms, the Aard-Vark, we have the exceptional "interparietal"—so large and universal in the Insectivora—it seems reasonable to suppose that we have in the Old and New World Edentata two "suckers" from some old "root-stock," that separated from each other long since, diverging and breaking up, each into its own special subdivision, of which sub-division we have only two genera, representing two, families in the Old World, and many genera and several families—especially if we take in the extinct kinds—in the New World.*

MANIDÆ.

My materials for working out the skull in this family were as follows:—

First Stage. Embryo of *Manis*,—? sp.; $2\frac{1}{3}$ inches long, snout to root of tail; tail itself $\frac{2}{3}$ inch long (Plate 1, figs. 3, 4).†

Second Stage. Embryo of *Manis brevicaudata* (from Ceylon; procured for me by Mr. WARD); $4\frac{2}{3}$ inches long, snout to root of tail; head $1\frac{2}{3}$ inch long; tail $2\frac{1}{5}$ inches (Plate 1, figs. 5, 6).

Third Stage. New-born young of *Manis Temminckii*; head $2\frac{1}{4}$ inches long.

Fourth Stage. Adult Pangolin's skull, *Manis*,—? sp.

First Stage.—Embryo of *Manis*,—? sp.; $2\frac{1}{3}$ inches long (Plate 1, figs. 3, 4).

The skull of this very immature embryo (Plate 11, figs. 1–6) differs very greatly from anything I have as yet seen in the Mammalia; it has its endocranial parts as abortive as its ectocranial.

* In the present state of my slow work I scarcely can hint at the relation of these Old and New World Edentata to the groups below and around them; I feel sure, however, that the Aard-Vark is the nearest to the Insectivora, of any in the Order; and that the New World kinds, generally, and the Old World Pangolins, also, are nearer to the Monotremes than to the Marsupials.

† The youngest Tatou (*Tatusia hybrida*) was only $1\frac{1}{2}$ inch long from snout to root of tail (Plate 1, figs. 7, 8), but its development was twice as much advanced as this; the Pangolins, like the Aard-Vark, are very large at the time of birth. This embryo of the Pangolin, for which I am indebted to Dr. GÜNTHER, is therefore my proper starting-point in the study of the skull in the *Edentata*. In the Insectivora, Marsupialia, &c., I shall describe much earlier stages than this. But if time and materials serve, I hope, some day, to add an appendix to the present paper, giving earlier stages.

I have been able to compare it with the early skull—twice as advanced, and yet with a very perfect chondrocranium—in the Armadillo and the Unau, amongst the *Edentata*.

But in types that have yet to be described, especially the Marsupials and Insectivores, I find early crania differing in various ways, but quite normal, and with a well-developed chondrocranium.

In the Monotremes I have the most important, because most *radical*, types for comparison; but in both genera—*Ornithorhynchus* and *Echidna*—in young two or three times as advanced as this embryo, the chondrocranium is most massive and well developed—almost *Dipnoan*.

Both in the early skull of the Marsupialia and of the Insectivora I shall be able to show how gentle the modification is of a Mammalian skull at this stage, from that of the embryo Crocodile. Even if that good, practically fundamental type of skull of a well-developed *Amniote* (see Trans. Zool. Soc., vol. xi., plate 65), be compared with those of the Tatou and Unau just described (Plates 2 and 8), it will be evident that we have in the chondrocranium of that Reptile everything we want, in a generalized form, out of which to frame (mentally) the much more specialized skull of a normal Mammal.

But there are other Sauropsida whose skulls have undergone, in various ways, the uttermost degree of specialization—I refer to the Ophidia and Carinate Birds.

In explaining this early skull of the Pangolin and also its latter stages—even that of the adult—I shall have to show a parallelism in several things between the skull of this low Eutherian, and of those two extreme forms of the Oviparous Amniotes—the Snake and the Flying Bird.

The earliest skull, worked out by me, of the Ostrich (Phil. Trans., 1866, Plate 7), being at the same stage, is very profitable for comparison; yet, when all is done, and the likeness of this skull to any or all of these Sauropsidan types has been shown, there will still remain all that is strictly and absolutely Mammalian, the result of a transformation of various parts that suggests a *true historic metamorphosis* which once lifted up the Mammal, when just emerging from its low *larval* form, far above the platform of the other Amniota—the Sauropsida,—whether scaly or feathered.

The *lower view* of the skull (Plate 11, fig. 1) shows that the nostrils (*e.n.*) are large, and obliquely inferior in position; they are roofed over by dilated alinasals (*al.n.*), which have a wide base (*n.f.*).

All the beginnings of the ectoskeletal tracts are fine bony films, and are very far from investing the parts they are intended to cover.

The premaxillaries (*px.*) are small, V-shaped bones, with their rounded angle foremost; their proper dentary tract is no larger than their palatine process, which is short at present; afterwards (fig. 8) it is long, having received the addition of the small corresponding anterior paired vomer (fig. 1, *v'*).

Each maxillary (*mx.*), as seen from below, is a leafy lanceolate bone, with a notched hinder end and an inferior ridge. This ridge is the closed alveolar region; it

is arched outwards, and runs from end to end of the bone, its hind part being continued into the inner fork of the bone. From this ridge a scooped plate runs inwards as a palatine flange to the main bone; its outline, on the inside, is symmetrical with that of the alveolar ridge. The right and left lanceolate palatine plates are separated by a space nearly their own individual width; the first third of this space is taken up by the palatine processes of the premaxillaries and the front paired vomers, the hinder two-thirds is occupied by the vomer, proper (*v.*), the outer edges of which rest upon the corresponding palatine plates of the maxillaries. The vomer is split in front, keeled all along, and somewhat trilobate behind; it is a stout, shortish bone. The nasal capsules are seen inside and around these bones—side, septum, and terminal recesses (*al.s.p.*, *al.e.*); the septum is first seen where it begins to run over the fore part of the vomer, and the proper olfactory region, after swelling outwards beyond the maxillaries, runs inwards over the sharp forks of those bones, to end right and left of the presphenoidal region (*p.s.*).

As far as the maxillaries are concerned, this skull is now perfectly “schizognathous;” so it is as regards the palatines (*pa.*), which are in a very primitive, *quasi-reptilian* condition. Each bone is falcate, and arched inwards; it is thicker forwards than behind, is a sharp wedge in front, binding obliquely on to the inside of the inner sharp process of the maxillary, whilst, behind, it runs outwards as a fine point of bone, binding over the pterygoid (*pg.*). Behind the vomer (*v.*), the palatines are, at their nearest, nearly their own width apart, whilst, further back, they expose the whole width of the basicranial beam.

The palatal series is completed by the pterygoids (*pg.*); these bones are only two-thirds the length of the palatines, of the same thickness, on the whole, and are wider apart, for at their middle they elbow out, like two pieces of “knee-timber.” The fore end of each bone is sharp, and runs obliquely inside the palatine, the hind converging part is rounded, and is capped by a truly cartilaginous remnant of its *mother-tissue*. This cartilaginous hamular process is common in the embryos of low Eutheria. It is a slight re-appearance of the old “pterygo-quadrato” of the Ichthyopsida. The rest of the superficial bones seen in this view are the frontals (*f.*), and the squamosals (*sq.*); the former are turned in under the suborbital ridge, and over the orbit, and the latter are applied to the endocranium opposite the pterygoids. The frontals are very partial, however, in this region, and only partially invest the arrested orbitosphenoids (*o.s.*). Behind these endo- and exo-skeletal laminæ there is a large lateral fontanelle, which takes up most of the posterior region of the orbital space (see also fig. 3). The squamosals are distinguishable from those of a Chick by the presence of a small, flattish, pyriform tract of cartilage attached to their jugal process; in the Chick this process serves for muscular attachment merely; here, in this low Mammal, we have the “glenoid” facet for the special Mammalian mandible, at its lowest state of development.

The floor and sides of the chondrocranium are largely seen in this view; I have

already spoken of its nasal or olfactory territories. The hind part of the perpendicular ethmoid (*p.e.*), and all the rest of the basis cranii, is displayed; but the edges of the bar, in front, are hidden by the inbent palatines; just in front of their middle, the presphenoid (*p.s.*) begins, and this is halfway, exactly, between the end of the snout and the front edge of the foramen magnum (*f.m.*). If the postclinoid wall could be seen, it would be found to be half way from the end of the former to the foramen magnum; the open pituitary space (*py.*) is a little in front of it.

A little in front of that primary opening, the basicranial beam is composed of three bars melted into one; the lateral bars are the trabeculæ, and they end between the widest parts of the ethmoidal swellings and the middle of the vomer; thence the basiseptal mass is formed of the azygous intertrabecula.

The orbitosphenoids are trabecular crests, as the great internasal partition is an upgrowth of the intertrabecula.

In the Crocodile and Alligator (see Trans. Zool. Soc., vol. 11, plate 64, fig. 2, *tr.*, *o.s.*) the orbitosphenoids, are seen growing directly upwards and outwards, from the paired trabeculæ. After the great intertrabecular crest is well developed, and the trabeculæ become thinned out on its sides, right and left, *some transverse sections* show a discontinuity between the orbitosphenoids, perched at the top of the crest, and the flattened trabeculæ from which they sprung (*ibid.*, plate 67, figs. 2, 3).

In Serpents (Phil. Trans., 1878, Plates 28–31) there is no intertrabecula, and the nasal roofs dip down, and coalesce with the trabeculæ, which become fused in the internasal region. But in the interorbital region the trabeculæ persist as free terete rods of cartilage, and both the orbitosphenoids and alisphenoids arise in the wall of the membrano-cranium as small, free patches of cartilage. This is a curiously abortive and arrested condition of these parts.

Here in this little skull, which is abortively developed, both within and without, the very feeble orbitosphenoids, small and with very imperfect angular extensions, above (compare figs. 1 and 3 with the skull of the embryo of *Tatusia*, Plate 2, fig. 1), are articulated to, or distinct from, the proximal part, ending above it in a bilobate process. There is, however, evidence here that this is the abortive development of a type above the Marsupials, for the optic nerve (II.) passes through a ring of cartilage, and not through a common optico-sphenoidal fissure, as in them.

The rest of the sphenoid, excluding the abortively developed orbitosphenoids, is a remarkable structure. The basal beam is very wide, and has, for a Mammal, an unusually large and almost Sauropsidan pituitary hole; opposite that unfinished space the base grows out into a pair of thick rounded ears of cartilage, thicker and a little wider than the lateral processes of the presphenoid, which are perforated for the optic nerve. A rounded notch is seen both in front of and behind these small auriform alisphenoids (*al.s.*), and these notches are actual foramina, through the membrano-cranium; the foremost is the sphenoidal fissure (V^2), and the hinder is the foramen ovale (V^3), only a *foramen* as it respects the membrane, not the cartilage. But the

hinder of these passages is a great distance from the mid-line, and has a considerable (proximal) part of the alisphenoid between it and the proper basis cranii. The breadth of the investing mass or parachordal tract behind the pituitary opening is nearly equal to that of the cochleæ (*chl.*)—those diverticula of the huge auditory capsules. The notch for the foramen ovale (V^3 .) is against the inner third of the cochlea, the squamosal reaches the outer third, and then increases the size of the tegmen tympani (*t.ty.*), the incus is shown in that space overlapped by the squamosal. The bulbous cochleæ (*chl.*) have the appearance in this view of being only composed of two coils, for the proximal coil is very large, and the distal is not marked off from the second. The outline, even in the inner face, is evident, but the cartilage of the capsule has for some distance coalesced with the basal plate (*b.o.*), that is, along its inner edge, from the foramen ovale (V^3 .) to the opening for the internal carotid artery, and then again on to the fissure for the 9th and 10th nerves (for X., XI., *read* IX., X.). The stapes (see also figs. 3 and 6) has been removed from the fenestra ovalis and from the incus (*i.*), and from the latter the primary mandible or malleus (*ml*) has been removed. Thus in this figure the pier of the primary mandibular arch, the quadrate—or, speaking specially of it as a Mammalian element, the incus—is seen inside the posterior radiations of the squama temporis (*sq.*). Its position here in this very simple kind of Mammalian skull is well worthy of consideration.

If we take the short crus of the incus as the equivalent of the “otic process” of the quadrate, and the long crus as a special Mammalian modification of the incus for articulation with the head of the stapes (=extra stapedial process of the columella, see in Chameleon, Trans. Zool. Soc., vol. xi., plate 16), and remember that in the Mammal the “orbital process” is suppressed, we shall see clearly what these things mean. In all essentials, everything is the same, here, as in the Fowl (Phil. Trans., 1869, Plate 81).

The body of the incus, which articulates with the primary mandible, is opposite the middle of the cochlea; the long crus runs inwards to join the stapes—or *columella* in this case (see fig. 6)—and the short crus or otic process runs backwards over the stapes and fenestra ovalis, so as to get behind the ampulla of the horizontal canal (see fig. 3, *h.s.c.*; and in the Fowl, *op. cit.*, Plate 81, fig. 5, *q.*, *h.s.c.*). The fenestra rotunda, in this figure, is hidden from sight by the small rounded epihyal (*e.hy.*) which is already confluent with the capsule; behind it the facial nerve (VII.) escapes through the stylo-mastoid foramen, giving off in its escape the chorda tympani to join the 3rd branch of the 5th nerve inside the primary mandible. In spite of the intrusion of the auditory capsules, and their tilted position, the cranial nerves make their escape in a very orderly manner. Here the facial nerve (VII.) although thrust far outwards—having to bore its way through the forepart of the capsule, from the meatus internus, and then travel backwards, under the tegmen tympani, yet manages to escape into the face a considerable distance in front of the 9th and 10th nerves (IX., X.).

The opisthotic region (*op.*) behind and outside the cochlea is very large, and the

canals (see also figs. 3 and 4), are very conspicuous, shining through the hyaline cartilage. Outside the innermost lobe of the capsule, the ampulla and ascending part of the arch of the posterior semicircular canal (*p.s.c.*) is seen, and in front of it, more outward, the hind part of the horizontal canal (*h.s.c.*), which arches over the incus.

At present, the hind skull is a funnel-shaped structure, as though it were a detached and enlarged part of the spinal column. Along its wide floor, the basi-occipital region (*b.o.*), the notochord (*nc.*) still persists, and runs more than half way to the pituitary hole (*py.*); it enlarges somewhat whilst in the parachordal channel, and then ends in a point. Right and left of its hind part, at a moderate distance from each other, the occipital condyles (*oc.c.*) are seen to be sub-crescentic thickenings of the infero-lateral margins of the chondrocranium; above and behind them, the roof (*s.o.*), imperfect behind, is ossified by a median osseous centre.*

The lateral occipital region (*e.o.*) is but little raised as a paroccipital ridge; it is notched for the 9th and 10th nerves (IX., X.)—the foramen being in the interspace of the arch and the auditory capsule—and perforated a little further backwards and inwards for the 12th nerve (XII.). This would have been a pure chondrocranium but for the premature, single supraoccipital centre (*s.o.*).

The *upper view* (fig. 2) shows the wide alinasal region (*al.n.*) followed by the more contracted double tube of the aliseptal territory (*al.sp.*), and this gradually widening into the aliethmoidal (*al.e.*), which swells on each side of the face in front of the orbits, and contains the upper and middle turbinals. The pyriform cranium has the broad, partly ossified supraoccipital (*s.o.*) for its base, and shows the deficient chondrification (*s.o.n.*) over the foramen magnum (see also fig. 4). The fore margin of this convex wall is sinuous, concave right and left of the middle, but with a convex margin, there, on each side. The ethmoidal and supraorbital regions are covered with bony films; and also the right and left third of the most swollen part in front of the supraoccipital. Three pairs of these centres are visible from this aspect, the nasals, frontals, and parietals (*n.*, *f.*, *p.*).

The very small, short, nasals, are both in form, position, and relative size like those of a Bird, being deeply notched in front. But, in a Bird, these forks embrace the upper part of the external nostril, and between the nasals the premaxillaries send, each, a long lathy process—the nasal process (see in the Fowl, Phil. Trans. 1869, Plate 86, fig. 15). The Mammal has that process arrested, and the premaxillaries run under the outer edge of the nasals, and only have that extra-nasal process, large in certain types, *e.g.*, the Hare and Rabbit.

The frontals (fig. 2, *f.*) here lie over the orbital region, looking like the dislocated valves of a Bivalve; they do not meet in the middle, above and in front; beyond their

* A rare character—normal in Reptiles, but as rare in Birds as in Mammals; I have only, as yet, found it in one genus of Birds, namely, *Turdus*—the Thrushes (see Monthly Microscopical Journal, 1873, plate 9, pp. 102–107).

In this figure of the skull of the embryo Pangolin (Plate 11, fig. 1, *s.o.*) the roof with its bony tract is figured as it appeared in the *flattened preparation*; figs. 2–4 correct this.

middle they diverge rapidly, so do the parietals (*p.*) behind them, but they are separated by a much wider space, almost equal to their own width. Hence the fontanelle (*fo.*) is very large, has a narrow median limb in front, and a postorbital, and a supraoccipital pair of transverse limbs; above, the median part is, over the vertex, dilated as a wide lozenge-shaped space.

But these things are seen also in an instructive manner in the *side view* (fig. 3). The narrowish snout is but little turned downwards, it very suddenly passes from its short aliseptal region into the swelling ethmoids (*al.e.*). In front (*al.e.*) the alinasals form a crescentic portico over the sub-inferior nostrils (*e.n.*). Behind these parts—the snout, proper—the swelling caused by the inferior turbinal at the side, arches upwards and outwards from the semicylindrical upper tract (*al.sp.*), which contains the nasal turbinal; behind this is the bulbous olfactory region (*al.e.*), the narrow end of which (*m.tb.*) can be seen in the fore part of the orbit, below. The small forked nasal (*n.*) is seen to be a long way behind the external nostril (*e.n.*), and a good distance from the ascending toothed edge of the maxillary “scale” (*mx.*), in front of which is the narrow, oblique, ascending part of the premaxillary (*px.*).

The frontal (*f.*) is moulding itself upon the orbital recess, and has a neat, super-orbital edge; the bone is pinched in in front of that part. The toothed edges of these osseous scales—the frontals and parietals—nearly touch in the postorbital region. Under the inturned part of the frontal, the cartilage (*o.s.*) lines the orbit, and just shows itself beyond, at the edge of the temporal region. Below, in the postero-inferior recess of the orbit, the optic nerve (*II.*) can be seen emerging through its ring of cartilage (*o.s.*); it rests upon the thickish palatine bone (*pa.*). A large lozenge-shaped space is seen between the frontal, parietal, and squamosal (*f., p., sq.*); the latter hardly reaches the parietal in the temporal region, and is altogether a very jagged plate. Its jugal process runs outwards and forwards and shows its small pyriform glenoid facet (*gl.f.*); its posterior part runs, splintery, over the face of the auditory capsule, hiding the ampullæ of the anterior and horizontal canals (*a.s.c., h.s.c.*). But the hinder part of the latter, and the junction of the anterior and posterior canals (*p.s.c.*)—the latter displaying its ampulla—all these are clearly seen in this view, and also that the capsule itself is not much tilted, at present. The cochlea (*chl.*), with its coils, and the pterygoid (*pg.*) with its cartilaginous cap, are seen under the squamosal. Behind the swelling capsule, the large occipital arch shows an unusual amount of its surface in this aspect; it is a short, wide tube.

Above, the bony supraoccipital (*s.o.*) is partly seen; laterally, this broad arch shows its sinuous edge behind the parietal, coming down to unite with the capsule above the junction of the two upper canals (*a.s.c., p.s.c.*). The two parts of cartilage are confluent along the hind margin of the capsule, and here the exoccipital region (*e.o.*) is thickened obliquely, upwards and backwards, into a low paroccipital ridge; the condyle (*oc.c.*) is here seen in its upper part.

The incus (*i.*) is seen just peeping from under the postero-inferior corner of the

squamosal; the malleus (*ml.*) has been dislocated from it, and also the *new ramus* from its zygomatic or glenoid facet (figs. 3 and 6; in the former these parts are seen from the outside, in the latter more magnified figure, from within). The superficial secondary mandible (*d.*) is lesser than the deep primary rod (*mk.*); it is applying itself to the upper and outer face of that rod, and in front is composed of two delicate tracts of bone, the inner and lower of which (*sp.*, *line too short*) corresponds to the separate splenial of the Ovipara. But the main part of the ramus is a thickish lanceolate tract of hyaline cartilage; an "inferior labial," part of which tract has already become segmented off to form the glenoid facet.

MECKEL'S cartilage (*mk.*) has united with its fellow in front, and the two have an azygous rod in front of them, a basimandibular (*b.mn.*). The whole rod is sinuous, and thickens gradually backwards; the last fifth is behind the "ramus," and is the part which becomes the malleus (*ml.*). Then the rod is arched upwards, and thence swells into a head, or articular portion, with a saddle-shaped condyle; from the head there arises a long and a short process—internal and posterior angular processes, which become the manubrium mallei (*m.ml.*). The long process forms an acute angle with the main rod, and ends in a slight dilatation in the middle of the developing membrana tympani (*m.ty.*), in the fore margin of which a slight arc of bony cells is seen, the annulus (*a.ty.*). Under the proximal part of the rod a fine tract of membrane-bone is seen, the first appearance of bone to form the malleus (= the ectosteal "articulare" of the Ovipara).

The quadrate or incus (*i.*) is a quadrilobate segment of cartilage, binding against the malleus by the two front lobes, articulated to the tegmen tympani by the postero-superior, and applying its inturned postero-inferior lobe, which has an orbicular facet at its end, to the head of the stapes. The latter part (*st.*) is oval in its base or proximal part, and then its short *solid* stem dilates in an orbicular manner to articulate with the incus.

That is the pharyngo-hyal; the epihyal is seen from below as a small lobe of cartilage, confluent with the ear-capsule, and forming a small bridge for the facial nerve to pass over (fig. 1, *e.hy.*, VII.). The next segment is the ceratohyal (fig. 5, *c.hy.*), it is fibrous above, and instead of having an extra segment, above, and a hypohyal, below, as in most Mammals, there is but one piece altogether. The basal piece (*b.h.br.*) is also very rudimentary, being a bent U-shaped rod, with very short continuous crura (*t.hy.*).

Now in such an aberrant and feebly developed face as this, we can the better compare the Mammal with the Bird. In the latter the epihyal (=stylohyal) cartilage is also short; it does not, however, form an adhesion with the auditory capsule, but with a slender outgrowth from the neck of the columella (=stapes) (see "Bird's Skull," Part II., Trans. Linn. Soc., ser. 2: Zool. vol. i., Plate 20, figs. 7, and 8–11). That outgrowth—the infrastapedial band—is represented in Fishes by the interhyal, a segment which re-appears in the Mammal, and becomes wrapped up amongst the

fibres of the tendon of the stapedius muscle. In the Bird the stapes, or columella, has not a flat head, but a tongue-like process (extrastapedial), which sends upwards at its base a forked spike (suprastapedial).

The ceratohyal is not distinct, in the Bird (as in Manis), from the hypohyal, but this feeble distal rod does not end abruptly and articulate with a transverse basal piece; it runs forwards into the substance of the tongue, meeting its fellow, there, at an acute angle; whilst the basal piece is longitudinal, and fits into the sharp re-entering angle formed by the two ceratohyals. The long basal piece is divided into what represents two basibranchials; and where the two segments meet, there is given off a large, segmented, gill-less 1st branchial arch.

In the Bird the distal basibranchial forms the support for the thyroid cartilage; in the Mammal it is supported by, and articulated to, the paired hypobranchials of the aborted 3rd arch (=1st branchial).

The *end view* of this skull (Plate 11, fig. 4) is suborbicular—sinuous below—gently convex, and leans forwards above where the supraoccipital joins the parietals (*s.o.*, *p.*). These latter are just seen, above, and so also are the squamosals (*sq.*) at the sides. The foramen magnum (*f.m.*) is large and oval, with the long diameter vertical; it has a small deficiency in its upper outline, which leads to a circular membranous space—"the median occipital fontanelle" so familiar in certain Birds, *e.g.*, Pigeon, Owl, &c. (see Trans. Zool. Soc., vol. v., plate 34, fig. 2; plate 35, fig. 1; and plate 37, fig. 6, *m.o.f.*). Over this, from edge to edge, the cartilage has become ossified, by the azygous supraoccipital (*s.o.*), which is two-winged above, and forked below, the forks holding the fontanelle, like pincers. The rest of the occipital cartilage (*e.o.*, *b.o.*) is free from bony deposit; in the middle of the basal plate, under the foramen magnum (*f.m.*), the notochord (*nc.*) can be seen lying on the upper part of the thickness of the floor. The exoccipital region is very slightly raised into a paroccipital ridge, right and left, and is well marked off from the auditory capsules, in which are seen the posterior and horizontal canals (*p.s.c.*, *h.s.c.*). Underneath, in the distance, the cochleæ (*chl.*) swell the bottom of the skull, right and left.

Second Stage.—*Embryo of Manis breviceaudata*; $4\frac{2}{3}$ inches long, from snout to root of tail (see Plate 1, figs. 5, 6).

The *under view* of the skull at this stage (Plate 11, fig. 8), which is twice as advanced as the last, shows a great approach to the permanent condition.

The *inferior* nostrils (*e.n.*) are protected by a rounded but quite simple alinasal fold, and they approach each other more closely now, right and left of the alate floor. Part of the aliseptal region can be seen right and left of the front bones of the face—the premaxillaries (*px.*). These bones (*px.*) are very feeble, and are composed of an outer and an inner stalk; in the rounded re-entering angle, formed by the two stalks, the opening of "JACOBSON'S organs" (*j.o.*) can be seen. The narrow

fore part of the bone in its toothless alveolar region runs with its fellow close up to the alate alisnasal floor; it broadens to send upwards and backwards (see also fig. 7, *px.*) its falcate facial plate. The palatine processes, once very short (fig. 1), are now extremely long, they have evidently made their hind part from the paired front vomers (fig. 1, *v.*). Two-fifths of the palatine plate of each maxillary (*mx.*) comes short of the mid-line, and exposes the long styles running backwards from the premaxillaries. The rest of these plates is complete, the termination of them behind is in sharp wedges that run between the palatines (*pa.*). The region between the thick edentate margins of the palate is elegantly lanceolate, and is more than a third of the general width of the face as seen from below; it is also high or arched, for the fore palate in this type is very hollow. The arched alveolar ridges turn inwards to clamp the fore part of the palatines (*pa.*), and outside the ridges the bone is seen, right and left, expanding in a roughly convex manner to form the large facial plate (see also fig. 7, *mx.*). That plate swells suddenly over the lateral ethmoidal masses, and in the widest part is burrowed below for the 2nd branch of the 5th nerve (V^2). The ridge from the infraorbital opening of that burrow runs backwards and outwards, and ends in a short, free, blunt zygomatic process, on which, in this stage, I find no trace of a jugal bone. The palatines (*pa.*), as seen from this aspect, are as long as the palatine region of the maxillaries. A considerable right-angled space divides the two bones behind, and a more acute-angled gap receives the maxillaries in front.

They are somewhat pinched in, laterally, are slightly bevelled, externally, in front, and form a low ridge outside; each bone is gently hollowed towards its fellow; the two unite and carry on the median suture of the hard palate, which is half the length of the basis cranii, including the snout. This view only gives half the extent of the palatine bones (see fig. 7, *pa.*) which have a large orbital development. The pterygoids (*pg.*) have only the average development, their external outline is concave as in the case of the palatines; their lower edge is thick, and they have a free hamular process, capped, still, with cartilage; they are two-thirds the length of the palatines; they still overlap the cochleæ (*chl.*). Two large bony tracts can be seen on each side, the orbital plates of the frontals (*f.*), and the zygomatic and postglenoid regions of the squamosals (*sq.*). The hind part of the nasal capsules (*mtb.*) are still uncovered in the inner part of the orbital floor, the infraorbital nerve (V^2) is seen running under this tract right and left. The pyriform glenoid facet (*gl.f.*) in the back of the zygomatic stump of the squamosal (*sq.*) is now large, and the bone, after swelling to enclose the facet, contracts into a neck, and then, hollow within, overarches the auditory capsule; the bony eave reaches back beyond the stylomastoid foramen (VII.) Inside the orbital plate of the frontal a large exposed part of the osseous orbitosphenoid (*o.s.*) is shown as a rounded wing right and left. The optic nerve (II.) is escaping from its inner part, and its edge in front is notched for the re-entering orbitonasal nerve, which emerges from the

skull at the sphenoidal fissure with the 2nd branch of the 5th ($V^1, ^2$). The pre-sphenoidal region (*p.s.*) is still unossified; it can be seen between the diverging palatines. The posterior sphenoid stretches across the whole inter-glenoidal region, outside and inside the pterygoids. The basisphenoid (*b.s.*) has ossified three-fourths of its proper territory; it is emarginate both before and behind. Nearer the eye than the orbital wing (*o.s.*), each alisphenoid ($V^1, ^2$ to V^3 .) reaches the squamosal in front, and is then deeply notched for the 3rd branch of the 5th nerve (V^3 .) This notch is protected by bone behind, which runs between the nerve and the auditory capsule (*chl.*); on the outside the foramen ovale is finished by other parts, it merely notches the outer edge of the alisphenoid bone. In this figure the left annulus and its related parts are shown; whilst on the right side of the head—left of the figure—the lower face of the capsule is exposed.

The annulus (*a.ty.*) is a wide U-shaped tract, thickened at the end of its inturned cornua; the foremost of these is notched to let MECKEL'S cartilage (*mk.*) pass. This is drawn as cut across. The narrow annulus leaves a wide and exposed drum membrane (*m.ty.*), in which we see a long manubrium mallei proceeding from the head of the malleus (*ml.*), which articulates with the incus (*i.*) under the double tegmen formed by the squamosal (*sq.*) outside and the capsule within. The cochlea is exposed on the inner side of the annulus, and where the pterygoid (*pg.*) overlaps these parts, there the Eustachian aperture opens into the throat. The cochlea and vestibule (*chl.*, *op.*) are large and normal; they are quite unossified; the fenestra ovalis (*fs.o.*) is large; outside it is the passage for the 7th nerve (VII.), which escapes through the stylomastoid foramen behind the small epihyal (*e.hy.*); the rounded part behind that opening (*op.*) contains the ampulla of the posterior canal. A band of cartilage separates the fenestra ovalis (*fs.o.*) from the fenestra rotunda (*fr.*), which is seen behind the first or proximal coil of the cochlea (*chl.*). A deep groove runs between the occipital arch and the capsule, and on the inner side of the vestibule both parts are notched to make a common passage for the 9th and 10th nerves (IX., X.). Behind and within this is another passage or hole in the occipital arch within the exoccipital bone (*e.o.*), which is creeping forwards; this is for the large hypoglossal nerve (XII.). Thence to the edge this part is ossified; and the bony matter runs right and left, up to and over the convex arcuate condyles (*c.oc.*). But a very wide band of cartilage is seen continuous with, and in front of the condyles, margining the foramen magnum (*f.m.*), and ending in a concave margin, where the basioccipital bone (*b.o.*) has broadened out to twice its interauditory region. That bone is rather pinched in towards its fore end, where it is notched, and has a fine tubular process in the notch which runs much of the distance between this bone and the basisphenoid (*b.s.*); that process is the ossified sheath of the fore part of the cranial notochord (*nc.*)

The *upper view* (Plate 12, fig. 1) shows how greatly the investing bones have developed since the early stage (Plate 11, fig. 2). The facial region is very small

compared with the cranial; the whole outline is pyriform. The nasal capsule is still considerably exposed, the whole alinasal, half the aliseptal, and part of the aliethmoidal parts (*al.n.*, *al.s.p.*, *al.e.*) still being visible. But the forked, *ornithoid* nasals (*n.*) have more than doubled their size, and outside them the premaxillaries and maxillaries (*px.*, *mx.*) just show their upper edge.

The nasals and frontals (*n.*, *f.*) now fairly meet in the middle, and the frontal suture is now of considerable extent; behind it the lessening fontanelle (*fo.*) is a four-rayed lozenge of membrane. The postorbital part of the frontal and the contiguous part of the parietal (*p.*) are too convex to allow the squamosal to be seen in this view, yet it is a large bone (see Plate 11, fig. 7, *sq.*). There is a fontanelle in the lambdoidal region, three-rayed, and half the size of the other; the parietals then meet for about half their inner margin to make the sagittal suture. The hind skull lessens one-third to form the occipital cincture (*s.o.*) which is largely ossified in its upper part—more than half of the part exposed in this aspect; about a third in reality (Plate 12, fig. 2, *s.o.*).

The *side view* (Plate 11, fig. 7) has gained a more normal form than that of the early stage (fig. 3), the greater development both of the deep and of the superficial parts has brought this about.

The large, nearly inferior, circular nostril (*e.n.*) is seen covered by a crescentic roof (*al.n.*) and the beginning of the roof and side of the great nasal tube (*al.sp.*) is seen in front of the oblique falcate facial plate of the premaxillary (*px.*) which is pedate in front, where it forms the aborted alveolar region. The nasal is seen over the olfactory capsule just reaching the frontal (*f.*) and the arched top of the facial plate of the maxillary (*mx.*), which thickens below to form the edge of the jaw, and sends backwards a free zygomatic process, the root of which is perforated by the 2nd branch of the 5th nerve (*V²*). The top of the maxillary does not reach the frontal, but the nasal wall (*al.e.*) outside the upper turbinal (*u.tb.*) is exposed for some extent there, and in the antorbital region, showing there an unossified "pars plana" (*m.tb.*). There is no lacrymal bone, a rare character in a Mammal, as far as my experience goes. The well formed upper and orbital plates of the frontal (*f.*) give form to the upper half of the orbit, in which this bone forms roof and wall, the latter is a large rounded tract. The upper region of the frontal has a very large postorbital extension, and the large membranous tract seen there in the immature embryo (fig. 3), is here covered by the frontal and squamosal, the parietal in this type being kept well out of the temporal fossa. Thus in this side view the parietal (*p.*) looks scarcely larger than the squamosal (*sq.*) which reaches nearly as far backwards, and much further forwards, than the great upper plate.*

The squamosal is notched behind the orbit to give form to that space, and is scooped over the hinge for the mandible; the rest of the bone is evenly convex; it ends behind, like the parietal, in a rounded outline. Under the orbit the large

* I fail to understand this modification, the opposite of what is seen in the Little Anteater (Plate 10), which has a far more perfect lower jaw than the Pangolin.

ascending plate of the palatine (*pa.*) is seen ; it helps the maxillary to form the ant-orbital bony wall.

The hind skull now leans backwards, above ; it is very convex, and has its upper and middle part ossified (*s.o.*, *e.o.*) ; the exoccipital, a broad band, runs across and then downwards behind the crescentic convexity of the opisthotic—which encloses the posterior canal (*p.s.c.*)—and the reniform occipital condyle (*oc.c.*). The articulated mandible and the ear-drum hide parts seen in the other side view (fig. 3) ; the annulus (*a.ty.*) runs inwards and downwards.

The outer and inner mandibles (here seen from the outside, but shown in their inner aspect and more enlarged in Plate 12, fig. 4) are very instructive in this type, at this stage.

Even now the superficial ramus is a very small sinuous bar, with a considerable amount of cartilage in its hinder fourth, into which the dentary (*d.*) runs, ending in a point. The condyle (*cd.p.*) is a convex pyriform tract, lying lengthwise, and with the narrow end forwards, it is quite similar to that of the *Echidna*, but the ramus itself (= dentary) is less developed than in that type, although stouter ; it has now no rudiments, even, of the coronoid and angular processes.

In this figure (Plate 11, fig. 7) the parts are shown *in situ* that correspond with what we see in the embryo Sauropsidan, the incus or small quadrate (*i.*) is just seen in front of the epihyal (best seen in fig. 8, *e.hy.*), under the tegmen tympani ; also the long internal angular process (*m.ml.*), with a rudiment of the posterior spur, running along the membrana tympani, and MECKEL'S cartilage running under and within the dentary, which, however, has been made largely out of cartilage.*

MECKEL'S cartilage (Plate 12, fig. 4, *mk.*) is slenderer, relatively, its thickest part, now, being near the symphysis ; there, meeting with its fellow, it forms a considerable basimandibular (figs. 4 and 5, *b.mn.*).

As in the Green Turtle (*Chelone viridis*) the ectosteal articulare (=superficial bony centre of malleus), appears first, and the endosteal centre afterwards—in that Reptile *several years* afterwards. The head of the malleal end of the Meckelian rod is solid and convex ; the manubrium (*m.ml.*) is slender and more arcuate than in the early embryo (Plate 11, fig. 6), and the lesser posterior process is more indistinct. The large incus (*i.*) and the short, columelliform stapes (*st.*) are unossified, as yet ; the

* I have never found an "inferior labial" cartilage in a Reptile ; in Birds, however, it has turned up ; in 1843 I found and figured a tract of this kind, of an oblong shape, over the middle of the mandible in the Coot (*Fulica atra*), and twenty years afterwards I dissected out the same thing in another of the Rallidæ, namely, *Gallinula chloropus*. Now one thing is noticeable in this comparison, and that is that in the Sauropsida, as far as I have seen, MECKEL'S cartilage simply shrinks and dies out in the main part of the mandible in front of the "articulare," and does not ossify and become a direct addition to the jaw. Nor can I find any actual endosteal ossification of MECKEL'S cartilage in the distal part in the Edentates, although the part that is ultimately absorbed directly in front of the malleus (= articulare) is separately ossified in the Unau (Plate 9, fig. 7) ; but in the Insectivora, and even in Man, a large tract of MECKEL'S cartilage ossifies, and then unites with the ramus.

interhyal has not appeared, up to this time; but abortively developed parts are often *late*. The inturned neck of the incus is curiously alate. The base of the stapes is very thick.

The distal parts of the hyoid arch (Plate 12, fig. 3) have undergone little change except as to size and solidity (see Plate 11, fig. 5); but the thyrohyals (*t.hy.*) are more incurved, for clasping the larynx.

The *end view* (Plate 12, fig. 2), as compared with the same aspect of the skull in the early stage (Plate 11, fig. 4), shows considerable progress in development.

The thick parietals (*p.*) almost meet to finish, with the supraoccipital, the lambdoidal suture. The squamosals (*sq.*) now show considerably from the end; they have gained much substance, and are large convex plates.

The upper half of the face of the great occipital arch has its middle third occupied by a supraoccipital bone (*s.o.*), shaped roughly like an hour-glass; it does not yet reach the foramen magnum (*f.m.*), but the fenestra (or fontanelle) over that doorway is now a mere notch in the lower edge of the cartilage.

Nearly half the space from the lower edge of the bony supraoccipital to the occipital condyles (*oc.c.*) is occupied, below, by the large spreading exoccipitals (*e.o.*). Their upper margin is sinuous, their outer rounded, and the large outer margin runs over the opisthotic convexity. Below, each bone runs in as an uncinat tract, between the opisthotic and the condyle; the thickish, convex, outer edge of the tract is the low, indistinct paroccipital process. The opisthotic tract, which has taken the form of the enclosed posterior canal, must be conceived of as lying some distance from the eye (see also Plate 11, fig. 8), and the bulbous cochleæ (*chl.*) as still further off.

This stage is further illustrated by a *vertically longitudinal section*, made a little to the left of the mid-line in the fore half (Plate 13, fig. 12).

We see at once in this figure what is also seen in the side view (Plate 11, fig. 7), namely, that the snout and fore part of the nasal capsule is considerably curved downwards. I only see that in this stage and in this species, and am not sure whether there is some *specific* modification in this case; at any rate, this skull thus repeats a character seen well in *Cycloturus* (Plate 10, fig. 7).*

The ethmoseptal or front half of this skull is one-fourth longer than the proper basiscranii or speno-occipital region. In the early stages they were equal.

Nowhere is the intertrabecula, or thick base of the great partition (*p.e.*, *s.n.*), more distinct and massive than in this; but for its crest, it would be almost Cetacean.†

* These lesser modifications, both as seen in *species* and in *stages*, are almost endless, and yet none of them is without signification. The two nine-banded Armadillos differ in this respect, for *Tatusia peba* (Plate 5, fig. 6) has a very straight snout, whilst the closely related *Tatusia hybrida* has it considerably decurved (Plate 2, figs. 1 and 8, and Plate 6, fig. 3).

† See ESCHRICHT'S figure of the skull of an embryo of *Balæna japonica* in a posthumous paper published by the late Professor REINHARDT: "Ni Tavler til Oplysning af Hvaldyrenes Bygning," tab. ii., Copenhagen, 1869.

The alinasal fold (*al.n.*) runs well round the end of the septum (*s.n.*), which shows the usual fenestra at this part (*inf.*); behind the snout the alæ nasi give off from their base the usual spoon-like recurrent cartilage (*rc.c.*) for the protection of "JACOBSON'S organ."

Two bones protect most of the top, but, below, the middle part, only, is supported by bone. The upper are the nasals (*n.*), and frontals (*f.*), the lower the vomer (*v.*); I did not find the "postero-lateral vomers" developed in this stage; when they do appear they do not remain distinct, for long: the antero-lateral vomers had evidently already coalesced with the premaxillaries (Plate 11, fig. 8). The floor of the deep olfactory recess, or cribriform plate (*cr.p.*) has been cut across; but it will be seen that this section leaves a large triangle of cartilage above and behind, making the recesses appear much deeper than they otherwise would do; this forms a large cartilaginous "cristi galli" or proximal solid part of the *falx cerebri* (see also in *Tatusia hybrida*, Plate 2, fig. 1, *cr.g.*, where, however, it is not so large as in this type.)*

The hemispheres are lodged in a strong box, already; the fontanelle (*fo.*), and the triradiate suture between the frontal, parietal, and squamosal (*f.*, *p.*, *sq.*) are clearly seen, and the growing thickness of the bones, especially of the parietal, where it forms an attachment for the "tentorium cerebelli" in front of the anterior semicircular canal (*a.s.c.*). The falcate cartilage over the low bony orbito-sphenoid (*o.s.*', *o.s.*) still shows its distinctness and is still a considerable distance behind the cribriform plate, below. The bony orbitosphenoids (*o.s.*) are obliquely oblong and are turned forwards and outwards; the large optic foramen (II.), well surrounded by bone, lies low down; the basal bar (*p.s.*) is not ossified. A considerable fenestra (or fontanelle) still exists over the sphenoidal fissure (*V*^{1 2}), not yet covered over by the frontal and squamosal. Under the latter the alisphenoid (*al.s.*) lies outwards, and leans forwards, letting the nerve of the lower jaw (*V*³.) pass over its edge at the hinder fourth; a snag of bone protects the nerve behind, but above, it escapes through a notch. The basisphenoid (*b.s.*) is separately ossified, and has taken up much of the cartilage of its own territory; then comes a tract of cartilage three-fourths as long, and then a tract of bone, the basioccipital (*b.o.*).

The latter bone comes far short of the foramen magnum (see Plate 11, fig. 8). The fore part of the spheno-occipital synchondrosis is thick, forming the low postclinoid wall. In the large "foramen lacerum" between it, the alisphenoid, the squamosal, and the round end of the large cochlea, the internal carotid artery enters. The large auditory capsule is separated, above, from the supraoccipital (*s.o.*) by a deep groove that contains the "lateral sinus," and is partly overlapped by the posterior (*tentorial*) edge of the parietal, and lower down by the posterior edge of the squamosal.

* If the presphenoid (*p.s.*) were crested, like this part, in front, then we should have a cartilaginous septum to the orbits, as in the Bird (see Phil. Trans., 1869, Plate 81, figs. 3, 4, 5); in that case the cartilaginous crista galli would be an additional crest on the antero-superior edge of this vertical orbital septum.

Thus the swelling cochlea (*chl.*) has made itself a very accurate "nest" in the inferolateral region of the skull, and the posterior canal (*p.s.c.*) rising up from its junction with the anterior (*a.s.c.*) pushes itself into the antero-internal face of the exoccipital (*e.o.*). The whole arch of the anterior canal is seen, and the fore part of the space under it is well scooped for the "flocculus." The great multiperforate "meatus internus" (VII., VIII.) is arched over by a convex tract of cartilage; below, the entrance is floored by the swelling cochlea.

The whole capsule is large and normal, both as to the parts shown, and also, as to the degree of tilting it has undergone during growth.

The hind part of the wall formed by the occipital arch, is as large as the large preauditory region, walled in by the parietal and squamosal. In this *internal side view* the supraoccipital bone (*s.o.*) looks less than it is, but the band of cartilage below it shows its full breadth. The middle third of the wall—nearer the bottom than the top—is formed by the exoccipital (*e.o.*) which is somewhat of an hour-glass shape. It is notched, below, for the large 12th nerve (XII.), and in front of and below it the common nick for the 9th and 10th nerve (IX., X.) is seen. The cartilage between the basioccipital and exoccipital (*b.o.*, *s.o.*) is narrower than the tract above, but widens out behind, to lose itself in the large convex condyle (*oc.c.*).

*Third Stage.—Newly-born Pangolin (Manis Temminckii), South Africa ;
head $2\frac{1}{4}$ inches long.*

This young Pangolin was born in captivity in its native country, and died the next day (see Proc. Zool. Soc., 1878, pp. 632, 633). I am indebted to Dr. SCLATER for this very valuable specimen.

This type, like its neighbour the Aard-Vark (*Orycteropus*, next to be described), becomes very large and well developed before birth, and the skull promises, even then, the strength it ultimately attains to.

The lower view (Plate 12, fig. 6) shows the sutures and synchondroses very clearly, and the remarkable shape of this toothless skull.

The alinasal region (*al.n.*) in front of the premaxillaries (*px.*) is short, and but little seen in this aspect; the nostrils (*e.n.*) are now more lateral. The premaxillaries have recovered some strength and size, now; their marginal and palatine parts are stronger; between these the notch for the opening of JACOBSON'S organ is rounded. The maxillaries (*mx.*) soon expand into broad shoulders, laterally, after which the general convexity of the outline of the skull only lessens slightly, a little behind the junction of the maxillaries with the frontals (*f.*), and, again, behind the auditory capsules, where the occipital cincture retains its great similarity to the skeletal segments that follow it. The alveolar ridge is now a sharp balk between the general convexity of the upper face, and the general concavity of the hard palate, which is imperfectly developed, but in a manner very different from what we see in Marsupials and

Insectivores, where this floor fills in well, at first, and then suffers large absorption in the part where the maxillaries and palatines join. If we compare this with the two previous stages, and with the adult, we shall see that there is a steady attempt to pass from the normal primary schizognathous condition to the normal secondary desmognathous state, and that in this curious toothless type the latter is never attained to—it comes short of the mark of the high and perfect Mammalian hard palate.*

Only in the hinder third do the concave palatine plates of the maxillaries approximate, and then not perfectly; in the front third they fail to hide the palatine spikes of the premaxillaries which run, as a wedge, far into the angle formed by those bones. In the middle third they are divided by the protruding ridge on the fore part of the vomer. The scooped part of the maxillaries inside the sharp alveolar edge is twice as large as the second and still more scooped part near the mid-line; where the bones nearly meet behind their thin edge is thickened. That thickened edge ends in a point, and the corresponding palatine sends its pointed fore end between that point and the outer flange of the bone which runs backwards and outwards. The outline of the maxillary is then notched, then bulbous, and is then obliquely cut away, where it articulates with the frontal; the infraorbital foramen (V^2 .) has but a small bridge under it, but from it there runs a considerable fossa upwards and forwards. Behind the bridge the jugal process is very stunted.

On each side of the vomer, the maxillaries are most concave; that bone (v .) is thick and split at its fore end. This exposed part is of great interest to the morphologist; it corresponds with the enlarged dentigerous fore end of the bone in osseous Fishes, which in their extreme specialization have acquired a median vomer; and also with the flat infero-anterior part of the vomer of the Green Turtle (*Chelone viridis*) ('Challenger Series,' vol. i., Zool., plates 10 and 11); and of certain Birds, *e.g.*, *Falco*, *Dicholophus* (Trans. Linn. Soc., ser. 2, Zool., vol. i., plate 24). Odd enough, one of the strongest and most perfectly specialized of the skulls of the Eutheria—that of the *Cat*—shows a trace of this very plate, where the maxillaries fail to meet in the hard palate.

The palatines (pa .) form a squarish tract; they make about one-third of the hard palate, which ends with them; and, indeed, they fail to produce the plate in their hinder fourth, and the hind margin of the hard palate is cut away in a crescentic manner. The submarginal groove of the maxillary palatine plate runs on under the palatine, but soon turns outwards and is lost. The palatines form one-third of the wall of the great nasopalatine canal behind, and the pterygoids (pg .) two-thirds; these bones, like the palatines, have a broad basicranial flange, and this upper dilatation of these vertical bones overlaps the basioccipital. The wall or vertical part is deeply notched behind, and thus the hamular process (see also fig. 8, pg .) is large and free.

* To me this seems to suggest that whilst the Pangolin has suffered degeneration and relapse, as it were, as regards the teeth, and with the teeth the size and fulness of the jaws, yet that this abortion and suppression began when the type itself was very low, and only very imperfectly desmognathous.

The whole series of palatine bones in this scarcely perfect hard palate is a narrow, oblong tract, with the sides gently bowed out, and the ends gently converging. Opposite the end of the hard palate the fronto-squamosal suture, which is very large (see fig. 8), runs across, and the strong, concave orbital plate of the frontal takes up all the orbital space here, except at the inner edge.

There we see part of the orbitosphenoid (*o.s.*) notched at its anterior margin where the ophthalmic nerve (V^1) is re-entering the skull through the orbital foramen. The optic passage (*II.*) is out of sight; but the sphenoidal fissure ($V^{1,2}$) comes into view, followed by the deeply notched, oblong alisphenoid (*al.s.*), notched deeply in the middle of its outer margin by the 3rd branch of the 5th nerve (V^3); it does not finish the foramen ovale, and emerges far in front of the auditory capsule (*chl.*). Those wings and these capsules are both walled in, externally, by the huge squamosals (*sq.*) that have pushed the parietals away from their frontal attachment, below (see fig. 8), and continue the general ovoidal convexity of the skull up to the paroccipital prominence (*e.o.*). Each bone has a pneumatic cavity opening behind the stunted zygomatic process (see also Plate 13, fig. 1—for $\times 2$, read $\times 3$), with its oval glenoid facet, which reaches, in this specimen, nearly to the fore end of this arrested process. Then the whole lower part of the bone in the postglenoid region is hollowed out to form an upper chamber to the “cavum tympani;” hence the great convexity of the squamosal in its hinder half (see also fig. 8). The whole line of junction of this great bony scale with the infero-lateral parts of the hind skull is well worthy of remark (Plate 12, fig. 6, and Plate 13, fig. 1). A strong flange from the glenoid region, inside the postglenoid pneumatic foramen (*p.n.f.*), binds on to the outer edge of the alisphenoid, running in with an angular process to complete the imperfect foramen ovale (V^3) and then, after leaving the hinder half of the alisphenoid, clamping the antero-external margin of the auditory capsule (*chl.*). Here this “flange” becomes scooped and runs upwards until it ends in the general hollowing of the bone above the tympanic cavity. In its hinder part the bone strongly closes in under its own pneumatic cavity and interdigitates with the rough, grooved opisthotic, and the small epihyal bridge (*op., e.hy.*).*

Since the last stage (Plate 11, fig. 8, *p.s.*) the presphenoidal region has become bony and the bar (Plate 12, fig. 6, *p.s.*) looks like that next behind it (*b.s.*), but I strongly question the *independence* of it, as an ossification; it was most probably formed by the confluence of the orbitosphenoids in the middle cartilage.

The next basal piece, the basisphenoid (*b.s.*) is an independent centre; it is oblong, nearly as long as the broad (*reptilian*) basioccipital, and is separated by a moderate tract of cartilage from the other two basal bony plates. In this species there is, now, a small pituitary hole (*py.*) at the front third of this flat bone. The huge oval basioccipital, behind it, is everywhere surrounded by cartilage except where it binds

* I am satisfied that anyone wishful to compare the skull of an adult Pangolin with that of any high *normal* Mammal, will not complain of these details, nor make light of the pains I have taken to pull this puzzle to pieces to get at its meaning.

against the cochleæ (*chl.*), and behind; there it has thick-ribbed edges, which make the middle part of the bone concave; this is like what is seen in the Unau (Plate 9, fig. 1); this is shown still more where these ridges are *functional*, as in the Anteater (Plate 10, fig. 1).*

The oval basioccipital (*b.o.*) is notched a little where it forms the front boundary of the foramen magnum (*f.m.*); on each side of that end the large occipital condyles are seen (*oc.c.*); their direction is infero-posterior. The exoccipitals (*e.o.*) run well outwards to the grooved and rough opisthotic (*op.*), which is wedged in between the squamosal and the gently convex paroccipital ridge.

The large hypoglossal (condyloid) foramen (XII.) is partly finished inside by cartilage, and the exoccipital bone only partially surrounds that nerve and the 9th and 10th (IX., X.) at their exit; the cartilage here is half as broad as the bone outside it. The bony tracts seen in the distance behind the foramen magnum are not parts of the supraoccipital but an extension of the lateral bones (see also fig. 9, *e.o.*, *s.o.*) The moderately broad annulus tympanicus has been left *in situ* on the left side (Plate 12, fig. 6, *a.ty.*); on the right side of the skull this bone and the ossicles were removed (see also Plate 13, fig. 1). This imperfect ring has doubled its breadth since the last stage (Plate 11, fig. 8), but it fails to run along the meatus externus, and leaves the large membrana tympani exposed in this view.

The well and roughly ossified auditory capsule (Plate 12, fig. 6; and Plate 13, fig. 1, *chl.*, *op.*) runs obliquely inwards and forwards, warty, as it were, and riddled with holes and passages. The facial nerve (VII.) runs through a bony canal, and appears on the roof of the tegmen tympani to escape again through the stylo-mastoid foramen, which is bridged over by the small confluent epihyal (*e.hy.*) (see also Plate 11, fig. 8, *e.hy.*, VII.), which has become confluent at its once free end with the highly ossified capsule, behind the *obliquely seen* fenestra rotunda (*f.r.*). Another small bridge of bone at right angles with the inner end of the epihyal bridge separates the fenestra rotunda from the fenestra ovalis (*fs.o.*). In front, the ossified wall of the cochlea (*chl.*) fits into digitations of the alisphenoid (*al.s.*) by knobs of bone; and, behind the stylomastoid foramen (VII.), the opisthotic region, is divided into two rough convexities by a considerable groove. On the inner face, where the cochlear and opisthotic regions unite, there the bony mass is notched twice, to let out the 9th and 10th cranial nerves (IX., X.).

The pyriform shape is well seen in the *upper view* of the skull (Plate 12, fig. 7). The snout (*al.n.*) is twice as much seen here as in the lower view (fig. 6). The only additional parts that come into view as compared with the last stage (fig. 1) are the squamosals (*sq.*) that can be just seen flanking the parietals (*p.*). The pre-maxillaries (*px.*) are seen in front, and the maxillaries (*mx.*) can also be seen flanking the frontals (*f.*); the partly ossified supraoccipital (*s.o.*) finishes the structure behind. The still-notched, but improved, nasals (*n.*) run well back between the frontals,

* This character reappears in normal tooth-bearing Mammals, *e.g.*, in the Marmot (*Arctomys monax*).

which pinch in very little over the orbits, and cover as much surface above as the parietals (*p.*), for what they lack in breadth they gain in length. The sutures are now well finished and dentate, the lambdoidal takes an arcuate turn forwards, in the middle, and retreats at the sides, where the parietals are only flanked by the unossified margins of the supraoccipital plane.

The *side view* (Plate 12, fig. 8) shows well the feebleness of the short straight face, and the fruit-like roundness and general convexity of the skull, proper, to which no thick-bellied muscles are attached, and over which a strong horny helmet has grown.

A thin wedge of bone, the facial part of the premaxillary (*px.*), runs its point between the nasal (*n.*) and the maxillary (*mx.*), above; this is bounded in front by the snout, with its crescentic fold over the almost lateral nostril (*en.*). The square-topped maxillary takes up much of the outer edge of the nasal, and then runs downwards and backwards, where the lacrymal should be, and barely covers the nasal capsule. The antorbital, as well as the lower edge, is thick, and the infraorbital foramen and fossa (*V².*) are seen in front of the round, stunted rough zygomatic process in which, in this specimen, I can find no distinct rudiment of a jugal bone. A small vascular foramen is seen above the main passage (*V².*) in the hind margin of the fossa. The supraorbital part of the frontal ends below in an arcuate line, which is roughly semi-circular, and straightish in the middle; the orbital plate is most hollow, almost angular, where it runs downwards to the orbital foramen for the re-entrance of the 1st branch of the 5th nerve (*V¹.*). The lower edge of the orbital plate ends in a line parallel with its upper edge; in the notch the orbitosphenoid (*o.s.*) is seen, and the oblique, but large, optic hole (*II.*). Below the frontal, and behind the maxillary, the palatine (*pa.*) is seen edgewise as it runs upwards to form its basicranial flange, and forwards to assist the maxillaries and frontals to finish the antorbital wall. This is done imperfectly, and a considerable lanceolate cartilaginous "pars plana" is to be seen between the maxillary and the palatine. At the fore end of that tract I have looked in vain to find a lacrymal foramen. The 2nd branch of the 5th nerve (*V².*) strongly grooves the outer face of the palatine on its journey from the sphenoidal fissure to the infraorbital canal.

Most of the hind-skull, as seen in this view, is composed of two nearly equal tracts of bone, the parietal and squamosal (*p., sq.*). The coronal suture ends on the highest angle of the squamosal, which is not scooped out to form any definite temporal fossa, all the space answering to that valley is to be seen in that part of the squamosal which has caught the notched hinder margin of the frontal. This is made into a small space for the temporal muscle by the ridge which runs down to form the stunted zygomatic process, in the infero-internal face of which the glenoid facet lies. Behind this ridge is the pneumatic foramen (*pn.f.*), then a gentle hollow, and then the general convexity over the large air cavity that forms the chamber over the *cavum tympani*. The hamular process of the pterygoid (*pg.*) and the annulus (*a.ty.*) are just to be seen, away from the eye, below, and the margin of the occipital plane, behind. A gentle concavity is seen between the external or paroccipital edge of the exocci-

pital (*e.o.*), and the thickened rim formed by it to the foramen magnum. The bony and cartilaginous parts of the supraoccipital are just seen, and also the condyle (*oc.c.*), below.

The lower jaw (Plate 12, figs. 8, 10, 11, *d.*) is a mere sinuous bar of bone, capped at its posterior-superior part by a condyloid facet, in front of which a slight elevation is all that appears of the coronoid process (*cr.p.*), and under which there is no angular process, whatever. The symphyseal face is oval and rough, and the dentary edge is sharp and roughly dentated; between that part and the aborted coronoid process the upper outline sinks into a gentle curve, answering to the convex outline below. Inside the hind part of the ramus the bone is scooped away for MECKEL'S cartilage and the burrowing nerve (V^3), and vessels. The secondary mandible is now one-fourth larger than the primary, for the fore part of MECKEL'S cartilage (*mk.*) is lost, and the rest is a sinuous rod partly in front of and partly behind the persistent ramus. This sub-proximal part of the primary rod is only attached to the ramus in front of the bony processus gracilis, behind, by ligamentous fibres. The proximal part, now the ossified malleus (*ml.*), is quite normal, with the curved manubrium (*m.ml.*) and is equal to the processus gracilis. The incus (*i.*) is now quite ossified, and its short crus is relatively larger. The stapes (figs. 11 and 12, *st.*) is still merely a columella, with a ragged hinder margin to its flat rugous stem, and a small interhyal in the tendon of the stapedius muscle (*i.hy., st.m.*).

In this species, at this stage, there is a small second upper ceratohyal (fig. 13, *c.hy.*), and the rest of the bar (*c.hy.*) is ossified in its middle part; the basal bar, with its horns (*b.h.br., t.hy.*) is still unossified; its shape has not changed since the last stage.

The occipital region, as seen from behind (Plate 12, fig. 9), shows great progress in ossification since the last stage (fig. 2); and in this more finished ovoid the superficial bones (*sq., p.*) come more into view in this aspect. The notch above the foramen magnum (*s.o.n.*) is as large here, as in the smallest specimen (Plate 11, fig. 4), the lateral cartilaginous tracts failing here for some distance. The three bones that are forming this face of the skull (*s.o., e.o.*) are still separated by a considerable amount of cartilage. The basal bone (*b.o.*) just comes into view. The paroccipital margin (*p.oc.*) of the lateral bones (*e.o.*) forms a definite ridge on each side, separated from the condyle (*oc.c.*) by a gentle vacuity.

Fourth Stage.—Skull of adult Pangolin. (Manis — ? sp.).

Some things worthy of notice appear in the skull as it becomes adult. In the *lower view* of the adult skull, with the hinder part removed (Plate 13, fig. 2), we see the strength of the roof-bones, and that they are strongly marked, inside, by the brain; these *digital impressions* of the inner table are very clear. So also is the bony tentorium (*t.tm.*) strong, and strongly fixed to the supraoccipital (*s.o.*) as its key-stone; outside that ingrowth the great tympanic recess in the squamosal (*sq.*) is laid bare. In front of this the postglenoid pneumatic foramen (*pn.f.*) is seen, and in

front of it the strong stunted zygomatic process with its small oval, glenoid facet (*gl.f.*) on its inner face in front. The basisphenoid (*b.s.*) was cut across near its front margin, and only part of the alisphenoids are shown—just to the *notch* for the 3rd branch of the 5th nerve (V^3). Then we see the sphenoidal fissure between the two wings ($V^1, 2$); the optic foramen (II.), the orbital foramen (V^1), and the orbital tunnel (V^2).

The palate is much like that of the newly born specimen (Plate 12, fig. 6), but the palatines (*pa.*) are relatively longer, the *palatal* portion of the hard palate being nearly as long as that of the maxillary (*mx.*), which is very imperfect in front, and shows the long (*borrowed*) palatine processes of the premaxillaries (*px.*), and the forked antero-inferior part of the vomer (*v.*). The alveolar flange of the maxillary (*mx.*) is perforated in two or three places, and the right palatine has lost its bony floor in one place, just as in Marsupials and some Insectivores, but not to the same extent. A small seed-like jugal (*j.*) is now to be seen on the angle of the maxillary—its jugal process—but there is no lacrymal, and the place where that bone and the bony “*pars plana*” should be seen is merely an enlargement of the very open suture—like a mere *crack*—which runs, above, between the frontal and maxillary, and then, below, between these two bones and the palatine, where it rises into the floor of the orbit, in front.

The *hind view* of the fore skull (Plate 13, fig. 3) shows the strength of the frontal cincture, the concavities (“digital impressions”) of the inner table, the enormous size of the ethmoid with its cribriform plate (*cr.p.*), and the strength and depth of the “*crista galli*” (*cr.g.*). The optic foramina (II.) are surrounded by bone, and the whole anterior sphenoid (*o.s.*) is about equal to that of *Man*—relatively to its size. The sphenoidal fissures ($V^1, 2$) are large oval passages, and the nasopalatine canal (*n.p.c.*) is large and subcircular. The manner in which the squamosal grow downwards to form the hollow zygomatic processes is also seen in this view, and the thinness of the floor of the sella turcica (*l.s., read b.s.*). The pterygoids (*pg.*) are anchylosed, to a great degree, to the posterior sphenoid.

A *front view* of the nasal end of the dry skull shows that the septum nasi (fig. 4, *s.n.*) in front of the vertical ethmoid is unossified, but that the nasal and inferior turbinals (*n.tb., i.tb.*) are quite bony, and anchylosed to the nasals (*n.*), in one case, and to the maxillaries (*mx.*), in the other.

ORYCTEROPODIDÆ.

Nearly ripe embryo of Aard-Vark, Orycteropus capensis (Plates 14, 15).

Here, if anywhere, we have a generalized type, evidently very archaic. Figures of the adult suggest the idea that this is an ancient, primordial, unarmed Armadillo.*

* The figures (Plate 1, figs. 9–11) given of the head in this nearly ripe embryo (belonging to the Museum of the Royal College of Surgeons) are suggestive of the new-born young of several types of

I have, moreover, to begin the description of this type of skull under an impression, which I believe is not prejudiced, that *Orycteropus* comes nearer the Marsupials and the lower Insectivores, and is further from the Monotremes, than the other Old World Edentates—the Pangolins. The whole of the New World Edentates, whether toothless, or with an imperfect dentition, appear to be like the Pangolins, upgrowths from the Monotremes.

Unfortunately, I cannot bring the evidence for these views forward, now; but the papers on the skull of the Insectivora and Marsupialia will follow, next, upon the present.

The complex structure displayed in the lower view (Plate 14, fig. 1), if traced out point by point, will show how much unlikeness there is between the only two remaining types of Old World Edentates. The face is long, the measurement, even now, of the base shows the tract in front of the fore margin of the presphenoidal territory to be twice the extent of the tract behind that point. Here the development of the jaws hardly suggests any change from that of the ordinary typical Mammals, with their well-developed sets of teeth, all round. The alinasal cartilages and nostrils (*al.n.*, *e.n.*) are very peculiar, and quite unlike what I have lately been describing.

Here the nostrils are anterior, and the intervening alæ, after spreading out into projecting folds and processes, suddenly narrow in, and then project again right and left, the projection being caused by a peculiar and large narial valve (*n.v.*). A deep fissure—not a solution of continuity of the cartilage—runs across, below, arching backwards a little in front of the premaxillaries (*px.*); and a median groove runs forward from this part to the end of the snout, the converging folds of the floor in this front part being elegantly crescentic—back to back. The part behind the transverse arched groove soon opens out, right and left, where it gives off the recurrent cartilages (fig. 5, *rc.c.*); I shall describe these parts soon.

In this developing skull there is a palatal character seen at once, which is permanent in the curiously arrested skull of the Pangolin, this is the imperfect desmognathism of the palate, in front, exposing the vomer (*v.*). As to the character of the bones covering the endocranium, they are very unlike those of Armadillos, Sloths and Pangolins, not thick and cellular, but thin and fibrous, very much like those of the Insectivora. The premaxillaries (*px.*) have retained their normal size, notwithstanding their loss of teeth; the alveolar edge is a thick tract, with a lanceolate outline, and

higher Mammalia, *e.g.*, *Lamb*, *Calf*, &c.; but on my first, and very casual, look at the British Museum spirit-specimen, of the same age as this, I mistook it for the young, from the pouch, of some large kind of *Kangaroo*.

The head, only, of this single stage, as worked out here, will be fruitful of suggestions of relationship, which point to quite other quarters than those just mentioned, which are, manifestly, somewhat fanciful.

There are two species of this isolated, unique genus, namely, *O. capensis* and *O. æthiopicus*—(see Proc. Zool. Soc., 1869, p. 431, and 1870, p. 669; also "List" of the animals of Zool. Soc. 1883, p. 192, fig. 35, and p. 193, fig. 36). The differences between these two, external and internal, are not great, but are worthy of note.

it is separated from the palatine process by a deepish concavity; the two processes reach backwards about the same extent. The re-entering angle between the two processes is rounded for the opening of JACOBSON'S organ (see also fig. 5, *j.o.*), and the wedge-like end of the maxillary (*mx.*) reaches up to this passage.

The maxillaries are nearly half as long as the whole basal line, from the fore end of the snout to the foramen magnum, and their alveolar tract is really large, behind, where the two last teeth, with their subdivided pulps, take on somewhat of a *Zeuglodontic* character.

The first of the simpler front teeth—there are five, in all, at this stage—would answer to the second or third premolar, of a Hedgehog or a Mole; all those that should be in front of this part are suppressed, and yet the jaw-bones have suffered but little by this suppression.

The palatine plates of the maxillaries certainly do resemble those of the Armadillos (see Plate 2, fig. 2), for inside the steep alveolar wall the great palatine flange, at first scooped, rises into a ridge, and is then separated by another concave and grooved tract from the lesser submesial tract of bone. This tract is deficient, both before and behind; in front it lets us see the fore part of the main vomer (*v.*) and the small front paired vomers (*v.*', see also fig. 5). The main part of the maxillaries ends a little in front of the palatine end (*pa.*) of the hard palate, but at present the last alveolus is not walled in. The shoulder of the maxillary, its jugal region, extends outwards nearly as far as any part of the skull, the only wider part is the glenoid region (*gl.f.*). The infraorbital canal (*V*².) is one-fourth the length of the maxillary, and its opening in front is infero-lateral.

The total length of the palatines (*pa.*) is half that of the maxillaries, but they form less than one-third of the hard palate; that tract runs in between that of the maxillaries, leaving those bones only a narrow flange, there, inside the inner alveolar wall. The two plates do not meet well together, especially in front, and each forms, in this part, a rounded leafy plate of bone, fitting against a large, rounded notch on the inner angle of each maxillary plate.

The margin of each palatine, behind, is rounded, and has a strong rim, which is distinct from the thickened outer rim of the bone at its articulation with the end of the maxillary. Under that outer rim, which forms a bridge, there is a large oblique oval passage, or subway, and from it, in front, a groove runs forwards, along the outer third of the flat plate. The unfloored part of each palatine is only two-thirds as long as that which helps to form the hard palate; it is thick-edged below, and that edge does not project so far outwards as the hinder rim of the completer part; above, it is oblique, with a shortened upper margin, to which there is scarcely any basicranial flange.

The pterygoids (behind *pa.*) continue the wall to the nasopalatine canal, they are as long as the palatines, and have a broader basicranial flange, which runs backwards, and is emarginate in front of the Eustachean opening (*eu.*). The short thick hamular

process is but little free at its end (see also fig. 3., *pg.*) ; the fore part of each bone, above, runs inwards over the palatines and the two bones are toothed where their thin edges touch.

Outside these bones, we see, in the distance, the orbital plate of the frontal (*f.*) with its large vascular hole, and at the margin of this space the jugal (*j.*), a considerable bone, broadened out where it overlaps the maxillary. It is, in turn, overlapped by the squamosal (*sq.*), whose jugal process passes a short distance beyond the jugal, and then, on its inside, at its root, we see the rather large glenoid facet (*gl.f.*) which is oval, the long axis forwards, but the fore part emarginate, having there a deep rounded notch.

The squamosal can be seen a little in front of the glenoid cartilage ; laterally, it runs from its jugal process, backwards, until we see it, after forming four gentle convexities and slightly converging, lie over the auditory capsule, ending beyond the stylomastoid foramen (VII.).

The thickened postglenoid edge is separated from the beginning of the hollow, and somewhat pneumatic, part that covers the tegmen tympani. The inner margin is scooped, thin, and then thickens again before it ends as a scaly tract over the swelling in the ear capsule caused by the horizontal semicircular canal (see fig. 3, *h.s.c.*).

Another superficial bone is seen inside the squamosal ; this is the tympanic (*a.ty.*), it is a thinnish U-shaped tract, with a foot-shaped flange, in front, for protection of the processus gracilis of the malleus. This imperfect ring leaves a large space of the auditory capsule only covered by membrane on its inner side, and the rim of the bone lies a good distance behind the Eustachian opening (*eu.*). The membrana tympani (*m.ty.*) is much exposed, and the unossified manubrium (*m.ml.*) is seen running obliquely across it.

The proximal, ossified part of the orbitosphenoid (*o.s.*), can be seen in the fundus of the orbit, with the optic nerve (II.) running through, and the maxillary nerve (*V².*) behind, it. A considerable tract of each alisphenoid (*al.s.*) is seen between the pterygoid and squamosal (*sq.*), and the large inferior branch of the 5th nerve (*V³.*) passes through a very large foramen ovale, which lies in the centre of the plate, but which is not quite bound in with bone on the outside.

The large median beam, with the presphenoidal region unossified, the basisphenoidal centre (*b.s.*), the basioccipital, and the whole occipital cincture will be described soon, as parts of the separated endocranium (Plate 15, figs. 1, 2). There is in this figure a small scale of bone seen in front of the stylo-mastoid foramen, and on the proximal part of the epihyal cartilage (*e.hy.*) ; this is the proper *parosteal* stylohyal bone (*st.h.*), answering to that of Man, and of the Rabbit.*

I have not found this superficial ossicle in any other kind of Edentate, and

* PROFESSOR FLOWER'S "tympano-hyal" answers in a general way to this bone, but it lies deeper, and soon forms the *ectosteal* plate of a small patch of bone which is added to the "opisthotic," but belongs to the proximal part of the hyoid arch, where it has become confluent with the capsule.

therefore must add it to the list of characters in which this type comes nearer to the *normal Mammal* than its congeners.

The *upper view* of the cranium (Plate 14, fig. 2) shows, in front, the remarkable form of the snout, the roof of which suddenly pinches in, in front, after dilating as suddenly on emerging from beneath the nasal bones (*n.*). The roof (*al.n.*) ends in front, like the nib of a pen, and the sides are swollen, and then scooped away in a crescentic manner, making the nostrils look forward. Close beneath this expanded front lies the root of the curious long twisted narial valve (*n.v.*, fig. 3) which projects in front, right and left of the contracted fore end of the snout.

The difference between the general outline of this skull, and that of a nearly ripe *Tatusia hybrida*, is considerable; moreover, although larger relatively at the time of birth, it is not nearly so much developed (compare Plate 14 with Plate 6).

The Edentate diminution of the jaws is much less than in the Tatou; indeed, the skull is fairly intermediate between the skull of that kind of Armadillo and that of a large and important Insectivore from the East Coast of Africa, namely, *Rhyncocyon*—a type to be described in my next paper.

In both these nearly mature embryos the basifacial length is twice that of the basicranial, the point taken being that where the vertical ethmoidal and the presphenoidal regions meet. But the Aard-Vark's head is much the longer and narrower of the two—more like that of an Anteater, in this respect, and yet more like the skull of an Insectivore than that of any of the Myrmecophagidæ. Looking at the main roof bones the nasals are now only one-tenth shorter than the frontals and are one-tenth longer than the parietals (*n.*, *f.*, *p.*). This is a very different proportion to what we see in *Tatusia*, and yet the general form is very similar, for the frontals have to swell and broaden over huge ethmoidal masses in both cases (Plate 15, figs. 1, 2; and Plate 5, fig. 1). Thus, in both cases, the antorbital and postorbital regions are of equal breadth, except in so far as the latter is widened by the squamosals in the glenoid region. The general frontal convexity seen in *Tatusia* (Plate 6, fig. 2), and still more in *Dasypus* (Plate 7, fig. 2), is exchanged in *Orycteropus* for a considerable median hollowing of the roof, which affects even the hinder part of the nasal bones. So that, as we shall see in the next figure (3), there is a very peculiar "beetling" of the brow in this type, the convexity of the frontals being only lateral and not general. But the skull rises well in the coronal region; yet there, at present, it is unfinished, a large diamond-shaped fontanelle (*fö.*) still persisting. Here we gain that which the Armadillos are deficient in, namely, a good postorbital process to the frontal bone, as the end of a good, clean, well arched supraorbital rim. That ridge and process is very short and abortive even in the Unau (Plate 9), which has also some suprafrontal hollowing, but in *Cycloturus*, *Tatusia*, *Dasypus*, and *Manis*, all this is absent.*

* We shall see this *Echidnine* feebleness of the skull in many of the Insectivora, also, so that this imperfection of the orbit must not be taken as a necessary correlate of the suppression or abortive

Here the nasals (*n.*), narrowing steadily forwards, have their edge cut away from without, inwards, and not notched as in *Manis*. The upper part of the facial plate of the premaxillaries and maxillaries (*px.*, *mx.*) can just be seen, and also the lacrymal; (see fig. 3, *l.*) under and outside the well-formed orbital rim, the jugal (*j.*) can be seen, and behind it the most projecting part of each squamosal (*sq.*).

The front two-thirds of the frontal suture, and the hinder third of the sagittal, are complete; behind the latter, the temporal fossa is evidently gaining somewhat upon the postero-external part of each parietal. The lambdoidal suture is in two limbs, as it were, in front, running forwards in the middle, and backwards, behind, between the two parietals and the one large, wide, bracket-shaped intraparietal (*i.p.*); and behind, having a similar curve, and separating the intraparietal from the projecting endoskeletal supraoccipital (*s.o.*). Outside the latter this plane is unossified, and part of the projection is opisthotic, the swelling caused by the posterior canal being just caught by the eye.

The *side view* (Plate 14, fig. 3) shows many things well, that are only partly visible in the other aspects.

In front, the curious snout, with its alæ, valve, and opening (*al.n.*, *n.v.*, *e.n.*), are shown, and these are followed by the oval face-plate of the premaxillary (*px.*) with its pedate lateral enlargement, below. The remaining three-fourths of the alveolar edge belongs to the maxillary (*mx.*), but the foremost third is edentulous. Surmounted by the long nasal (*n.*) this bone forms most of the side of the large, long face; its upper margin ascends, at first gently, and then suddenly, its lower edge descends gently and sinuously back to the jugal (*j.*). The highest part contributes to the bony investment of the swelling ethmoidal mass (*al.e.*) which it fails to cover, not meeting the frontal (*f.*) at that part.

The hinder half of that preorbital tract is, however, covered by bone, but not by either of these; the lacrymal (*l.*) comes in here as an antorbital wedge. It is a pyriform bone about the size of the face-plate of the premaxillary, has a straightish edge above, against the frontal, but dips into the maxillary below. The large canal is behind this rounded lobe; then the bone flattens inwards to form a small orbital plate, and thickens, below, where it places a solid foot upon the fore part of the jugal.

The hind part of the maxillary, the direction of which is forwards and upwards, is scooped for the broad overlapping fore end of the jugal (*j.*), so that the zygomatic part of the maxillary is almost half its hind border; this is burrowed by the upper maxillary nerve, which comes out at a moderate distance from the jugal, at the infra-orbital foramen (*V²*). Thence, forwards, the face-plate of the maxillary is grooved twice—under the great swelling, and just above the alveolar margin; a vascular foramen is seen in front of the great nerve passage, in this lower groove.

development of the teeth. *Rhynocoyon* and *Orycteropus* come very near each other in this character; the former, indeed, lies, in this respect, between the Shrews and Moles on the one hand, and the *almost* Lemurine *Tupaia* on the other.

Here the form of the frontal is well seen, and can be compared with the same view in the *Tatou* (Plate 6, fig. 3). Here the swelling in front of and above the orbit makes the skull at this part almost as bulky as it is in the region of the upper fontanelle (*fo.*), and in this side view the frontal seems to be made of two parts, separated by a deep, oblique valley. The supraorbital ridge does not extend so far backwards as the wall-plate of the bone, which runs back there, and notches the fore edge of the parietal, on the lower part of the coronal suture. Thus the parietal is of a more normal size, and the squamosal does not dominate this part of the skull as in Pangolins and Sloths.

Below the notch, the parietal (*p.*) forms a round lobe which rests upon both the cartilaginous top of the orbitosphenoid (*o.s.*), and the wholly ossified alisphenoid (*al.s.*), and further back it forms the upper part of the temporal fossa, its whole lower edge being somewhat concave, and the outline both there and behind is somewhat emarginate, to receive the arched margin of the squamosal and intraparietal (*i.p.*). The latter bone is about one-third the size of the parietal, and it reaches back over the outer edge of the unossified part of the occipital plane.

The squamosal (*sq.*) is quite normal, it is much smaller than that of a Sloth or Pangolin, and much larger than that of *Cycloturus*.

The temporal squama has an arched upper edge; the hind margin of the bone is broad and emarginate; the outer face is moderately convex for a moderate pneumatic cavity over the drum cavity, and both there, where the glenoid cartilage (*gl.f.*) has grown on to it, the margin is notched; the zygomatic spur is well developed.

From the peculiar manner in which the overlappings, or imbrications, of the parts that form the inner wall of the orbit are developed, the mind at once refers to the skull of the Insectivora. The orbital plate of the frontal (*f.*) is a thin hollow shell of bone, the hind margin of which is one large crescentic notch, inside which a semicircular tract of the semiosseous orbitosphenoid is exposed; the optic nerve (II.) escapes through the proximal part of the bony base of this tract, and the ophthalmic nerve (*V*¹.) re-enters the skull near the junction of the bone and cartilage in that plate. The rounded corners of both the frontal and parietal bones overlap the cartilage postero-superiorly, and, behind, its cartilaginous part is notched in the same crescentic manner as the orbital plate of the frontal, and is then overlapped by the semicircular fore edge of the alisphenoid (*al.s.*), which round edge is nearly parallel with the hind margin of the orbital plate of the frontal. This outstanding fore edge of the alisphenoid forms the *hinder* boundary of the sphenoidal fissure (*V*¹, ².); its *inner* boundary is formed by the orbitosphenoid (*o.s.*). The palatine (*pa.*) crops up in the antero-inferior part of the orbit; the pterygoid (*pg.*) can be seen below the jugal arch. Below the tegmental notch of the squamosal the tympanic (*a.ty.*) and manubrium can just be seen. The supraoccipital bone (*s.o.*) bends down behind the intraparietals, behind which the thick wide convex unossified part is seen. Behind the lower lobe of the end of the squamosal a small convexity is seen; this is formed by the hori-

zontal canal (*h.s.c.*); behind this the larger crescentic swelling is due to the posterior canal (*p.s.c.*). The exoccipitals (*e.o.*) margin the foramen magnum (see also fig. 4, *e.o.*); below, the occipital condyle (*oc.c.*) is shown, and outside this the low paroccipital ridge (*p.oc.*).

The facial nerve (VII.) is seen escaping below the horizontal and posterior canals where they meet, and in front of the nerve the epihyal (*e.hy.*), with its obliquely oblong splint, the stylohyal (*st.h.*). The cartilaginous bar is elbowed and enlarged; it then runs downwards and forwards into the upper ceratohyal (*c.hy.*) without segmentation. Then comes the lower ceratohyal half as long as the main bar, and then, less than half as long as the lower ceratohyal, the hypohyal (*h.hy.*). That little hillock of cartilage dilates to articulate with the fore part of the U-shaped basal bar (*b.h.br.*), a very regular semi-ellipse. The sides (or horns) of which are the continuous thyrohyals (*t.hy.*).

When the hyoid bar becomes segmented from the cranial part, then this will be quite a normal hyoid arch, except that the thyrohyals are continuous. But in the Edentata the hyoid arch is most variable, and that not only as to Families, but the genera *Dasypus* and *Tatusia* do not agree in the structure of this arch.

The smallness and imperfection of the teeth has given rise to a great reduction in the size and bulk of the fore part of the mandible; this is a much larger "ramus" than that of *Tatusia* (Plate 6, fig. 3), for the hind part is very large, the coronoid process (*cr.p.*) being of great extent and rather wide. The articular or condyloid part (*cd.p.*), with its oval condyle, runs downwards and forwards till it meets the overlapping thick part where the vessels and nerves enter. That thickening corresponds to the distinct coronoid bone of the Ovipara, and the gently convex inner wall of the ramus to the splenial bone. Below the foramen, the ramus forms a second lobe similar to the rounded angular process (*ag.p.*) behind.

The *end view* (Plate 14, fig. 4) shows the occipital plane, still largely unossified. The investing bones (*i.p.*, *p.*, *sq.*) can be seen overlapping the whole of this hind wall, and the auditory capsules (*op.*), swollen here with the posterior canal (*p.s.c.*), are seen planted into a deep oblique notch, right and left; below these the facial nerve (VII.) and the epihyal (*e.hy.*) come into view. The rest is occipital, and here we see, as a correlate of the development of the large intraparietal, a decrease in the size of the subcircular supraoccipital (*s.o.*); see also in *Tatusia* (Plate 6, fig. 4). By this we know that we are further from the Monotremes, and from the rest of the Edentata. A large sinuously transverse muscular ridge runs across this bone already, so that here, as in the temporal region and lower jaw, we see that we have to do with a strong and muscular animal. The subcircular foramen magnum (*f.m.*) has the outer part of its arch and upper half occupied by the rounded exoccipitals (*e.o.*); their depth, the depth of the cartilage between them and the supraoccipital centre, and the depth of the occipital condyles (*oc.c.*), are all nearly equal. Outside the condyles, the arch projects as a quite distinct, though not large, paroccipital ridge and process (*p.oc.*): a

good normal Mammalian character. The concave hind margin of the basioccipital (*b.o.*) is seen in the distance.

The ossicula auditûs (Plate 15, fig. 4) are, like those of the Armadillos (Plate 6, fig. 6 and 11; and Plate 7, fig. 6), intermediate between those of the more aberrant Edentates and those of ordinary Eutheria.

Already in this relatively, and really very large, embryo, these parts are well formed, and the rest of the primary jaw is gone. The *inner view* (Plate 15, fig. 4) shows a reniform sinuous condyle, on a large head, which is convex externally, and scooped on the inside. The large styliform processus gracilis (*p.gr.*) is a little longer than the styliform manubrium (*m.ml.*), which is still cartilaginous. DORAN's figure (*op. cit.*, Plate 64, fig. 14) shows a still smaller manubrium and a still larger processus gracilis, even in the adult.

The quite normal incus (*i.*) is ossified, but the stapes (*st.*) has its facet and neck still cartilaginous; in the adult (DORAN, *op. cit.*) the long crus of the incus has become slenderer and the hole through the *high* stapes somewhat larger, and more circular. I see no interhyal nucleus in the tendon of the stapedius muscle (*st.m.*). One more point may be noticed, namely, that the base of the stapes is convex, and projects inwards beyond the rim, as in the Mole (*Talpa europæa*), but not to the same extent.

In the *lower view* of the *peeled inner skull* (Plate 15, fig. 1), the eye is almost confused with the number of parts to be described. If these figures be compared with figures already given by me in other papers of the endocranium,—of Selachians (Trans. Zool. Soc., vol. x., plates 34–42), and of the larvæ of the Urodela and Anura (Phil. Trans., 1877, Plates 21–29; Phil. Trans., 1876, Plates 54–62; and *ibid.*, 1881, Plates 1–44; Linn. Trans., ser. 2., Zool., vol. ii., plates 14–21)—it will be seen that the interpretation of the Mammalian skull is no easy task. But there lie, *obliquely between* this marvellously specialized skull and the skull of the Ichthyopsida, the various kinds of skulls to be seen in the oviparous “Amniota,” or Sauropsida.

To see the meaning of what lies before me, here, in the skull of this somewhat abnormal, low Eutherian, I find it necessary to remember the structure of the skull in every division of the great groups just mentioned, that is in Serpents, Lizards, Tortoises, Crocodiles, and Birds.

But the best of all these is the Crocodile, an ancient type, and one on which the loss of parts by *degenerative specialization*, is much less than in the other Sauropsida, for the living members of those other groups are manifestly more modified than the Crocodile.*

This *lower view* (Plate 15, fig. 1) shows, behind the exposed part of the snout

* Now, and for the future, I must avoid the use of the term *Reptilian*, qualifying it by the prefix *quasi*,—for what is low in a Mammalian skull; if some Palæontologist were to stumble upon a fossil *Hypotherian* it would be a great gift of fortune, then one could use that term as an adjective. That such a type once existed I feel certain—as certain as that I myself have had a series of ancestors.

(*al.n.*, *e.n.*) already described, that the double nasal canal, after narrowing in a little, enlarges only gradually in the aliseptal region (*al.sp.*). But in the aliethmoidal (*al.e.*) or proper olfactory territory it widens out rapidly, and forms a large bulbous structure which reaches backwards to the anterior sphenoid (*o.s.*, *p.s.*). This broad end of the pyriform labyrinth is not finished by cartilage below, and the internasal *desmos* which binds side to side is the main vomer (*v.*). But the septal region, above the front half of the hard palate, and which is supplied by the ophthalmic or orbitonasal branch of the 5th nerve, is open, now that the lower bony floor has been removed. The thick base of the alinasal region behind the crescentic groove soon opens out, right and left, like curtains folded back, and the aliseptal wall behind the snout, for an extent which is half the length of the whole labyrinth, turns inwards very little below. This open part is divided into two lanceolate spaces by the septum nasi (above *v'*), and its grooved bony rest—the vomer (*v.*, see also Plate 14, fig. 5).

But the nasal canals are not open towards the hard palate more than by narrow chinks; for there are two pairs of folded cartilages in this general open space—two on each side—one, the internal, half the size of the other, the external, fold.

From above the inner part of the selvedge of the closed floor of the snout, close to the septum nasi, right and left, a rod of cartilage—the recurrent cartilage or the cartilage of JACOBSON'S organ—grows backwards, and before it passes inside the opening of that organ (*j.o.*) it sends a curling process half way round the front of the passage. The narrow stem, beyond the opening of the organ, soon expands, and then the cartilage becomes lanceolate, and ends opposite the middle of the outer coil, or inferior turbinal (*i.tb.*). Below, the recurrent cartilage is convex; seen from the side (Plate 15, fig. 3, *rc.c.*), it is seen to be scooped on its supero-external face. The inferior turbinal arises opposite the thickening part of the lesser tract; it also has the same lanceolate form with a convex under face, like the other, but is twice as large. This “maxillary,” or “inferior, turbinal” is not fixed by its fore end; its root is from the side; it is an ingrowth of the aliseptal wall (*al.sp.*). The thin lamina which grows inwards is concave below, it runs half-way across the gap in the floor towards the vomer, and then forms an upper and a lower secondary fold. These are coiled over from their common free face, like the leaflets of *Cycas revoluta*, but to a greater extent.

The nasal turbinals cannot be seen in this figure; they are similar in all the Edentata, and dip down from the cartilage that underlies the nasal bones, just as the inferior turbinals grow in from the cartilage that lines the maxillaries (see in *Tatusia*, Plate 3, figs. 9 and 10, *n.tb.*). In the figures just referred to, and in figures, soon to be described, of these parts in the Hedgehog, a free section of cartilage is seen right and left of the septum nasi (*s.n.*, *pc.c.*). They are a little displaced by the razor, and should lie nearer the base of the septum. This dissection of the nasal labyrinth of the Aard-Vark gave me the interpretation of those sections of the nose of *Tatusia* and *Erinaceus*.

The lanceolate form of the gap right and left of the septum (Plate 14, fig. 5, and

Plate 15, fig. 1) is finished on the inside in its hinder half, by a *precurrent* cartilage, which overlaps the recurrent tract (*pc.c.*, *rc.c.*). This stoutish rod, which ends in a point in front, is a direct ongrowth from the inner edge of the nasal floor, over which floor the copious folds of the so-called "middle turbinal" are to be found. Behind these precurrent spikes, the proper olfactory floor, formed by a large ingrowth of the aliethmoidal fold (*al.e.*), is a wide sinuous tract, convex towards the inside, and at the outside, but concave along the middle. This wide part is divided, by a renewal of the concavity, into two lobes, the inner of which lies on a lower plane than the outer, and reaches a little further back. The inner part of the inner lobe is hollowed out, the nasal floor running upwards, in a concave manner, to reach the vomer. The outer and higher lobe is rather uncinatè, hooking a little towards the orbitosphenoidal region; it is the lower face of the great lateral ethmoidal mass, seen *from above* in fig. 2.

The main median investing bone, the vomer (*v.*), and the small paired anterior bones (*v'*), were not peeled off with the rest of the superficial bones, when the preparation, here figured, was made. The large parosteal tract (*v.*) has been dominated by two very distinct endoskeletal structures, namely, the intertrabecula, and the floor of the double nasal labyrinth. This large, long vomer reaches by its hind forks as far as the labyrinth, whose halves it unites, below; in front, it runs nearly as far as to JACOBSON'S organ. It is cleft, behind, up to its middle, the cloven part having the keel divided, which has run back from the fore half. In the foremost part the bone is simply rounded, running thence to its grooved upper face, on which the front partition wall rests.

This very remarkable foliaceous vomer (Plate 14, fig. 5; Plate 15, figs. 1 and 3, *v.*) is roughly pointed in front; then at the beginning of its second third it gives off a narrow wing, right and left, and these wings widen up to the median slit; a little behind it they end. Overlapping them, another pair of wings arise, right and left, twice as wide, and then another pair wider still, which run on to the diverging end of the forks, behind; the left middle wing is perforated.

The vomer is pinched in under the first and last wing, which are thinnish, as is usual in the edges of the Mammalian vomer (Plate 15, fig. 3, *side view*); but the middle wing is a solid mass with an oval outline.

This lobe or wing did not peel away easily, like the other, as is usual with a parostosis in its relation to the underlying cartilage, but *had to be broken away*, there being no line sharply dividing the bone-cells from the cartilage-cells. Thus the vomer is here grafted on to each moiety of the cartilaginous nasal capsule at the inner edges of its floor, as in Passerine Birds.*

* See NITZSCH, article "Passerinæ," in ERSCH and GRÜBER'S 'Encyclopædie,' 1840; "Ueber die Familie der Passerinen," Zeits. für die gesammten Naturwiss., 1862; HUXLEY, Proc. Zool. Soc., April 11, 1867, pp. 450-454; and my papers on the *Ægithognathous* type of skull, Trans. Zool. Soc., vol. 9, plates 54-62, and vol. 10, plates 46-54: Trans. Linn. Soc., ser. 2, Zool. vol. i., plates 20, 21; and Monthly Micros. Journ., 1872, plates 34-39; and, *ibid.*, 1873, plates 8-10.

I may have missed this peculiar structure in some of my dissections ; this is the last skull at which I have worked—if so this character will not easily escape me again. It appears to me to be a *new* and *rare* thing, and one of many remarkable cases of the conformity of the Mammalian skull with what is to be found in the Oviparous types—high and low.

Afterwards, I have no doubt, the bony matter transforms still more cartilage, that bone soon becoming ankylosed with the ossified tracts of the rest of the lateral ethmoids. Whether “posterior paired vomers” appear or not I cannot say, possibly the hindmost lobes or wings of the main bone become distinct for a time, and then unite with the bone forming within, so as to complete the *compound desmognathism* of the Mammalian upper face.

The anterior paired vomers (*v'*.) are very small in this type ; they are club-shaped, convex below and towards the septum, and hollow towards JACOBSON'S organs, of which they are the bony correlates. They lie right and left, a little in front of the main vomer.

The skull proper is composed, now, of about equal parts of unossified and ossified cartilage. The anterior sphenoid shows no basal piece below ; the whole of the thick beam, from the basisphenoid (Plate 15, fig. 3, *p.s.*, *p.e.*, *s.n.*) to the end of the snout, being cartilaginous.

That beam shows lateral wings where it passes into the alisphenoids, but for the rest of its extent, as seen from below, it is simply convex, lessening forwards (Plate 15, figs. 1 and 3, *p.s.*, *s.n.*).

In this large embryo the orbitosphenoids (*o.s.*) have lost their ethmoidal and supra-auditory attachments, but the wide outer half is still unossified. Their rounded fore edge comes short of the retiring margin of the lateral ethmoids, only membrane flooring the front part of the cranial cavity there. The ear-shaped upper part of each orbitosphenoid runs backwards inside the alisphenoids (fig. 2), but the two broad wings of bone at the proximal part are in front of the alisphenoids, and these form the front boundary of the sphenoidal fissure, through which the 1st and 2nd branches of the 5th nerve (*V*^{1, 2}.) escape. The orbitosphenoidal bones are thick, below, fore and aft of the optic foramen (*II.*), and the front thickening nearly touches the vomerine fork on one side—the right in the figure—and overlaps it on the left, the concave margin of the bone fitting against the rounded inner lobe of the great nasal capsule. The hinder thickening of the bone, below, rests upon the ossified angle of the proximal part of the alisphenoid (*al.s.*).

The posterior sphenoid is about equal now to the anterior, which it imbricates, behind, clearing itself well, outwards, from the rest of the skull wall.

The bony basisphenoid (*b.s.*) occupies about three-fourths of its own territory ; the whole of this subpituitary part is thick and convex, showing no sign of the primary deficiency in the cartilaginous floor. The sides (*al.s.*) have united, already, with their keystone piece, but a groove below marks the old line of division

of the bony centres. The alæ are not ossified up to their root in front, but the bone reaches the front of the unfinished basisphenoid bone (*b.s.*); behind, they overlap it. The hollow under the junction of the base and alæ is the place where the pterygoids clamped the skull (Plate 14, fig. 1); here the alisphenoids are bevelled; beyond that part they are strongly convex, as they grow first outwards, and then upwards. All their three free edges are crescentically emarginate; the notch in front forms part of the wide sphenoidal fissure ($V^{1,2.}$); on the outside a suture is seen running from the concave edge to the large foramen ovale ($V^3.$). The alæ being measured fore and aft, is in the middle of the bone, but it comes near the outer edge. Here, again, we have that remarkable character of the alisphenoid which we have just seen in the Sloth, Pangolins, and in the genus *Dasypus* (Plate 7, fig. 1), but not in *Tatusia* (Plate 5, fig. 1), where the alisphenoid, freed from the general cranial wall of the chondrocranium, is slow in developing—see especially in *Manis* (Plate 11, fig. 1, *al.s.*)—and thus the huge trigeminal nerve sends its hindmost branch over the edge of the ala. Normally, the 3rd branch of the 5th notches this hind margin of the alæ (see in *Tatusia*, Plate 5, fig. 1, $V^3.$), the “foramen ovale” being completed afterwards by a postneural bar of bone. But in the Mole (*Talpa europæa*) it perforates the primary cartilage, and the 2nd branch does the same, so that in that type the “foramen rotundum” is also a primary foramen of the chondrocranium, and not a notch completed afterwards by a bony bar.*

The large outer and hinder lobe of the alisphenoid binds in front of the “tympanic recess” of the squamosal, and then the hind margin rapidly running forwards, this bone closes upon that great auditory outgrowth, the cochlea (*chl.*). Between the cochleæ the basal beam keeps on widening backwards, behind the bony basisphenoid (*b.s.*). There is a tract of this widening cartilage three-fourths the extent of the bone; behind this the basioccipital is twice as long as the cartilage, and reaches to the front (or lower) edge of the foramen magnum (*f.m.*).

This latter bone (*b.o.*) is six-sided, has a straight front margin, a concave side margin lying against the convex cochleæ, a slightly concave margin followed by cartilage, postero-laterally, and its emarginate end is at the foramen magnum. The condyles (*oc.c.*) are short, convex, and ear-shaped; the small exoccipital bones (*e.o.*) are close in front of them, and end against the hypoglossal (or condyloid) foramen (XII.). The fore part of the foramen magnum has the bone and cartilage raised into a protecting

* If we lose patience over these details we shall miss the best things in this minute morphology. In the normal freedom and out-thrust of the Mammalian alisphenoid, and in the very varied manner of escape of this inferior maxillary nerve—*through*, or *over*, or *behind* the alæ—we have specializations that must be compared with the modification of this part of the general cranial wall to be seen in Serpents, Lizards, and Tortoises, where what is one continuous growth in Sharks, Frogs, &c., is in one case a little patch, in the next a narrow “upright,” and in the third case, the Chelonian, it has suffered complete suppression. (See Trans. Zool. Soc., vol. x., plate 38, fig. 2; Phil. Trans., 1881, Plates 1–44; *ibid.*, 1878, Plates 27–33; *ibid.*, 1879, Plates 37–45; and ‘Challenger Reports,’ vol. i., Zoology, plates 1–13.)

rim. Outside the condyles a definite low convex paroccipital ridge is seen (*po.c.*), outside this the cartilage is opisthotic (*op.*). Beyond and behind the condyles, there is a narrowish tract of cartilage, and there the lower edge of the bony supraoccipital (*s.o.*) is seen bulging backwards.

The ovoidal cochlear region of the auditory capsule (*chl.*) lies each in its own oblique, well-made socket; the rest of the capsule seen in this aspect is the tegmen tympani outside, and the opisthotic region (*op.*) postero-externally. Outside the tegmen the large pneumatic foramen of the squamosal (*tr.c.*) is drawn in outline, and under the tegmen the facial nerve (VII.) is seen passing to its place of exit, the stylomastoid foramen. In front of the nerve the small stylohyal bone (*st.h.*) is seen, and inside it the epihyal cartilage (*e.hy.*) Further inwards, in the enlarged occipito-auditory "foramen lacerum posterius," the 9th and 10th nerves (IX., X.) are emerging a little in front of the 12th (XII.). In front of this semicircular chink, the fenestra ovalis and fenestra rotunda (*fs.o.*, *f.r.*) are shown in the fundus of the nut-shaped cochlea (*chl.*), the proximal or hinder part of which is more convex than the rest.

The *upper view* (Plate 15, fig. 2) of the endocranium shows what a long tract there is of the nasal labyrinth before we come to the dilated, and most complex, true olfactory region; the cartilage roofing and walling all the regions in may still retain the old terms of alinasal, aliseptal, and aliethmoidal (*al.n.*, *al.sp.*, *al.e.*). The whole structure, as seen in this aspect, is more like the parts of a *flower* than the fore end of a skull; the vestibular fluted part is very elegant, with its two pairs of semicylindrical tracts, gradually enlarging backwards, and then appearing to end, in each, in a point. Between these pointed ends, of which the submesial go furthest back, the roof (*al.e.*) is sinuously and gently concave, and then ends in a perforated triangular tongue—as in Birds—that tongue-like growth being the top of the moderately developed cartilaginous "crista galli" (*cr.g.*).

Right and left of the crista galli—which is the concave free, posterior, *mediastinal* edge of the perpendicular ethmoid (see also fig. 3, *p.e.*, *cr.g.*), the large, hollow, burrowing olfactory fossæ are seen floored by the multiperforate cribriform plate (*cr.p.*). This porous roof over the "middle turbinals" is itself the floor of the fore skull, and these two pre-cranial *ovens* are themselves roofed in front and at their sides by the arched edges of the upper turbinal regions of the olfactory capsule. The copious growths of the upper turbinal (*u.tb.*) are indicated right and left in the great pillow-shaped lobes of the ethmoid. On the inner edge of each of these there is a small angular *tag* of cartilage, and at a moderate distance behind the round swelling end of these upper turbinal masses, the round fore end of the cartilaginous, outer part of the orbitosphenoid (*o.s.*) is seen; the *tag* is the remnant of the bond that did hold the much larger orbitosphenoid to the olfactory capsule.

The cribriform plate is margined behind by a thick rim of cartilage—very thick inside and below the *tag*; but nearer the middle the cartilage is still more solid, form-

ing a remarkable structure right and left of the axial crest, which is hollow between these two sessile *berries* of cartilage, and then thickens as it passes into the presphenoidal region (*p.s.*).

We must cross over into the territory of another group of the "Amniota" to get an explanation of these parts, which appear to be rather for ornament than use, but which are really most important in their morphological signification.

In the chondrocranium of the Crocodile and Alligator (see Trans. Zool. Soc., vol. xi., plates 63–67, and especially plate 67, fig. 1, *i.tr.*, *c.tr.*) we have the explanation of this right and left berry-shaped swelling of the hind part of the ethmoidal region. They are the swollen ends of the paired trabeculæ—the "cornua trabeculæ," so familiar to us in the Ichthyopsida.*

A large unciform lobe of the orbitosphenoidal cartilage (*o.s.*) is seen lying upon the bony alisphenoid (*al.s.*), but it is now two-thirds its own length from the front edge of the large supraauditory (or *pteroitic*) cartilage (*s.a.c.*), with which it was once continuous. The hind margin of the still large orbitosphenoid is a great semicircular notch, the fore margin is wavy, up to the rounded front and outer margin. The first and largest rounded notch of the orbitosphenoid fits against the berry-like cornu trabeculæ (*c.tr.*), and the inner angle of the bone is separated from the same part of the other side by cartilage, the hindmost part of the perpendicular ethmoid (*p.e.*). Nearly in the middle of the inner margin of the bony part the oblique optic passage (II.) is seen well margined by bone behind (see also fig. 1), but in this aspect this margin of bone is pressed upon by a mass of cartilage. Between the two bony tracts—orbitosphenoids (*o.s.*)—there is a short, thickish wedge of bone with notched sides; this is the presphenoid (*p.s.*), it is *doubtfully independent*, but is well marked off by a right and left groove.†

The cartilaginous tract between the pre- and basisphenoidal ossifications is also elevated into a sort of double berry; here with no stem between. Here we have the trabeculæ behind the intertrabecula, with the thickening at their origin, showing here most on the upper side, whereas this is seen most on the lower in the Crocodilia (*op. cit.*, Plate 65, figs. 1–3). The large bony alæ (*al.s.*) lie down low and are well scooped; they have a sharp raised ridge on their inside, and this is separated from the now confluent basisphenoid by a groove which is open at both ends; in the hinder space the internal carotid artery (*i.c.*) enters, and then runs along the groove. In front, the basisphenoid projects between the roots of the trabeculæ; behind, it is notched thrice

* The reader is also referred to the sections of the skull of the embryo Turtle (*Chelone viridis*) ('Challenger Reports,' Zool., vol. i., plate 5, especially fig. 7, *i.tr.*, *tr.*). If these figures be compared with those of the like sections of the skull of the embryo of *Struthio camelus* (Phil. Trans., 1866, Plate 10, figs. 2–5, *s.n.*), and of the skull of the *Chick* (Phil. Trans., 1869, Plate 81, fig. 6, *s.n.*, and *ibid.*, Plate 83, fig. 4, *s.v.l.*), the meaning of these things will be evident.

† The presphenoid is very rarely an independent ossification; it attains to that special condition most perfectly in the Marsupials and Rodents; but in that remarkable Insectivore, *Rhyncocyon*, the presphenoid has evidently had its own longitudinal centre of ossification.

to receive the *three convexities* of the parachordal tract. The bone is gently hollow for the pituitary body, and this "sella turcica" is finished behind by the triple rising, very slight, of the postpituitary wall, the fore part of the cartilaginous tract in which the basisphenoid and basioccipital (*b.o.*) will ultimately meet. The three convexities of the cartilage are due to the manner in which the thick parachordal tracts met, and united, over the narrowing cranial end of the notochord.

Below (fig. 1), the investing mass, or parachordal cartilage, was finished into bone right and left, by the basioccipital (*b.o.*); above, the sharp edges that lie against the nut-shaped cochleæ (*chl.*) are unfinished, the rest corresponds with what is seen below.

The cochleæ (*chl.*) look broader in this aspect than from below; they overlap the out-thrust alisphenoids, somewhat; their arched inner porch or meatus internus (VII., VIII.) is seen in this view, and also the widened chinks for the 9th and 10th nerves (IX., X.). The bulging supraoccipital centre (*s.o.*) has the outer third, on each side, occupied with a large convex inturned crest of cartilage, which runs forwards in front of the hinder angle of the alisphenoid; that foremost part is the remnant of the great continuous band that did run into the orbitosphenoid. It is mainly the hinder third of the sides of the "tegmen cranii," and is supraoccipital behind, and "pterotic" at the sides.*

This "demonstration" will be finished when I have described the great septum of the nasal labyrinth in its *lateral aspect* (Plate 15, fig. 3). The whole of the large crest of the intertrabecula is rather low, its basal or primary part is very round and solid. A large oval fenestra (*i.n.f.*) lies in front of the crest, surrounded by the alinasal growths (*al.n.*).

These are figured as cut away, but from the lower part there is given off the recurrent or JACOBSON'S cartilage (*rc.c.*), a long, hollow-faced spatula, with a small vomerine bone (*v.*) above its dilating part, in front. The aliseptal fold (*al.sp.*) is thin, but where the hinder part of the roof is cut through the alieithmoid (*al.e.*), there the cartilage is very solid. Behind it the cartilaginous crista galli (*cr.g.*) stands like a reversed "rostrum." The margin of the septum then forms one large, nearly semi-circular notch along the thin end of the intertrabecular septum (*p.e.*). Concentrically with this, a little lower down, the thick, cribriform plate (*cr.p.*) is cut through. Behind the fossæ, the stem of the cornu trabeculæ (see fig. 2, *c.tr.*) is cut through, and then comes the orbito-presphenoidal bone (*p.s.*) grooved laterally in the attempt to form a distinct median centre. Much cartilage is still unused, below and behind; then the basisphenoid (*b.s.*) shows itself through the thickness of the basal beam. The

* This lateral tract is ossified separately in the Osseous Fishes as the "pterotic" (see "Salmon's skull," Phil. Trans., 1873, Plates 5-8). In the Mole and Shrew the ossification of this part (as I shall presently show) takes place in a remarkable manner. The opisthotic rapidly ossifies nearly all the walls of the labyrinth, but the prootic arises in its normal place, and then, pushed upwards, so to speak, by the huge opisthotic, runs into this supraauditory crest, forming a *ptero-prootic* bone.

hind part of the septum is marked with hills and hollows that correspond with the folds of the middle turbinal.

SUMMARY AND CONCLUSION.

In the present state of my research I can make but little use of comparisons, and draw very few deductions. Most of the work already done is still in the form of figures, with no written descriptions, and that is only about a fifth of the work laid out for me in the Mammalian Class.

Nevertheless I am much mistaken if the knowledge already obtained in this Order of the Edentata, alone, is not of considerable value; the living types composing it are so far removed from each other by specialization that they, evidently—Family after Family—represent large groups of forms that must have existed in the past.

As *placental* Mammalia, these types come, of necessity, into Professor HUXLEY's highest group—the “Eutheria;” and yet in both the skull and the other parts of the organization worked out by me, namely, the *shoulder-girdle* and *sternum*, they come nearer at times to the Prototheria than the Marsupials themselves—that middle group, the Metatheria.

Therefore it occurs to me, and the author whose terms I have just used will, I believe, agree with me in this view, namely, that these Edentata are the direct children of the Prototheria. That they passed through a Metatherian stage is a thing not to be controverted, but I believe that it was not, in most cases at least, utilized—it was an abbreviated prenatal stage; they lost their Marsupial bones and never acquired any Marsupial modification of their abdominal skin. A great satisfaction now arises to me from the fact that my very narrow line of research brings me to the reiteration of Professor FLOWER's views of the Edentata, *inter se*.

The Old World types are sharply divided from those of the New World; but types so different in appearance and habits as the Sloth and the Ant-bear can be shown by embryology, as well as by their general anatomical structure, to be, in reality, closely related. Adaptive modification has done its utmost in these two cases; but it has only masked, it has not destroyed, the essential fundamental conformity of these two grotesque and aberrant types of Mammals.

I need not repeat here what I said in the Introduction as to my change of views since the publication of my paper on the Pig's skull (Phil. Trans., 1874, Plates 28–37), as to the general homology of the “*ossicula auditûs*.” The researches of BALFOUR, SALENSKY, and FRASER have caused me to think over this question again, and to doubt the conclusion that Professor HUXLEY first, and I afterwards, had come to on this question; if further research shows that the views of to-day are untenable, I shall be ready to receive that fresh light.

When the development of the skull has been worked out in Family after Family in the Orders that compose the whole Class, then will be the time for a general

Summary, and we shall then be better able to appreciate the fragmentary nature of the existing groups of Mammalia, and to imagine, in some degree, with the help of Palæontology, what the lost kinds were like.

In working out this Order I have had constantly to refer to the structure and development of the skull in the Sauropsida, and at the same time to be careful not to call any modification of a low Mammalian type of skull *Reptilian* or even *Sauropsidan*. I want a term of wider import than even Professor HUXLEY's title for the Mammalian *root-stock*, namely, "*Hypotheria*," as that would only lie under the Prototheria, and not under the Reptiles and Birds too. *Proto-Amniota* occurs to me, but unfortunately the second existing group of Mammalia, the Marsupials or Metatheria, are themselves *proto-Amniota*, having both that important foetal membrane and its correlated sac, the allantois, in a primary, or at least an arrested, condition.

At present, therefore, I use a term which, I think, cannot be misunderstood, namely, *quasi-Reptilian*, as its use does not suggest the idea of the possessor of such a character being derived from a Reptilian stock.

Using this precaution, I freely, from time to time, refer the reader to my published figures of the parts of the growing skull in Serpents, Lizards, Crocodiles, and Birds, because that, *in some things*, these highly specialized modern oviparous Amniota retain certain structural characters that are manifestly archaic, and that can be easily compared with their counterparts in the skull of the gill-bearing tribes.

Out of the great number of parts that are in conformity with what is seen in the other Classes, especially in the Sauropsida, I have been anxious to eliminate and put into prominence, characters that are peculiar to, and diagnostic, of the Mammal. Some of these are as much so as the *hair*, and *mammary glands*, and are therefore of great interest to the Morphologist. Yet the most striking and important of these have to be plucked out of the very fire of controversy, so that the survey of a wider and still wider field is urgently necessary; that survey, fully made, will be the work of years.

When speaking of these low forms—the Edentata—and asserting that they are archaic, or arrested, or abnormal, I am, of course, thinking of such normal forms as the Insectivora, and of the higher types that ascend above them—Lemurs, Carnivora, Ungulata, &c. Happily, everyone is familiar with the structure of the skull, in the adult, in these groups; and although these high forms have their own highest or culminating type—yet that which is highest in a Mammalian skull, as such, can be approximatively ascertained.

Suppression, or even abortive and abnormal development of, the teeth is always attended with abnormal development of the extensive facial structures; these, it is evident, modify the outward form of the head much more than any difference that can arise in the form, or proportional size of the skull proper, so far as it is a mere box to contain the central nervous system.

These remarks, it will be seen, have their bearing on the modifications to be seen in

the skull of the Edentata. But for what is seen in *Orycteropus*, I should leave the Marsupial type of skull out of question in the present comparison. All the New World kinds, and the Pangolins of the Old World, may be considered in relation to each group—to the Monotremata below them, and to the Insectivora above, or rather outside, them.

As far as I can see at present, the parietals coalesce very early in the Monotremes, and the large supraoccipital grows over to meet this quasi-reptilian roof, and form the lambdoidal suture.

In the Edentata the parietals do not meet and coalesce early; but the supraoccipital region is very large, turns over towards the parietals, and ossifies early, and has no interparietal separating it from the parietals.

This takes place in all but *Orycteropus*, which has one of the largest interparietals I have seen, and thus agrees with Marsupials, Insectivora, and the Mammalia, generally, that have normal teeth.

The premaxillaries are very small in the Edentata, especially those that are absolutely toothless; *Orycteropus* has the best developed premaxillaries of any of the members of this Order. The maxillaries have the best development in *Orycteropus*, and the feeblest in the Pangolins; and they and the little Anteater (*Cycloturus*), have only the rudiment of a jugal. That bone, although large, does not make a finished zygomatic arch in the Sloths; it does in the Armadillos; it is quite normal in *Orycteropus*. The most Crocodilian development of the hard palate takes place in the Ant-bear and the Tamandua; in *Cycloturus* the pterygoids go quite as far back as in the large kind, and are attached to strong basipterygoid processes of the basioccipital bone. In the Sloths, especially *Choloepus didactylus*, *C. Hoffmanni*, and *Bradypus tridactylus*, the pterygoids are very large and long, and in the last kind form a great "antrum" on each side. The basioccipital bones have considerable basipterygoid processes with no bones attached to them.

In *Dasypus*, the Manidæ, and in *Orycteropus*, the pterygoid bones are quite normal, but in the genus *Tatusia*, amongst the Dasypodidæ, the short, thick pterygoids add somewhat to the hard palate.

The lacrymal is absent in the Pangolins, huge in the Aard-Vark and Armadillos, and smallish in the Anteaters and Sloths.

The squamosal is pneumatic in all these types, adding a considerable upper gallery to the tympanic chamber; this agrees well with what is seen in Marsupials and Insectivores.

The os tympanicum is feebly developed in all the Edentata, about equal to what we see in Marsupials and Insectivora, but in none is there any such enlargement of the drum cavity as is seen in some Marsupials, and a few Insectivora, formed by a growth of the alisphenoid and a large "os bullæ;" nor from a special wing of the basisphenoid, as in the Hedgehog and Tenrec.

Where there are several teeth, as in Armadillos and the Aard-Vark, then the *stapes*

is normal; in the Sloths with fewer teeth, and in the toothless Anteaters and Pangolins, the stapes is a short columella; in the lesser Anteater and in the Sloth a slight perforation may take place after ossification, but this element is imperforate in the cartilaginous stage. I cannot find that the fore part of MECKEL'S cartilage forms any part of the "ramus," as Insectivora and other normal Mammals; it seems simply to become absorbed, as in the Sauropsida. The angular and coronoid processes of the lower jaw are well developed in all except the Pangolins; in them these parts are more aborted than in the Echidna.

Also in the early embryo of the Pangolin the chondrocranium, instead of equalling that of a Frog or a Skate, as it does in most kinds both of this Order and of the Mammalia, generally, is very feebly developed, almost as much so as in Serpents and Lizards, and, as in the Serpent, the orbitosphenoidal plate, at least its upper part, is a separate patch of cartilage.

In the osseous stage, the Armadillos of the genus *Tatusia* have their alisphenoid in two pieces, like the two separate tracts of the cartilaginous orbitosphenoid of the Pangolin, and in this genus, contrary to the rule of the Edentata, but according to the rule of the normal Mammalia, the 3rd branch of the 5th nerve notches the hind margin of the alisphenoid.

In the others it primarily notches the outer margin of that free-edged plate, although it often becomes enclosed in bone, afterwards, thus, passing, in the adult, through a well-formed foramen ovale. Only in the Sloth do I find a bar of bone enclosing the space through which the 2nd branch of the 5th nerve passes out, thus forming the foramen rotundum.

And only in the Sloth do I find the foramen opticum, which begins as a perfect passage, surrounded by cartilage behind, converted afterwards into a mere notch, thus opening into the sphenoidal fissure. This is primary in Marsupials, and exceptionally so in *Sorex vulgaris* amongst the Insectivora; in that type the nerve may or may not have a bony bar formed behind it, afterwards. This variation may occur in the same individual, the right and left sides differing. But in Marsupials, as in the Sauropsida, there is, normally, no postneural cartilaginous bar, either in the cartilaginous or the bony stage.

I shall refer to this imperfect list of modifications of the skull of the Edentata in my next and following papers.

LIST OF THE ABBREVIATIONS.

The Roman numerals indicate nerves or their foramina.


<i>ag.</i>	Angulare.	<i>eu.</i>	Eustachian tube.
<i>ag.p.</i>	Angular process.	<i>f.</i>	Frontal.
<i>al.e.</i>	Aliethmoid.	<i>f.m.</i>	Foramen magnum.
<i>al.n.</i>	Alinasal.	<i>fl.r.</i>	Floccular recess.
<i>al.s.</i>	Alisphenoid.	<i>fo.</i>	Fontanelle.
<i>al.s.c.</i>	Alisphenoidal canal.	<i>f.r.</i>	Fenestra rotunda.
<i>al.sp.</i>	Aliseptal.	<i>fs.o.</i>	Fenestra ovalis.
<i>a.p.f.</i>	Anterior palatine foramen.	<i>gl.c.</i>	Glandular crypts.
<i>a.s.c.</i>	Anterior semicircular canal.	<i>gl.f. and gl.c.</i>	Glenoid cavity or cartilage.
<i>at.</i>	Atlas.	<i>h.hy.</i>	Hypohyal.
<i>a.ty.</i>	Annulus tympanicus.	<i>h.s.c.</i>	Horizontal semicircular canal.
<i>ax.</i>	Axis.	<i>i.</i>	Incus.
<i>au.</i>	Auditory capsule.	<i>i.ag.</i>	Internal angular process.
<i>b.a.</i>	Basilar artery.	<i>i.c.</i>	Internal carotid.
<i>b.h.br.</i>	Basihyobranchial.	<i>i.hy.</i>	Interhyal.
<i>b.mn.</i>	Basimandibular.	<i>i.f.l.</i>	Inferolateral fontanelle.
<i>b.o.</i>	Basioccipital.	<i>i.n.f.</i>	Internasal fenestra.
<i>b.pg.</i>	Basipterygoid process.	<i>inf.</i>	Infundibulum.
<i>b.s.</i>	Basisphenoid.	<i>i.p.</i>	Interparietal.
<i>C.</i>	Brain.	<i>i.tb.</i>	Inferior turbinal.
<i>c.au.</i>	Concha auris.	<i>i.tr.</i>	Intertrabecula.
<i>cd.p.</i>	Condylod process.	<i>iv.</i>	Investing mass.
<i>chl.</i>	Cochlea.	<i>j.</i>	Jugal.
<i>c.hy.</i>	Ceratohyal.	<i>j.o.</i>	JACOBSON'S organ.
<i>c.p. and cr.p.</i>	Coronoid process.	<i>l.</i>	Lachrymal.
<i>cr.g.</i>	Crista galli.	<i>l.c.</i>	Lachrymal canal.
<i>cr.p.</i>	Cribriform plate.	<i>l.c.i.</i>	Long crus of incus.
<i>c.tr.</i>	Cornu trabeculæ.	<i>l.s. and s.c.</i>	Lateral sinus.
<i>c.ty.</i>	Cavum tympani.	<i>lx.</i>	Larynx.
<i>d.</i>	Dentary.	<i>m.</i>	Mouth.
<i>d.c.</i>	Dentary canal.	<i>m.a.e.</i>	External meatus
<i>e.</i>	Eye.	<i>mb. and m.ml.</i>	Manubrium mallei.
<i>e.hy.</i>	Epihyal.	<i>m.c.</i>	Meatus cartilage.
<i>e.n.</i>	External nostrils.	<i>m.g.</i>	Mucous gland.
<i>e.o.</i>	Exoccipital.	<i>mk.</i>	MECKEL'S cartilage.
<i>ep.</i>	Epiotic.	<i>ml.</i>	Malleus.
<i>e.pg.</i>	External pterygoid.	<i>mn.</i>	Mandible.

MR. W. K. PARKER ON THE SKULL IN THE MAMMALIA.

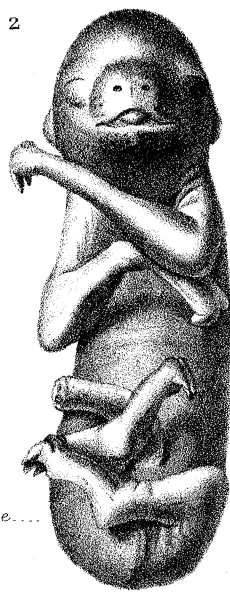<i>ms.pg.</i>	Mesopterygoid.	<i>p.t.</i>	Post-temporal.
<i>mt.c.</i>	Mastoid cells.	<i>p.t.r.</i>	Posterior tympanic recess.
<i>m.ty.</i>	Membrana tympani.	<i>p.ty.</i>	Pretympanic process of malleus.
<i>mx.</i>	Maxillary.	<i>px.</i>	Premaxillary.
<i>n.</i>	Nasal.	<i>py.</i>	Pituitary region.
<i>nc.</i>	Notochord.	<i>rc.c.</i>	Recurrent cartilage.
<i>n.f.</i>	Nasal floor.	<i>r.vb.</i>	Recessus vestibuli.
<i>n.p.</i>	Nasal passage.	<i>s.a.c. and s.t.c.</i>	Supra-auditory cartilage.
<i>n.p.c.</i>	Nasal palatine passage or canal.	<i>s.ag.</i>	Supra-angular.
<i>n.tb.</i>	Nasal turbinal.	<i>s.c. and l.s.</i>	Sinus canal.
<i>n.v.</i>	Narial valve.	<i>s.c.i.</i>	Short crus of incus.
<i>o.b.</i>	Os bullæ.	<i>s.n.</i>	Septum nasi.
<i>oc.c.</i>	Occipital condyle.	<i>s.o.</i>	Supraoccipital.
<i>op.</i>	Opisthotic.	<i>s.ob.</i>	Supraorbital.
<i>o.s.</i>	Orbitosphenoid.	<i>sp.</i>	Splénial.
<i>p.</i>	Parietal.	<i>sq.</i>	Squamosal.
<i>pa.</i>	Palatine.	<i>sq.c.</i>	Squamosal cells.
<i>p.ag.</i>	Posterior angular process.	<i>st.</i>	Stapes.
<i>p.cl.</i>	Posterior clinoid.	<i>s.t.</i>	Supratemporal.
<i>p.e.</i>	Perpendicular ethmoid.	<i>st.a.</i>	Stapedial artery.
<i>pg.</i>	Pterygoid.	<i>st.h.</i>	Stylohyal.
<i>pg.c.</i>	Pterygoid cartilage.	<i>st.m.</i>	Stapedius muscle.
<i>p.gl.</i>	Postglenoid process.	<i>t.al.s.</i>	Tympanic wing of alisphenoid.
<i>p.gr.</i>	Processus gracilis.	<i>t.b.s.</i>	Tympanic wing of basisphenoid.
<i>phx.</i>	Pharynx.	<i>tg.</i>	Tongue.
<i>p.mx.</i>	Palatine plate of maxillary.	<i>th.c.</i>	Thyroid cartilage.
<i>p.n.</i>	Posterior nares.	<i>t.hy.</i>	Thyrohyal.
<i>pn.f.</i>	Pneumatic foramen.	<i>tr.</i>	Trabecula.
<i>p.ob.</i>	Postorbital.	<i>tt.</i>	Tentorium.
<i>p.oc.</i>	Paroccipital.	<i>t.tm.</i>	Tensor tympani.
<i>p.p.f.</i>	Posterior palatine foramen.	<i>t.ty.</i>	Tegmen tympani.
<i>p.px.</i>	Palatine process of premaxillary.	<i>u.tb.</i>	Upper turbinal.
<i>pr.o.</i>	Prootic.	<i>u.t.r.</i>	Upper tympanic recess.
<i>p.s.</i>	Presphenoid.	<i>v., v', v''.</i>	Vomerine bones.
<i>p.s.c.</i>	Posterior semicircular canal.	<i>vb.</i>	Vestibule.

PLATE 1.

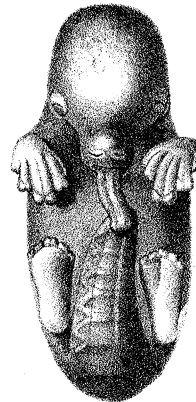
Figures.		Number of times magnified.
1	Embryo of Unau (<i>Cholopus didactylus</i>); about half ripe (1st stage); side view	nat. size.
2	The same; front view	ditto
3	Early embryo of Pangolin (<i>Manis</i> — ? sp.) (1st stage); front view	$1\frac{1}{2}$
4	The same; side view	$1\frac{1}{2}$
5	Advanced embryo of Pangolin (<i>Manis brevicaudata</i>), from Ceylon (2nd stage); front view	nat. size.
6	The same; side view	ditto
7	Embryo (one-third ripe) of Armadillo (<i>Tatusia hybrida</i>) (1st stage); side view	2
8	The same; front view	2
9	Head of nearly ripe embryo of Aard-Vark (<i>Orycteropus capensis</i>); upper view	$\frac{1}{2}$ nat. size.
10	The same; side view	ditto
11	The same; front view	nat. size.




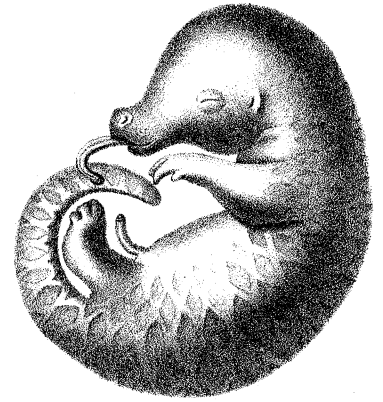
.....Nat. size.....




3 x 1½



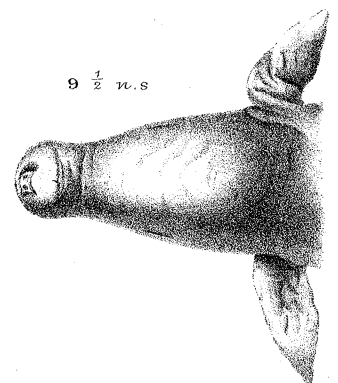
4 x 1½



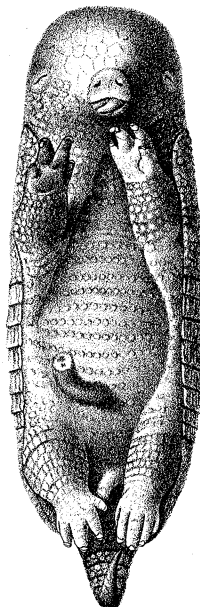
11 n.s



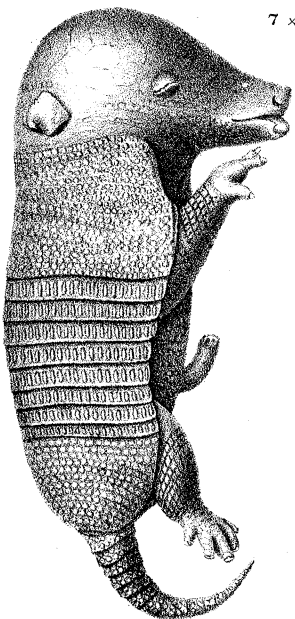
9 ½ n.s



8 x 2



7 x 2



10 ½ n.s

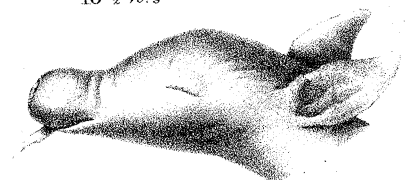
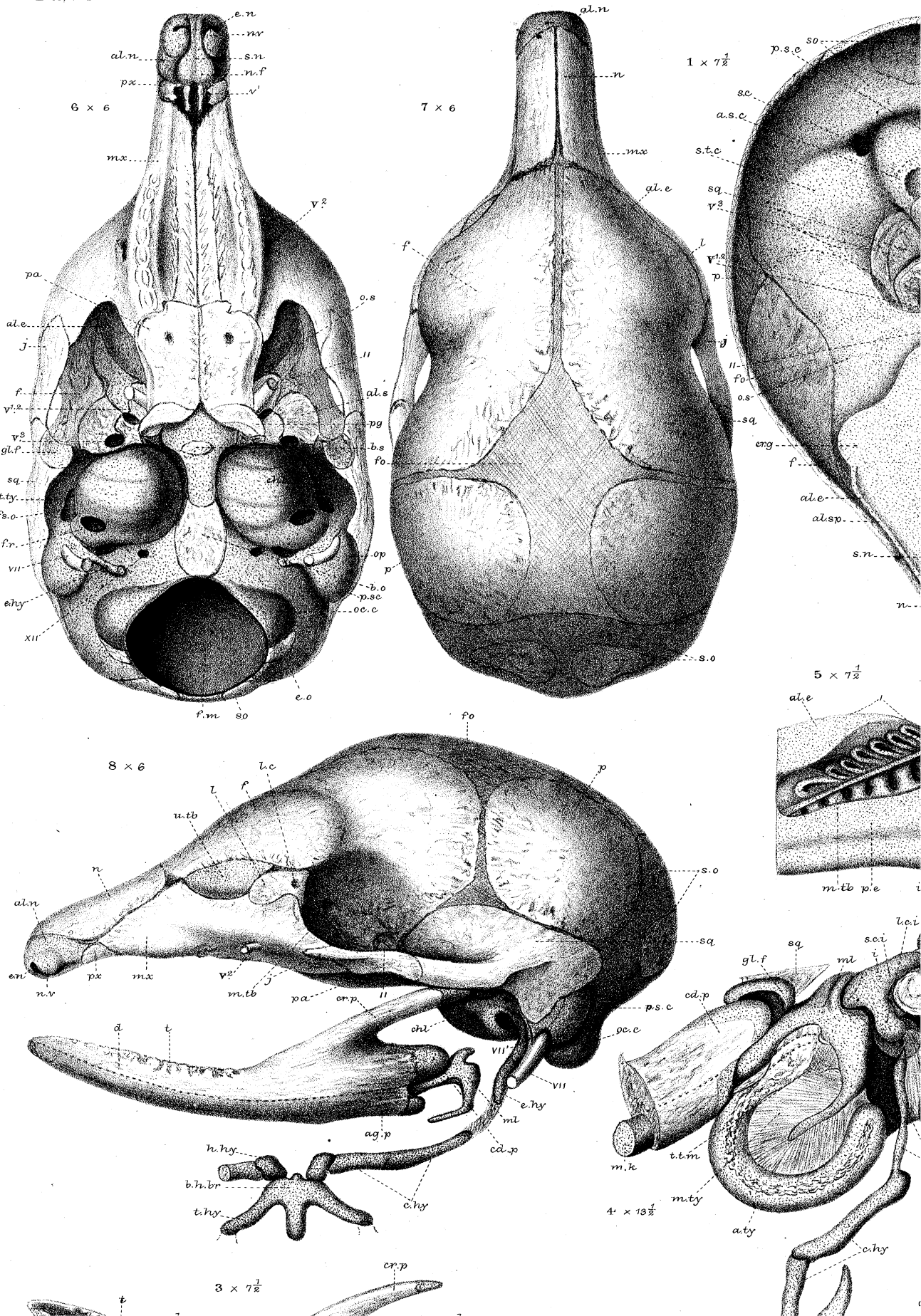
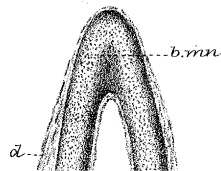
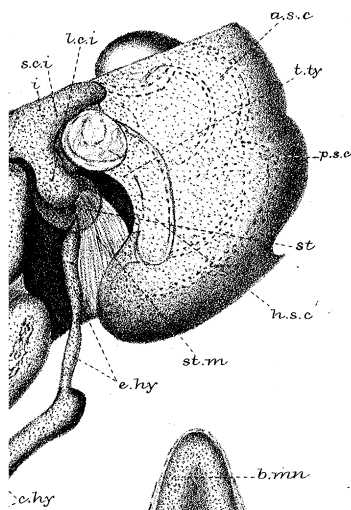
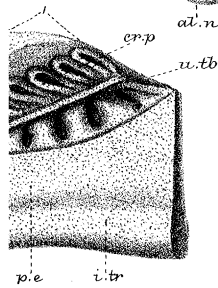
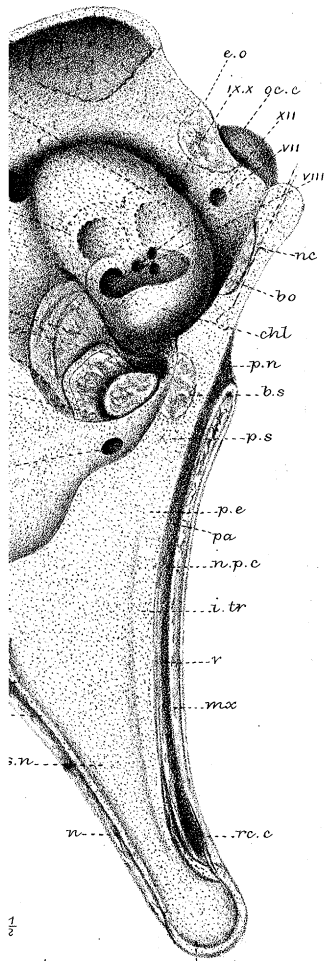


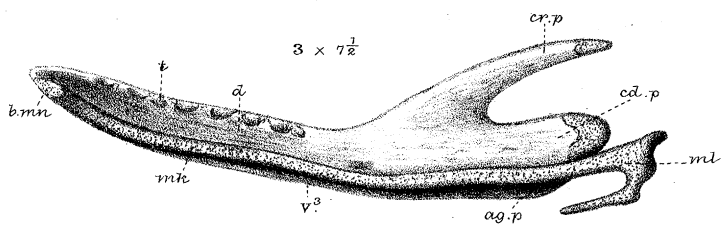
PLATE 2.

Figures.		Number of times magnified.
1	<i>Tatusia hybrida</i> (1st stage); embryo $1\frac{2}{3}$ inch long (snout to root of tail); section of skull; inner view	$7\frac{1}{2}$
2	The same*; fore part of lower jaws; upper view	$13\frac{1}{2}$
3	The same; lower jaw; inner view	$7\frac{1}{2}$
4	The same; auditory region; outer view	$13\frac{1}{2}$
5	The same; part of ethmoidal region, with turbinals exposed, and rudiment of cribriform plate shown . .	$7\frac{1}{2}$
6	<i>Tatusia hybrida</i> ; 2 inches long (2nd stage); skull; lower view	6
7	The same; skull; upper view	6
8	The same; skull; side view	6

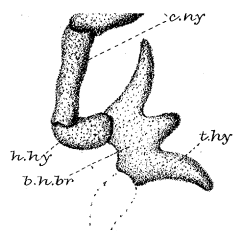
* This figure is not numbered on the Plate; it is below fig. 4.



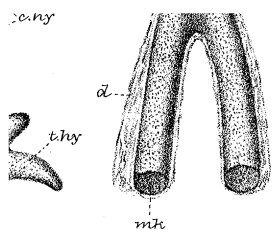




Parke & Coward lith.
W.K.P. del.



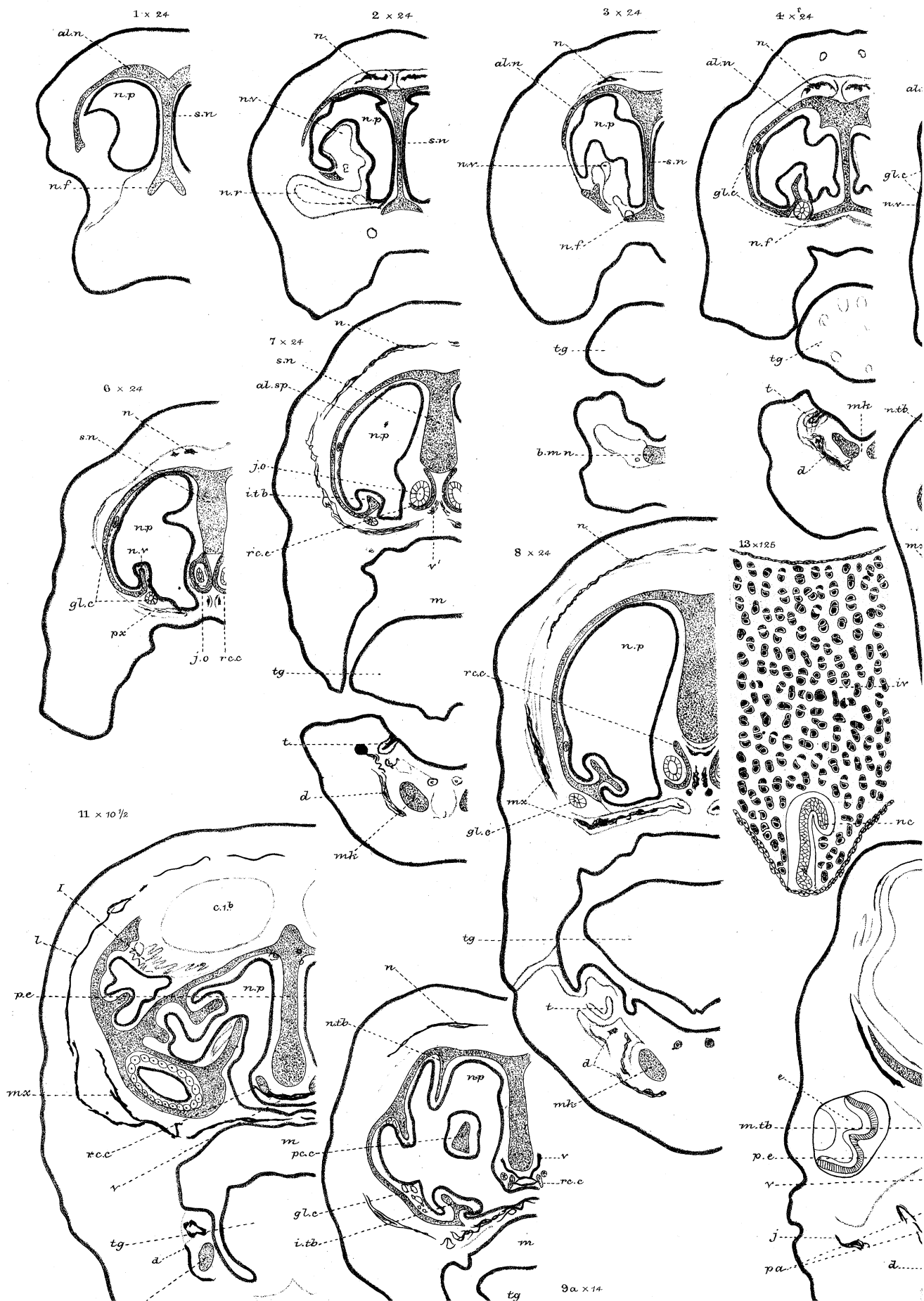
Tatusia hybrida.

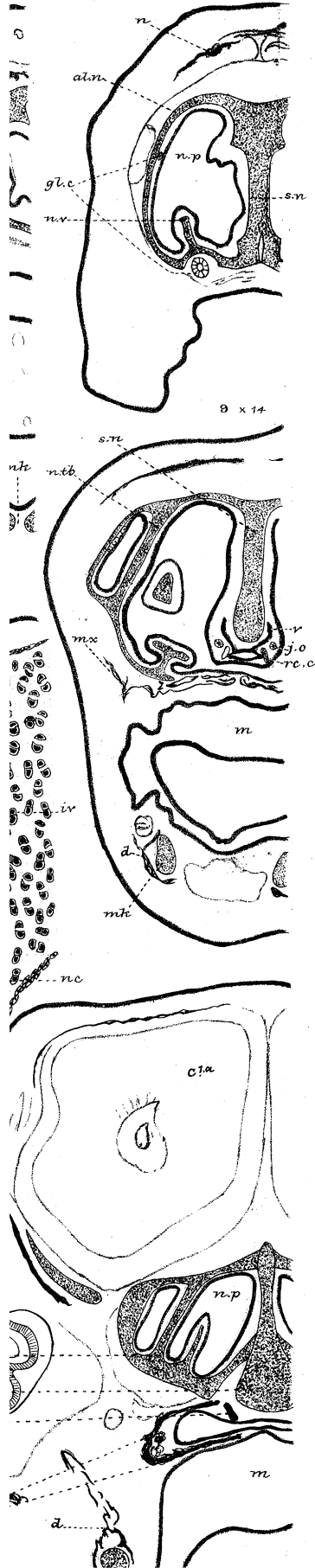


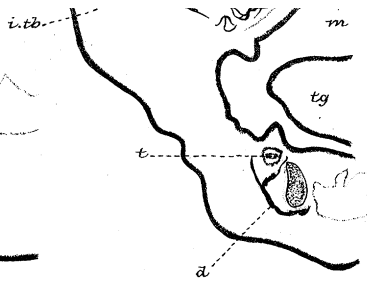
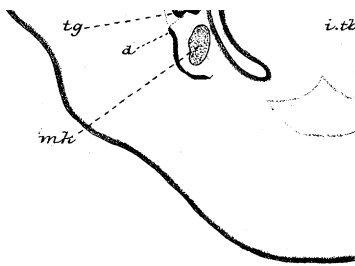
West, Newman & Co. imp.

PLATE 3.

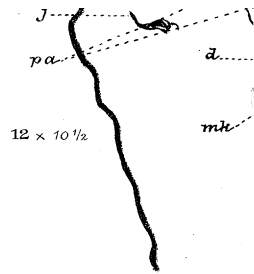
Figures.		Number of times magnified.
1	<i>Tatusia hybrida</i> (1st stage); embryo; $1\frac{2}{3}$ inch long; 1st of a series of vertically-transverse, thin, transparent sections	24
2	The same; 2nd section	24
3	The same; 3rd section	24
4	The same; 4th section	24
5	The same; 5th section	24
6	The same; 6th section	24
7	The same; 7th section	24
8	The same; 8th section	24
9	The same; part of 9th section	14
9A (read 10)	The same; 10th section	14
11	The same; 11th section	$10\frac{1}{2}$
12	The same; 12th section	$10\frac{1}{2}$
13	The same; part of 17th section (Plate 4, fig. 5) . . .	125







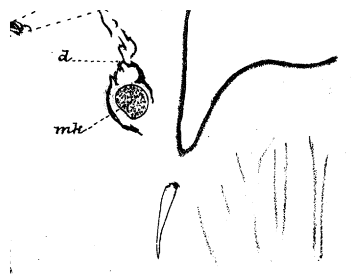
9a x 14



12 x 10 1/2

Parker & Coward del et lith
W.K.P. div.

Tatusia hybrida.



West Newman & Co imp.

PLATE 4.

Figures.		Number of times magnified.
1	(Continuation of same series); 13th section	$10\frac{1}{2}$
2	The same; 14th section	$10\frac{1}{2}$
3	The same; 15th section	$10\frac{1}{2}$
4	The same; 16th section	$10\frac{1}{2}$
5	The same; 17th section	$10\frac{1}{2}$
6	The same; 18th section	$10\frac{1}{2}$
7	The same; 19th section	12
8	The same; 20th section	12
9	The same; 21st section	12
10	The same; 22nd section	12
11	The same; 23rd section	12
12	The same; 24th section	12
13	The same; 25th section	12

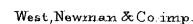
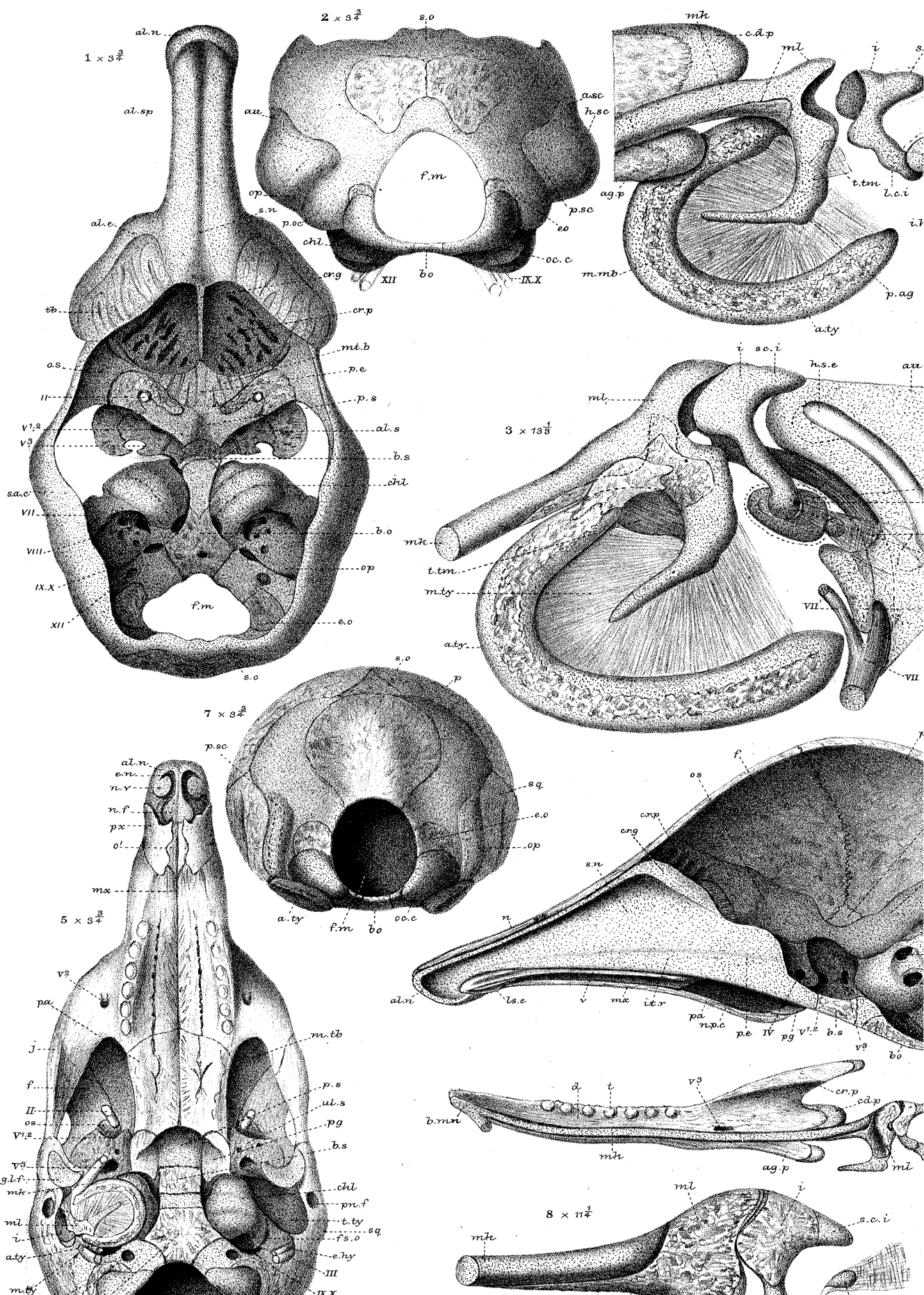
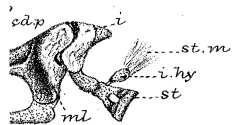
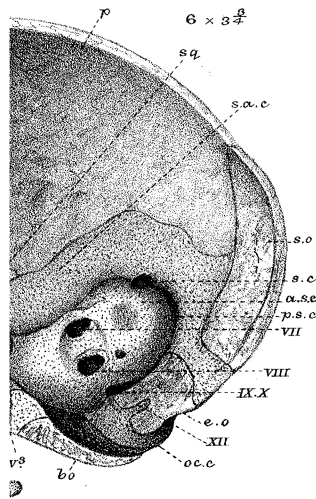
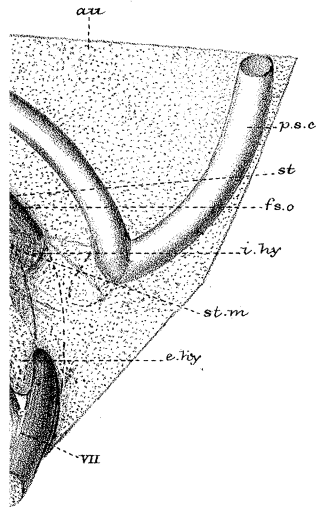
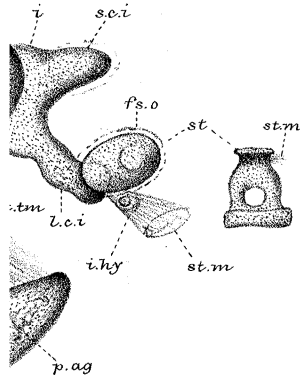


PLATE 5.

Figures.		Number of times magnified.
1	<i>Tatusia hybrida</i> ; embryo; 3 inches long (3rd stage); endocranium; upper view	$3\frac{3}{4}$
2	The same; end view.	$3\frac{3}{4}$
3	The same; auditory region; outer view	$13\frac{1}{3}$
4	<i>Tatusia hybrida</i> ; embryo; 2 inches long (2nd stage); auditory region; outer view	$13\frac{1}{3}$
5	<i>Tatusia peba</i> ; embryo; 3 inches long (4th stage); skull; lower view	$3\frac{3}{4}$
6	The same; vertical section of skull; inner view . . .	$3\frac{3}{4}$
7	The same; skull; end view	$3\frac{3}{4}$
8	The same; ossicula auditûs	$11\frac{1}{4}$

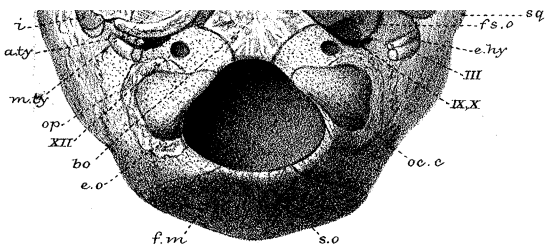


4×133

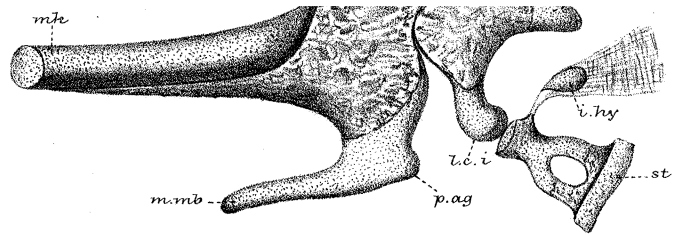


s.c.i





W.K.P. del.
Parker & Coward lith.



1-4, *Tatusia hybrida*; 5-8, *T. peba*.



hy

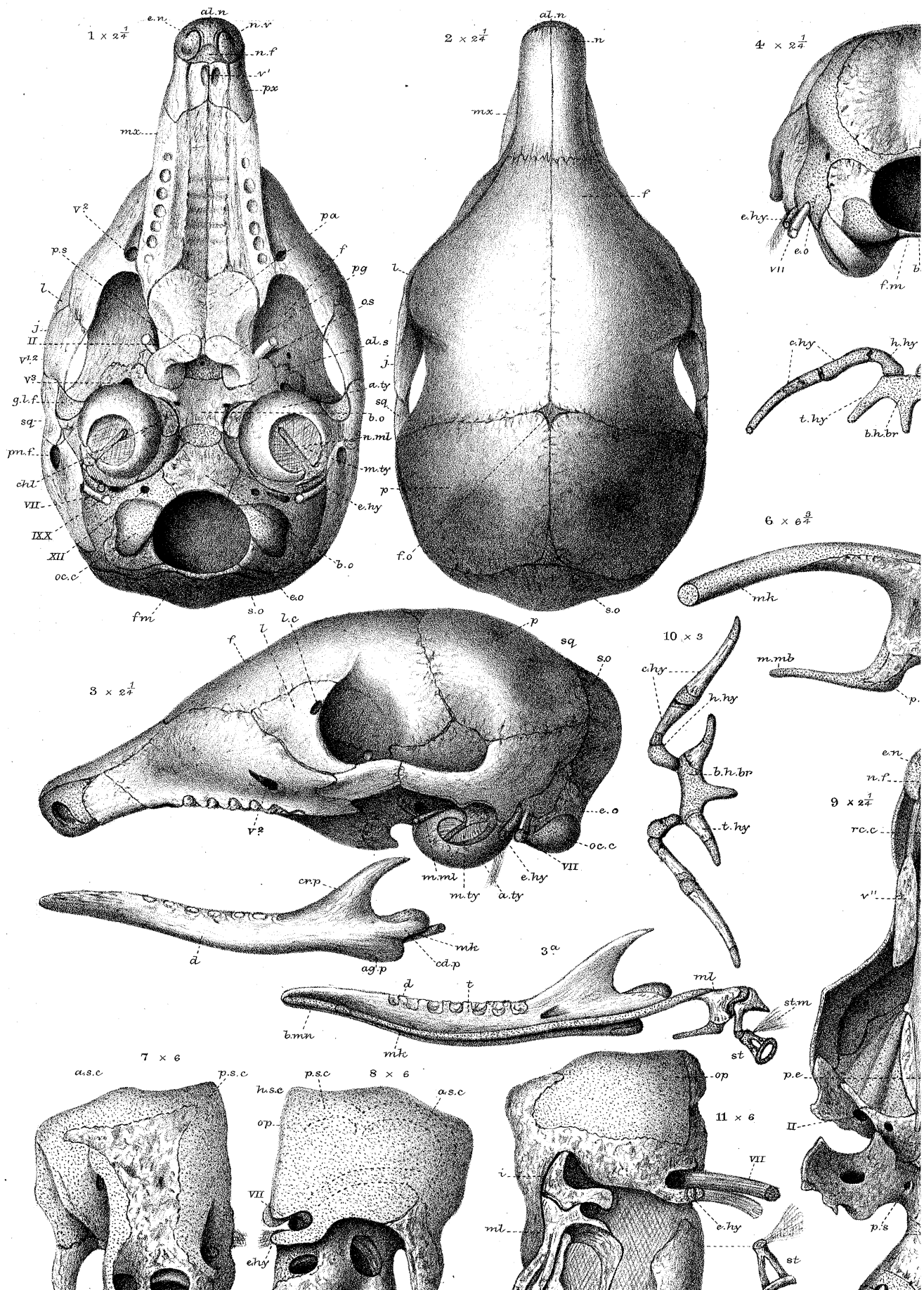


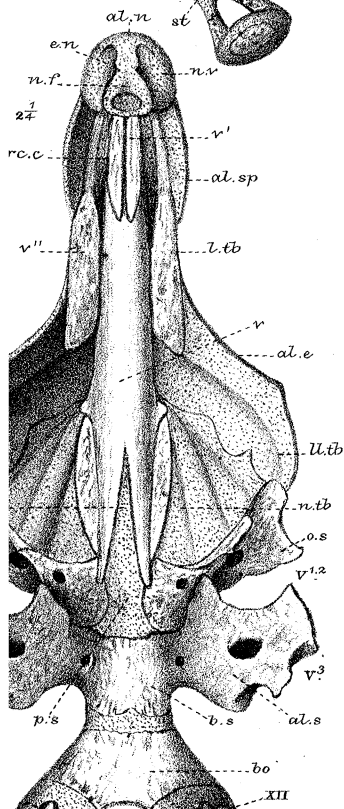
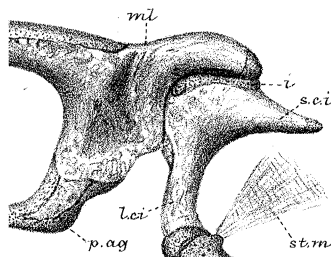
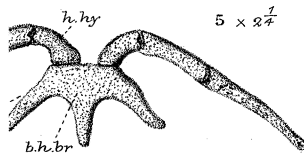
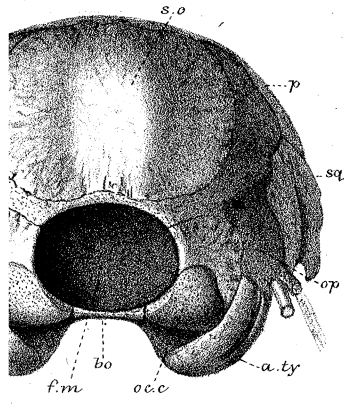
st

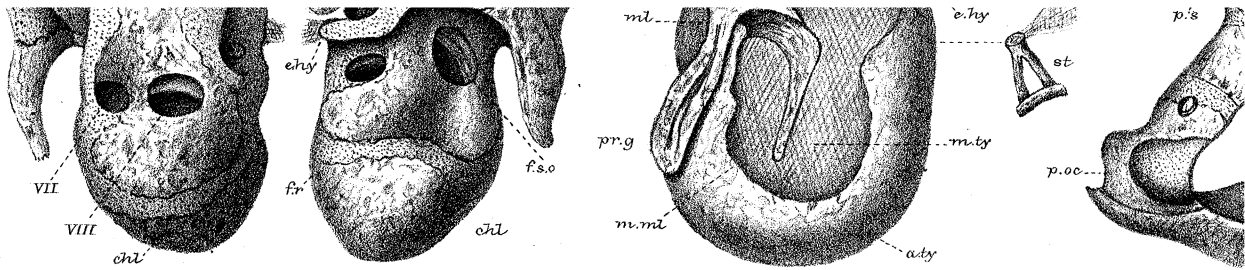
West, Newman & Co. imp.

PLATE 6.

Figures.		Number of times magnified.
1	<i>Tatusia hybrida</i> ; ripe embryo; 4 inches long (5th stage); skull; lower view	$2\frac{1}{4}$
2	The same; upper view	$2\frac{1}{4}$
3	The same; side view	$2\frac{1}{4}$
3A	The same; lower jaw; inner view	$2\frac{1}{4}$
4	The same; end view	$2\frac{1}{4}$
5	The same; os hyoides; under view	$2\frac{1}{4}$
6	The same; ossicula auditûs; outer view	$6\frac{3}{4}$
7	The same; auditory capsule; inner view	6
8	The same; outer view	6
9	<i>Tatusia peba</i> ; new born (?); $4\frac{1}{2}$ inches long (6th stage); endocranium; lower view	$2\frac{1}{4}$
10	The same; os hyoides; under view.	3
11	The same; auditory region; outer view	6

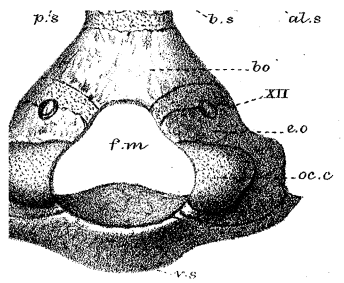






W.K.P. del.
Parker & Coward lith.

1-8, *Tatusia hybrida*; 9-11, *T. peba*.

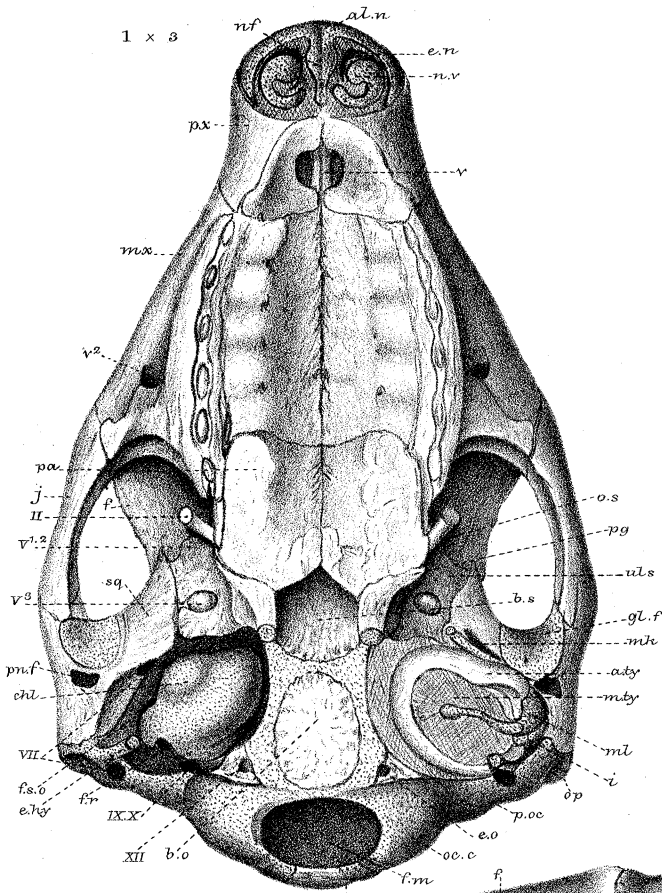


West, Hazzan & Co. Inc.

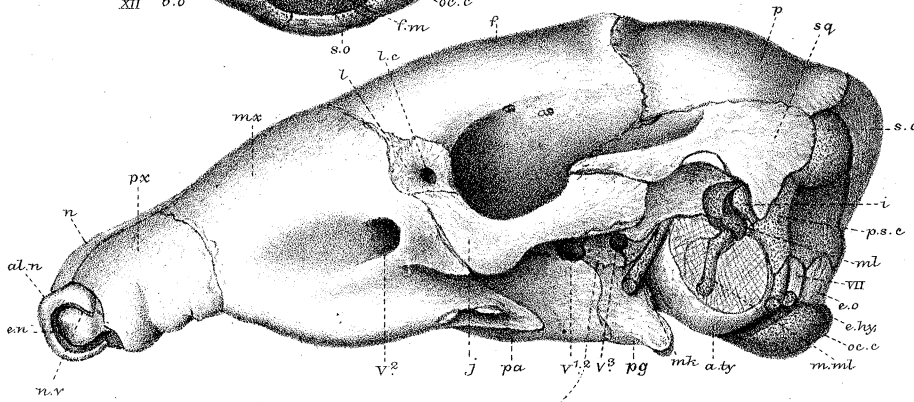
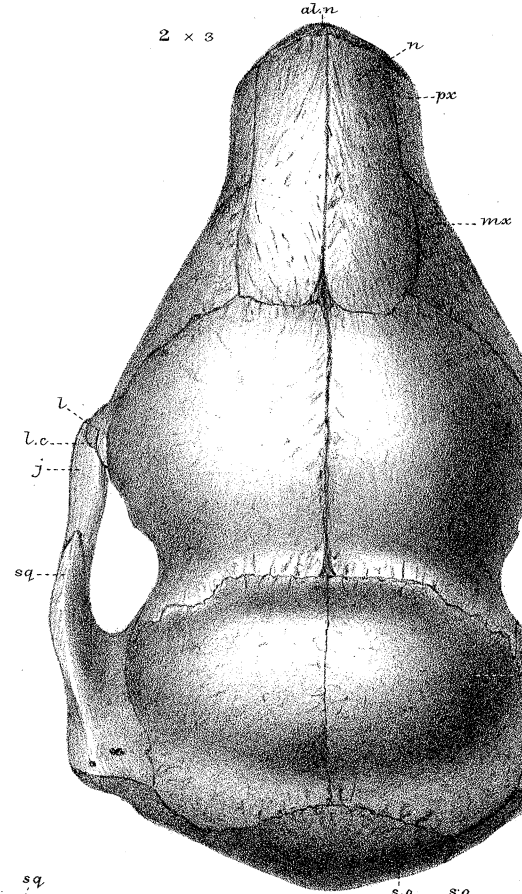
PLATE 7.

Figures.		Number of times magnified.
1	<i>Dasypus villosus</i> ; ripe embryo; $4\frac{2}{3}$ inches long (5th stage, continued); skull; under view	3
2	The same; upper view	3
3	The same; side view	3
3A	The same; lower jaw; inner view	3
4	The same; skull; end view	3
5	The same; os hyoides; inner view	3
6	The same; ossicula auditûs; outer view	9

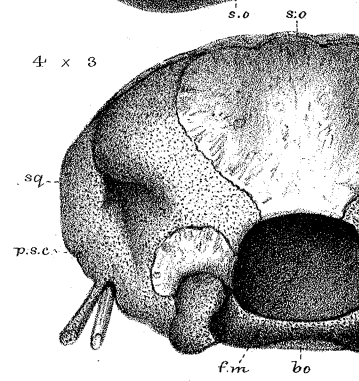
1 x 3



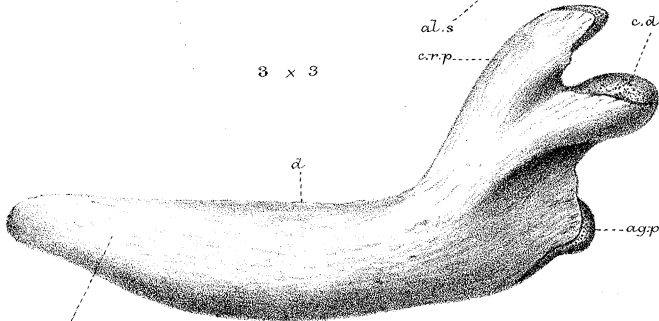
2 x 3



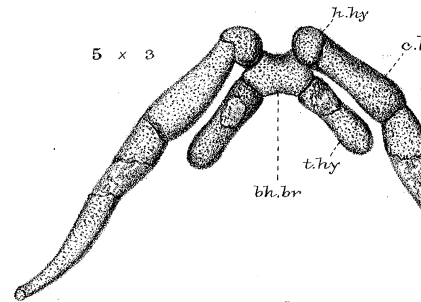
4 x 3



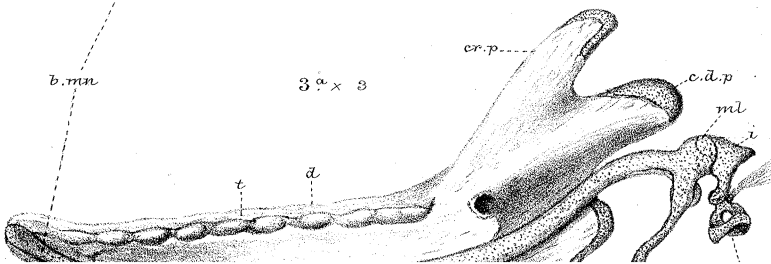
3 x 3



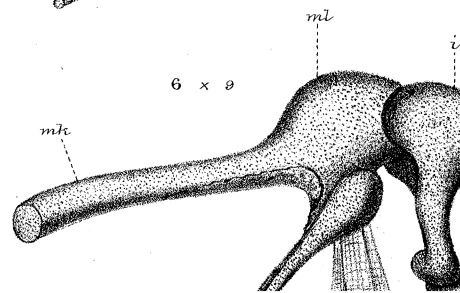
5 x 3



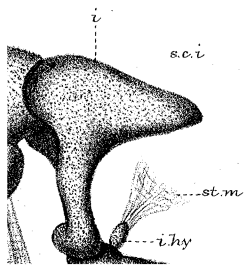
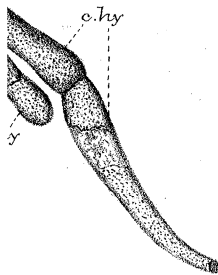
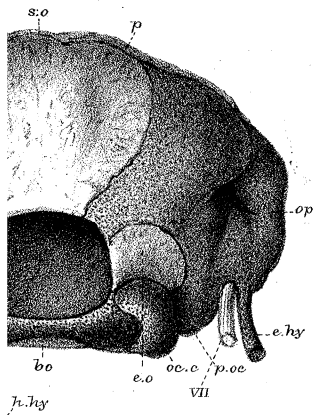
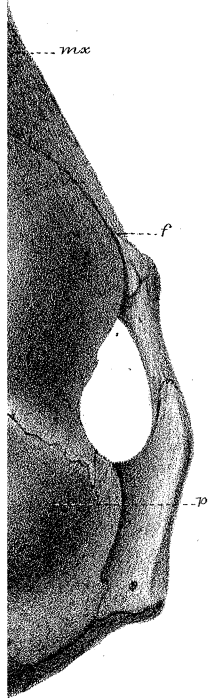
3 x 3

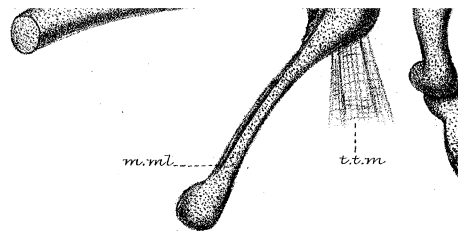
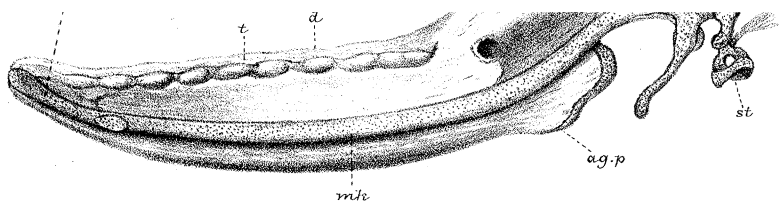


6 x 3



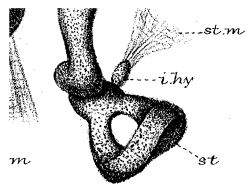
px





Parker & Coward lith.
W.K.P. del. ad nat.

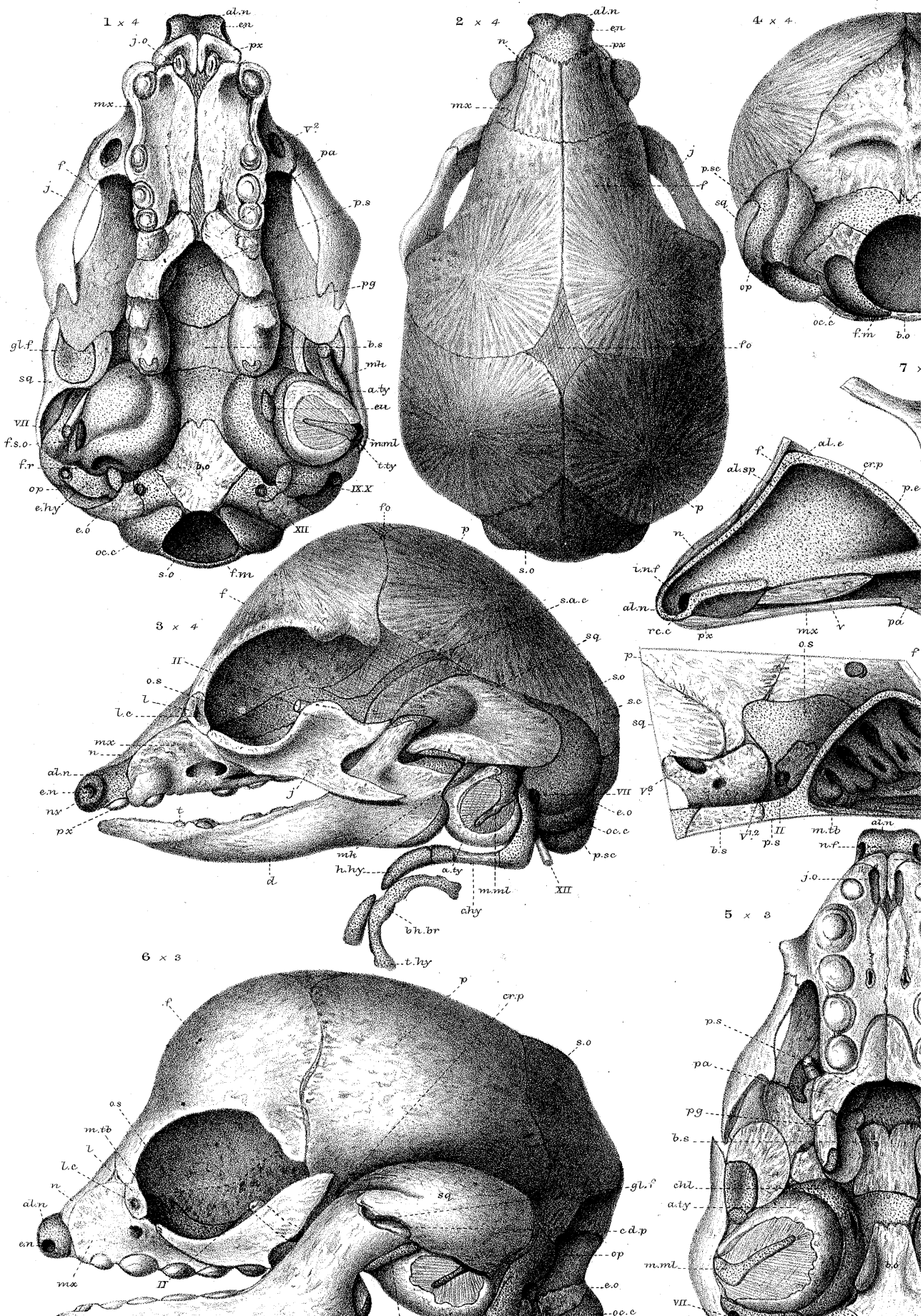
Dasypus villosus.

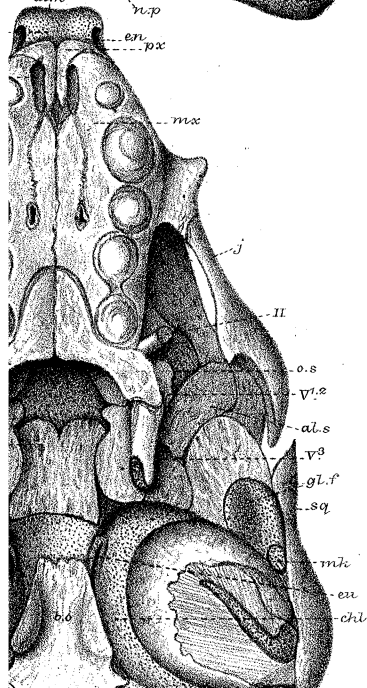
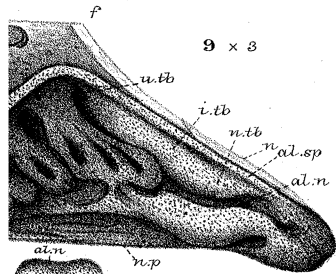
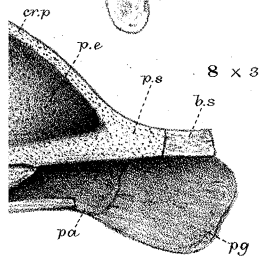
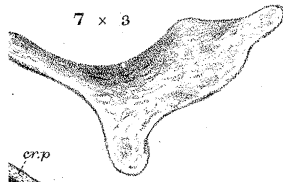
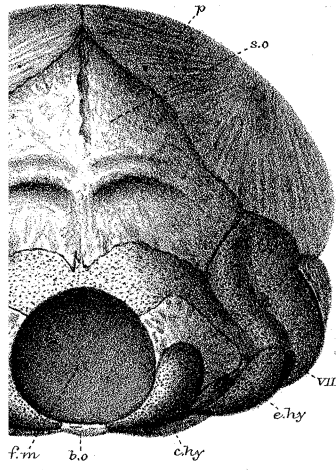


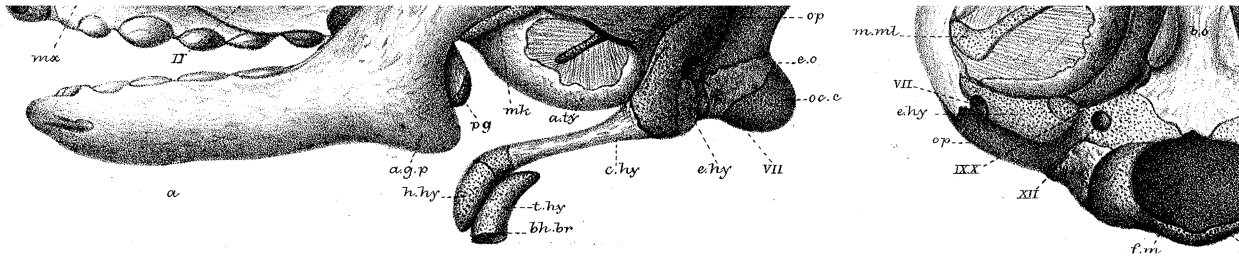
West, Newman & Co. imp.

PLATE 8.

Figures.		Number of times magnified.
1	Unau (<i>Cholopus didactylus</i>) (?) ; embryo ; $3\frac{1}{4}$ inches long (1st stage) ; skull ; lower view	4
2	The same ; upper view	4
3	The same ; side view	4
4	The same ; end view	4
5	Ai (<i>Bradypus, Arctopithecus</i> , GRAY, ? sp.) ; embryo ; 5 inches long (2nd stage) ; skull ; lower view	3
6	The same ; side view	3
7	The same ; right malar bone	3
8	The same ; nasal region of skull ; side view of septum .	3
9	The same ; showing turbinals.	3

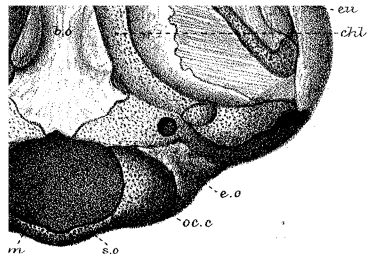






Parker & Coward.
W.K.P. del ad nat.

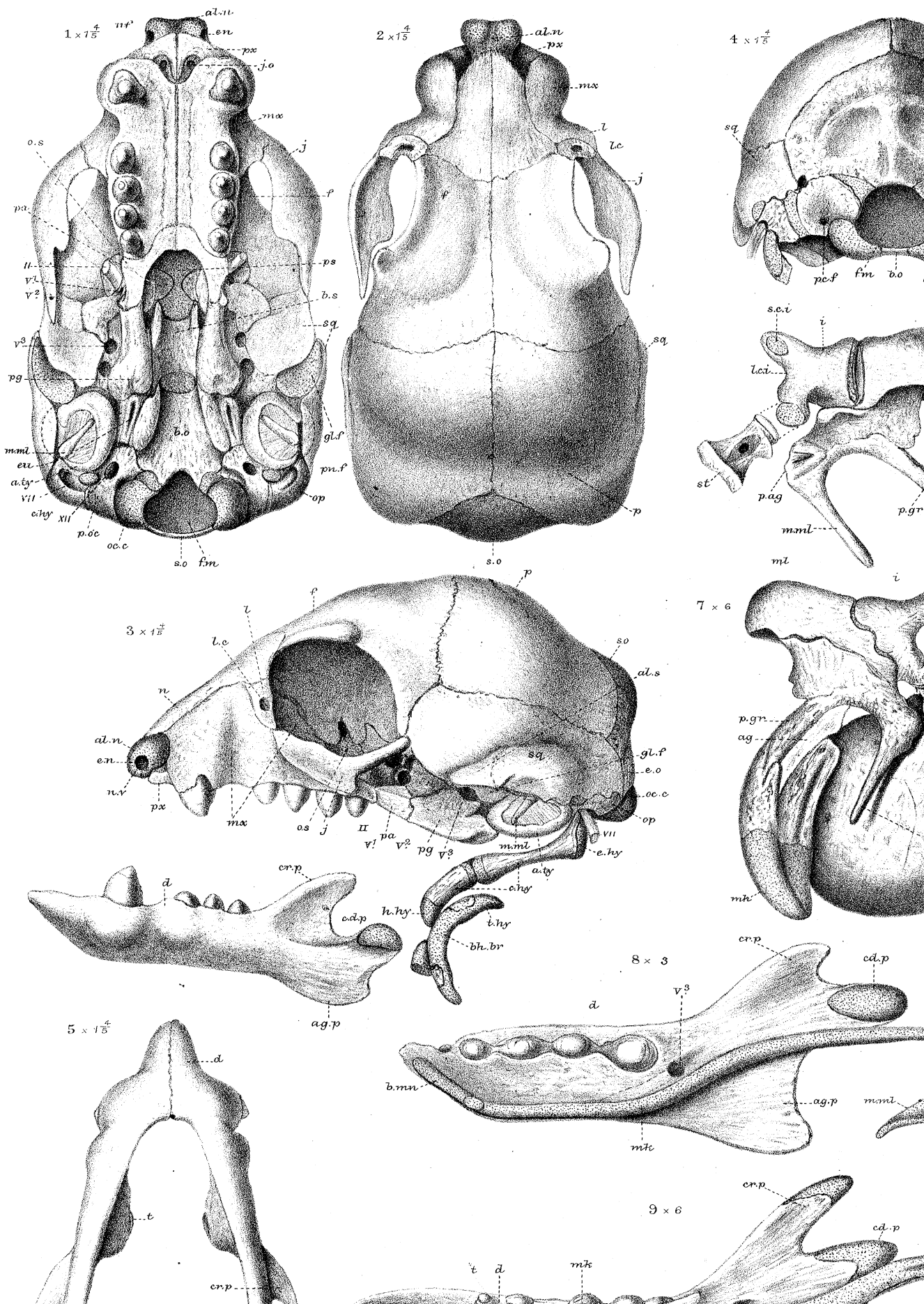
1-4 Choloopus, 5-9 Bradypus.

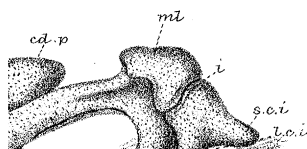
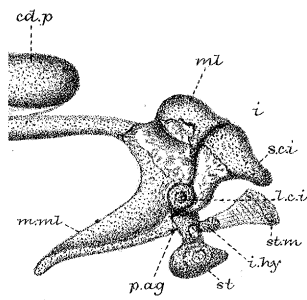
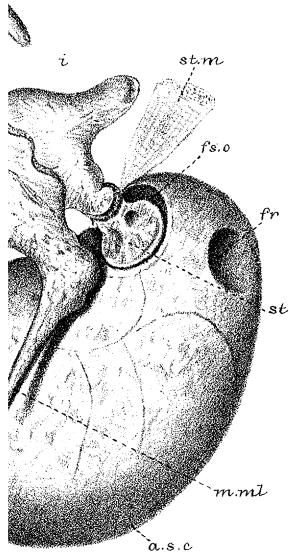
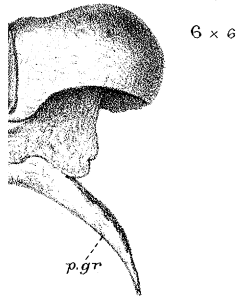
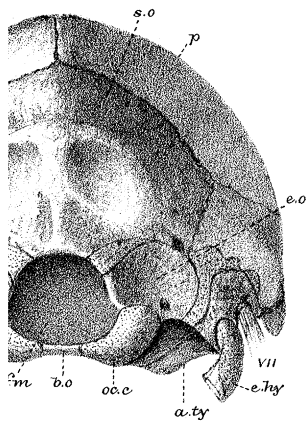



West, Newman & Co imp.

PLATE 9.

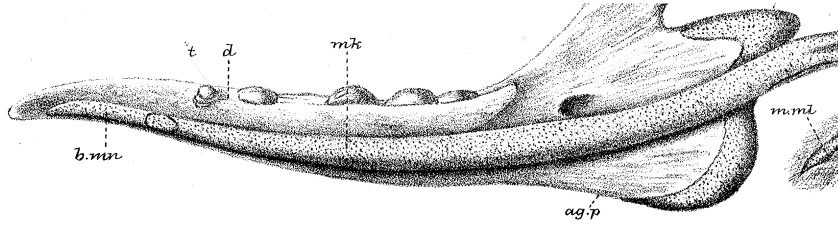
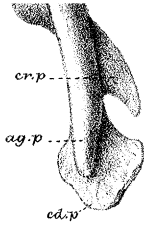
Figures.		Number of times magnified.
1	<i>Cholopus Hoffmanni</i> ; young; 8 inches long (3rd stage); skull; lower view	$1\frac{4}{5}$
2	The same; upper view	$1\frac{4}{5}$
3	The same; side view	$1\frac{4}{5}$
4	The same; end view	$1\frac{4}{5}$
5	The same; lower jaws; under view	$1\frac{4}{5}$
6	The same; ossicula auditûs; inner view	6
7	The same; ossicula auditûs and auditory capsule; outer view	6
8	<i>Bradypus (Arctopithecus)</i> (2nd stage); lower jaw and ossicula auditûs; inner view	4
9	<i>Cholopus didactylus</i> (?) (1st stage); the same parts; inner view	6





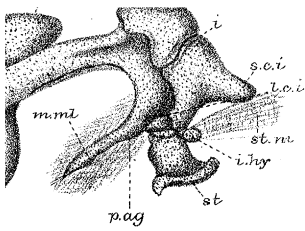


W.K.P. del. ad. nat.
Parker & Coward lith.



1-7, & 9 Cholopus: 8 Bradypus.

We

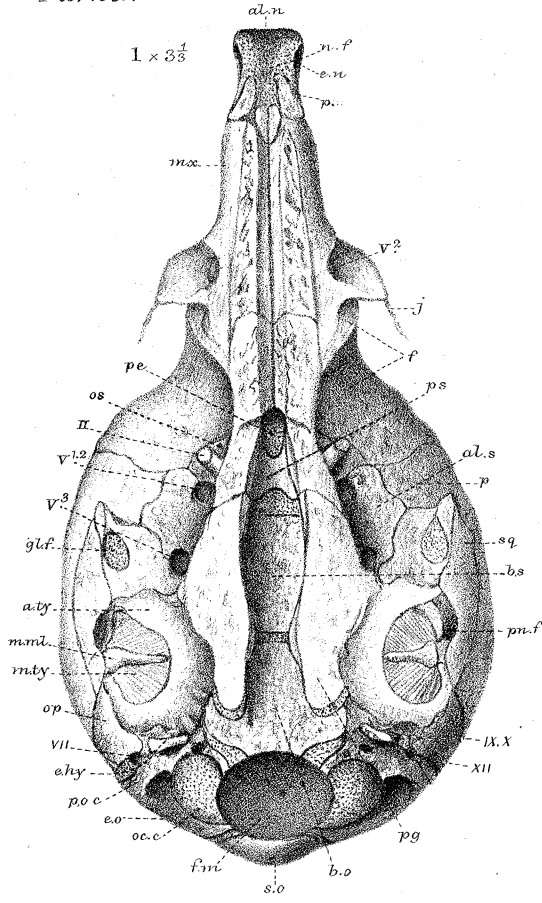


West, Newman & Co. imp.

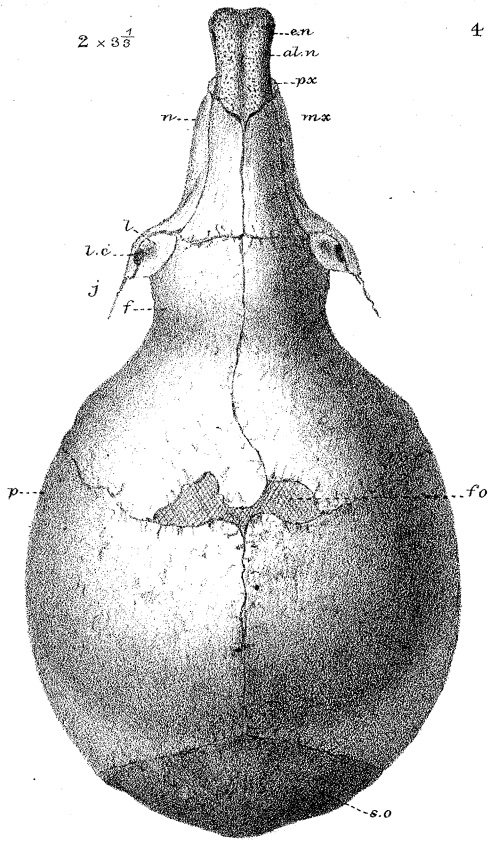
PLATE 10.

Figures.		Number of times magnified.
1	<i>Cycloturus didactylus</i> ; young; head, $1\frac{1}{4}$ inch long; skull; lower view	$3\frac{1}{3}$
2	The same; upper view	$3\frac{1}{3}$
3	The same; side view	$3\frac{1}{3}$
3A	The same; lower jaw; inner view	$3\frac{1}{3}$
4	The same; end view of skull	$3\frac{1}{3}$
5	The same species; larger specimen; $4\frac{1}{2}$ inches long; head, $1\frac{1}{2}$ inch; ossicula auditûs; outer view	10
6	The same; os hyoides; inner view	10
7	The same; vertical section of skull; inner view	$3\frac{1}{3}$
8	The same; part of skull, showing turbinals	$3\frac{1}{3}$
9	The same species; lesser specimen; temporal region oblique; lower view	$6\frac{2}{3}$
10	The same; larger specimen; vomer and related parts; lower view	6

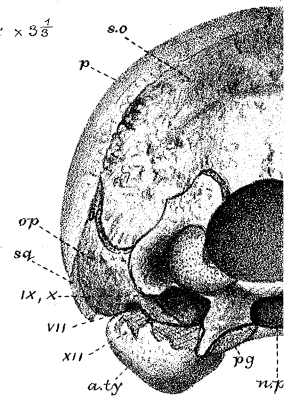
1 x 3 1/3



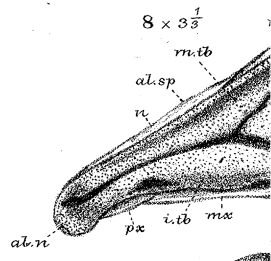
2 x 3 1/3



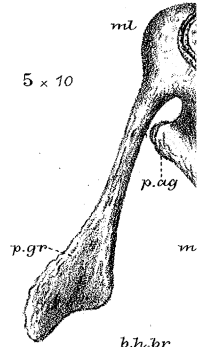
4 x 3 1/3



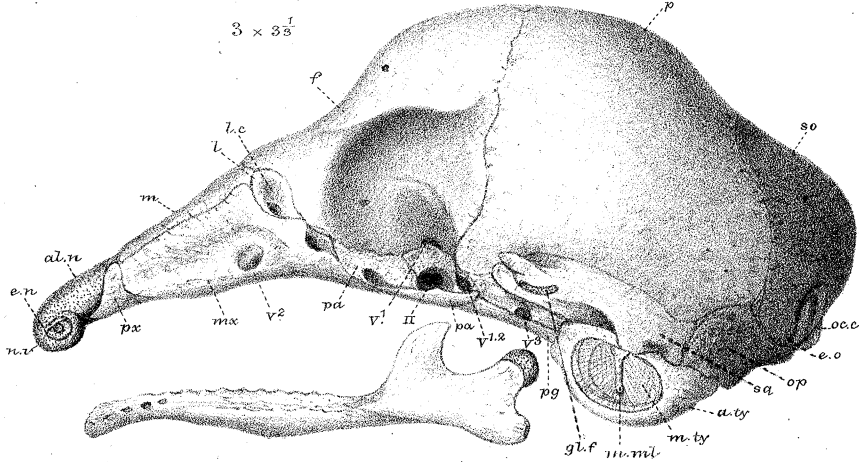
8 x 3 1/3



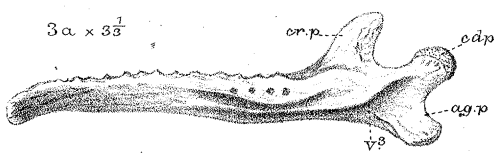
5 x 10



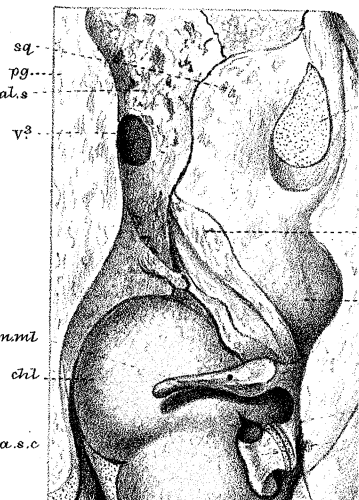
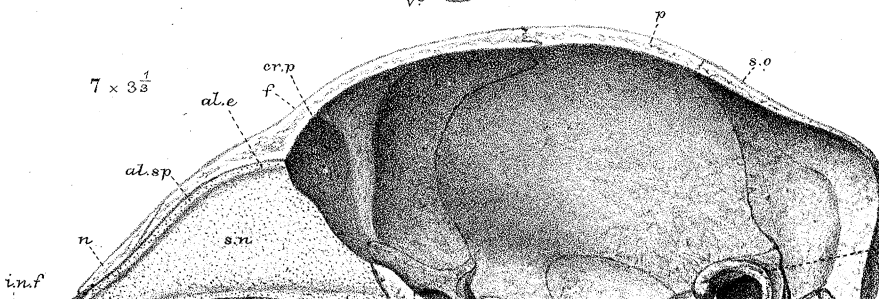3 x 3 1/3

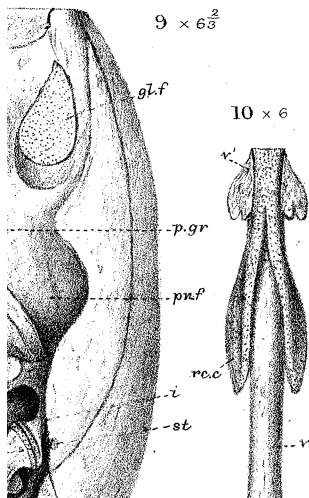
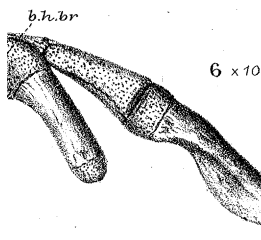
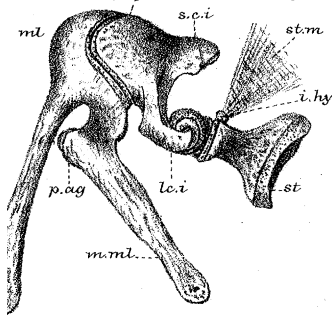
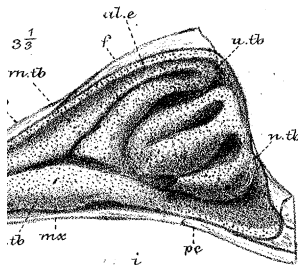
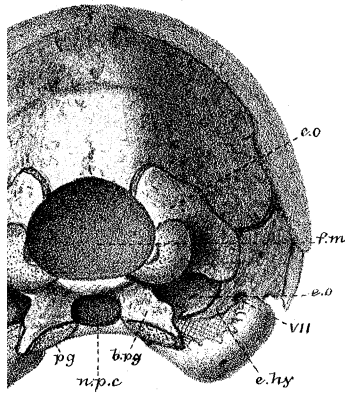


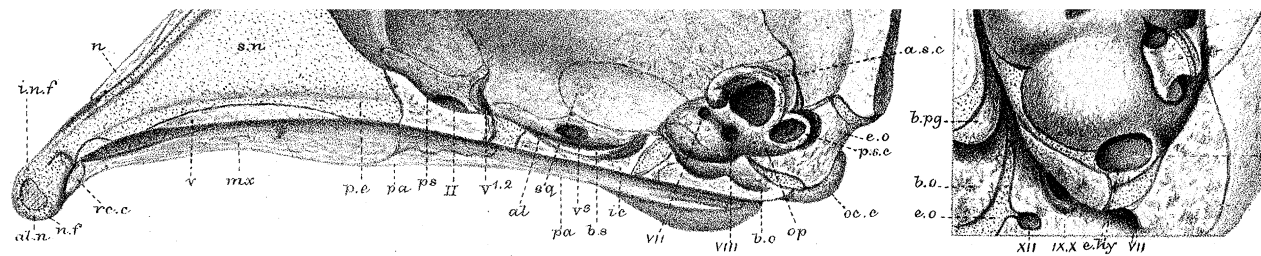
3a x 3 1/3



7 x 3 1/3

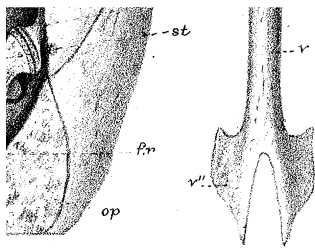






W.K.P. del. ad nat.
Parker & Coward lith.

Cycloturus.



West, Newman & Co. imp

PLATE 11.

Figures.		Number of times magnified.
1	Pangolin (<i>Manis</i> — ? sp.); embryo; $2\frac{1}{3}$ inches long (1st stage); skull; lower view*	4
2	The same; upper view	4
3	The same; side view	4
4	The same; end view	4
5	The same; os hyoides; upper view	4
6	The same; lower jaw and auditory region; inner view .	6
7	<i>Manis brevicaudata</i> ; embryo; $4\frac{2}{3}$ inches long (2nd stage); skull; side view	2
8	The same; under view	2

* All the parts behind *b.o.* and *oc.c.* should have been drawn in shade; they belong to the roof.

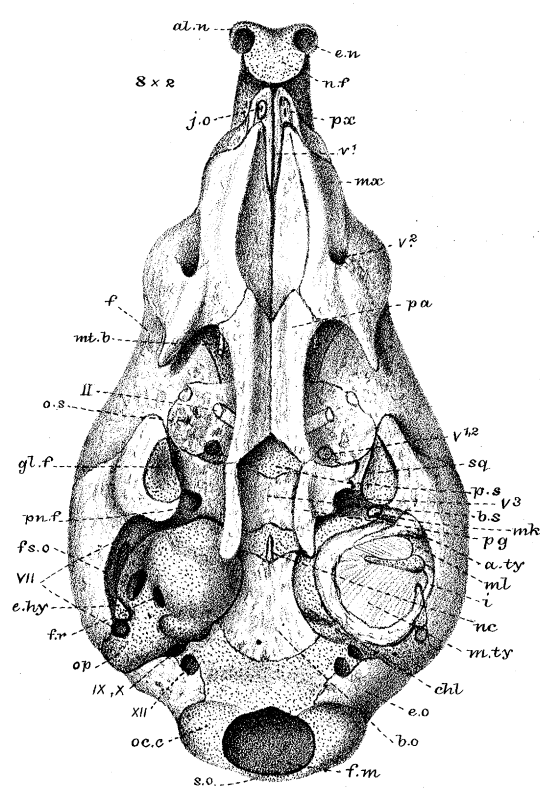
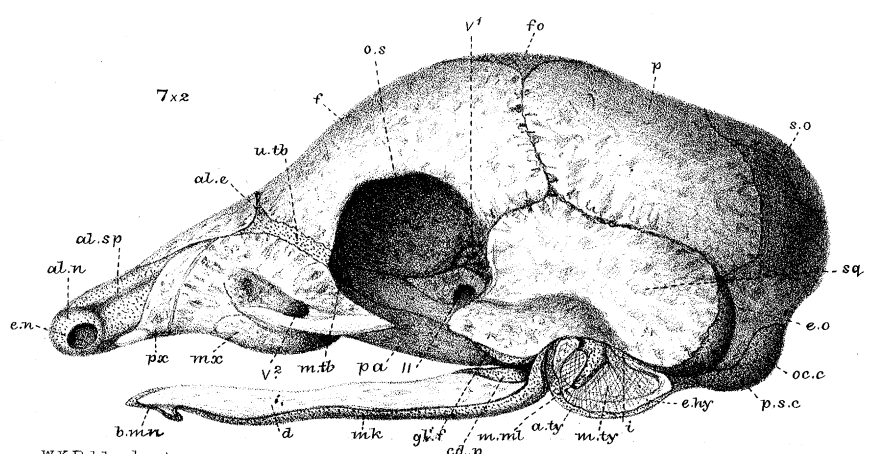
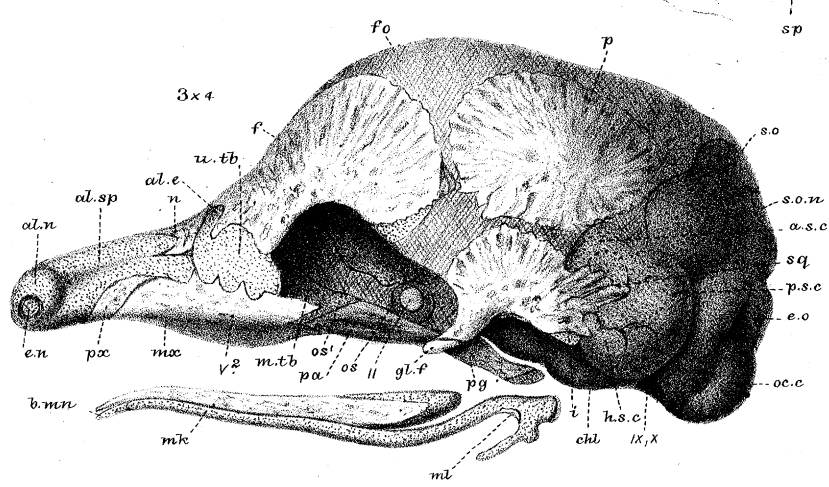
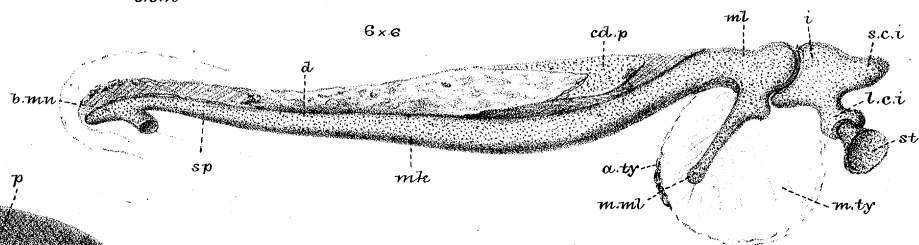
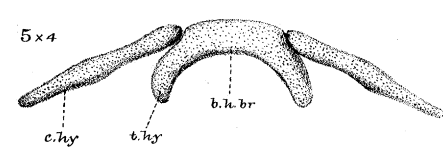
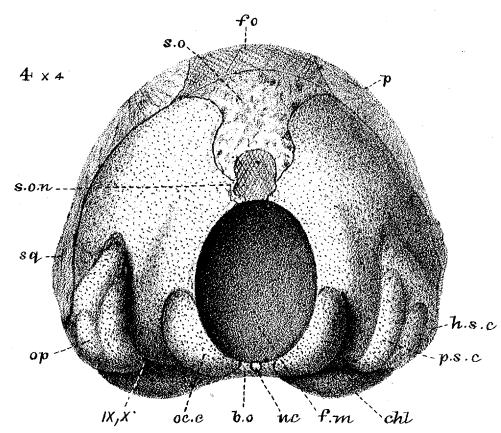
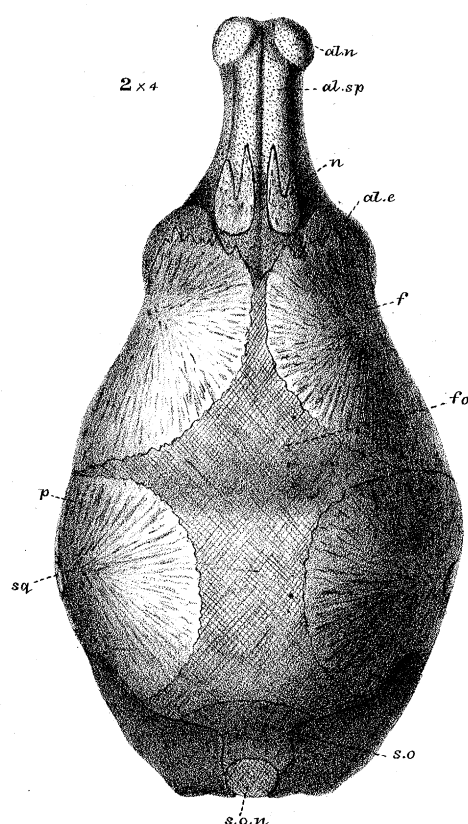
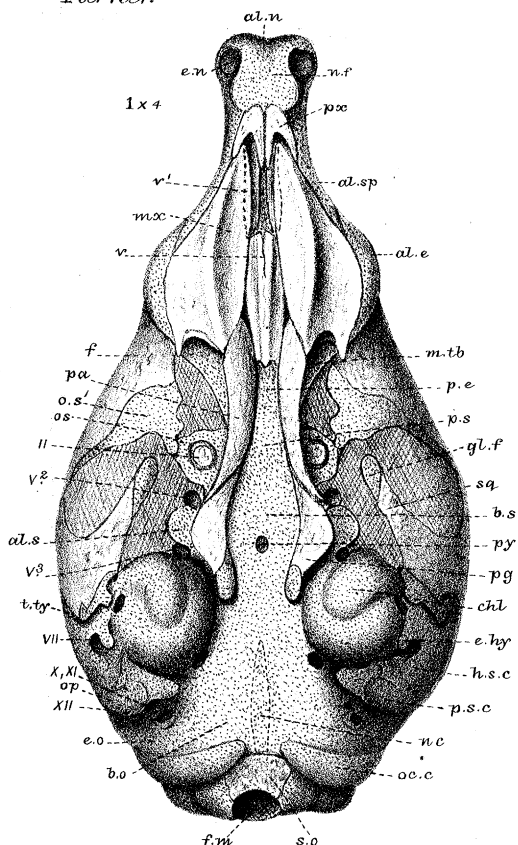


PLATE 12.

Figures.		Number of times magnified.
1	<i>Manis brevicaudata</i> (as in figs. 7 and 8 of last Plate); skull ; upper view*	3
2	The same ; end view	3
3	The same ; os hyoides ; inner view	3
4	The same ; lower jaw and ossicula auditûs ; inner view .	$4\frac{1}{2}$
5	The same ; both lower jaws ; fore part of under view .	$4\frac{1}{2}$
6	<i>Manis Temminckii</i> ; young ; 2nd day after birth ; head, 2 $\frac{1}{4}$ inches long (3rd stage) ; skull ; lower view . . .	2
7	The same ; upper view	2
8	The same ; side view	2
9	The same ; end view	2
10	Lower jaw ; inner view.	2
11	The same part ; with ossicula auditûs ; inner view . . .	$2\frac{2}{3}$
12	The same ; stapes and part of incus	8
13	The same ; os hyoides ; inner view	$2\frac{2}{3}$

* In any want of correspondence between the number of times a figure is said to be magnified, on the Plate, and in the descriptive page, the latter gives the true number.

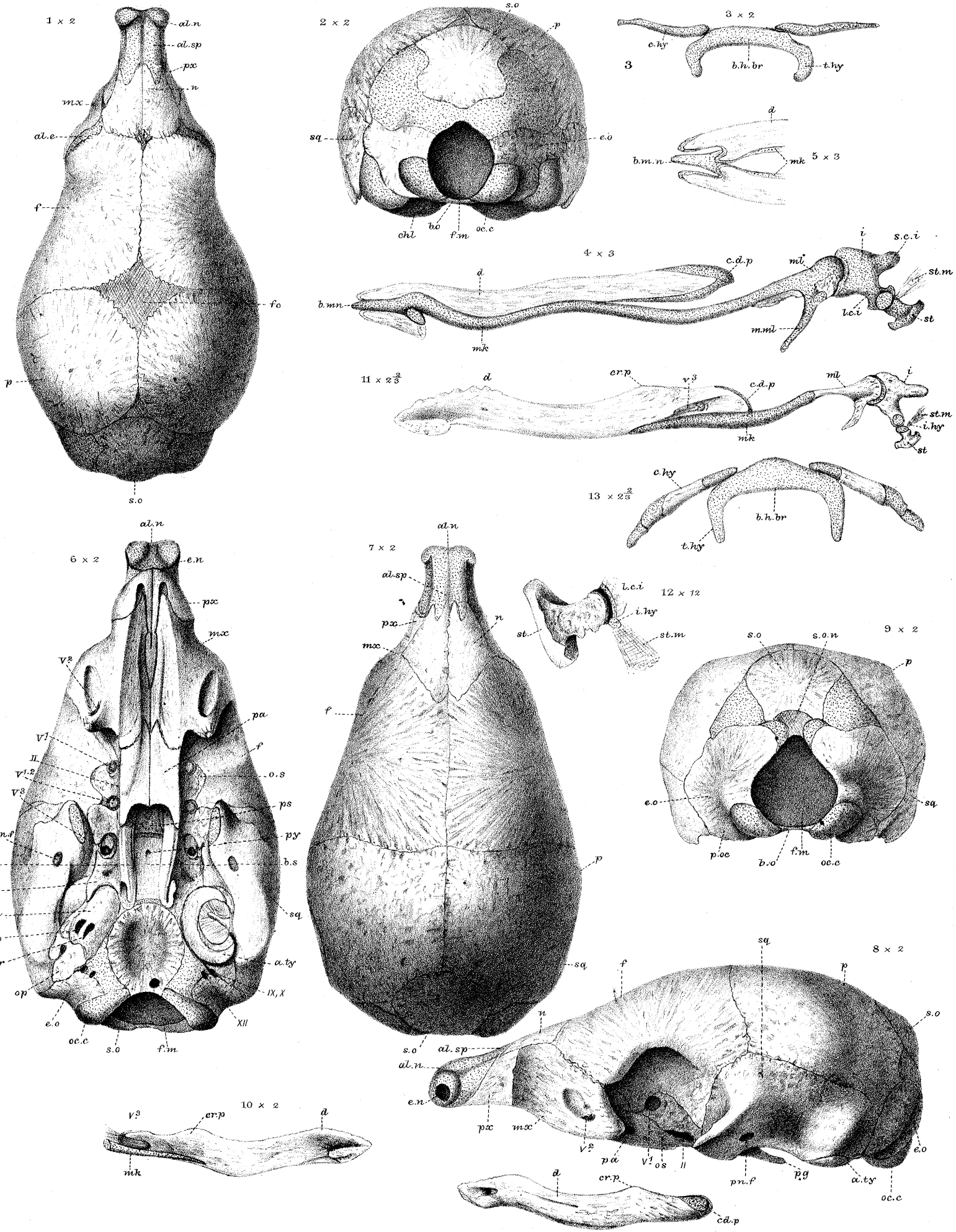
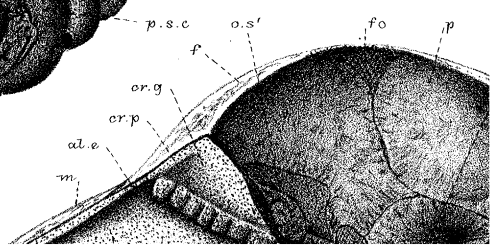
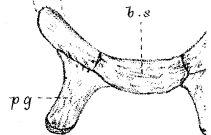
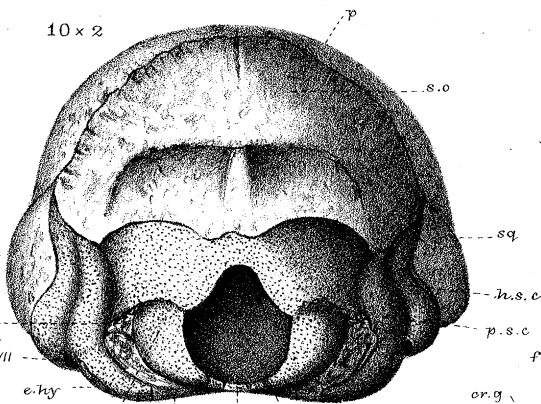
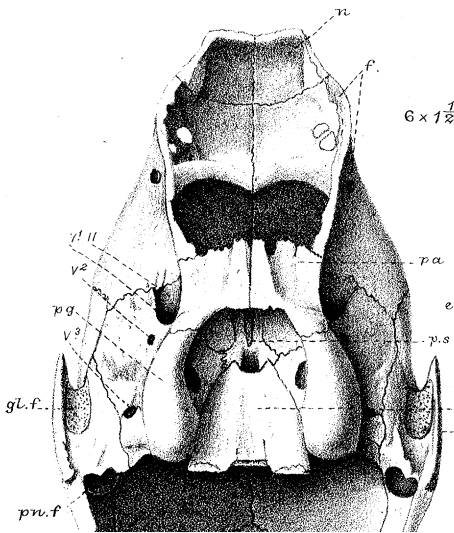
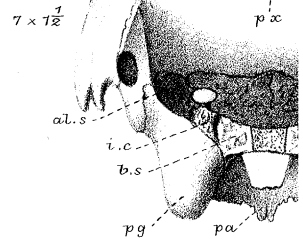
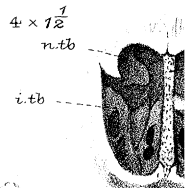
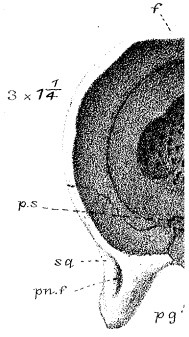
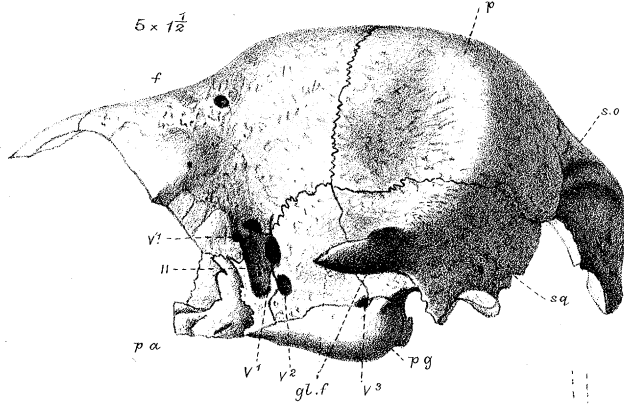
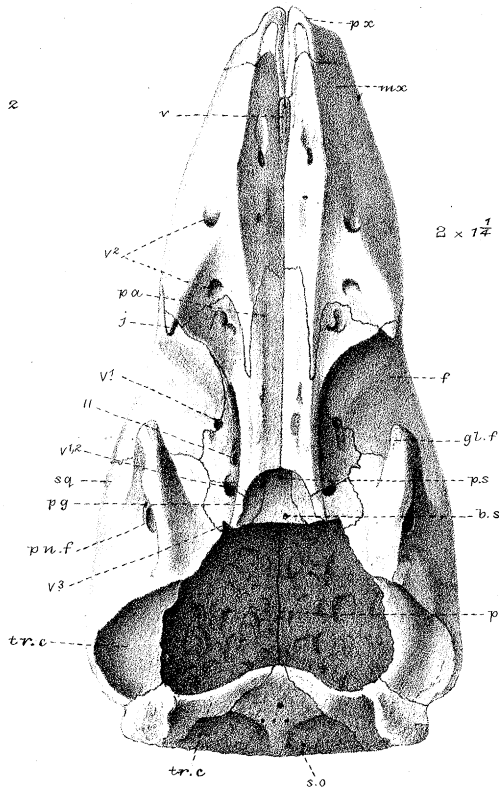
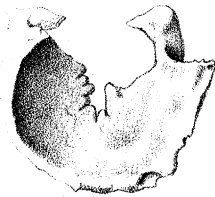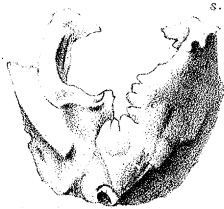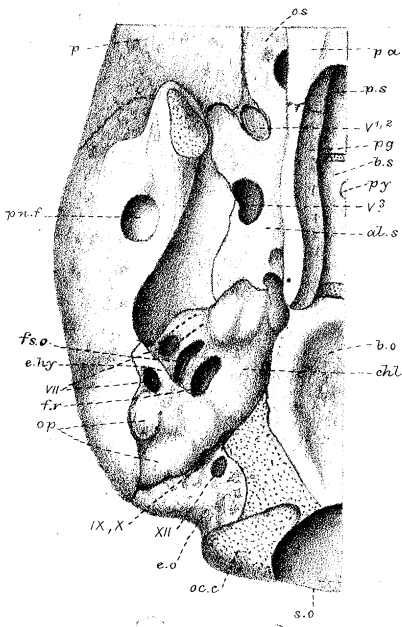
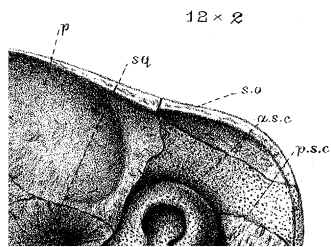
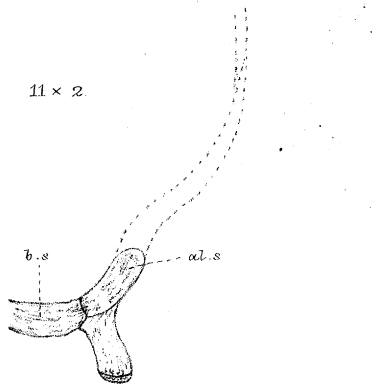
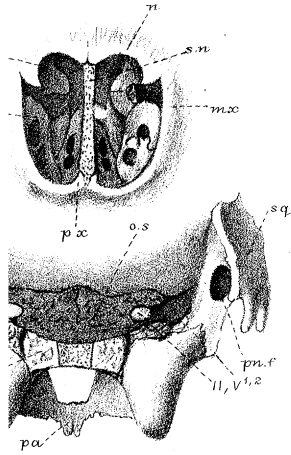
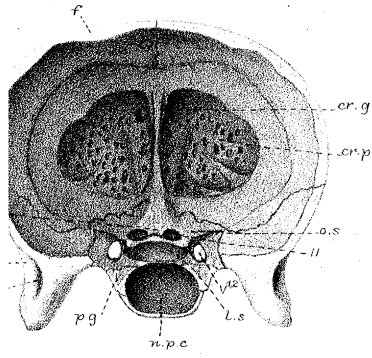
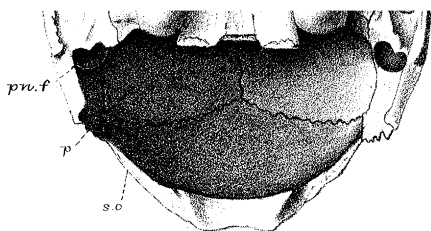


PLATE 13.

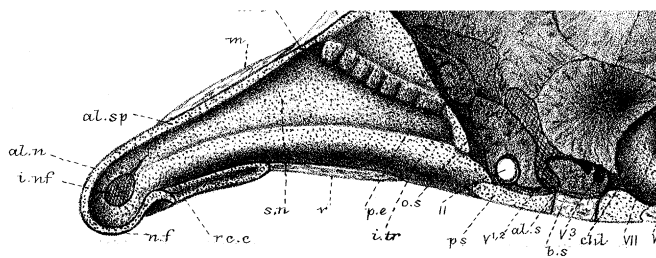
Figures.		Number of times magnified.
1	<i>Manis Temminckii</i> (3rd stage); left part of basis cranii; lower view	3
2	<i>Manis</i> — ? sp.; adult (4th stage); skull; part of lower view	$1\frac{1}{4}$
3	The same; cribriform plate; hinder view	$1\frac{1}{4}$
4	The same; front view of nasal region	$1\frac{1}{2}$
5	<i>Bradypus tridactylus</i> , Linn.; half-grown (4th stage); part of skull; side view	$1\frac{1}{2}$
6	The same; lower view	$1\frac{1}{2}$
7	The same; hinder view	$1\frac{1}{2}$
8	The same; os tympanicum; outer view	2
9	The same; inner view	2
10	<i>Bradypus (Arctopithecus)</i> (2nd stage); skull; hind view	2
11	The same; section of basisphenoidal region	2
12	<i>Manis brevicaudata</i> (2nd stage); vertical section of skull; inner view	3



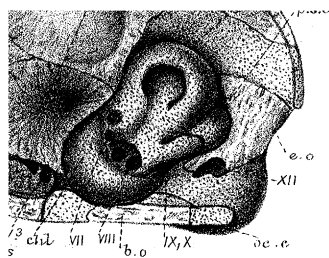




W.E.P. del. ad nat.
Parker & Coward. hth.



1-4, & 12, Manis. 5-11, Bradypus.



Wes. Newman & Co. Eng.

PLATE 14.

Figures.		Number of times magnified.
1	<i>Aard-Vark (Orycteropus capensis)</i> ; nearly ripe embryo; skull; lower view*	$1\frac{1}{2}$ nearly
2	The same; upper view	do.
3	The same; side view	do.
4	The same; hind view	do.
5	The same; vomerine region; lower view	3

* These figures should have been marked $\times 1\frac{1}{3}$ and $\times 2\frac{2}{3}$, like those of the next Plate.

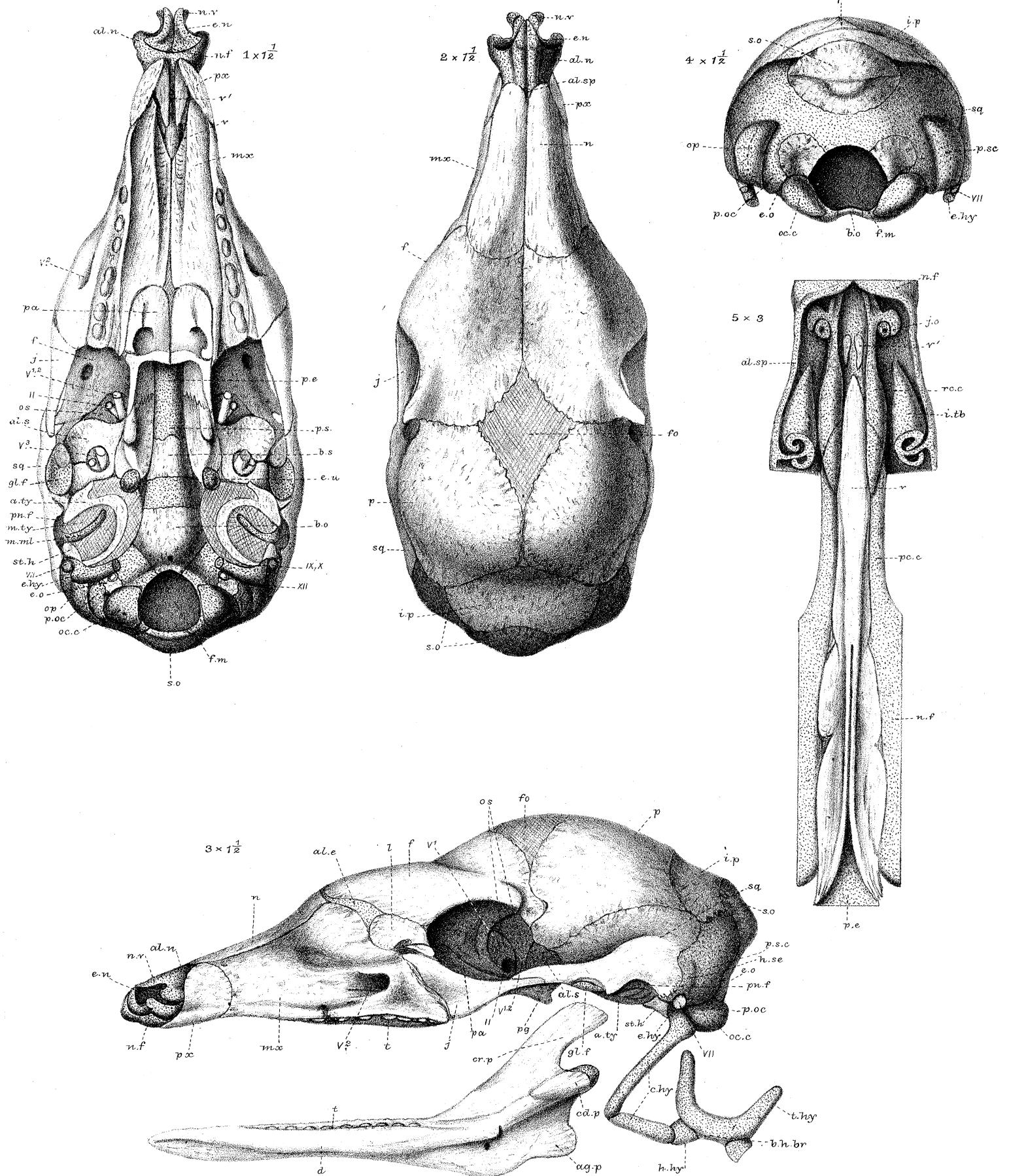
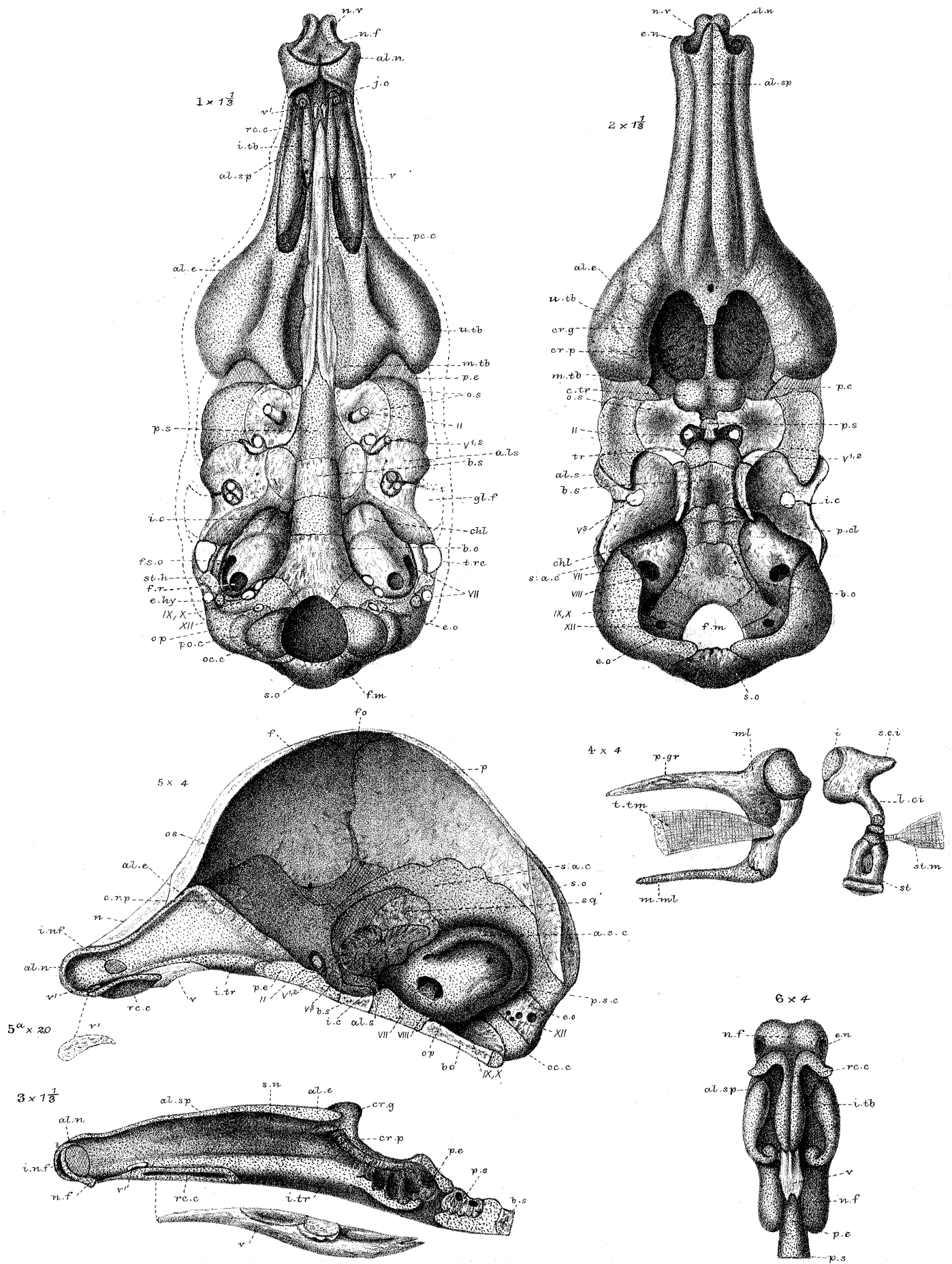
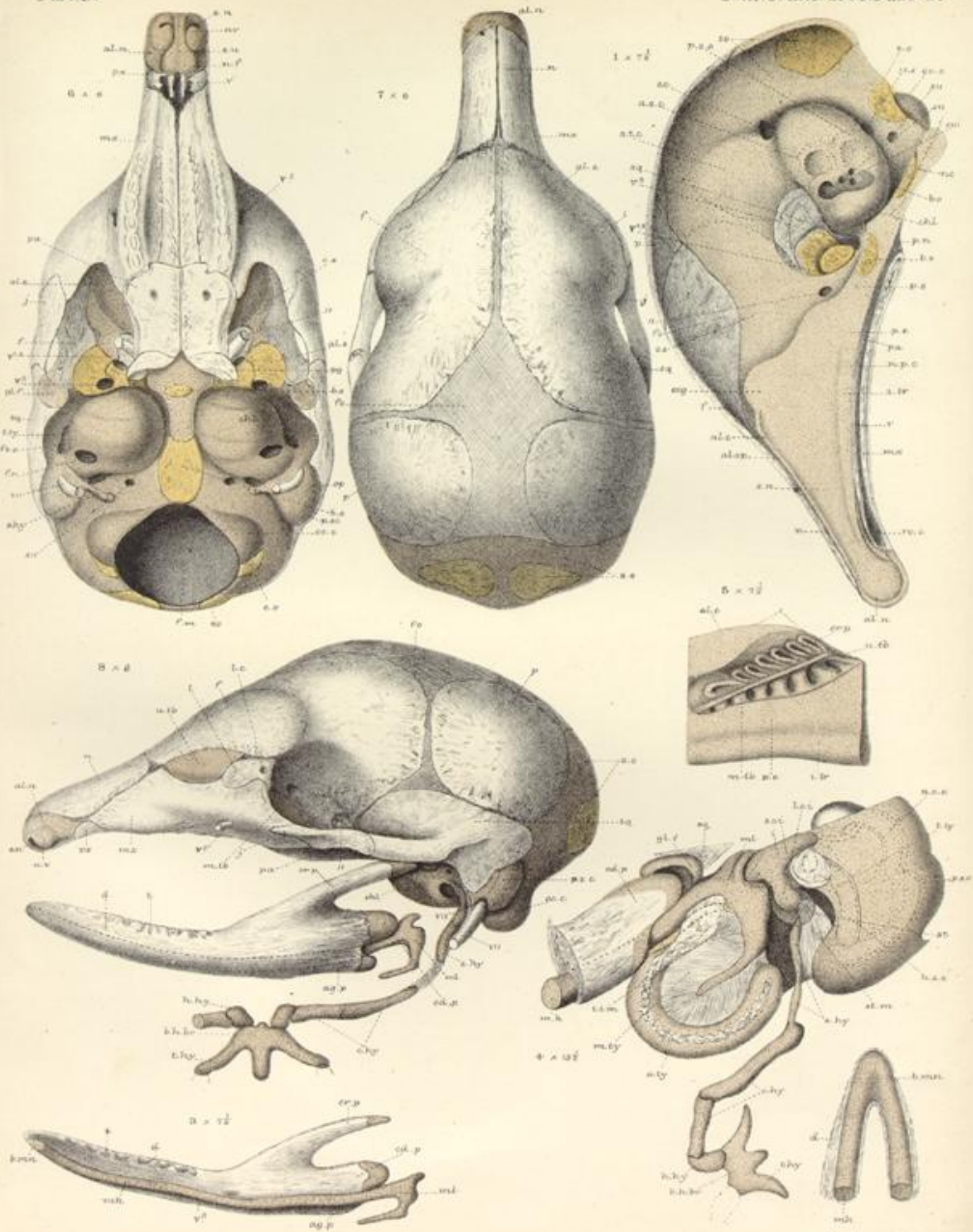
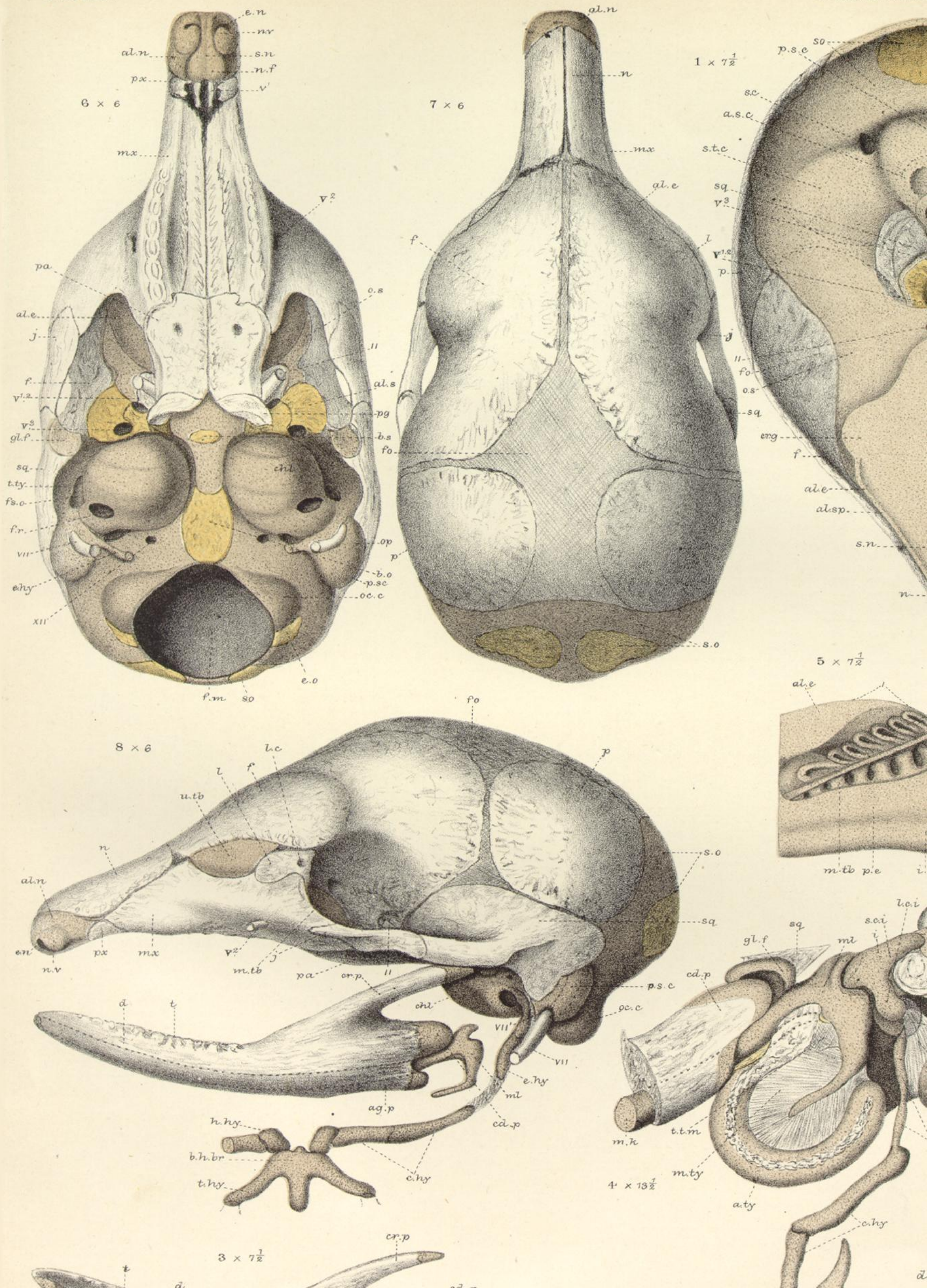


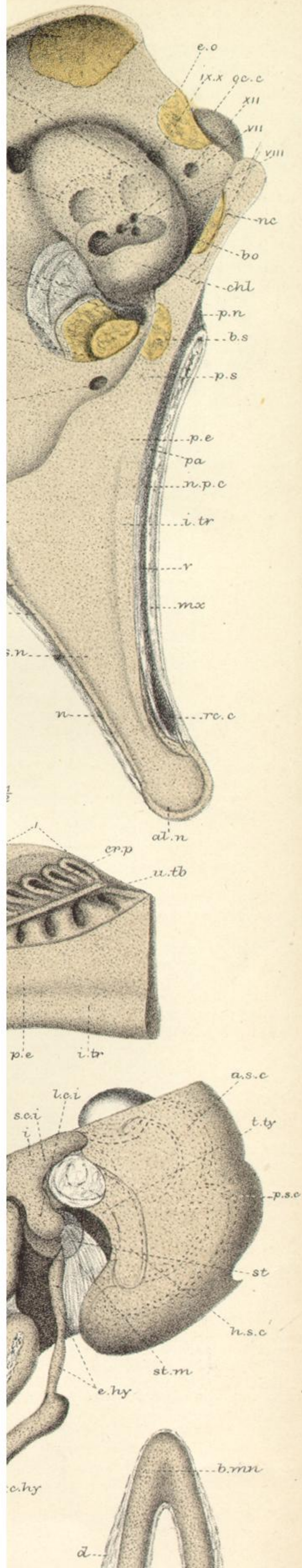
PLATE 15.

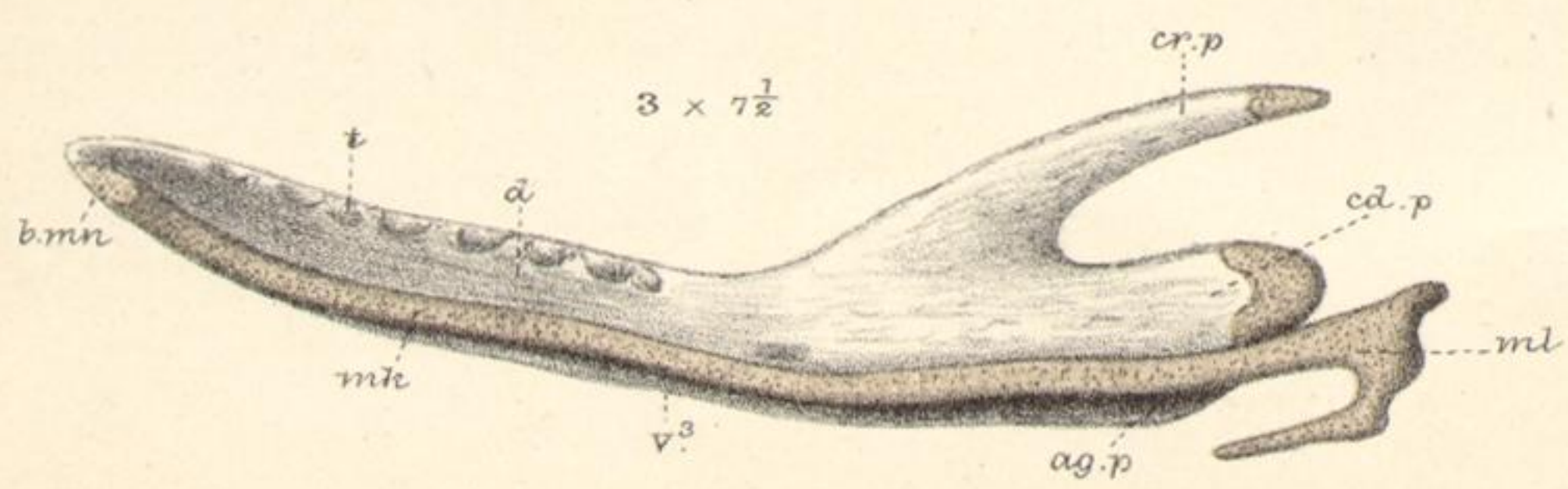
Figures.		Number of times magnified.
1	<i>Orycteropus capensis</i> (continued); endocranium; lower view	$1\frac{1}{2}$ nearly
2	The same; upper view	do.
3	The same; septum nasi and vomer; side view	do.
4	The same; ossicula auditûs; inner view	4
5	<i>Cholopus didactylus</i> (?) (1st stage), vertical section of skull; inner view	4
5A	The same; separate; anterior paired vomer	20
6	The same; vomerine region of skull; lower view . . .	4



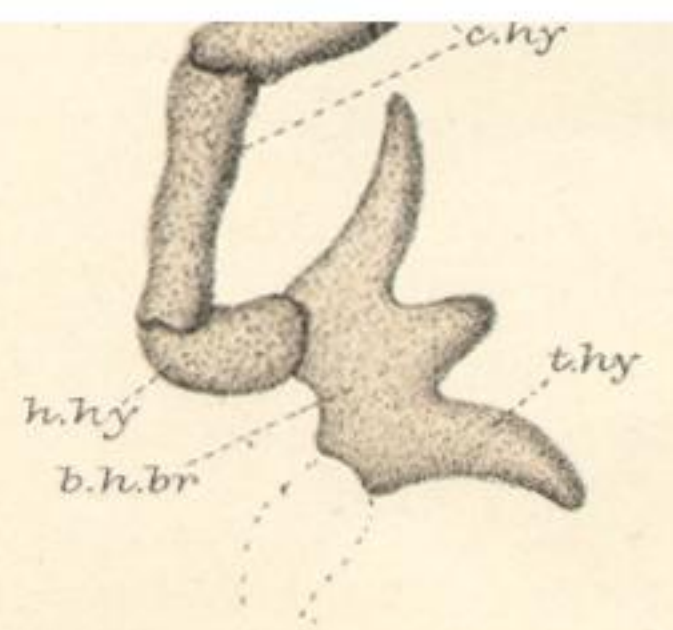




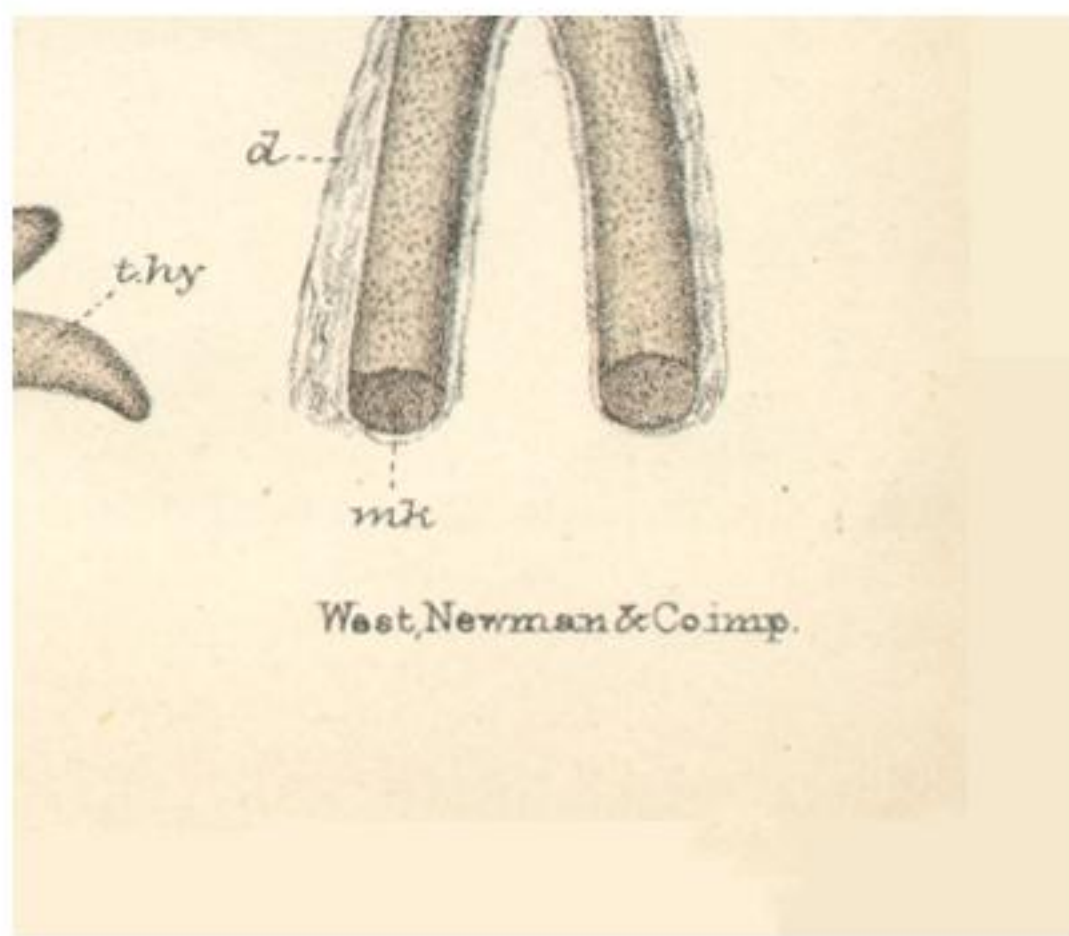


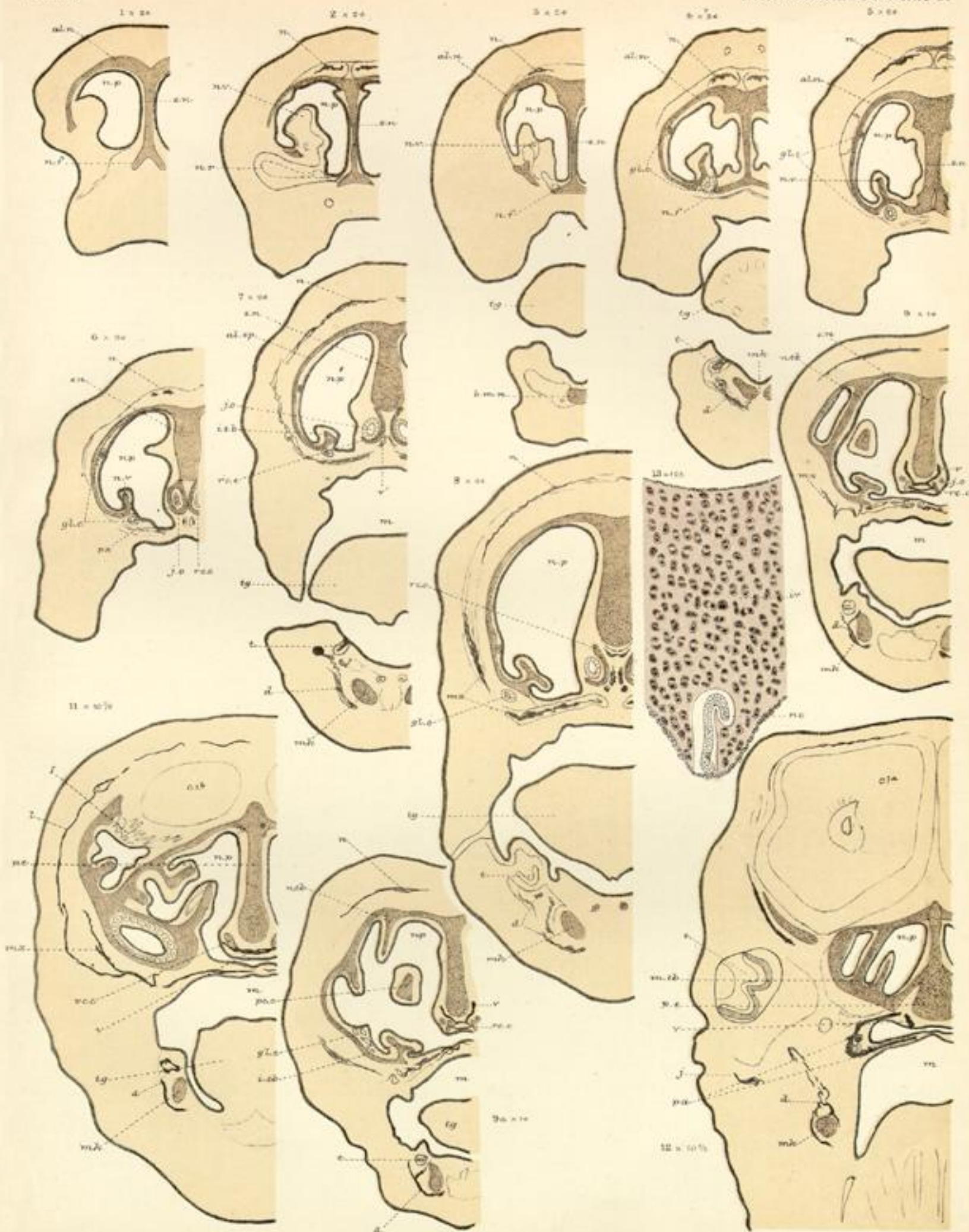


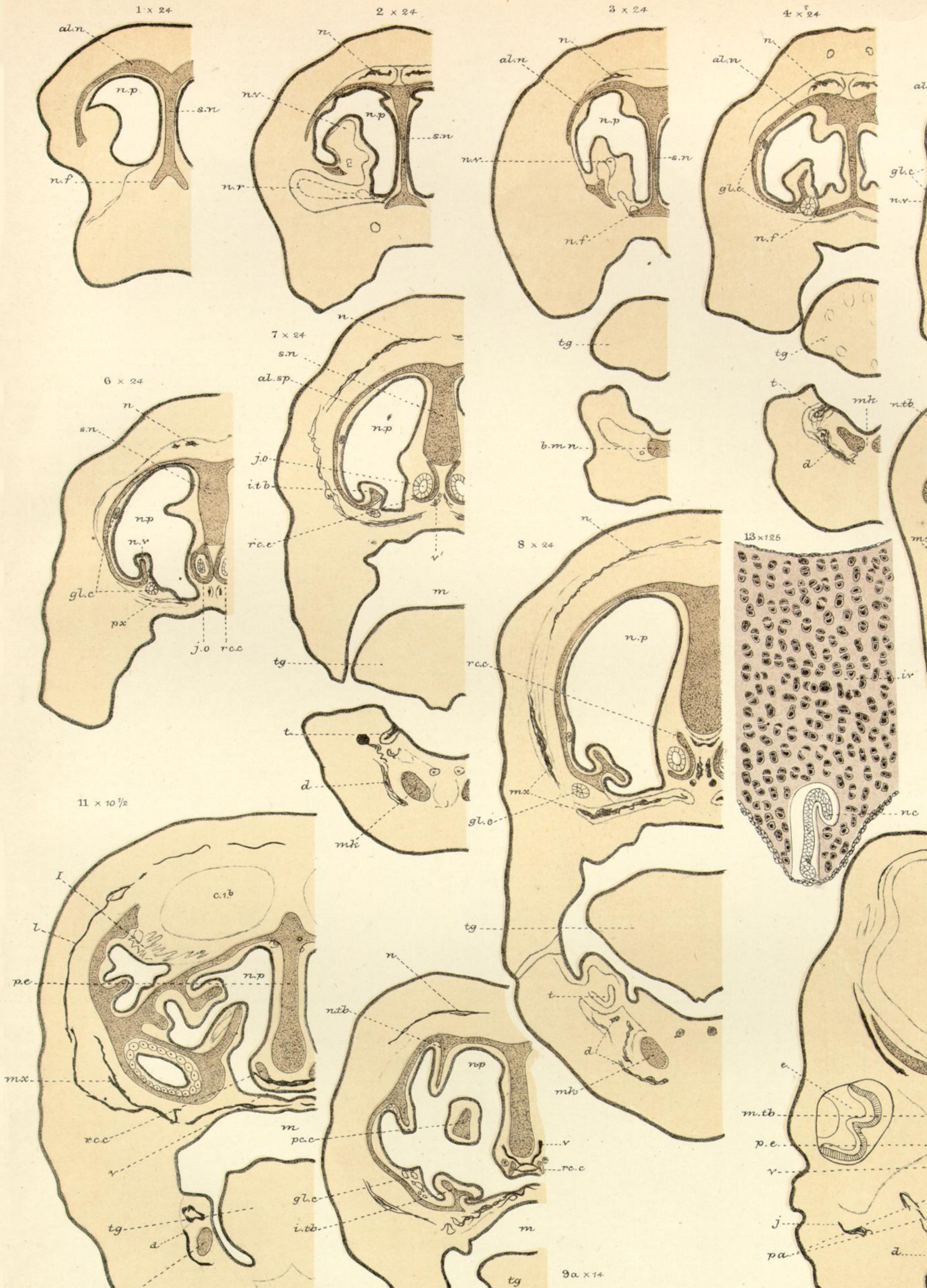
Parker & Coward lith.
W.K.P. del.

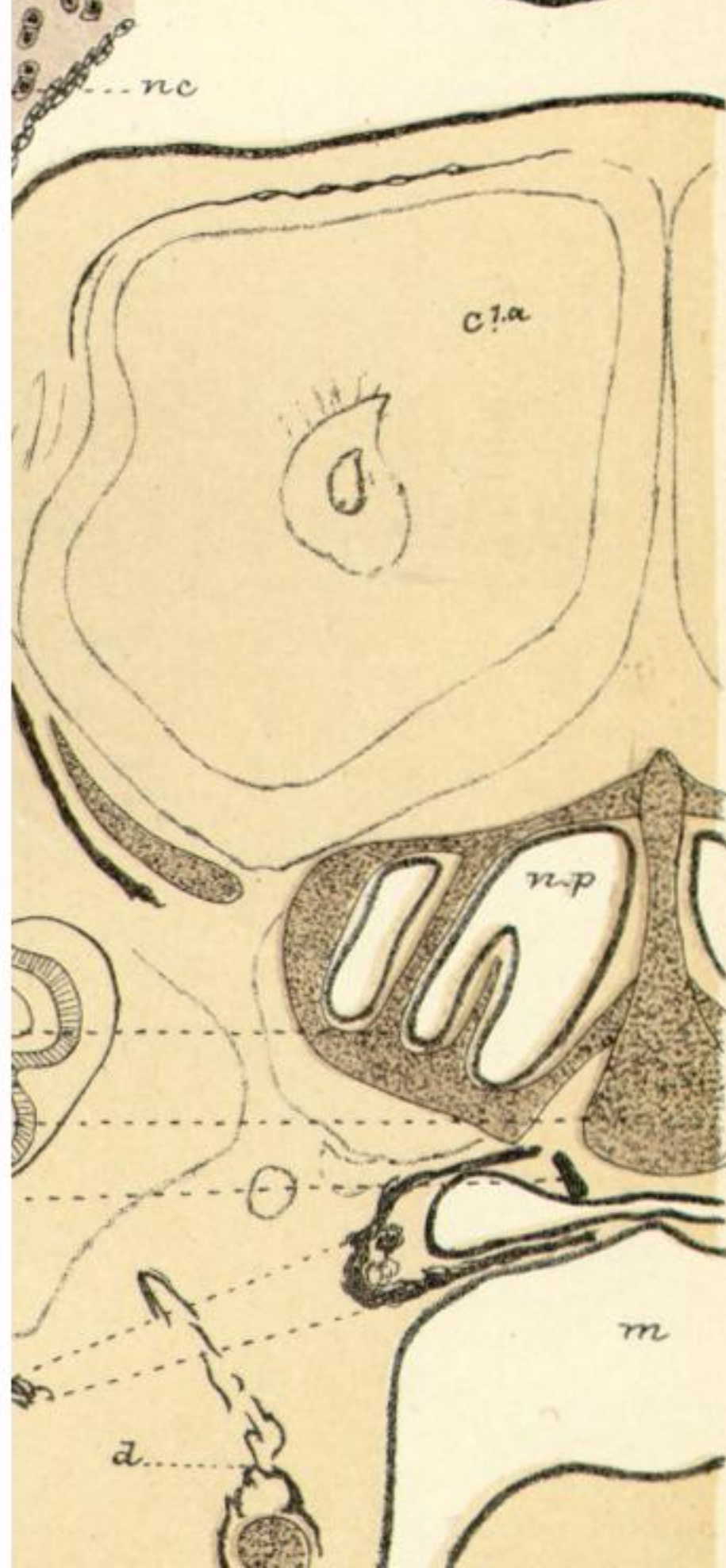
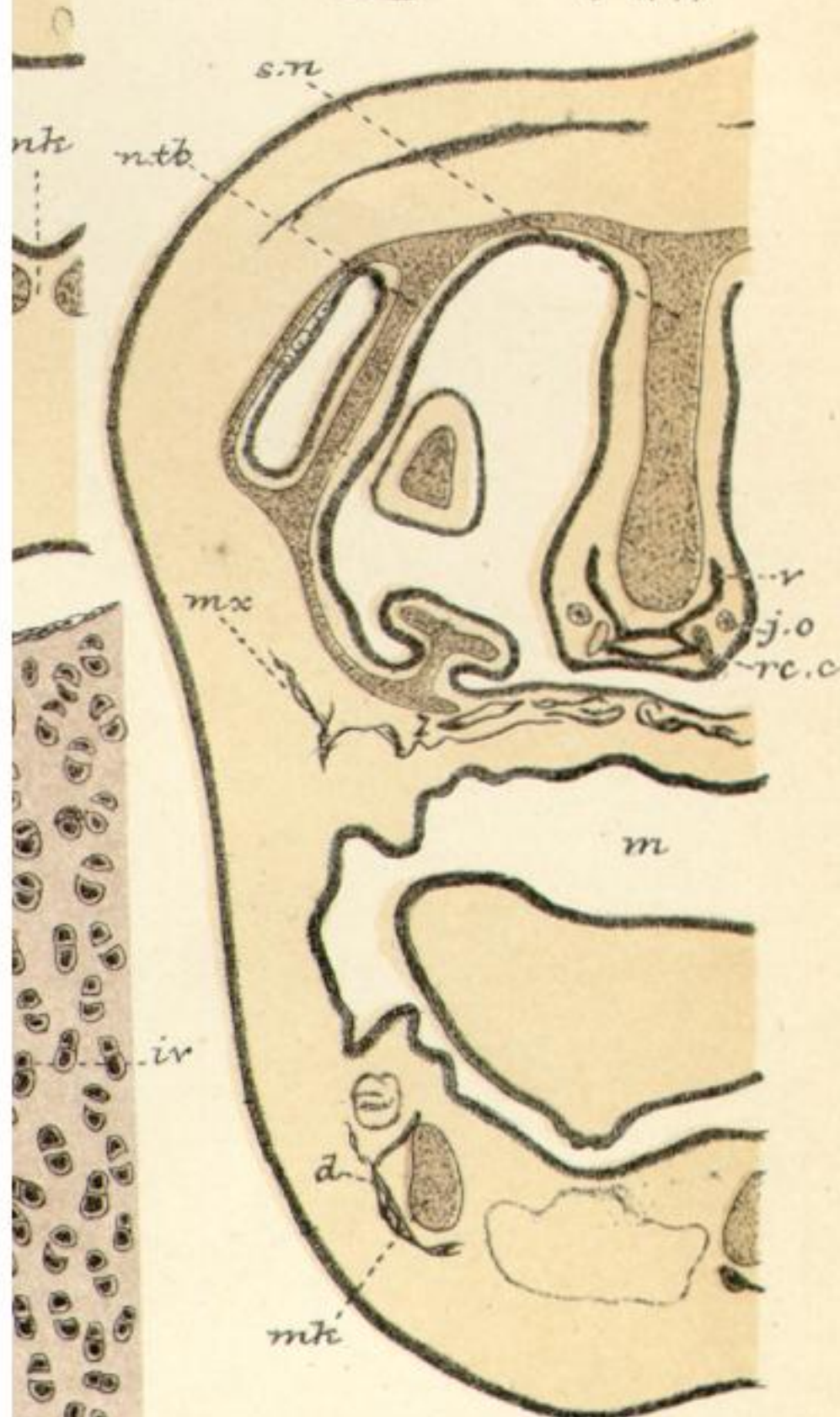
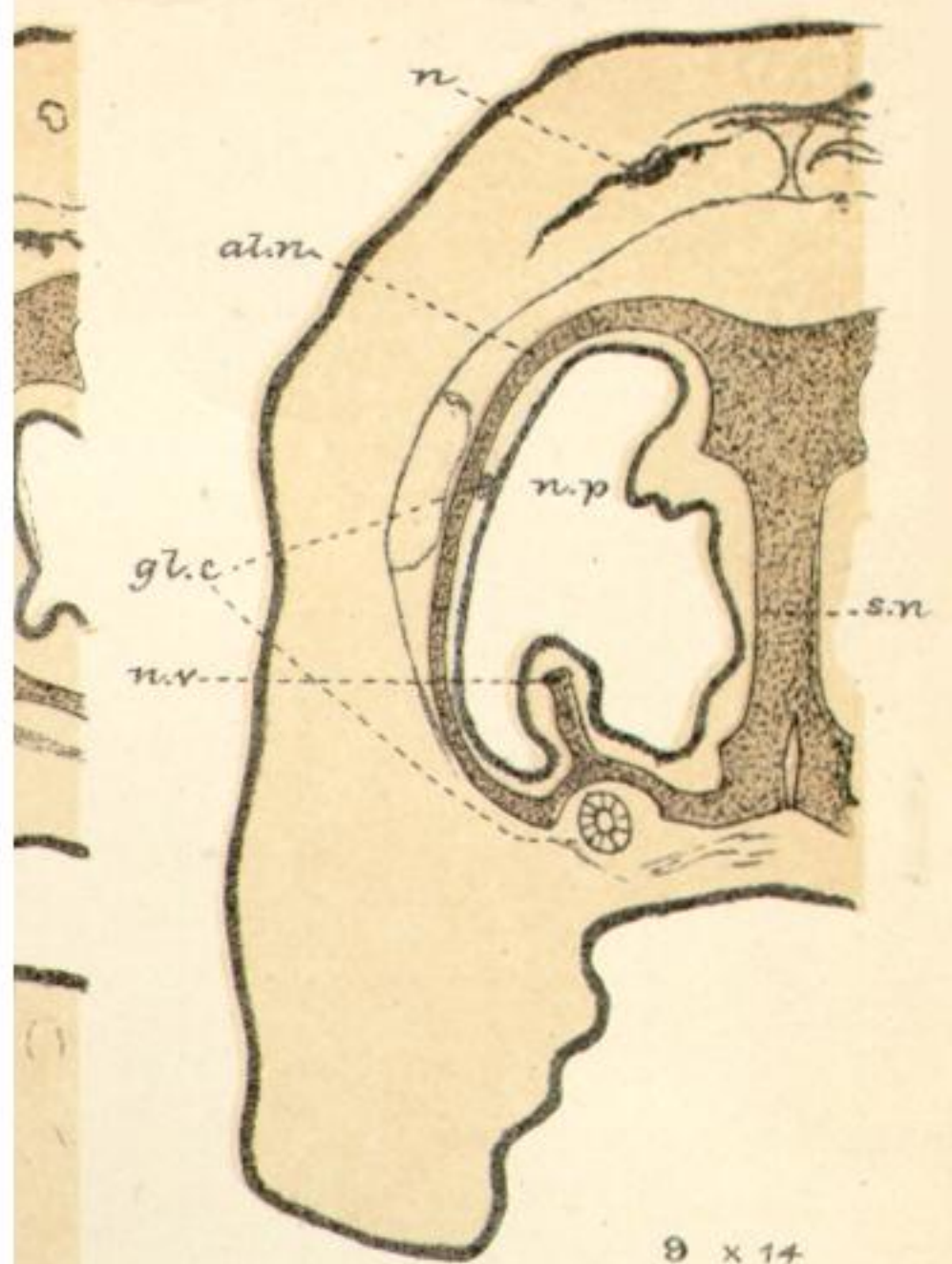


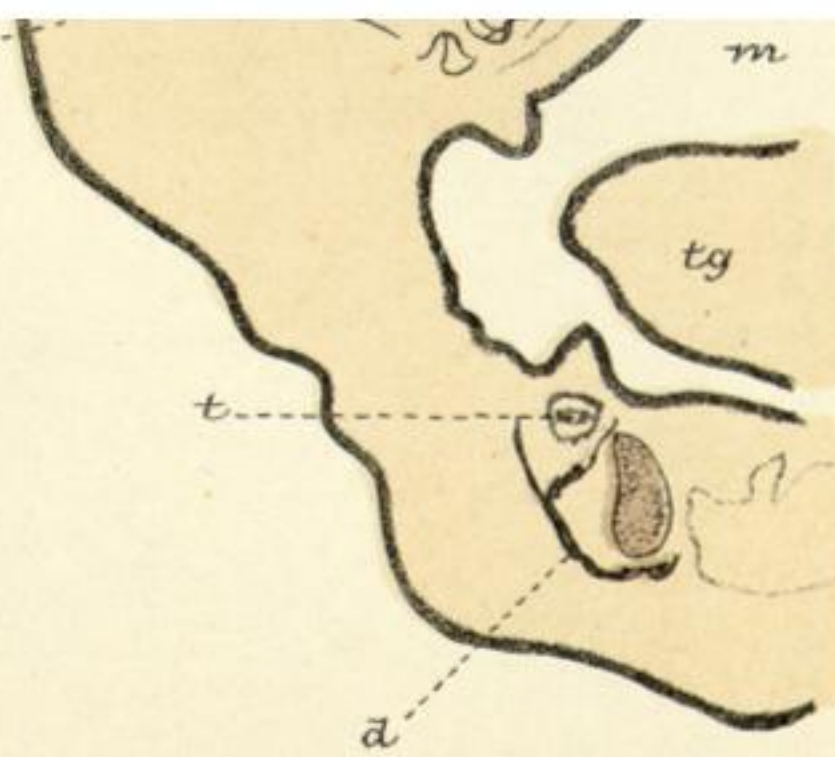
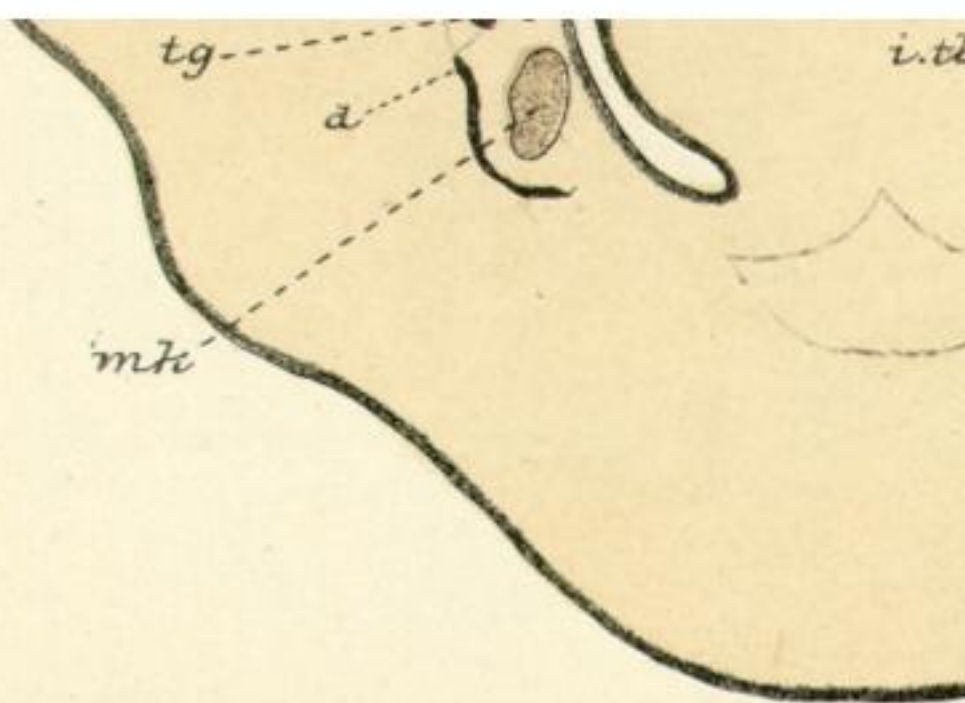
Tatusia hybrida.



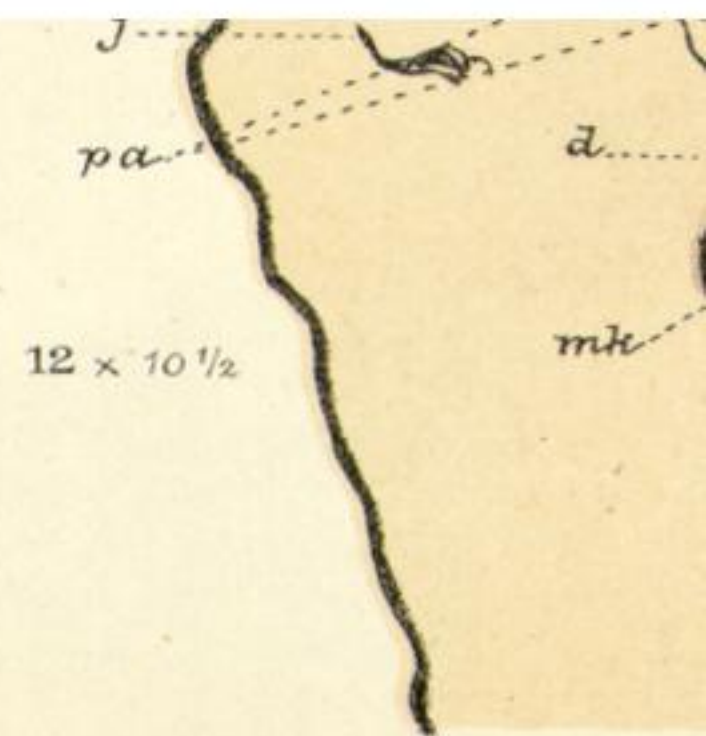








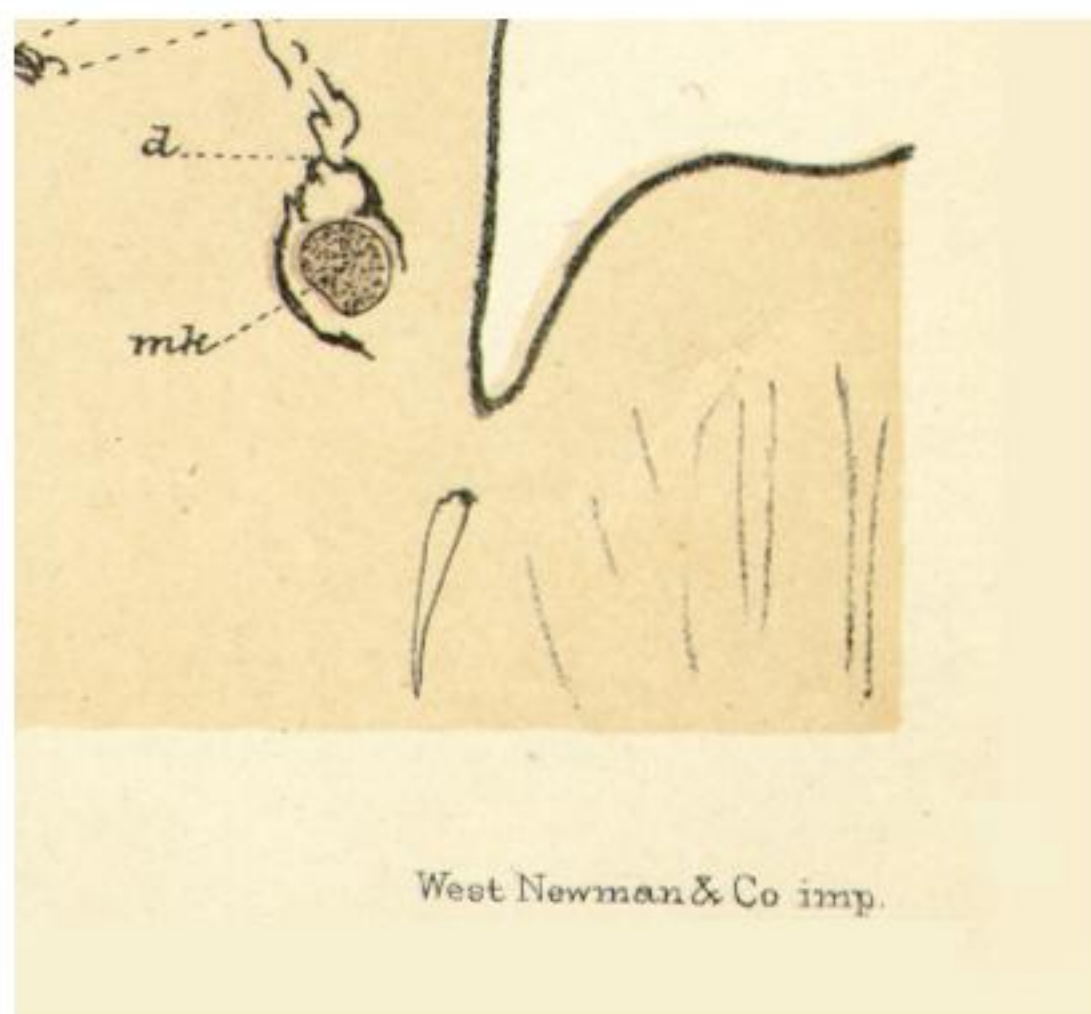
9a x 14

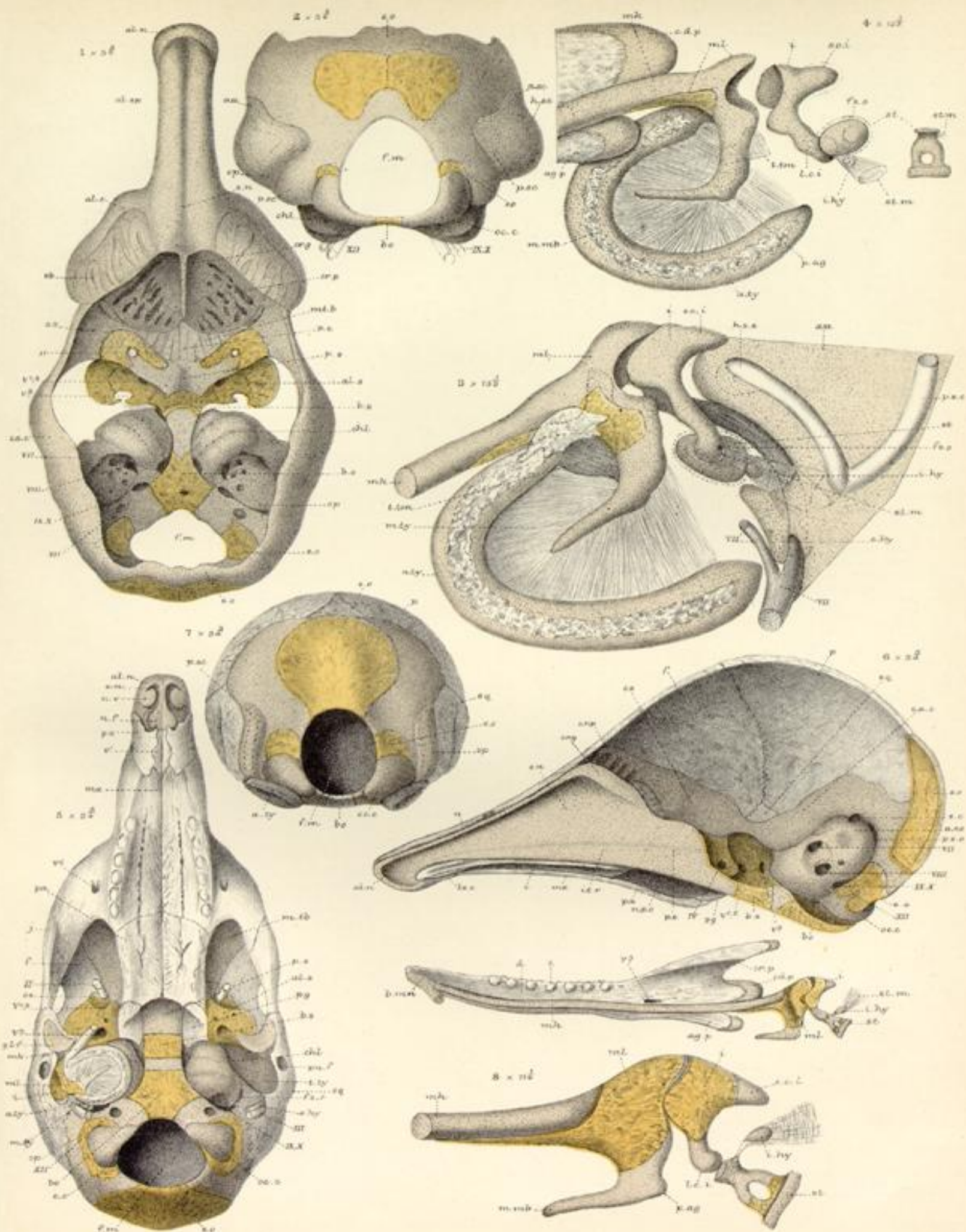


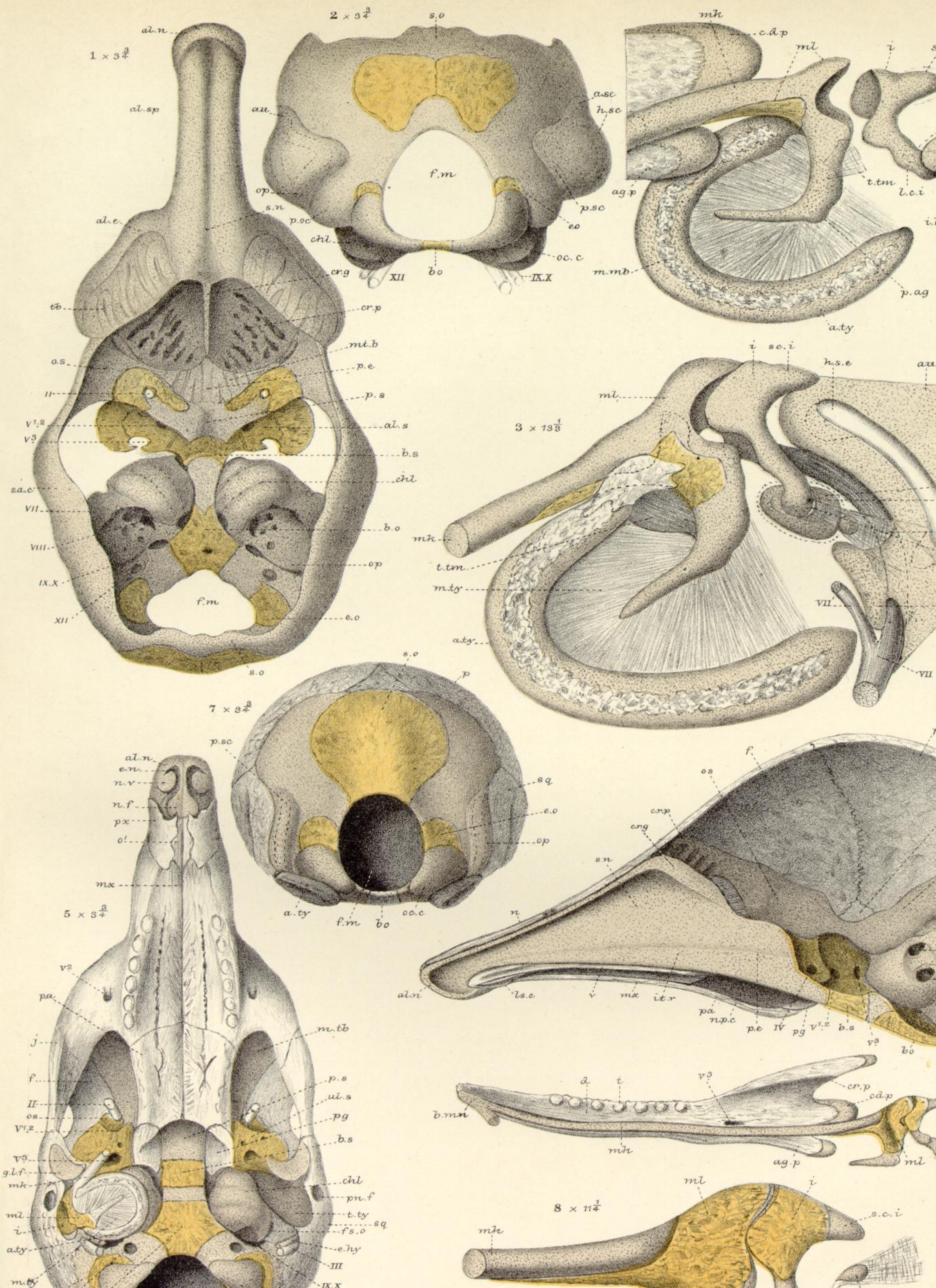12 x 10 1/2

Parker & Coward del et lith
W.K.P. dir.

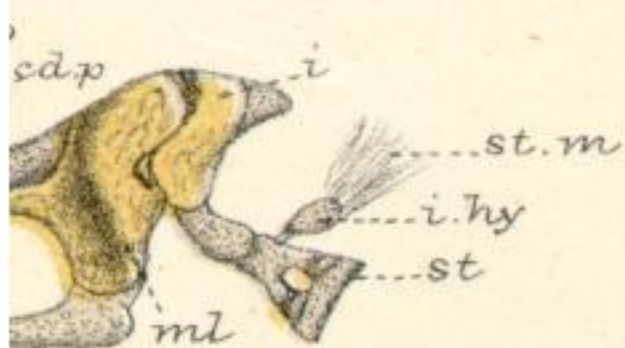
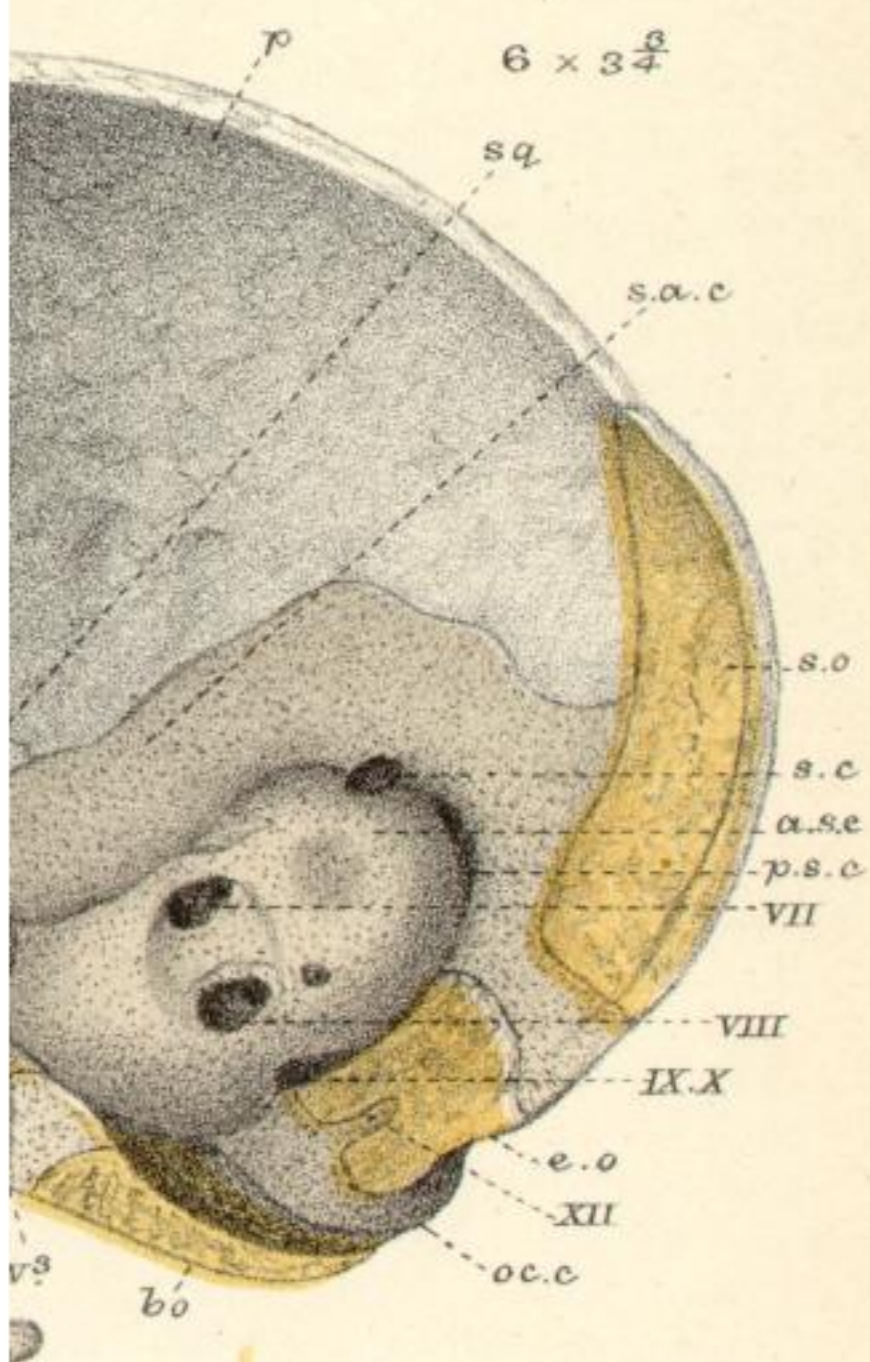
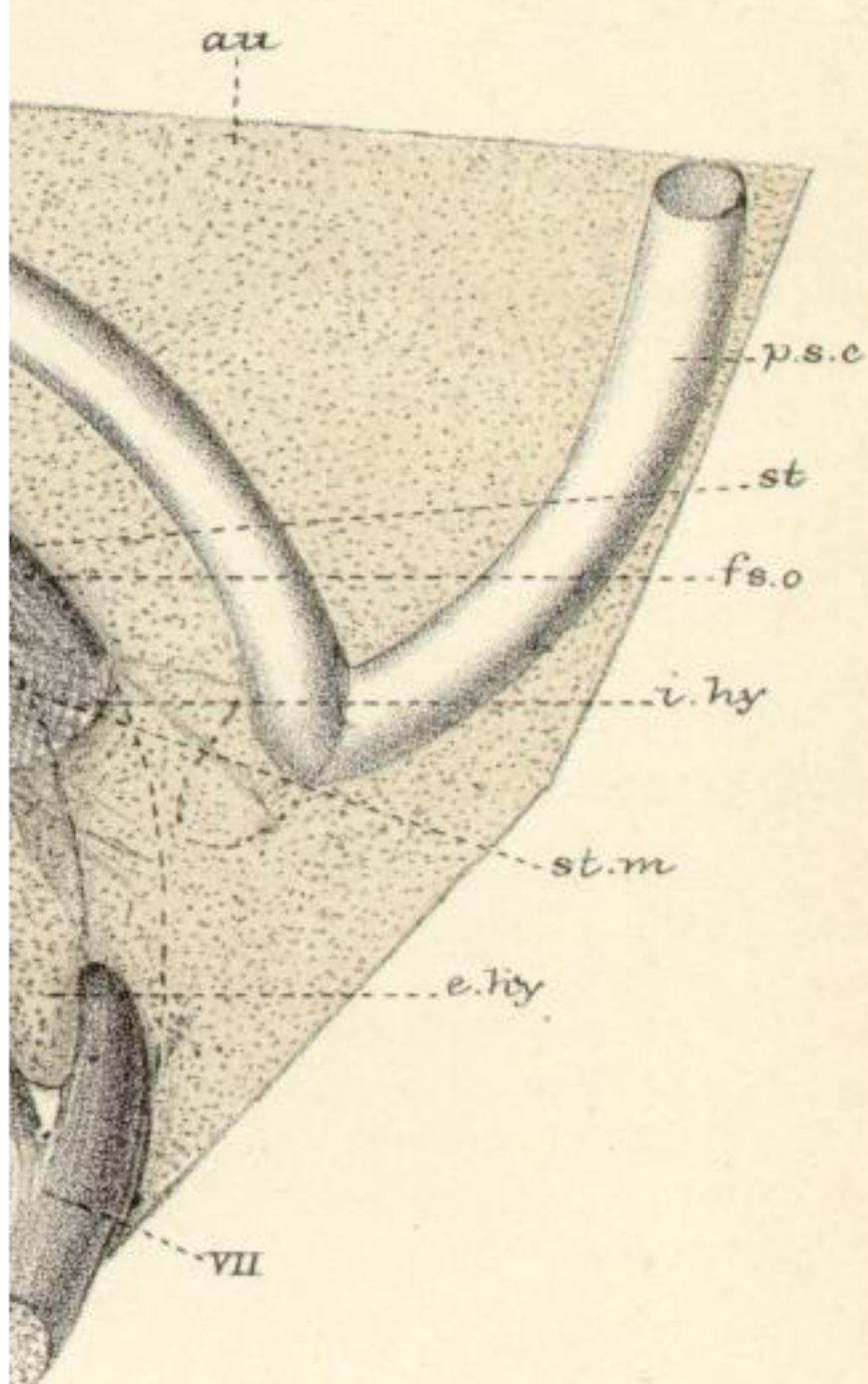
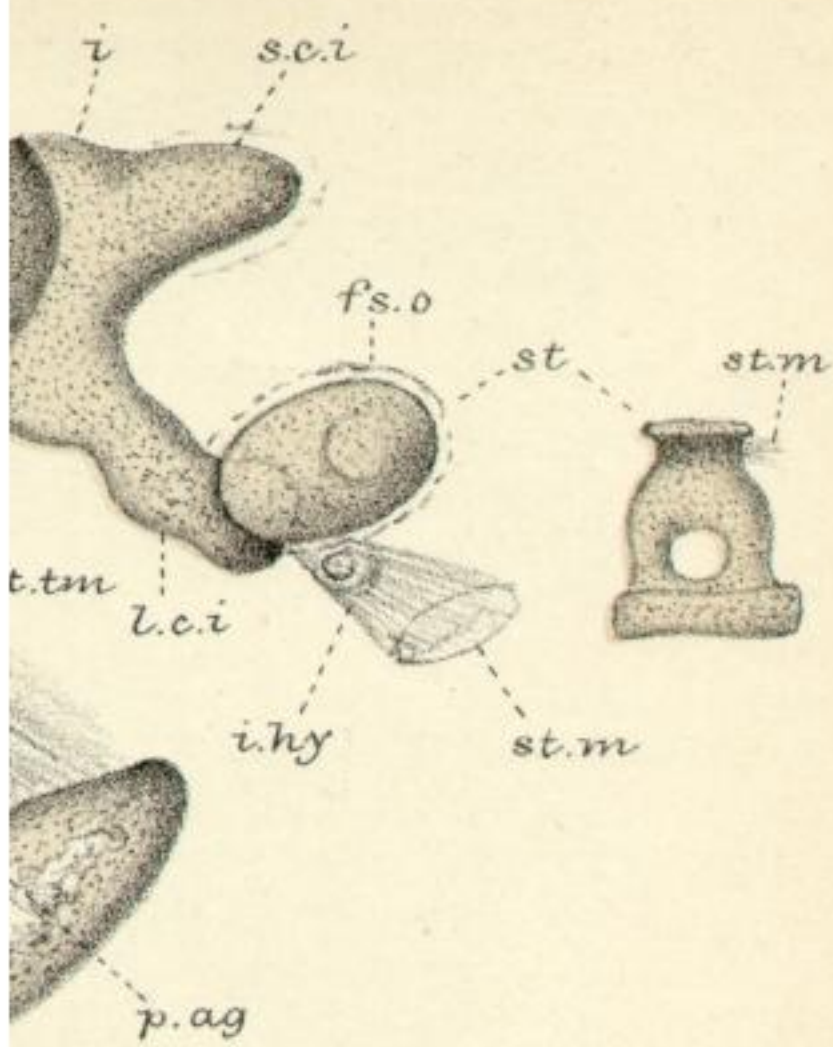
Tatusia hybrida.



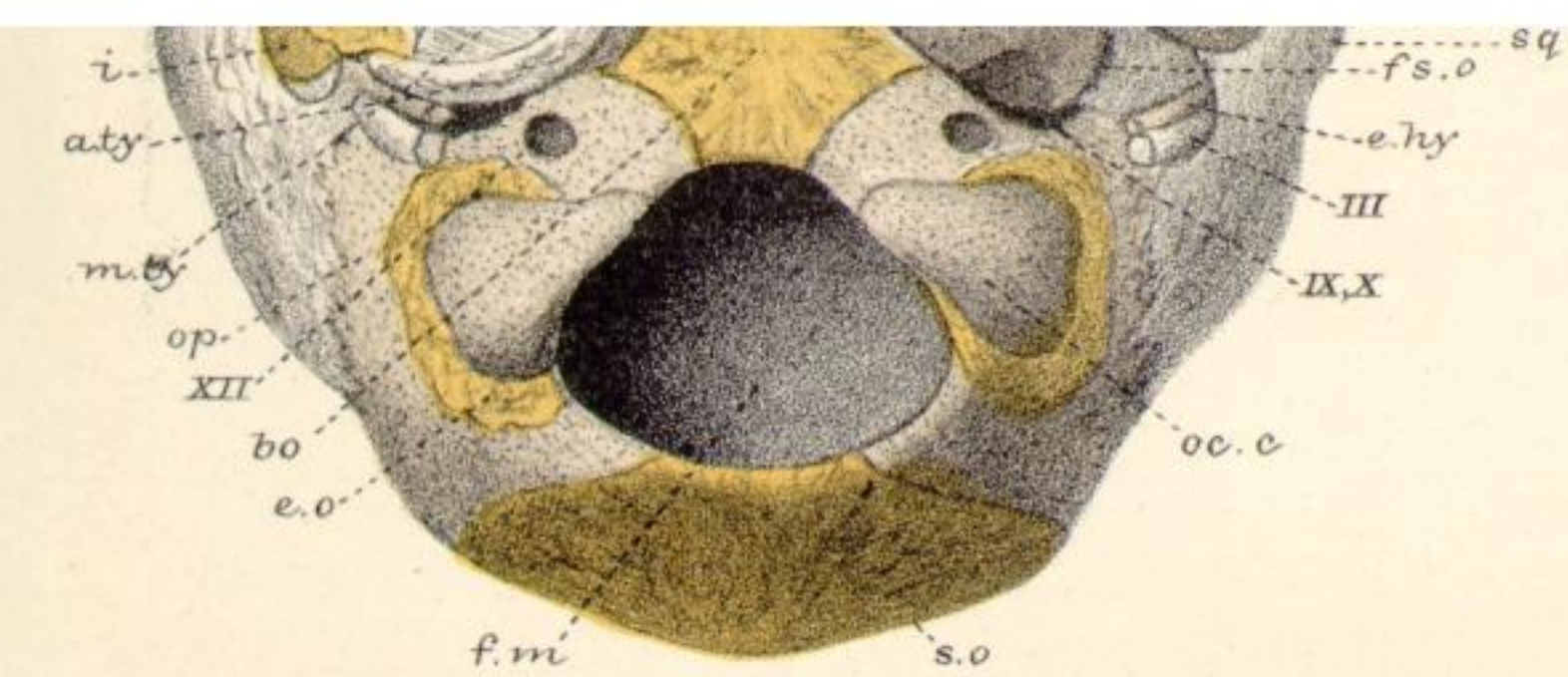




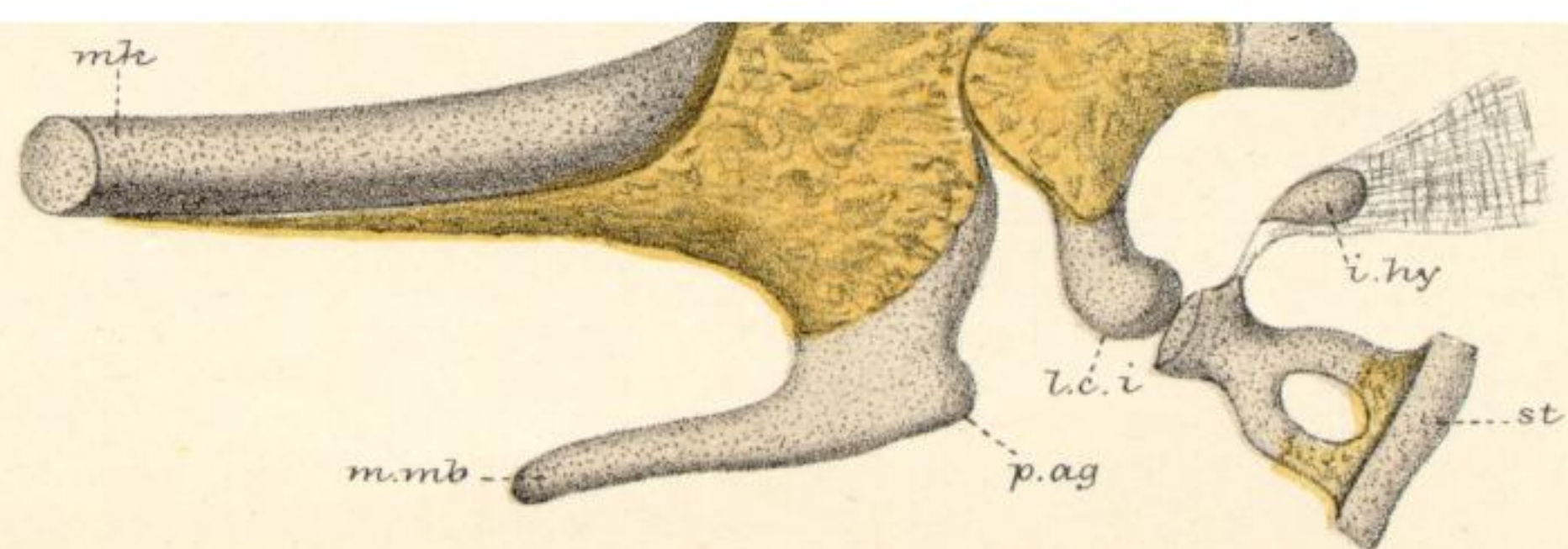
$4 \times 13\frac{1}{3}$



s.c.i



W.K.P. del.
Parker & Coward lith.



1-4, Tatusia hybrida; 5-8, T. peba.

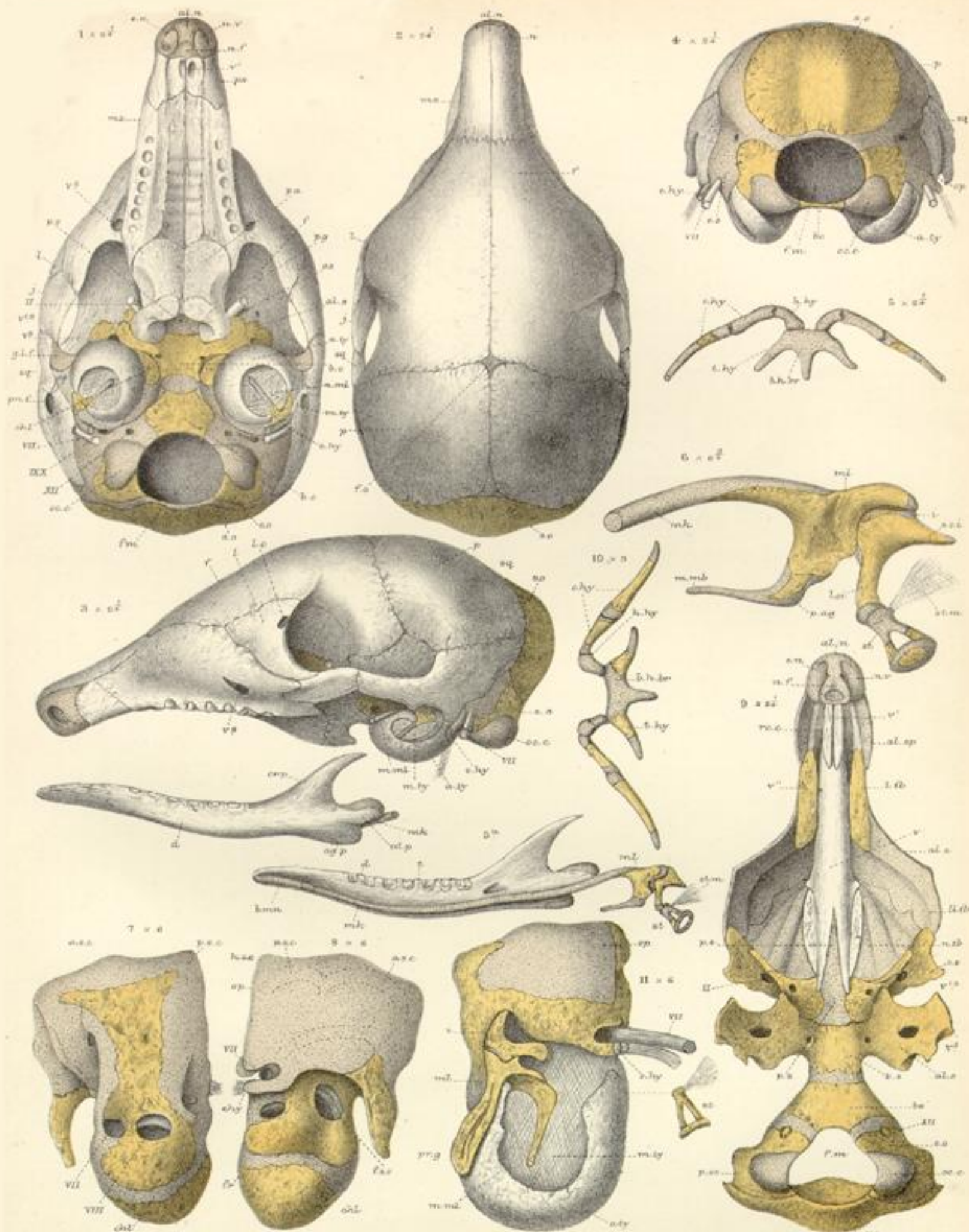


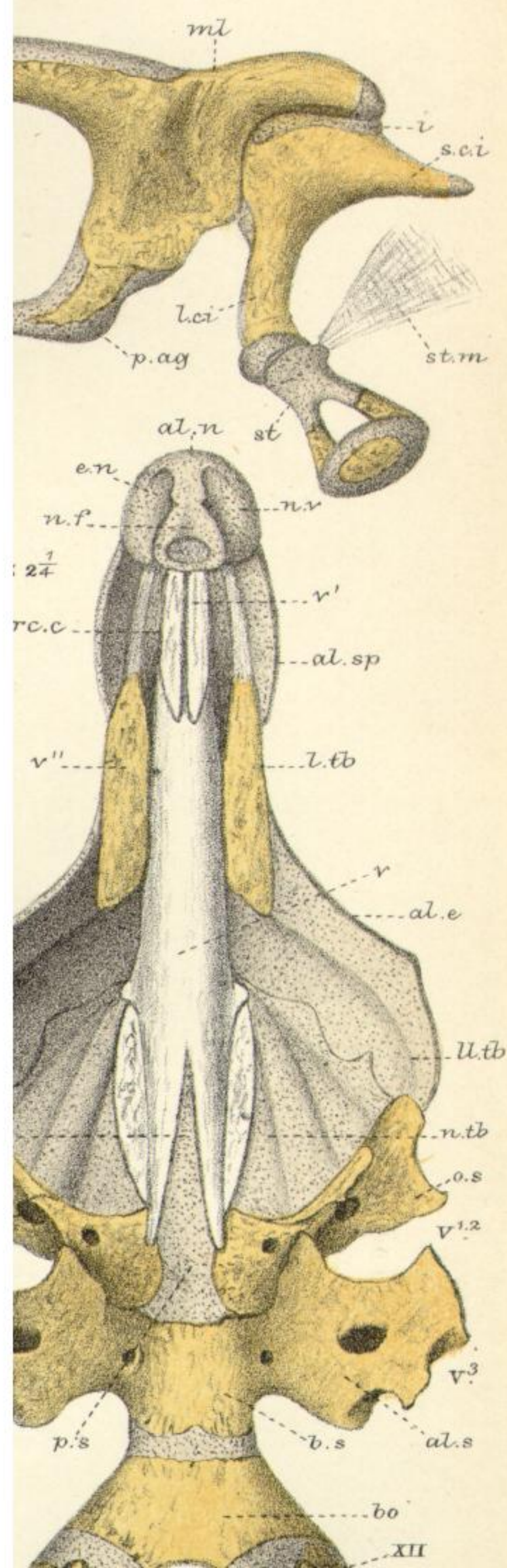
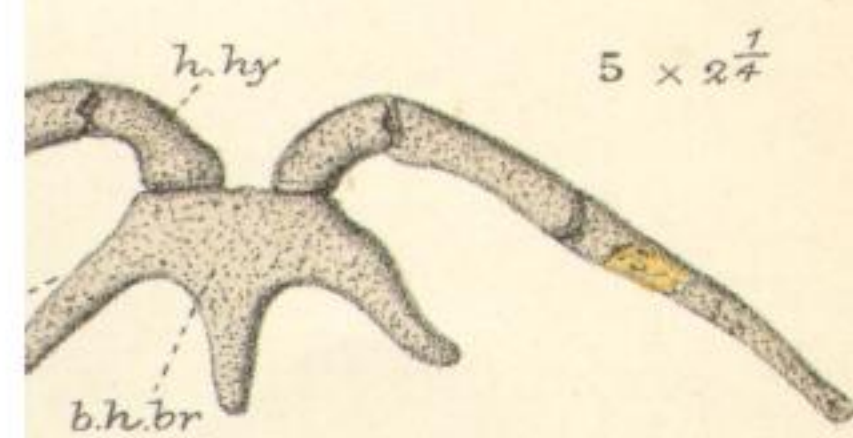
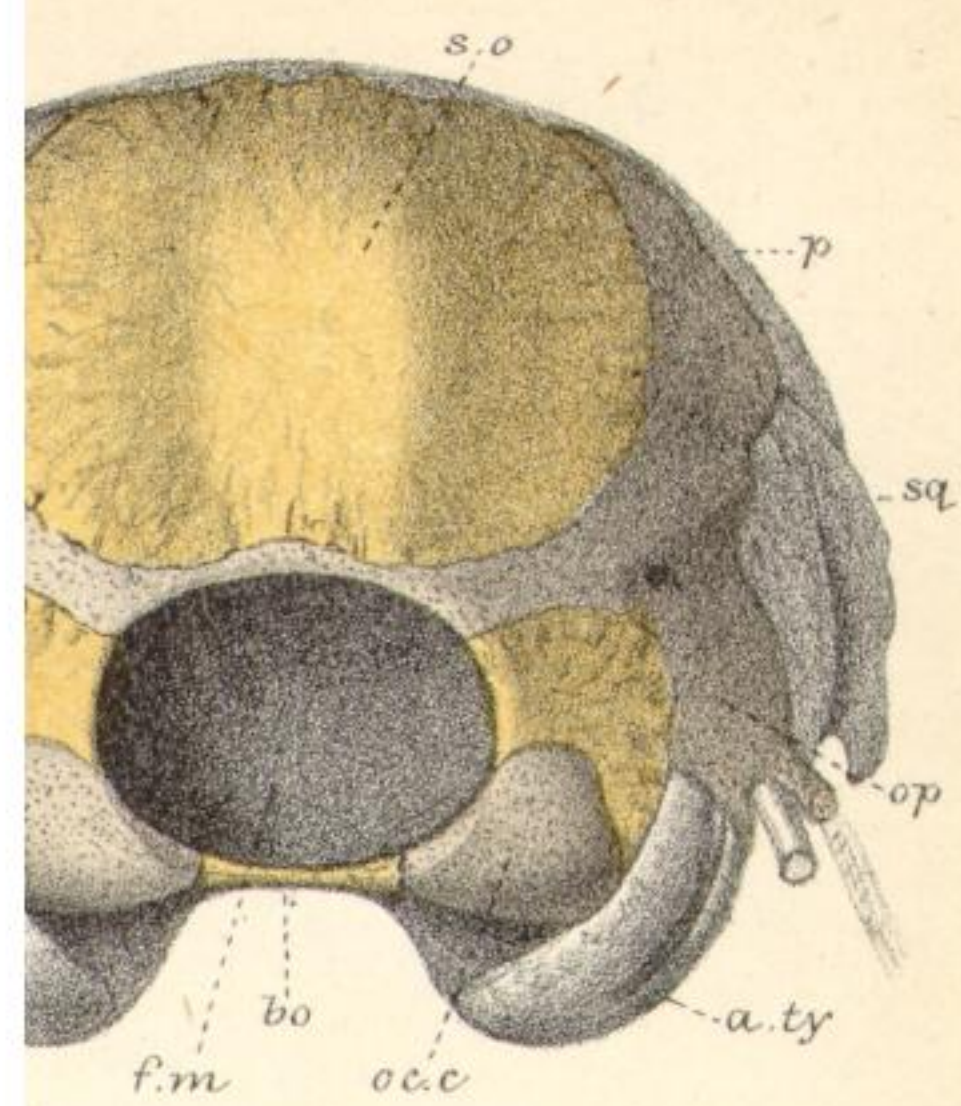
.hy

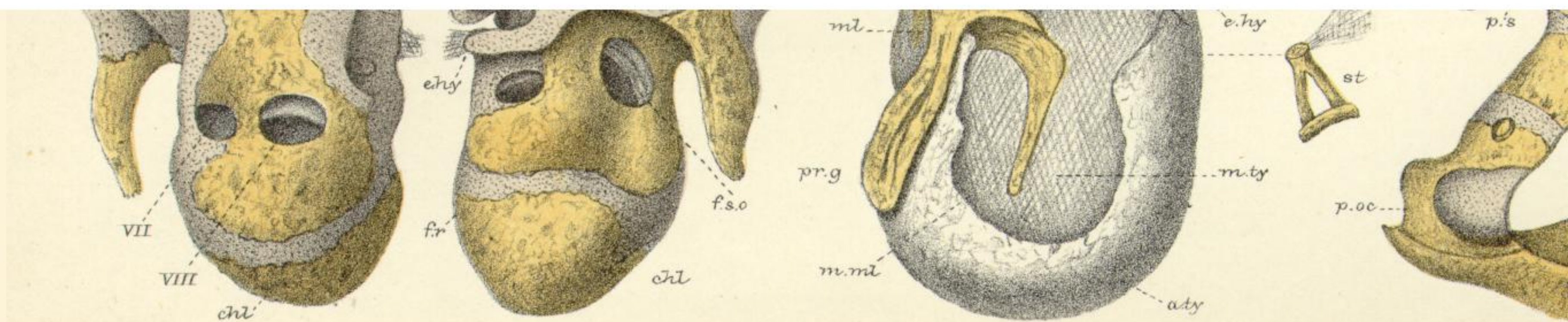

st

West, Newman & Co. imp.

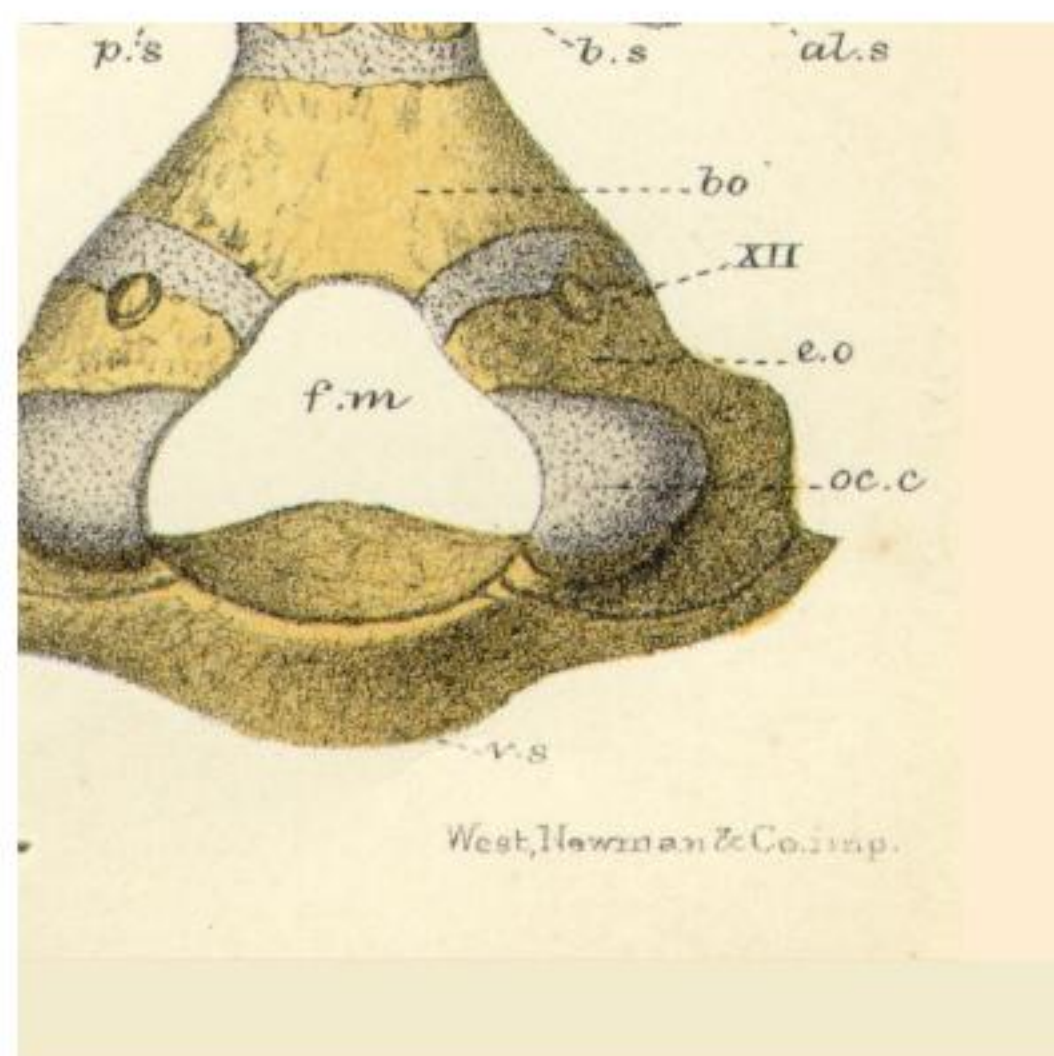


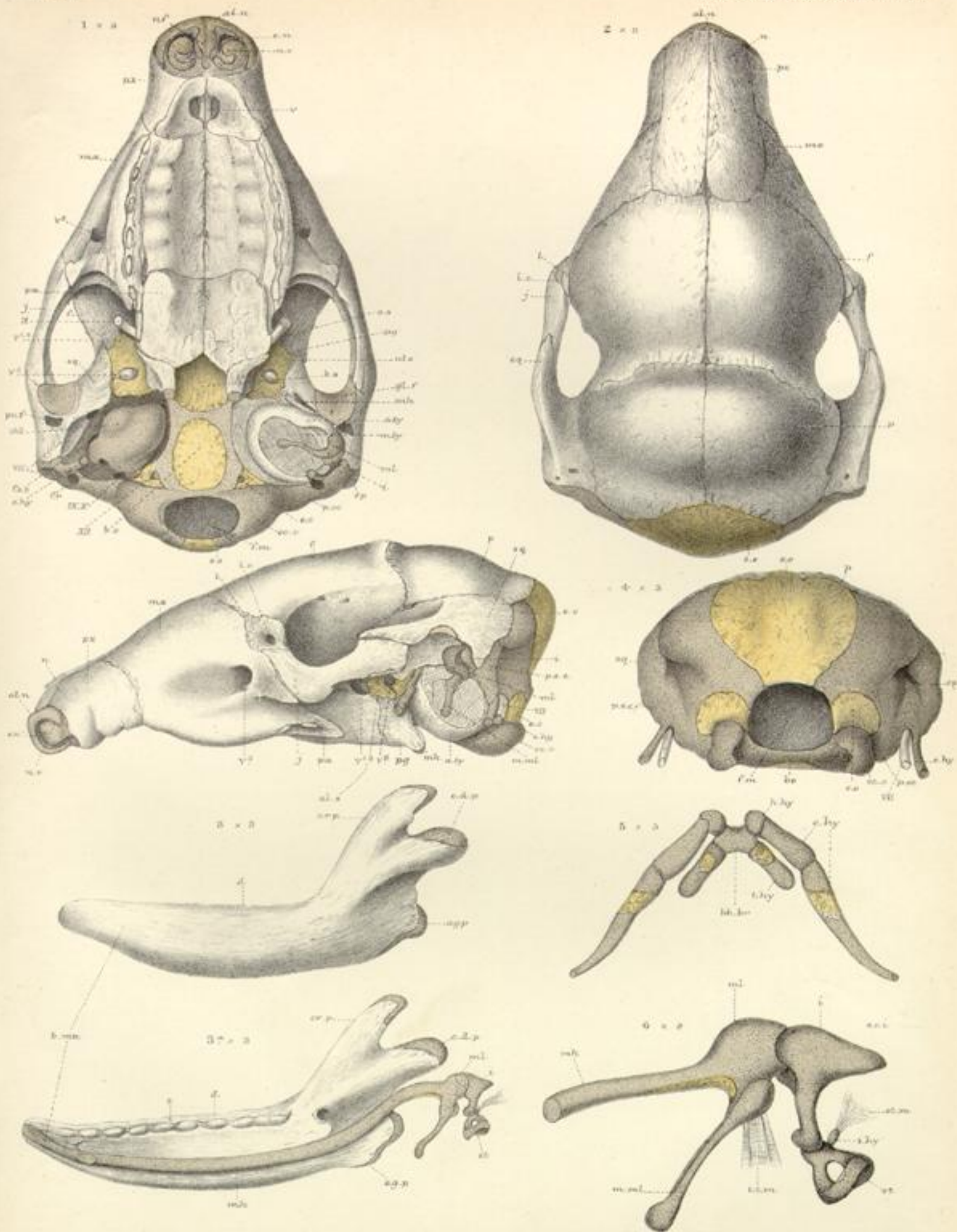


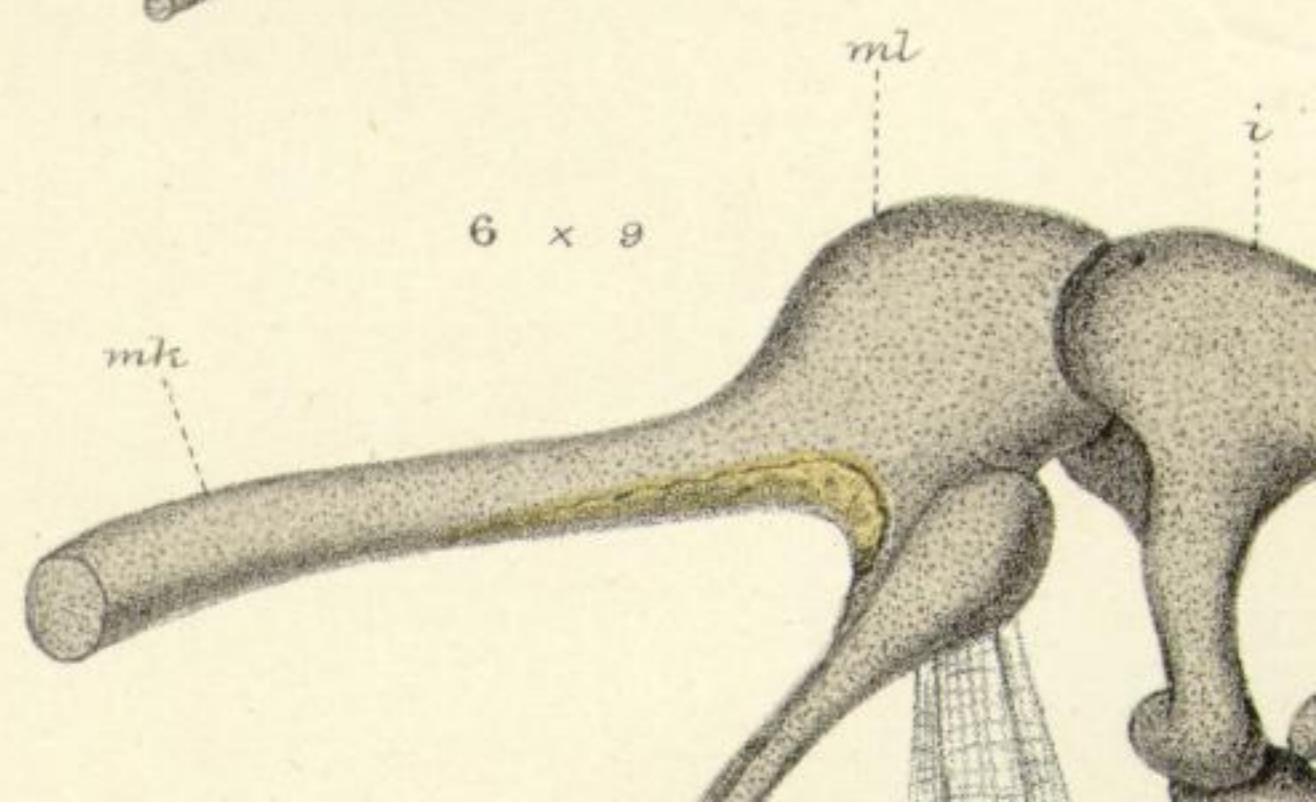
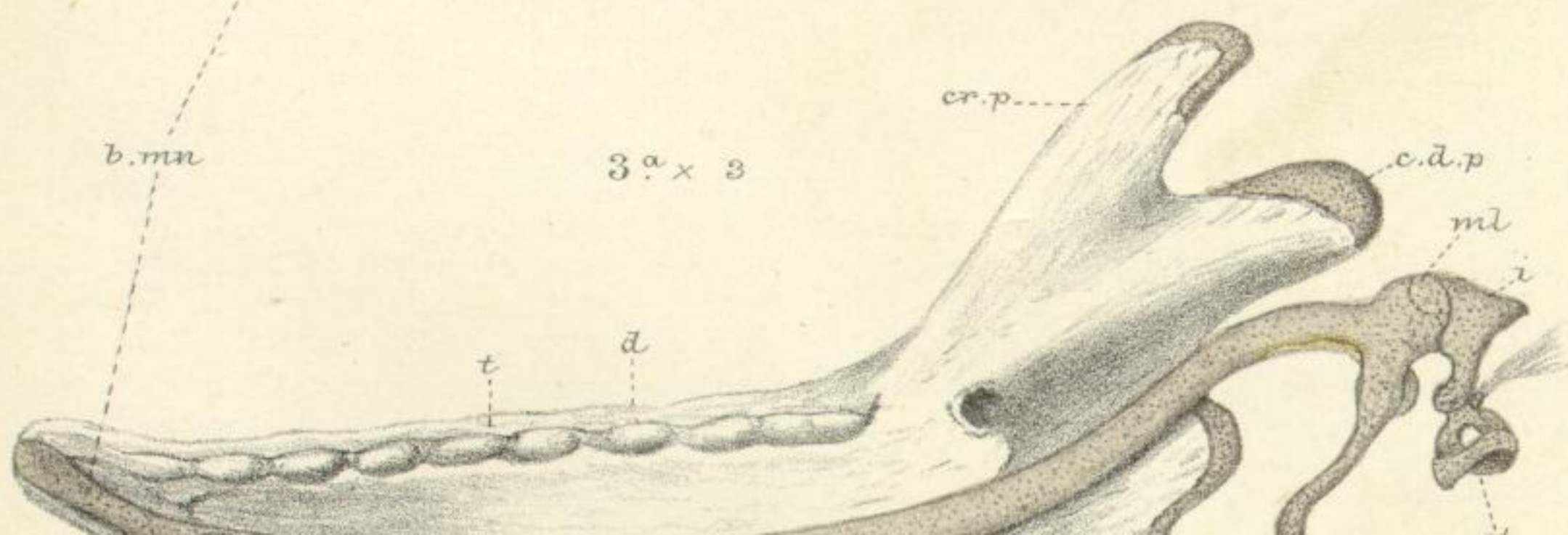
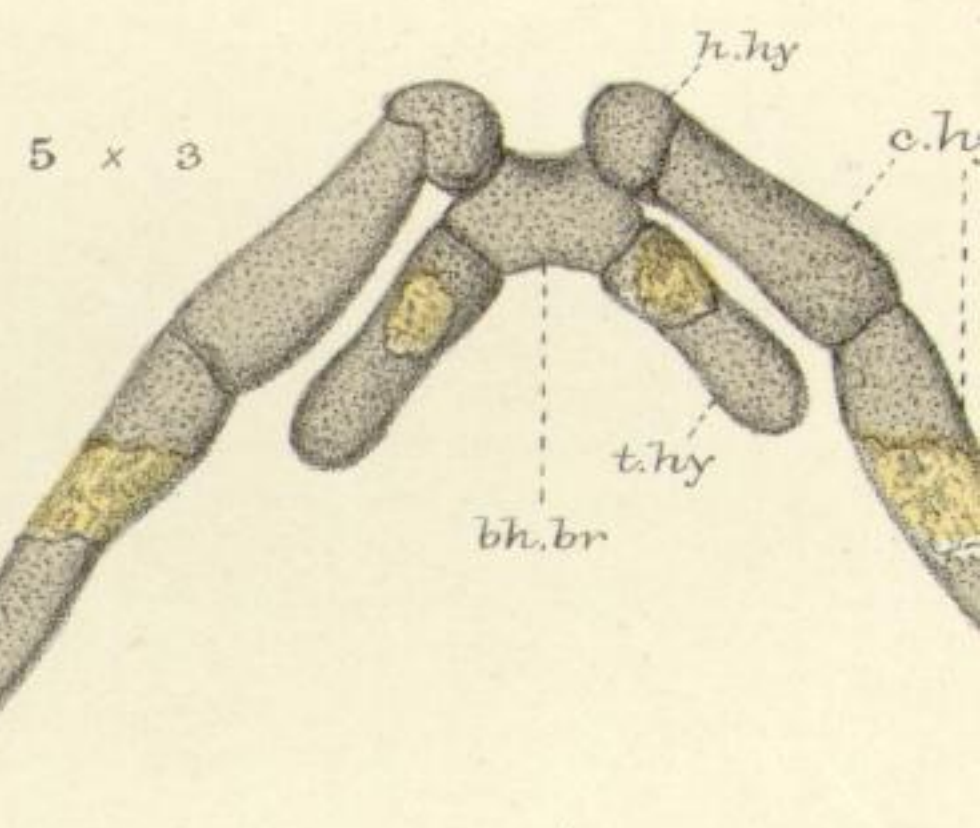
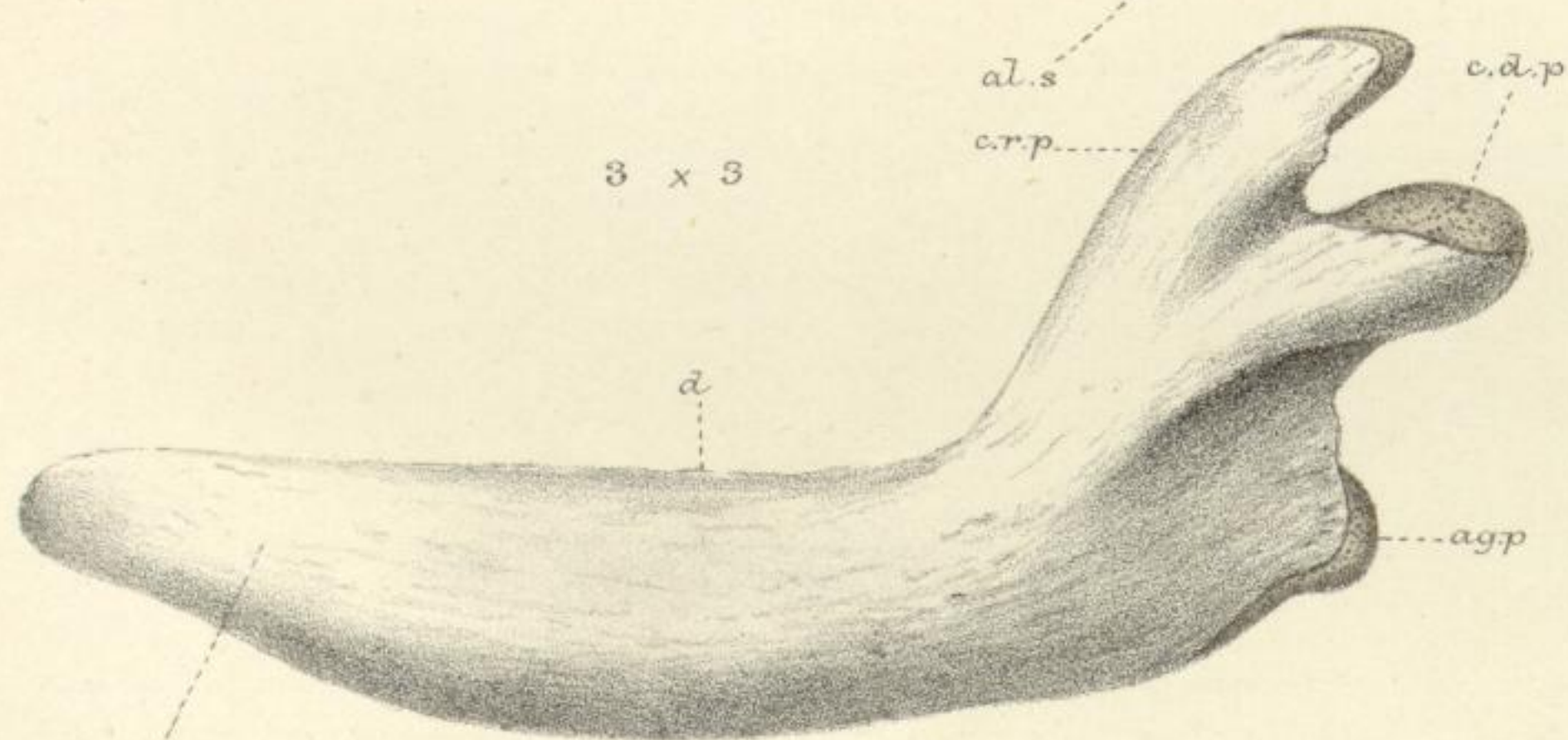
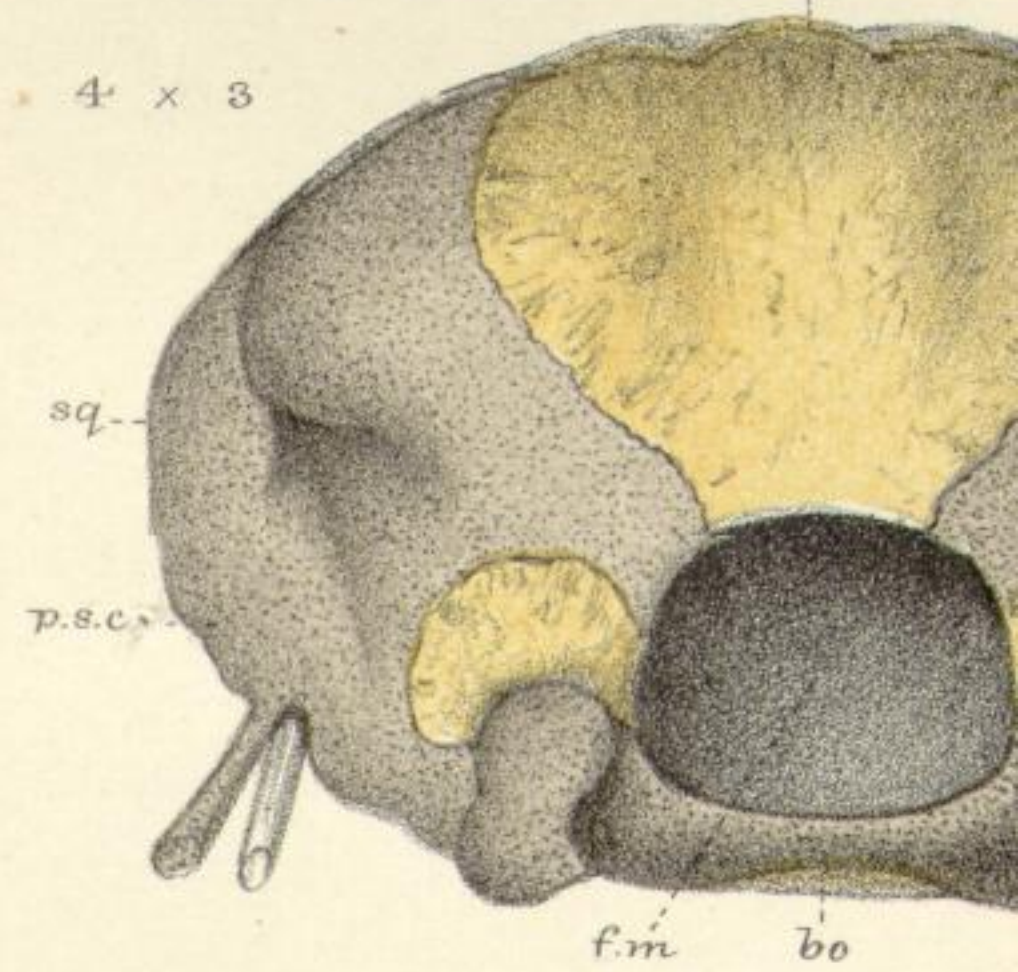
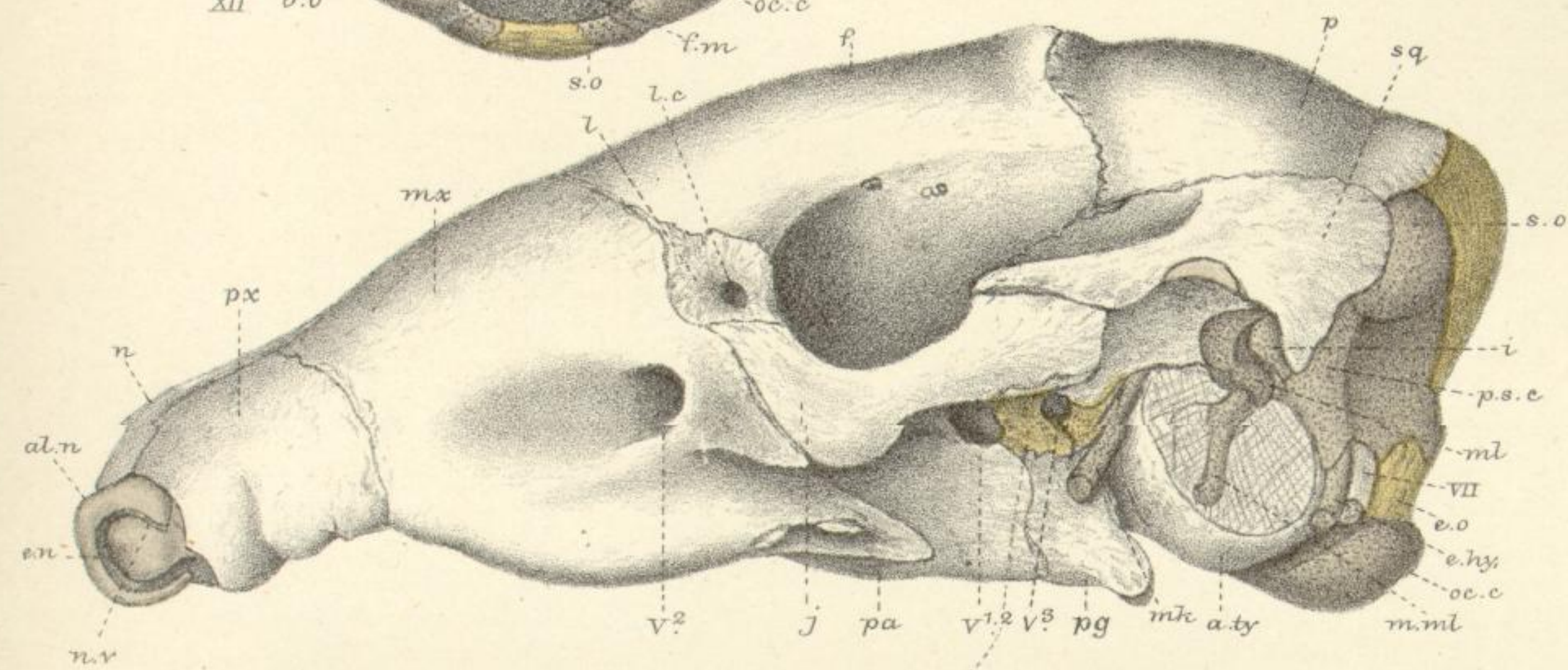
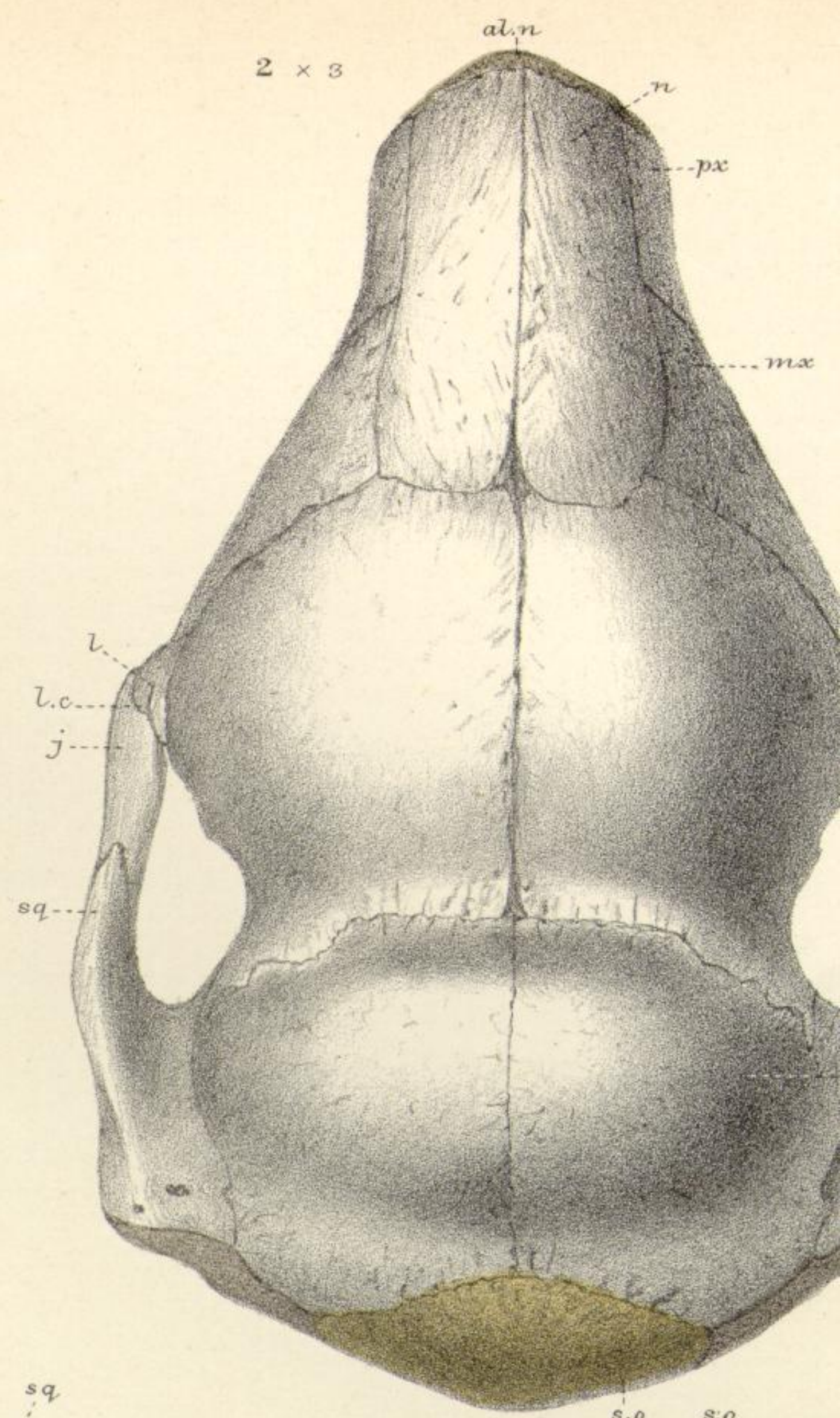
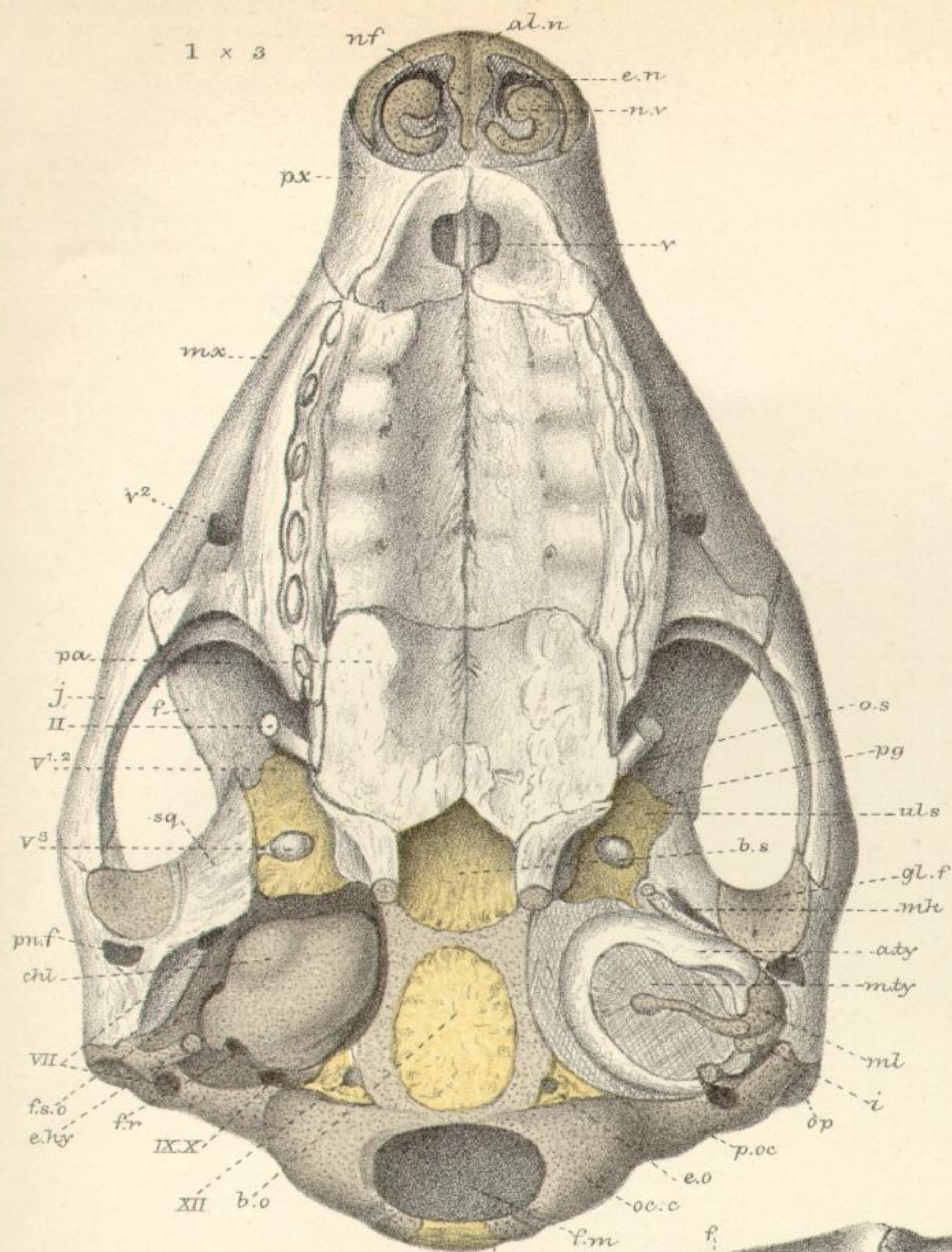


W.K.P. del.
Parker & Coward lith.

1-8, *Tatusia hybrida*; 9-11, *T. peba*.







px

max

f

p

s.o

p

op

e.hy

bo

e.o

oc.c

p.oe

VII

i.hy

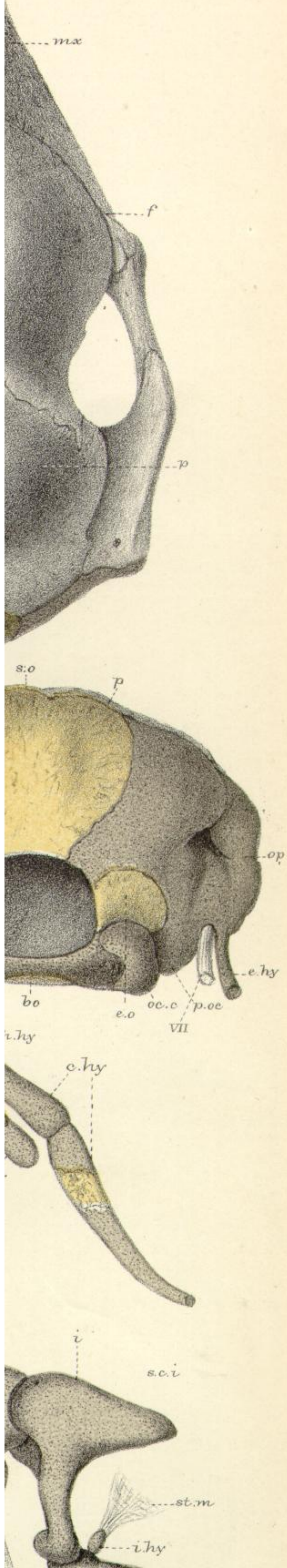
c.hy

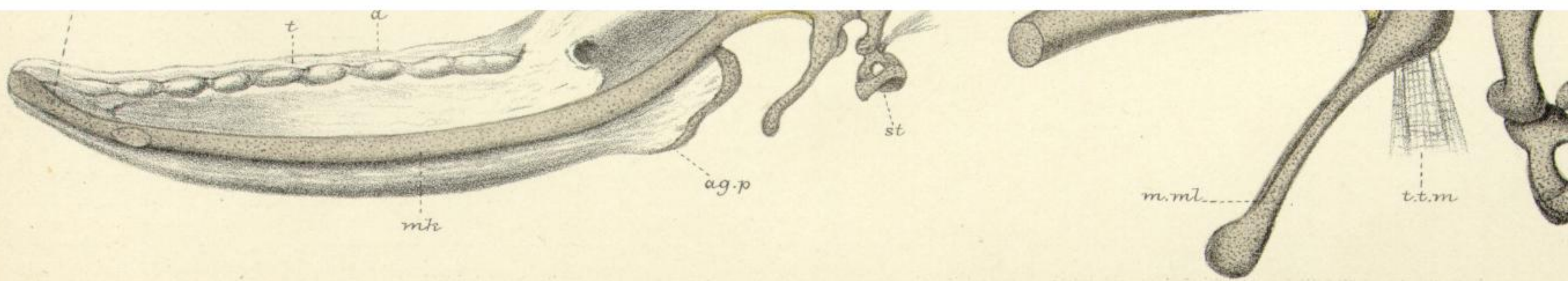
i

s.c.i

st.m

i.hy

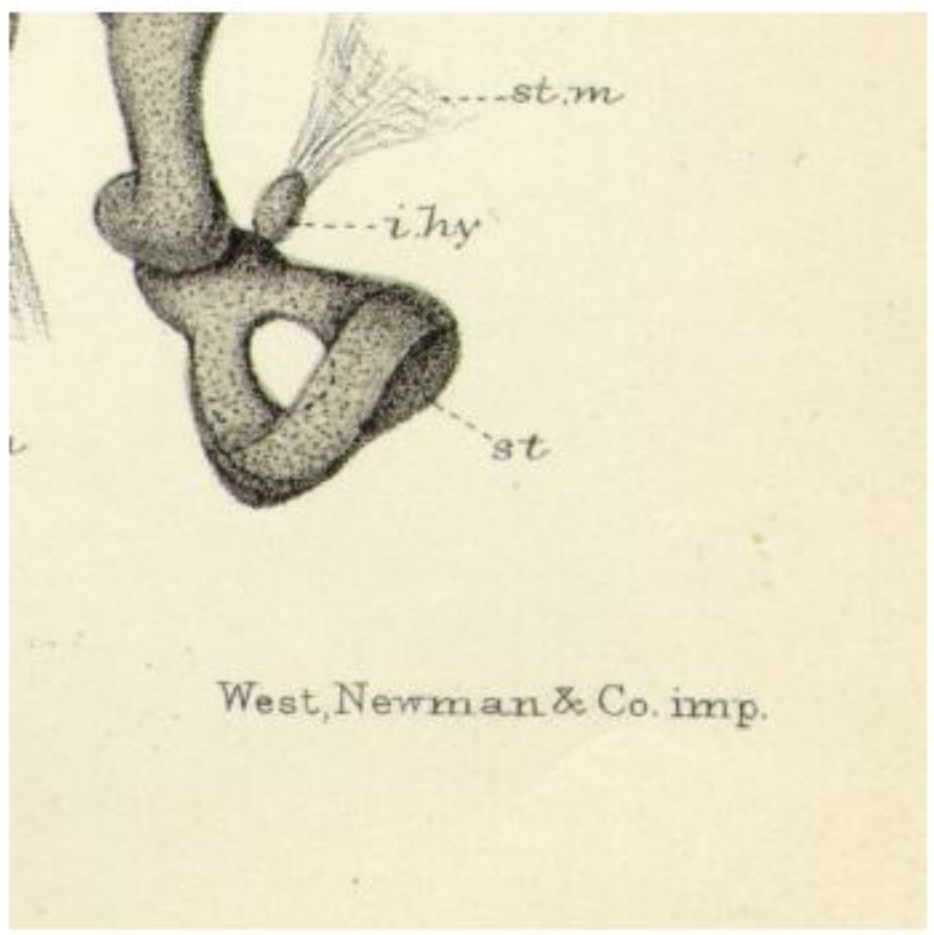




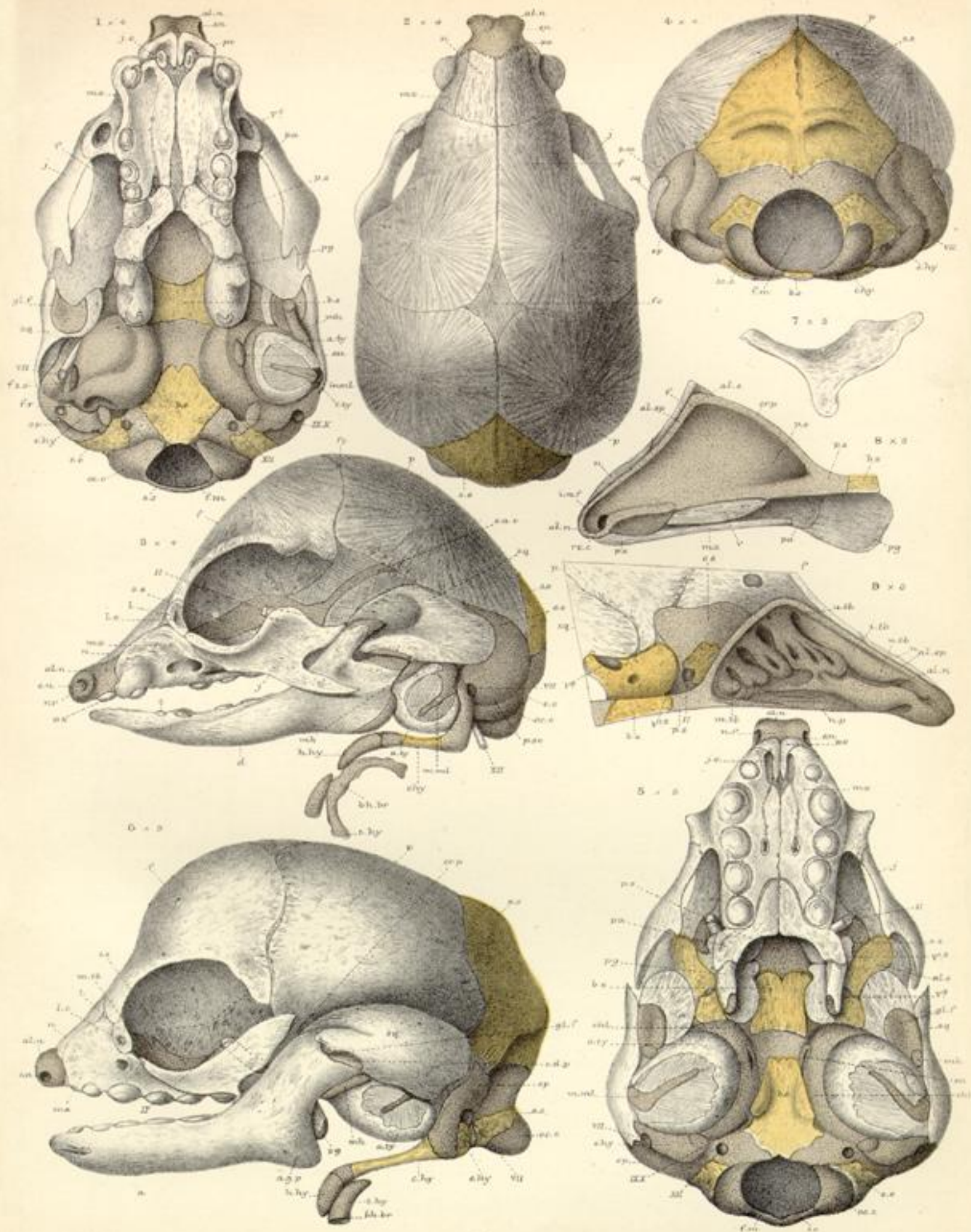
Parker & Coward lith.
W.K.P. del. ad nat.

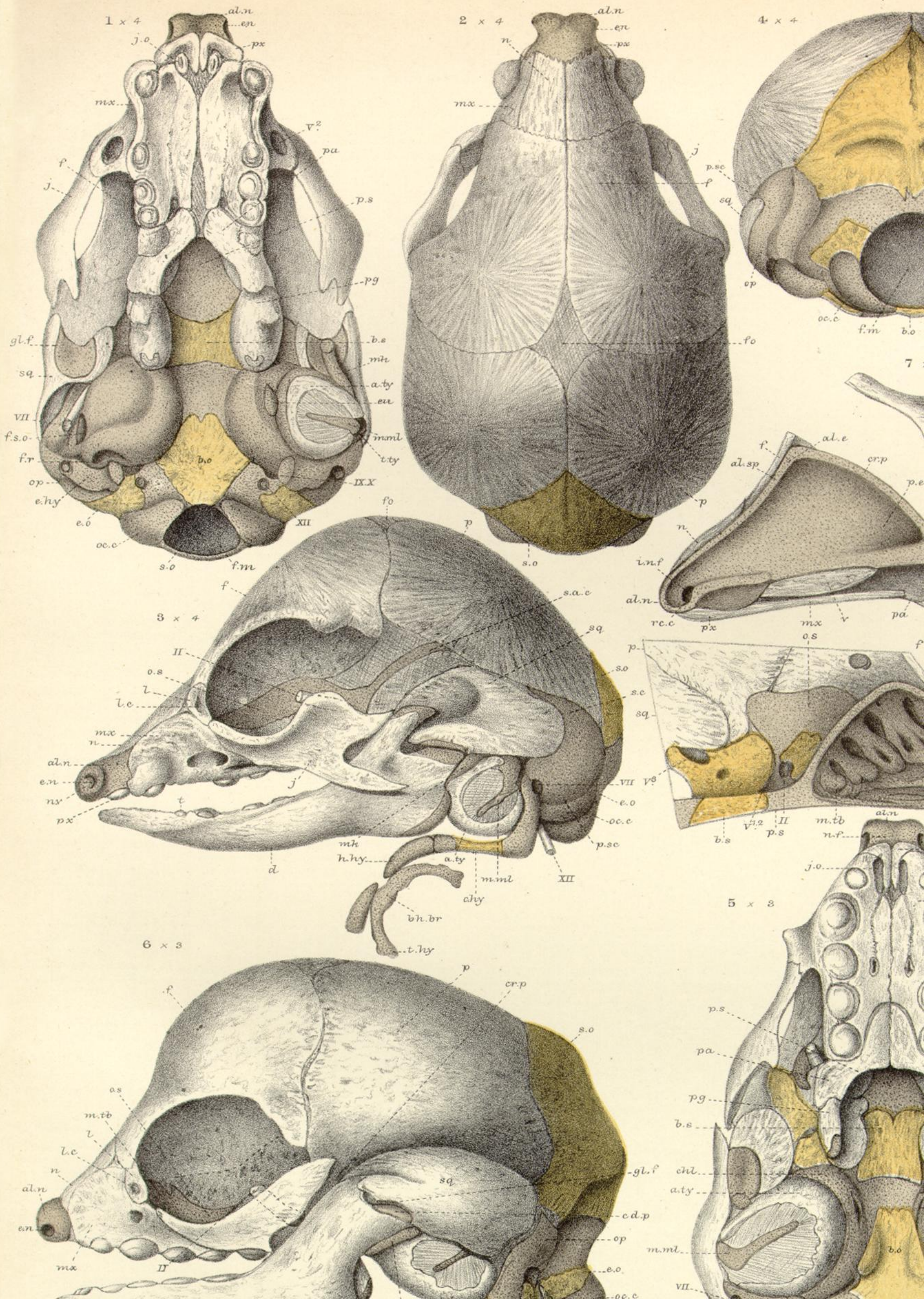Dasypus villosus.

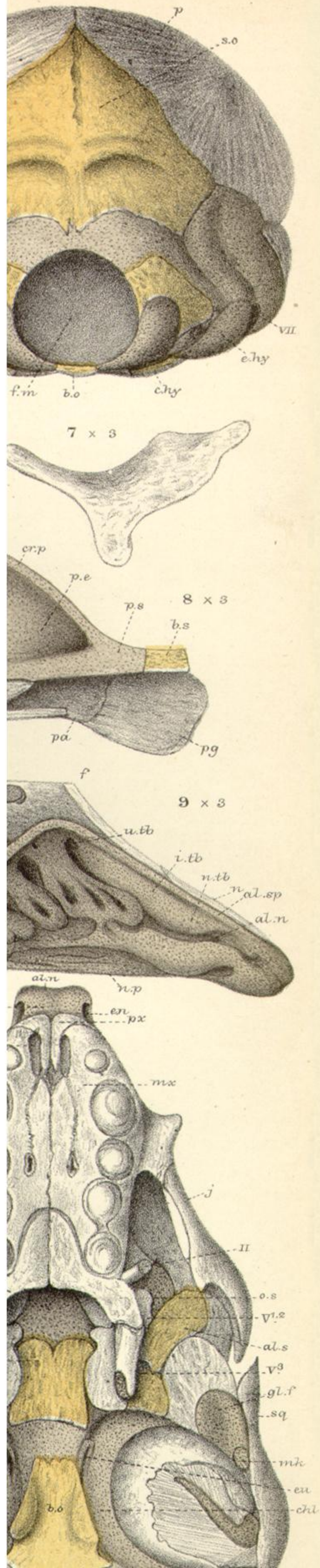
We

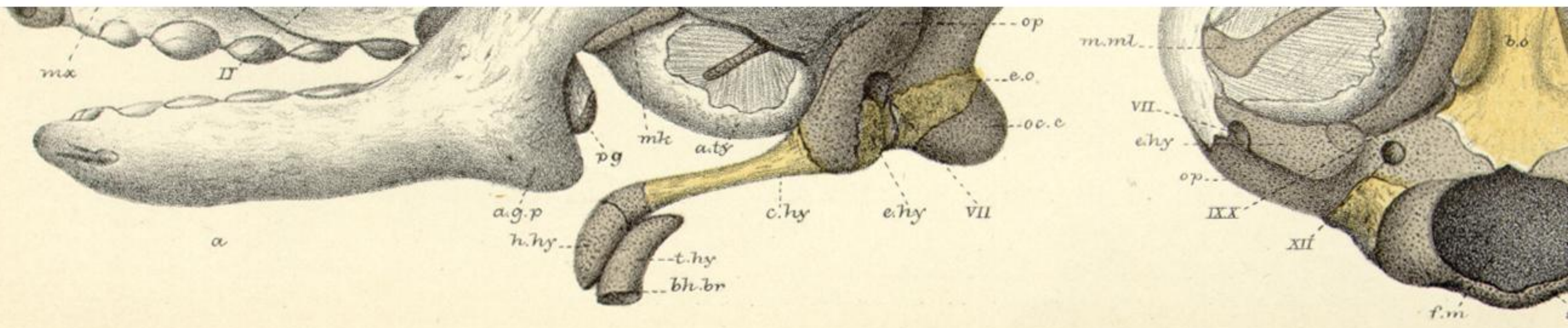


West, Newman & Co. imp.



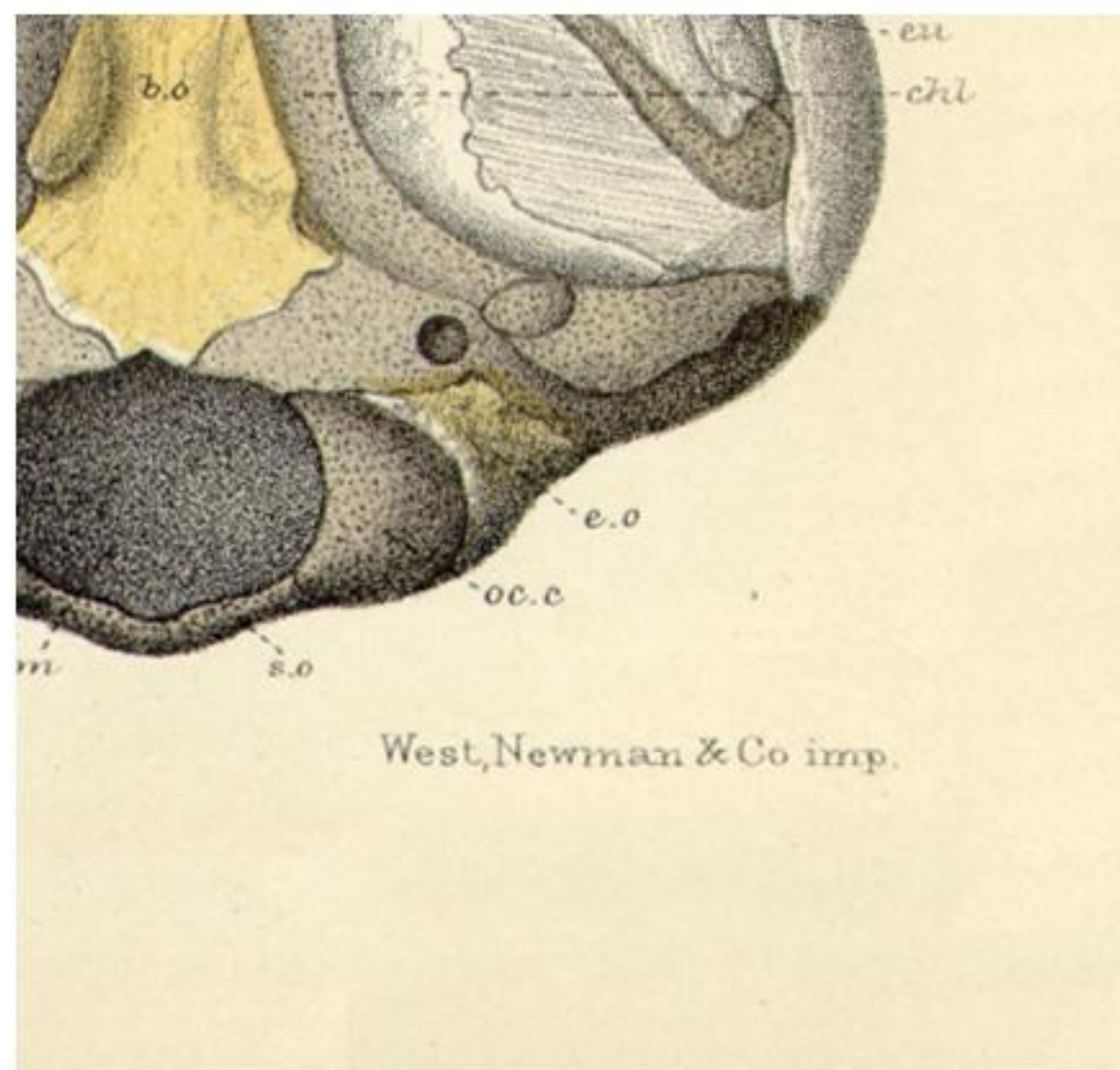


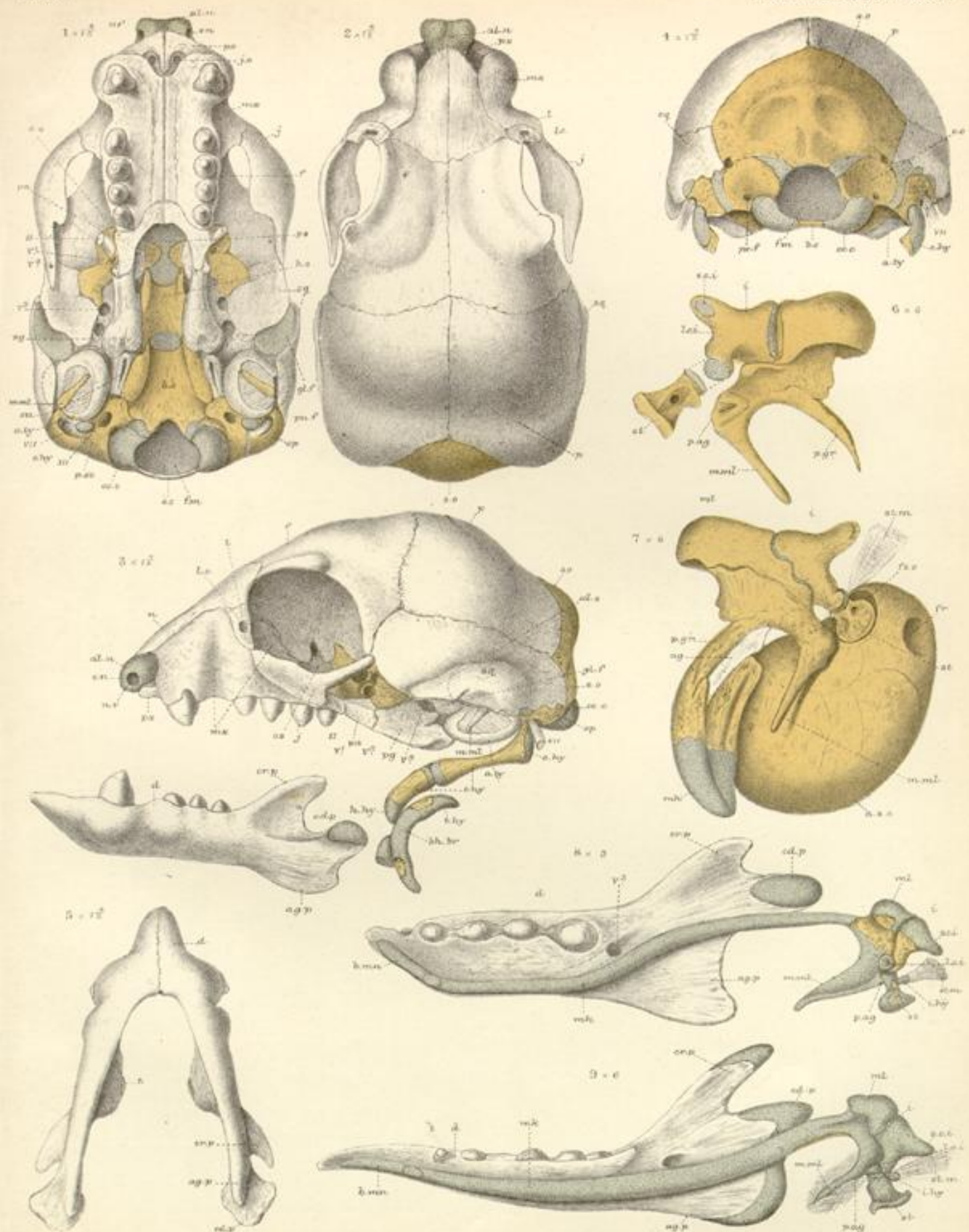


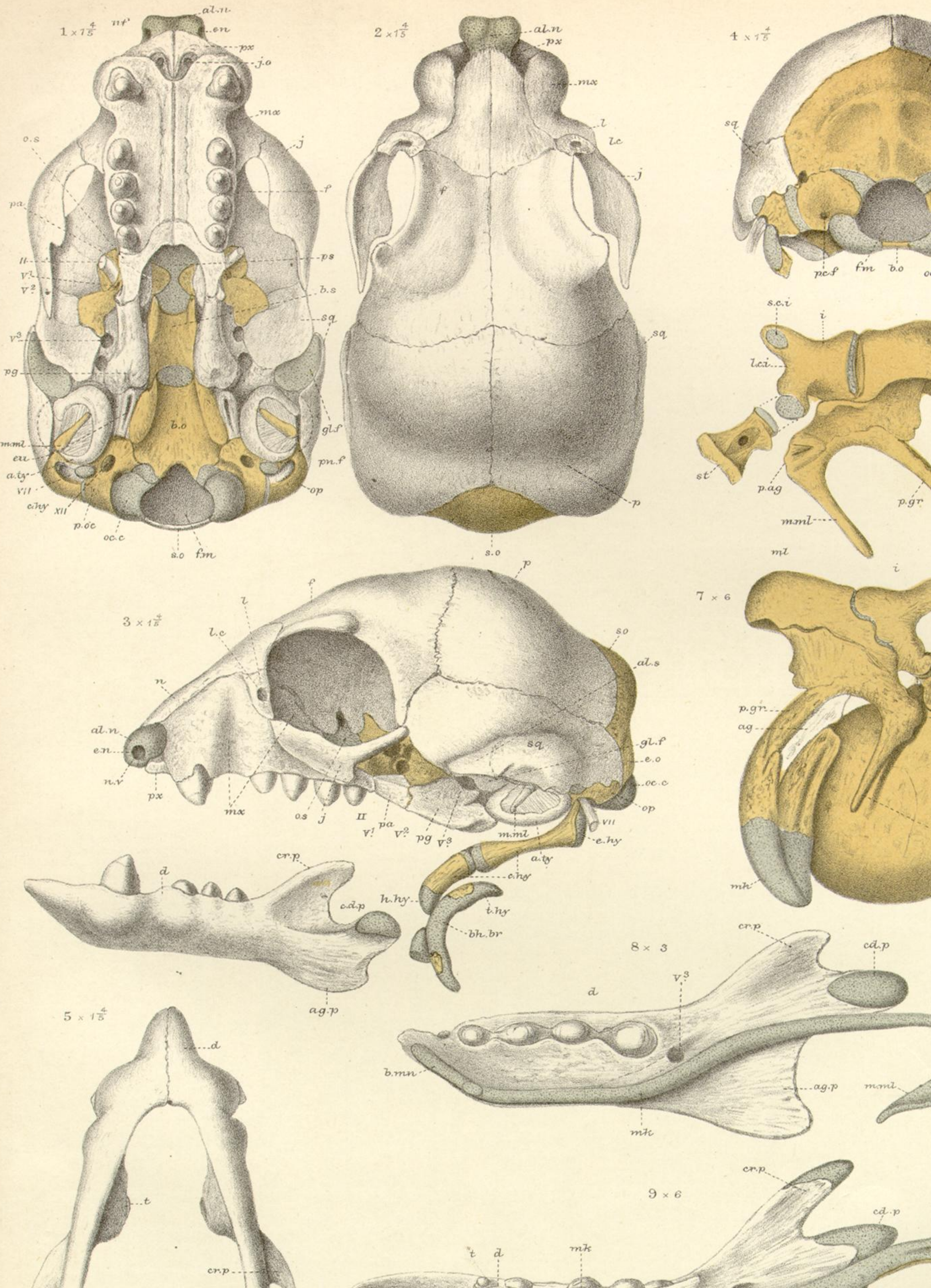


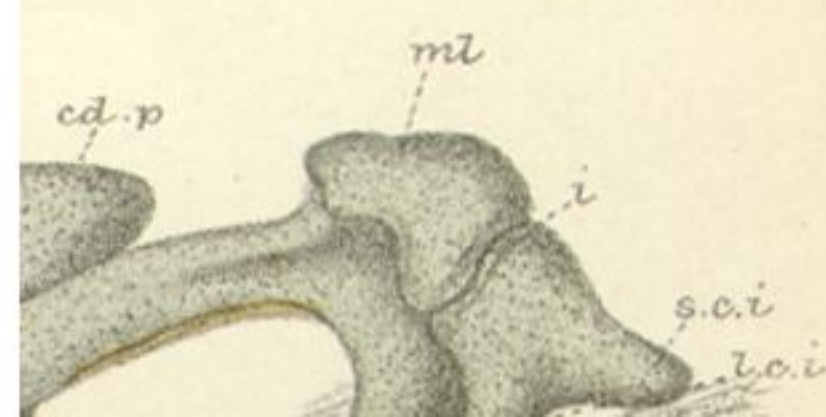
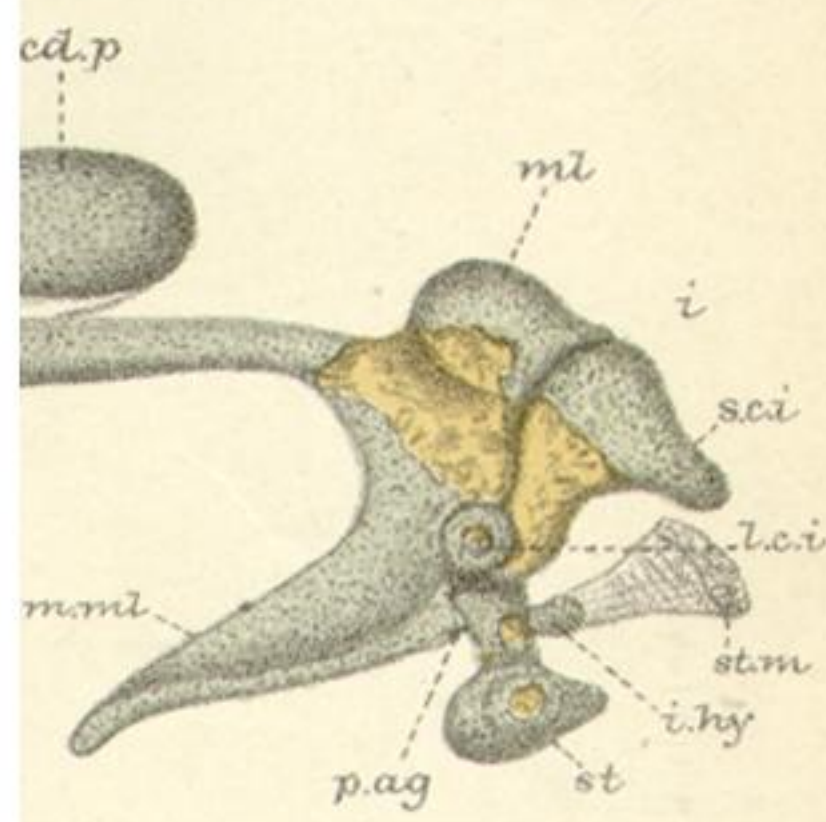
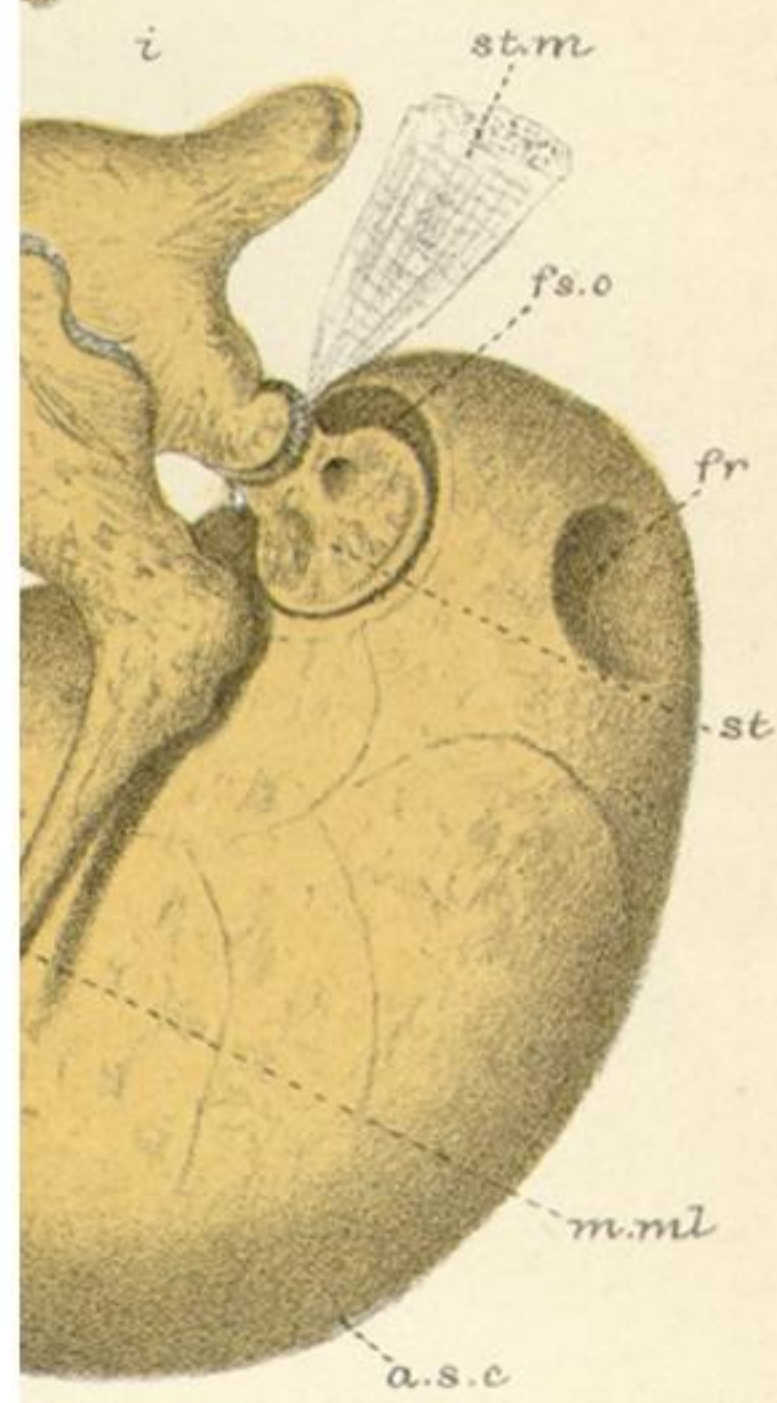
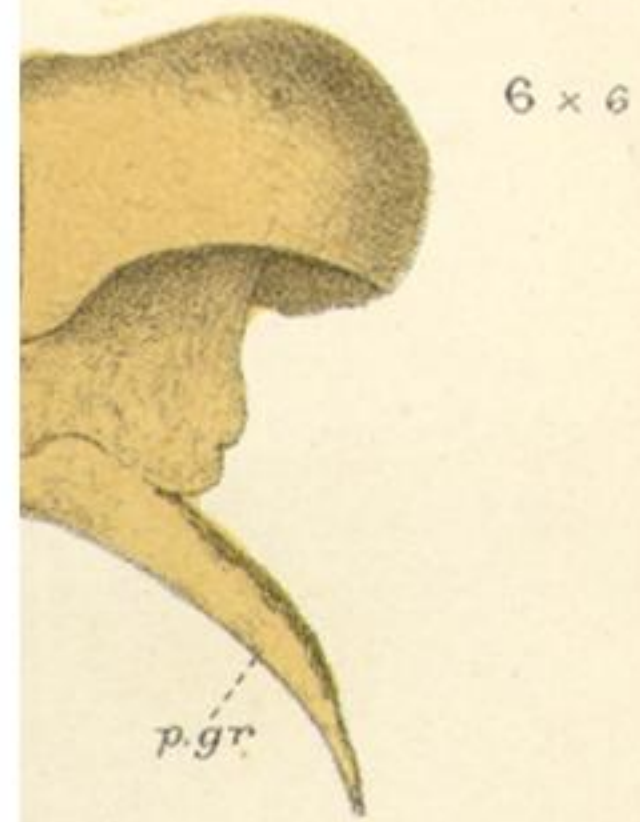
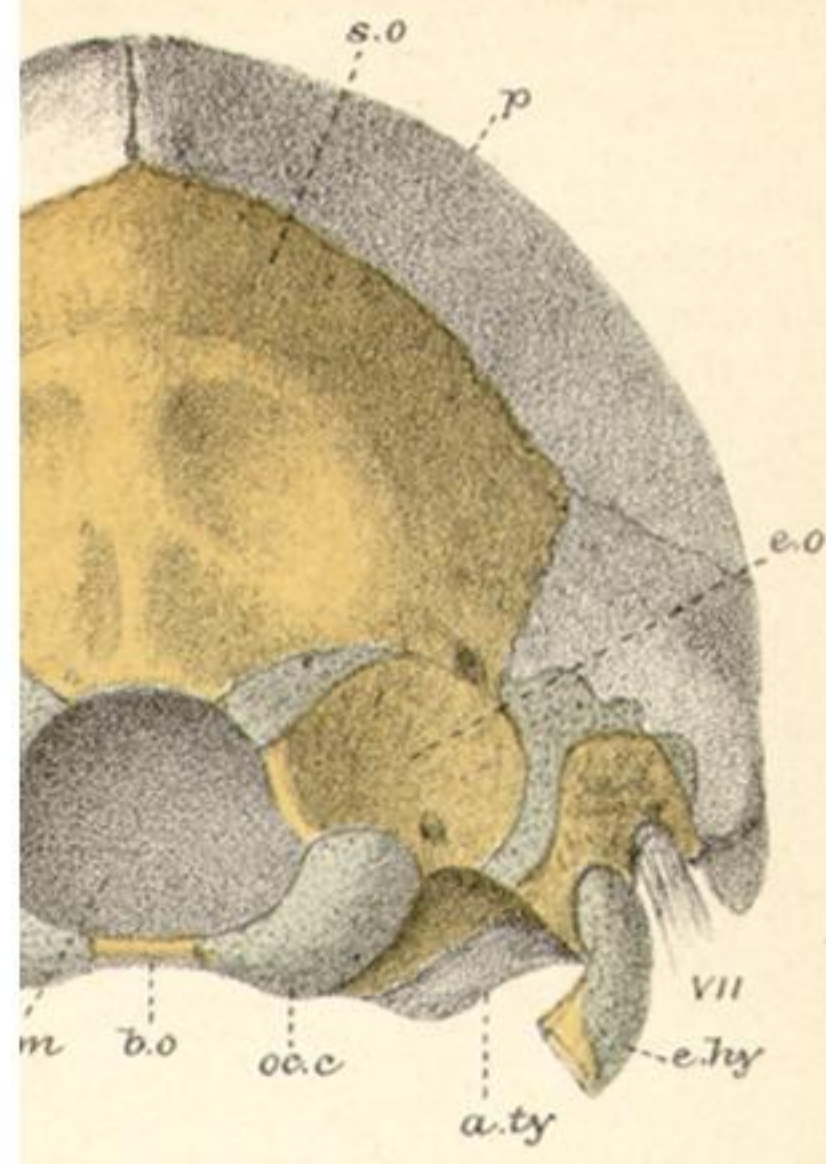Parker & Coward
W.K.P. del ad nat.

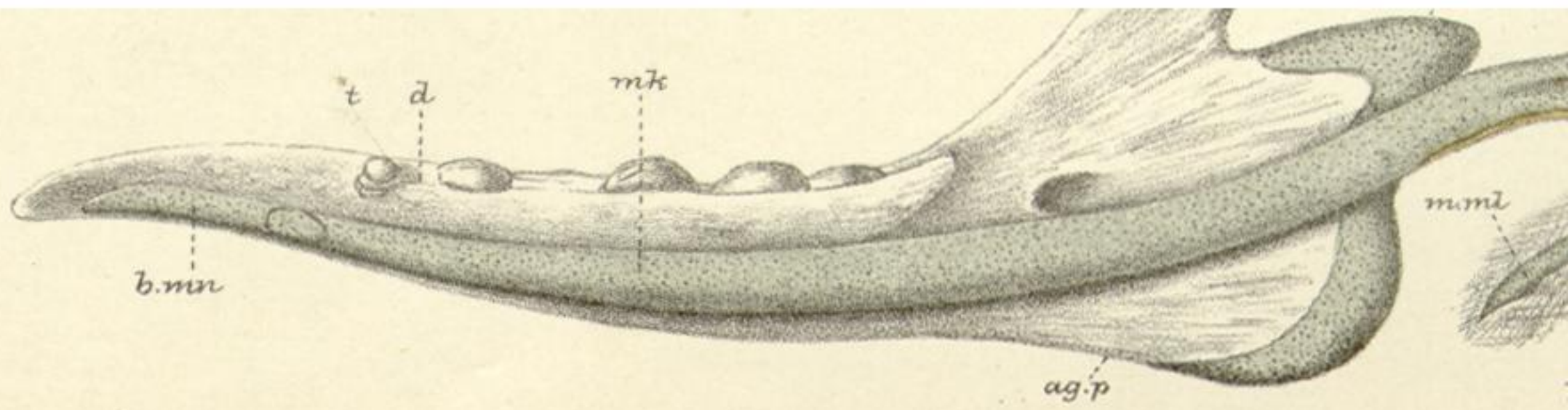
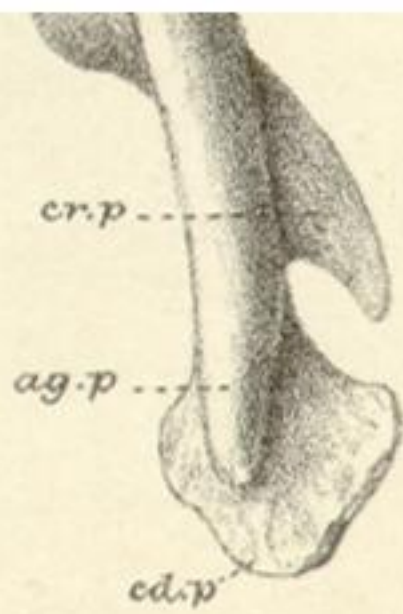
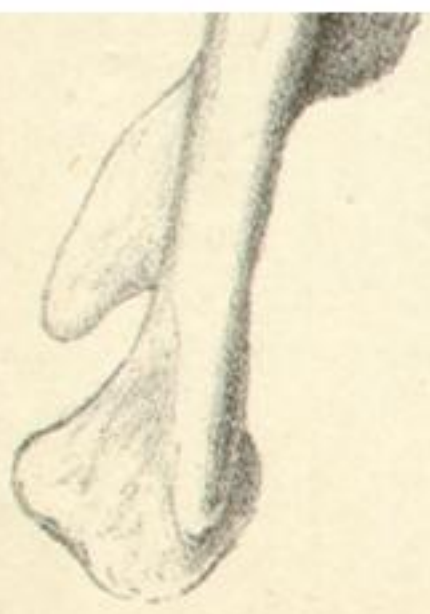1-4 Choloepus, 5-9 Bradypus.





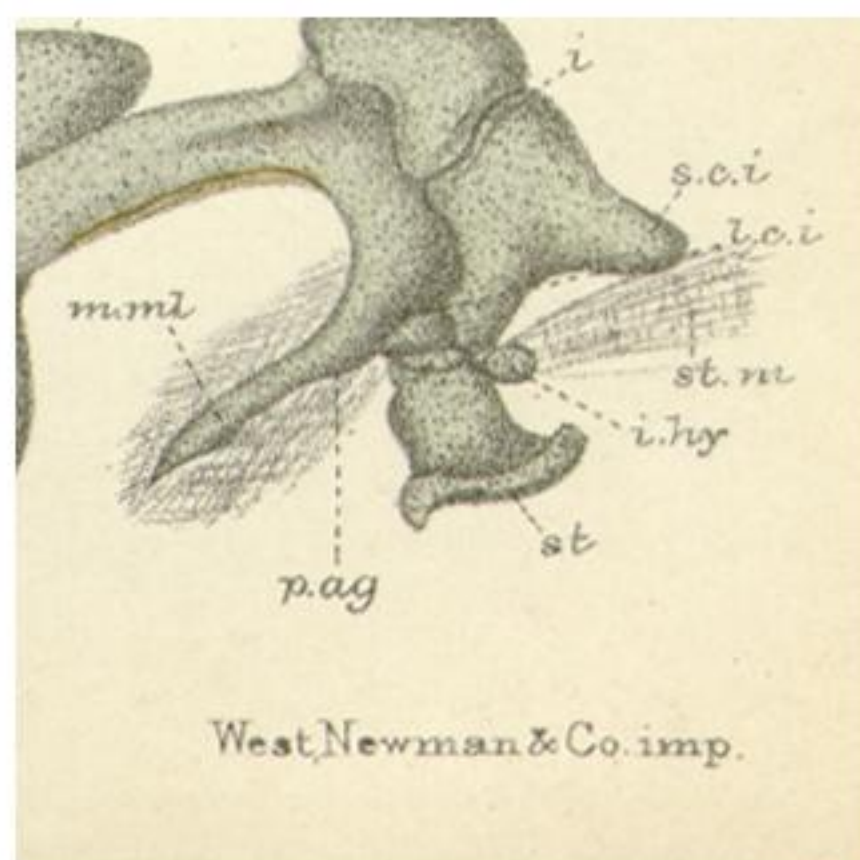




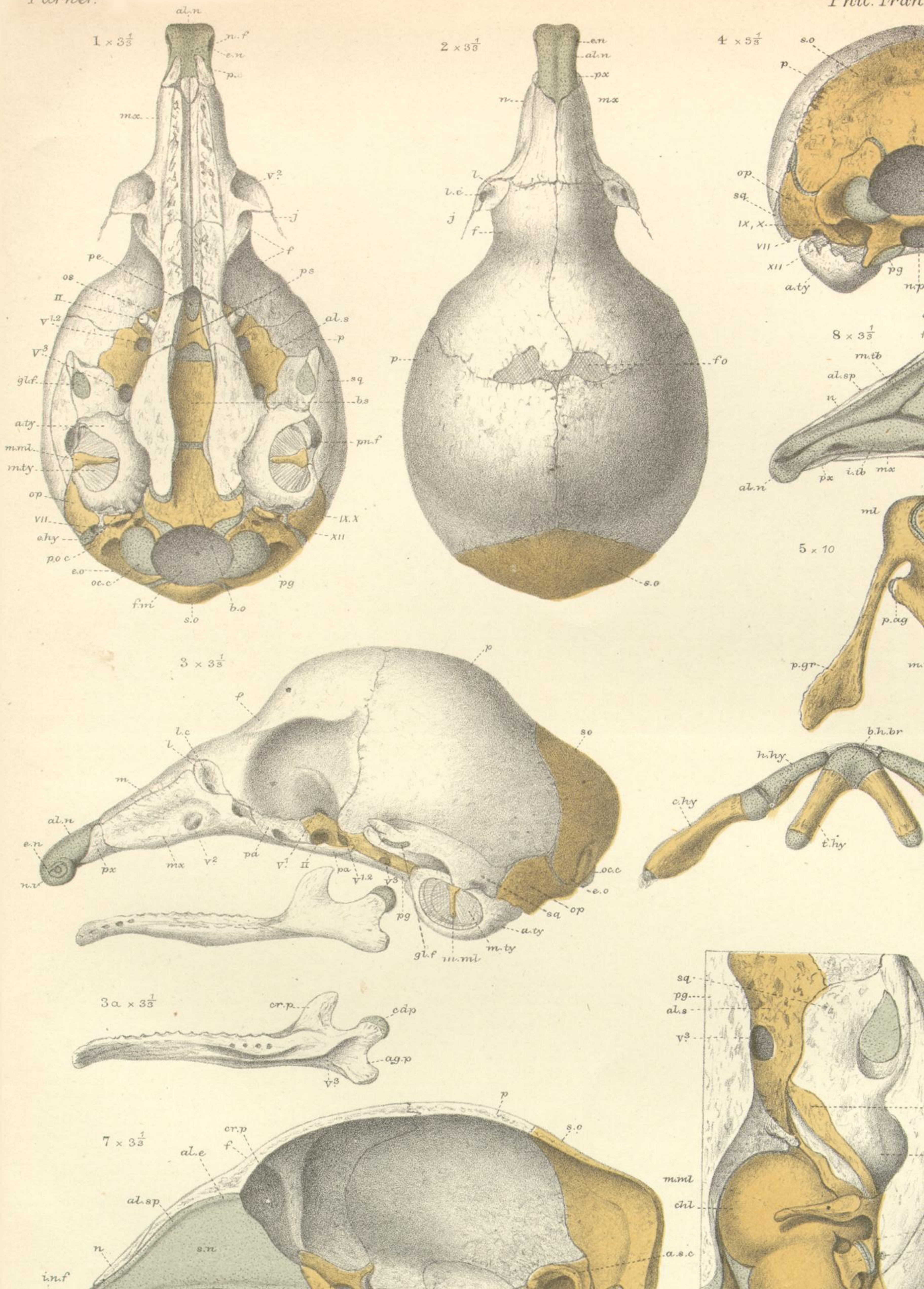


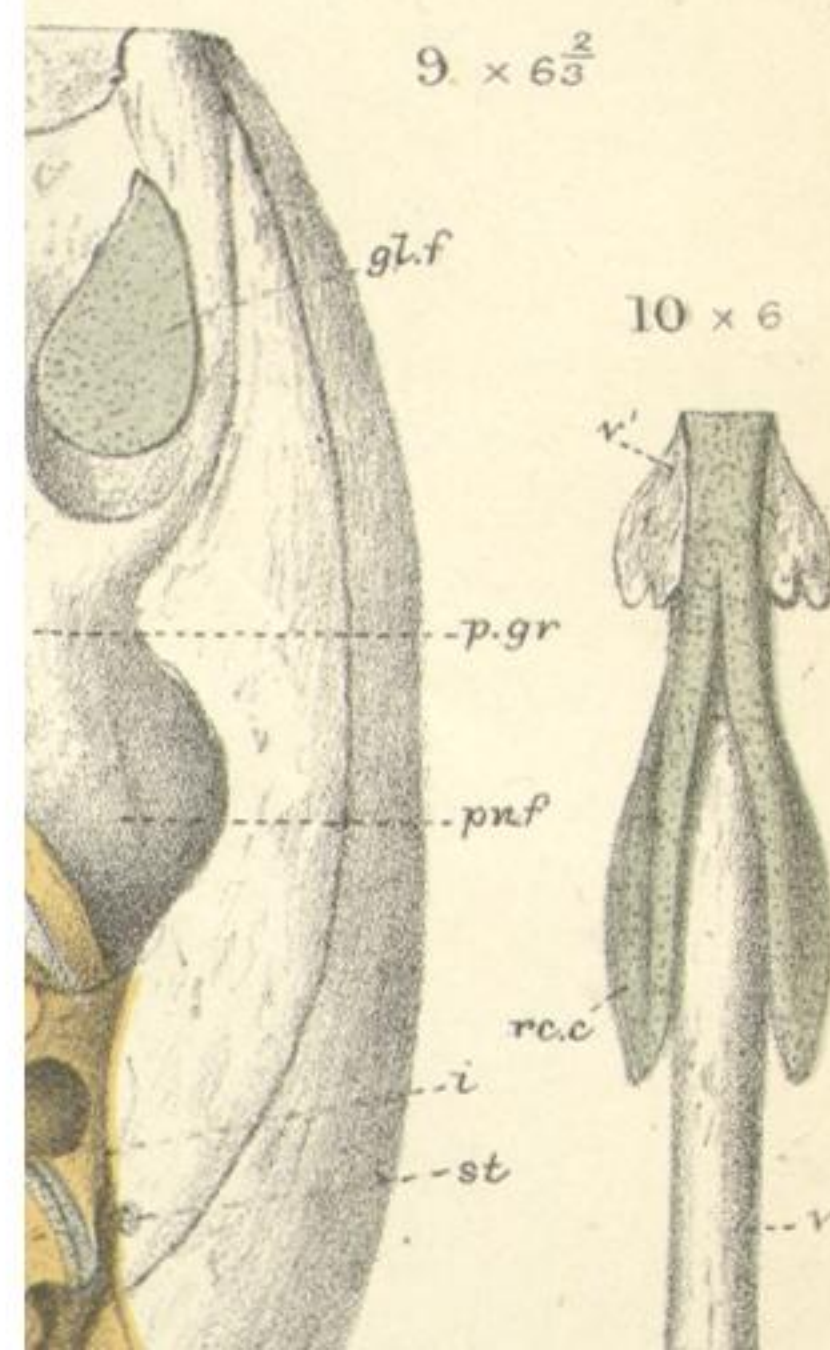
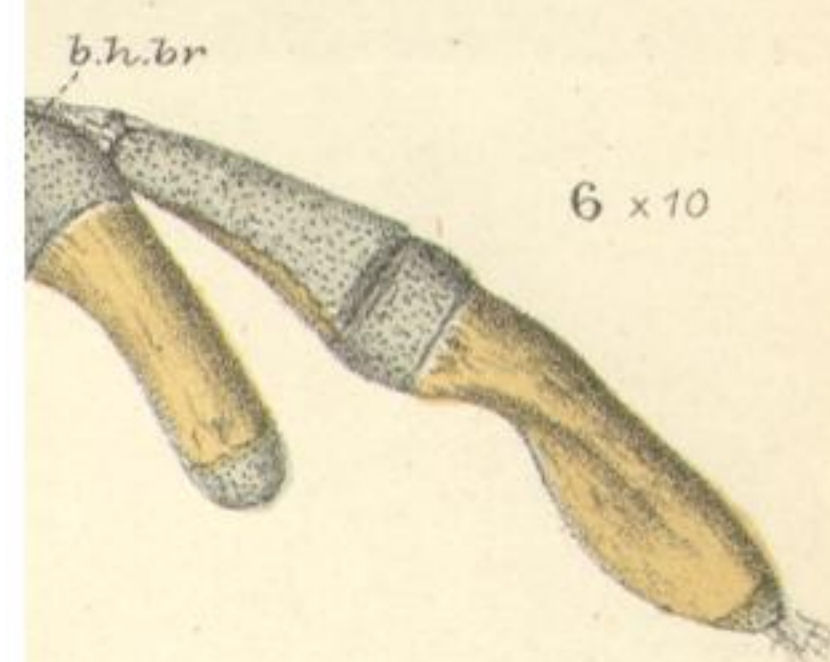
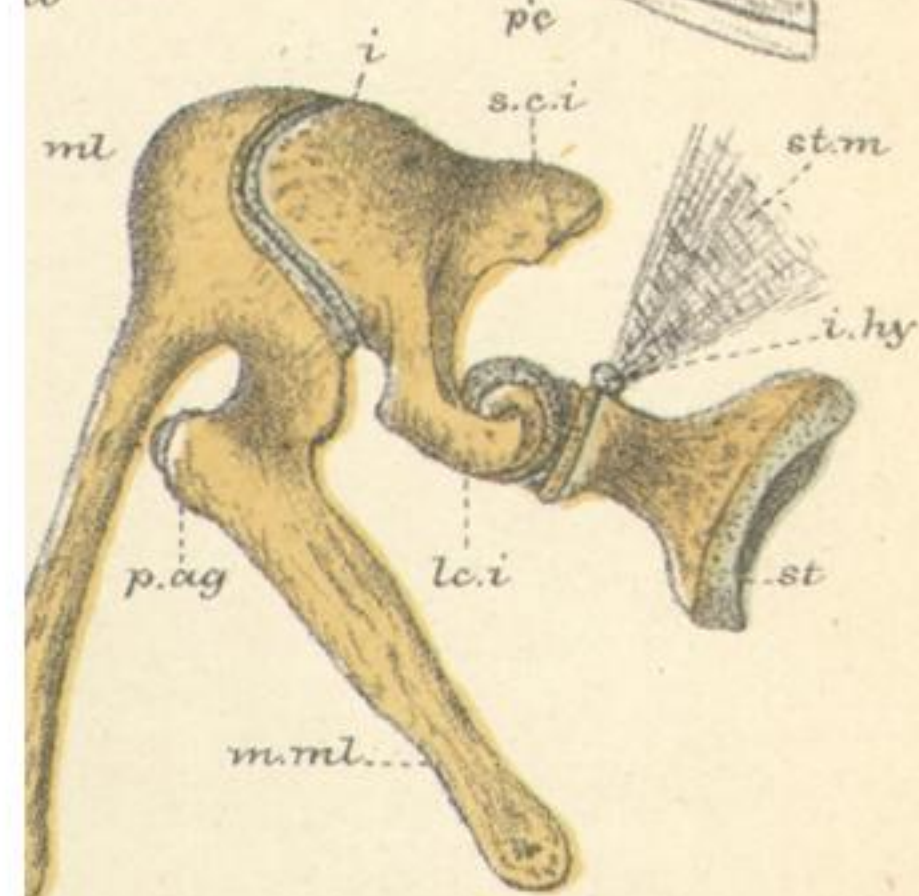
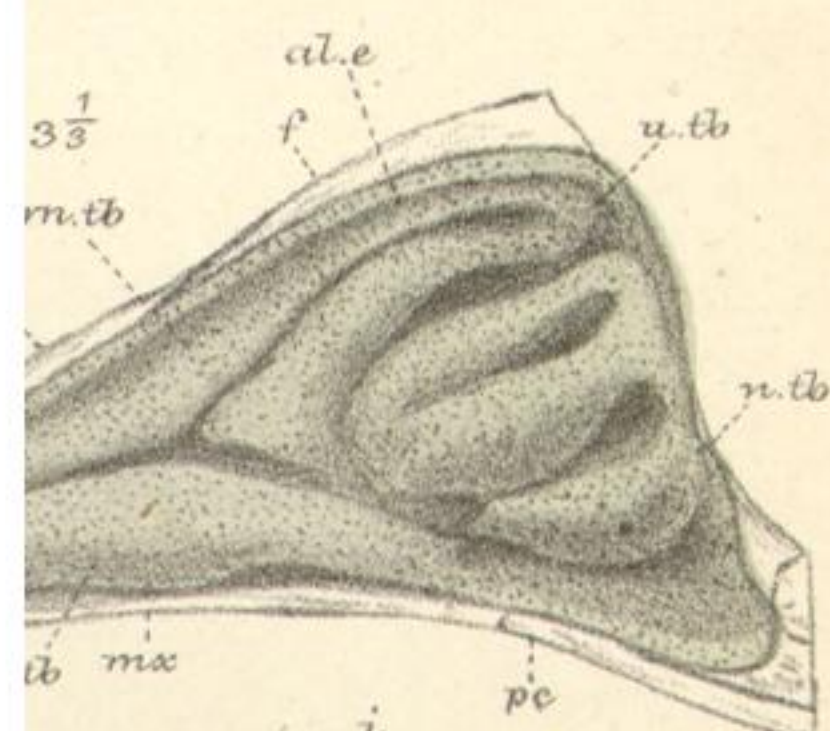
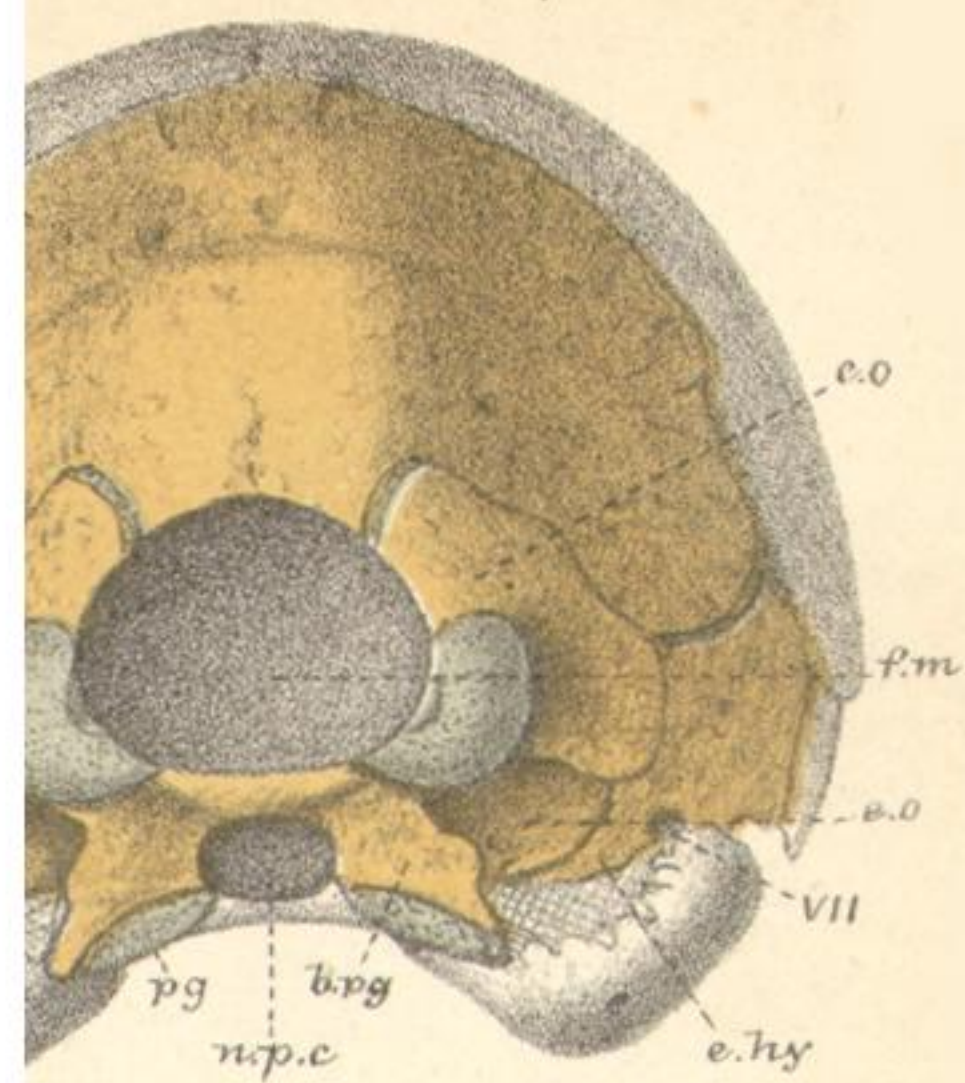
W.K.P. del. ad nat.
Parker & Coward lith.

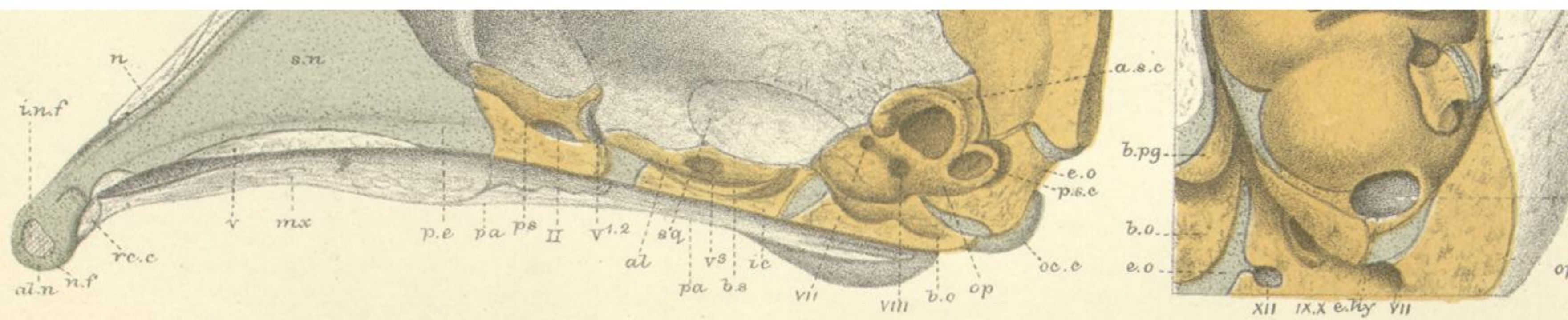
1-7, & 9 Cholopus: 8 Bradypus.



West Newman & Co. imp.

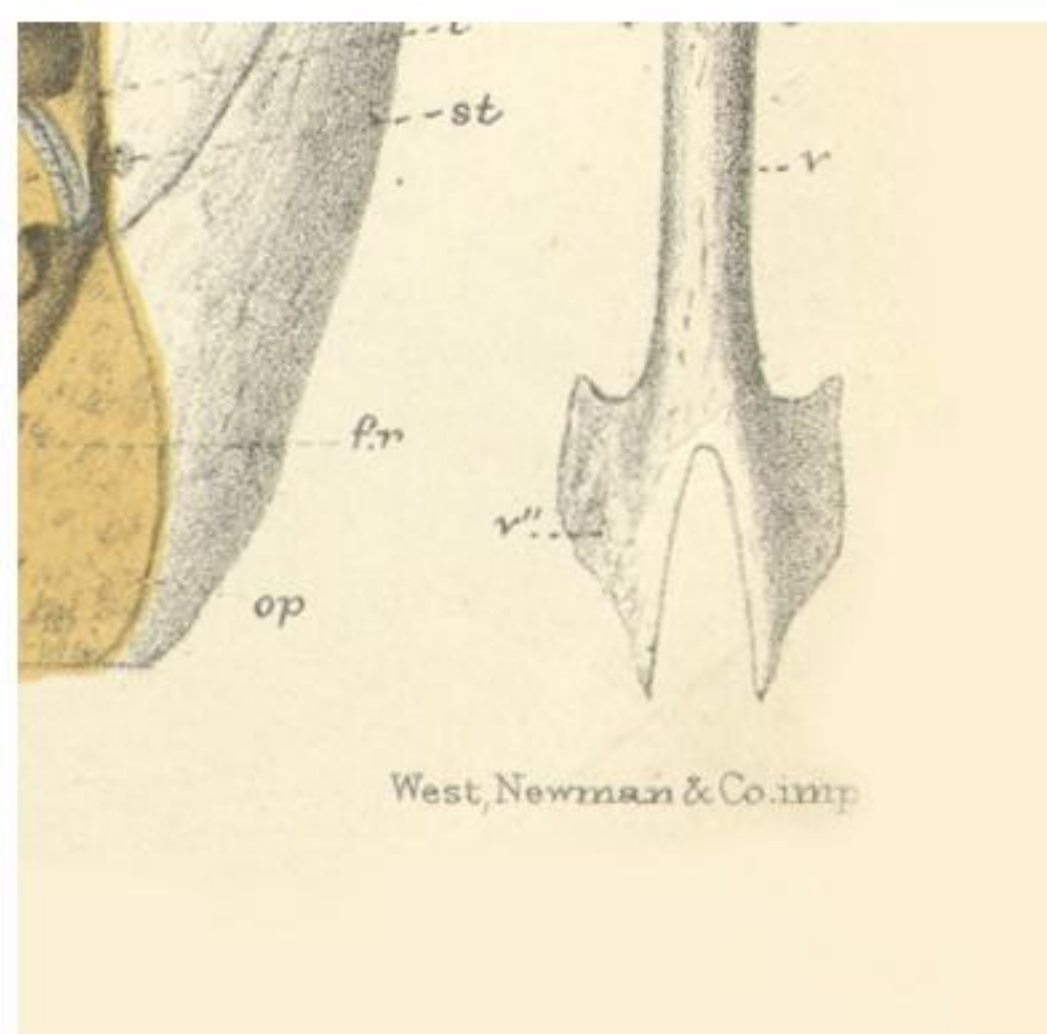


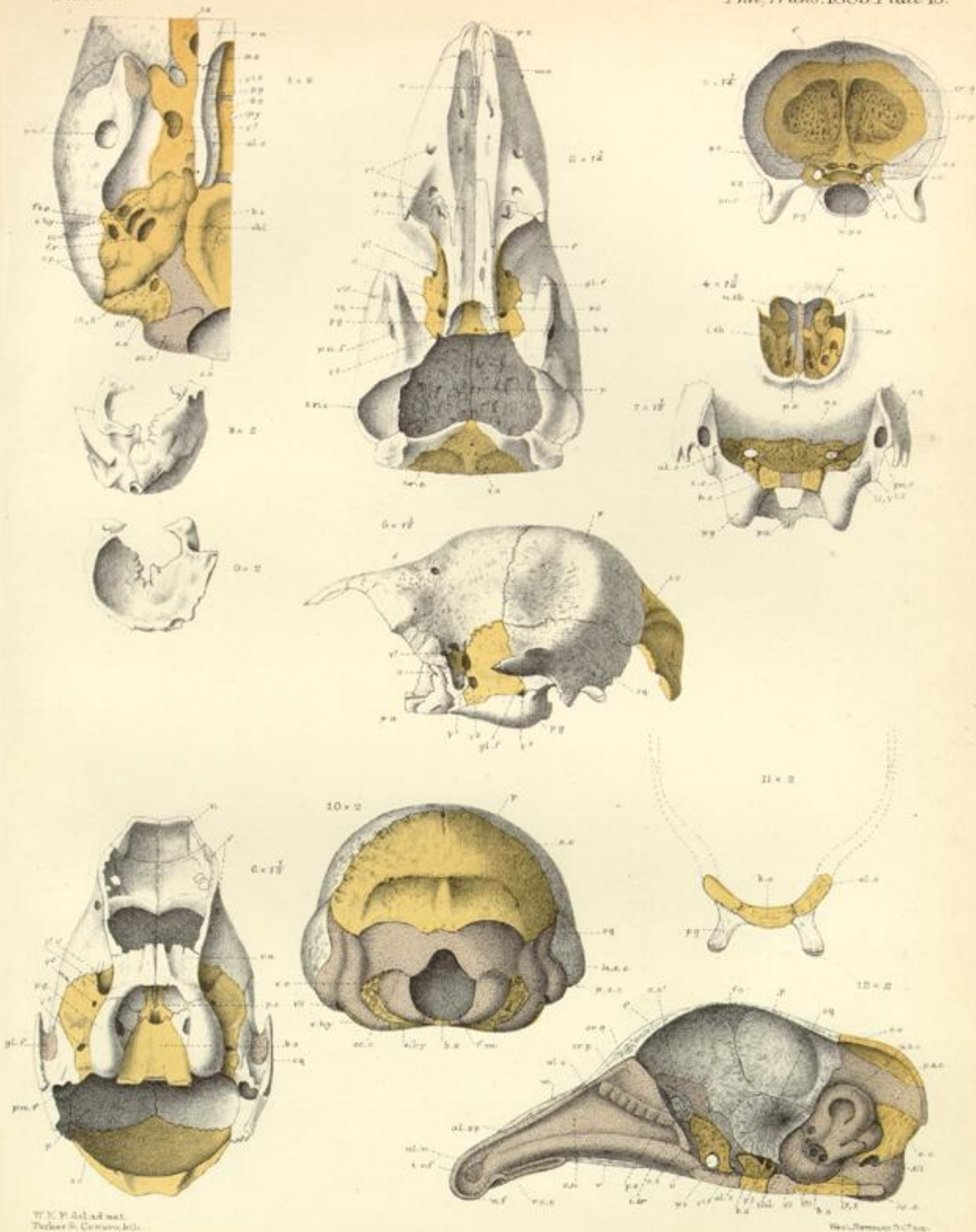

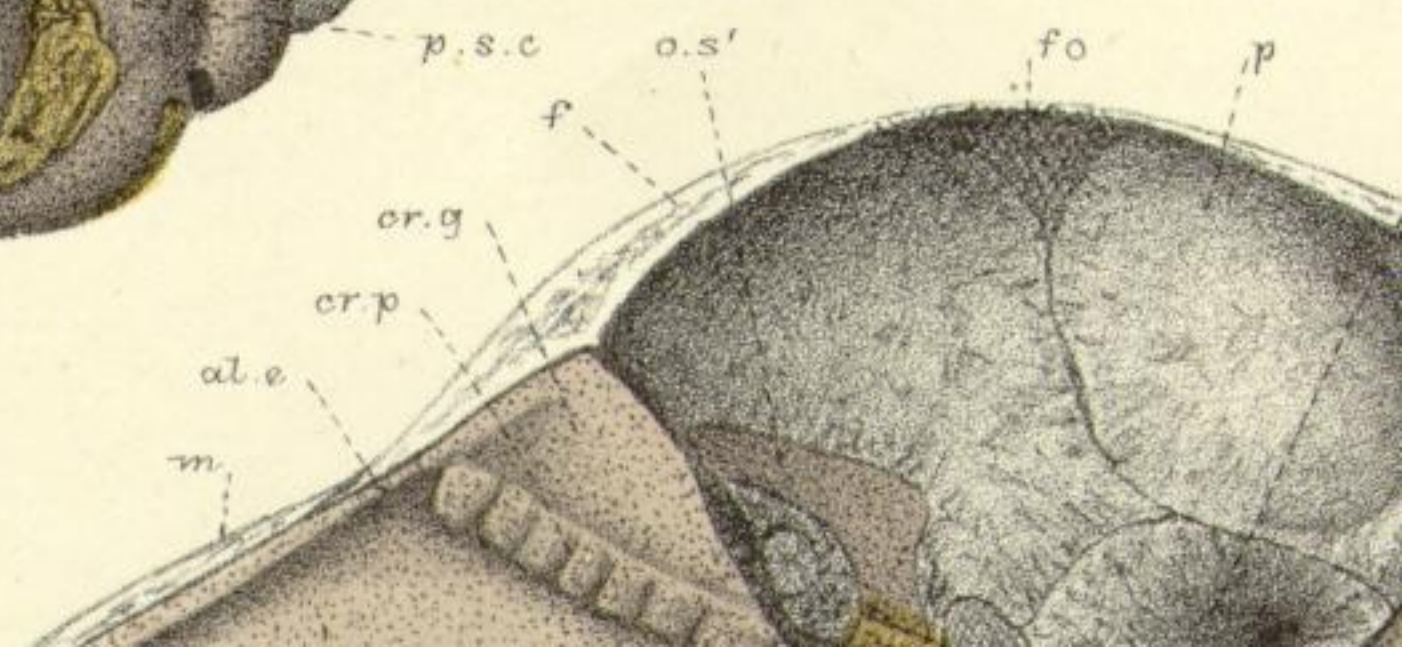
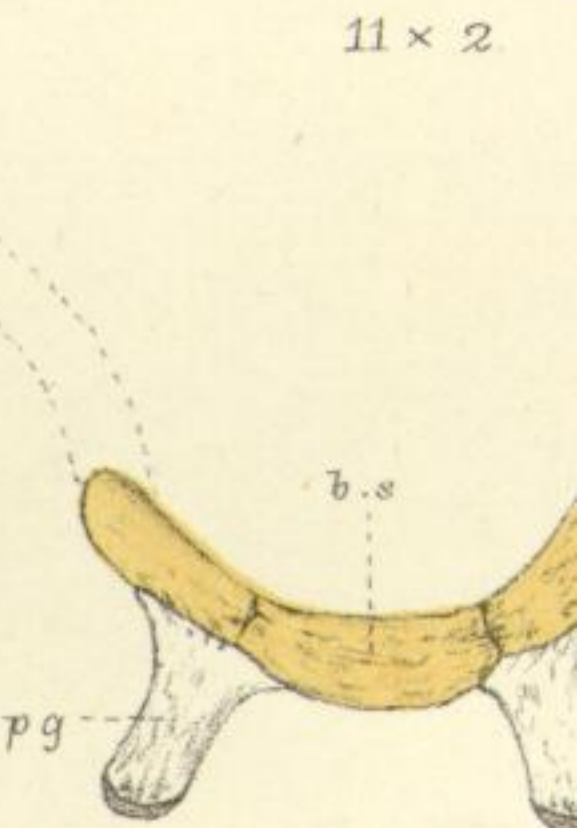
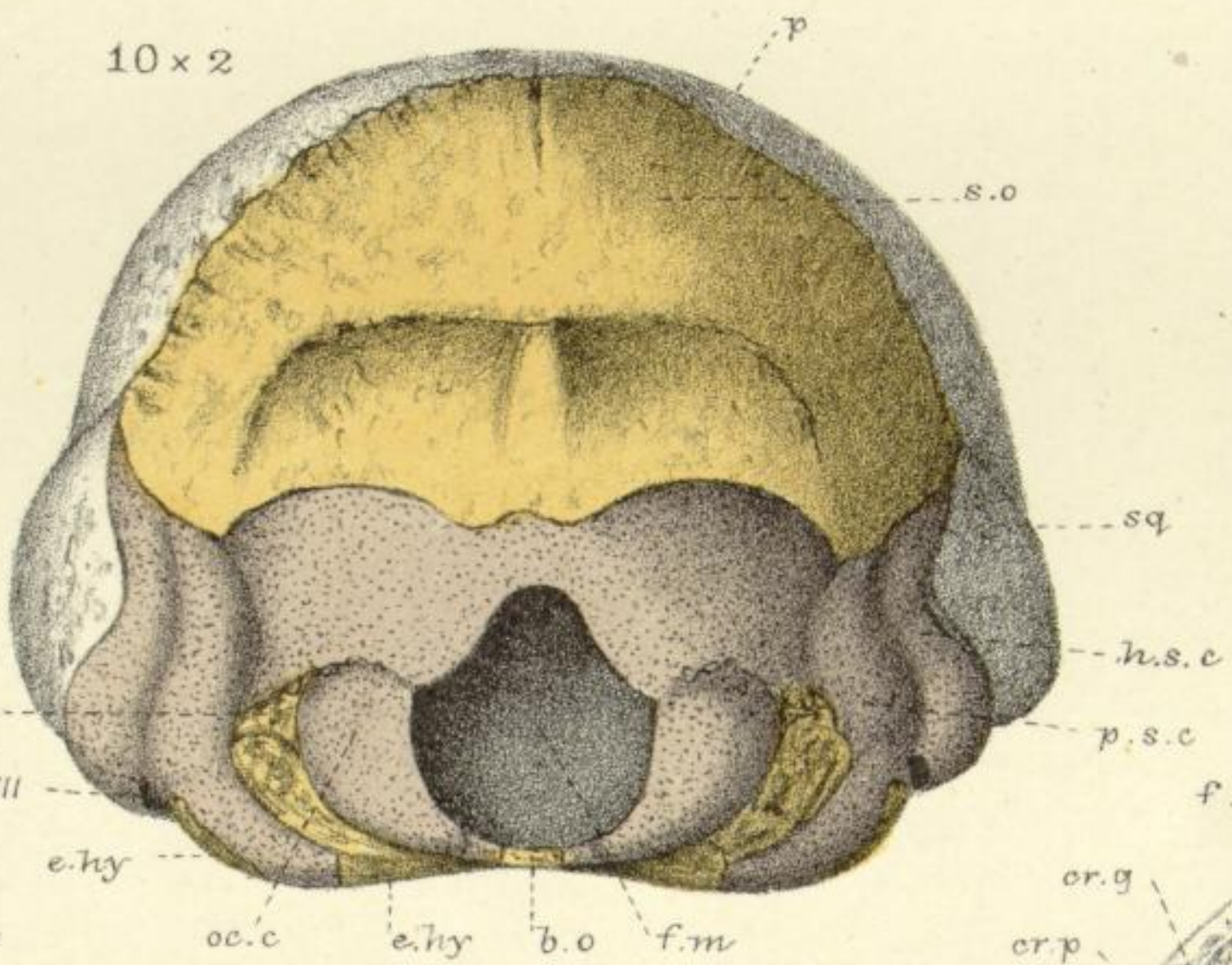
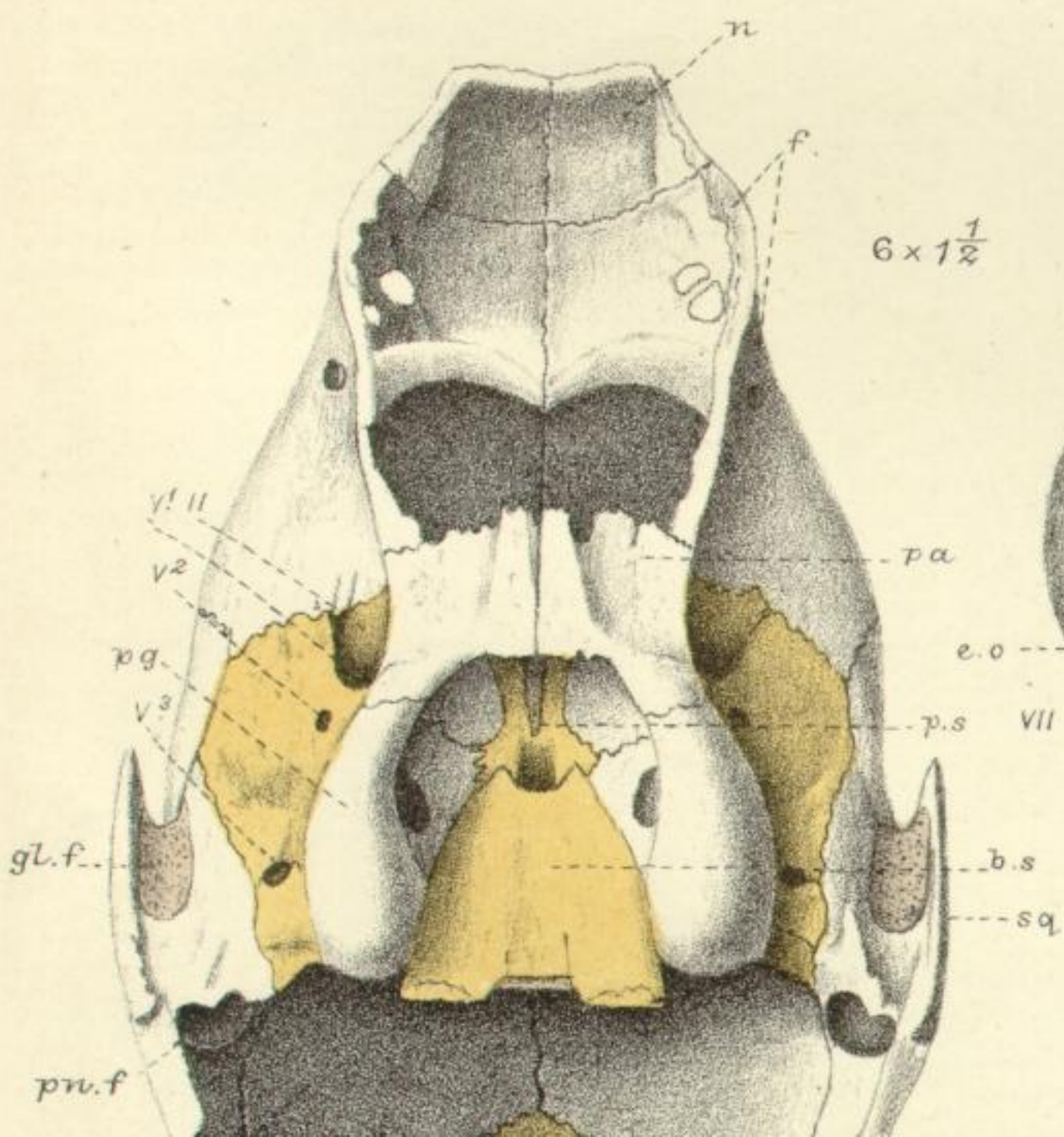
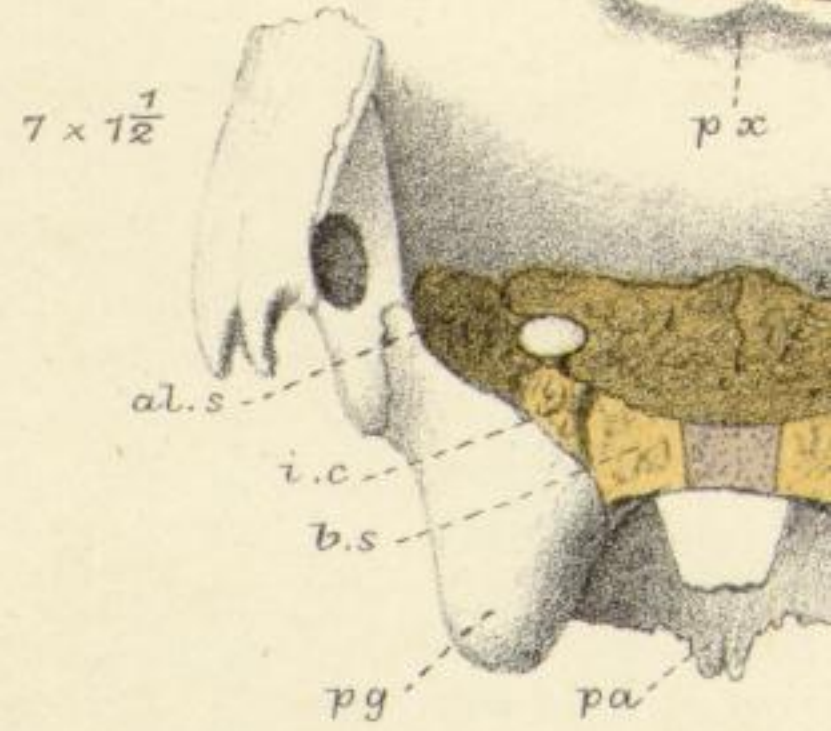
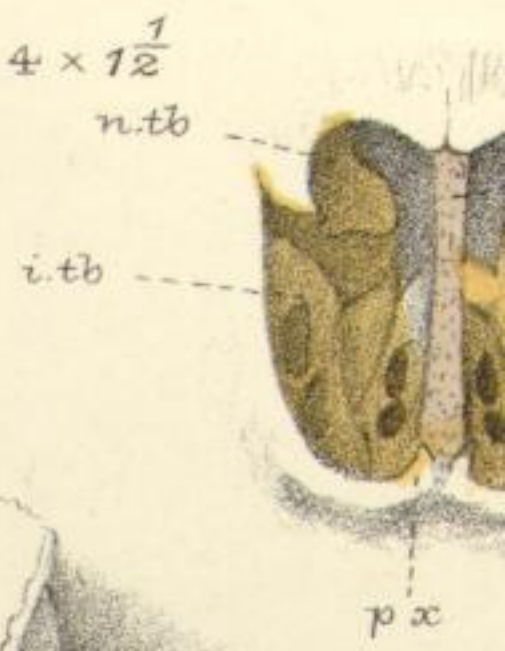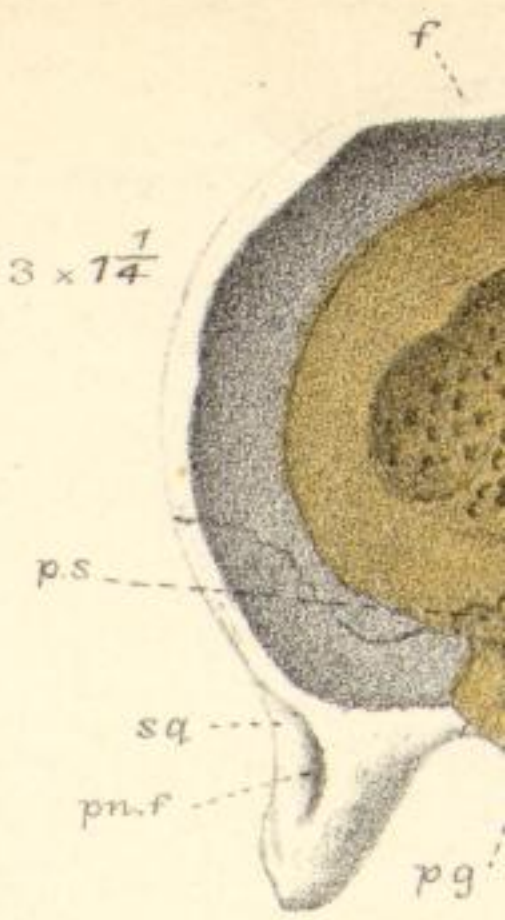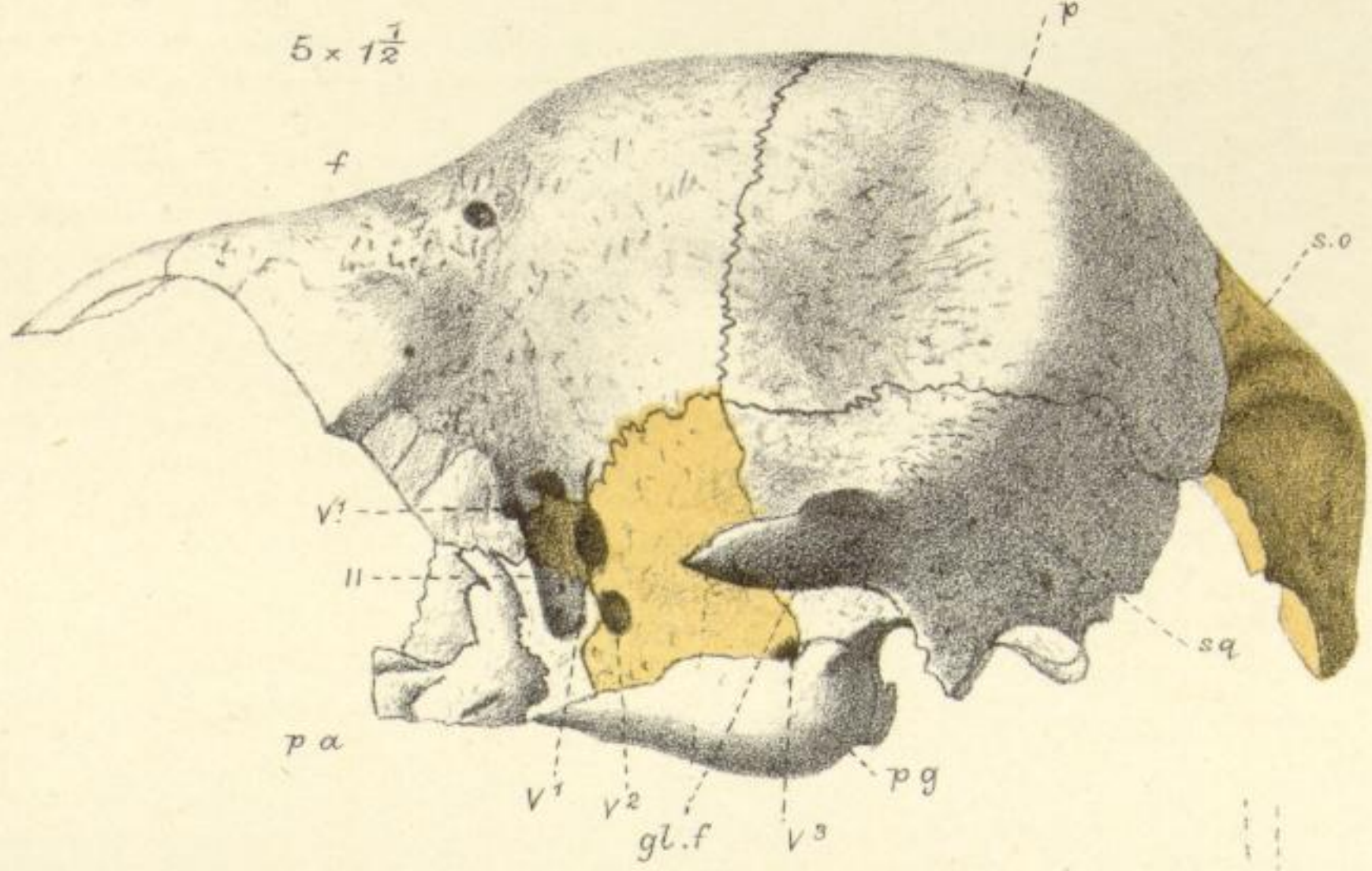
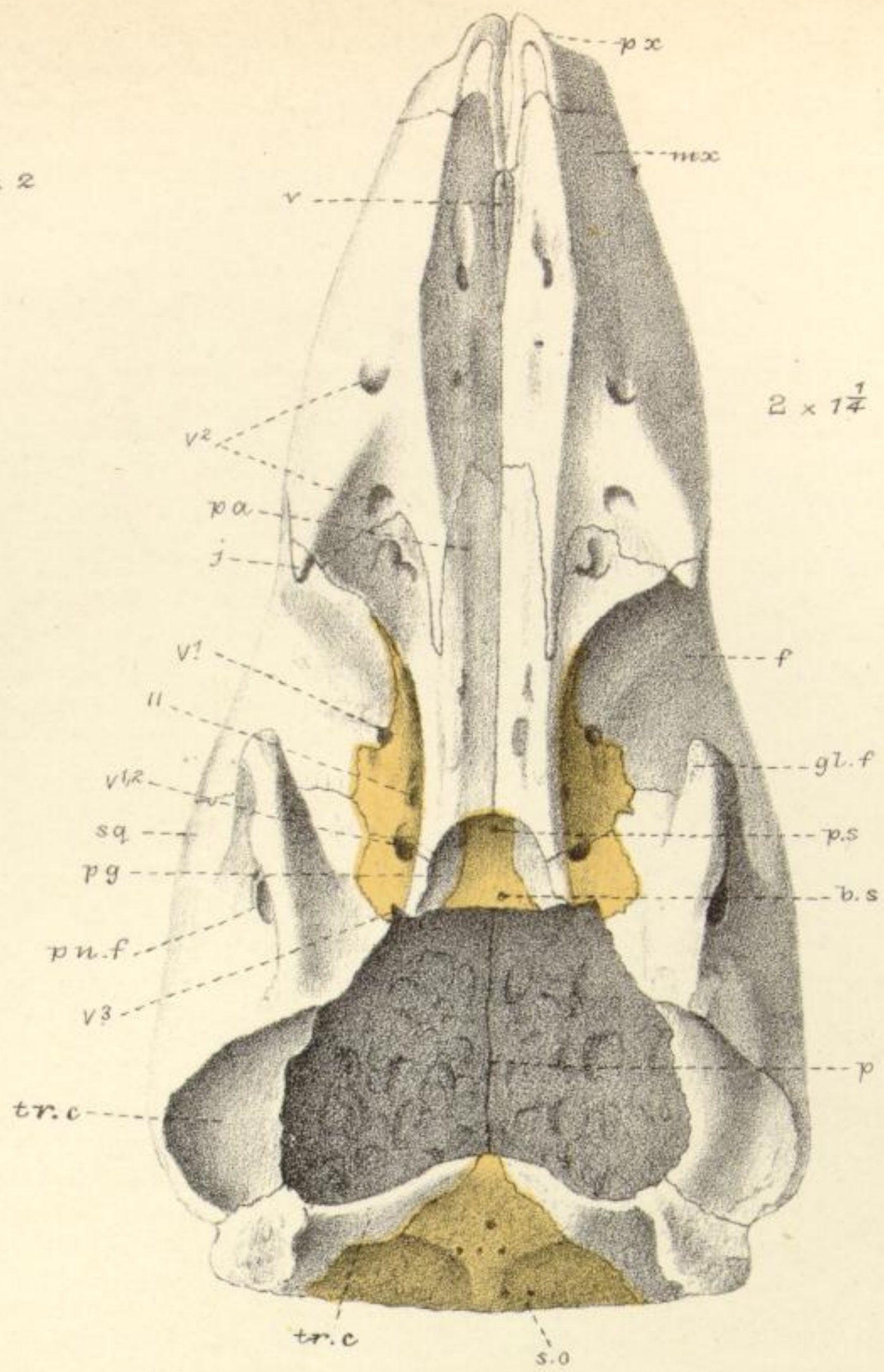
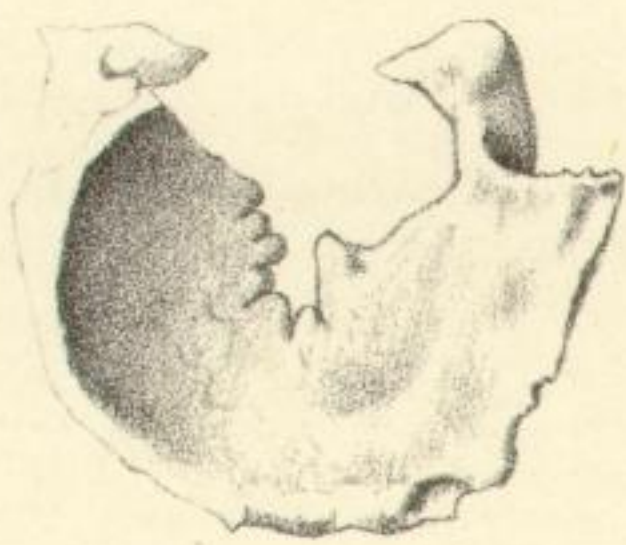
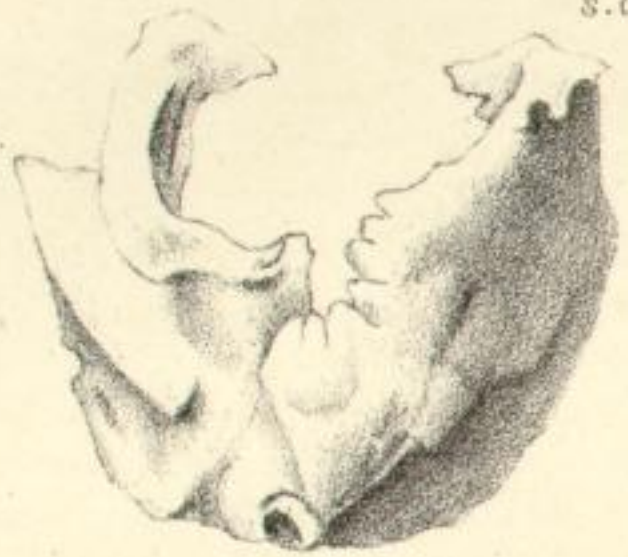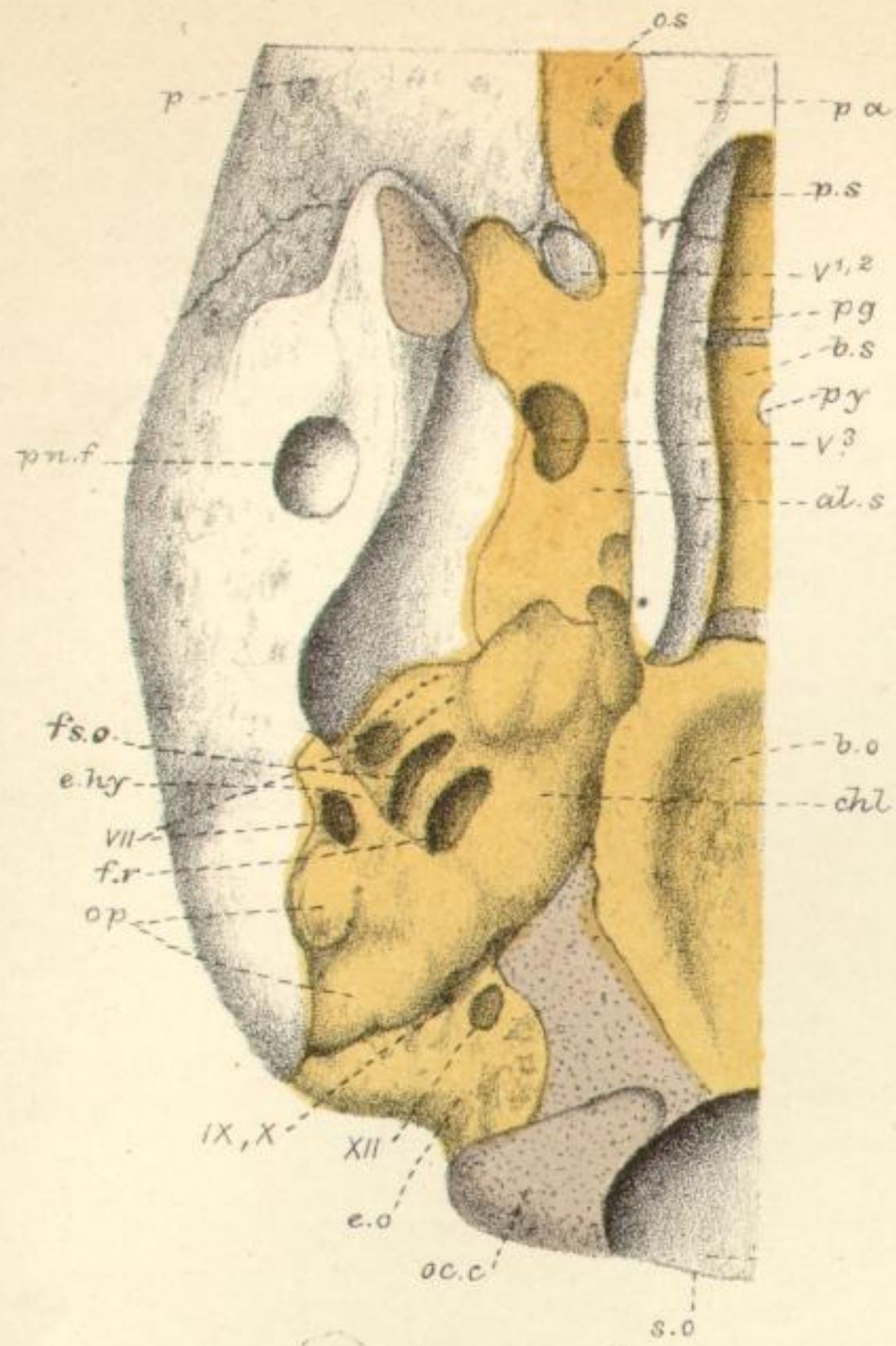


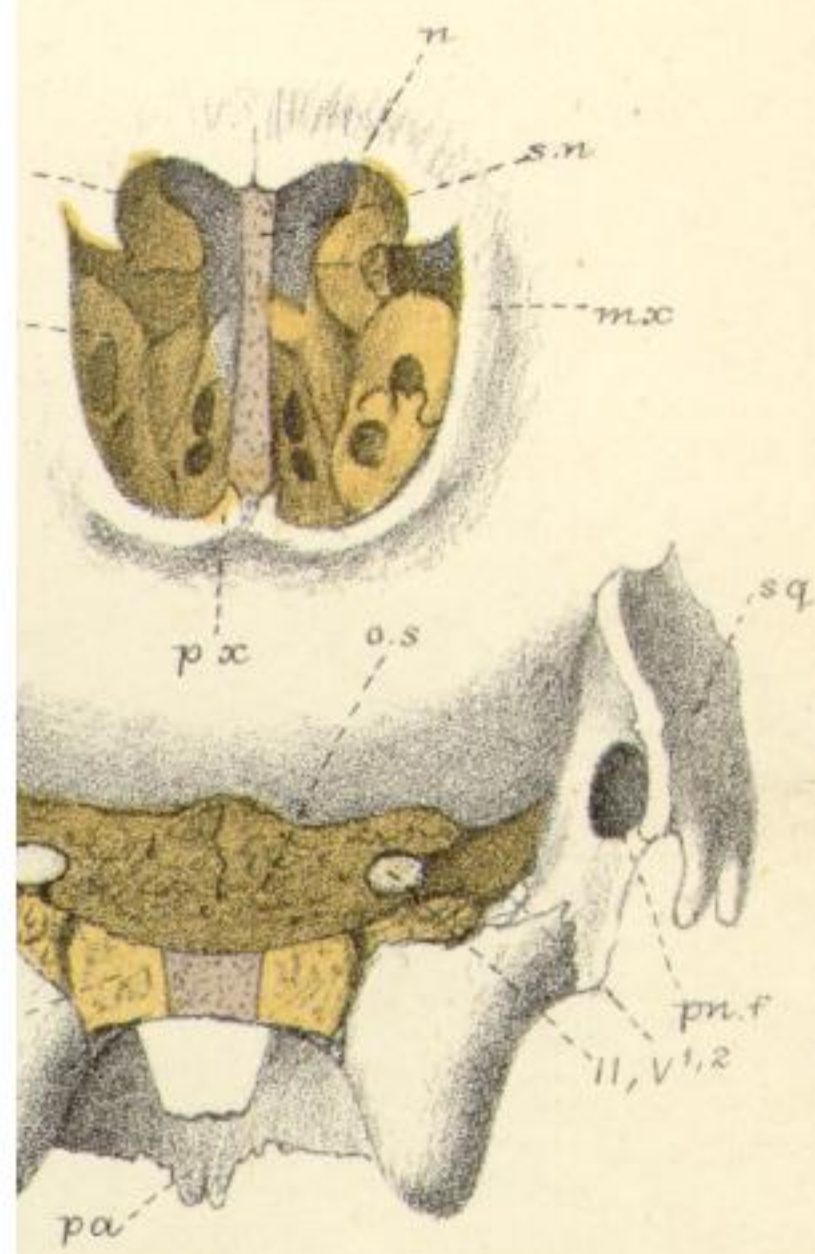
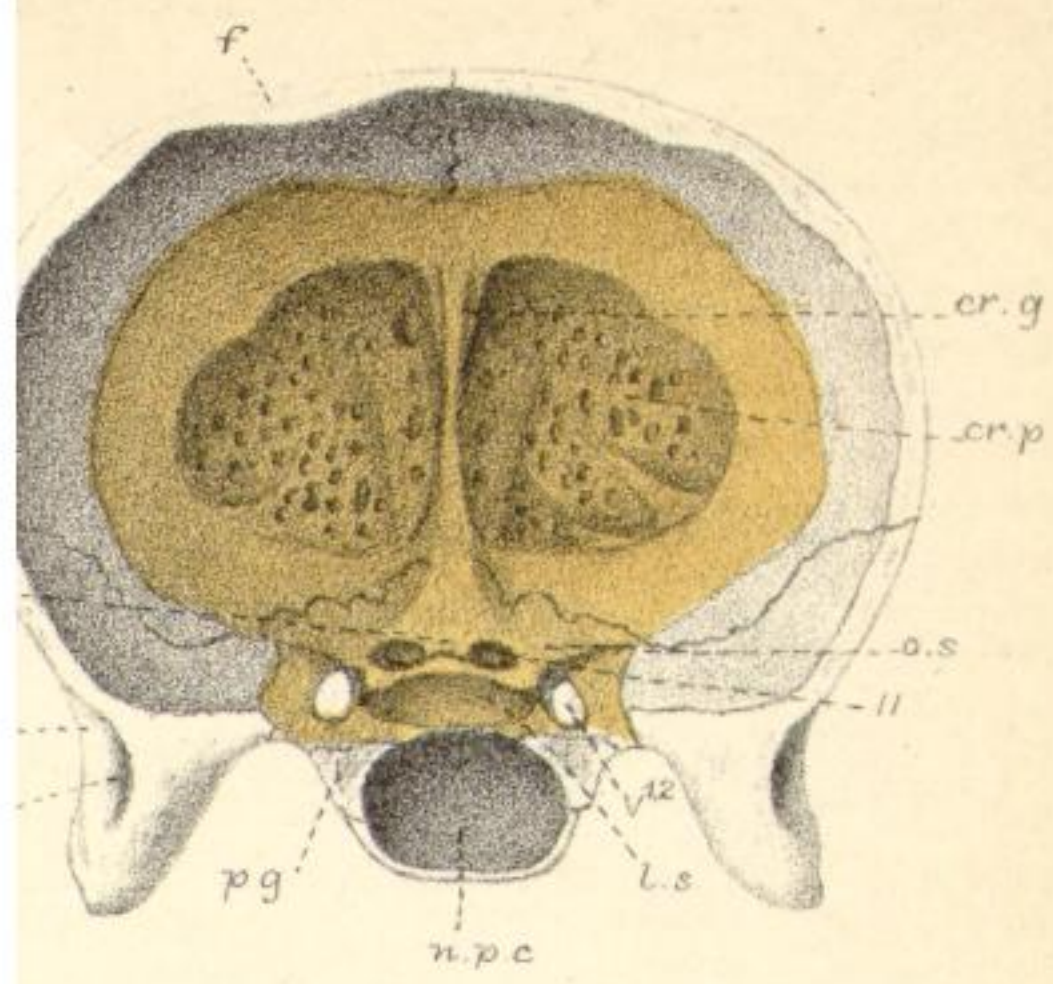
W.K.P. del. ad nat.
Parker & Coward lith.

Cycloturus.

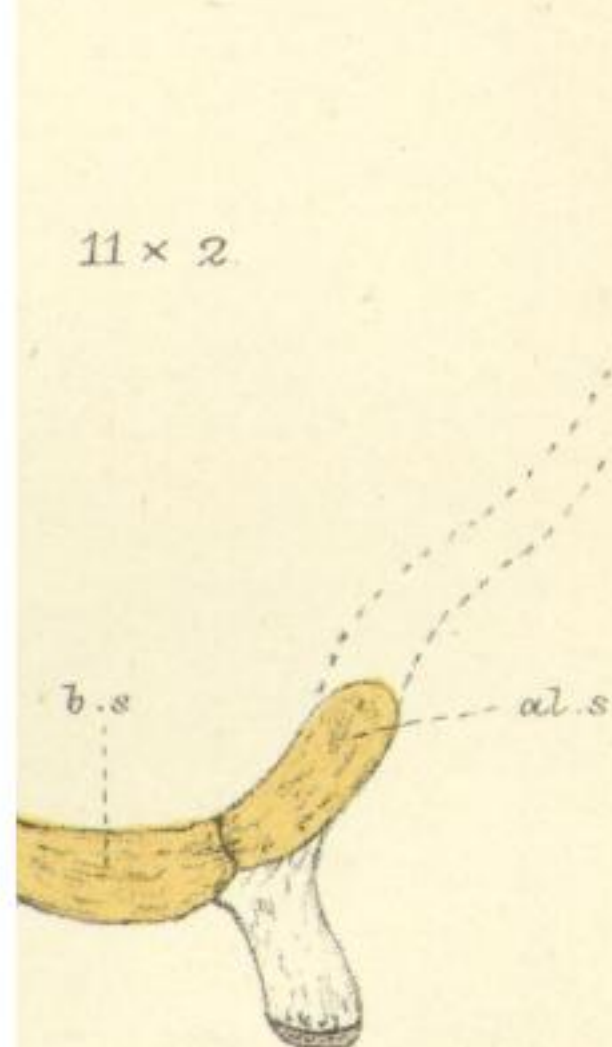




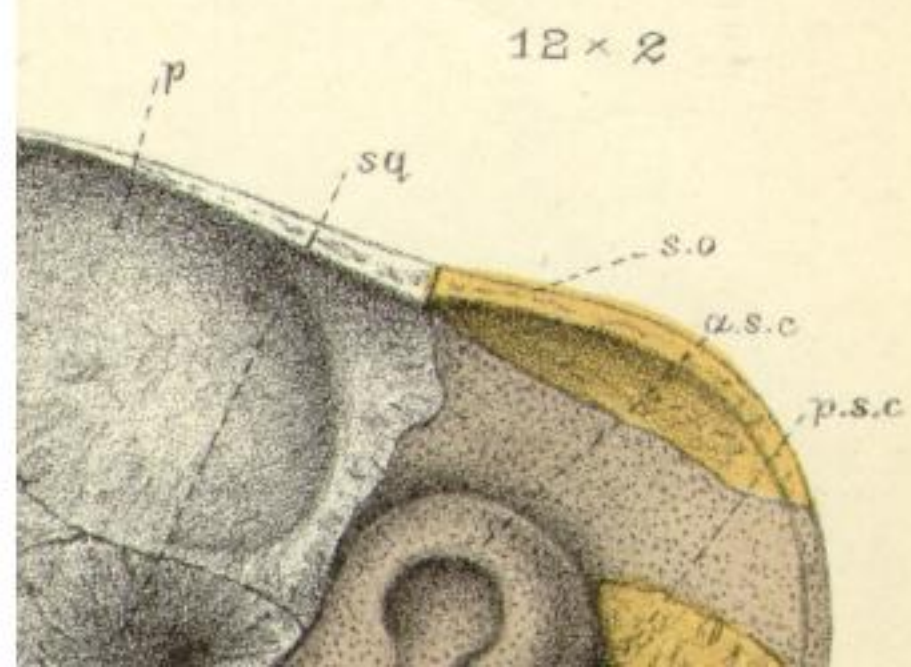


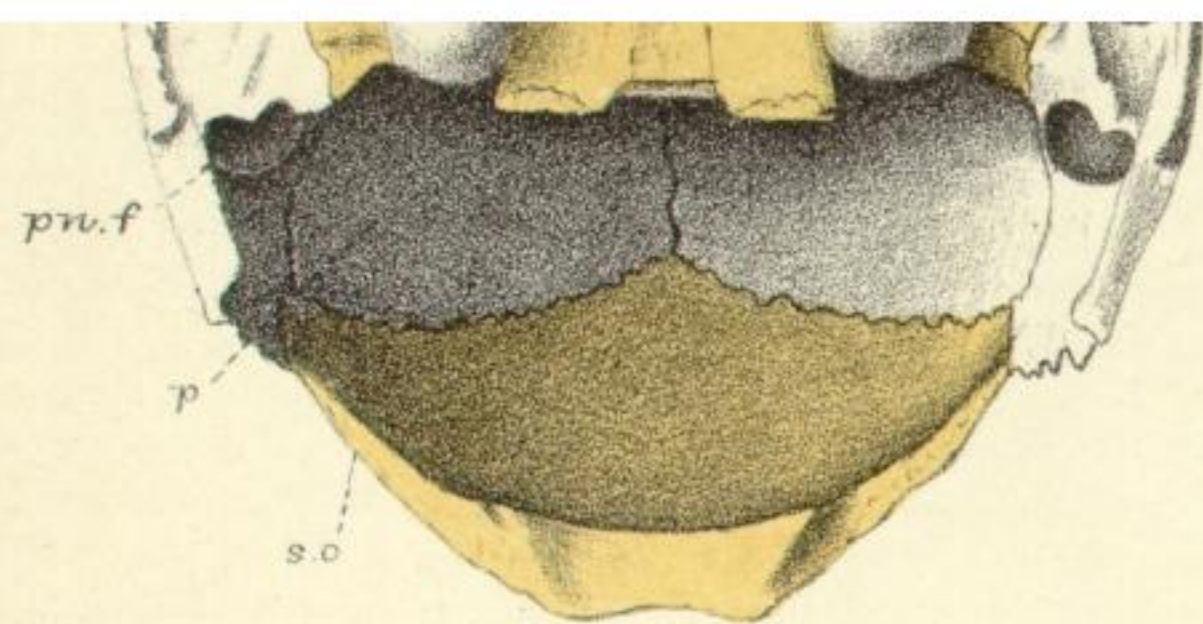


11 x 2

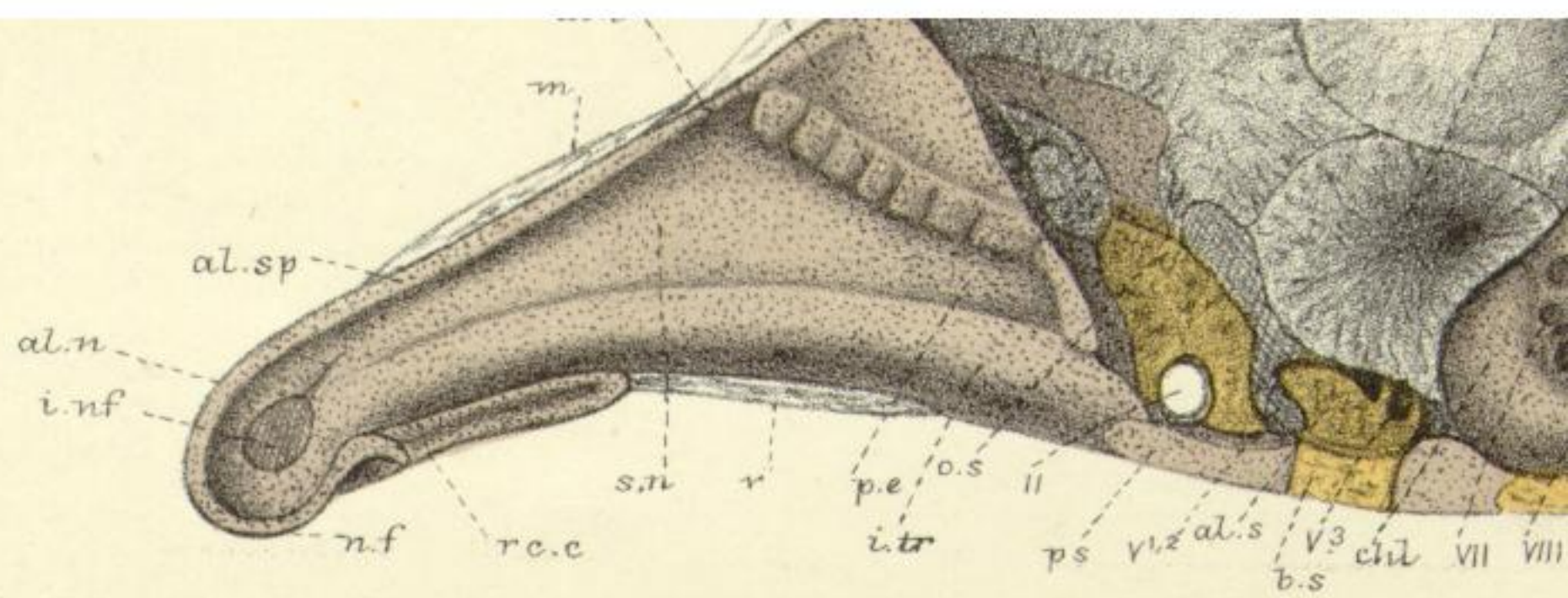


12 x 2

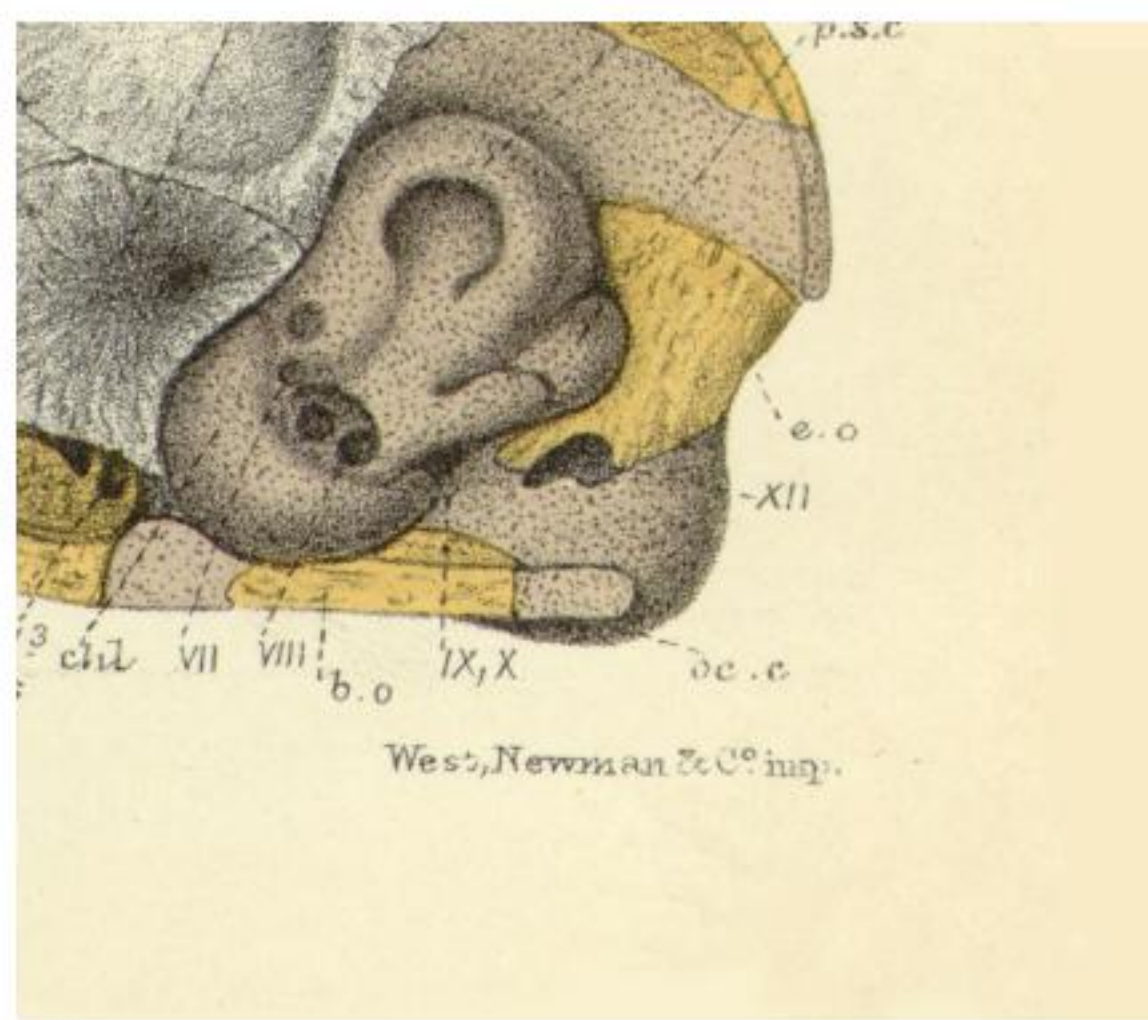


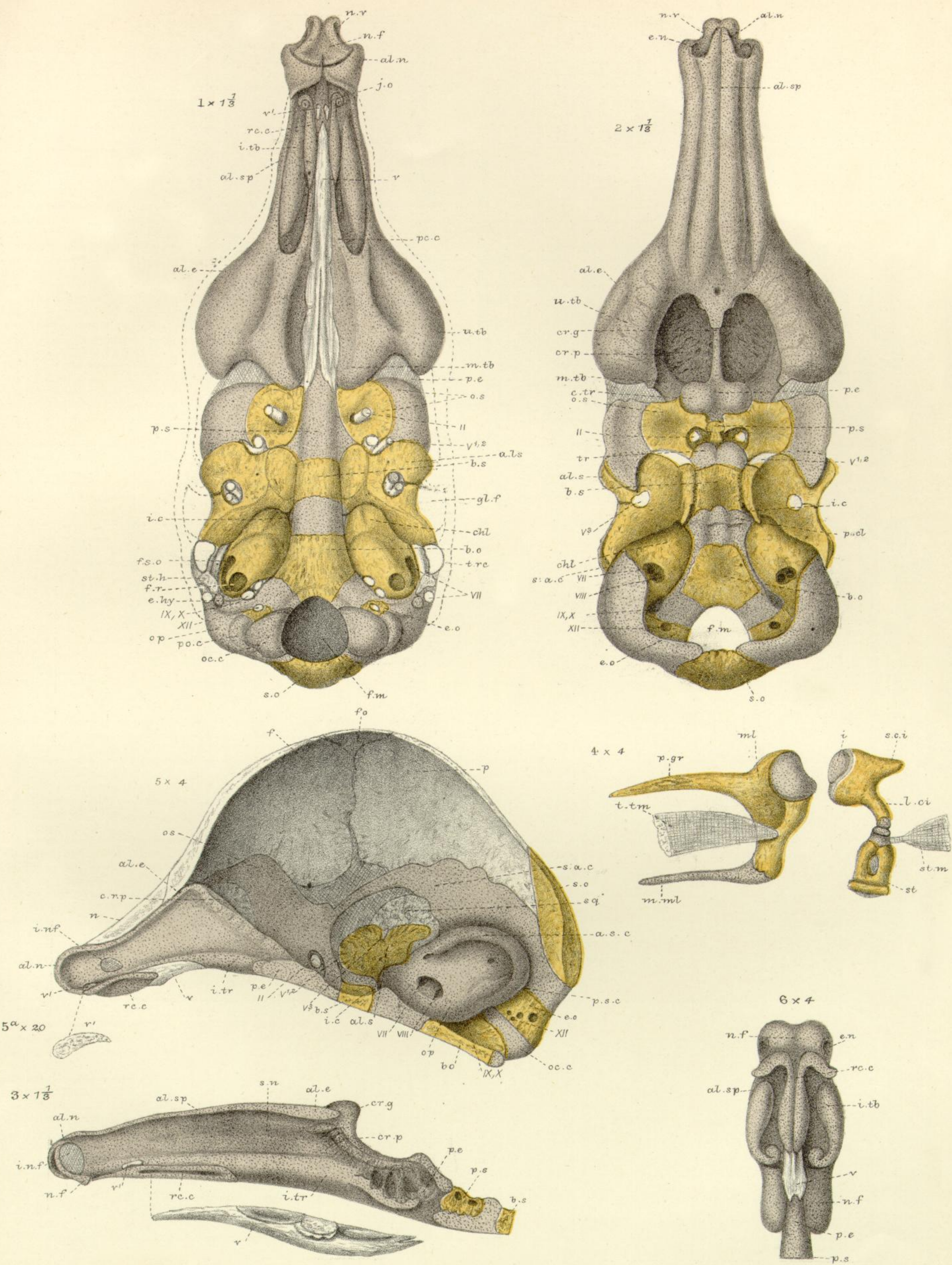


W.K.P. del. ad nat.
Parker & Coward lith.



1-4, & 12, Manis. 5-11, Bradypus.





1-4, *Orycteropus*. 5, 5^a, 6, *Cholopus*.

PLATE 15.

Figures.		Number of times magnified.
1	<i>Orycteropus capensis</i> (continued); endocranium; lower view	1½ nearly
2	The same; upper view	do.
3	The same; septum nasi and vomer; side view	do.
4	The same; ossicula auditus; inner view	4
5	<i>Cholopus didactylus</i> (?) (1st stage), vertical section of skull; inner view	4
5A	The same; separate; anterior paired vomer	20
6	The same; vomerine region of skull; lower view	4