

III. *On the Course of the Fibres of the Cingulum and the Posterior Parts of the Corpus Callosum and Fornix in the Marmoset Monkey.*

By CHARLES E. BEEVOR, M.D., F.R.C.P.

Communicated by Professor DAVID FERRIER, F.R.S.

Received June 12,—Read June 19, 1890.

[PLATES 20—24.]

CONTENTS.

	PAGE.
Introduction	135
Methods of investigation	137
Description of brain of Marmoset	139
Cingulum: previous descriptions	140
,, sagittal direction	143
,, horizontal „	147
,, frontal „	153
,, summary	159
,, calcarine fibres	162
,, superficial fibres of gyrus fornicatus	163
Corpus callosum, posterior part: previous descriptions	165
,, sagittal direction	166
,, horizontal „	171
,, frontal „	176
,, summary	179
Fornix, body and posterior pillar: previous descriptions	180
,, sagittal direction	182
,, horizontal „	185
,, frontal „	188
,, summary	193

THE present investigation has for its scope to follow out the course of certain fibres in the brain which have hitherto escaped minute investigation.

Introduction.

There are various methods which have been adopted to work out the course of the fibres in the brain. The method by dissection of the brain with the scalpel has been

28.4.91

much employed, and though it is doubtless of value in tracing out the coarser strands, it is open to the objection that the parts are very much displaced by the operation necessary to follow out the fibres, and also that relations may be artificially produced which do not actually exist. Moreover it is quite impossible to trace the fibres to their ultimate ending, as this can only be accomplished by the use of the microscope.

The methods of tracing the fibres by producing degeneration in the different tracts by dividing them during life, and also the method of examining the period in foetal life at which the fibres acquire their medullated sheath, which has been employed by FLECHSIG, give most certain results, but they present great difficulties when a large system of fibres like the cingulum, which courses round the whole extent of the brain, has to be minutely examined.

It was also found that to work out the course of the cingulum it was quite impossible to perform this satisfactorily in a brain like that of Man or the Monkey, which possessed a deep calloso-marginal sulcus, round which it was probable that the fibres of the cingulum would have to pass on their way to other parts, and which would prevent them from being traced in any other plane than that of the frontal. Owing to the unwieldy size of the human brain it is very difficult, if not impossible, to trace the fibres under the microscope, and pathological anatomy has not hitherto thrown any light on the course of the fibres treated of in this paper.

It was therefore thought desirable to follow out these fibres by making serial sections in different planes of a small but high brain like that of the Marmoset, and by using reagents which especially differentiate the medullated fibres.

The part of the brain which has been investigated in the present research comprises the cingulum or the longitudinal fibres of the gyrus fornicatus, the body and the posterior pillars of the fornix, and the connections of the posterior part of the body and the splenium of the corpus callosum with the occipital and temporo-sphenoidal lobes.

Before proceeding to a description of the work I shall cite references from some of the best-known text-books, and for this purpose I shall give extracts from QUAIN'S 'Anatomy,' 9th edition, from works on the Brain by MEYNERT, SCHWALBE, OBERSTEINER, WERNICKE, HUGUENIN, HENLE, and from FOVILLE'S 'Atlas of the Brain.' These descriptions apply to the brain of Man only, but, as far as I can ascertain, there is no account published of the minute anatomy of the Marmoset's brain. For the sake of convenience each of the above-named structures will be described separately as it appears in the three different planes, and after tracing it through these different directions a *résumé* will be given of the connections and appearances of each structure as a whole, *i.e.*, in the three dimensions of space. To prevent confusion the references to the various authors for each of the different parts under consideration will be put separately with the description of each part.

Method of Investigation.

The parts of the brain under examination are contained in the interior of the cerebrum and are approached with great difficulty for the purposes of producing degeneration during life, while, as far as we know at present, pathological changes in Man do not throw much light on the subject.

It has seemed to me that the best results would be obtained by making serial sections in different planes of the brain of one of the lower animals, which should be small enough for easy manipulation, and yet at the same time should be sufficiently high in the animal scale for comparison with the brain of Man. For this reason the brain of the Marmoset was almost entirely used, and I have to thank Mr. F. BEDDARD, prosector to the Zoological Society, for kindly providing me with material. The different species of Marmoset used comprise the *Hapale jactans* and *Hapale penicillata*.

In one case the brain of the Bonnet Monkey, *Macacus sinicus*, was employed.

Details of Method.—The brains of the Marmoset were put direct into a 3 per cent. solution of bichromate of potassium, where they were hardened in the usual way from two to four months and in one case for twelve months. After hardening, the brain was embedded in celloidin and cut into sections by SCHANZE'S microtome, from a 50th to a 25th of a millimetre thick. The sections were stained by WEIGERT'S hæmatoxylin method,* and in other cases by PAL'S† modification of WEIGERT'S method. The sections were dehydrated in the ordinary way by absolute alcohol, clarified by oil of cloves or origanon oil, and mounted in Canada balsam. The origanon oil, the use of which was introduced by WEIGERT, has the advantage over oil of cloves in that it does not dissolve out the celloidin, which is thus able to hold together the finer parts of the section and prevent its being torn to pieces in the process of clarifying. It was found, however, that after the use of origanon oil, owing probably to the contraction exerted by the celloidin, these large sections after the application of the cover glass did not present a perfectly flat field when viewed with the higher powers of the microscope, and it was difficult to trace fibres in sections treated in this way.

To obviate this difficulty, and at the same time to prevent the sections from being damaged, the following plan was adopted in some of the sections: they were dehydrated on the slide by absolute alcohol, this was run off without disturbing the sections, which were then clarified by adding origanon oil. When this was completed, the oil was drained off the slide as much as possible, and oil of cloves was carefully added. This was again run off after dissolving the celloidin, drained, and the preparation mounted in Canada balsam dissolved in xylol.

Some of the sections were also cut after imbedding in paraffin. The brain was

* 'Fortschritte der Medicin,' 1884, p. 190; 1885, No. 8.

† 'Brit. Med. Journal,' 1888, vol. 1, p. 510.

hardened in methylated alcohol, it was then put into a 3 per cent. solution of bichromate of potash for two weeks, washed in water and in methylated alcohol and put direct into WEIGERT'S hæmatoxylin for three or four days, developed in the usual way, imbedded in paraffin after passing through absolute alcohol and oil of cloves, and the sections mounted after removing the paraffin by xylol.

Direction of the Sections.—In the following descriptions the sections of the brain were cut in the following planes, viz., sagittal, horizontal, frontal, and fronto-oblique. The sagittal sections were made in a plane which is in a vertical and an antero-posterior direction, in fact parallel to the median surface of one hemisphere. The horizontal sections were cut in a plane which would be horizontal in Man or Monkey when in the erect position. This plane is, therefore, at right angles to the sagittal and along the greatest length of the brain, namely, from the tip of the frontal lobe in front to the tip of the occipital behind. The frontal sections were cut in a plane at right angles to the horizontal, viz., transversely across both hemispheres and in a vertical line. In the fronto-oblique sections the plane was transverse, but instead of being vertical or horizontal it inclines upwards and forwards and downwards and backwards so as to be parallel to the long axis of the medulla oblongata and pons Varolii.

In this way sections were obtained of the brain corresponding to the three dimensions of space; and, for the sake of comparison with the brain of Man, the animal is considered to be in the erect posture with the face directed forwards, and not in the position of walking on four legs, when the face would be directed towards the ground.

In preparing the series for every one plane, all the sections were examined as they were cut, but only those were mounted which presented a slight difference from the section preceding it.

We thus have in the sagittal plane a complete series beginning at the middle line and extending outwards as far as the external capsule; in the horizontal direction a complete series from the upper surface of the centrum ovale above to the level of the crus cerebri below, while in the frontal and fronto-oblique planes the series extends from the level of a fronto-oblique plane drawn through the anterior part of the crura cerebri, and extending backwards to a similar plane through the occipital lobe and at a point a short distance behind the most posterior limit of the lateral ventricle.

In this way it was considered that the different tracts of fibres might be traced from section to section in the individual series, and that points of difficulty which could not be ascertained in one section could be elucidated by examining the part in the other planes, and by combining the appearances seen in the three planes, a mental image of the structure in the three dimensions of space could be obtained.

Description of the Brain of the Marmoset (Hapale penicillata).

The brain of the Marmoset measures in its greatest length from the tip of the frontal lobe in front to the tip of the occipital behind from 3·2 to 3·5 centimetres, and across its broadest part, viz., across the temporo-sphenoidal lobes 2·5 to 2·7 centimetres. Its greatest depth from the vertex to the inferior surface of the temporo-sphenoidal lobe is about 2·2 centimetres.

The frontal and occipital lobes are well developed, and the latter completely overlap the cerebellum. The most striking part about the Marmoset's brain is the almost complete absence of convolutions, the surface being quite smooth and possessing only a few of the chief fissures. Of these only the following can be made out; on the outer surface the *fissure of Sylvius* is well marked (Plates 23, 24, figs. 34, 39, *S.F.**), and has a straight direction upwards and backwards, reaching a point about the middle of the outer surface of the hemisphere. The fissure is represented only by its horizontal limb, as no trace of its anterior ascending limb can be found.

In the temporo-sphenoidal lobe there is a distinct indentation below and parallel to the fissure of Sylvius. This represents the *parallel sulcus* in the brain of other animals.

There is no definite depression for the *fissure of Rolando*, unless its position is indicated by a blood-vessel which runs in the direction corresponding to this fissure in other animals.

On the median aspect of the Marmoset's brain, the surface is very smooth, and there is only the slightest indication of a *calloso-marginal sulcus*, but on frontal section especially in the anterior part it can be seen as a very slight superficial depression in the cortical grey matter.

The most marked fissure on the median surface is the *calcarine* (figs. 5, 34, 44, *F.C.*). It commences behind, near the tip of the occipital lobe and runs forward, at first horizontally, and then turns downwards and forwards. It appears anteriorly to join the dentate or hippocampal sulcus in sagittal sections (see fig. 10, *H.S.*, *F.C.*). But this is really not the case, as on following these sagittal sections outwards, the isthmus of the gyrus fornicatus is seen to separate the two; there is no doubt, however, that the calcarine fissure at its commencement forwards takes origin very near to the dentate (*cf.* fig. 43 right, *H.S.*, *C.S.*). The calcarine is therefore a fissure of very great importance.

In fronto-oblique sections (fig. 44) the direction of this fissure is seen to be in a direction outwards and downwards from the median line, and, as will subsequently be seen, it is in the cortex bounding this sulcus that we have the system of fibres which I have termed the calcarine.

The *Dentate* or *Hippocampal* sulcus (figs. 10, 35, 43 right, *H.S.*) extends from the under surface of the gyrus fornicatus above, downwards along the anterior edge of the

* See Explanation of Plates, pp. 197-199.

gyrus hippocampi to the hollow in the hook of the uncinatè or hippocampal convolution below. It is seen very well in sagittal sections, where it is bounded by the fascia dentata. In frontal sections it forms a deep groove on the median aspect of the temporo-sphenoidal lobe (fig. 40, *H.S.*), and in horizontal sections it is particularly well marked, separating the fascia dentata from the gyrus hippocampi.

In the above description the dentate sulcus has been traced to the under surface of the gyrus fornicatus above. In frontal sections, however, this sulcus can be seen to exist on the inferior surface of the gyrus fornicatus, and lying on the corpus callosum as far forward at least as the vertical level of the optic commissure, as has already been described in other animals.*

It will therefore be seen that with the exception of the gyrus hippocampi with its fascia dentata, and the grey matter bounding the deep calcarine fissure, the brain of the Marmoset has no convolutions. This property is of the highest importance in working out the fibres of the cingulum. Owing to the absence of a calloso-marginal sulcus along the median face of the hemisphere the gyrus fornicatus and its contained cingulum is not separated off from the rest of the median surface (*i.e.*, the gyrus marginalis) and the centrum semi-ovale, as it is in the brain of Man or the Macaque Monkey; but this sulcus in the Marmoset is represented by a slight indentation along the median line, and by the inner surface of the centrum semi-ovale presenting in frontal sections (figs. 39, 40) a slight concavity, at the lower end of which is situated the cingulum in close contact with the corpus callosum and the centrum semi-ovale.

The fibres of the cingulum will not, therefore, have to wind round the deep calloso-marginal sulcus, as in Man and the Macaque Monkey, but can pass direct into the centrum semi-ovale, and their course will thus be brought into view in one of the three planes of sections, a result which it would be impossible to obtain in the two other brains referred to above.

I will now proceed to a detailed description of the structures under consideration, and will begin with the cingulum, giving first the views of the different authorities on the subject.

Cingulum.

Called also fibres of the gyrus fornicatus, fillet of the corpus callosum (MAYO).

Previous Descriptions.—These fibres are described by QUAIN† “as constituting the white substance of the gyrus fornicatus, and they take a longitudinal course immediately above the transverse fibres of the corpus callosum.

“In front they bend downwards within the gyrus to which they belong, and are connected with the anterior perforated space, being joined by certain longitudinal fibres which run along the under surface of the corpus callosum near the middle line. Behind they turn round the back of the corpus callosum, and thence descend to the

* Cf. ZUCKERKANDL, ‘Ueber das Riech-Centrum.’

† QUAIN’S ‘Anatomy,’ 9th edition, p. 356.

point of the temporo-sphenoidal lobe, where, according to FOVILLE, they again reach the perforated space. Offsets from these fibres pass upwards and backwards into the secondary convolutions derived from the gyrus fornicatus in the longitudinal fissure.'

According to SCHWALBE* : " Along the whole course of the gyrus fornicatus, there is a longitudinal system of fibres, situated on the mesial surface of the hemisphere ; starting from the lamina perforata anterior it is situated near to the genu, the body and the splenium of the corpus callosum ; it then follows the course of the gyrus hippocampi to its ending in the gyrus uncinatus. The greater part of these fibres is covered by the grey cortex inside the gyrus fornicatus and gives off fibres to neighbouring convolutions and receives fresh ones in return ; it becomes smaller in the isthmus of the gyrus fornicatus, and again enlarges in the gyrus hippocampi, in the central medulla of which it ends. A small component part of this system of fibres, which remains attached to the upper surface of the body of the corpus callosum, after the gyrus cinguli has become detached from it, is known as the 'tænia tecti.' This set of fibres does not pass into the medullary centre of the gyrus hippocampi, but turns behind the splenium corporis callosi on to the surface of the gyrus hippocampi, forming the peculiar peripheral medullated layer, described as substantia reticularis, which again forms the superficial medullary lamina (Kernblatt) between the subiculum cornu Ammonis and the fascia dentata."

The cingulum, as described by MEYNERT,† " surrounds the corpus callosum ; above it lies a broad convolution after removing the sulcus calloso-marginalis. The medulla of this convolution is joined continuously on to the cingulum as well as the larger and shorter fasciculi proprii of the gyrus fornicatus which cover the cingulum, and it is also joined to the first frontal and parietal convolutions surrounding this gyrus. The lowest bundle of the cingulum lying next to the corpus callosum (nervus Lancisi) connects the Ammon's horn (substantia reticularis) with the olfactory convolution. After the cingulum has formed a covering for the calloso-marginal sulcus, and has formed all these connections with the cortex, its bundles continue backwards below the splenium corporis callosi, and at the highest point join the fasciculi proprii upon which are laid the calcarine and fronto-occipital sulci, these connect the cingulum with the gyrus lingualis."

MEYNERT‡ states that, according to ARNOLD, the bundles run through the corpus callosum from the cortex of the gyrus fornicatus to join the fornix and also into the septum pellucidum, therefore other convolutions besides the gyrus uncinatus send " projection-bundles " through the fornix.

HUGUENIN§ describes the cingulum in terms similar to that of QUAIN, and other authors, and states that " it ends posteriorly and inferiorly in the region of the nucleus

* SCHWALBE, 'Lehrbuch der Neurologie,' Erlangen, 1881, p. 759.

† 'Psychiatrie,' Wien, 1884, p. 37.

‡ *Op. cit.*, p. 39.

§ 'Anatomie des Centres Nerveux,' 1879, p. 126.

amygdalæ, with which it has connections which have not yet been clearly elucidated. Behind the splenium of the corpus callosum the bundle is thinner, and again increases in thickness as it descends in the hippocampus; this difference in size is due to the fact that different systems of fibres contribute to its formation. There is no doubt that there are fibres here which connect the internal surface of the frontal convolutions with the cortex of more distant parts, viz., the apex of the temporal lobe. During the course of this bundle, it forms various intermediate stations of communication, and this is proved by the fact that the bundle of fibres, when traced from their beginning to their ending, do not get progressively smaller, but below the corpus callosum they become larger, as also in the temporal lobe. In the course of the cingulum above the corpus callosum, numerous other fibres from the neighbouring parts of the cortex, join it and then leave it again after a longer or shorter course; this small system of arciform fibres is united to the fibres which go the whole length of the cingulum; these fibræ arciformæ resemble the fibræ propriæ of other parts, and help to swell the size of the cingulum above the corpus callosum; they are least numerous behind the splenium corpus callosi. . . . In Mammalia the cingulum receives at its anterior part fibres from the medulla of the olfactory lobe. . . . These longitudinal fibres of the cingulum are crossed by transverse fibres from the medullary centre of the hemispheres; these terminate in the cortex of the gyrus fornicatus, and are the fibres of the corpus callosum. It is not known whether any fibres of the corona radiata also follow this direction. On the other hand the fibres of the cingulum itself are distributed to the cortex of all the parts situated above it. . . . We have called the bundle of fibres lying beneath the gyrus fornicatus (circonvolution de l'ourlet) a system of association fibres. . . . And as the different parts which they unite have such marked physiological differences we are quite justified in considering these fibres as systems connecting the various functional regions of the brain."

HUGUENIN* also states that "the medulla of the olfactory lobe is united through its internal root to the medulla of the gyrus fornicatus (anterior part), while, by the external root, the olfactory nerve is joined to the medulla of the gyrus hippocampi and to the subiculum of the cornu Ammonis, that is the system of association fibres lying under the gyrus fornicatus."

In FOVILLE's 'Atlas,'† Plate 14, fig. 1, and on Plate 18, fig. 1, the inner surface of the human brain is dissected to show fibres coursing upwards and backwards from the horizontal part of the cingulum along the connecting gyri to the marginal convolution, also to the convolutions below the calcarine fissure, and to the gyrus hippocampi and the nucleus amygdalæ. These are the fibres described above by HUGUENIN, and they evidently take their course on the surface of the convolution, forming a system of "fibræ propriæ," and do not penetrate into the mass of fibres of the centrum ovale.

* *Loc. cit.*, p. 131.

† Paris, 1844.

According to OBERSTEINER,* the cingulum is described "as an arched system of fibres which course in the medullated substance of the gyrus cinguli. The cingulum lies through the greater part of its course on the corpus callosum at that point where its fibres begin to radiate into the centrum ovale, and, as a rule, the cingulum can be seen even in the lower animals, in frontal sections through the hemisphere, as a round bundle of transversely cut fibres."

"We see, therefore,† that in the striæ longitudinales mediales (nervus Lancisi), including the fascia dentata (the outer zone of fibres), we have to look for the real edge of the superficial fibres of the cortex.

"Anteriorly, the striæ longitudinales mediales are continued into the peduncles of the corpus callosum, which descend to the base of the brain; posteriorly, they enter the fascia dentata of the cornu Ammonis, as well as the layer of white matter called the substantia reticularis Arnoldi.

"In some respects, viz., the arrangement of the third layer, the cortex of the subiculum cornu Ammonis has an unmistakable resemblance to that of the gyrus cinguli."

Sagittal sections.—To understand the direction and disposition of the fibres of the cingulum, it will be best to describe it first in sagittal sections, beginning at the median line and passing outwards. Further, it will be convenient to divide it up into three parts, viz., a horizontal, situated in the gyrus fornicatus above the corpus callosum; an anterior part extending in the gyrus fornicatus from the front of the genu of the corpus callosum down to the anterior perforated spot; and a posterior part contained in the isthmus of the gyrus fornicatus and hippocampal gyrus and reaching from behind the splenium of the corpus callosum along the temporo-sphenoidal lobe to its anterior end.

In the sagittal direction after cutting through the grey cortex corresponding to the marginal convolution and the gyrus fornicatus in man, we reach the fibres of the cingulum, which appear first as a faint line of horizontal fibres, running from behind forwards and coursing round the front of the corpus callosum. They lie just above the corpus callosum and are distinct from the fibres of the centrum semi-ovale, except at the most anterior part, where the two seem to blend together.

In front of the genu of the corpus callosum, the anterior fibres have a direction downwards and backwards. They seem to arise in the centrum ovale and run downwards, but where they end cannot be accurately ascertained. At the most inferior part, i.e., next to the anterior perforated spot, the lowest fibres seem to be continued into the olfactory nerve and especially its internal root. It would thus appear that the olfactory nerve is connected with fibres of the cingulum, which proceed from the centrum ovale of the extreme anterior frontal region, and not with those which come from that part of the cingulum which is above the corpus callosum, i.e., the horizontal part.

* 'Nervösen Centralorgane,' 1888, p. 347.

† *Loc. cit.*, p. 359.

It may be remarked here that this root of the olfactory nerve also arises from a group of cells in the angle formed by the nerve with the anterior descending part of the cingulum.

In the next sections the horizontal part of the cingulum, *i.e.*, the part above the corpus callosum, comes into view and it can be divided into two parts, an anterior and a posterior. The anterior part lies directly in contact with the upper surface of the corpus callosum, whereas the posterior part is separated from the corpus callosum by the grey matter of the gyrus fornicatus. This difference in appearance can be explained by examining frontal sections, where it is seen that in sections at the vertical level of the optic commissure (see fig. 39, *Cing. h.*), the principal axis of the cross section of the cingulum is almost vertical, whereas in sections through the more posterior part of the corpus callosum (fig. 40, *Cing. h.*) this axis is horizontal; or in other words, the breadth of the cortex corresponds to the gyrus fornicatus, increases in a horizontal transverse direction as we pass backwards, and in so doing it makes the cross section of the cingulum become more horizontal. It follows from this that a sagittal section of the Marmoset's brain would, at the vertical level of the optic commissure, cut through the cingulum lying on the corpus callosum without passing through any grey matter, while more posteriorly more of the grey matter would appear between the cingulum and the corpus callosum (see p. 154).

The anterior part of the horizontal cingulum lies, as we have seen, on the corpus callosum, and has a direction forwards and downwards, parallel to the upper surface of the corpus callosum. The connexions of its fibres are very difficult to ascertain; posteriorly they seem to come from the cortex of the gyrus fornicatus, and anteriorly they appear to end in the centrum ovale, but this is not at all certain. In the posterior part of the horizontal cingulum the connections are more decided. Here, as has already been mentioned, the fibres of the cingulum are separated from the corpus callosum by the intervening cortex of the gyrus fornicatus (figs. 1-4).

As this posterior part of the horizontal cingulum comes more in view as we proceed outwards, the anterior part which was seen to be close on to the corpus callosum gradually disappears, till in fig. 1 we have only the posterior part visible. This would show that the horizontal part of the cingulum is not parallel to the median line, but that its direction runs backwards and outwards, and, therefore, it is not possible to see its whole extent in any one section cut parallel to the median surface. In figs. 1-4, the posterior part of the cingulum forms an arch beneath the centrum semi-ovale, and contains in its concavity the cortex of the gyrus fornicatus. The arch consists of fibres having an antero-posterior direction; its posterior end appears to spring from that part of the gyrus fornicatus which is posterior to the corpus callosum, *i.e.*, the commencement of the isthmus, and the anterior leaves off abruptly near the upper surface of the corpus callosum. On microscopical examination a very definite arrangement of its fibres can be made out; posteriorly the arch receives fibres from the cortex of the gyrus fornicatus, and then along the whole convexity of the arch the

fibres which it received posteriorly run forward and are then directed upwards and forwards into the centrum ovale. The arch is therefore not formed by a continuity of fibres from end to end, but each fibre runs for a certain length in it, and then turns upwards into the centrum ovale. Whether the cavity of the arch receives any fresh fibres from the gyrus fornicatus it is not possible to say for certain, but it is certain that fibres do come from the isthmus behind the corpus callosum. We have here, therefore, a relay of fibres whose direction is always from behind forwards and upwards to pass into the centrum semi-ovale.

The fibres which are most inferior in the arch, *i.e.*, those nearest to the corpus callosum, start their upward course into the centrum semi-ovale at a more anterior point than the fibres which form the superior convex part of the arch, or, in other words, the more anterior fibres are nearer to the median line, and also pass up into the centrum ovale anteriorly to the more external fibres.

The fibres which pass into the centrum ovale run upwards and forwards, and although they can be traced half way through its vertical depth, it has been impossible, owing to their complex arrangement, to trace them to the cortex on the vertex of the brain. It is suggested, however, that probably such is their destination.

As we pass to sections which are further removed from the middle line, the arch of the cingulum becomes smaller at the expense of its anterior part (fig. 4), and the gyrus fornicatus diminishes also in size until we reach the point where the cingulum is cut through by the fibres coming out from the posterior part of the corpus callosum to sweep round into the occipital lobes forming what is known as the tapetum.

The posterior fibres of the arch of the cingulum, *i.e.*, behind the corpus callosum, which are situated in the hinder part of the gyrus fornicatus, here end in the form of a bulb (fig. 5, *Cing. p.*), whence fibres pass down to the superficial surface of this convolution (fig. 5, *S.f.*).

The part of the cingulum in front of the intercepting fibres of the corpus callosum soon disappears in the next sections, leaving only the bulbous portion behind the splenium of the corpus callosum (fig. 5).

This bulbous enlargement comes into close relationship with a system of fibres which we may call the calcarine fibres (fig. 5, *C.f.*) (by which is meant the fibres contained in the convolution which, in the Marmoset, surrounds the prolongation of the calcarine fissure within the occipital lobe, see p. 162), and it forms the central white matter of the portion of the gyrus fornicatus which remains posterior to the corpus callosum, lying intermediately between the horizontal and posterior divisions of the cingulum.

The fibres in this bulbous formation of the cingulum soon assume an oblique direction, and appear in these sections as points, or in short lengths, where they are cut directly across or obliquely, and this direction of the fibres persists for some

distance, as the same appearance is seen in as many as six or seven successive microscopical sections of this series (figs. 5-9).

During this course the direction of the fibres is in a plane at right angles to the sections, and they form part of the inner wall of the posterior cornu of the lateral ventricle, being separated by the ventricle from the posterior part of the corpus callosum and its tapetum.

The posterior part of the gyrus fornicatus soon begins to be prolonged downwards and forwards (fig. 9) to join the hippocampal or uncinate convolution, forming what is known as the isthmus of the gyrus fornicatus. The relation of the isthmus of the gyrus fornicatus to the calcarine fissure has been referred to in the anatomical description of the Marmoset's brain (p. 139).

The bulb of the cingulum, whose fibres, as we have seen above, have assumed a transverse oblique direction, now send a prolongation of fibres downwards and forwards along the isthmus of the gyrus fornicatus (fig. 10, *Cing. p.*), while at the same time the superficial fibres of the gyrus hippocampi (*S.f.*) are prolonged along the dentate sulcus (*H.S.*). The former fibres are soon seen (fig. 11, *Cing. p.*) to sweep downwards and forwards in a thick leash in front of the fibres of the corona radiata which are continuous with those of the occipital region below the calcarine sulcus, into the descending hippocampal gyrus.

The cingulum then courses along the centre of the hippocampal gyrus to end in the cortical surface on the inferior part of the temporo-sphenoidal lobe, but it has no connection with the nucleus amygdalæ situated in front of the uncinate or hippocampal convolution.

We thus have the third or posterior part of the cingulum in its entire extent reaching from behind the forceps major above, down to the anterior part of the temporo-sphenoidal lobe below. In this extent its size does not vary much, except that at the lower part it swells out before finally tapering off.

In sections still further removed from the middle line the fibres of the cingulum are intercepted in the isthmus of the gyrus fornicatus by another band of fibres. These come from that part of the corpus callosum which is known as the forceps major (fig. 11, *F.M.*), and which is situated between the main body of the corpus callosum above and the upper end of the cortex of the hippocampal or uncinate convolution below, and just anterior to the descending fibres of the cingulum, from which latter it can be distinguished by its oblique direction downwards and backwards, and by the fact that its fibres are stained a much deeper colour than the cingulum.

These fibres of the forceps major (fig. 12, *F.M.*) course downwards and slightly backwards through the outer fibres of the cingulum, which they cross at an oblique angle, and their dark stained fibres (with WEIGERT's method) are in marked contrast to the paler fibres of the cingulum. (See corpus callosum, p. 170.)

After this decussation of the two sets of fibres, the cingulum diminishes very much in size and only its lower end remains.

As far as can be ascertained, this posterior part of the cingulum in the temporo-sphenoidal lobe does not send any fibres forwards into the uncinate or hippocampal convolution, but, on the contrary, communications (figs. 11 and 12, *S.f.*) from the superficial fibres of the cornu Ammonis run forwards and downwards to join the descending fibres of the cingulum. At its most inferior part it forms a thick leash of fibres (figs. 11, 12, *Cing. p.*) situated just below the uncus of the uncinate convolution, and from this leash fibres are given off into the cortex on the inferior surface of the temporo-sphenoidal lobe, extending to its anterior end.

As far as can be judged from these sections the descending fibres of the cingulum do not end either in the hippocampal convolution or in the nucleus amygdalæ of the hippocampal lobule.

The direction of the individual fibres of this posterior portion of the cingulum in the upper part of its course is in the long axis of the tract, but at its lower end it receives offsets from the superficial fibres of the cornu Ammonis which enter it in a direction downwards and forwards. Here the tract of the cingulum is made up of a series of oblique fibres which spring from the superficial fibres just mentioned (figs. 11 and 12, *S.f.*), and go obliquely through the long axis of the cingulum to end in the cortex on the under surface of the temporo-sphenoidal lobe.

In sections nearer the middle line this most inferior part of the cingulum is crossed by the fibres of the alveus (see Fornix, p. 184).

The appearance of the cingulum, as it is seen in horizontal sections will now be considered.

Horizontal sections.—On making successive sections in a horizontal direction, beginning at the vertex and proceeding downwards, we arrive at the white matter of the centrum ovale (compare frontal sections of cingulum, fig. 39), and soon the first indication of the cingulum (horizontal part) appears on the median side of the centrum ovale as fine fibres having a horizontal antero-posterior direction.

These fibres occupy about the second fourth of the whole length of the section. Posteriorly they end abruptly, but anteriorly and along their whole outer border they turn outwards into the centrum ovale, and it is observed that the fibres which are situated nearest to the middle line make this turn outwards into the centrum ovale at a point further forward than the fibres which are more external, similar to what was seen in sagittal sections.

On proceeding lower (fig. 13, *Cing. h.*), we find the cingulum as a band of horizontal fibres running in the antero-posterior direction. It presents two curves, namely, an anterior one which is convex towards the middle line and a posterior which is concave. This convexity explains how the anterior part of the cingulum is brought nearer to the median line in sagittal sections (see p. 144) than the posterior part.

The cingulum is here bounded immediately on the inner side by the grey matter of the gyrus fornicatus (*G.F.*), and on the outer side by the white matter of the centrum ovale (*C.R.*).

At this level its fibres turn outwards and forwards into the centrum ovale at its anterior end only, while posteriorly it forms a club-shaped bulbous enlargement, which comes into close contact with the calcarine fibres (*C.f.*) (see p. 145).

On tracing the fibres of the cingulum in succeeding horizontal sections (fig. 14, *Cing. h.*) the middle part disappears while the two ends continue, thus showing that the fibres have an arched direction from before back (comp. sagittal sections, p. 144).

In subsequent sections (fig. 15) the only parts of the cingulum which are visible are these anterior and posterior ends of the arch.

When we have passed the level of the inferior margin of the gyrus fornicatus and reached the fibres of the corpus callosum as they cross to the opposite hemisphere, the posterior end of the arch of the cingulum (fig. 16, *Cing. p.*) appears in the gyrus fornicatus, close to and posterior to the hinder part of the corpus callosum, and in close apposition to the calcarine fibres (*C.f.*) which bound it posteriorly. It presents a dotted appearance, showing that its fibres are cut across, and it is in marked contrast to the calcarine fibres, which have a more or less horizontal direction. The fibres of the cingulum are also distinguished from the calcarine by staining a slightly lighter colour. These two sets of fibres become very intimately connected, but lower down the calcarine are diminished in number. The cingulum while maintaining its descending direction appears to send off fibres which turn outwards and end abruptly at the inner wall of the lateral ventricle. They are in short lengths and are evidently the continuation of the cingulum in an oblique direction outwards and downwards (fig. 18). These fibres lie close to the inner wall of the posterior cornu of the lateral ventricle, being only separated from that cavity by a thin layer of the corpus callosum, whose fibres have a direction at right angles to those prolonged from the cingulum. On the inner side of the cingulum are the calcarine fibres, which are distinct from those of the former. Consequently, at this level (fig. 22), we have on the inner wall of the posterior ventricular cornu (*L.v.p.*) the fibres arranged in the following order, beginning from the ventricle and going backwards and inwards :—

- 1st. The fibres of the corpus callosum (*Spl.*).
- 2nd. The prolongation from the cingulum, having a direction at right angles to the former (*Cing. p.*).
- 3rd. The calcarine fibres, having a direction backwards, but less outwards than those of the cingulum (*C.f.*).

The 1st and 3rd of these fibres will be referred to later.

The fibres of the anterior part of the arch of the cingulum (figs. 16–22, *Cing. a.*), are now seen in front of the genu of the corpus callosum in the anterior descending part of the gyrus fornicatus, where they send fibres forwards and outwards into the centrum ovale.

In tracing the posterior part of the cingulum arch downwards (fig. 23, *Cing. p.*) its fibres are gradually pushed backwards and outwards by the formation of the hippocampus major (*C.A.*), which intervenes between the corpus callosum (*Spl.*) and the cingulum; the latter thus comes to occupy the position of the fibres prolonged backwards from it above. The calcarine fibres, still lower (fig. 28) form a faintly stained descending tract, showing only their cut ends (figs. 28-34, *C.f.*), and situated behind the commencing hippocampus major (*C.A.*). This tract of calcarine fibres is prolonged backwards from the neighbourhood of the cingulum along the inner wall of the posterior cornu and extends to the tip of the central white matter of the occipital region, its fibres presenting the appearance of points, *i.e.*, cut across (fig. 34, *C.f.*).

In all these sections (figs. 23-34) the cut-across cingulum lies behind the cornu Ammonis or hippocampus major (*C.A.*), and as we descend in the sections this becomes more developed, and at the same time the cingulum becomes flatter in appearance. It is in contact posteriorly with the tract of calcarine fibres (*C.f.*) which are here continued along the inner wall of the posterior ventricular cornu; on the outer side of the cingulum is the forceps major (*F.M.*), from the splenium corporis callosi, which has now reached the posterior surface of the cornu Ammonis (fig. 29); its inner end projects into the cortex of the gyrus hippocampi, where it comes into contact with the superficial fibres of this gyrus (*S.f.*, fig. 29). In the above arrangement the forceps major is readily distinguished from the cingulum by the fact that its fibres are so much more deeply stained.

In fig. 35 we have the superficial fibres (*S.f.*) of the gyrus hippocampi very well marked, situated along the posterior edge of the dentate or hippocampal sulcus (*H.S.*) and with a horizontal direction, which later becomes descending. They lie just in front of the cingulum, arching round it, but no definite connection can be made out between them at this level.

The principal axis of the cingulum (as seen in these sections), which had been transverse, now assumes more of an antero-posterior direction, the external end becoming the more posterior (figs. 34-38).

The calcarine fibres prolonged backwards along the inner wall of the posterior cornu have now (fig. 35, *C.f.*) a more horizontal direction, namely, outwards and backwards, and at right angles to the fibres of the forceps major, which is now (fig. 37) beginning to pass backwards into the occipital region.

In figs. 35 and 36 we have the calcarine fibres (*C.f.*) forming the outer boundary of a strip of grey matter, which, if traced forwards to the free inner edge of the hippocampal gyrus, is found to contain there the vestige of a fissure which appears to arise out of the dentate or hippocampal sulcus (*H.S.*); this is the calcarine fissure (*F.C.*) which is seen fully formed in figs. 29-34, and consequently the strip of grey matter is the cortex forming the floor of the calcarine fissure (comp. figs. 41-45). This piece of cortex is bounded along the whole extent of its inner side by a layer of fibres (fig. 35, *C.f.*) which have the same direction as the fibres on the outer side of

this cortex, *i.e.*, backwards and outwards, therefore these are the calcarine fibres of the inferior lip of the calcarine fissure. In the next section (fig. 36) the two sets of fibres have begun to join, and later (fig. 37) the cortex has disappeared and its place is taken by the calcarine fibres, having a direction backwards and outwards, while in fig. 38 only the lowest part (*C.f.*) of these fibres is visible, the space being occupied by the forceps major.

From this it seems that these calcarine fibres can be traced round beneath the cortex at the bottom of the calcarine fissure, and that their direction is from the median line outwards and backwards, and after passing round the fissure they ascend vertically or obliquely along the inner surface of the posterior ventricular cornu in the cortex, forming the superior lip of the calcarine fissure (see p. 163), extending forwards to come into close relation with the cingulum.

Having now reached a level below the bottom of the calcarine fissure (fig. 37) there is a great confusion of fibres, and those from the posterior part of the internal capsule and the optic radiations of GRATIOLET have begun to merge with the central white matter of the convolution which formed the inferior lip of the calcarine fissure, on the median aspect of the occipital lobe, fig. 38, *C.R.*

In fact here the part of the occipital lobe on the outside of the calcarine fissure and of the lateral ventricle is merged with the part of the occipital lobe which is below that fissure.

The fibres of the cingulum still have the appearance of being cut across, and subsequently the most internal fibres of the hinder part of the internal capsule, which, in previous sections proceeded to the extreme posterior part of the occipital convolutions, now turn sharply round the lateral ventricle into the neighbourhood of the cingulum. This is owing to the fact that we have now reached a level near to the inferior surface of the occipital lobe, which, as we shall see further on, disappears altogether from the sections. At the same time the posterior cornu of the lateral ventricle gradually becomes shorter, receding from behind forwards, till at this level it does not extend farther back than the cingulum, in fact it almost ceases to exist as such.

In the next section the cingulum appears to consist of two parts, an external part associated with the system of fibres bounding the outer or ventricular surface of the cornu Ammonis and forming what is known as the alveus (see p. 188), and an inner set of fibres situated between the apex of the cingulum (as here seen) and the projection formed by the anterior border of the central medullary substance of the temporo-sphenoidal lobe. This latter is the part of the cingulum into which the fibres from the internal capsule (described above) seem to end. This division, though, perhaps, not very marked at this point, becomes more so further down.

In the next sections we get below the level of the occipital convolutions, and from this point downwards we have only to deal with the white matter of the descending temporo-sphenoidal lobe.

Here all the fibres from the internal capsule make a sharp curve inwards, almost at right angles, to end in the temporo-sphenoidal lobe, and at the same time the conical projection of the cut across cingulum and the central medulla of this lobe have come together, the cingulum now merely forming a projection on the anterior part of the medullated substance.

The fibres of the cingulum here assume more of an oblique direction, and come in contact with fibres from the most internal part (*i.e.*, nearest to the ventricle) of the posterior fibres of the internal capsule. From the apex of the projection of the cingulum there is a large number of fibres passing between it and the superficial fibres of the cornu Ammonis (external medullated layer).

The cingulum now becomes less and less until it forms a small bulbar enlargement at the posterior end of the alveus, and the direction of its fibres is now distinctly forwards and inwards.

As we proceed downwards the cingulum fibres become more separated by the descending cornu of the lateral ventricle from the mass of fibres forming the medullary centre of the temporo-sphenoidal lobe. At the same time the cingulum fibres make a rather thick plexus with the superficial fibres of the cornu Ammonis.

We have now reached the horizontal level below the frontal lobes, the last vestige of which has now entirely disappeared.

The cingulum traced down to the level of the optic commissure maintains the same relation as before.

We have now followed the posterior extremity of the cingulum as far as the horizontal level of the optic chiasma. It will now be necessary to revert to the anterior part of the cingulum, mention of which was made on p. 148.

In the section made at the horizontal level of the upper part of the corpus geniculatum externum (fig. 34, *Cing. a.*), the cingulum is seen as cut-across fibres lying in the gyrus fornicatus, in front of, and in immediate contact with, the genu of the corpus callosum. It forms a narrow oblong tract, whose direction is forwards and outwards, parallel to the genu of the corpus callosum.

At its outer part some of its fibres seem to take an outward and forward direction into the frontal medullary centre, but this is not very definite. This appearance prevails till the horizontal level of the anterior commissure is reached, where the genu of the corpus callosum is very faintly represented, and only at its outer part. Below this level it is very difficult to make out the fibres of the cingulum, which seem to end here in a plexus.

Attention must here be called to a narrow bundle of fibres which appears to be a part of the corpus callosum, and which is situated in front of the genu of this body, and is first seen at the level where this part of the corpus callosum begins to disappear. Its fibres are horizontal, and pass to the region of the cingulum forwards and outwards from the septum lucidum, or from the grey matter on the inner side of the lateral ventricle below the level of the genu of the corpus callosum. This bundle,

when seen in sections below this level and that of the lateral ventricle, can be traced outwards and forwards to mingle with the fibres from the extreme anterior end of the corona radiata, and then appears to pass on with them to the lowest frontal region.

Lower down still we reach a point where the fibres of the internal capsule have ceased, and this bundle of fibres still exists, and can be traced outwards to form an angle with the lowest anterior fibres of the corona radiata.

When traced inwards at this level, it is found to end in the continuation of the septum lucidum below the lateral ventricle, for we have now reached a point which is inferior to the floor of the most anterior part of this cavity. When examined at the level where the last vestige of the frontal lobe is seen, it forms a very fine horizontal band of medullated fibres, bounding the anterior margin of the caudate nucleus.

From the consideration of the above description, it would seem that the point, where the last trace of the anterior part of the cingulum can definitely be made out, is at the horizontal level of the middle of the anterior commissure, below which the characteristic appearance of the cut-across cingulum disappears, and its place is taken by a confused plexus, and partly by this bundle of fibres.

It seems, however, probable that this horizontal bundle of fibres in front of the corpus callosum ends externally in the cingulum, and at the place where this latter becomes indistinct, these fibres become more developed. Subsequently they take the place of the cingulum, and as we have seen, course outwards to mingle with the fibres from the corona radiata. They are certainly not part of the corpus callosum, as they do not pass to the opposite hemisphere, and the direction of the fibres is outwards and forwards, while that of the corpus callosum is more directly outwards. It therefore seems more likely that these are the extreme anterior fibres of the cingulum.

These are probably the fibres which can be seen in sagittal sections made nearest to the median line, as a layer of short horizontal fibres in front of the genu of the corpus callosum.

The above conclusion is borne out by sagittal sections of the Monkey, in which the fibres of the cingulum can be traced in the gyrus fornicatus round to the front of the genu of the corpus callosum, from which they are quite distinct. At the most anterior inferior part, the fibres of the cingulum have a direction downwards and backwards, and at right angles to those of the corpus callosum. They appear in short lengths, and are evidently proceeding in a plane which is oblique to that of the section, whereas the fibres of the cingulum in front of the point where the bend of the genu of the corpus callosum commences, have a direction almost vertically downwards, and consequently in horizontal sections these would appear as points, whilst the lowest fibres of the cingulum would be seen cut into short lengths. So here in the Marmoset the fibres of the cingulum in front of the genu of the corpus callosum appear in horizontal sections as points, whereas the fibres taking their place lower

down are cut more obliquely. Whether these fibres are part of the cingulum or not, they seem to connect the septum lucidum with the anterior inferior part of the frontal region.

It has been considered by some writers, notably BROCA,* that the cingulum forms one of the roots of the olfactory nerve, and it has been likened to the frame of a racket, which, forming a loop in the gyrus fornicatus and gyrus hippocampi, unites its two ends with the olfactory nerve, which thus forms the handle of the racket.

In the present sections the first appearance of the roots of the olfactory nerve is not seen till we reach the last vestige of the frontal lobe, which is a very considerable distance from the definite termination of the cingulum, which as we saw, was at the level of the anterior commissure. There seems not sufficient evidence that the olfactory nerve can be traced to the part of the cingulum in front of the callosal genu, in horizontal sections.

On referring to sagittal sections (p. 146), it was shown that the termination of the descending posterior part of the cingulum takes place in the cortex of the inferior surface of the temporo-sphenoidal lobe, and that in the Marmoset the cingulum has not the connection with the olfactory nerve as described by BROCA.

Having considered the cingulum in the sagittal and horizontal directions, I will continue with a description of it in the frontal, and also in the frontal oblique directions.

Frontal Sections.—In making a frontal section (fig. 39, *Cing. h*) at the level of the optic commissure through the brain of the Marmoset, the cingulum is seen as a comma or pear-shaped bundle of fibres with the concavity towards the middle line, and with its general axis directed downwards and outwards, presenting the distinct appearance of fibres cut transversely.

This bundle is situated at the lowest part of the internal angle of the centrum semi-ovale. Above, it is bounded by the rest of the centrum ovale, below and internally by the grey matter of the gyrus fornicatus (*G.F.*), and on its most inferior part the tail of the comma passes outwards and downwards, and then inwards, where it rests on the upper surface of the corpus callosum.

The appearance of the transversely cut fibres is in marked contrast to those of the corpus callosum (*C.C.*), which sweep round its outer margin on their way to the cortex, and to the fibres from the internal capsule (*C.I.*), which pass upwards and inwards across the direction of the callosal fibres to end in the cortex. In this plane no fibres can be definitely seen to pass out from the cingulum into the cortex. Those fibres which do seem to come from the cingulum are really fibres from the corpus callosum or internal capsule, which pass through the cingulum, but are not connected with it.

As we pass from before backwards in these sections, the cingulum presents the same comma shape, but it gradually alters its position. The corpus callosum becomes

* 'Revue d'Anthropologie,' 1878, "Anat. Comp. des Circonvolutions Cérébrales;" "Recherches sur les Centres Olfactifs," *ibid.*, 1879.

broader, and at the same time the gyrus fornicatus increases in the transverse horizontal direction ; this has the effect of pushing the tail of the comma-shaped cingulum further away from the median line, so that the principal axis of its cross section instead of being almost vertical as in fig. 39, becomes almost horizontal (fig. 40, *Cing. h.*). We therefore have the head of the comma forming the inferior median angle of the centrum semi-ovale, then passing almost horizontally outwards between the fibres of the corpus callosum above and the gyrus fornicatus below, and gradually tapering into its tail, which winds round the convexity of the most external part of the gyrus fornicatus and then runs inwards for a short distance along the upper surface of the corpus callosum with which it is in close contact. The most inferior end of the tail of the cingulum here comes into very close relation with a system of fibres which form the superficial fibres of the gyrus fornicatus (fig. 40, *S.f.*). These fibres are seen here as points along the inferior edge of a sulcus, which is the continuation of the dentate or hippocampal sulcus forwards in the gyrus fornicatus. The strip of cortex, which is separated from the rest of the gyrus fornicatus by this sulcus, rests on the upper surface of the corpus callosum, and at its outer part receives the tail of the comma-shaped cingulum, so that only the breadth of this strip of cortex intervenes between this part of the cingulum and the superficial fibres of the gyrus fornicatus.

Whether there is any communication between those two sets of fibres cannot be ascertained in frontal sections. On comparing the shape of the cingulum in figs. 39 and 40, the different appearances of the cingulum as seen in sagittal sections will be understood (see p. 144).

In the next series of frontal sections beginning at the vertical level through the anterior part of the pons Varolii, and extending backwards to the vertical level of the posterior part of the optic thalamus and the posterior end of the corpus callosum, the cingulum is still seen as a comma-shaped body having the same relations as before, but with its chief axis becoming more horizontal, the large end of the comma being directed inwards and the tail outwards and downwards, and with the fibres composing it cut across transversely.

In the last section of this series, viz., that opposite the level of the hinder part of the optic thalamus, the direction of the chief axis of the cingulum is quite horizontal. In all these sections it has not been possible to trace any fibres either entering the cingulum from the gyrus fornicatus, or passing into or out of the cingulum from the centrum ovale.

On considering the relation of the fibres leaving the cingulum to pass into the centrum ovale, it will be remembered that in sagittal sections (p. 145) these fibres pass out from the cingulum in a plane running forwards and upwards. The explanation is, I think, clear, why we do not see them in the frontal direction, as they would necessarily be cut across obliquely.

One of the most important points is that the cingulum, when traced forward to the vertical level of the optic chiasma and backwards to the vertical level of the hinder

part of the corpus callosum, does not vary in size, or, at any rate, does not become smaller as we advance forwards. This fact is very remarkable, as we see from sagittal sections that the cingulum continually gives off fibres upwards into the centrum ovale along its whole horizontal course in the gyrus fornicatus, and yet it does not diminish in size.

The fibres of the cingulum do not seem to be more closely aggregated together in these posterior frontal sections than in the anterior. It seems, therefore, reasonable to suppose that its fibres must be reinforced by continual additions, and it is suggested that these additions are received from the gyrus fornicatus.

As the cingulum can be traced into the temporo-sphenoidal lobe (in sagittal sections) we should expect to find it in this region in frontal sections. In looking at preparations made in the frontal direction through the temporo-sphenoidal lobe, the cingulum is seen as a tract of cut-across fibres lying superior to, but in contact with, the central white matter of this lobe (fig. 40, *Cing.*, *p.*), and it here forms a bulbous enlargement.

Fine fibres can be seen passing across the grey matter between the cingulum and the superficial fibres of the gyrus hippocampi (the external medullated layer of the cornu Ammonis). This condition is maintained as we pass backwards until we reach the region behind the level of the pons and medulla.

Another series of sections were taken through the right half of a Marmoset's brain, which was cut in a fronto-oblique plane, beginning in front through the most anterior part of the pons Varolii, and extending backwards to the middle of that part and the posterior extremity of the lenticular nucleus.

In these sections the cingulum appears as a comma-shaped collection of transversely-cut fibres situated at the extreme inner and inferior angle of the centrum semi-ovale.

A few fine fibres issue from the upper part of the cingulum into the gyrus fornicatus, but they seem to be passing through the former from the centrum ovale on their way to the cortex, and do not actually take their origin from the cingulum.

In these sections the cingulum keeps the same size, and does not vary as we pass either in an anterior or posterior direction.

In a further fronto-oblique section, which was taken at the level through the posterior part of the corpus callosum above and the fourth ventricle below, the cingulum is seen in the gyrus fornicatus, having a similar appearance to that already described in the other fronto-oblique sections.

In the temporo-sphenoidal lobe, the cingulum (the third or posterior part) can be distinguished as a pyramidal-shaped collection of fibres, lying above and in contact with the central white matter of this lobe. The cingulum is here so involved with the fibres of the alveus (the prolongation of the fimbria from the fornix) that it is difficult to separate them (see sagittal sections, p. 147).

In the next sections (fig. 42, 43, right) made through the most posterior part of the corpus callosum and the corpora quadrigemina, the cingulum fibres (fig. 43, right *Cing.*, *p.*) are seen as part of a projection of white matter upwards into the gyrus

hippocampi, which is separated off on the inner side from the projection of the central white matter of the temporo-sphenoidal lobe, by a fissure which here seems to spring from the hippocampal or dentate sulcus (*H.S.*); this is the commencement of that most important fissure, the calcarine (*F.C.*). We have, therefore, the white matter here forming a **U**-shaped collection of fibres round the calcarine fissure. The limb of the **U** containing the cingulum is external, and superior to the calcarine fissure, and is composed of two parts; the inner part nearer the middle line is formed by the calcarine fibres (fig. 43, right, *C.f.*), whilst the outer part, which bounds inferiorly the cornu Ammonis, shows fibres cut across and is the cingulum (fig. 43, right, *Cing., p.*).

It will now be advisable to explain more minutely the relation of the calcarine fibres to those of the cingulum. At first it might appear as if the cingulum extended from the inner lip of the calcarine fissure round to the outer lip and so up the isthmus of the gyrus fornicatus, but on examining sagittal sections (figs. 10 and 11), and horizontal sections (figs. 35, 36) it is seen that the cingulum never becomes inferior or posterior to the calcarine fissure. Further, it will be remembered that the sections (figs. 41-45) which we are now examining, are not frontal but fronto-oblique. Consequently, a section made at this level would pass inferiorly through the occipital lobe—this is shown by the fact that we have now reached the point where the calcarine fissure appears in sagittal sections to pass backwards from the dentate sulcus—and would therefore cut through the cingulum somewhere in the upper part of the gyrus hippocampi, or in the isthmus of the gyrus fornicatus (fig. 10, near *S.f.*). We have here, therefore, the calcarine fissure becoming more marked as we proceed backwards, whilst the dentate sulcus diminishes and finally disappears. Passing therefore round the bottom of the calcarine fissure there is this **U**-shaped set of fibres, viz., the calcarine (fig. 41-45, *C.f.*).

At the bottom of the **U**, and extending upwards along its outer limb, the cingulum is seen (fig. 43, right, *Cing., p.*) as a conical collection of fibres projecting upwards into the gyrus hippocampi and helping to form the outer limb of the **U**-shaped calcarine fibres. It is particularly to be noticed that the cingulum is represented by these conical fibres only, the rest of the **U** being calcarine. This appearance was referred to in horizontal sections, where the separation between the calcarine and cingulum fibres can be better understood (p. 150).

The direction of the fibres composing this outer limb is also different, the calcarine fibres having a course downwards and inwards to reach the bottom of the **U**, whereas those of the cingulum are irregularly cut across.

An important change has now taken place (fig. 42, left) between the relation of the gyrus hippocampi to the gyrus fornicatus; this latter has gradually become prolonged downwards along the median face of the hemisphere, and it finally reaches the gyrus hippocampi and joins it, forming the isthmus of the gyrus fornicatus.

The hippocampal or dentate sulcus now changes its direction, the inner end becoming the superior, so as to be parallel with and external to the gyrus fornicatus. We have,

therefore, the gyrus fornicatus and gyrus hippocampi forming a continuous convolution, having the projection of the cingulum at its lower part, and separated on its outer surface from the fascia dentata by the hippocampal or dentate sulcus (*cf.* fig. 44, left, *H.S.*).

The change in the position of the dentate sulcus will be more easily understood if we look upon the junction of the gyrus hippocampi and gyrus fornicatus as a growing upwards of the former to join the latter.

On fig. 45, right side, the two convolutions are still separated and the calcarine fissure (*C.F.*) is seen to be formed by two lips, an upper and a lower, containing a U-shaped collection of fibres; the upper one is bounded above by the hippocampal or dentate sulcus (*H.S.*), which proceeds from the free median edge of the gyrus hippocampi into the substance of this structure. If now this upper lip were to be prolonged upwards till it joined the gyrus fornicatus (*G.F.*) the hippocampal sulcus would have its inner end carried upwards, and its direction would be changed from being almost horizontal (*H.S.* in fig. 45, right) to one parallel to the isthmus of the gyrus fornicatus, where it would bound this structure on its outer side separating it from the fascia dentata (*H.S.* in fig. 44, left).

As we proceed more posteriorly the cingulum comes into relation with the forceps major (fig. 41, left, *F.M.*), which here extends to the floor of the descending ventricular cornu and bounds the cingulum on its outer side; at the same time the U-shaped tract of the calcarine fibres becomes larger as the calcarine fissure increases in depth. Its fibres have now the following direction: when traced from the tip of the inner limb of the U they are here connected with the cortex and have a direction down and out parallel to the limb of the U, but on reaching the outer horn they have a direction outwards and upwards.

In the next sections (figs. 42-44, left) where the gyri hippocampi and fornicatus have joined, the U-shaped tract increases in size and its outer and upper horn is prolonged up the isthmus of the gyrus fornicatus, carrying the cingulum (*Cing. p.*, fig. 44, left) up with it, while at the same time the fibres of the forceps major diminish in size and finally disappear from this part.

Up to this point (fig. 45, left) there has been no alteration in the fibres of the horizontal cingulum (*Cing. h.*), situated in the gyrus fornicatus on the under surface of the centrum ovale. These fibres have been already described in frontal sections further forward, as having the shape of a comma and presenting transversely cut fibres.

In more posterior sections they begin to have a direction downwards into the gyrus fornicatus, *i.e.*, towards the centre of the circle of which the comma is an arc. By this time the posterior cingulum has advanced up the isthmus of the gyrus fornicatus and in the next section its fibres join the comma-shaped fibres of the horizontal cingulum above, so that eventually we have the whole of the concave part of the "comma" completely filled up by the fibres of the cingulum which have been traced up the gyrus fornicatus. We thus get instead of the "comma," a collection

of fibres shaped like a bulb (see sagittal and horizontal sections), of which the stalk is formed by these fibres from the isthmus of the gyrus fornicatus.

We have therefore traced the posterior part of the cingulum up through the isthmus to the posterior extremity of its horizontal part on the inner and under side of the centrum ovale, where it forms the bulbous enlargement which was also seen in the sagittal and horizontal planes.

The question as to how many of these fibres, which are seen in the gyrus fornicatus below the bulbous enlargement, belong to the cingulum and how many to the calcarine fibres, it is difficult if not impossible to answer. A glance at a sagittal section in which the cingulum is seen through the whole of its posterior part (fig. 11, *Cing. p.*) will show that a fronto-oblique section, sloping as it does downwards and backwards, through the upper end of the cingulum would include only a small portion of its cross-section and the rest of the fibres in the gyrus fornicatus, and the cortex forming the upper lip of the calcarine fissure would be calcarine fibres; it seems probable therefore that only the fibres immediately below the bulb belong to the cingulum, the rest being part of the calcarine fibres which here have the following arrangements.

Starting below in the white matter of the occipital convolution below the calcarine fissure, the fibres spring apparently from its cortex and pass horizontally outwards along the direction of the tract to the part forming the bottom of the calcarine fissure, where they appear in short lengths. The fibres directly external to the bottom of the calcarine fissure are cut obliquely and their precise direction cannot be ascertained, but it appears to be outwards and upwards, across the direction of the tract.

The fibres issuing from the bulb of the cingulum downwards, and which probably belong to the cingulum, have a straight course for a short distance, tapering as they proceed, but whether they end in the cortex of the isthmus of the gyrus fornicatus cannot be definitely ascertained. These fibres, when traced to the periphery of the bulb, end abruptly and probably run forward.

This bulbous enlargement is bounded on the outer side by the corpus callosum, above by the centrum ovale, and on its inner side by the cortex of the gyrus fornicatus.

In the next sections the bulbous enlargement has disappeared, as we are now posterior to it, and in its place we find that the fibres which are seen in the upper part of the superior calcarine lip pass upwards along the inner side of the centrum ovale, and instead of ending abruptly they pass on and turn upwards into it. In further posterior sections there are two layers of these fibres, an inner which is directed towards the highest point of the centrum ovale, and an outer next to the corpus callosum, which winds round the upper end of this structure into the centrum ovale on the outer side of the posterior ventricular cornu. It is considered that, as this appearance is continued with slight modifications in the rest of these sections which reach for some distance into the occipital region, these fibres cannot be part of

the cingulum which, as we saw in sagittal sections, does not extend into the occipital region, but form part of the calcarine system of fibres.

Whether these fibres arise at their lower end from the cortex forming the superior calcarine convolution (or upper lip of the calcarine fissure) is not certain, but they appear to do so.

We thus have a system of fibres which can apparently be traced (the system, not the individual fibres) from the tip of the central white matter in the temporo-sphenoidal lobe round the convolution bounding the bottom of the calcarine fissure, and up the superior limb of this convolution to its continuation on the median surface of the hemisphere. There it winds round the inner side of the lateral ventricle and the corpus callosum, and turns upwards and outwards into the white matter of the hemisphere, the centrum ovale.

Summary.—Having followed the fibres of the cingulum in consecutive sections in the different planes, it will now be advisable to try and combine the different appearances seen.

To facilitate the description of the cingulum it will be, as before, divided into three parts :—

1st. The horizontal, lying above the corpus callosum.

2nd. The anterior, extending in front of the corpus callosum.

3rd. The posterior, extending from behind the splenium of the corpus callosum to the anterior part of the temporo-sphenoidal lobe.

1st. The horizontal. The horizontal part extends from the isthmus of the gyrus fornicatus behind to the anterior part of the corpus callosum in front. On transverse section it has the form of a comma, with its concavity towards the middle line and towards the gyrus fornicatus. On its outer side is the centrum ovale and the corpus callosum, along which its tail extends to the under surface of the gyrus fornicatus. Its fibres rise posteriorly from the cortex of the isthmus of the gyrus fornicatus (sagittal sections). They then pass upwards and forwards from behind the splenium of the corpus callosum, and turn upwards and outwards into the centrum ovale. Along the whole of this horizontal part fibres are being continually given off into the centrum ovale, into which they can be traced through half of its vertical depth. The most anterior of these are nearer to the middle line than the posterior.

The cingulum in this part, therefore, consists of a series of fibres having a direction forwards and upwards, and which run for a short distance only along the cingulum. There is no doubt that the anterior end of each individual fibre passes into the centrum ovale. With regard to their posterior ends the origin is not so clear, as, with the exception of the isthmus, no definite connection can be made out between the under or inner surface of the cingulum and the cortex of the gyrus fornicatus.

At the anterior part the (horizontal sections) cingulum sends fibres outwards, and also some round the genu of the corpus callosum to the centrum ovale.

2nd. The anterior part of the cingulum in front and below the genu of the corpus

callosum appears in sagittal sections to consist of fibres which, arising from the most anterior part of the centrum ovale, pass downwards and backwards and thence into the internal root of the olfactory nerve. The direction of the fibres is here in the opposite direction to what it is in the horizontal part, if the cingulum were extended, so to say, in a straight line; though these fibres are described as part of the cingulum, it must be remembered that in horizontal sections the direct continuity of the fibres could not be traced lower than the level of the anterior commissure. It is therefore doubtful whether this part really belongs to the cingulum system.

3rd. The posterior part of the cingulum extends from behind the splenium of the corpus callosum to the anterior part of the temporo-sphenoidal lobe.

The tract of fibres as it descends in the isthmus of the gyrus fornicatus becomes further removed from the middle line, and gradually gets behind the hippocampus major, where it becomes flattened in the horizontal transverse direction. Lower down its transverse section appears more round, and as it becomes horizontal in the temporo-sphenoidal lobe its section is more triangular, with the apex upwards.

At first its fibres come into close relation with the calcarine fibres, from which they are not easily separated (see p. 162). These calcarine fibres lie behind those of the cingulum as far down as the level of the inferior surface of the occipital lobe.

The cingulum, in passing into the gyrus hippocampi behind the cornu Ammonis, still keeps posterior and internal to the forceps major (horizontal sections, fig. 37), and at the level below the calcarine fissure the most external fibres of the cingulum are traversed by the latter on their way to the cortex below the calcarine fissure (sagittal sections).

The relation of the cingulum at this level (*i.e.*, just below the horizontal level of the calcarine fissure) to the neighbouring grey cortex is not very definite, as no connection can be traced either into the gyrus hippocampi in front of it, or to the cortex below the calcarine fissure behind it (sagittal). In the temporo-sphenoidal lobe the cingulum runs downwards and forwards in the gyrus hippocampi. Its constituent fibres run obliquely downwards; they receive offsets from the superficial fibres of the gyrus hippocampi on their upper surface, and they end in the cortex on the inferior surface of the temporo-sphenoidal lobe. It is to be remarked that, whilst the fibres which can be traced from the part of the cingulum which is at a level superior to the calcarine fissure, end in the cortex of the inferior part of the temporo-sphenoidal lobe, that part which receives offsets from the superficial fibres ends in the cortex at a point further forwards. Further, the superficial fibres from the most anterior part of the cornu Ammonis (see fig. 11) run forwards in the most anterior part of the cingulum, where it forms a leash of fibres, which end in the cortex of the under surface of the tip of the temporo-sphenoidal lobe; it is quite certain that none of these fibres turn upwards to end in the nucleus amygdalæ, and they certainly do not go towards the locus anterior perforatus.

The cingulum here consists of layers of short fibres, having a direction downwards

and forwards, coursing between the cortex of the gyrus hippocampi and that of the temporo-sphenoidal lobe.

The arrangement is somewhat similar to what was seen in the horizontal part of the cingulum, with this difference: that, whereas in the latter the individual fibres ran forwards and upwards, here they run forwards and downwards. It therefore seems probable that in both cases they form a connecting system between the gyrus fornicatus and the gyrus hippocampi on the one hand and the centrum ovale (? cortex on external surface) and the cortex of the temporo-sphenoidal lobe on the other.

Similarly to what was seen in the horizontal part of the cingulum, its transverse diameter does not vary much throughout its extent in this part, but owing to the difficulty of separating it from the calcarine fibres, this point is not certain.

In reference to the functions of the cingulum and the arrangement of its fibres, I have in one case tried to cause degeneration in its fibres.

To produce this, I asked Professor HORSLEY to perform the operation in a Monkey (*Macacus sinicus*) of dividing the cingulum in its horizontal course through the gyrus fornicatus. The operation was done under an anæsthetic, and with strict antiseptic precautions, by means of a blunt hook introduced along the median surface of the left hemisphere after gently drawing it away from the middle line. The place chosen was at the junction of the quadrate lobule with the horizontal part of the gyrus fornicatus, and therefore just below the angle which the calloso-marginal sulcus makes when it changes its direction from downwards and forwards to horizontally forwards. The animal lived for two months after the operation, and on examining the brain it was found that at the median surface the cut extended through the whole width of the gyrus fornicatus, but in sections made external to the median line, although the whole extent of the convolution was not cut through, the fibres of the cingulum were completely severed. After hardening the brain, serial sections were made in the sagittal direction, beginning from the median line and passing outwards to the vertical level of the outer part of the head of the caudate nucleus. After staining the sections with PAL's method, on examining the cingulum in front of, and behind the cut, the following appearances are seen:—The gap left by the operation is filled up near the middle line by a slight amount of cicatricial tissue, but there is no evidence of any inflammation, showing that the wound had healed by first intention. In front of the cut the fibres of the cingulum end abruptly at their posterior ends, and although there is the appearance of injury to the ends of the fibres, no degeneration can be traced along their continuity forwards; there is no change in the staining of the myeline sheath.

Posterior to the cut, the fibres of the cingulum can be traced forwards to where they have been cut across. Degeneration is seen to have taken place at the margin of the cut, and on tracing these fibres backwards they are found to be slightly degenerated for a considerable distance backwards, but whether the change in each fibre extends through the whole length of its course cannot be made out. There is,

however, a marked difference between the fibres at the inferior part (*i.e.*, that next to the corpus callosum) of the cingulum, and those more superior (*i.e.*, nearer to the calloso-marginal sulcus); these latter were not cut across, as they turned upwards before reaching the seat of operation, and consequently they are not degenerated, and their individual fibres can be made out very well, but in the former, under a high power (F, ZEISS), there is a considerable amount of degeneration, which extends some way backwards.

From this one experiment it would appear that the cingulum, when cut across, does not degenerate forwards, but any change takes place in a posterior direction. Further that it is not possible even after cutting the cingulum completely across to produce degeneration in all its fibres. This is in harmony with the arrangement of the fibres as seen in sagittal sections of the Marmoset, and confirms the opinion there expressed that the cingulum does not contain fibres running through its whole length, but is made up of relays of fibres which are continually leaving it.

It should be stated that after the operation no change could be detected in the animal operated on, there was no paralysis and no evidence of any loss of sensation, though it was carefully tested.

On comparing this description of the cingulum with the account given by various authors on human anatomy, it would seem that, although communications have been traced along the annectant gyri from the cingulum to other convolutions, they are described by FOVILLE and HUGUENIN (p. 142) as *fibræ arciformæ* and resemble the *fibræ propriæ* of other parts. In the Marmoset, on the other hand, the fibres of the cingulum have a definite direction; they are quite distinct from the superficial *fibræ propriæ*, and with the exception of the calcarine fibres, they have an arrangement special to themselves; they end deeply in the centrum ovale, and are not part of the superficial connecting fibres of the cortex.

The peculiar arrangement of the cingulum in the gyrus fornicatus is of especial interest, when considered with the fact found out by Professors HORSLEY and SCHÄFER,* that whereas the marginal convolution was excitable, no movement was produced when the gyrus fornicatus was stimulated electrically, and moreover that loss of sensation on the opposite part of the body was produced in Monkeys when parts of this convolution were removed, thus showing that it was associated with the function of sensation. It is here suggested that in the Marmoset the cingulum may form internuncial fibres between the gyrus fornicatus—the sensory part of the cortex—and the part of the centrum ovale in connection with the so-called motor cortex.

Calcarine Fibres.—In describing the cingulum frequent allusion has been made to a system of fibres which I have called calcarine, from the fact that they are found in that part of the cortex which is involuted to form the calcarine fissure.

In all the different planes (especially sagittal and horizontal) great difficulty was

* 'Phil. Trans.' B., vol. 179 (1888).

found (figs. 5, 22, 23, *Cing. p.*, *C.f.*) at the junction of its horizontal and posterior parts to find the limit of the cingulum in the posterior direction. It was seen to be merged into a set of fibres which could be traced into the occipital region along the most superficial part of the white matter in the cortex bounding the calcarine fissure. It was not till sections were made in the fronto-oblique direction that the relation of these fibres became more evident. It was then seen that posterior to the vertical level of the horizontal part of the cingulum there was a U-shaped layer of fibres (figs. 41-45, *C.f.*) in the occipital region, maintaining an analogous position to that of the cingulum further forwards. In more posterior sections the direction of these fibres at the superior part was from the cortex forming the upper lip of the calcarine fissure upwards, forwards, and outwards round the inner side of the tapetum into the centrum ovale; the fibres bounding the lowest part of the calcarine fissure had a direction in horizontal sections (fig. 38) backwards and outwards from the cortex of the inferior lip of the calcarine fissure, while those in the inferior lip of the calcarine passed from the calcarine cortex downwards and outwards (fig. 44, left). In figs. 1, 2, all the occipital fibres are calcarine, with a direction forwards and upwards.

It is therefore probable that these calcarine fibres form a connecting system between the cortex bounding the calcarine fissure and the centrum ovale. Moreover the fibres stain (with WEIGERT'S method) a tint similar to that of the cingulum; it is therefore probable that the two systems are analogous, *i.e.*, association—or collateral—fibres which connect the centrum ovale with the gyrus fornicatus and the cortex bounding the calcarine fissure, respectively, for like the cingulum the calcarine fibres appear as relays, and no one fibre can be traced from the tip of the inferior lip continuously through the whole tract to the centrum ovale. Another remarkable point is the manner in which the calcarine fibres hedge off their cortex from surrounding parts, apparently even from the corpus callosum (see p. 180).

Superficial Fibres of the Gyrus Fornicatus.—In the description of the cingulum frequent reference has been made to the superficial fibres of the gyrus fornicatus. It is not here intended to follow out the whole course of these fibres, but it will be advisable to refer to them as they come into relation with the cingulum.

These fibres are seen having an antero-posterior direction at the most inferior part of the gyrus fornicatus (fig. 4, *S.f.*) in sagittal and also in frontal sections (fig. 40, *S.f.*), and in the latter plane they appear to come into very close relation with the cingulum.

It has been already stated (p. 140) that in the Marmoset the dentate or hippocampal sulcus is prolonged from the gyrus hippocampi along the horizontal part of the gyrus fornicatus, and can be traced as far as the frontal level of fig. 39, and probably in front of this point. In frontal sections (fig. 40) this prolongation of the dentate sulcus is seen passing outwards from the median line into the gyrus fornicatus, and cutting off a very narrow strip of grey matter (indusium griseum) next to the superior surface of the corpus callosum. It is in the outer part of this strip, where it is attached to the rest of the gyrus fornicatus and along the edge of the dentate sulcus,

that these superficial fibres are seen, having a horizontal antero-posterior direction; but though they come into close contact with the tail of the comma-shaped cingulum, they are separated by a strip of cortex, and no fibres can be here seen to pass between them. When traced backwards along the edge of the gyrus fornicatus these fibres pass to the isthmus, always keeping along the edge of the dentate sulcus, which now separates the fascia dentata from the commencing gyrus hippocampi (figs. 5, 29, *S.f.*). The fibres in the isthmus have an antero-posterior direction parallel to the free cut surface of the gyrus fornicatus (fig. 5), and fibres radiate towards them from the bulb-shaped posterior end of the horizontal cingulum, but it is uncertain whether they join. The superficial fibres then descend to the edge of the gyrus hippocampi which forms the posterior inferior lip of the hippocampal sulcus (figs. 10, 35, 38, *S.f.*, *H.S.*), they keep parallel to the cingulum, and just in front of it. They descend to the lower end of the gyrus hippocampi where they end in a plexus. Along this part of their course, offsets are given downwards and forwards to the cingulum, the main part of which they form at its inferior end (figs. 11, 12, *S.f.*). It will be observed that these fibres now form what is known in the cornu Ammonis as the external medullated layer, Kernblatt, or lamina medullaris involuta. When they are traced upwards in sagittal sections (fig. 11, *S.f.*), they end in a fine plexus at the upper end of the gyrus hippocampi, where they come into contact with the protoplasmic processes of the large cells of the pyramidal cell layer of that gyrus.

The superficial fibres of the gyrus fornicatus have been described by SCHWALBE* and other authors as part of the cingulum, but whether this is correct or not, they certainly have a course which is distinct from this structure, while it is only in the gyrus hippocampi that a connection between the two sets of fibres can definitely be made out.

In connection with this matter it is interesting to note the manner in which the cornu Ammonis or hippocampus major is formed. In horizontal sections (fig. 16, *F.D.*, *Cing. p.*) the fascia dentata is slightly seen on the anterior edge of the dentate sulcus and on its posterior edge a faint line shows the superficial fibres, while the cingulum is seen behind and outside the sulcus. If now we imagine the superficial fibres to be pushed, so to say, outwards together with the dentate sulcus into the substance of the gyrus hippocampi, and at the same time the cingulum to extend inwards into the outer surface of this gyrus until the two sets of fibres overlap each other, the cingulum being the posterior, we get the appearance of the cornu Ammonis gradually produced, as seen in figs. 23-34, and more marked still in figs. 35-38 (*H.S.*, *S.f.*, and *Cing. p.*), and thus the sigmoid form is brought about by the gradual extension of the superficial fibres and the cingulum in opposite directions into the gyrus hippocampi.

Having finished the account of the cingulum, the posterior part of the corpus callosum will now be described.

* *Loc. cit.*

Posterior Part of the Corpus Callosum.

Previous Descriptions.—According to QUAIN'S 'Anatomy' (9th edit.), vol. 2, p. 344, "From the posterior end, or splenium, of the corpus callosum they (the fibres) arch round the posterior and inferior cornua of the lateral ventricle, forming the upper and outer wall of those parts of the cavity, into the temporo-sphenoidal and the lower part of the occipital lobes. Lastly, from the under part of the splenium fibres pass with a bold sweep (forceps major) into the posterior and superior parts of the occipital lobes."

The forceps major is further on (p. 346) described as forming a longitudinal eminence (bulb of the posterior cornu) on the inner wall of the posterior cornu of the lateral ventricle, where the fibres of the forceps major curve round from the splenium of the corpus callosum to enter the occipital lobe.

SCHWALBE* states that the hinder part of the body of the corpus callosum and its splenium are destined for the temporal and occipital convolutions. "The fibres from the posterior part of the body run laterally and inferiorly in an arch, convex outwards, and course in the upper lateral wall of the posterior and inferior horns of the lateral ventricle as a thin layer of white matter, being only covered over by the ependyma, and called the tapetum. This structure contains the callosal fibres for the temporal and the inferior part of the occipital convolutions. The swelling formed on the under surface of the callosal body by the rolling under of the fibres—the splenium proper—sends its fibres to the posterior and upper part of the occipital convolutions in such a way that the latter are supplied by the callosal fibres coming from the angle formed by the splenium with the body, while the posterior part of the occipital gets its callosal fibres from the splenium itself. . . . The arrangement on each side of these concavely-shaped tracts from the splenium forms what is known as the forceps major posterior. It will be seen that, as the splenium is attached directly to the corpus callosum, so the forceps major is in immediate contact with the tapetum, and represents the portion of the tapetum which is rolled up towards the middle line."

According to HENLE,† "the fibres from the splenium which bend round into the posterior extremities of the hemispheres are called by REIL '*the forceps*;' the fibres radiating out of the body of the corpus callosum form the *tapetum*." . . . "The outer wall (*loc. cit.*, p. 147) (of the lateral ventricle) which is concentric with the surface of the hemisphere, and forms the upper and lateral boundary of this cavity, is identical with the tapetum; it begins at the posterior edge of the thalamus, with a concave base corresponding to the height of the outer wall, and gradually diminishes from before backwards, till finally it ends as a fine point." . . . "The median wall (*loc. cit.*, p. 148) of the posterior horn is formed by '*the forceps*;' this forms a longitudinal fold or projection into the cavity of the posterior cornu, and is called *bulbus cornu*

* 'Lehrbuch der Neurologie,' p. 494. 1881.

† 'Handbuch der Anatomie des Menschen,' p. 146. 1868.

posterioris, and becomes deeper from before backwards, and, as the floor narrows, we finally have only a semilunar-shaped furrow in the tip of the occipital lobe."

OBERSTEINER* states "that it is probable that the corpus callosum sends fibres to the whole surface of the cerebrum, with the exception of the inferior and anterior parts of the temporo-sphenoidal lobes and the olfactory regions (tractus olfactorius)." . . .

"From the splenium corpus callosi a large white mass of fibres, the forceps posterior, run backwards to the posterior part of the central hemispheres, having their convexity towards the middle line. . . . The thick tracts of white fibres which are given off from the posterior part of the body of the corpus callosum are directed for the most part downwards, and form the lateral wall of the posterior and inferior parts of the lateral ventricles."

Sagittal Sections.—Before proceeding to the description of the posterior part of the corpus callosum, it should here be remarked that there seems some difference of opinion among the authorities as to the definition of the word "splenium." According to QUAIN,† the whole of the posterior end of the corpus callosum is called the splenium; whilst the part which is rolled under, called the "bourrelet" or pad, is termed the under part of the splenium.

On the other hand, SCHWALBE‡ describes the rolling under of the posterior part of the corpus callosum as the splenium. He qualifies this on the next page by stating that the splenium proper is the swelling rolled round towards the front on the inferior surface of the corpus callosum.

HENLE§ again makes a difference between the splenium, which gives off the fibres known as the forceps, and the posterior part of the body of the corpus callosum, which gives rise to the radiating fibres forming the tapetum.

The corpus callosum will be here described as consisting of three parts, the *posterior part of the body*, which gives rise to the tapetum; the *splenium proper*, or the part rolled under the former, from which springs the forceps major posterior; and an *intermediate part*, connecting the splenium proper to the body of the corpus callosum.

Sagittal sections.—The corpus callosum presents at the median line a thickened posterior end; on the under surface of this there is an oval collection of fibres having the smaller end forwards—this oval is the splenium proper, and it is separated off from the rest of the corpus callosum by a septum into which the median fibres of the fornix can be seen to pass (see p. 182). The direction of the callosal fibres is transverse to the plane of the section.

The corpus callosum and its splenium are so fitted together that the whole presents at the median line a uniform contour.

* *Loc. cit.*, p. 345.

† *Loc. cit.*, p. 344.

‡ *Loc. cit.*, p. 493.

§ *Loc. cit.*, p. 146.

In succeeding sections, on examining the posterior part of the corpus callosum, it (fig. 1, *C.C.*) consists of a rounded thickened end, and attached to its lower part is the oval collection of fibres of the splenium proper, which is separated off from the main part of the corpus callosum by a septum, which appears in fig. 1 as a slight interval, and into this septum the fibres of the median part of the fornix still enter (*F.m.*, see p. 182). In the next sections this septum passes upwards into the substance of the corpus callosum, and detaches its most posterior end from its main part, leaving them in connection only at their upper parts.

We have here, therefore, the posterior end of the corpus callosum presenting three different parts, viz., the posterior part of the body (fig. 4, *C.C.*); below this, and separated by a septum, is the splenium proper (*spl.*); and joining the splenium proper to the main part of the corpus callosum are the fibres (*spl.*'), which, attached to the posterior-superior part of the splenium below—a slight fibrous septum intervening—and above to the posterior-superior angle of the main part, form an intermediate portion between the corpus callosum and its splenium. It is to be observed that the median fibres of the fornix pass into the corpus callosum in front of this intermediary part. In all these callosal fibres the direction is transverse to the plane of the section.

In more external sections the axis of this intermediary part of the splenium, which here appeared vertical, becomes more oblique, so as to slant backwards and upwards. The posterior part of the body soon begins to send fibres backwards into the occipital region, which cut through the outer part of the cingulum, and in the next section this intermediate part of the corpus callosum becomes still more inclined backwards, and also sends fibres backwards into the occipital region, lying beneath those from the posterior part of the body.

The prolongations backwards from these two parts of the corpus callosum are so closely connected that it is difficult to separate them, and it is not till we arrive at a more external section that a distinct differentiation can be made out. Here (fig. 5, *C.C.*, *Spl.*') the fibres from the intermediate connecting part of the corpus callosum can be seen arising rather abruptly between the splenium proper (*Spl.*) and the body, and passing backwards and then upwards into the occipital region, where they form a leash of fibres distinct from the prolongation backwards from the posterior part of the corpus callosum, along whose under surface they course; they lie on the bulbous enlargement of the cingulum and the calcarine fibres (fig. 5, *Cing. p.*, *C.f.*), which separates them from the cortex forming the upper lip of the calcarine fissure. The arrangement of these two parts of the callosal fibres is better explained in fronto-oblique sections (*q.v.*).

In the next section of the series (fig. 6) these fibres from the intermediate part of the corpus callosum, are separated off from the main body by the lateral ventricle, whose posterior cornu here begins to be formed. Here, also, these fibres become very closely applied to the bulbous enlargement of the cingulum (see p. 146), so that they

are free on their upper surface towards the lateral ventricle, while inferiorly they are bounded by the cingulum and the calcarine fibres. They can still be traced from between the splenium and the corpus callosum in front, where their fibres are arranged in short cut bundles, to the end of the posterior cornu of the lateral ventricle behind. Here the fibres have a distinctly horizontal antero-posterior direction, and do not present the short lengths seen more anteriorly. When traced posteriorly they end between the fibres from the body of the corpus callosum and the calcarine fibres, and blend finally with the former. In more external sections (figs. 8 and 9), the posterior part of these fibres disappears, while the portion of them in front of the cingulum still exists. As will be seen further on, these fibres in front of the cingulum are the commencing forceps major from the splenium.

We must return to the splenium, which was described as an oval structure below the body of the corpus callosum. As we proceed further outwards the following changes occur (fig. 5), the splenium (*Spl.*) becomes more triangular, and forms a wedge-shaped bundle of cut-across fibres with the apex downwards. It lies between the optic thalamus (*O.T.*) in front, and the commencement of the fascia dentata (*F.D.*) behind. At its upper part it is separated from the main body of the corpus callosum by the median fibres of the fornix.

In the next section (fig. 6) the shape of the splenium has become more wedge-shaped, and its fibres are arranged in distinct bundles.

We have now (fig. 7) in the occipital region the following set of fibres from above downwards. Beginning with the cortex of the outer superior surface of the occipital lobe we have, first, the sub-cortical plexus of fibres of the centrum ovale; next, below them, the fibres coming from the posterior part of the internal capsule (*C.R.*), with probably some of the optic radiations of GRATIOLET, which have a direction upwards and backwards; below them the fibres from the hinder part of the corpus callosum (*C.C.*), which are quite distinct, and are bounded in front by the caudate nucleus, while behind they end in a long narrow tail of fibres, which, diminishing as they extend backwards, can be traced to the posterior part of the occipital lobe (figs. 9, 10, *Tap.*). The arrangement of the fibres is at first so irregular that no definite direction can be made out, but in the tail it is downwards and backwards, thus making a sharp angle with those from the internal capsule.

The posterior part of the corpus callosum has here a semi-pyriform shape, the large end being forwards and the smaller end of the pear being posterior, where it forms the long tail of fibres. It is bounded above by the corona radiata; in front by the caudate nucleus, and inferiorly by the posterior cornu of the lateral ventricle, which here separates it from its splenium and from the calcarine fibres (fig. 10, *C.f.*). This prolongation of the corpus callosum backwards into the occipital lobe is what is known as the tapetum, and its relations will be better understood by referring to the description of the corpus callosum in the horizontal direction. At present it will suffice to note that there is no connection between these fibres of the corpus callosum

and those of the internal capsule, as has been stated by Professor HAMILTON ('Roy. Soc. Proc.,' February, 1884); in fact, the two sets of fibres are at an acute angle to each other.

We must now consider the relation of the splenium to the posterior part of the corpus callosum. In fig. 5 (*Spl.*) the splenium is of a triangular shape, and is, so to speak, wedged in between the optic thalamus in front and the fascia dentata behind. At its anterior and upper angle are the fibres of the fornix, *i.e.*, the posterior descending crus (*F.l.*), which forms the tænia hippocampi. Here, therefore, the splenium is in close proximity to its main body. In the next section (fig. 6), however, the posterior part of the corpus callosum is seen to be separated from its splenium by a distinct space. This space is the commencement of the posterior horn of the lateral ventricle, and is very well seen in fig. 7.

The posterior part of the body of the corpus callosum is therefore above the lateral ventricle, whilst the splenium is below it, and, as will be more apparent in horizontal sections (p. 175), the splenium supplies parts on the inner wall of the ventricle.

On examining the triangular collection of fibres of the splenium their arrangement is not uniform. At the upper or thicker end of the wedge the fibres are transversely cut across and arranged in large bundles, loosely packed together, whereas, at the apex of the wedge, the fibres are much less stained and are packed closer together. Moreover, the latter receives the fibres of the fornix which eventually form the tænia hippocampi (see p. 183). This arrangement into two sets of fibres is very important, as the subsequent course will show.

As we proceed further outwards the fibres of the main body of the corpus callosum do not alter much, except that the tapetum can be traced for a further distance into the occipital region.

The deeply stained fibres of the upper part of the wedge, which are evidently the fibres of the splenium, or, as they must now be called, the forceps major posterior, *i.e.*, the continuation of the splenium backwards and outwards, pass gradually backwards over the superior surface of the hippocampus major and become much thicker, so that in fig. 11 there is the following arrangement at the upper end of the hippocampus major:—In front we have the posterior pillar of the fornix (*F.p.*) on its way to form the tænia hippocampi, and here stained brown colour (WEIGERT); above, the deeply stained fibres of the forceps major (*F.M.*) arranged in large bundles, having an oblique direction downwards and backwards over the upper surface of the hippocampus major, where they are separated from the tapetum (*C.C. tap.*) by part of the choroid plexus, here stained yellowish-brown by WEIGERT's method.

The forceps major of the corpus callosum maintains the same position at the upper end of this part of the hippocampus major until we reach fig. 12, when its fibres, which have hitherto been transversely or obliquely cut across, alter their direction. The whole mass is continued in a thick bundle in a direction downwards and backwards behind the upper end of the hippocampus major. These fibres, which are

deeply stained, cut right across the most external fibres of the cingulum (see p. 146) as they lie between the hippocampus major and the calcarine fibres. When traced further some of these fibres of the forceps major seem to pass downwards behind the hippocampus major along with the descending fibres of the cingulum, but the majority of them course downwards and then turn sharply backwards into the white substance of the occipital lobe which is below the calcarine fissure, tapering as they proceed backwards. The course of these fibres is very decided, as they cut through the outer part of the descending cingulum, and they are best seen in fig. 12 (*F.M.*) where they form a very broad mass. Their ultimate ending cannot be definitely ascertained, but their direction is towards the cortex of the inferior and median parts of the occipital lobe below the calcarine fissure, a part which does not, as far as I have been able to ascertain, receive any fibres from the tapetum or from the main body of the corpus callosum; they certainly do not go towards the calcarine cortex.

At this level (fig. 12) the tapetum can be traced backward to the most posterior part of the occipital lobe, where its fibres have a direction downwards and backwards.

In the next section the fibres of the forceps major have almost entirely disappeared, while, at the same time, the tapetum becomes enlarged. We have now reached a point which is external to the grey matter at the bottom of the calcarine fissure, and where the tapetum fills up the place occupied by this grey matter and by the forceps major. There is, therefore, the following arrangement. The corpus callosum at this level is represented by a considerable mass of fibres of an irregular quadrilateral shape, which is bounded above and below by the horizontal fibres of the corona radiata (posterior part). In front it is in contact with the posterior part of the caudate nucleus, as it is turning downwards and forwards; behind it is a space, probably the posterior cornu of the lateral ventricle, corresponding to the position of the grey matter at the bottom of the calcarine fissure; in front and below, the anterior margin of the corpus callosum forms the posterior wall of the lateral ventricle, which here separates it from the upper end of the hippocampus major. A prolongation of the corpus callosum is sent downwards and forwards behind the hippocampus major, but separated from it by the lateral ventricle, the direction of the fibres being downwards. The lateral ventricle is therefore an important landmark in this region, in distinguishing the corpus callosum from its forceps major. The position of the forceps major in relation to the lateral ventricle is always on its internal and inferior wall, while the tapetum is on the external and superior, according as the section is horizontal or sagittal. At the present level we can tell that the part of the corpus callosum now visible belongs to the main body from the fact that it is superior to the lateral ventricle. On the posterior and superior edge of the gyrus hippocampi there is a band of fibres whose direction is parallel to the tapetum, from which it is separated by the ventricle; probably these are fibres of the forceps major.

In the next section the corpus callosum has contracted to very small dimensions; the direction of its fibres is downwards and slightly forwards. It is seen as a horn-

shaped collection of fibres, surrounded on its upper and posterior sides by the horizontal fibres of the corona radiata or optic radiations. In front, the larger end of the horn abuts on the caudate nucleus, and below it, lies the lateral ventricle and the superior end of the hippocampal gyrus.

In the next section the caudate nucleus is prolonged downwards and forwards (forming the anterior wall of the descending cornu of the lateral ventricle) to join the small remaining part of the lenticular nucleus. At the upper end of the lateral ventricle, as seen in these sections, we have a small piece of the corpus callosum which has the same relation as before, but its fibres are directed more forwards. In the last section of this series extending as far out as the vertical level of the fissure of SYLVIVS, the basal ganglia are represented by a very small piece of grey matter, forming the anterior wall of the lateral ventricle.

The corpus callosum in its position at the upper end of the lateral ventricle is in contact with the basal ganglia in front (? caudate nucleus) and sends a prolongation backwards and downwards behind the hippocampal grey matter, with which, however, no connection can be made out. These fibres, which are really the remains of the tapetum, are still seen on the superior wall of the descending cornu of the lateral ventricle, and they form a crescent-shaped collection of fibres arching over the superior and posterior ends of the hippocampal grey matter. They have a direction forwards and downwards, but their ultimate ending cannot be ascertained in sagittal sections.

Horizontal Sections.—The relation of the posterior part of the corpus callosum will now be described in horizontal sections, and here, as in the sagittal, we shall consider it under the heads of (1) the posterior part of the body of the corpus callosum, with its prolongation backwards, the tapetum; (2) the splenium, with its prolongation backwards known as the forceps major posterior; (3) an intermediate part connecting the splenium with the posterior part of the body of the corpus callosum.

As was seen in the sagittal sections, the great distinctive difference between the two parts of the corpus callosum is, that with the exception of the region near the middle line, they are separated by the lateral ventricle. The main body, with its tapetum, being external and superior to this cavity, whilst the splenium with its forceps major is inferior and internal.

The first definite appearance of the corpus callosum from above is seen (fig. 13, *C.C.*) outside the cingulum, and also in the occipital region. It here forms a small club-shaped collection of fibres, which is bounded on the outer side by the corona radiata, and on the inner side by the calcarine fibres (*C.f.*). It is prolonged backwards in the form of a tail, forming a concavity towards the middle line, and the direction of the fibres is backwards and slightly inwards.

In the next sections (fig. 14), this arrangement of the corpus callosum is more marked, and the tail of the fibres above described is seen to be prolonged backward along the concave wall of a space (*L.v.p.*), which is evidently the commencement of the posterior cornu of the lateral ventricle. The direction of the fibres is now back-

wards and outwards. When traced forward, this part of the corpus callosum (*C.C. tap.*) is found to be in connection with a tract of fibres which extends forwards along the whole length of the brain as far as the frontal region, and which is bounded on its inner and on its outer side by the cingulum (*Cing. h.*), and the fibres of the corona radiata (*C.R.*), respectively. This tract is the main part of the corpus callosum (*C.C.*), whilst the club-shaped collection of fibres and its prolongation into the occipital region is the highest part of the tapetum (*Tap.*).

In fig. 15 the corpus callosum is well seen in its whole length, extending from the frontal region into the posterior part of the occipital. We here have the first appearance of the caudate nucleus and the lateral ventricle, which is beginning to separate off the middle part of the corpus callosum from the centrum ovale.

It is not until we arrive at the level where the lateral ventricle is well exposed (fig. 16), that we perceive the first indication of that part of the corpus callosum (*Spl.*) which connects the splenium to the main part. In this section the posterior part of the body of the corpus callosum is well represented by a thick mass of fibres (*C.C.*), which have near the middle line a transverse horizontal direction, but which on passing outwards turn backwards, and are continued into the club-shaped bundle of fibres which can be traced sweeping round nearly to the tip of the white matter of the occipital region. These are the fibres which form the tapetum (fig. 16, *Tap.*). They are, as before, separated by a very narrow space, the posterior cornu of the lateral ventricle (*L.v.p.*), from the calcarine fibres and the cingulum (*C.f.*, *Cing. p.*).

The posterior cornu (*L.v.p.*) is seen at its anterior part to separate off a tract of fibres from the main part of the corpus callosum. This tract (figs. 16–22, *Spl.*) appears on the inner side of the space as a collection of horizontal fibres, but towards the middle line it joins the rest of the corpus callosum. In an external and posterior direction its free border is bevelled off like a chisel, and its fibres are there cut horizontally across. This is the first appearance of the connecting fibres of the splenium in horizontal sections, and it is here bounded in front by the ventricle, behind by the fibres of the cingulum and their prolongation outwards.

On first examining these sections this tract of fibres (*Spl.*) appeared at first to be the splenium proper, but on a more careful comparison of these sections with those in the sagittal direction I think there is no doubt that this tract is that part of the corpus callosum which is intermediate between the posterior part of the body of the corpus callosum and its splenium.

The connections and relations of this tract are important; at first (fig. 16) its fibres can hardly be separated from the body of the corpus callosum, but in lower sections (fig. 22) the lateral ventricle has separated them at their outer part, and the direction of its fibres is different in the several levels.

Thus, above (fig. 16), nearly all the fibres are cut across, but, as we descend, the number of these diminish, and they are limited to the extreme posterior border of the tract, so that in fig. 20 the fibres have an oblique direction, which becomes more

horizontal as we reach fig. 22; also in the upper section (fig. 16) no continuity can be traced between the fibres of this tract and the middle line of the corpus callosum, but, as we descend (fig. 22), the course of the most posterior fibres of the corpus callosum is horizontally outwards from the median line into this tract, and here, as has been already shown, the direction of the fibres is horizontal.

The appearance of the fibres being cut across in the upper sections, would show that they are either ascending or descending, and in the lower sections that they are oblique or horizontal. However, as we pass from upper to lower sections, the tract advances forwards, away from the occipital region; this would give the fibres a direction from above, downwards and forwards—the direction which this tract assumes in sagittal sections (fig. 5, *Spl.*'). Another point is that this tract is in close contact with the cingulum (fig. 16, *Spl.*', *Cing. p.*), whereas, in sagittal sections (fig. 5, *Spl.*), the splenium proper is separated from the cingulum by the isthmus of the gyrus fornicatus.

In the next section (fig. 23, *Spl.*') the intermediate part of the corpus callosum ends abruptly at its outer end, while towards the middle line it blends with the posterior part of the body of the corpus callosum, which, as will presently be described, here becomes separated from its prolongation backwards—the tapetum. More inferiorly we get below the level of these two parts of the corpus callosum, and have only the splenium proper to deal with (fig. 26).

In fig. 23 we have reached the level where the tapetum (*Tap.*) has become separated off from the posterior part of the corpus callosum, which here ends abruptly not far from the middle line; it now appears as a club-shaped collection of fibres, having the tail of the caudate nucleus (*c.n.*) in front, the mass of fibres of the centrum ovale on its outer side, and posteriorly it ends in a tail, which, tapering as it proceeds backwards, can be traced to the posterior part of the occipital lobe. This prolongation backwards is bounded the whole way by the fibres of the centrum ovale, which are almost at a right angle to the tapetal fibres, whose direction is downwards and outwards. There is certainly no communication between them. On the inner side of the tapetum, which is prolonged backwards behind the limit of the lateral ventricle, we have the calcarine fibres (*C.f.*).

The club-shaped part of the tapetum is bounded on its inner side by the lateral ventricle, which here contains the choroid plexus, separating it from the prolongation backwards of the splenium, viz., the forceps major.

The forceps major makes its appearance (fig. 23, *F.M.*) as a band of fibres just outside the intermediate part of the corpus callosum (*Spl.*'), but not in connection with it, and passes round in front of the commencing cornu Ammonis or hippocampus major (*C.A.*), which here begins to form a projection forwards into the lateral ventricle. The fibres of the forceps major have a horizontal direction and end abruptly at their outer part, and posteriorly, where they are in contact with the cingulum, they are cut horizontally across.

In the next sections (fig. 26) we have got below the level of the main part of the corpus callosum, and only the splenium is seen, extending from the middle line into its forceps major round to the outer side of the hippocampus major; but in the whole extent of this course no definite connection can be found between the fibres of the forceps major and the cortex of the cornu Ammonis.

In the above account the corpus callosum lies in close relation with the fornix, which appears in front of it. The two structures are separated at first by an interval, but they afterwards come into contact (fig. 24); the difference in staining, as was observed in other sections, is well marked, especially in fig. 28, where the darker stained fibres next to the cornu Ammonis are the forceps major, and the light-coloured fibres next to the tænia hippocampi the fornix.

The horizontal fibres of the splenium and the forceps major gradually diminish as we descend, until we reach (fig. 29, *Spl.*) the apex of the wedge-shaped splenium (as seen in sagittal sections).

In the next sections this has disappeared, leaving only that part of the forceps major which is external and posterior to the hippocampus major, the fibres of which are cut across, and are arranged in a triangular-shaped bundle (figs. 29-34, *F.M.*). Where the last traces of the forceps major in front of the cornu Ammonis are seen (fig. 29, *Spl.*), there are some faintly stained fibres, which, as we saw above, are part of the fornix. This is particularly seen in the next section (fig. 30), where the light colour shows that they belong to the fornix (see p. 186).

In further sections we have then, representing the forceps major, the collection of cut-across fibres situated on the inner wall of the lateral ventricle, behind the cornu Ammonis. They are very deeply stained, and, at first sight, seem to be the continuation of the fornix round the ventricular surface of the hippocampus major. But in further sections, these fibres from the fornix, when traced to the posterior part of the cornu Ammonis, are quite distinct from the forceps major.

As has been seen in other planes, the two systems, viz., the splenium with its forceps major and the fornix with its alveus, lie so closely together that it is difficult to say where one begins and the other leaves off. This has been particularly seen in sagittal and frontal sections. In these horizontal sections, the prolongation of the forceps major round the outer side of the cornu Ammonis, and the prolongation of the alveus from the fimbria of the fornix lie one above the other. We have here reached a point where the two systems come in contact, and those fibres which, after winding round the cornu Ammonis, do not run into the triangular collection of fibres of the forceps major behind the cornu, but end in a separate collection in front of this triangle, are the first indication of the alveus (see p. 187).

As was stated above, the forceps major (fig. 35, *F.M.*) lies on the inner wall of the lateral ventricle behind the cornu Ammonis, forming a triangle the apex of which is directed backwards. In front of it is the alveus (*Alv.*), and behind it the calcarine fibres (*C.f.*).

In the next sections (fig. 36), these fibres of the forceps major, which have hitherto been cut across, *i.e.*, descending, become oblique and are prolonged backwards. We have here reached the bottom of the calcarine fissure (*F.C.*) where the calcarine fibres can be seen passing along its floor. Lower down (figs. 37, 38) we have got almost below these fibres, and can now see those of the forceps major (*F.M.*) spreading out like a brush, and having a direction backwards and inwards. A few of the most inferior calcarine fibres can still be seen on the outer side of the forceps major, having a direction at right angles to its fibres, which they separate from the calcarine cortex. Further on, this appearance is better marked (fig. 38, *C.f.*). The calcarine fibres at the bottom of the fissure soon disappear altogether, and the forceps major has the following arrangement. Just behind the cornu Ammonis the fibres appear as points, *i.e.*, cut across, and from this place they radiate backwards, spreading outwards and inwards, and lose themselves in that part of the white matter of the occipital lobe which is derived from the posterior part of the corona radiata and the optic radiations of GRATIOLET.

Their ultimate ending in the cortex cannot be traced in these sections, but they certainly do not join the corona radiata, with whose fibres they make sharp angles.

Further on, we get below the level of the forceps major, which disappears gradually, and the space is filled up with the white matter of the corona radiata, whose fibres now turn sharply round to reach the cortex of the gyrus hippocampi, for now a section has been reached which is below the level of the posterior cornu of the lateral ventricle.

In sagittal sections it appeared as though the forceps major sent some fibres downwards into the temporo-sphenoidal lobe, but this point cannot be made out in these horizontal sections.

Having now described the forceps major in horizontal sections, the further course of the tapetum (the prolongation backwards of the main part of the corpus callosum) must now be followed out.

As already mentioned, it forms a club-shaped bundle of fibres on the outer wall of the posterior cornu of the lateral ventricle. This shape gradually becomes more triangular; diminishing in size, it at length (figs. 35-38, *Tap.*) forms a narrow band lying immediately behind the tail of the caudate nucleus (*c.n.*), and extending to the hindermost part of the posterior cornu. The direction of its fibres has also altered, and they are now cut across (*i.e.*, descending), standing out as points in marked contrast to the fibres of the corona radiata, which are horizontal. This arrangement is seen as far as the end of the posterior cornu, where the fibres of the tapetum again become more horizontal.

In further sections the tapetum can be traced to the level where the posterior cornu leaves off and the descending cornu of the lateral ventricle begins. On the outer wall of this cavity the tapetum is again seen immediately behind the caudate nucleus as a very thin band, its fibres having a direction at first backwards and inwards and then downwards. Its further appearance is in the form of small dots and in the same

position, as far as the section corresponding to the horizontal level of the optic commissure, after which it can no longer be made out. It will be seen by the very small size of the tapetum that its distribution in the descending cornu must be very slight.

Frontal Sections.—The first appearance of the splenium of the corpus callosum is seen in frontal sections at the vertical level through the middle of the pons and the posterior part of the optic thalamus. It there appears as a narrow band of fibres having a transverse direction and separated by a horizontal septum from the under surface of the main part or body of the corpus callosum; at the outer part of this septum, the longitudinal fibres of the fornix are seen.

Passing posteriorly to the next section, which is made at the vertical level where the optic thalami are completely separated from the hemispheres, the splenium is much larger, and it soon becomes the same thickness as the main part of the corpus callosum.

At the outer and upper part of the splenium is the fornix, separating it from its main body. The fibres of the splenium end abruptly at the outer margin, and their direction is obliquely transverse, they are also rather deeply stained. On the other hand the fibres of the fornix are quite distinct from those of the splenium, being more closely aggregated and only faintly stained.

As mentioned above, there is a distinct septum running transversely, separating the two parts of the corpus callosum, and along it the fornix extends only for a short distance, so that at the median line the splenium is in such close contact with the under surface of the body of the corpus callosum that the two cannot be differentiated.

In the fronto-oblique sections the splenium is not definitely seen until we reach that made through the corpora quadrigemina (fig. 43, right half, *Spl.*). Here the corpus callosum is much enlarged in its vertical direction, and at its outer margin is the fornix (*F. p.*), very faintly stained. Winding round the outer surface of the cornu Ammonis, which is here very much enlarged, there is a narrow band of fibres more darkly stained than the fornix, with which it comes in close contact in the lateral ventricle. These darker stained fibres can be traced down to the under surface of the gyrus hippocampi, and they are probably the commencement of the forceps posterior of the splenium. It is here very difficult to demonstrate, for certain, where the descending posterior pillar of the fornix (*tænia hippocampi*, *alveus*) leaves off, and where the forceps major of the splenium begins, for both of them wind round the outer surface of the cornu Ammonis along the inner wall of the lateral ventricle, to end in the white substance of the temporo-sphenoidal lobe.

It is seen, however, that whereas the forceps major can be traced inwards in this plane into the most inferior part of the corpus callosum, *i.e.*, the splenium, the posterior pillar of the fornix appears to spring from the septum between the two parts of the corpus callosum. Moreover the former is more deeply stained than the fornix, and it does not present the sharp angle which the latter makes at this level.

In the sagittal and horizontal sections the same difficulty was experienced in differentiating the two systems, but in the fronto-oblique sections the arrangement can be more clearly seen. As we pass backwards the forceps major gradually increases in size, while the posterior pillar of the fornix diminishes and finally disappears, showing that the fornix lies in part of the forceps major. At the succeeding fronto-oblique levels (fig. 45, right), the splenium (*Spl.*) appears as a projection outwards on the under surface of the corpus callosum, its fibres being cut across obliquely. At its outer end it is connected with the forceps major (*F.M.*), which extends as a thick band along the outer side of the fascia dentata (*F.D.*), forming the inner wall of the lateral ventricle. This is better seen (fig. 41, left) where the forceps major (*F.M.*) passes outwards, downwards, and backwards to the level of the floor of the lateral ventricle, where it forms a thick collection of fibres between the cingulum (*Cing. p.*) on the inside, and the lateral ventricle (*L.v.p.*) on the outside. The forceps major is separated by a slight space from the fascia dentata and cornu Ammonis, and no fibres can be traced from it into their cortex. At the level of the floor of the lateral ventricle the fibres end abruptly.

In the next sections (fig. 42, 43, left) the outer wall of the lateral ventricle, which in the previous sections was formed in part by the tail of the caudate nucleus (fig. 41, left, *c.n.*), is now made up entirely by the tapetum of the corpus callosum. The tapetum is seen (fig. 41, left, *Tap.*) in all sections anterior to this (as far forwards as the anterior part of the descending cornu), as a narrow band of fibres extending downwards from the lower margin of the caudate nucleus to the level of the floor of the lateral ventricle (descending cornu). On passing backwards this part of the tapetum increases in length at the expense of the caudate nucleus, until at the posterior limit of this nucleus, the tapetum (fig. 44, left, *Tap.*) extends along the whole outer wall of the lateral ventricle, springing out of the main body of the corpus callosum above, and tapering gradually downwards to the level of the floor of the lateral ventricle below, where it comes into contact with the forceps major.

From the outer surface of the posterior part of the corpus callosum fibres are sent to pass through the whole matter of the centrum ovale. The plane of the fibres is downwards and backwards, and at right angles to those of the centrum ovale, which here have a sagittal direction. At this point, therefore (fig. 44, left), the posterior cornu is lined entirely by the prolongations from the corpus callosum, having the forceps major on its inner, and the tapetum on its outer wall. Both these parts increase very much in size, and the forceps major at its lowest part forms a large collection of fibres, ending abruptly below the calcarine fissure on the inner side of the floor of the lateral ventricle. This corresponds to the point in horizontal sections where the forceps major radiates backwards in a horizontal plane (see p. 175).

In the next section (fig. 45, left) the forceps major gradually disappears when traced down the inner wall of the lateral ventricle.

It should, however, be remarked that there is still a collection of fibres in the

central white matter of the convolution forming the lower lip of the calcarine fissure in the place occupied by the termination of the forceps major, and it is, moreover, situated near the inferior end of the tapetum (fig. 44, left, *F.M.*). These fibres are therefore the last part of the forceps major; they have a direction downwards and inwards and are in contact above with the calcarine fibres (*C.f.*), which separates them from the calcarine cortex.

Here (fig. 45, left), although the fibres of the forceps major diminish in extent and thickness, there is still a collection of fibres at the point where the forceps major leaves the corpus callosum (fig. 44, left, *Spl.*) which does not become smaller or less deeply stained. This collection of fibres is oblong in shape and is situated at the upper end of the lateral ventricle; it is attached above to the main part of the corpus callosum, and its long axis slants downwards and outwards to its lower end which is bevelled off; on its inner side it rests on the grey matter of the isthmus of the gyrus fornicatus—a faint trace of the fascia dentata being also visible—and on the outer side it is separated by the lateral ventricle from the tapetum. The direction of the fibres which was previously down and out, now alters; they become more and more oblique, till they appear as bundles of points, showing that they are cut across and are now taking an antero-posterior direction. Before this condition is reached the upper part of the forceps major has entirely disappeared. These fibres, when traced backwards, do not vary their position, but keep to the inner side of the upper end of the lateral ventricle—the angle which they make with the tapetum forming the roof of this cavity. This tract alters in shape, becoming more triangular, and has the same relations, except that it is now (*i.e.*, posterior to fig. 45) bounded by the cingulum on its inner and under surface. Its fibres can be traced to the end of the posterior cornu of the lateral ventricle, and after that they blend with the tapetum. As to what is the distribution of this part of the corpus callosum it is difficult to be certain; it is very doubtful if it gives off fibres to the subjacent cortex, but in this plane the connection cannot be definitely made out.

I think there is no doubt that these are the fibres which come from the intermediate part of the corpus callosum, which is situated between the posterior part of the body and the splenium, and which was seen in sagittal (fig. 5, *Spl.*) and in horizontal sections (fig. 22, *Spl.*) forming along with the tapetum the superior and inner angle of the posterior cornu of the lateral ventricle. In horizontal sections the shape of this tract with the bevelled edge is very similar to the appearance in the fronto-oblique sections.

The tapetum can be traced (in sections posterior to fig. 45) to below the level of the floor of the lateral ventricle and that of the calcarine fissure, where its fibres end in the mass of white matter of the hemisphere. Although the individual fibres cannot be traced into the cortex, their direction makes it probable that the tapetum sends fibres to the outer part of the occipital region, whilst the forceps major supplies the cortex on the median and inferior surface of the occipital lobe below the level of the calcarine fissure.

In following the corpus callosum further backwards we arrive at the end of the posterior cornu of the lateral ventricle, which is diminished to a very small size. It is bounded on the outer side by the tapetum of the corpus callosum, which extends downwards to the under part of the occipital lobe, and on the inner side by the fibres from the intermediate part of the corpus callosum, which presents a small collection of cut-across fibres.

In the next section, which is behind the posterior limit of the lateral ventricle, these two parts of the corpus callosum come into contact, and, in the last section, it is almost impossible to separate them.

Summary.—From the foregoing description of the hinder part of the corpus callosum and its splenium in the various planes, we see the following arrangement:—At the middle line, and for a short distance on either side, these two parts of the corpus callosum are so closely united that it is almost impossible to separate them, although under the microscope a narrow septum can be traced transversely between them. Outside this level (fig. 6), the two begin to be separated by the lateral ventricle. The main part or body of the corpus callosum ends posteriorly on either side in the tapetum, which runs backwards and outwards along the roof and outer side of the posterior cornu of the lateral ventricle. It also extends along the outer wall of the descending cornu of this cavity as far forwards as its anterior part. The anterior margin of the tapetum is formed by the tail of the caudate nucleus, lying behind which it is always seen in horizontal and sagittal sections. The tapetum is therefore distributed to the parts of the hemisphere bounding the posterior and inferior cornua of the lateral ventricle on their outer side, though, to judge from the size of the tapetum in the anterior part of the descending cornu, its connection there must be very slight.

The splenium, which is at first oval on sagittal section at the middle line, becomes triangular as it extends outwards, and more separated from the main part of the body, and connecting these two is the intermediate part of the corpus callosum, which is continued backwards between them into the occipital region. The splenium is now prolonged, as the forceps major posterior, obliquely downwards and backwards round the anterior and external surfaces of the cornu Ammonis, or hippocampus major, to the posterior inferior aspect of that structure (*F.M.*, figs. 11, 23). In this course it forms the inner wall of the posterior cornu of the lateral ventricle, but as far as can be made out it does not seem to send any fibres into the hippocampus major. The forceps major has now been traced down to the floor of the lateral ventricle and below the level of the calcarine fissure, where it (*F.M.*, figs. 12, 38, 41) turns sharply backwards at an obtuse angle, and spreading out it passes into the mass of fibres coming from the corona radiata. Its shape thus resembles the letter **Z**, if its acute angles be made obtuse.

Though its individual fibres cannot be traced into grey matter, its direction is towards the cortex on the inferior and median part of the occipital lobe below the

level of the calcarine fissure, and it apparently does not supply the calcarine cortex. The terminal fibres (*F.M.*, fig. 38), which course in the direction of the hinder end of the posterior horn of the lateral ventricle, come into contact there with the tapetal fibres.

The intermediate fibres (*Spl.*', fig. 4), between the tapetum and the splenium proper, run backwards, being attached at their upper and inner end to the tapetum, but soon become free of the splenium and forceps major (*Spl.*', figs. 5, 22). After passing the vertical level of the forceps major, the fibres can be traced along the roof of the posterior cornu of the lateral ventricle, forming with the tapetum the apex of the upper part of this cavity (fig. 45, left); here they may give off fibres to the cortex of the gyrus fornicatus, but not to that forming the upper lip of the calcarine fissure, and they can be followed posterior to the lateral ventricle, where they blend with the tapetum.

From the above description it appears that the arrangement of the different parts most resembles the account given by SCHWALBE (p. 165), and especially with reference to the opinion that the upper and posterior parts of the occipital convolutions are supplied by the callosal fibres coming from the angle formed by the splenium with the body, and which I have here termed the intermediate fibres. The relation of this part to the tapetum, and the manner in which the two parts together form the roof of the lateral ventricle has not, I believe, been fully described. I have been unable to trace any fibres from any part of the corpus callosum to the cortex bounding the calcarine fissure.*

I would again emphasize the relation of the callosal fibres to the corona radiata; in no case has any junction been found between the terminal fibres of these two great systems, a connection which has been so strongly insisted on by Professor HAMILTON, and which I have already contested in a previous paper (see 'Brain,' Parts XXXI., XXXIII.) with regard to the other parts of the corpus callosum.

In the last part of this paper will be described the fornix, and particularly the body and the posterior crura.

Posterior Part of the Fornix.

Previous Descriptions.—It is stated in QUAIN'S 'Anatomy'† that each anterior pillar of the fornix is connected near the foramen of MONRO with the peduncle of the pineal gland and with the tænia semicircularis, and it also receives fibres from the septum lucidum.

* [The calcarine cortex corresponds to the cuneus in Man and the higher Apes, which is considered by some to be the chief localisation for the opposite half of the visual field. The possible absence of a commissure between the two sides might explain the persistent hemiopia after lesion of the cuneus in Man.—February 24, 1891.]

† *Loc. cit.*, p. 348.

"The posterior pillars, or crura, of the fornix are the diverging posterior prolongations of two flat lateral bands composing the body. . . . Each crus enters the descending cornu of the lateral ventricle, where part of its fibres are distributed on the great hippocampus, and the remainder are prolonged as the narrow band of white matter known as the *tænia hippocampi* or *fimbria*."

In the same work* the *tænia semicircularis*, or *stria terminalis*, is described as "a narrow whitish band between the nucleus caudatus and the optic thalamus. It forms part of the floor of the lateral ventricle, and it is continued backwards into the white substance of the roof of the descending cornu, and finally ends in the nucleus amygdalæ in the inferior cornu. In front, where it is largest, it reaches the corresponding anterior pillar of the fornix, with which it comes into connection."

According to MEYNERT† the crura fornicis possess a commissure below the splenium of the corpus callosum and within the psalterium. According to the same author and HUGUENIN, the crura fornicis are augmented by fibres from the medullary lamina of the cingulum at the anterior part, where they form the body of the fornix; these fibres pass through the corpus callosum transversely, and join the fornix.

HUGUENIN‡ states that the "fibres of the alveus proceed from the cortex of the cornu Ammonis, but they ascend to the trigonum in the posterior pillar of the fornix, which higher up sends some of its fibres to the opposite side through the psalterium, so that there exists between the two cornua Ammonis a transverse commissure. Directly after the junction of the posterior pillars with each other, along the median line, they receive a new band of fibres which, proceeding from the association fibres of the cingulum, pass through the fibres of the corpus callosum, unite with the trigonum, and accompany the latter in its course, . . . and descend in front of the anterior commissure."

OBERSTEINER,§ after giving the relations of the fornix according to the description already given, says that "the two posterior crura of the fornix enclose on the under surface of the corpus callosum a triangular area, with clearly-marked transverse arrangement of fibres, and with the apex of the triangle directed forwards (*psalterium lyra Davidis*). It consists of a thin medullated layer, which is often incompletely united with the under surface of the corpus callosum, but which is separated from it by a cleft (the ventricle of VERGA)."

Further on in his work,|| he says that "there is no doubt the fornix contains many fibres which, coming out of the cortex of the Ammon's horn, seem to end in the corpus mamillare, and therefore are analogous to the fibres of the corona radiata. A small part of the fibres of the fornix, which radiate into the septum lucidum, must be

* P. 352.

† *Loc. cit.*, p. 760.

‡ *Loc. cit.*, p. 134.

§ *Loc. cit.*, p. 69.

|| *Loc. cit.*, p. 343.

reckoned as association fibres, as the septum is to be looked upon as part of the cortex cerebri."

The part of the fornix with which we are concerned in this paper, is the highest part of the arch, which lies in the floor of the lateral ventricle on the optic thalamus, and is commonly called the body of the fornix, as well as the posterior part of the arch, which descends the inferior cornu of the lateral ventricle.

It may be said at once that the anterior part of the fornix known as the ascending and descending pillars, will not form part of this paper, as the subject has already been worked out by VON GUDDEN and FOREL ('Archiv f. Psychiatrie,' vol. 7, p. 77; vol. 7, p. 422; vol. 11, p. 428).

Sagittal sections.—The horizontal fibres which form the highest part of the arch of the fornix are seen in the lateral ventricle, lying beneath the corpus callosum, and resting on the optic thalamus in the groove between this body and the caudate nucleus (fig. 1, *F.*).

Its fibres, which have an antero-posterior direction, can be traced backwards to the splenium of the corpus callosum. In this course, just before they reach the splenium, the fibres are doubled back upon themselves, so as to form a sigmoid appearance, which, as we proceed outwards from the middle line, becomes more posterior, until at last it reaches the splenium.

On arriving there its fibres are divided into two parts by the splenium:—(1) Some of them pass above it and enter into the posterior part of the corpus callosum, where they have a direction at right angles to its transversely cut fibres, and thus separate off the splenium from the main body of the corpus callosum; (2) In sections further removed from the middle line, the rest of the horizontal part of the fornix passes down in front of the splenium, between it and the posterior border of the optic thalamus. This, as will subsequently be seen, is the commencement of the part called *tænia hippocampi*, which descends the inferior cornu of the lateral ventricle to reach the cornu Ammonis, where it is also known as the fimbria.

To return to the fibres of the fornix which pass above the splenium. As stated above, they pass into the corpus callosum. They appear (figs. 1–4, *F.m.*) as a very fine bundle connected with the body of the fornix in front, and behind they pass into the septum between the splenium of the corpus callosum and its main part. The fibres there take a direction upwards and backwards, at right angles to that of the fibres of the corpus callosum. The individual fibres of the fornix can be traced as far as the superior surface of the posterior part of this structure, but what their final ending may be, cannot be ascertained. They appear as septa between the thick bundles of the corpus callosum, but whether they pass out with its fibres to join grey matter elsewhere cannot be here made out. They do not seem to be continuous with the cingulum as has been described by HUGUENIN.

The other part of the fornix, lying in front of the splenium and behind the optic thalamus, must now be described.

The first appearance of the fibres of the horizontal part of the fornix descending in front of the wedge-shaped splenium of the corpus callosum is in fig. 5 (*F.l.*).

Here the bundles of the transverse fibres of the splenium (*Spl.*) are seen, and in front of them is a narrow band of fibres from the body of the fornix descending to the apex of the splenium, where they become more or less transverse in direction. They continue to pass down along the descending cornu of the lateral ventricle, being bounded in front by the pulvinar of the optic thalamus, and behind by the commencing fascia dentata of the gyrus hippocampi. During this time the transverse fibres of the splenium alter in shape, and are readily distinguished from the descending fibres of the fornix by their marked transversely-cut appearance, and by the fact that they are more deeply stained (by WEIGERT's method) (fig. 10, *F.M.*, and *F.l.*).

The posterior pillar of the fornix continues descending, and finally joins the fimbria of the cornu Ammonis (fig. 11, *Fimb.*), the fibres still preserving their peculiarity of being stained a lighter colour (by WEIGERT's method) than the adjacent fibres of the splenium.

At a point half way down the descending cornu the fimbria (fig. 11, *Fimb.*) appears to form a fusiform enlargement lying behind the lower part of the corpus geniculatum externum (*c.g.e.*). The part of the fimbria beyond this enlargement is very narrow, where it is known as the alveus (*Alv.*), while the part above this becomes much increased so as to be the same size throughout (fig. 12, *Fimb.*).*

The fibres of the tænia hippocampi have a distinctly longitudinal direction and are exactly parallel to the posterior curved surface of the corpus geniculatum externum, from which it is separated by the descending cornu of the lateral ventricle.

The tænia hippocampi, or the fimbria, is prolonged downwards along the whole extent of the free margin of the fascia dentata of the gyrus hippocampi to the lower end of the ventricle, and then over the extreme anterior end of the cornu Ammonis, when it is known as the alveus (figs. 11, 12, *Alv.*), and it here separates this gyrus from the hippocampal or pyriform lobule (*H.L.*) with the nucleus amygdalæ.

The relation of the tænia to the cortex of the hippocampal convolution must now be described, beginning with the lowest part.

In the sections of this series, nearest to the middle line in which the inferior part of the cornu Ammonis first appears (fig. 5), the lowest end of the alveus is seen bounding the anterior and superior surfaces of the cornu Ammonis (*C.A.*), but separated by a space from the hippocampal lobule in front of it. On microscopical examination the alveus has no connection with the hippocampal lobule, and this statement holds good throughout this series of sections.

* [The tænia hippocampi, or fimbria, is the continuation of the crus posterius fornicis and forms a thick band of fibres on the superior and anterior surface of the fascia dentata, whereas the alveus denotes the narrow band of fibres proceeding from the fimbria round the anterior and external surfaces of the cornu Ammonis to its inferior and posterior surfaces.—February 20th, 1891.]

This lowest end of the alveus (figs. 8-10, *Alv.*) can be traced into a leash of fibres which turn downwards and spread out across the cingulum (*Cing.*, *p.*), to end in the cell layer of the cortex on the inferior surface of the temporo-sphenoidal lobe. This leash of fibres in which the alveus ends, is in close contact with that formed between the termination of the cingulum and the superficial fibres of the gyrus hippocampi, but even with high powers (F, ZEISS) no definite connection can be made out between the two.

The alveus (fig. 10, *Alv.*) has here a direction parallel to the superior and anterior surface of the cornu Ammonis, and when traced upwards, appears to give off fibres into its cell layer. It appears to do so because, although numerous fibres are seen in the adjacent layers of the cortex, there is not that extensive radiating out of fibres from the alveus which is seen in other parts.

At the upper surface of the cornu Ammonis the fimbria (fig. 10, *Fimb.*) sends down fibres into its cortex, and in some sections the plexus is continued downwards into the central part of the grey matter of the fascia dentata (*F. D.*).

On looking at the next section (fig. 12), where the fimbria (*Fimb.*) and the alveus form a continuous band reaching from the upper part of the hippocampus major and the tail of the caudate nucleus (*Alv.*, *c.n.*, fig. 11) to the anterior inferior end of the cornu Ammonis below, it can be made out that along the whole of this course where the fimbria is in contact with the grey cortex of the cornu Ammonis, a fine plexus is given off into it.

It is difficult to say for certain in which direction the fibres are given off from the part of the fimbria which is parallel to the surface, but in the alveus it is still from the cortex of the cornu Ammonis, downwards and forwards, in fibres of short lengths. It will be observed on looking at fig. 12 that the convoluted appearance of the fascia dentata (*F. D.*, fig. 11) gradually disappears, and at the same time the outer cell layer of the cornu Ammonis extends upwards at the expense of the fascia dentata. Into this extension of the cell layers of the cornu Ammonis, fibres are sent off by the tænia. The direction of its fibres at the upper part is now probably downwards and forwards into the cortex. At the same time the lower end of the alveus (fig. 12, *Alv.*) begins to extend round the inferior surface of the cornu Ammonis, so as to separate this from the underlying cingulum (*Cing. p.*). The direction of the fibres of the alveus is a transverse one, *i.e.*, the fibres appear in section as points, and in marked contrast to the longitudinal fibres of the cingulum.

These fibres of the fimbria in succeeding sections gradually appear further backward along the inferior surface of the cornu Ammonis, while, at the same time, the tænia hippocampi or fimbria gradually loses its upper end (*i.e.*, the part between the tail of the caudate nucleus and the optic thalamus). In further sections outwards the fimbria diminishes still more, until the cornu Ammonis, as here seen, is completely surrounded by only a thin band of fibres, which must be the alveus, as the section is now external to the level of the fimbria (see fig. 38). This appearance becomes more

marked on passing outwards, and in the most external sections of this series the cornu Ammonis is seen as an oblong piece of grey matter encircled by a band of fibres which are arranged in short cut bundles and completely separate this gyrus from the surrounding structures, viz. :—at the upper and posterior end, the remains of the corpus callosum; in front, the descending cornu of the lateral ventricle and the descending tail of the caudate nucleus, which here joins the outermost part of the lenticular nucleus; further in front are the remains of the nucleus amygdalæ and inferiorly the fibres from the posterior part of the internal capsule, which are visible as far forward as this nucleus.

The direction of the fibres surrounding this, the extreme outer part of the cornu Ammonis, is important. The level now reached is so external that these fibres must be looked upon as part of the alveus (*cf.* horizontal sections, fig. 38), except at the extreme upper end where they may form part of the fimbria. On the upper surface, which is bounded by the descending cornu of the lateral ventricle, the fibres are in short-cut lengths and are directed forwards and downwards *towards* the cortex, but they do not give off many fibres. At the lowest anterior end of the lateral ventricle they become parallel to the surface of the cortex, and round the front of the cornu Ammonis they change their direction and go downwards and forwards *from* the cortex. As the under surface is reached the direction of the fibres is confused and becomes at right angles to the cortex, and for the rest of the distance from here to the upper end of the lateral ventricle the fibres are in short lengths in the direction *from* the cortex down and forwards.

Horizontal Sections.—The first appearance of the body of the fornix is seen in horizontal sections, when the level is reached where the lateral ventricle is first opened (fig. 16, *F.*).

It there appears in the lateral ventricle on the inner side of and parallel to the inner border of the caudate nucleus (*C.N.*), and bounded on its inner side by the cut-across ends of the transverse fibres of the corpus callosum.

The direction of its fibres is backwards and outwards. The fornix increases in size as we proceed downwards and has in these sections a fusiform shape.

It lies free in the cavity of the ventricle, and at this level has no connection with the surrounding parts. It is bounded on the outer side by the choroid plexus, which separates it from the caudate nucleus. As we descend, a mass of grey matter (stained orange in the sections) appears in the middle of the fusiform shape of the fornix; this is the optic thalamus, which gradually separates the fibres of the fornix (figs. 20–22, *O.T.*), but they are joined again behind that body; on the inner side the fibres soon disappear leaving the thalamus free. This appearance is explained by examining a frontal section (fig. 40) where the fornix rests on the thalamus like a roof, horizontal sections of which would expose the thalamus with the fornix on either side of it.

The fibres on the outer side of the optic thalamus, when traced forwards, end in a

small piece of grey matter occupying a median position and bounding the inner side of the lateral ventricle (figs. 22, 23, *S.L.*). This is the septum lucidum.

We need not pursue these fibres any further forwards as it is outside the scope of the present work, and the termination of the anterior pillars of the fornix has already been worked out by Professors GUDDEN and FOREL.

Posteriorly these fibres run between the optic thalamus and caudate nucleus to the hinder part of the former (fig. 23, *F.L.*), where they form a knob-like shape, which is situated in a cavity of the lateral ventricle, bounded on the inner side by the optic thalamus (*O.T.*); by the tail of the caudate nucleus (*c.n.*) and choroid plexus on its outer side; and in front, by the medullated fibres of the corona radiata. This part of the fornix, lying external to the optic thalamus, is gradually lost as we proceed to lower sections, and the two ends of the arch alone remain, viz., the anterior end in the septum lucidum (fig. 29, *S.L.*), which is now separated from the optic thalamus by the foramen of MONRO (*For.M.*), and the posterior which forms the knob-like projection just referred to (*F.L.*). This latter, as will be seen later on, is really the tænia hippocampi and its fibres soon assume a downward direction, *i.e.*, they appear as if cut across (fig. 29, *F.L.*).

We must now return to the fibres of the fornix on the inner side of the optic thalamus.

In fig. 22 (*F.i.*) these fibres have a direction backwards and outwards behind the optic thalamus, and lying just in front of the posterior part of the body of the corpus callosum, from which, however, they are distinctly separated, being stained by hæmatoxylin of a lighter colour.

They are at first (fig. 23) free in the lateral ventricle, but in the next section (fig. 24) they come into close contact with the forceps major. In lower sections (fig. 26) the fornix appears as a thin faintly-stained band of transverse fibres, running outwards with the forceps major, but when traced inwards they do not extend to the middle line except in fig. 28. These are probably the transverse fibres which are considered to extend across the middle line to the other hemisphere, and to have a different course from those described above as lying internal to the optic thalamus. When traced outwards they join the base of the knob-like projection of the outer fibres of the fornix above referred to, and beyond this they pass into the cortex of the cornu Ammonis.

It is exceedingly difficult to separate the course of these fibres of the fornix from those of the corpus callosum, but one is helped by the fact that the latter are stained by WEIGERT's method a deep blue, almost black colour, while the fibres of the fornix are stained a lighter tint (see corpus callosum, p. 174).

In fig. 29 (*F.L.*) the knob-like projection of the external fibres of the fornix, which we may now call the tænia hippocampi, or fimbria, is still seen to be descending, and to have the same relations in the lateral ventricle to the surrounding parts as before. At the base of the projection we have the light-coloured fibres of the transverse part

of the fornix, and behind them the transverse fibres of the forceps major of the corpus callosum.

At fig. 30, these fibres of the forceps major in front of the cornu disappear, leaving the transverse fibres of the fornix, which gradually diminish till we reach fig. 32, where they disappear almost entirely, leaving the knob-like projection of the *tænia hippocampi*, which now lies quite free in the descending cornu of the lateral ventricle, except at its posterior part, where it rests on the cornu Ammonis, having the tail of the caudate nucleus on its outer and the optic thalamus on its anterior and inner sides, with the ventricle intervening. In figs. 35-37, although there are no horizontal fibres of the corpus callosum or fornix on the inner side of the *tænia hippocampi*, there is a considerable band of fibres going out from the posterior part of the *tænia*, and running round the external surface of the cornu Ammonis to its hinder surface (*Alv.*). These fibres appear as if cut into short lengths, having a direction from the cortex backwards and outwards. In this course they form the anterior part of the inner wall of the posterior cornu of the lateral ventricle, and wind round to the posterior surface of the cornu Ammonis. Posterior to this convolution and between it and the hippocampal gyrus, there is a considerable projection of white matter. At the outer part, next to the ventricle, three sets of fibres are to be recognised under the microscope—1st, the fibres of the fornix just described, coming round the outer surface of the cornu Ammonis from the *tænia hippocampi*; 2nd, the calcarine fibres (*C.f.*) at the extreme posterior part; and 3rd, between the two a wedge-shaped mass of fibres, the forceps major (*F.M.*), having its outer surface free towards the lateral ventricle.

The differentiation of these fibres into three parts is better seen in sections stained by WEIGERT'S method than by PAL'S.

Besides these three sets of fibres, we must not forget the cingulum, which forms the most internal part of this portion of white matter.

The first of the three sets of fibres described above, which is considered to come from the *tænia hippocampi* or fimbria, forms what is known as the alveus of the cornu Ammonis, and its fibres can be traced on their inner side into its cell-layer, whence they pass in a direction outwards and backwards, while posteriorly, on arriving behind the cornu Ammonis, the direction of their fibres is evidently descending, and they finally blend with the fibres of the cingulum.

The alveus occupies the same place as the forceps major higher up; but whereas the fibres of the latter can be traced directly from the splenium, the former is narrower, and its individual fibres do not sweep round out of the fimbria, but they exist only in short lengths, instead of in one continuous band of fibres.

It will thus be seen that at this level the alveus lines the inner wall of the lateral ventricle which corresponds to the cornu Ammonis. On the other hand the whole outer wall of the posterior cornu is formed by the tapetum of the corpus callosum (*Tap.*).

The relation of the alveus to the cornu Ammonis and to the cingulum remains the same as far as fig. 38 (*Alv.*).

When traced further down still, we come to the level where the forceps major fibres cease, and where the posterior cornu of the lateral ventricle does not extend further back than the posterior surface of the cornu Ammonis, and the fibres from the posterior part of the internal capsule are turning sharply inwards to end in the hippocampal convolution. Here the knob-shaped fimbria, with its fibres cut across transversely, is well seen, as well as the alveus, proceeding from its outer border and occupying a position round the outer surface of the cornu Ammonis, behind which it comes into relation with the cut-across fibres of the cingulum.

The part of the alveus nearest the fimbria shows short cut fibres arranged at right angles to the cortex of the cornu Ammonis; more posteriorly they pass from the cortex back and out, while near the cingulum the fibres appear as points.

In the section where we have nearly reached the level of the lowest part of the occipital cortex, the fimbria alters in shape. It becomes triangular, with the apex backwards, and its fibres are seen to be arranged in a distinctly antero-posterior direction. This direction is continued into the alveus for the first part of its course, where the fibres are arranged in short lengths at right angles to the cortex, but posteriorly near the cingulum the fibres appear as points on the convexity of the cornu Ammonis, *i.e.*, the part turned towards the ventricle; but on approaching the cingulum the fibres are cut obliquely, but for the most part run forwards and backwards. Where the fimbria and alveus are in contact with the cornu Ammonis they send a plexus into its cortex. This is especially the case at the anterior and posterior parts.

In the section which is on a level with the under surface of the frontal lobe, the last vestige of which is seen, the cornu Ammonis increases very much in size, owing to the fact that it is here cut across in a slanting direction as it descends forwards.

The fimbria is much increased in size, and it is turned inwards towards the crus cerebri, which lies on its inner side, whilst in front is the posterior cut end of the optic tract. Its most internal fibres are directed backwards and outwards, forming a thick plexus in the cornu Ammonis, while the rest of them have an antero-posterior arrangement. The relation of the alveus remains the same as before. When traced downwards the fimbria remains enlarged, with all its fibres directed inwards and forwards until we reach the level of the middle of the optic chiasma, after which the cornu Ammonis appears enormously enlarged, and then the fimbria suddenly diminishes, so that in the last section of this series the alveus takes its place and appears as points, separating the cornu from the hippocampal lobule, as the level is now below that of the fimbria.

Frontal and Fronto-oblique Sections.—Having discussed the fornix in sagittal and horizontal sections, it will now be examined in the frontal and in frontal-oblique planes. It will be more convenient to take the latter first, as they show the fornix

at a point further forward than in the frontal sections. In the most anterior sections, passing through the most anterior part of the pons and crus cerebri, the septum lucidum is well seen at the middle line, forming an irregular four-sided figure, being in contact with the under surface of the corpus callosum above, and bounded on the outer side by the lateral ventricle and below by the space known as the foramen of MONRO.

It contains some cut-across fibres, which gradually form a projection on its outer side. This increases at the expense of its grey matter, which gradually alters in shape, until we have the septum lucidum appearing as a narrow triangular piece of grey matter, and, attached to it below, a horizontal collection of fibres, which at the middle line are cut away, while at their outer part they become oblique. This is the commencing body of the fornix, which now comes into contact with the under surface of the corpus callosum, the choroid plexus intervening.

At the most inferior part of the septum lucidum there are a few transverse fibres which leave off abruptly at the middle line. Their nature is not known.

The fornix continues to increase outwards, the fibres there having an oblique transverse direction, whilst at the middle line there is a considerable collection of fibres which are cut transversely and have a longitudinal direction, and the grey matter of the septum lucidum is very slightly represented. We already see that the fornix here consists of two distinct parts: 1st, a median; 2nd, a lateral oblique. These correspond to the two divisions of the fornix seen in sagittal sections (p. 182). The median fibres appear as points, *i.e.*, they have a sagittal direction, whilst the lateral fibres are cut across obliquely.

The under surface of the fornix is now in contact with the superior surface of the optic thalamus, and so closes up the space leading from the lateral ventricle inwards between the fornix and the optic thalamus; this space or channel is known as the foramen of MONRO.

In the next section the fornix is closely applied along the whole of its under surface to the upper surface of the optic thalamus. At the inner part the small triangular piece of the septum lucidum still remaining begins to be separated off together with the median fibres of the fornix from the rest of the fornix by a space. Separated from this and lying closely applied to the corpus callosum above and on the optic thalamus beneath is the rest of the fornix presenting a number of obliquely cut fibres.

The fornix has now been traced to the fronto-oblique level of the posterior extremity of the lenticular nucleus and to about the middle of the pons.

Having now described the fornix so far in fronto-oblique sections, it will be convenient to examine it in frontal sections.

In the first frontal section, which is made at the vertical level of the optic commissure (fig. 39), the fornix is seen lying between the corpus callosum (*C.C.*) above and the optic thalamus below (*O.T.*). It consists of a heart-shaped median

part (*F.m.*), with two lateral parts like wings (*F.l.*), which are joined to the central part by a narrow isthmus which forms a sigmoid bend between them. The central part is made up of two halves, each of which contains in its upper part a small portion of grey matter, here stained yellow, which is in close contact with the under surface of the corpus callosum. This is evidently the remains of the septum lucidum, as has been already traced in fronto-oblique sections.

Situated just below the grey matter of the septum lucidum are some cut-across fibres, which are the median longitudinal fibres seen in horizontal sections (p. 186). The lateral part of the fornix, or wing, has an irregular shape and is quite free in the lateral ventricle. The rest of the fibres in the central part of the fornix and also in the lateral part are arranged in such a confused manner that it is rather difficult to say what their course is, but for the most part they appear transversely cut at the inner part and obliquely cut at the outer part. The median part is gradually divided by a notch on its under surface into two halves.

This part of the fornix soon (fig. 40) becomes flatter and more spread out along the under surface of the corpus callosum, and the notch which existed on the under surface between the two halves of the central median portion gradually disappears. The lateral parts (*F.l.*) on either side, which are gradually extending, are now united to the central portion (*F.m.*) by a still narrower isthmus, which makes here a more pronounced sigmoid bend. At the same time the shape of the lateral part alters, and it makes an angle where it rests on the optic thalamus.

The median part becomes thinner and more extended laterally, so that in fig. 40 it forms a narrow horizontal band (*F.m.*) which is in contact with the under surface of the corpus callosum for its middle third (*C.C.*), with which it becomes completely blended, and from which it can only be distinguished by the transversely cut appearance of its fibres, which are at right angles to those of the corpus callosum. The fibres of either side do not extend quite to the middle line. In the lateral part which extends to the outer limit of the lateral ventricle the direction of the fibres is obliquely downwards and outwards.

The next series of frontal sections extends from the anterior part of the pons to about its middle.

In these sections the corpus callosum has increased very much in thickness, and along the middle two-fourths of its under surface there is an exceedingly narrow band of transversely cut fibres. This arrangement, which is fairly well marked at the outer part of the middle third of the under surface of the corpus callosum, cannot be so definitely made out at the median line.

When traced outwards, this narrow band is seen to be connected with the two lateral parts or wings of the fornix by a faint sigmoid-shaped isthmus. This narrow band then, is evidently the continuation of the median portion of the fornix.

The lateral parts of the fornix are here very well developed. They lie in the lateral ventricle on each side, resting on the upper free surface of the optic thalamus and making an angle parallel to the upper surface of that body.

The direction of the fibres in the lateral part is oblique in the part nearest the middle line, and descending outwards and downwards at the external end. Above them a collection of vessels is seen in the lateral ventricle lying close to the nucleus caudatus, this is the choroid plexus on either side, whilst below the fornix and resting on the upper surface of the two optic thalami, is a membrane containing numerous blood vessels—the velum interpositum or the central part of the fold of pia mater entering the brain by the great transverse fissure between the fornix and the optic thalamus.

The lateral parts of the fornix are really what have been described as its essential parts, and it is the union of these two, at the middle line, which is considered to form what is known as the body, whilst the prolongations of these lateral portions, forwards and backwards, are known as the anterior and posterior crura respectively, and the latter crus subsequently becomes the *tænia hippocampi* or *fimbria*.

As we proceed further backwards in these sections, the sigmoid isthmus becomes straight. At the same time, the median fibres of the fornix, in contact with the corpus callosum, begin to interpose themselves between its lowest layer and a fresh set of fibres which have a transverse direction. The median tract cannot be traced completely across, but on the other hand a distinct septum, here stained yellow, is seen following the same course as the tract; but it is quite impossible to demonstrate the transverse commissural fibres of the fornix.

This layer of fibres, which is inferior to the median fornix and the septum, is the commencement of the splenium of the corpus callosum. If this be so, these transversely cut median fibres correspond to those fibres of the fornix which, in sagittal sections (p. 182), pass between the main part of the corpus callosum and its splenium. After the median fibres of the fornix have been traced into the septum between the corpus callosum and its splenium, they gradually diminish until they disappear and the lateral fibres are alone left.

At the vertical level which we have now reached, the caudate nucleus is turning downwards to form the part known as its tail or surcingle, and, consequently, we can trace its grey matter from the part in the lateral ventricle above, to the tail in the descending cornu of that ventricle below. At the same time, the optic thalamus is almost detached from the cortical mantle, and the *tænia hippocampi* can be traced for a considerable distance downwards and outwards as it lies free in the lateral ventricle, between the optic thalamus and the caudate nucleus.

In the next series of sections, the optic thalamus and the pons are completely separated from the rest of the brain.

In the middle line, the corpus callosum is separated into two parts by a horizontal septum, viz., into the posterior part of the body and the splenium. Connected with this septum are the fibres of the fornix (which immediately becomes very much enlarged), passing outwards and downwards, in a thick bundle, to the cornu Ammonis.

The fornix, at its commencement here, lies to the outside of the splenium of the corpus callosum, whose fibres end abruptly at their outer part, and are stained a much deeper colour than the fibres of the fornix, and no communication can be traced between them.

We have reached here the vertical level where the main portion of the lateral ventricle is in direct communication with its inferior cornu, and it is along this communication that the fornix or *tænia hippocampi* can now be traced. Its fibres have a distinctly downward course, and on reaching the cornu Ammonis some of them enter the cell-layer of the cortex, while some of its outer fibres are prolonged along the outer surface of the cornu Ammonis, *i.e.*, that turned towards the lateral ventricle.

These last-named fibres form the alveus, and prolongations are sent from them into the cell-layer of the cornu Ammonis. The direction of these fibres at the upper part of the alveus, is *from* the cortex outwards and downwards; at the middle part they are transversely cut across, and at the lowest part, they assume a direction downwards and inwards from the cortex. They end in the bulbous-shaped fibres of the subiculum cornu Ammonis or, in other words, the central white matter of the temporo-sphenoidal lobe. In a more anterior section (fig. 40) these fibres (*Alv.*) turn downwards through the cingulum (*Cing. p.*) into the cortex of the temporo-sphenoidal lobe.

In another fronto-oblique section (fig. 41, right half) the corpus callosum (*C.C.*) is seen as a very wide mass of fibres. Here the posterior pillar of the fornix (fig. 41, right, *F.p.*) is seen as a thick band springing from the middle of the corpus callosum, *i.e.*, between its main part and the splenium, and coursing downwards along the lateral ventricle and on the outer surface of the optic thalamus to the cornu Ammonis where it is known as the fimbria (*Fimb.*), whilst on the other half of the section (fig. 41, left) which is the more posterior, the forceps major springs direct from the splenium.

The direction of the fibres of the fornix is a downward one corresponding to the long axis of its descending part.

Here again attention must be called to the difference in the depth of staining between the fornix and the callosal fibres, the light tint of the former being in marked contrast to the dark staining of the latter.

In fronto-oblique sections (figs. 42, 43, 44, right) through the posterior part of the corpora quadrigemina the descending pillar of the fornix and the forceps major of the corpus callosum (*F.p.*, *Spl.*) are in close apposition along the inner wall of the lateral ventricle. The fornix can be distinguished from the latter by its faint staining and by its apparent origin from the middle of the corpus callosum, whilst the forceps major is the direct continuation downwards and outwards of the splenium, and is stained as deeply as the rest of the corpus callosum. Therefore, as in sagittal sections, the descending pillar of the fornix lies just in front of the splenium and its

forceps major, so that in making a series of fronto-oblique sections from before back we at first cut through the fornix and behind that the splenium with its forceps major. It must be remembered that the descending pillar of the fornix is prolonged like a sheet along the whole length of the cornu Ammonis in the descending cornu of the lateral ventricle.

We thus see in fronto-oblique sections, that the fornix is gradually encroached upon by the splenium and forceps major as we pass backwards, until at the level where the gyrus fornicatus has joined the gyrus hippocampi, the fornix has almost quite disappeared (fig. 45, right).

In the next level (fig. 41, left) the fornix has entirely disappeared, and in its place is the forceps major (*F.M.*).

Summary.—As has been already mentioned, the part of the fornix here described includes the body, forming the highest part of the arch and the posterior crura. As the anterior crura will not be described, the account here given refers to the fornix after it has emerged from the septum lucidum to pass backwards as well as its arrangement in this part of the grey matter just before leaving it.

While in the septum lucidum the fornix appears as a single tract of fibres (fronto-oblique sections), but just before leaving this structure it can be seen to separate into two sets of fibres, viz. :—(1) a median ; (2) a lateral part.

The median part of one side is (frontal sections) joined to the corresponding part of the other side, being separated by a septum or raphe. The median fibres of opposite sides, together with the remains of the posterior part of the septum lucidum, form a structure which is as thick in a vertical direction as the corpus callosum. On either side the lateral part of the fornix is almost separated off from the median part, being merely attached by a narrow sigmoid band. Traced backwards the median fibres of either side, which throughout have a horizontal antero-posterior direction, are flattened horizontally along the under surface of the corpus callosum ; and whereas the fibres of opposite sides were in contact with each other in front of the splenium, they gradually separate and pass into the septum between the corpus callosum and its splenium, and they can be traced into the substance of the corpus callosum (sagittal sections) in the septum as far as its upper and posterior surface, but how they leave this structure it is not possible to say. In the sagittal sections of a brain of the Monkey already referred to (p. 161), fibres can be discerned passing through the corpus callosum almost like septa between the cut-across callosal fibres, and they are very similar to the course of the median fibres of the fornix in the corpus callosum of the Marmoset. But when these fibres are traced in the Monkey to the posterior and upper border of the corpus callosum, they appear to pass out of this body, and also at first to turn backwards and join the fibres of the cingulum, but on examination with higher powers of the microscope (C, ZEISS), it is not possible to make out a true connection between the two sets of fibres, the relations between them being more of the nature of a decussation. This appearance is only seen in the

sagittal section, where only a small piece of the cingulum remains in front of the posterior end of the corpus callosum.

It is probable that these are the fibres referred to by MEYNERT and by HUGUENIN (see p. 181), as coming from the cingulum and passing through the corpus callosum to join the body of the fornix and so proceeding forwards. Whether they do come from the cingulum is, I think, not to be demonstrated. I am unable to find that either MEYNERT or HUGUENIN describe these fibres, which pass through the corpus callosum as a separate median bundle, remaining distinct as far forward as the septum lucidum from the lateral fibres coming up from the posterior crura.

The lateral fibres of the fornix form that part which is usually described as the body: its shape is at first rounded; it then becomes flattened in a horizontal direction, and diverges from the middle line, lying on the optic thalamus and between this and the caudate nucleus. And whereas the median part of the fornix is attached to the under surface of the main part of the corpus callosum, the lateral part is free in the lateral ventricle (frontal sections).

On reaching the splenium the lateral part of the fornix descends in front of this structure, lying between it and the optic thalamus.

It is here rather difficult to separate the fornix from the splenium and its forceps major, which lie directly behind it, but the difference in staining by WEIGERT's method between the two is so marked that it gives considerable assistance. Moreover (fronto-oblique sections) the fornix appears to arise from the septum between the two parts of the corpus callosum, whereas the splenium is continued directly into its forceps major.

The descending part of the fornix, known as its posterior or descending pillar or crus, can be traced forwards along the descending cornu of the lateral ventricle to the anterior part of the hippocampus major or cornu Ammonis. In this course it is known as the *tænia hippocampi* or *fimbria*. It will thus be seen that the lateral part of the fornix forms a sheet of fibres extending the whole width of the lateral ventricle of each side, and this sheet becomes narrowed as it descends this cavity, being collected into the cord-like *fimbria*, from which again a very thin sheet, the *alveus*, is spread over all the cornu Ammonis.

Having now described the general arrangement of this part of the fornix it will be advisable to give a more minute account of the direction of its fibres, and their relation to the cortex of the cornu Ammonis.

In the body of the fornix the fibres of the median part are very irregular in direction, but for the most part they have an antero-posterior course. In the lateral part the fibres in sagittal sections appear in short lengths which have a direction downwards, outwards, and backwards; while forming the body they have no connection with surrounding grey matter, except the septum lucidum in front.

The posterior crus forms a roundish tract (knob-shaped on cross section) which takes

the course of the descending cornu, its fibres having at first a direction downwards and backwards, and then downwards and forwards.

When the fornix reaches the antero-superior surface of the cornu Ammonis, it forms the fimbria and sends fibres into the cortex, and also a leash of fibres round the ventricular surface of the cornu Ammonis to the subiculum; this forms the alveus. We thus see that the cornu Ammonis is surrounded on three of its sides, viz., the supero-anterior, external, and infero-posterior, as well as on its anterior limit, by the different parts of the fornix, *i.e.*, the fimbria and alveus, which thus form a continuous sheet of white matter over those surfaces of the cornu Ammonis.

It is therefore not difficult, by examining frontal and horizontal sections, to explain how in sagittal sections made through the outer part of the cornu Ammonis, we see this structure to be oblong in shape, to diminish as we proceed outwards, and to be surrounded by a layer of fibres, the alveus. In sagittal sections the cornu lessens in extent from above downwards, from the fact that, as we descend in horizontal sections, it projects more into the lateral ventricle, and this lower part would therefore be the last to disappear in sagittal sections made successively from within outwards.

The direction of the fibres of the fimbria and the alveus is important, and it can only be made out by careful examination in all the three planes. To begin posteriorly, the fibres of the fimbria in sagittal and fronto-oblique sections (figs. 11, 43) run in the plane of the latter section, *i.e.*, downwards and backwards; they are continued into the alveus in the same plane as far as the inferior surface of the cornu Ammonis, where the direction becomes more obliquely antero-posterior. It was found so very difficult to combine the appearances of the fimbria and the alveus into one mental picture, that it was necessary to make a model of the cornu Ammonis, and arrange the fibres according to their appearances already seen in the various planes. On doing this it appears that the fimbria forms a tract of fibres along the antero-superior aspect of the cornu Ammonis, having a direction parallel to its cortex, into which offsets are sent downwards and forwards as far as the horizontal level through the inferior surface of the occipital lobe; here (as seen in horizontal sections) the direction of the fibres changes, and they then course from the cortex of the cornu Ammonis forwards and then downwards round the anterior extremity of this structure, to end in the cortex on the inferior surface of the temporo-sphenoidal lobe; these fibres, in front of the cornu Ammonis, are really part of the alveus, which has the following arrangement:—At the posterior end of the cornu Ammonis, as stated above, some of the fibres from the fimbria pass into the alveus, and wind round the outer surface of this cortex to its under surface, where they are directed forwards and downwards; in front of this part the alveus receives fibres from the cortex of the cornu Ammonis, around which it winds till the under surface is reached, when the fibres turn downwards towards the cortex of the under surface of the temporo-sphenoidal lobe.

It would thus appear that, whereas the direction of the fibres of the fimbria is from behind forwards into the cell-layer of the cornu Ammonis, the direction of the alveus is from this cortex downwards to end in the medullary centre of the inferior surface of the temporo-sphenoidal lobe.

A few words must now be said with regard to the transverse fibres of the fornix, which have been described by authors as forming a commissure between the cornu Ammonis of opposite sides. It was remarked, in describing the fornix in the three different planes, how difficult it was to separate the splenium from the fornix, which lay beneath and in front of it. This was particularly the case with the horizontal and fronto-oblique planes (*cf.* figs. 30, and 44 right), where it was only possible to arrive at some separation between the two sets of fibres by the difference in the amount of staining by WEIGERT's method. On looking at sagittal sections near the middle line (figs. 1 to 4), it will be found that no transverse fibres exist in the neighbourhood of the posterior part of the body of the fornix except those of the splenium. I can only suggest that the transverse fibres seen in the horizontal sections may pass across to the opposite side with the splenium proper, and these may form the anterior and inferior part of the triangular bundle of the splenium (fig. 4) which is stained a much paler tint than the rest of the fibres, and be commissural between the cornua Ammonis of opposite sides, for no fibres can be traced into them from the forceps major. It must be stated that no transverse fibres of the fornix could be traced across the middle line in frontal sections.

I would again call attention to the manner in which the fornix is stained by WEIGERT's hæmatoxylin method. In all the sections made in different planes, and of course from different brains, the fornix is always stained of a much lighter tint than that of the internal capsule and the corpus callosum. Whether this is due to a less development of the myeline sheath—the structure stained by the hæmatoxylin—I am not prepared to say, but it does not seem to be caused by a looser aggregation of the fibres, as individual fibres of the internal capsule are as deeply stained as when they are in compact bundles. In connection with this subject it is interesting to note the structure known as the *tænia semicircularis*, which lies in the floor of the lateral ventricle between the caudate nucleus and the optic thalamus, just outside the body of the fornix. It is seen as a round bundle of fibres in sagittal and frontal sections (figs. 5–10, 40, *T.S.*) and as a narrow band in horizontal sections (fig. 23, *T.S.*) which is exceedingly faintly stained, just in front of the fornix and between this and the tail of the caudate nucleus, and it seems to consist of little more than fibrous tissue. It is suggested that it is the degenerated remains of a structure once more highly developed. We therefore appear to have three sets of fibres differing in their powers of being stained by this method, viz., those which are strongly coloured, as the corpus callosum; those which are less well stained, the fornix and also the cingulum; and those which are hardly stained at all, the *tænia semicircularis*.

EXPLANATION OF PLATES 20-24.

(The same letters apply to all the figures.)

- Alv.* Alveus of Cornu Ammonis.
- Cing.* $\left\{ \begin{array}{l} a. \\ h. \\ p. \end{array} \right\}$ Cingulum $\left\{ \begin{array}{l} \text{anterior part.} \\ \text{horizontal part.} \\ \text{posterior part.} \end{array} \right.$
- C.A.* Cornu Ammonis or Hippocampus Major.
- C.C.* Body of Corpus Callosum.
- F.M.* Forceps major posterior of Corpus Callosum.
- Spl.* Splenium of Corpus Callosum.
- Spl.'* The part intermediate between the Body and the Splenium.
- Tap.* Tapetum of Corpus Callosum.
- C.E.* Capsula Externa.
- C.f.* Calcarine fibres.
- C.g.e.* Corpus geniculatum externum.
- C.I.* Capsula Interna.
- C.N.* Caudate Nucleus.
- c.n.* Tail of Caudate Nucleus or Surcingule.
- C.q.* Corpora quadrigemina.
- C.R.* Corona Radiata.
- Cer.* Cerebellum.
- Cr.* Crus Cerebri.
- F.* Fornix.
- F.i.* Fibres of Fornix internal to Optic Thalamus.
- F.l.* Lateral fibres of Fornix.
- F.m.* Median fibres of Fornix.
- F.p.* Posterior descending pillar or crus of Fornix.
- Fimb.* Fimbria or Tænia Hippocampi of Cornu Ammonis.
- F.C.* Fissura Calcarina.
- For.M.* Foramen Monroi.
- G.F.* Gyrus Fornicatus.
- H.L.* Hippocampal Lobule containing the Nucleus Amygdalæ.
- H.S.* Hippocampal or Dentate Sulcus.
- L.N.* Lenticular Nucleus.
- L.V.* Lateral Ventricle.
- L.V.d.* Descending Cornu of Lateral Ventricle.
- L.V.p.* Posterior Cornu of Lateral Ventricle.

O.Ch. Optic Chiasma.

O.T. Optic Thalamus.

O.t. Optic tract.

S.F. Fissure of SYLVIVS.

S.f. Superficial fibres of Gyrus Fornicatus and Gyrus Hippocampi, or superficial medullary lamina.

S.L. Septum Lucidum.

T.S. Tænia Semicircularis.

DESCRIPTION OF THE FIGURES.

PLATE 20.

Figs. 1-4.—Photographs of microscopic sections of the brain of the Marmoset (*Hapale penicillata*) cut in the sagittal direction and stained by PAL's hæmatoxylin method. The medullated fibres are stained black, and the grey matter is of a grey colour. Fig. 1 is made a short distance from the middle line, and the other sections are external to it. Magnified three diameters.

PLATE 21.

Figs. 5-10.—Photographs of similar sections of *Hapale penicillata*. Sagittal direction. Stained by WEIGERT's method. Magnified three diameters.

PLATE 22.

Figs. 11 and 12.—Photographs of sections of *Hapale penicillata*, sagittal direction. Stained by PAL's method. Magnified two diameters.

Figs. 5-12 represent levels progressing gradually outwards.

PLATE 22.

Figs. 13-15.—Photographs of sections of the right hemisphere of *Hapale jactans*. Horizontal direction. Stained by WEIGERT's method. Magnified two diameters.

Fig. 13 is the most superior, and is taken a short distance below the highest point of the centrum ovale.

PLATES 22, 23.

Figs. 16-34.—Photographs of sections of the right hemisphere of *Hapale jactans*. Horizontal direction. Stained by WEIGERT's method. Magnified two diameters.

A greater interval exists between figs. 22 and 24 than in the other figures.

PLATE 23.

Figs. 35-38.—Photographs of sections of the right hemisphere of *Hapale penicillata*. Horizontal direction. Stained by PAL's method. Magnified two diameters.

PLATE 24.

Figs. 39 and 40.—Photographs of sections of the brain of *Hapale jactans*. Frontal direction. Stained by WEIGERT's method *in toto*.

Fig. 39 is taken through the optic chiasma; fig. 40 is immediately anterior to the pons Varolii. Magnified two diameters.

PLATE 24.

Figs. 41-45.—Photographs of sections through the corpora quadrigemina of the brain of *Hapale penicillata*. Fronto-oblique direction. Stained by WEIGERT's method. Magnified two diameters.

The two hemispheres are not cut at quite the same level, the right being more anterior than the left, so that the right half of fig. 45 is anterior to the left half of fig. 41, thus giving the appearance of ten levels from before backwards.

N.B.—In fig. 29 the line from *F.M.* should be continued to the white dot behind the cornu Ammonis.

In fig. 34 the line from *F.M.* is carried too far beyond the forceps major to the cingulum, which the line from *Cing. p.* should reach.

In fig. 39 the line from *F.m.* should be continued to the white dot in the fornix beneath the corpus callosum to which it points, while the line from *C.C.* should be continued on to the corpus callosum; the line from *F.l.* ends at the eighth white dot, and external to it is a black dot, where the line from *L.V.* should end.

In fig. 40 the line from *L.V.* should be continued to the dot internal to the line from *c.n.*

In fig. 41 the line from *Spl.* should be continued to the white dot on the inferior part of the corpus callosum; the line from *F.D.* ends in the eighth and not the sixth white dot; the line from *F.C.* ends in the black dot on the grey background; the line from *H.S.* ends in the sixth white dot

SAGITTAL SECTIONS.

Fig 1

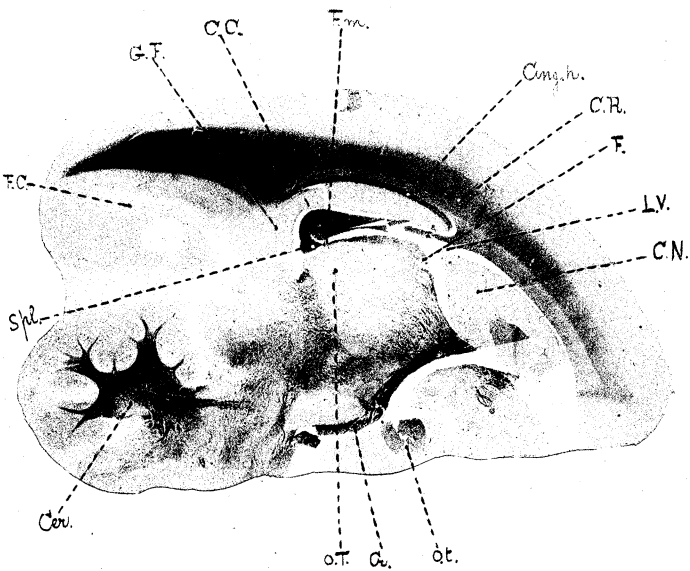


Fig 2

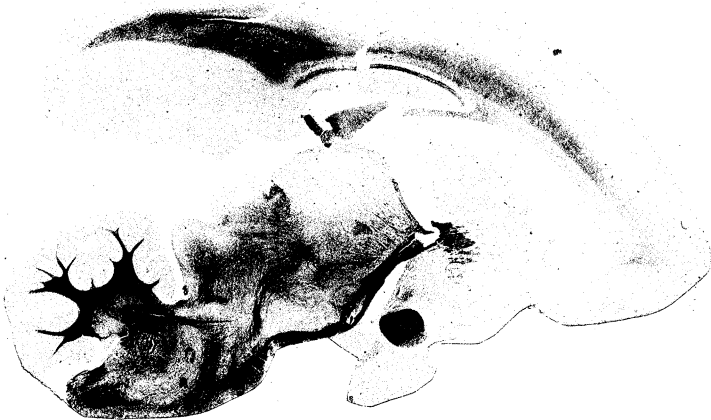

Fig 3

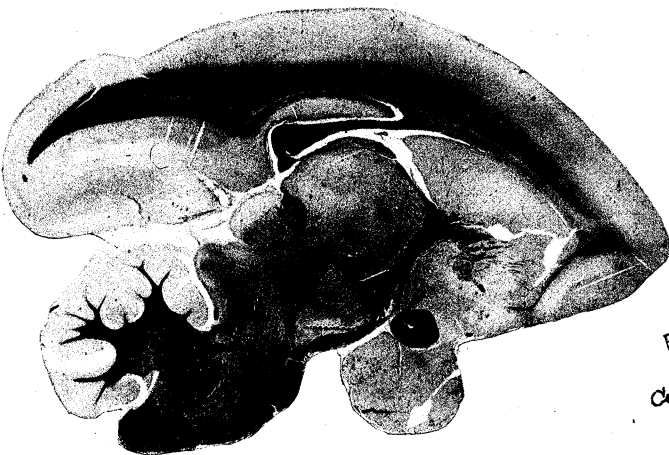
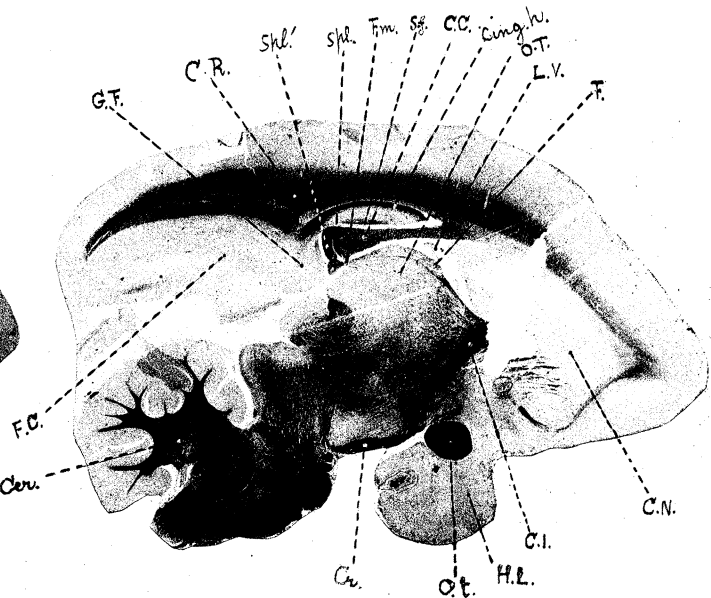


Fig 4



SAGITTAL SECTIONS.

Fig 5

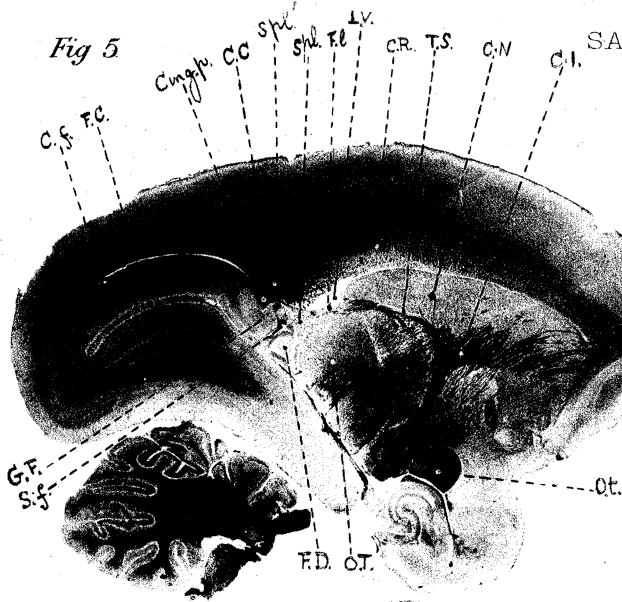


Fig 6

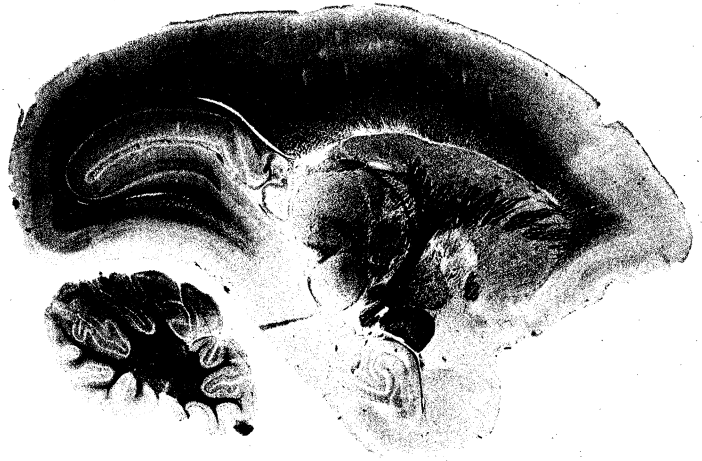

Fig 7

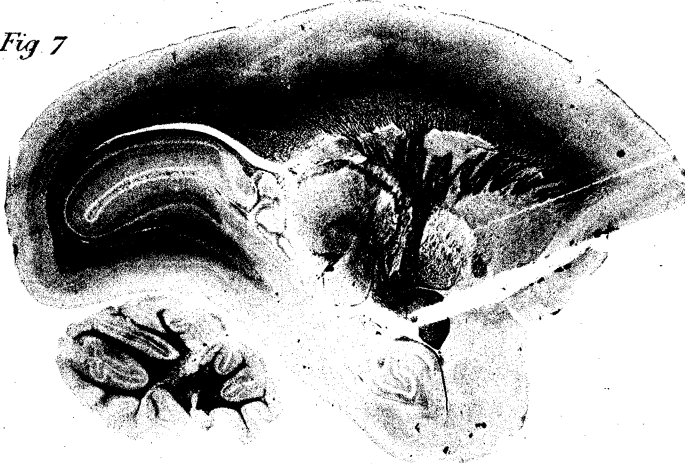

Fig 8

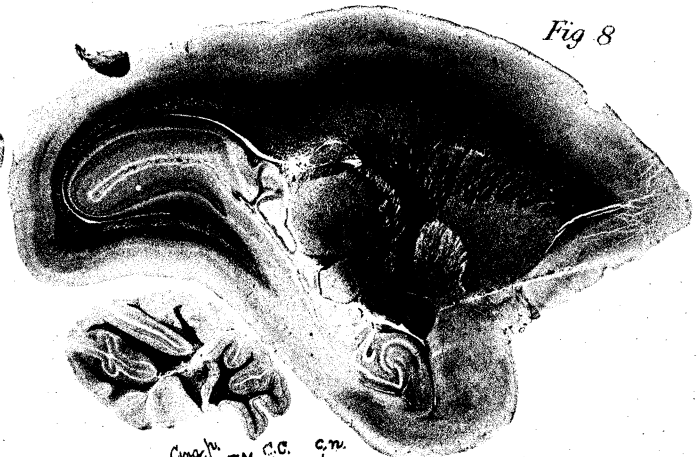


Fig 9

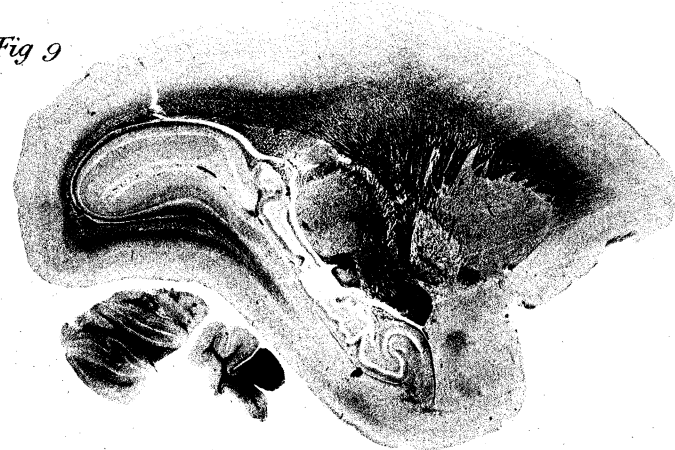
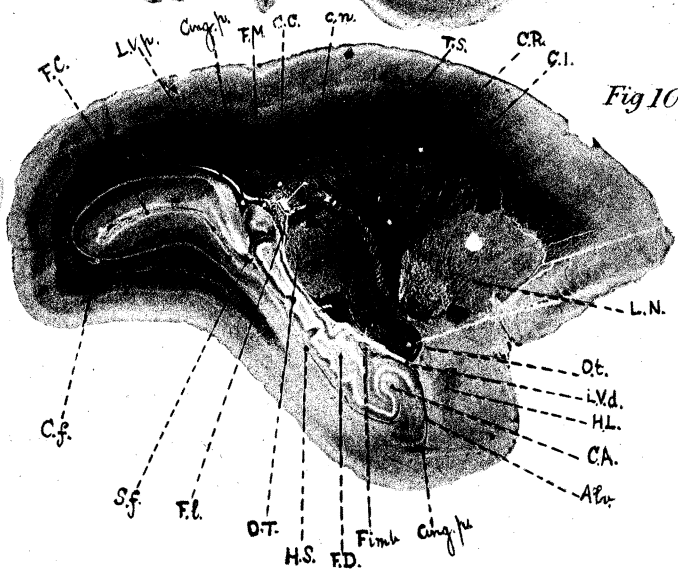
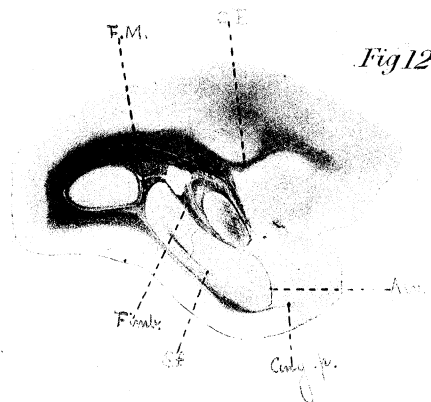
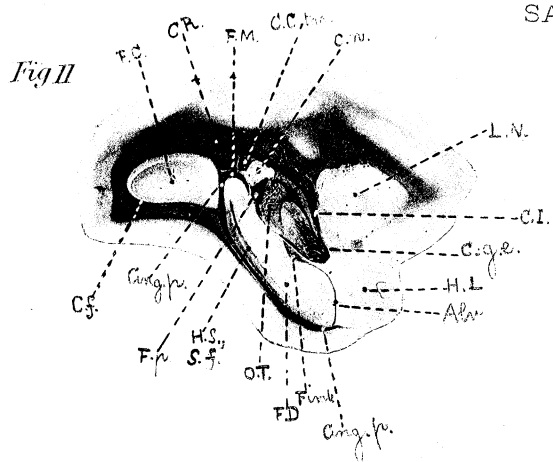


Fig 10



SAGITTAL SECTIONS.



HORIZONTAL SECTIONS.

Fig 13

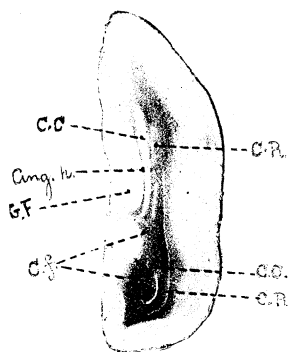


Fig 14

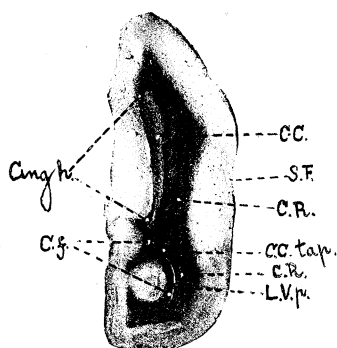


Fig 15

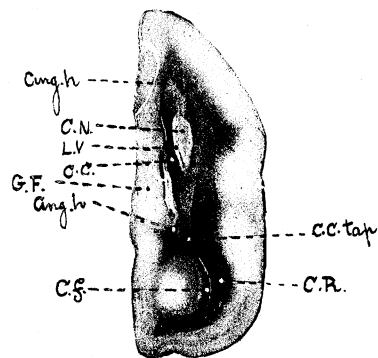


Fig 16

Fig 17

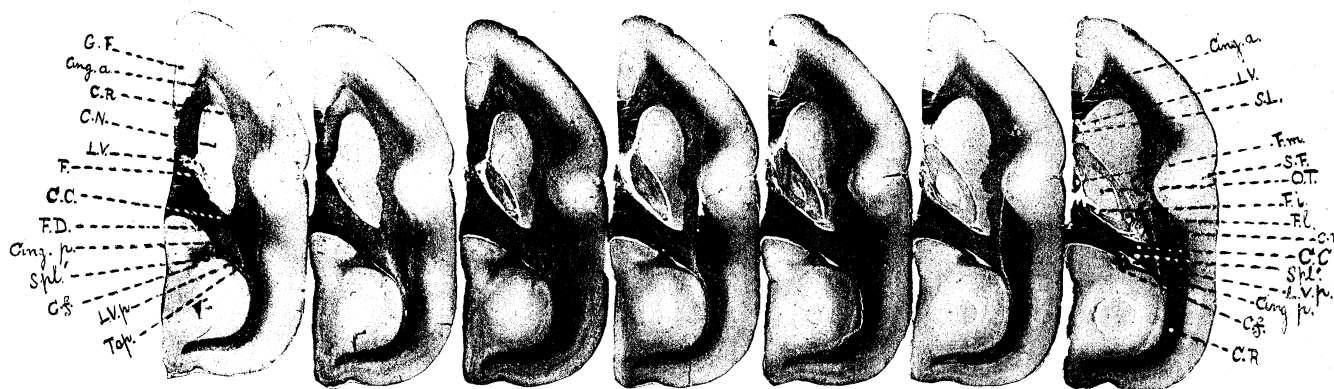Fig 18

Fig 19

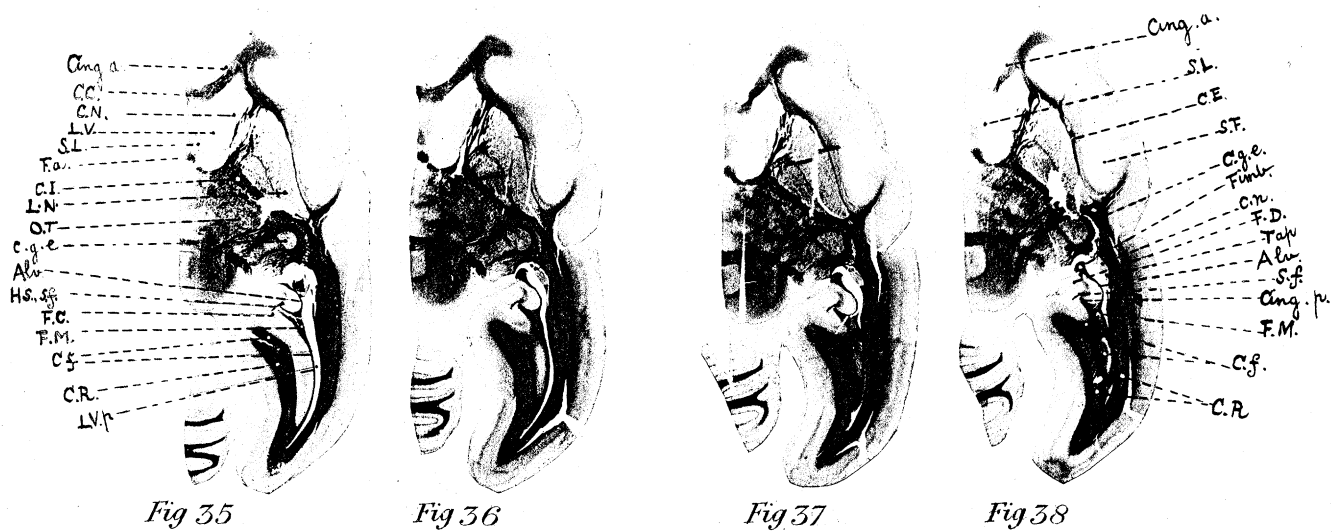
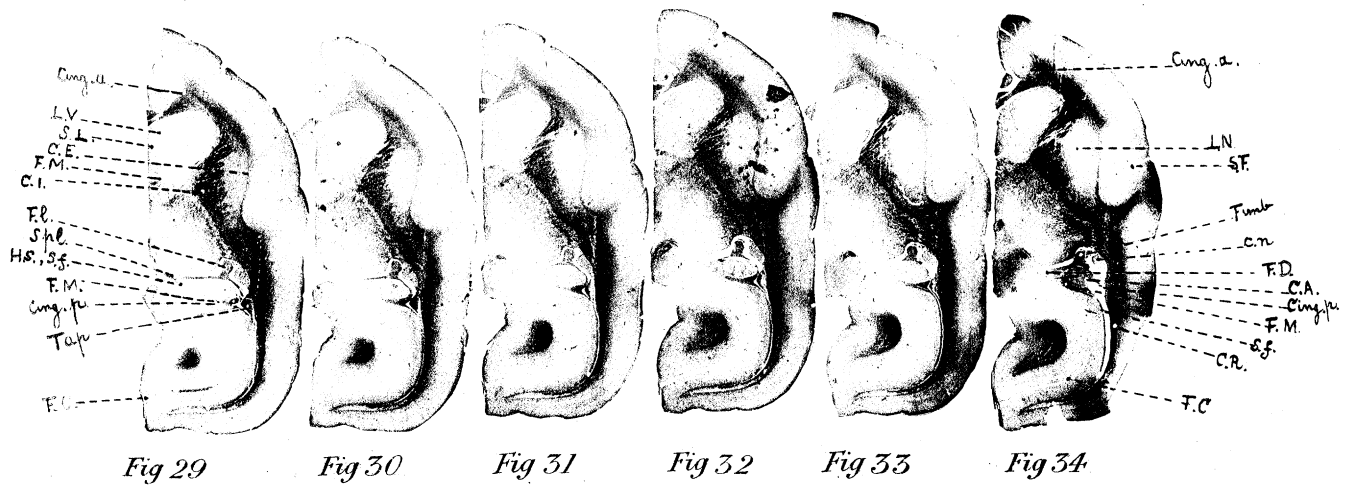
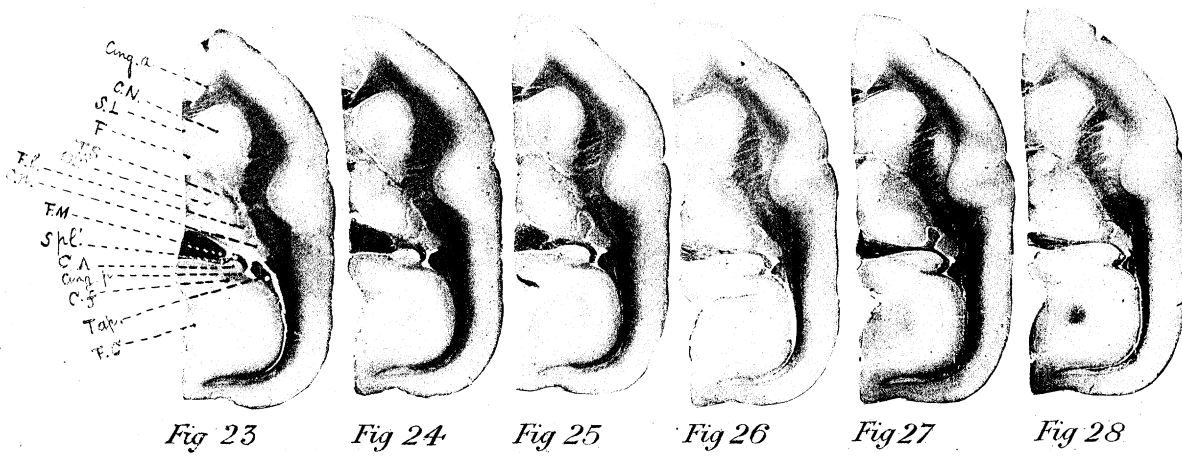
Fig 20

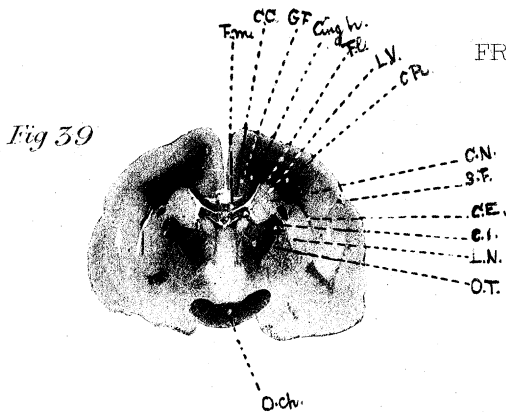
Fig 21

Fig 22

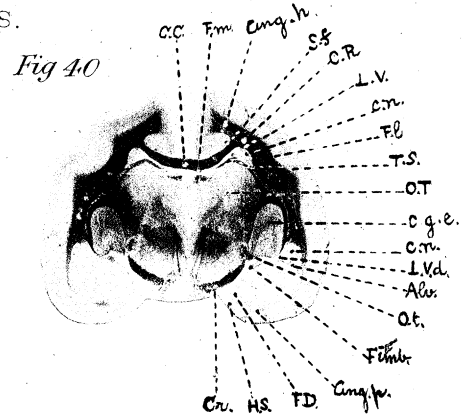


HORIZONTAL SECTIONS.





FRONTAL SECTIONS.



FRONTO-OBLIQUE SECTIONS.

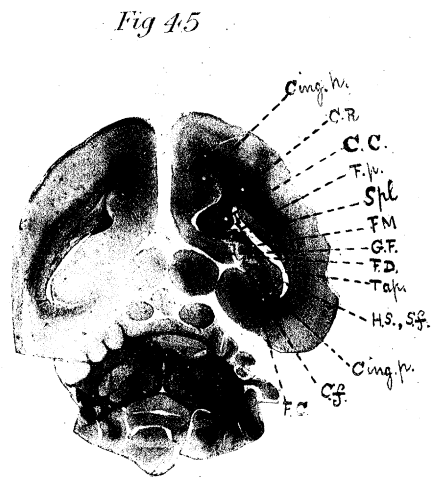
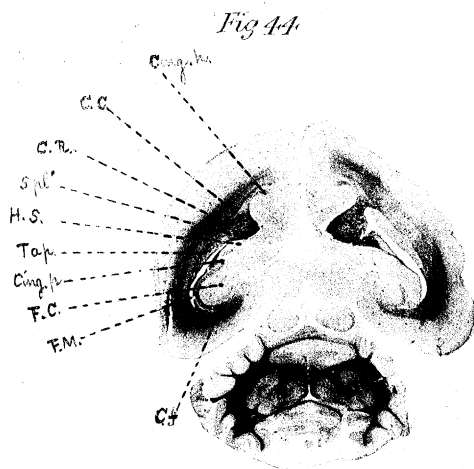
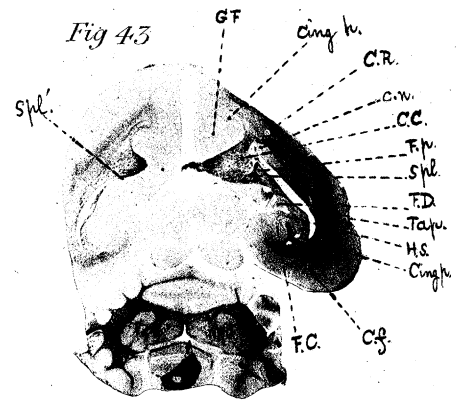
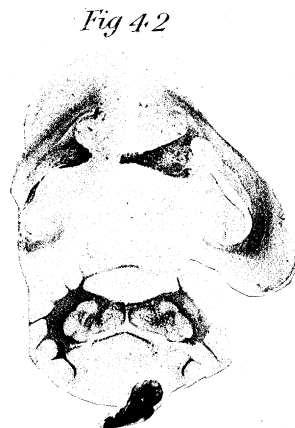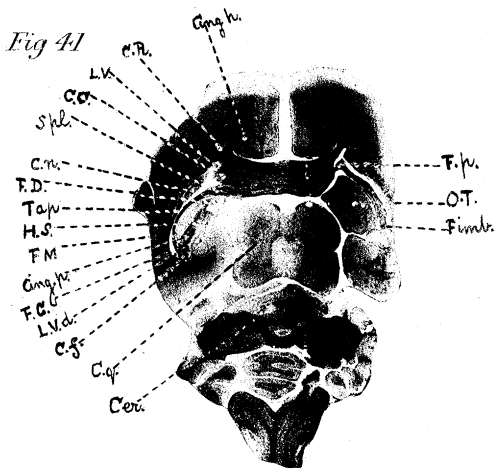


Fig 1

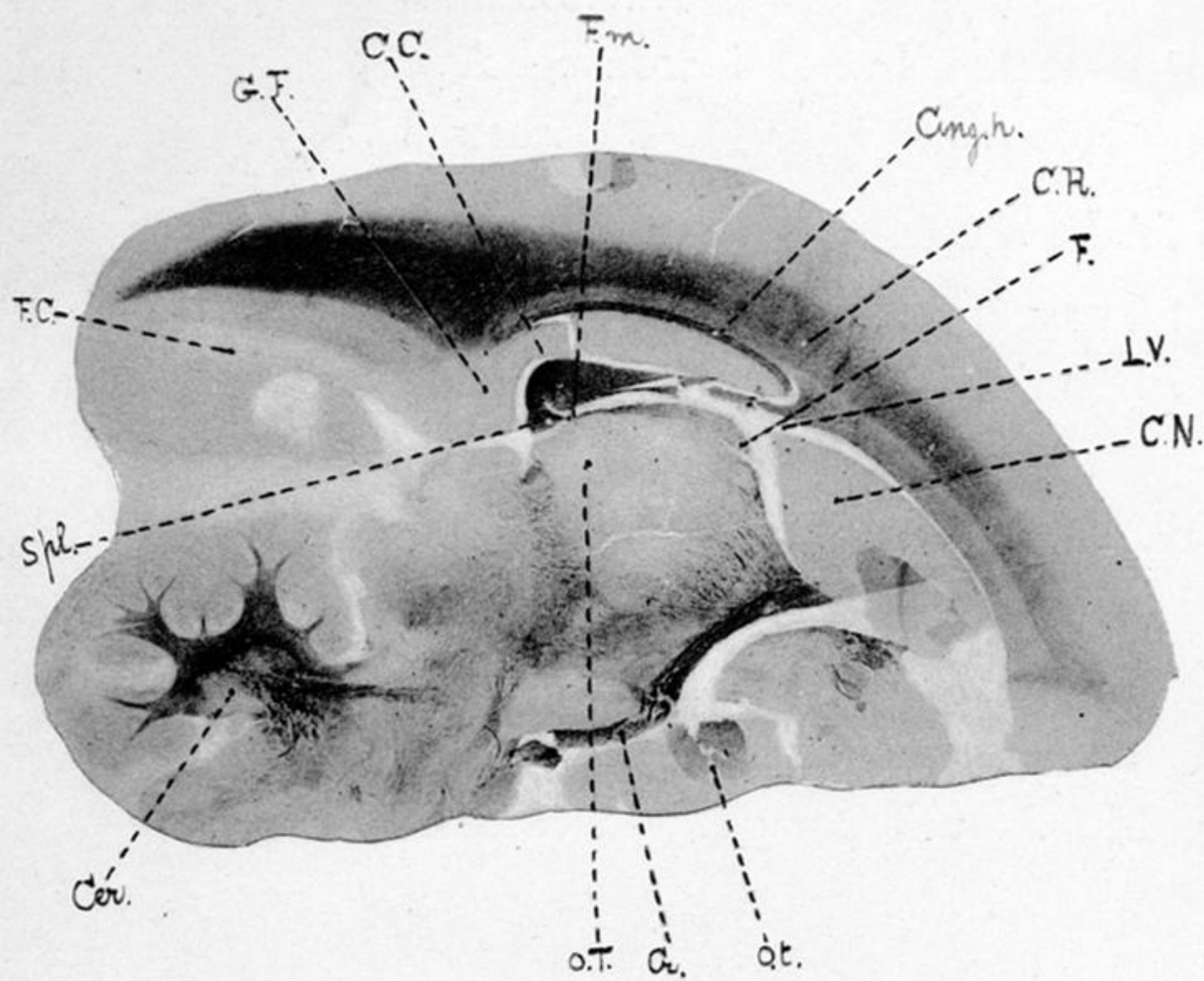


Fig 2

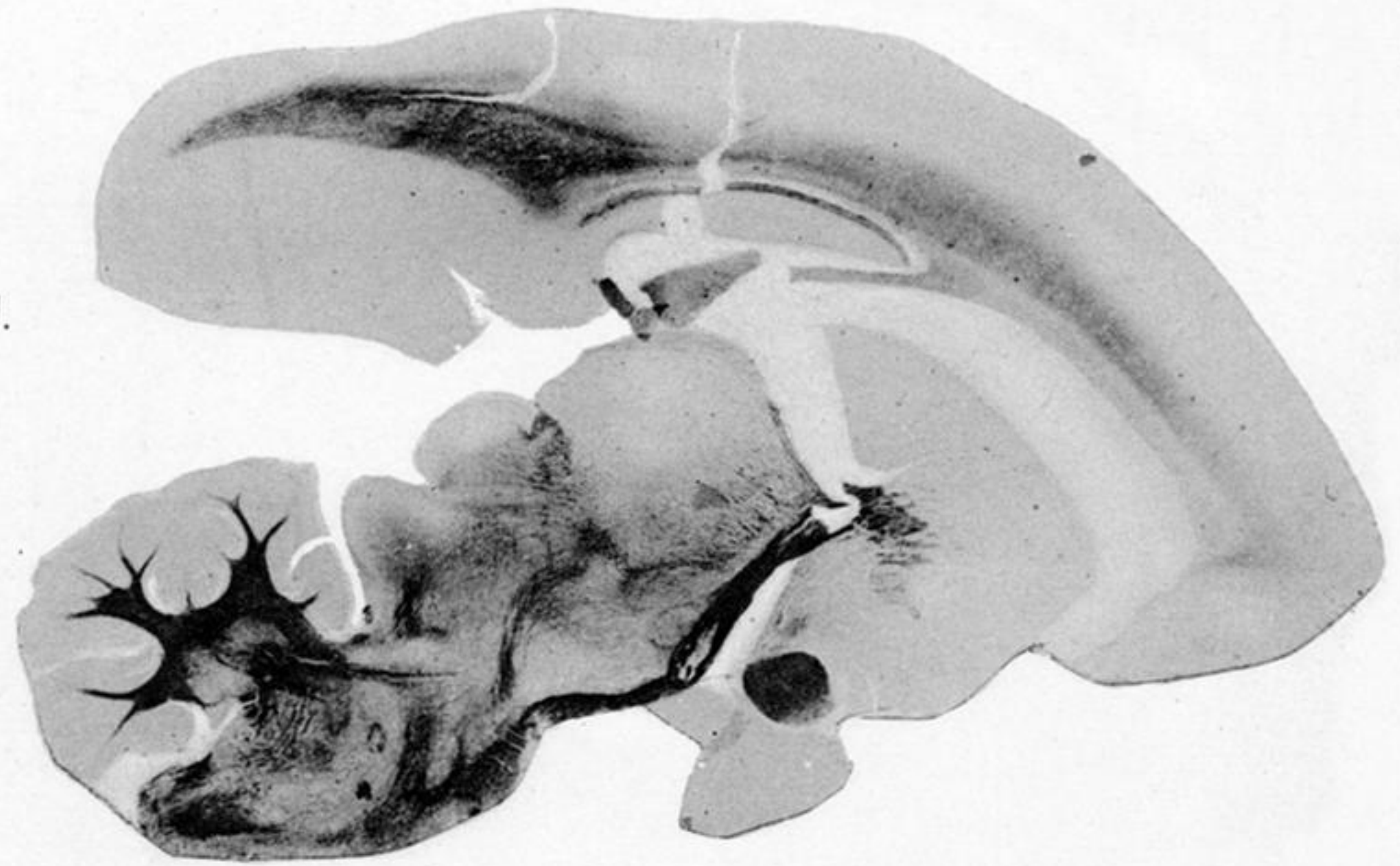

Fig 3

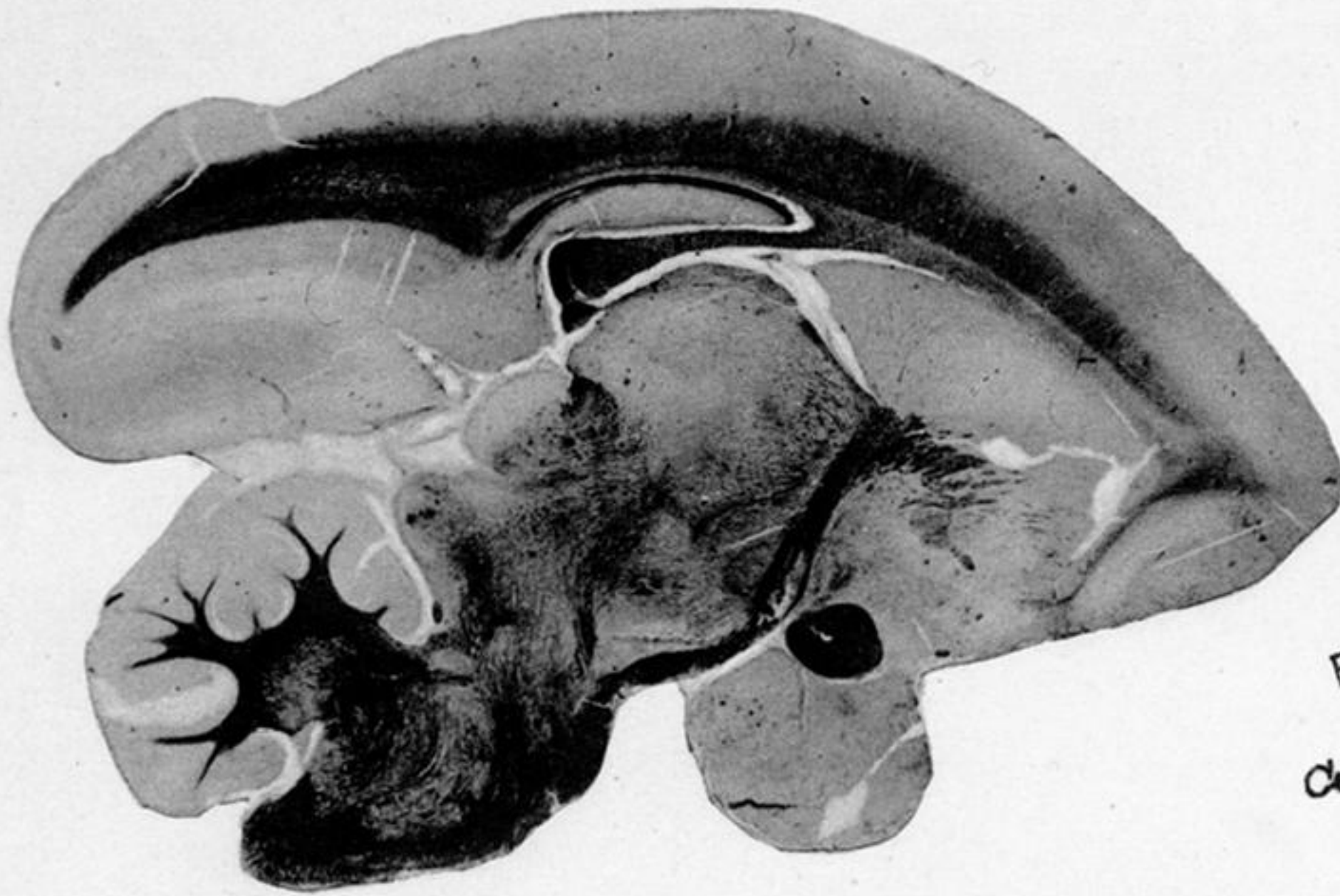


Fig 4

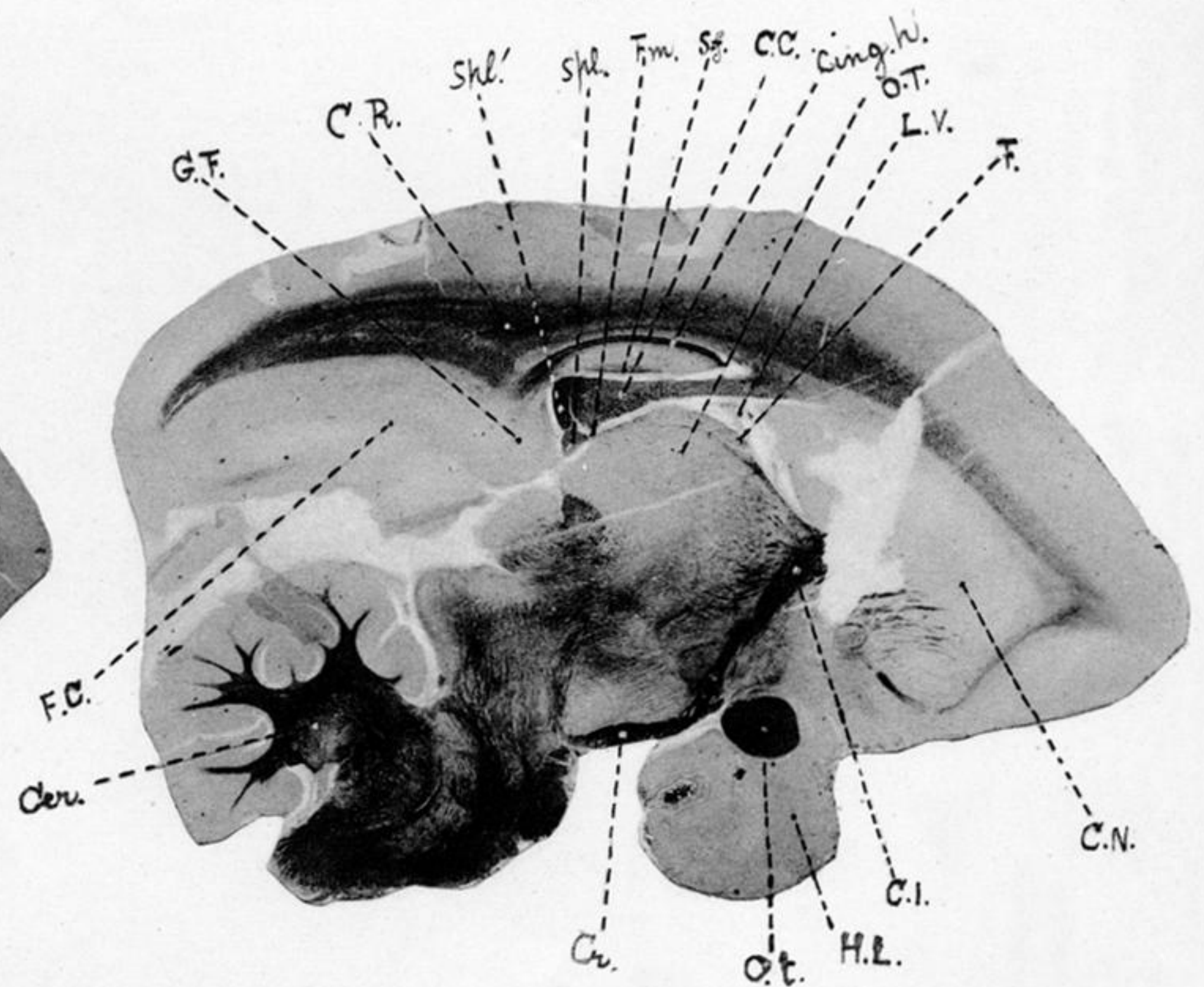


PLATE 20.

Figs. 1-4.—Photographs of microscopic sections of the brain of the Marmoset (*Hapale penicillata*) cut in the sagittal direction and stained by PAL's hæmatoxylin method. The medullated fibres are stained black, and the grey matter is of a grey colour. Fig. 1 is made a short distance from the middle line, and the other sections are external to it. Magnified three diameters.

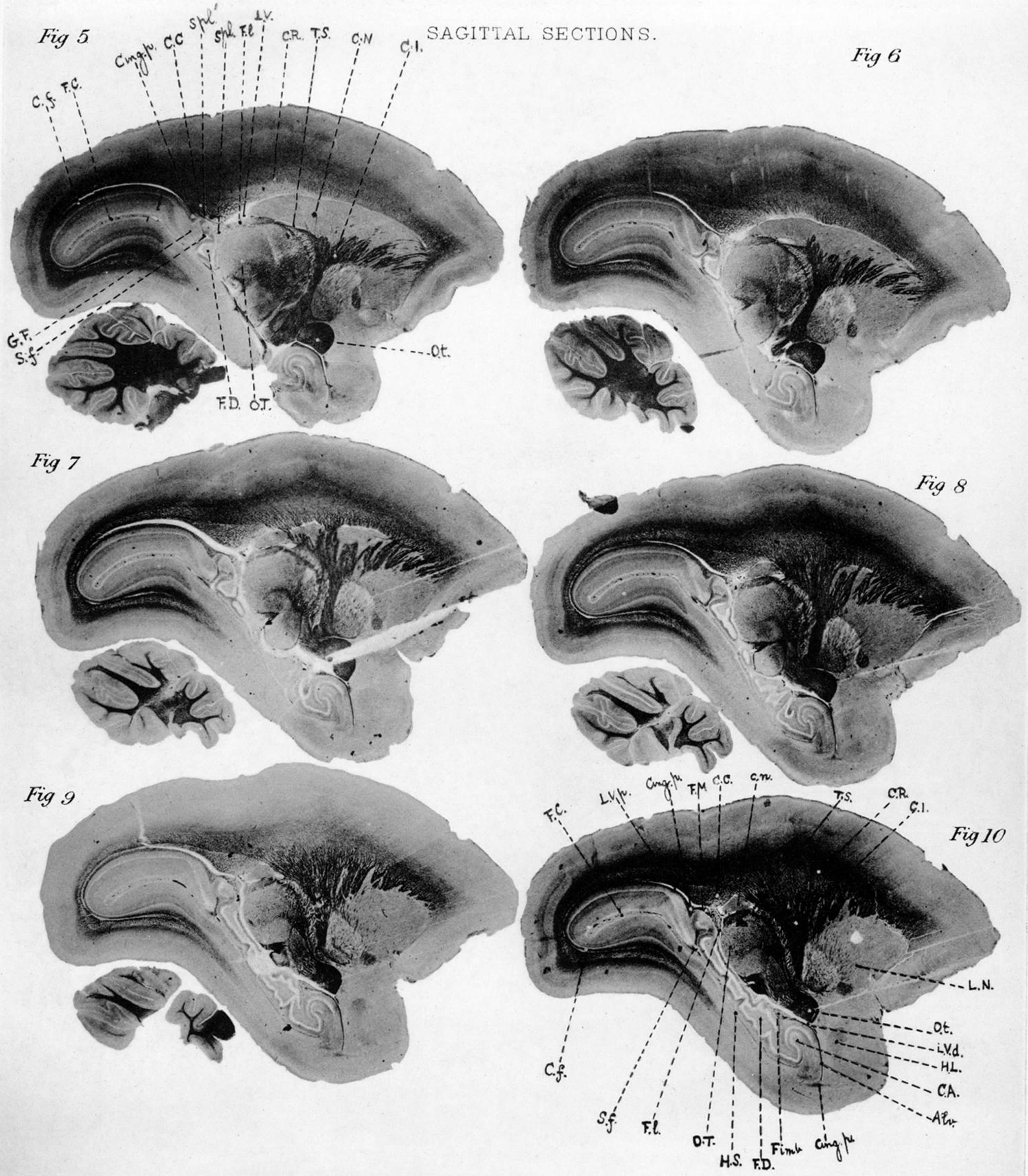


PLATE 21.

Figs 5-10.—Photographs of similar sections of *Hapale penicillata*. Sagittal direction. Stained by WEIGERT'S method. Magnified three diameters.

SAGITTAL SECTIONS.

Fig 11

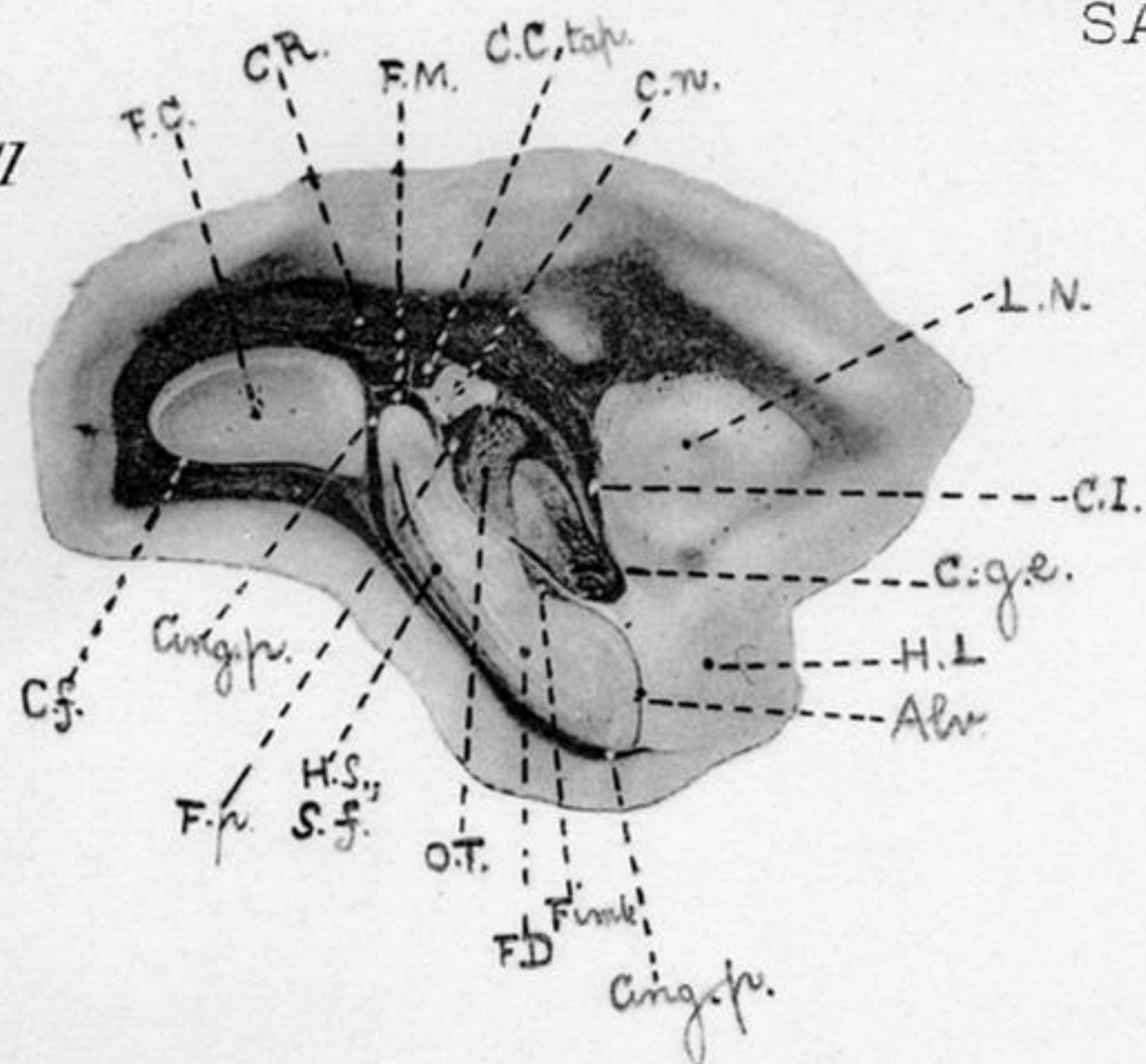
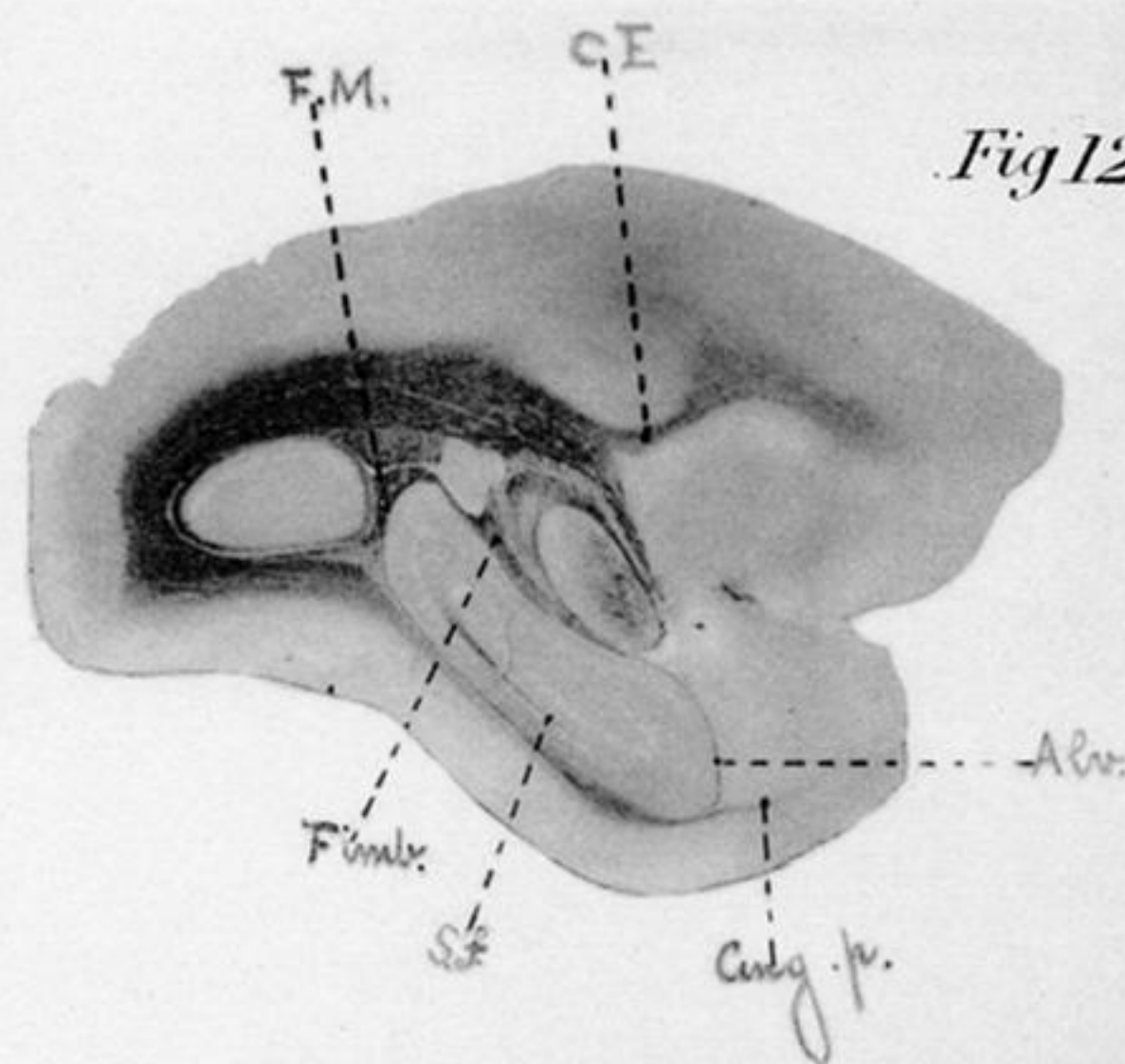


Fig 12



HORIZONTAL SECTIONS.

Fig 13

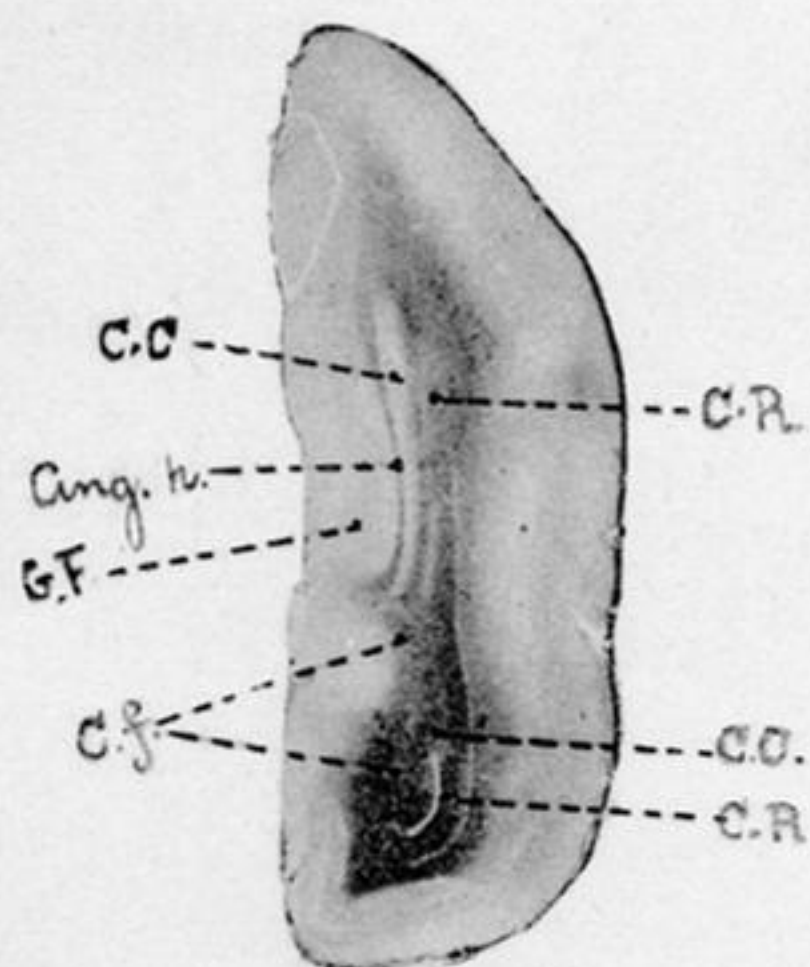


Fig 14

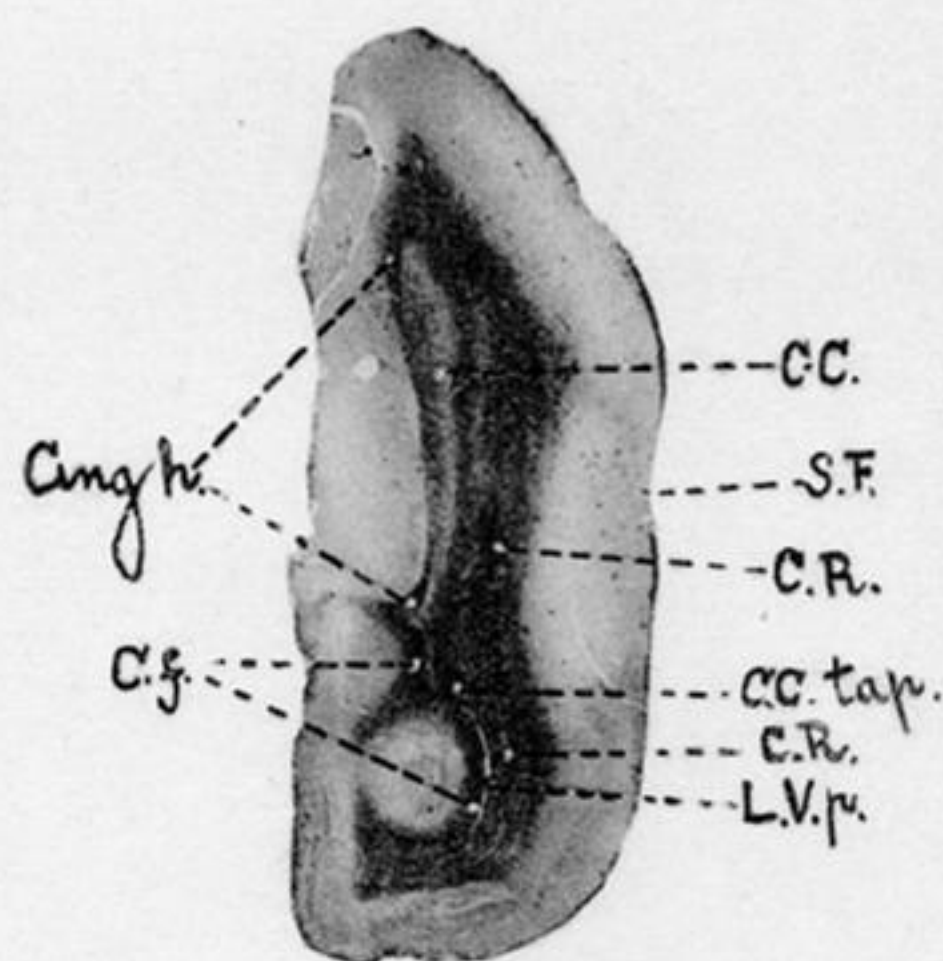


Fig 15

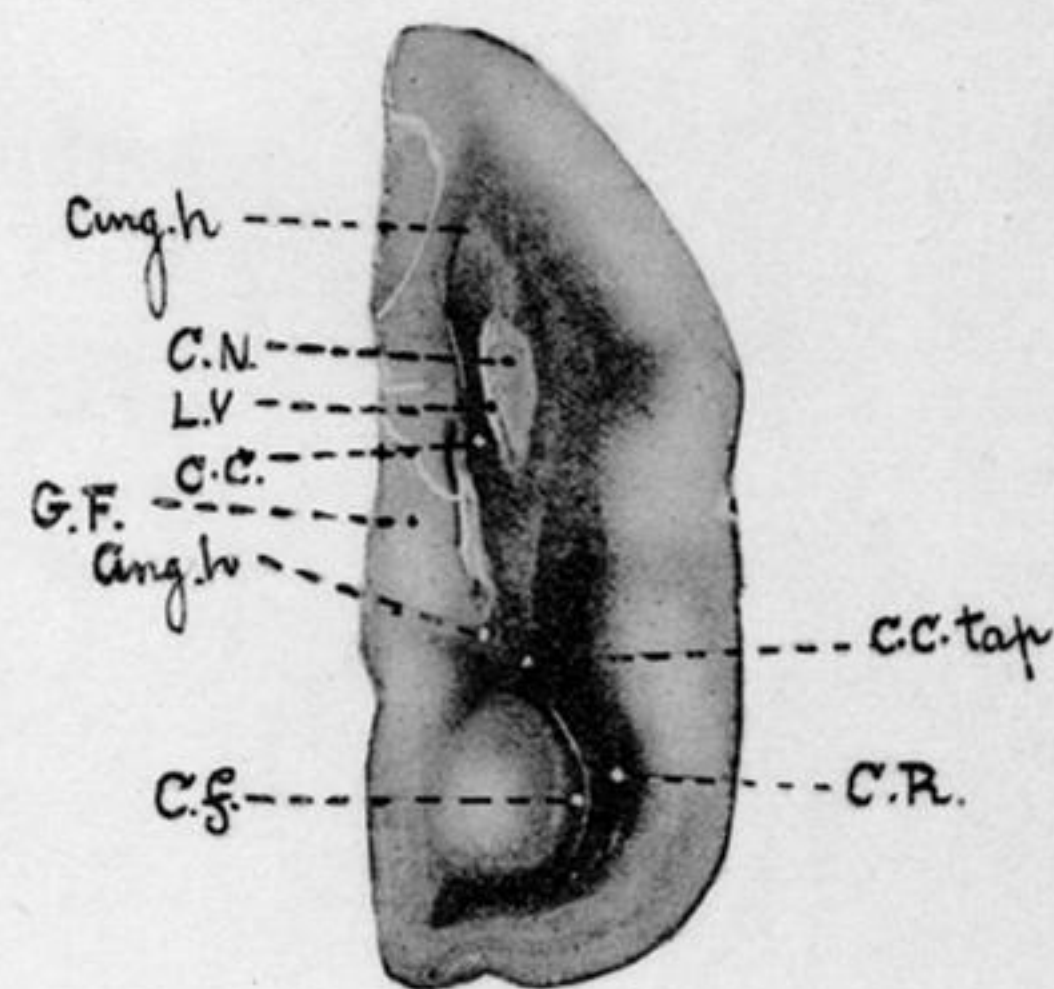


Fig 16

Fig 17

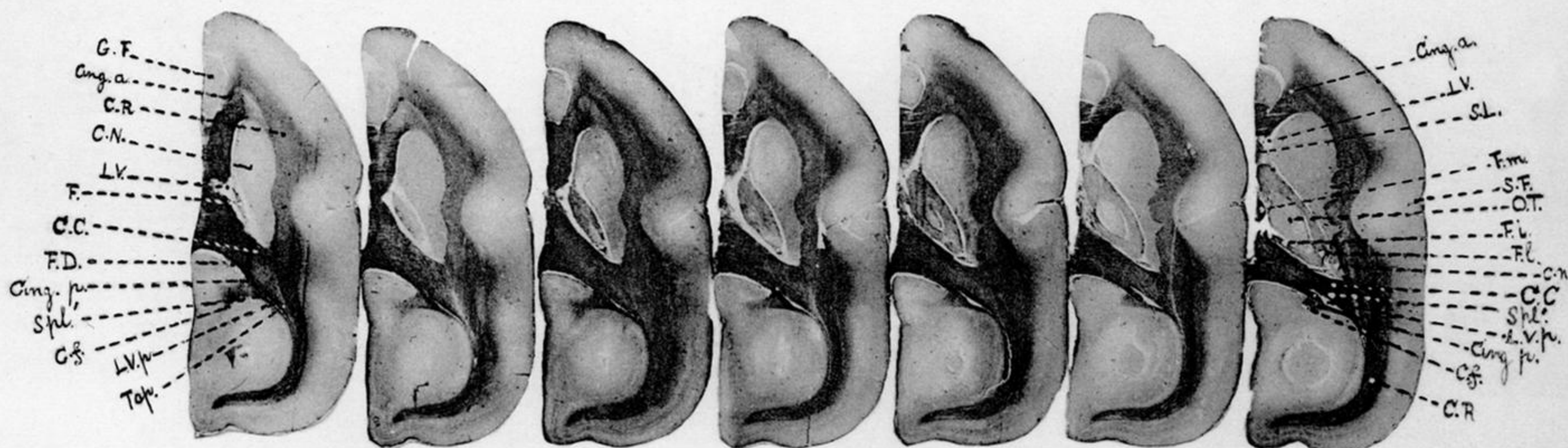
Fig 18

Fig 19

Fig 20

Fig 21

Fig 22



HORIZONTAL SECTIONS.

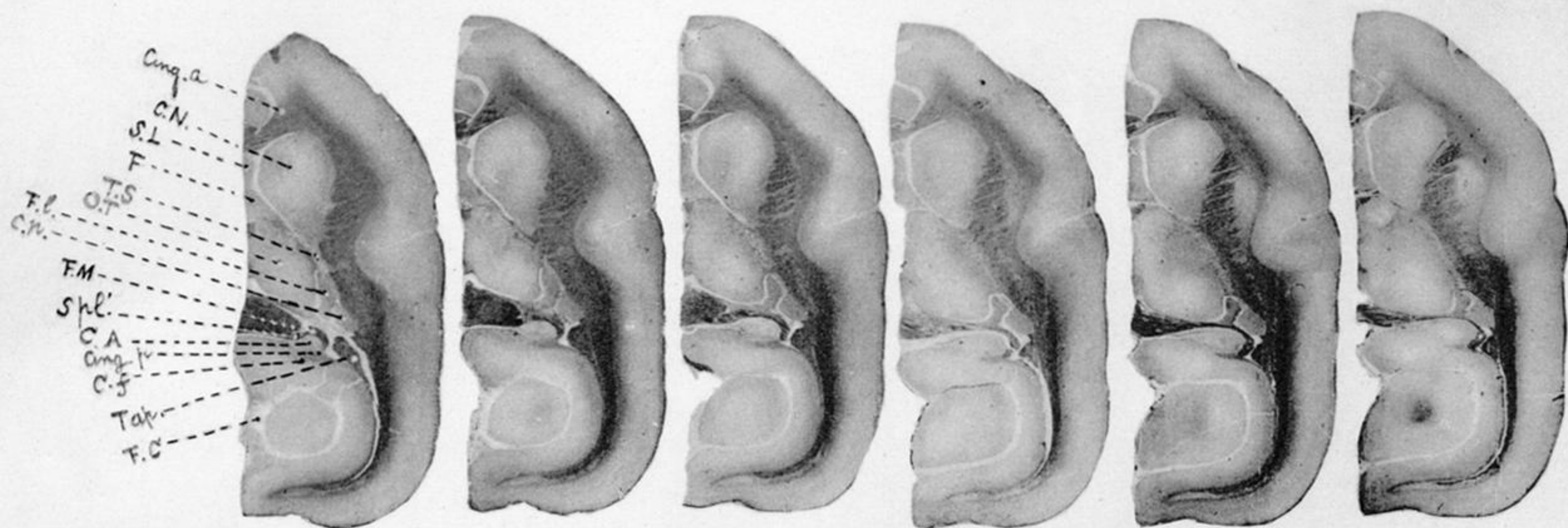


Fig 23

Fig 24

Fig 25

Fig 26

Fig 27

Fig 28

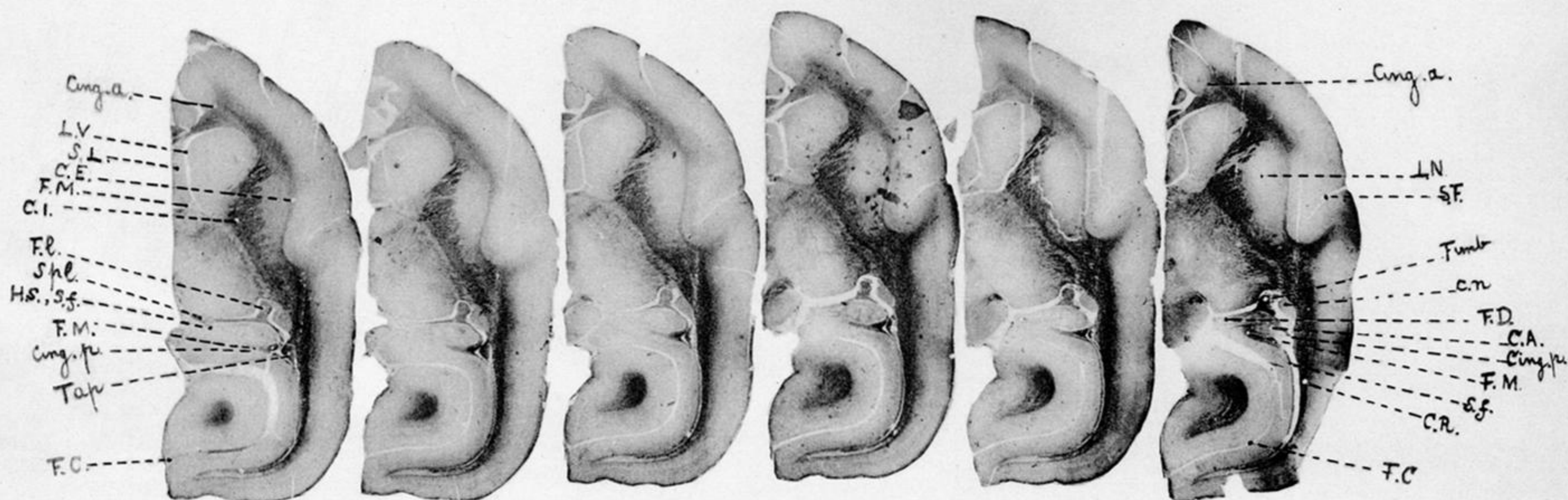


Fig 29

Fig 30

Fig 31

Fig 32

Fig 33

Fig 34

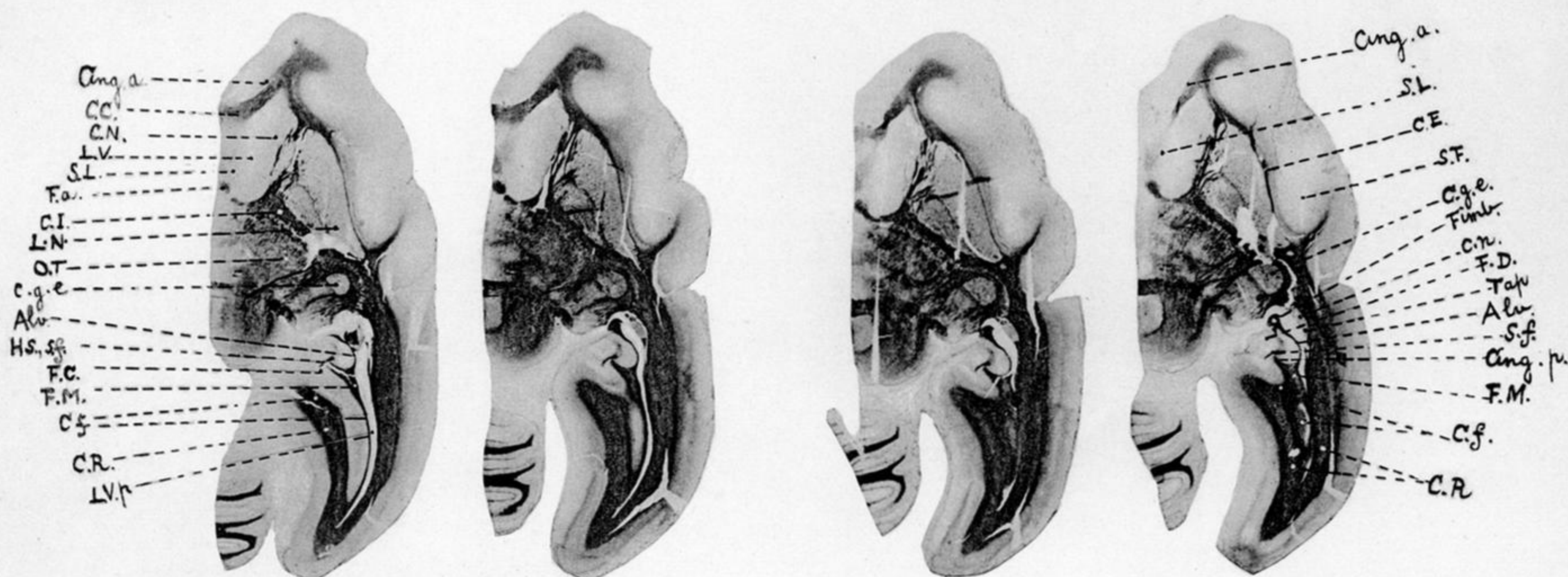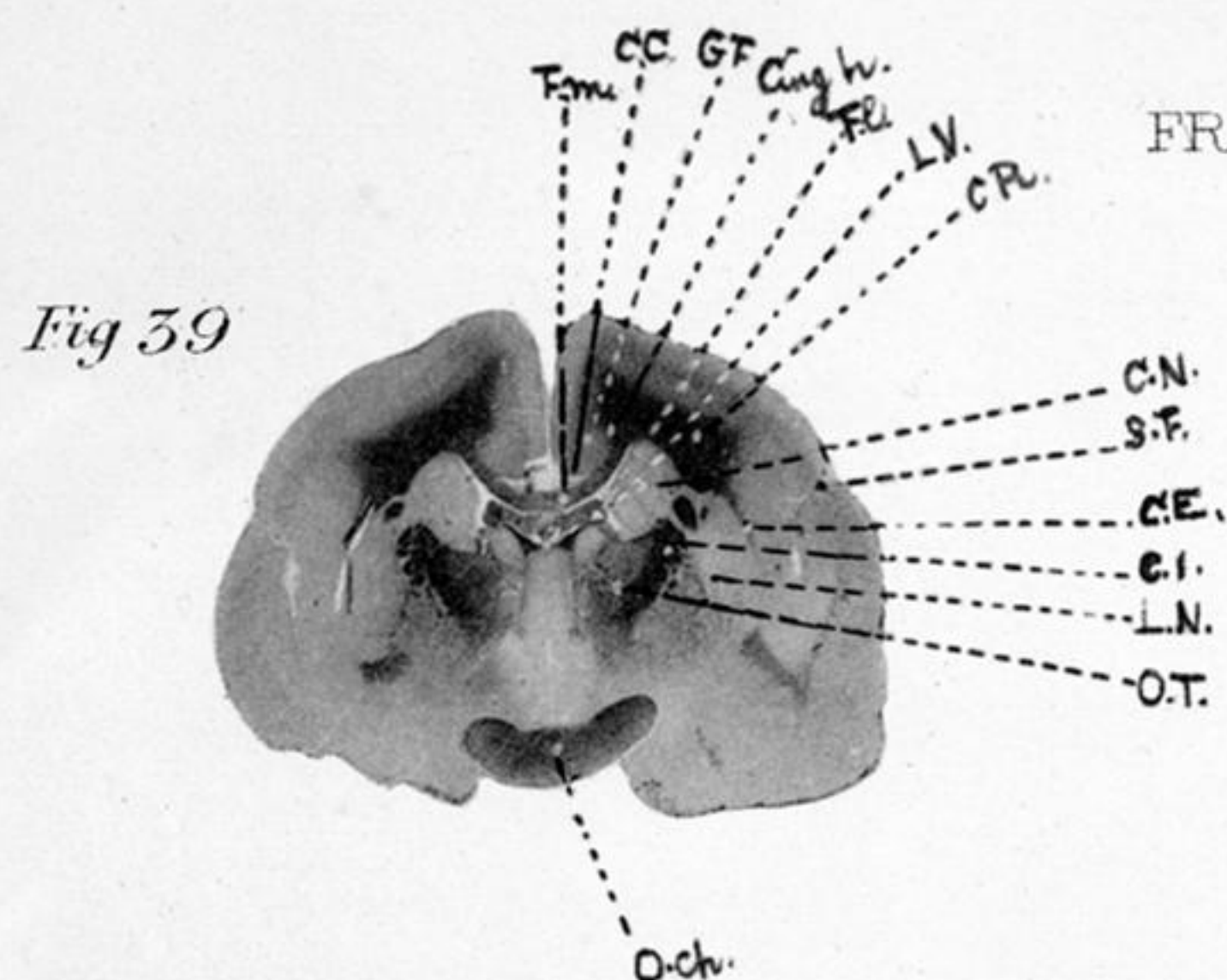


Fig 35

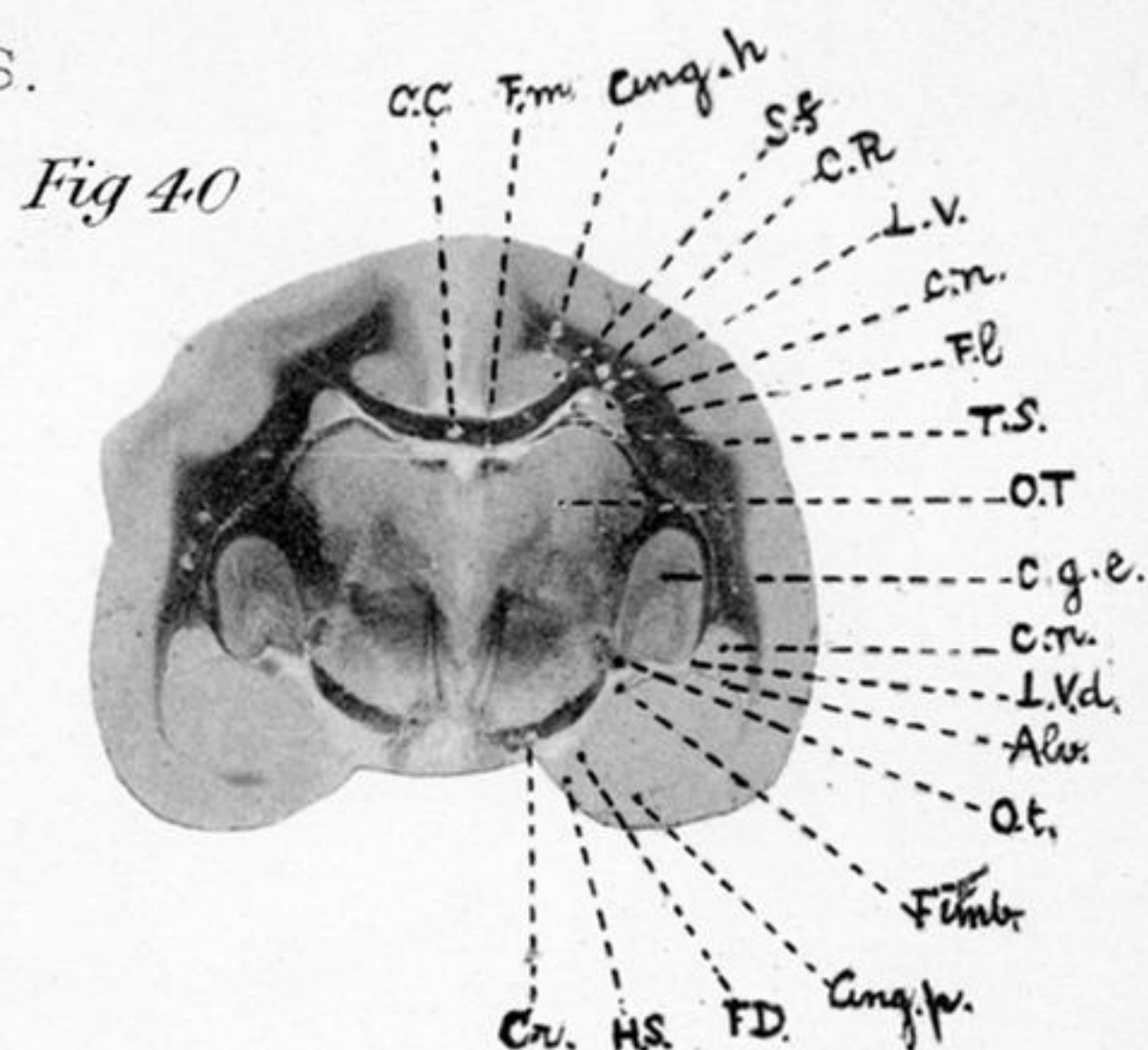
Fig 36

Fig 37

Fig 38



FRONTAL SECTIONS.



FRONTO-OBLIQUE SECTIONS.

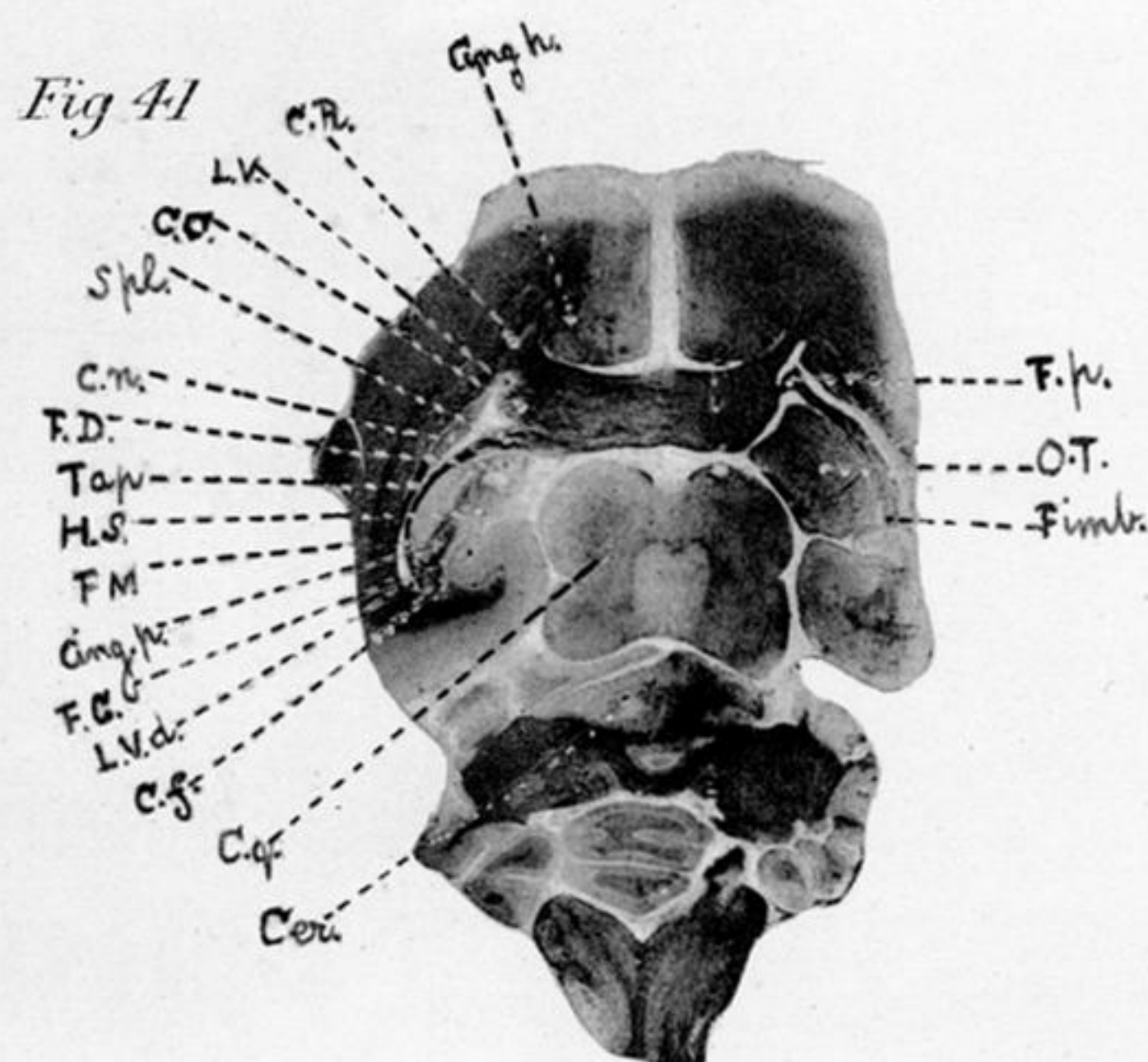


Fig 42

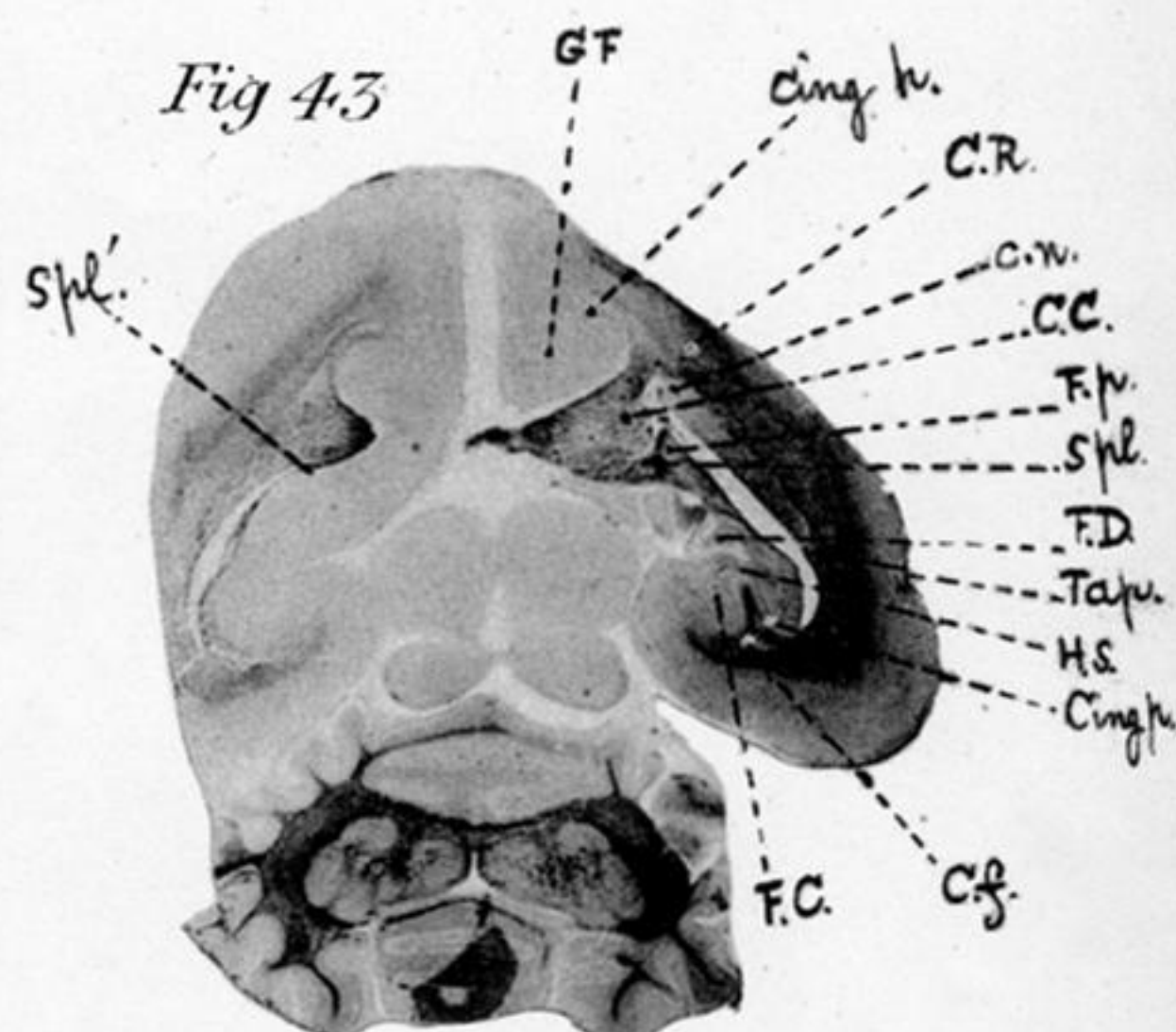
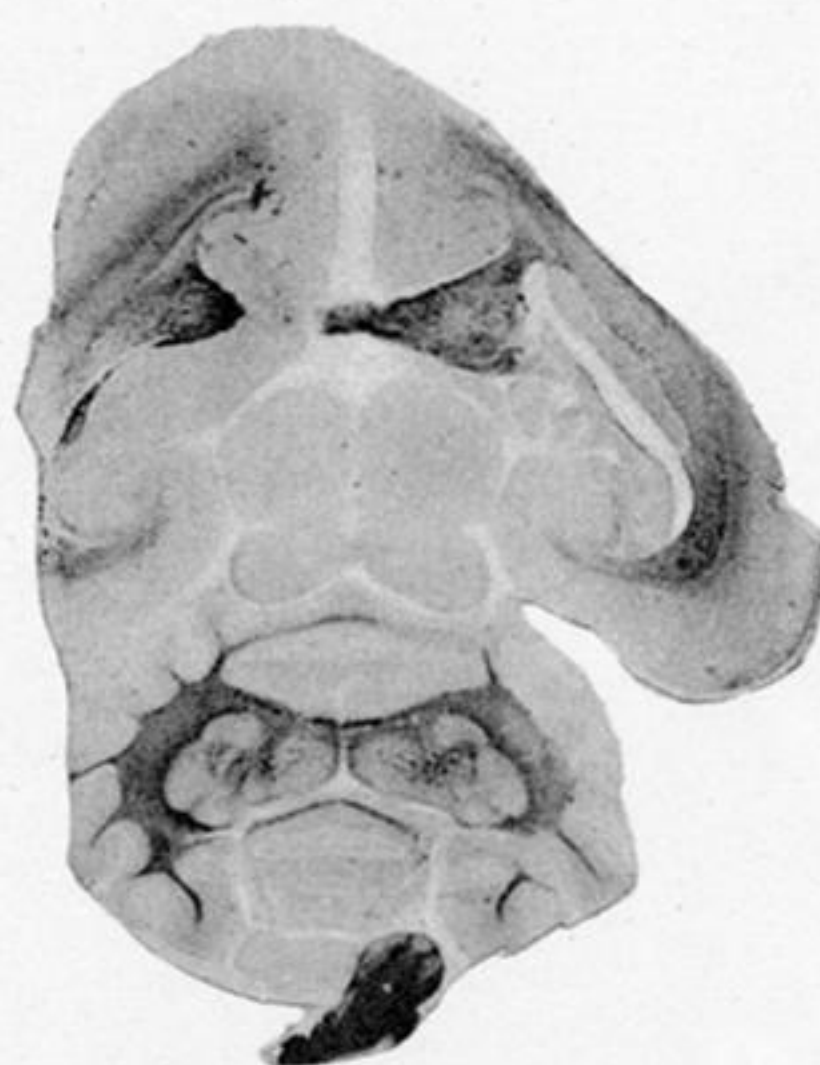

Fig 44

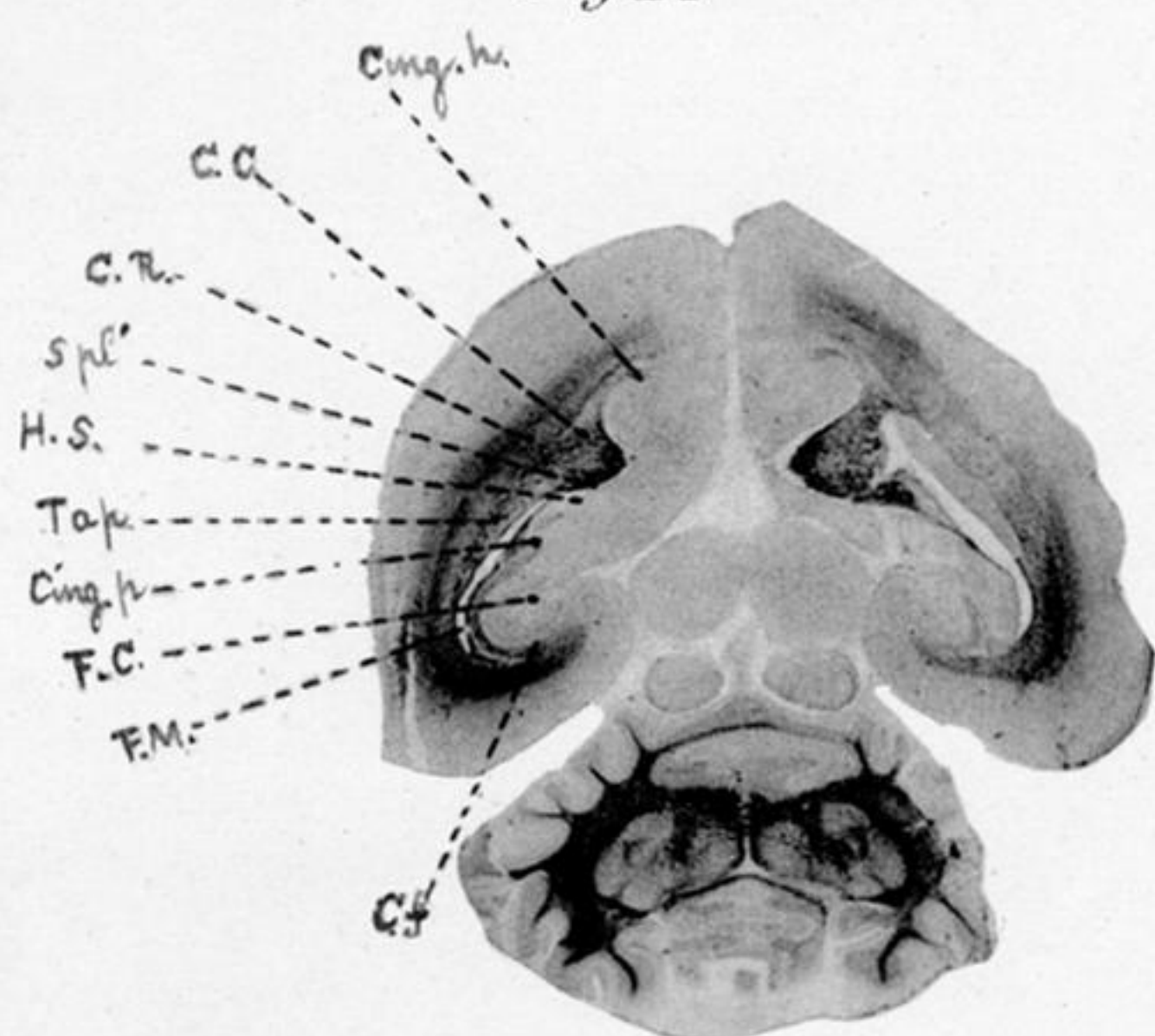


Fig 45

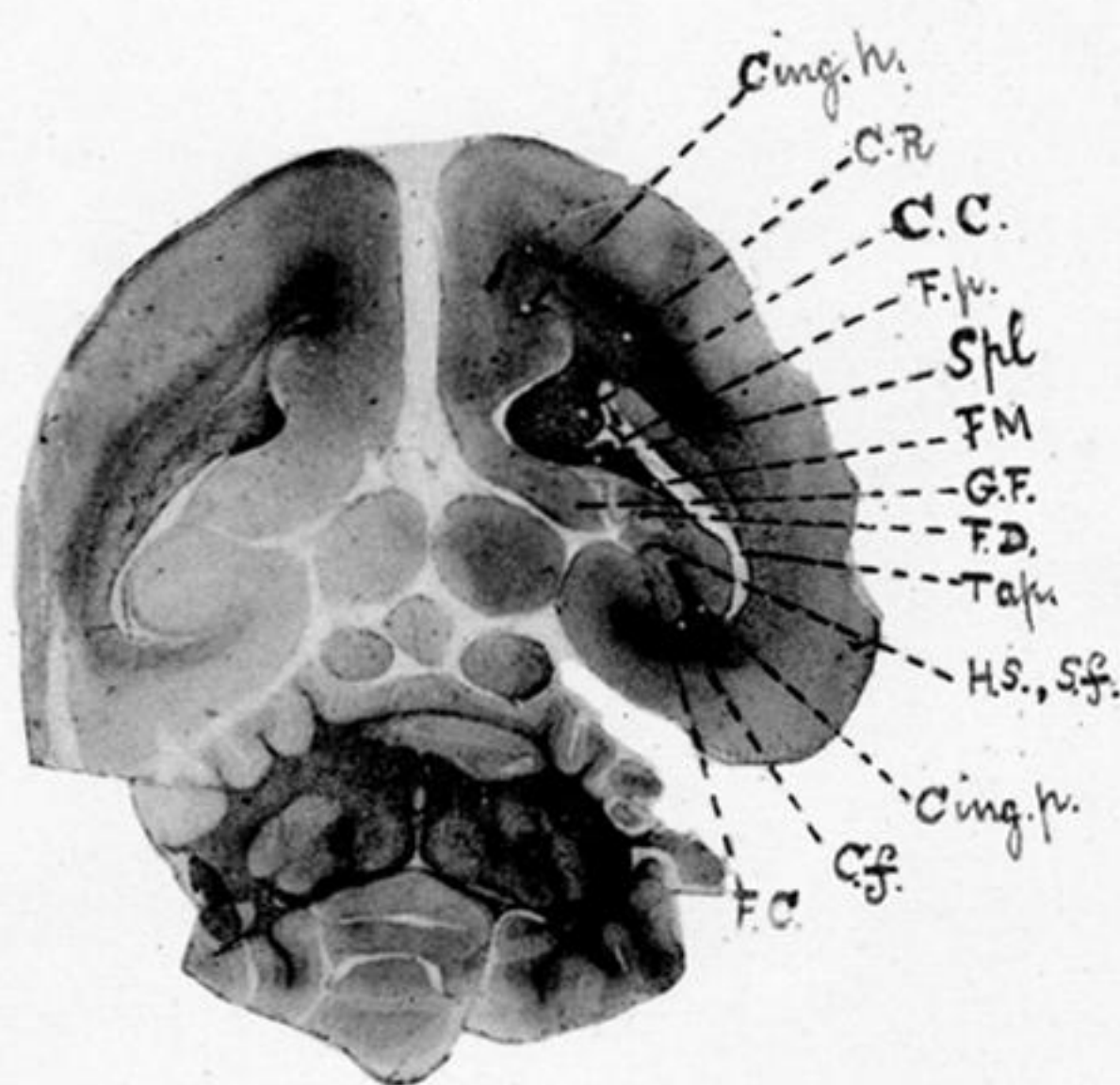


PLATE 24.

Figs. 39 and 40.—Photographs of sections of the brain of *Hapale jactans*. Frontal direction. Stained by WEIGERT's method *in toto*.

Fig. 39 is taken through the optic chiasma; fig. 40 is immediately anterior to the pons Varolii. Magnified two diameters.

PLATE 24.

Figs. 41–45.—Photographs of sections through the corpora quadrigemina of the brain of *Hapale penicillata*. Fronto-oblique direction. Stained by WEIGERT's method. Magnified two diameters.

The two hemispheres are not cut at quite the same level, the right being more anterior than the left, so that the right half of fig. 45 is anterior to the left half of fig. 41, thus giving the appearance of ten levels from before backwards.