

XVI. *A Record of Experiments illustrative of the Symptomatology and Degenerations following Lesions of the Cerebellum and its Peduncles and Related Structures in Monkeys.*

By DAVID FERRIER, M.D., F.R.S., Professor of Neuro-Pathology; and W. ALDREN TURNER, M.D., Demonstrator of Neuro-Pathology, King's College, London.

(From the Neuro-Pathological Laboratory, King's College, London.)

Received November 30,—Read December 14, 1893.

[PLATES 64–71.]

CONTENTS.

	PAGE.
1. Introduction	719
2. Methods of research	720
3. Experiments upon the cerebellum	722
4. Degenerations following complete or partial cerebellar extirpation	735
5. Experiments upon the cerebellar peduncles	744
6. Degenerations following lesions of the peduncles	753
7. Experiments upon the tubercles of the medulla and the consecutive degenerations	755
8. The fillet systems	759
9. The fifth nerve and its connections	763
10. List of references	766
11. Description of the plates	768

INTRODUCTION.

THE series of experiments, which are recorded in this paper, was undertaken for the purpose of ascertaining the effects, temporary or permanent, following total or partial extirpation of the cerebellum and section of its peduncles; and more especially with a view of determining by microscopic examination the position and relations of the secondary degenerations which might be induced. But, before this research had made much progress, the works of LUCIANI (1) and MARCHI (2) on a similar subject had appeared. Until LUCIANI, originally in the "Prima Memoria" [1884], and more recently in his work, "Il Cervelletto" [1891], published the results of his investigations, comparatively few experiments had been recorded on the cerebellum of monkeys. The only previous experiments were those of FERRIER (3) on the electrical excitability

MDCCCXCIV.—B.

4 Z

21.12.94

of the cerebellar cortex, supplemented by a study of the effects of localised lesions. These were few in number, and were confined merely to observation of the temporary phenomena, the animals being killed soon after the operation, so as to obviate the extension from the primary lesion by secondary inflammation. The experiments of LUCIANI, therefore, form, at present, the only basis of facts with which our observations may be strictly compared.*

We do not consider it necessary to refer to the vast literature relating to the effects of lesions of the cerebellum in other animals, which are sufficiently well known to all students of physiology. We therefore limit our references to those of more recent investigators working according to similar methods.

In addition to the experiments on the cerebellum itself, our research has included the effects of section of the cerebellar peduncles, and destruction of the tubercles on the posterior surface of the medulla oblongata, which stand in special relation to the inferior cerebellar peduncles.

In order to accomplish within a reasonable time the primary object of this research—the determination of the degenerations secondary to lesions of the cerebellum and its peduncles—the period of observation of the animals after the operation was limited by the time, at which the phenomena following the lesions appeared to have become stationary.

METHODS.

The research embraced both experimental and histological investigation.

(1.) The subjects of experiment were exclusively monkeys, *Macacus sinicus* and *rhesus*, but occasionally other species were employed.

The operation was in all cases regarded as a surgical procedure, and conducted under strictly antiseptic precautions. The animals were deeply anæsthetised by chloroform. We have preferred to keep the animals deeply under the influence of this anæsthetic, rather than to use preliminary hypodermic injections of morphia and chloral with slight chloroform anæsthesia, as employed by LUCIANI.

The cerebellum was exposed either from behind or from above. If exposed from behind, the occipital bone was trephined below the level of the lateral sinus, the opening being enlarged with the bone-forceps. The lateral sinus was ligatured on the one side, and the dura-mater and tentorium cerebelli divided. By this means, either the lateral or middle lobe, or even the whole organ may be clearly exposed. If exposed from above, the trephine was placed over the occipital lobe and the opening secondarily enlarged. The occipital lobe was tilted upwards, or, when

* While this paper was being written, Dr. R. RUSSELL communicated to the Brit. Med. Association [‘Brit. Med. Journal,’ September 23, 1893, p. 680] a *résumé* of similar researches which he had been prosecuting on dogs and monkeys, but, as they have not been published *in extenso*, we are unable to refer to them in detail.

necessary, the whole or part was removed, the lateral sinus ligatured, and the tentorium cerebelli divided and turned aside. An advantage of the upper over the posterior method is, that the attachments of the muscles of the neck to the occipital bone are left undisturbed.

To divide the superior and middle peduncles, the occipital lobe was removed and the tentorium divided, but it is unnecessary to tie the sinus. By this method, with only slight displacement of the cerebellar folia, these peduncles can be clearly exposed and divided with a cutting-hook. The guide to the superior peduncle is the fourth nerve, which is readily seen crossing its dorsal aspect; while the guide to the middle peduncle is the fifth nerve, which is observed issuing from the lateral aspect of the pons Varolii immediately below it.

The inferior peduncle and the tubercles on the posterior surface of the medulla were exposed by removing the lower portion of the occipital bone and dividing the occipito-atloid ligament, and tilting upwards the inferior margin of the cerebellum.

(2.) The degenerations were investigated by means of the Weigert-Pal hæmatoxylin method, and the osmium-bichromate method of MARCHI (2').

By the latter method, myeline in the process of disintegration, which occurs after a nerve fibre has been severed from its trophic centre, attracts the osmic acid, and, as a result, black spots of degenerated myeline stand out clearly from the more or less yellow stain of the normal tissue. But, as shown by SINGER and MÜNZER (5), OBERSTEINER (6) and SANDMEYER (7), a similar punctated black staining is observed in sections of normal spinal cord treated by this method. With the object of determining the value of MARCHI'S method as a trustworthy means of detecting secondary degenerations, we have subjected the following series of sections of the spinal cord to investigation.

(a) Portions of spinal cord removed from a monkey immediately after death; (b) portions of spinal cord from a monkey which had been dead sixteen hours before *post-mortem* examination was made; (c) portions of the spinal cord of a monkey which showed distinct evidence of secondary degeneration by the Weigert-Pal method.

The conclusions derived from a study of these preparations were: first, that black spots may be found in and around the nerve fibres of the normal cord and of the nerve roots, but to a less extent in the grey than in the white matter; and secondly, that the appearance of nerve fibres after separation from their trophic centres is merely an exaggeration of that which may be seen in normal nerve tissue stained immediately after death, and to a greater extent in that which has undergone some *post-mortem* change.

The mere occurrence of black spots cannot for this reason be regarded as conclusive evidence of secondary degeneration. MURATOFF (4) considers that degeneration cannot be assumed unless, in addition to mere black spots, large bullæ, formed by breaking up of the myeline sheath, are distinctly seen. It is, therefore, desirable that in

determining secondary degeneration, MARCHI's method should be corroborated by the Weigert-Pal or similar methods.

SERIES A. EXPERIMENTS ON THE CEREBELLUM.

(1.) *Extirpation of the whole cerebellum.*

This operation proved of so formidable a nature, that the majority of the animals on which it was performed, either did not recover consciousness or succumbed to shock within a few hours. One animal lived three days, another five days, while a third lived three months after removal of the cerebellum.

Exp. 1. *Macacus rhesus*; female. May 26th, 1893.

The cerebellum was removed in this instance from above by exposing and tilting upwards the left occipital lobe. The left lateral sinus was ligatured and divided, and the tentorium cerebelli incised and drawn aside so as to allow of the whole cerebellum being seen. This was then removed piecemeal by means of the galvano-caustic knife and scoop, in such a manner as to avoid mechanical injury or traction on subjacent or neighbouring parts. The hæmorrhage was only slight. The attachments of the muscles at the back of the neck were by this method not seriously disturbed.

On recovery from the anæsthetic, the knee-jerks were tested and found to be well marked and equal in both limbs; the pupils were equal and of medium size, and there was no distortion of the optic axes or nystagmus.

The animal, when undisturbed, lay prone on the floor with its fore-limbs doubled under it and its chin resting on its hands. There was no curvature of the vertebral column. When it began to move spontaneously, it exhibited a tendency to roll from left to right, and showed marked swaying and oscillation of the body and limbs.

On the following day, the monkey was still prostrate and was unable to stand or sit up except by holding on to some support; and in attempting to move it sprawled with its belly in contact with the floor, and arms and legs far apart. The grasping power was forcible and it laid firm hold of objects both by its hands and feet. Owing to the great unsteadiness of its movements, it could not feed itself and, therefore, required to be fed artificially. It was evidently aware of, and could localise, the slightest touch in any part of its body. Deglutition, micturition and defecation were quite normal, as were also respiration and temperature.

On the third day, the inability to stand or sit up still continued, and the animal speedily desisted from efforts to do so and remained prone on the ground. The oscillation of the head, trunk and limbs continued so great that it was still necessary to feed it artificially. Notwithstanding the extraordinary instability, objects placed in the palms or feet were grasped with great energy, and apparently as strongly as by a normal animal.

On the fourth day, the animal was lively and vigorous, and exhibited its usual wild temper when interfered with. It maintained the same prone position as previously described; namely, resting with its belly on the floor, its shoulders and thighs abducted, its knees and elbows flexed, and its hands and feet planted far apart, so as to form a wide basis of support. From this position it appeared unwilling to move spontaneously, and offered considerable resistance to any attempt to displace it. The grasp of the hands and feet was firm and forcible; but when the animal attempted to take a piece of fruit offered it, which it did with either hand, the unsteadiness of aim was so great that it had the utmost difficulty in seizing it. When placed near the leg of a chair or table, it was able to cling to it and support itself in a sitting posture for a short time, but this apparently was so uncomfortable that it soon assumed the usual prone position. The general health was good, the pulse, respiration and temperature normal; the knee-jerks were readily obtained; tactile sensibility, vision and hearing were to all the usual tests unimpaired.

On the fifth day, it was able to feed itself out of the dish placed before it, though with considerable difficulty, owing to the oscillation of its head and trunk. When offered a piece of apple it readily attempted to seize it, but the movements of the arms were so wild and irregular that it only succeeded after many fruitless efforts. It now exhibited greater spontaneous movement; it crawled slowly along the floor with the limbs wide apart; it occasionally attempted to sit up, but was unable to do so owing to its general unsteadiness. When near an object of support, such as the leg of a chair or table, it would sit up holding on firmly, its head and trunk swaying greatly.

At the end of the week the monkey showed greater tendency to move about spontaneously, but still in the same sprawling fashion, falling over when without support, but when in a corner, or clinging firmly to the leg of a chair, able to maintain its balance in a very unsteady manner. Any attempt to lay hold of food offered it gave rise to marked unsteadiness of its limbs and trunk, similar to the most pronounced oscillations seen in disseminated sclerosis in man. Apart from muscular effort, the oscillations entirely subsided. Hitherto no fine tremors had been noticed, but they were observed by the tenth day. These tremors were visible in conditions involving general muscular strain, but they passed into oscillations of larger amplitude on any definite volitional effort.

At the end of the third week, though unable to sit up without support, the animal had considerably improved in its powers of locomotion. It no longer crawled on its abdominal surface, but sprawled with its limbs wide apart so as to broaden its basis of support. When perfectly at rest there were no tremors, but on the slightest general effort, the tremors started in the arms, legs, trunk, and head:—the tremors of the head and neck being much more constant than those of the body and limbs. These tremors had, for a few days past, somewhat diminished in intensity. The general health remained good; the monkey was bright and intelligent; its organic functions were normal and the knee-jerks were active.

At the end of five weeks, a slight deviation of the head was observed, which had not before been noticed; viz., an inclination of the occiput to the right, the chin pointing to the left shoulder. The animal had the same sprawling gait and inability to sit upright without support, but was able to climb a rope or the lattice-work of the cage hand-over-hand with great agility exactly like a normal monkey. The tremors and oscillations, which had previously been so pronounced, now showed distinct signs of diminution.

At the end of the second month the gait was still sprawling. If at all excited or hurried, it fell over to the right side and backwards. It sat up without support, but this was accompanied by a gentle swaying of the body. The general health was good; the monkey was active and intelligent; the knee-jerks were distinctly and equally exaggerated, but there was no rigidity of the limbs.

Towards the end of the third month, the symptoms had apparently become stationary. The tremors of the head and trunk had largely disappeared, but the unsteadiness of the disseminated sclerosis type on volitional effort remained as before. About this time the monkey, having been deprived of its former companions, became dull and apathetic, and lost appetite; its general nutrition became impaired, and on the surface of the abdomen on which it usually rested, some patches of an eczematous nature were seen. It improved somewhat when another companion was obtained, but never regained its former vivacity, and gradually failed and died on August 12th, 1893.

Autopsy.—The *post-mortem* examination showed that the whole of the cerebellum had been removed with the exception of the stumps of the flocculi on either side, and a small portion of the grey-matter of the inferior vermiciform process roofing over a part of the fourth ventricle (Plate 64, fig. 4). The corpora quadrigemina and calamus scriptorius were fully exposed. The medulla and pons presented a shrunken appearance. With the exception of the left occipital lobe, which was slightly adherent to the dura-mater, the remainder of the brain was quite intact. Subsequent microscopic examination showed that the stump of the cerebellum, which consisted merely of a small portion of the grey-matter of the inferior vermiciform process and adjoining white matter of the roof of the ventricle, was composed chiefly of degenerated and cicatricial tissue. This examination also revealed that the superior medullary velum, or valve of VIEUSSENS, had been wounded on the left side. (For description of the degenerations, see p. 735 *et seq.*, Photograph, Plate 71, fig. 1).

Exp. 2. *Macacus sinicus*; male. May 31st, 1892.

In this instance the cerebellum was removed from behind by trephining the left occipital bone and detaching the muscular attachments on the left side from the superior curved line. The left lateral sinus was ligatured and divided.

Immediately after the operation the animal assumed any position in which it was

placed, lying upon its side, back, or belly. It rolled indifferently to either side, sometimes right round upon its axis.

On the second day it was well and active. When placed on the floor it lay on its belly with the limbs folded below it. On endeavouring to move, there was great awkwardness and swaying of the body, rolling to one or other side, and sometimes right round. It was unable to sit up without holding on to an object for support. As in the previous case, it progressed with its belly in contact with the floor, its arms and legs sprawling and planted far apart. It was, however, able to climb well hand-over-hand, but this was accompanied by much swaying of the body.

On the third day, a careful examination showed that, according to the usual tests, cutaneous sensibility was unimpaired. It appeared to hear and see distinctly on both sides. The knee-jerks were readily obtained. The grasp of the hands and feet was strong and forcible. The head was retracted, the chin being deviated towards the the right shoulder.

On the fourth day the animal, which hitherto had been progressing favourably, was found to be weak, and on the following day it died.

Autopsy.—The cerebellum was found to have been almost completely removed (see Plate 71, fig. 2). The corpora quadrigemina and calamus scriptorius had been clearly exposed. Roofing in the fourth ventricle was a fragment of the inferior vermiform process, and on either side there remained the stump of the flocculus with a remnant of its cortex. The brain was otherwise quite intact.

Exp. 3. In another case, *Macacus sinicus*, female, March 25th, 1893, which only lived three days after the operation, essentially the same primary phenomena were observed as in Exp. 2; viz., tumultuous disorders of equilibration, a tendency to fall indifferently to either side, swaying of the body, and sprawling gait. The muscular strength was strong, the grasp of the hands and feet being vigorous and well sustained. There was no loss of sensibility, and the knee-jerks were readily obtained and equal. In this case the cerebellum was almost completely extirpated, the only remnant being a rudiment of the right flocculus and a fragment of the posterior part of the inferior vermiform process.

Remarks.—The symptoms observed in these three monkeys correspond in essentials with those described by LUCIANI in the case of two monkeys in which he had almost completely removed the cerebellum, one of which lived one month, the other eighteen months after the operation.

The most noteworthy features in our cases are the extraordinary disturbances of station and locomotion, and the long-continued, and apparently persistent, unsteadiness of the trunk and limbs on muscular effort. We would, however, note the absence from the first of tonic flexion or contracture of the fore-limbs; the absence of any

marked distortion of the optic axes or nystagmus; the retention of great and apparently unimpaired muscular strength, as evidenced by the firmness of grasp of the hands and feet, and the agility in climbing; the presence, and ultimate increase, of the muscular tone, as indicated by the existence from the first, and subsequent exaggeration, of the knee-jerks (in Exp. 1).

We would further note the absence of any impairment of the general or special sensibility, or disturbance of the organic functions. We would look upon the slight general impairment of nutrition, and the local eczematous affection, as dependent merely upon the enforced position and the hygienic conditions under which the animal lived.

The tilting of the chin to the right in one case, and to the left in the other, we consider might be due to the unequal disturbance of the muscular attachments.

(2.) *Removal of the Lateral Lobe.*

This specially refers to the extirpation of the *left* lateral lobe, the middle lobe being left intact.

Exp. 4. *Macacus rhesus*; female. April 15th, 1891.

The left lateral lobe of the cerebellum was exposed by trephining over the occipital bone, ligaturing and dividing the left lateral sinus, and the lobe removed piecemeal by means of the galvano-cautery and scoop.

After the operation the animal was prostrate, so that the examination of its condition was not made until the following day, when it was found to be very unsteady, and frequently fell, generally to the right and backwards, but occasionally to the left. It exhibited no complete rotation to either side. In moving from one place to another it sprawled on the floor with its limbs wide apart, and it always made for some object of support, to which it clung tenaciously. Its motor power was good, for it was able to climb with ease, and with a normal use of all four limbs. Both knee-jerks were readily obtained, but the right was scarcely so well-marked as the left.

On the third day the monkey was lively and active, and the general health was good. Common sensibility, and the special senses, were unimpaired, as indicated by the usual tests. Its condition as to stability, progression, and muscular strength was essentially the same as before. It exhibited, on volitional effort with the left hand, wild and irregular movements, so that, when offered food, it frequently knocked it away instead of taking hold of it. With this were associated oscillations of the head and swaying of the trunk.

At the end of a week, while the animal sat at rest and undisturbed, with its back in a corner and the left limbs adducted and flexed, there was observed, apart from

obvious muscular exertion, a fine tremor of the head, upper part of the body, and of the left arm. These tremors passed on volitional effort, such as taking food, into irregular oscillations of considerable amplitude, similar to those of disseminated sclerosis in man.

At the end of a fortnight the monkey was still unsteady and its gait was sprawling, but it did not fall except when hurried or when it shook itself. The fine tremor above described in the arm and head had now become more marked, and was visible also in the left leg. The animal was in excellent health, and its muscular tone good, as indicated by well-marked knee-jerks—no apparent difference being noted between the two sides.

A month after the operation its power of maintaining equilibrium had improved, it walked more steadily and was able to climb the lattice-work of the cage hand-over-hand like a normal monkey. When sitting up in its favourite position, it exhibited well-marked tremor of the left arm and leg, which it endeavoured to control by placing the right foot over the left. From this time onwards the condition gradually improved.

When examined in greater detail at the end of the second month, it was found that the monkey walked more steadily, but the left arm and leg were raised and planted in an ataxic manner. When at rest, the fine tremor previously observed had disappeared, but the irregular oscillations on volitional effort, such as grasping food, were still pronounced. At this date there was noted an inclination of the head to the right, the chin being deviated towards the left shoulder. Its general health, intelligence, and muscular power showed no impairment.

From this time onwards no marked change was noted, and when examined at the end of the fourth month the symptoms were:—When at rest, adduction and flexion of the left limbs; during progression, a somewhat sprawling action of the left arm and leg. The chin continued to point towards the left shoulder. The general health remained excellent, and the knee-jerks were active. As the symptoms appeared to have become stationary, the monkey was killed under an anæsthetic on August 11th, 1891.

Autopsy.—The *post-mortem* examination showed that the whole of the left lobe of the cerebellum had been removed with the exception of the stump of the left flocculus. The middle lobe was quite intact. There was also observed obvious atrophy of the left restiform tract, and of the right inferior olivary body. (Plate 71, figs. 3 and 4.)

Subsequent microscopic examination (detailed below, p. 735 *et seq.*) showed that in addition to the lesion above described, the nucleus of DEITERS on the left side was implicated, apparently by traumatic influence.

Exp. 5. *Macacus rhesus*; female. December 6th, 1892.

This animal, operated upon in the same way, exhibited essentially the same symptoms as the preceding.

On the day after the operation, it lay prone upon its belly and progressed along the floor with its arms and legs sprawling. On raising itself, there was considerable swaying of the body, and it readily sought the support of a fixed object for security. When urged to progression, it fell backwards and to either side. There was no nystagmus, but immediately after the operation there appeared to be a slight deviation of the optic axes to the left.

On the third day the symptoms were the same, but of less intensity. It still required support to enable it to sit upright, and this was observed to be accompanied by a slight swaying of the body from side to side. There was no defect of common or of special sensation. It fell during progression only when hurried.

At the end of a week a fine tremor was observed in the left arm and leg, while the animal was sitting at rest and apparently making no obvious effort. On volitional effort, however, such as taking a piece of apple offered it, these tremors passed into the coarser oscillations of the disseminated sclerosis type, which have been already described under Exps. 1 and 4. During the next few days, these tremors increased in intensity, but at the end of three weeks they began gradually to lessen, and after six weeks were no longer observable. As regards other features at this time, the gait was sprawling, the ataxic movement being, however, confined to the left arm and leg, which were raised high and planted wide of the body. The monkey continued in excellent general health and nutrition. As the ataxic gait and tendency to loss of balance when hurried or excited appeared to have become stationary, the monkey was killed under an anæsthetic on February 6th, 1893.

Autopsy.—*Post-mortem* examination showed that the left lobe of the cerebellum, with the exception of the flocculus and the adjoining portion of the lobe had been removed. The middle lobe remained intact. The right olivary body was smaller than the left. Subsequent microscopic examination showed that the nucleus of DEITERS was quite intact, but that the left lateral fillet was wounded just behind the left posterior corpus quadrigeminum. (See below p. 741 ; Plate 67, figs. 5, 6 ; Plate 71, figs. 5, 6.)

Exp. 6. *Macacus rhesus* ; female. September 22nd, 1893.

In this instance the left lobe of the cerebellum was severed from the middle lobe by means of a knife and removed piecemeal.

Immediately after the operation, both knee-jerks were found to be well marked and equal. The pupils were of medium size, equal and contractile. If there was any deviation at all of the optic axes, it was slightly to the left, and perhaps more marked in the right eye. There was no nystagmus. When placed on the floor, it lay prone on its belly with the limbs doubled up, but there was no rigid flexion and no curvation of the vertebral axis other than a slight tilting of the head to the right, the chin pointing towards the left shoulder. On trying to rise from the prone position, the monkey fell to the right and then rapidly rolled to the left and lay still. The grasp of the left hand was so tight and well sustained that it was able to bear its whole weight on this hand.

On the following day the monkey was well and taking food. It could sit up without support merely by placing its hands far apart in front. While in such a position a gentle oscillation of the body was observed. It usually took food with the right hand, but when using the left irregular oscillations were detected. The gait was slow and sprawling, the belly being slightly raised from the ground, and the arms and legs planted far apart. There was no rotation on its axis. There was still an inclination of the head to the right, the chin being deviated towards the left. The knee-jerks were equal and easily obtained. There was no deviation of the optic axes. So far as could be judged, the grasps were as strong and as well sustained as those of a normal monkey, and no difference could be detected in the strength of the two sides. The actual force could not be measured with any certainty, although attempts were made to do so by means of a dynamometer.

On the third day, the animal sat more steadily, but when urged to move did so very cautiously, planting its left limbs wide, and readily falling if urged to greater activity. It fell generally to the left side. No fine tremors were observed in the limbs, but the left arm, on volitional effort, exhibited considerable oscillations. If it took food with its left hand, it usually transferred the food to the right, evidently on account of the unsteadiness of the left. The knee-jerks were active.

At the end of a week the same phenomena continued. The action of the left limbs in progression had a sprawling character, but there was no tendency to fall unless when hurried. The oscillations of the left arm on volitional effort continued, but they were not very pronounced, nor were any fine tremors observed. The animal was able to climb the lattice-work actively hand-over-hand.

At the end of a fortnight, the monkey had practically regained its stability. It was able to sit on its haunches, like a normal monkey, and to climb and run easily without falling. The left limbs, however, still showed a sprawling action, and the left arm still oscillated somewhat on taking food. Both knee-jerks were exaggerated, but apparently equal, and there was no rigidity of the limbs.

At the end of a month, the monkey was well and active, and it was difficult to distinguish it among a number of others engaged in their usual avocations. More careful observation, however, detected a slightly sprawling action of the left limbs during progression. The oscillations of the left arm were still observable. Both knee-jerks were increased, the left being considerably more active than the right.

Between this time and November 15th, 1893, when it was killed, the animal ran about and gambolled with the other monkeys, and was not markedly different from them in attitude or behaviour. On careful examination, however, at this date it was found that, though active and vigorous in its movements and without the slightest tendency to fall under any circumstances, the left limbs were somewhat ungraduated in the way in which they were lifted and set down during progression; and in particular that the left arm exhibited distinct oscillations when it was stretched out to lay hold of some object offered it. This was not visible in the left leg, for it was able to

lay hold of a piece of apple placed in this foot and raise it steadily to its mouth, and it could scratch itself steadily with this foot. The slight tilt of the chin to the left, before noted, was not now observable. The knee-jerks were active, and no marked difference was detected between them. The animal was sleek and well-nourished, and had evidently gained weight.

Autopsy.—The *post-mortem* examination showed that the left lobe of the cerebellum had been accurately and completely removed; the line of incision trenching perhaps slightly upon the middle lobe posteriorly (*vide* Plate 71, fig. 7).

Remarks.—The persistent symptoms exhibited in these three animals after the first tumultuous disturbances of equilibrium had passed off were similar in all respects to those observed after complete extirpation, with this important difference that they were confined to the limbs on the side of operation. This is in accordance with the results obtained by LUCIANI.

Except in the third instance (Exp. 6) there was no impulsive tendency to rotation, and in this animal only to a slight degree, the rolling being towards the side of lesion.

As regards muscular strength, as tested by the force required to detach the monkey from its hold on any object, we were unable to detect any difference between the two sides. There was certainly no diminution of muscular tone as far as this may be indicated by the state of the knee-jerk on the side of the lesion. This was perhaps slightly more marked on the side of lesion immediately after the operation in one case (Exp. 4), but in the other in which it was tested (Exp. 6) no obvious difference could be detected.*

The tendency in later stages, however, is towards an increase, more particularly on the side of the lesion.

We are, therefore, unable to confirm LUCIANI's statements as to the existence of muscular weakness (*asthenia*), or want of tone in the muscles (*atonia*), on the side of lesion, or generally after removal of the whole organ. The persistent and characteristic instability (*astasia*) we found to be more marked in the upper than lower extremities.

(3.) *Extirpation of the Middle Lobe.*

Exp. 7. *Macacus rhesus*. October 28th, 1891.

The middle lobe was isolated by an incision on each side and scooped out piecemeal.

After recovery from the anæsthetic the animal began to make active spontaneous movements, moving its limbs freely; but on attempting to raise itself fell repeatedly, tending on one occasion to roll to the left. It could, however, sit up clinging to some support. There was marked retraction of the head, the pupils were widely dilated, but there was no nystagmus or deviation of the optic axes. The knee-jerks were equal and active.

* We have not observed any such immediate marked exaggeration of the knee-jerk on the same side as Dr. RUSSELL appears to have found in dogs and rabbits ('Roy. Soc. Proc.,' vol. 53, 1893, p. 459).

On the following day inability to maintain the equilibrium without support was still pronounced. In progression the animal sprawled on its belly with the limbs widely abducted, swaying from side to side and falling repeatedly. Examined as regards its sensory faculties, these were found in all respects unimpaired.

At the end of a week it had regained considerable steadiness in station and locomotion, but the gait was still of the same swaying, sprawling nature, though the belly was now raised higher from the ground than before. Fine tremors were at this time observable in the head and trunk under conditions requiring general muscular effort, as, for instance, when trying to maintain an upright posture; these fine tremors did not affect the limbs. The general health was good, and the monkey was active and intelligent.

Towards the end of a fortnight the swaying movements had much diminished, but the gait showed the same sprawling character, though in less degree. The animal was able to climb and jump, but on several occasions when jumping from one object to another it apparently miscalculated its distance and fell. The tremors of the head and trunk before noted continued.

By the end of a month the animal had regained greater stability, but the gait was still awkward, the limbs being placed wide apart and the action high-stepping. The fine tremors still continued.

At the end of six weeks the animal was able to maintain its balance and walk with much greater steadiness except when hurried. There was a slight tilt of the chin to the right shoulder.

From this date onwards no material change occurred in the symptoms, and at the end of the fourth month, although able to sit up without support, the animal generally preferred to rest with its back in the corner of the cage. The tremors of the head were not visible under ordinary conditions, but were seen when the animal was excited or hurried; there were no tremors of the limbs. Its gait was of a somewhat sprawling character, the limbs being lifted high and planted wide, so as to increase the base of support. Its general health and nutrition were excellent, and the knee-jerks were well marked.

As the symptoms appeared to have become stationary, the animal was killed on February 20th, 1892.

Autopsy.—The *post-mortem* examination showed that the middle lobe of the cerebellum had been completely removed—only a small fragment on the left side remaining attached to the lateral lobe. The fourth ventricle was not exposed, but roofed over by tissue, which on microscopic examination was found to be only of a cicatricial nature. The gap formed by the removal of the lobe is shown in Plate 71, fig. 8.

Exp. 8. *Macacus sinicus*. October 6th, 1891.

The cerebellum was exposed from behind by trephining over the occipital bone,

ligaturing the right lateral sinus and dividing the tentorium. The middle lobe was disorganized by the cautery and scooped out.

After recovery from the anæsthetic the head was found to be retracted, but there was no nystagmus or ocular deviation. The monkey speedily began to make active movements, but on endeavouring to raise itself swayed much from side to side and fell backwards, sometimes to the right side, sometimes to the left.

Next day it was more steady, but tended to fall back if it tried to sit up unsupported, and in progression sprawled on the floor with its limbs wide apart. Carefully examined to-day with regard to common and special sensibility, it was found that these were in all respects unimpaired.

When examined at the end of ten days the animal was in good health and condition. Its unsteadiness was illustrated by the following observations:—When placed on the floor away from all support it fell over, and only recovered its equilibrium after considerable effort, and speedily made for some support with a sprawling gait and limbs wide apart. When shaking itself or raising its leg to scratch any part of its body it would fall over, and also when startled by a loud noise, unless clinging to some support. There was no fine tremor of the head, trunk, or limbs, but it exhibited oscillations of the arms when trying to lay hold of fruit placed on the floor before it.

At the end of a fortnight the animal, which had hitherto been in good health, had a series of epileptiform convulsions, after which attacks the knee-jerks were found to be exaggerated. The wound was found on examination to be healed, with the exception of a small sinus in the centre, but there was no evidence of septic inflammation. The monkey, however, died during the night.

Autopsy.—On *post-mortem* examination, however, a recent general inflammation of the meninges was discovered. The middle lobe had not been entirely destroyed, as the lesion did not extend into the portion roofing over the fourth ventricle. The rest of the cerebellum and brain was uninjured, but its consistence was less firm than normal.

Exp. 9. *Macacus rhesus*. May 2nd, 1893.

The cerebellum was exposed from above and the middle lobe destroyed and removed, as in the preceding case.

Immediately after the operation the head was retracted; the pupils were equal and of medium size; there was no nystagmus or ocular deviation; and the knee-jerks were equal and readily obtained. The animal was unable to maintain its balance or move from its position without falling to one side or the other.

Next day the monkey, on attempting to sit up, swayed much, and maintained its balance only by holding on to some support. In progression it sprawled with its limbs far apart, and its abdominal surface upon the ground, falling repeatedly. It was able, however, to climb with all four limbs in the usual manner, but its body swayed much while it clung to the lattice work of the cage.

On the fourth day it showed less tendency to fall, but its gait had the same

sprawling character as before. When offered food it had difficulty in seizing it, owing to irregular and oscillatory movements of the arm.

Next day, when climbing about, the animal fell from a considerable height and was stunned. From this it never completely recovered, and, as it remained weak and prostrate, it was killed under an anæsthetic.

Autopsy.—The place of the middle lobe was occupied by an easily removable clot. On this being removed the middle lobe was found to have been entirely destroyed, the lateral lobes being intact; but in this instance a thin layer of the inferior vermiform process roofing the fourth ventricle escaped. The corpora quadrigemina were clearly exposed at the anterior end of the gap.

Removal of the Posterior Part of the Vermiform Process.

Exp. 10. *Macacus rhesus*. April 19th, 1893.

The cerebellum was exposed from above, and the posterior part of the vermiform process destroyed by the cautery.

On the following day the animal was able to sit up without support, merely resting on its hands set far apart on the floor, but it was seen on several occasions, though apparently undisturbed, to fall over on its back. It was able to walk across the floor; but, though unsteady, it had not the obviously sprawling gait described in the previous experiments. There were no other noteworthy symptoms, there being no nystagmus or deviation of the optic axes.

The monkey died on the third day, and the *post-mortem* examination showed that the lesion was limited to the posterior part of the middle lobe of the cerebellum.

In addition to the above experiments, there were two in which the lesion embraced both the middle and the lateral lobe.

In the first of these, Exp. 11, July 7th, 1891, almost the whole of the right lateral lobe was destroyed, together with the right half of the middle lobe; in the second, Exp. 12, April 15th, 1893, the whole of the middle lobe was destroyed with a portion of the right lateral lobe.

In both the duration of life was only three days after the operation, but during this time they showed the same unsteadiness and sprawling gait as were observed in the other experiments, and there was temporary retraction of the head. There was no rotation, but both animals tended constantly to fall towards the right side.

(4.) *Division of the Cerebellum in the Middle Line.*

Exp. 13. Patas monkey (*Cercopithecus*); female. October 7th, 1893.

In this case the cerebellum was exposed by tilting the occipital lobe, tying the left lateral sinus and dividing the tentorium cerebelli. The middle lobe was clearly exposed and divided antero-posteriorly.

A few hours after the operation the monkey was able to sit up without support by resting on its hands planted widely apart in front. In this position it swayed from side to side, and frequently fell indifferently to either side. It usually lay prone on its belly. There was no deviation of the optic axes, but there was very considerable retraction of the head. The knee-jerks were equal and readily obtained.

The animal, however, was found dead next day.

Autopsy.—On *post-mortem* examination the cerebellum was found to have been completely divided, with the exception of a small part of the inferior vermiform process immediately overlying the calamus scriptorius. There was no injury to the corpora quadrigemina, nor was there any effusion into the fourth ventricle.

Exp. 14. Large red-faced monkey (species undetermined); female. October 14th, 1893.

The cerebellum was divided mesially as in the preceding case.

Immediately after the operation the animal moved its limbs actively. It fell indifferently to either side and with an inclination distinctly backwards. On several occasions, when sitting undisturbed, it was observed to fall flat on its back. It sat up holding on to a chair tightly with both hands and feet. So forcible was the grasp that it was easier to lift the monkey and the chair than detach its hold. On volitional effort, as in endeavouring to sit up, or in moving from one place to another, which it did with a sprawling gait, there was much swaying of the body. It climbed with agility hand-over-hand. The head was retracted, and the knee-jerks were equal and well marked.

On the following day the gait was still sprawling, the legs and arms being placed widely apart and the belly only slightly raised from the floor. There was no tremor, nor any oscillations of the arms when taking food to the mouth. There was a good deal of swaying of the head and trunk on effort, such as when lapping water out of a dish on the ground.

On the third day it walked in the same sprawling fashion, occasionally falling backwards. Although able to sit up without support, it preferred to lie down, as if from a feeling of insecurity or giddiness.

By the end of the week the symptoms had to a large extent passed off, the gait being, however, somewhat sprawling. There was no retraction or oscillation of the head. The knee-jerks also were readily obtained.

On the eighth day the symptoms which had been subsiding became intensified. The animal began to exhibit oscillations of the head and trunk, and a tendency to fall backwards, and to the side when walking. The unsteadiness was limited to the head and trunk, and did not affect the arms, as it ate a piece of apple holding it steadily to its mouth. As these symptoms seemed to increase, they appeared to indicate the existence of septic inflammation, and for this reason the animal was killed.

Autopsy.—The *post-mortem* examination showed that the cerebellum had been completely slit antero-posteriorly. On making frontal sections of this part, it was found that the incision had been carried downwards into the fourth ventricle throughout the extent of the cerebellum, but was slightly to the left of the middle plane. There were indications of recent inflammation of a septic nature on the under surface of the occipital lobe and inflammatory adhesion to the upper surface of the cerebellum.

Remarks.—From these experiments it appears that complete removal or lesion of the middle lobe of the cerebellum, including antero-posterior division, produces in general the same symptoms as those already detailed in connection with destruction of the whole organ and removal of the lateral lobe, but they do not affect one side more than the other, and are more pronounced in the head and trunk than in the limbs.

This was especially noteworthy in Exps. 7 and 14. In the first the middle lobe was completely removed, and in the second the primary lesion had become extended by secondary inflammation. These results harmonise with those of LUCIANI.

DEGENERATIONS FOLLOWING LESION OF THE CEREBELLUM.

The study of the degenerations secondary to complete, or partial, extirpation of the cerebellum, may be considered under the following heads:—

- (1.) Degenerations in the sphere of the superior cerebellar peduncle.
- (2.) In the sphere of the middle cerebellar peduncle.
- (3.) In the sphere of the inferior cerebellar peduncle.
- (4.) In the spinal cord.

(1.) *The Superior Cerebellar Peduncle.*

After extirpation of a lateral lobe of the cerebellum, we have traced degeneration in the superior peduncle in the following position and relations:—(See Exps. 4 and 5.)

(a.) Sclerosis of the brachium conjunctivum on the side of the lesion throughout its entire cross section, where it lies in the angle formed by the roof and floor of the fourth ventricle. The superior medullary velum, which forms a layer of white matter on the dorsal aspect of the brachium, and which probably contains the upward prolongation of the antero-lateral ascending, or GOWERS' tract, was unaffected. (Plate 64, figs. 4 and 5, *b.c.* and *s.m.v.*)

(b.) Atrophy of the bundles of fibres, into which the brachium resolves itself, in the tegment of the pons Varolii on the same side before the decussation (Plate 65, fig. 1, *b.c.*), and on the opposite side after the decussation. (Plate 65, fig. 1, *b.c.*)

(c.) Disappearance of the bundles of fibres within and dorsal to the red nucleus of the opposite side. (Plate 65, figs. 3 and 4, *r.n.*)

(d.) Atrophy of the fibres issuing from the anterior aspect of the red nucleus in the

"dorsal zone" of the subthalamic region and passing outwards into the optic thalamus. (Plate 65, fig. 5, *b.c.*, *r.n.*)

When viewed under a higher power of the microscope, the network of fine medullated fibres, which is characteristic of the healthy red nucleus, had almost entirely disappeared; and the cells of this nucleus, although not completely atrophied, appeared to have undergone some diminution in size.

The commissure which joins the two nuclei under the third ventricle was unaffected.

We were unable to detect any evidence of degeneration in the superior peduncle after extirpation of the middle lobe only. (Plate 65, fig. 6; Plate 66, fig. 1, *b.c.*)

After complete cerebellar extirpation, the condition above described occurred on both sides. Both brachia conjunctiva were completely sclerosed. There was entire absence of these structures in the tegment of the pons, atrophy of the decussation, and of both red nuclei. (Plate 64, fig. 4, *b.c.*; Plate 65, fig. 3, *r.n.*)

It was specially noted that the superior medullary velum, which forms the dorsal portion of the superior peduncle, retained a perfectly normal appearance. The importance of this fact will be pointed out when the constitution of the cerebellar peduncles is again under discussion. (See p. 753.)

The degenerations just described corroborate the view that the brachium conjunctivum is an efferent tract, passing from the lateral lobe of the cerebellum to the nucleus ruber and pulvinar thalami of the opposite side.* MENDEL (9) has described a tract of degeneration as the result of a hæmorrhagic lesion in the optic thalamus apparently passing from the pulvinar into the opposite corpus dentatum cerebelli. This, however, is opposed to our observations, which show complete disappearance of the fibres of the brachium centrifugal from the cerebellum. Nor can we corroborate BECHTEREW'S (11, 12) view as to the existence of a commissural strand in the peduncles uniting the vestibular nuclei. FOREL (10) believes that the fibres of the superior peduncle merely form a capsule to the red nucleus, and in reality pass into the optic thalamus. But the disappearance of the fine medullated network of the nucleus and atrophy of its cells, which we have described, indicates a much closer connection between the peduncle and the red nucleus. The atrophy of the issuing bundles, however, shows that the fibres of the peduncle do not entirely terminate in the cells of the nucleus.

The decussatio brachiorum is held by most observers to be complete, and our investigations confirm this. MARCHI (2), on the other hand, finds evidence of degeneration in both red nuclei after unilateral cerebellar extirpation, but more pronounced on the side opposite, than on the side of, the lesion. This we have not observed. Nor have we been able to trace a continuation of this peduncle, as described by MEYNERT and FLECHSIG, onwards to the cortex cerebri.

The great majority of the fibres of the brachium appear to arise in the corpus

* CRAMER (8), in a case of atrophy of the left half of the cerebellum, found considerable atrophy of the pulvinar thalami of the opposite side.

dentatum cerebelli, but it may receive accessions of fibres from other portions of the cerebellum. Thus BECHTEREW (12) has traced a strand, which medullates separately from the other bundles, to the roof nuclei and upper vermiform process; and VEJAS (13) found considerable atrophy of the brachium after removal of the flocculus in young rabbits. It is, however, probable that some of the peduncular fibres pass through the nucleus dentatus to the cortex cerebelli, without forming connection with its cells, but on these points our observations do not enable us to express an opinion.

The chief fact brought out by our observations is, that the brachium conjunctivum is efferent in function and undergoes complete degeneration after extirpation of the lateral lobe; while its perfectly intact condition after extirpation of the middle lobe alone, indicates that there is no *direct* connection between this portion of the cerebellum and the peduncle; although this does not negative the existence of an indirect connection through the cells of the corpus dentatum cerebelli.

(2.) *The Middle Cerebellar Peduncle.*

The transverse fibres of the pons Varolii constitute two sets, a superficial and a deep: of these the superficial form a compact layer on the ventral aspect of the pons, while the deep form many separate fasciculi in the interstices of which lie the cell-groups, which constitute the nucleus pontis. For the most part, both these sets of fibres decussate in the raphé of the pons. The most dorsally placed of these radiate after their decussation upwards into the tegmentum pontis.

The respective relations of the fibres of the pons to the spinal and cerebral systems have been the object of much investigation, but they are still involved in considerable obscurity. According to the observations of BECHTEREW (14), the pons is composed of two distinct systems: the cerebral and the spinal, the latter of which becomes medullated at an earlier period than the former. He is of opinion that the spinal centres are brought into relation with the cerebellum, mainly of the opposite side, through the continuation upwards of the antero-lateral ground bundles into the nucleus reticularis tegmenti pontis, and thence by the deep transverse fibres of the middle peduncle; while the fibres of the cerebral portion of the middle peduncle, after crossing the raphé, end in the cells of the tegmentum pontis, with which fibres from the crus cerebri are also in relation.

The effects of removal of a lateral lobe of the cerebellum upon the structures forming the middle peduncle were (Exps. 4 and 5):—

(a) Degeneration of the superficial layer of fibres as far as the middle line on the side of the lesion. (Plate 65, fig. 1, s.s.) The degeneration, however, did not result in complete sclerosis.

(b) Diminution in number and size, without actual disappearance, of the bundles of fibres forming the deep layers of the pons on the side of the lesion, as well as of those fibres which cross the middle line. (Plate 65, fig. 1, d.s.)

(c) Diminution in number and size, and eventually complete atrophy, of the cells of the grey-matter surrounding the bundles of pyramidal fibres, which form the nucleus pontis on the side opposite the extirpation. The fibres of the pyramids themselves remained intact.

(d) There appeared to be some atrophy of the network of fine medullated fibres of the nucleus reticularis tegmenti pontis on the side opposite the extirpation, but no obvious affection of the cells of the nucleus. (Plate 67, fig. 6, *n.t.p.*)*

No degeneration was traced in the middle peduncle after extirpation of the middle lobe. (Plate 66, fig. 1, *m.p.*)

After complete extirpation of the cerebellum the whole transverse system of the pons presented a markedly shrunk and atrophied appearance. The superficial and deep transverse systems presented the same sparseness, without complete disappearance, as was observed after ablation of the lateral lobe. (Plate 64, fig. 6.) The nucleus pontis on both sides was markedly atrophied; notwithstanding this, the pyramidal fibres remained perfectly intact.†

It would appear from these observations that the great majority of the fibres of the middle peduncle decussate and form connections with the cells of the nucleus pontis.

Our observations are entirely opposed to the statements of MARCHI (2), that the removal of a lateral lobe leads to degeneration of the fillet and posterior longitudinal bundles. In none of our experiments have these structures exhibited the slightest indication of degeneration or atrophy.

(3.) *The Inferior Cerebellar Peduncle.*

This structure is usually described as consisting of two divisions, an *external* and an *internal*; the former being connected with the spinal cord through the direct cerebellar tract, with the clavate and cuneate nuclei, and with the opposite inferior olivary body; the latter, or internal division, with the so-called "auditory nuclei." Our observations show that the degenerations following extirpation of the lateral lobe are limited to the external division; while those following destruction of the middle lobe are confined to the internal division.

The External Division.—After extirpation of the lateral lobe of the cerebellum, a well marked tract of degeneration was followed to the inferior olivary body of the opposite side, having the following position and relations (Exps. 4 and 5):—

(a) In sections taken from the restiform body shortly before it bends at a right-angle into the cerebellum, the area of degeneration occupied a ventral position, but

* This is confirmatory of BECHTEREW'S view that some of the decussated fibres pass to cells in the tegmentum pontis.

† The sparseness and absence of complete atrophy of the fibres described here was also noted by CRAMER (8) (*op. cit.*), who, in a case of unilateral cerebellar atrophy, found that the transverse fibres of the pons were not completely atrophied, but lay looser in the grey-matter.

in more distal sections it assumed a ventral and mesial situation. (Plate 64, figs. 1 and 2, *r.b.*)

(*b*) Passing from the ventral and mesial aspects of the restiform tract throughout its extent above the clavate and cuneate nuclei are large numbers of arcuate fibres—the *external arcuate* system. These fibres in normal sections are readily traceable through the ascending root of the fifth nerve and the grey reticular formation, across the raphé to the opposite olivary body. After removal of the lateral lobe, these fibres were found to have completely disappeared, their position being indicated by a number of white canals in the reticular formation and the ascending trigeminal root. (Plate 64, figs. 1 and 2, *r.f.*)

(*c*) Atrophy of the inferior olivary body of the opposite side, which was found to be due to two structural alterations, viz. (1) atrophy of the medullated fibres which enter the hilum from the opposite side; (2) shrinking and eventual disappearance of the multipolar cells of the corpus dentatum olivæ. The medullated fibres which remain intact are either commissural between the olives, or belong to the interolivary layer. (Plate 64, figs. 1 and 2, *i.o.*)

The accessory olivary nuclei shared in the atrophic changes above described, but the cells of the lateral nucleus remained intact.

In the case of complete cerebellar extirpation the atrophic changes above described occurred on both sides (Plate 64, fig. 3). The cells of the lateral nucleus of the medulla also presented a perfectly normal appearance.*

The tract just described constitutes the great efferent system of the inferior peduncle, and may be termed the *cerebello-olivary* system.

The remainder of the peduncle, which does not degenerate after cerebellar extirpation, constitutes an afferent system and will receive further consideration below. (*Vide* p. 757.)

The exact relations of the cerebello-olivary fibres are still a matter of doubt. BECHTEREW (12) and BRUCE (16) state that they terminate almost exclusively in the outer surface of the corpus dentatum cerebelli, though a few fibres may possibly reach the cerebellar cortex. STILLING, on the other hand, believed that only a few of the fibres of the restiform body end in the corpus dentatum. MARCHI (2) has described degeneration as occurring in the lateral part of the restiform body after ablation of the middle lobe. But our own observations are opposed to this, for we found no degeneration in the restiform tract after destruction of the middle lobe alone. This would prove that the external division of the inferior peduncle contains no *direct* efferent fibres from the vermiform process.

MEYNERT first described atrophy of the inferior olive in association with atrophy of the opposite cerebellar hemisphere. GUDDEN (19) and VEJAS (13) found that the cerebello-olivary tract underwent atrophy after removal of a cerebellar hemisphere in

* BECHTEREW (17) states that the fibres which connect the lateral nucleus and the restiform body medullate at an earlier date than the cerebello-olivary system. (*Infra*, p. 756.)

new-born animals; and BECHTEREW (17) and BRUCE (16), DARKSCHEWITSCH and FREUD (20) have described its myelination as occurring only in the last month of intrauterine life, by which time the other constituent tracts of the restiform body are already fully medullated. These observations, therefore, mutually confirm each other, and prove beyond doubt the intimate anatomical and functional relationship between the lateral lobe of the cerebellum and the opposite inferior olivary body.

The Internal Division.—Complete ablation of the middle lobe of the cerebellum (Exp. 7) was followed by degeneration of the internal division of the restiform body on both sides. In sections made through the medulla at the level of the genu facialis, this tract of degeneration was seen encircling the dorsal aspect of the superior peduncles. (Plate 65, fig. 6, *e.v.t.*) Through a series of sections the tract was traced ventrally to the nucleus of DEITERS (so-called large-celled external auditory nucleus). There was no evident atrophy of the cells of this nucleus, but the network of fine medullated fibres had disappeared. BECHTEREW (12) and BRUCE (16) have traced a connection between this tract and the roof nuclei of the cerebellum—each tract being connected with the nucleus of the opposite side, the decussation taking place in the middle plane and assisting to form the roof of the fourth ventricle.

This tract has been called by EDINGER (22) the “direct sensory cerebellar tract,” and is believed by him to connect certain of the sensory cranial nerves, particularly the trigeminal and auditory, and probably also the glosso-pharyngeal and vagus, with the cerebellum.

It has for some time been a matter of discussion whether DEITERS' nucleus has any connection with the auditory nerve. The view originally held by CLARKE, STILLING, MEYNERT, HENLE, and others, that the external auditory nucleus was connected with the auditory nerve, was disputed by DEITERS (21), who believed that it formed an internode between the antero-lateral column of the spinal cord and the cerebellum.

VON MONAKOW (23) found atrophy of the cells of DEITERS' nucleus after hemisection of the spinal cord in the upper cervical region in a new-born cat; and HELD (25) has shown, by the myelination method, that this nucleus has both crossed and uncrossed connections with the antero-lateral ground bundles, and with the lateral limiting layer of the spinal cord by means of the longitudinal fibre-systems of the reticular formation. ONUFROWICZ (24), moreover, has found that division of the auditory nerve is not followed by atrophy of the cells of DEITERS' nucleus.

These facts, taken in conjunction with our observations, indicate that the internal division of the restiform body, as described, is an efferent cerebellar tract connecting the middle lobe of the cerebellum with DEITERS' nucleus, and support the view that this nucleus is an internode in the cerebello-spinal system. In further confirmation of this view is the fact that in one of our experiments (Exp. 4), in which the nucleus of DEITERS was injured, there was a tract of descending degeneration in the anterior column of the spinal cord. (*Vide infra*, p. 743.)

As one would, *à priori*, expect, complete cerebellar extirpation is followed by atrophy of the cerebello-olivary system on both sides, combined with atrophy of the internal division of the restiform body. This experiment naturally removes the cerebellar portion of the internal division so that its condition cannot be determined directly, but the medullated network of DEITERS' nucleus seemed to have undergone complete atrophy on both sides, though the large cells of the nucleus presented a normal appearance. (Plate 64, fig. 4.)

(4.) *The Spinal Cord.*

MARCHI (2) has described, as a result of extirpation of half the cerebellum in monkeys and dogs, degeneration in the antero-lateral region of the spinal cord, and also in the anterior nerve roots on the side of the lesion. His description of the tract which occupies the periphery of the antero-lateral aspect of the cord is as follows:—"Posteriorly, it divides into two parts, one projected back and externally so as to join the direct cerebellar tract, with which it is in connection, the other passes internally and joins the pyramidal tract. This degeneration may be followed throughout the length of the cord." This tract he derives as follows from the cerebellum:—"The posterior longitudinal bundles and fillet have a common origin from the cerebellum, and especially from the middle lobe. They pass with the middle cerebellar peduncle and form connections, the former with the nuclei of the cranial nerves and the latter with the grey matter of the pons . . . At the level of the olives the posterior longitudinal bundles and fillet unite and pass into the antero-lateral regions of the cord." (*Op. cit.*, p. 16.)

Our own observations in connection with this matter have shown the presence of a tract of degeneration in the spinal cord in two cases in which the lateral lobe of the cerebellum had been removed. In the one case (Exp. 4), the area of degeneration occupied a position corresponding to the anterior extremity of MARCHI's tract (Plate 66, fig. 4), viz.: the periphery of the cord between the anterior nerve roots and the anterior median fissure; in the other (Exp. 5), there was no degeneration in this region, but a well-marked tract of comma-shape, the head lying immediately internal to and in contact with the antero-lateral ascending tract of GOWERS, and thence tailing off with the concavity inwards to the middle of the posterior horn. (Plate 67, fig. 2, *l.f.t.*)

A more careful investigation of the apparent discrepancy in the two cases revealed the fact that in the instance in which there was a circumferential degeneration of the anterior column, the nucleus of DEITERS on the same side was implicated; while in the case in which the degeneration was limited to the comma tract above described, there was lesion of the nucleus of the lateral fillet at the point where this tract ascends to the posterior corpus quadrigeminum.

The question then arose whether we could ascribe the degeneration of these tracts to the cerebellar lesion as such.

Examination of the spinal cord from the experiment in which the cerebellum was completely removed, showed no evidence of degeneration, either in the lateral or anterior column.* In this instance neither the lateral fillet nor the nucleus of DEITERS had been destroyed. (Exp. 1: Plate 66, fig. 5.)

In another experiment (Exp. 18) in which the middle cerebellar peduncle was cut, we also traced the comma-shaped tract in the lateral column of the spinal cord, apparently in relation with this lesion.

And further experiments, specially directed to the solution of this question and detailed below (*infra*, p. 761), proved that the comma-shaped degeneration in the lateral column of the spinal cord stands in relation to lesion of the lateral fillet; and that the marginal degeneration in the anterior column is in all probability connected with lesion of DEITERS' nucleus.

FLECHSIG (26), HELD (25), and BRUCE (16), by the myelination method, and VON MONAKOW (28), by the degeneration method, have differentiated in the medulla oblongata a tract continuous with the lateral fillet; but so far as we are aware, the relations of this tract to the cord have not been previously described. These by the degenerative method are, according to our observations, as follows:—

The lateral fillet tract.—From the nucleus lemnisci lateralis, an area of degeneration was traced through the pons and medulla into the lateral column of the spinal cord. The tract leaves the lateral fillet at the level of the motor nucleus of the fifth nerve, so that a section made at this point reveals the tract lying between the nucleus and the superior olivary body, and on the mesial side of the motor root. The degenerated area is visible amongst the fibres of the corpus trapezoideum lying ventral to the nucleus of the seventh cranial nerve, and between this nucleus and the ascending trigeminal root. (Plate 67, fig. 5, *l.f.t.*) The superior olivary body on the side of the lesion has undergone no change. At the upper end of the inferior olivary body, the tract in question occupies the dorsal (posterior) half of the area between the olive and the ascending root of the fifth nerve, the ventral (anterior) portion of this area which is normal being the continuation of the antero-lateral ascending tract of GOWERS. (Plate 67, fig. 4, *l.f.t.* and *a.l.asc.*)

With these relations the tract is traced to the distal end of the inferior olive. In still more distal sections through the medulla it lies in front of, and somewhat internal to, the direct cerebellar tract and dorsal to the ascending antero-lateral tract of GOWERS. By its mesial border it is in contact with the formatio reticularis grisea. At the lower end of the decussation of the pyramids, it lies ventral to and among the bundles of fibres which have crossed from the opposite anterior pyramid. (Plate 67, fig. 3, *l.f.t.*) From the level of the first cervical nerve it assumes the shape and position which it retains throughout the upper cervical region. It lies in the lateral column of the spinal cord, extending from the posterior horn as far forwards as the

* Several sections of the spinal cord from this case were submitted by us to Dr. HOWARD TOOTH, who agreed with the opinion here expressed.

ideal prolongation outwards of the anterior commissure. Anteriorly, it is expanded so as to form a head, which lies immediately internal to the head of GOWERS' tract, while posteriorly it is constricted and lies along the mesial side of the crossed pyramidal tract. (Plate 67, fig. 2, *l.f.t.*) The tract, gradually diminishing in size, we have followed distinctly as far as the sixth thoracic segment, but below this it is difficult to differentiate. (Plate 67, fig. 1, *l.f.t.*)

Throughout its course the degenerated tract is nowhere an area of complete sclerosis, but contains many healthy nerve fibres. These are, in the spinal cord, the fibres of the crossed pyramidal tract; while in the medulla, they appear to belong to the longitudinal fibre system of the lateral reticular formation.*

The Tract from Deiters' Nucleus.—As we have already mentioned (p. 727), in one of the cases in which the lateral lobe had been removed (Exp. 4), an area of degeneration was observed at the periphery of the anterior column corresponding in position with the anterior extremity of MARCHI's cerebellar tract. This tract was most distinctly seen in the upper cervical region, but could be followed into the lumbar enlargement.

In the spinal cord it occupied the periphery of the anterior column from the anterior nerve roots to the median fissure along which it extended a short distance. (Plate 66, fig. 4, *a.d.t.*) At the level of the pyramidal decussation it occupied relatively the same position as obtained in the spinal cord.

From this point upwards the area of degeneration could not be traced as a distinct tract, but, as the figures show (Plate 64, figs. 1 and 3, *r.f.*), the reticular formation, especially its dorso-lateral region, was less deeply stained than the opposite side, and presented an atrophied appearance. This condition was traced as far as the upper end of the restiform body.

In this case a careful examination of a number of sections taken through this region showed that the cells of DEITERS' nucleus on the side of the lesion were either entirely absent or were greatly reduced in number; and the whole appearance of the tegmentum at this point indicated some traumatic lesion connected with the removal of the lateral lobe. (Plate 66, fig. 3.)

We would again call attention to the fact that in the case of complete cerebellar extirpation no such tract of degeneration was discoverable in the spinal cord, and the cells of DEITERS' nucleus were normal; and a similar healthy appearance was observable in another case of extirpation of the lateral lobe (Exp. 5). (Plate 66, fig. 2.)

The evidence, therefore, is in favour of the tract in question being dependent upon destruction of the cells of DEITERS' nucleus. It is, however, our intention to further prosecute our researches on this point.

* The presence of this tract among the fibres of the crossed pyramidal tract would serve to account for the less degree of sclerosis in this region from lesion of the motor cortex than from hemisection of the spinal cord, as has been noted by SHERRINGTON (30); and BECHTEREW (36) has shown that on the mesial side of the direct cerebellar tract, and in the pyramidal tract, are scattered fibres, often forming a distinct system, which myelinate at an earlier date than the pyramidal fibres proper.

[Our subsequent examination of a third case of extirpation of the lateral lobe (Exp. 6) has revealed the same area of degeneration in the periphery of the anterior column of the spinal cord, and also the fact that the nucleus of DEITERS was involved in the experimental lesion.—August, 1894.]

We cannot, after careful investigation, confirm MARCHI's statement as to the existence of degeneration in the anterior nerve roots, posterior longitudinal bundles or mesial fillet after lesions of the cerebellum.

SERIES B.—EXPERIMENTS UPON THE CEREBELLAR PEDUNCLES.

(1.) *Division of the Left Superior Cerebellar Peduncle.*

Exp. 15. *Macacus sinicus.* May 24th, 1892.

The skull was trephined over the left occipital region, the left occipital lobe was removed and the tentorium cerebelli laid bare. This was divided so as to fully expose the corpora quadrigemina and superior peduncles. A cutting hook was then inserted mesially and the left superior peduncle divided outwards, immediately posterior to the fourth cranial nerve.

On the next day the monkey was found in good condition and had taken food spontaneously. There was great disturbance of equilibration. When placed on the floor it lay prone on its belly, with the left limbs flexed by its side and the right extended and abducted. On attempts at progression, it fell over constantly to the left side. When placed in the cage, it at once sought support in the corner, holding on to the wires with the right limbs. There was no palsy, for it climbed, using all four limbs vigorously. There was marked nystagmus in both eyes, especially in the left eye and on movement to the left. Both conjunctival reflexes were present, and it responded to tactile impressions on all four limbs.

There was no material change during the next few days. At the end of a week the monkey continued in good health; it had regained a greater degree of stability, but still exhibited the same tendency to fall to the left. When placed on the floor, it kept the right arm widely abducted, while the left arm was generally maintained in a flexed position and was the subject of fine tremors, which became greatly amplified on exertion. These tremors were also observed to some extent in the left leg. The nystagmus still continued, more especially in the left eye, and on lateral movements to the left.

At the end of a fortnight, the difficulty of maintaining the balance had, to a great extent, passed off, and the animal did not now require support to sit up. When startled, or when making a hurried movement, it fell over. The tremors and oscillations of the left arm and leg still continued well marked. It was noted also, that the head was kept with the occiput inclined to the left, and the chin pointing to the right shoulder.

At the end of a month the power of maintaining balance had improved. The left limbs were planted wide, and it occasionally fell when hurried. The tremors and oscillations of the left limbs were still present, but less marked than before. The nystagmus continued.

The animal was attacked by diarrhoea, which was epidemic in the laboratory at the time, and died forty days after the operation, without having exhibited any notable change or improvement.

Autopsy.—The brain was removed and placed, without disturbance of the parts around the seat of lesion, in MÜLLER'S fluid. Sections were subsequently made at this level and stained. One of them, from the middle of the incision through the peduncle, represents the extent of lesion (Plate 68, fig. 1*x*), and shows that, in addition to the superior cerebellar peduncle, the so-called descending root of the fifth nerve had also been cut (V, *d.*), and that the point of the knife had wounded a small portion of the dorsal region of the tegmentum pontis.

Exp. 16. *Macacus rhesus*, female. September 26th, 1893.

The operation was performed in the same way as the preceding.

One hour after the operation the animal lay prone with the arms and legs spread out. On the slightest attempt to change its position, it swayed much and fell indifferently to either side. There was no deviation of the optic axes, the corneal reflexes were normal, and the pupils were equal and of medium size; the knee-jerks were well marked and equal.

On the following day the animal was well and active. The most marked symptom was intense perturbation and swaying of the body on the slightest attempt at movement. As a consequence, it kept the prone position on the floor, but, nevertheless, was able to progress very slowly with its limbs widely sprawling. It rolled over to either side, and was unable to sit up without holding on to some support. There was no rigidity of the limbs, and although it did not use its left arm so frequently as the right, the grasp of this hand was strong and well-sustained. Irregular oscillations of the disseminated sclerosis type were well seen in the left arm on taking food. The head was tilted to the right, the chin being deflected to the left shoulder. The knee-jerks were readily obtained and equal. There was no defect of sensibility in the region of distribution of the left fifth nerve.

On the third day the chief feature was still the intense swaying and oscillation of the whole body on the slightest effort. Movements of the disseminated sclerosis type were marked in the left arm and leg. Owing, probably, to the discomfort occasioned by these oscillations, it did not use the left arm so frequently or so effectively as the right. There was no diminution in the lachrymal secretion of the left eye.

At the end of a week the monkey remained in much the same condition, a lessening

of the general agitation on effort having however occurred. Except when quite at rest, a constant tremor was observed in the left arm and leg, which passed into larger oscillations on volitional effort, as in taking food. The animal still fell during progression, mostly to the left side.

At the end of a fortnight, the symptoms had lessened considerably in intensity. The tremor was still present in the left arm, but it had disappeared from the left leg. When walking the left limbs were raised high and planted somewhat wide of the body, and the oscillations of the left arm of the disseminated sclerosis type were still very evident. The knee-jerks were active and, if anything, the left was slightly more marked than the right.

These symptoms continued, but in lessened intensity, when the animal was killed under an anæsthetic four weeks after the operation. (The condition of the brain will be described at a later date when it has been sufficiently hardened for examination.)

[*Autopsy*.—Microscopic examination at the seat of lesion showed that the superior cerebellar peduncle and the subjacent descending root of the fifth nerve had been divided on the left side. It was noticed also that the temporal and masseter muscles on the left side were considerably atrophied. There was, however, no evident implication either of the motor division of the fifth nerve, nor of its motor nucleus, so-called. The cerebellum was intact, save a slight softening over the seat of lesion of the peduncle.—August, 1894.]

In a third experiment (Exp. 17, *Macacus sinicus*, May 4th, 1892), in which the monkey only lived four days after the operation, there was observed, immediately after recovery from the anæsthetic, absence of the conjunctival reflex on the left side, and diminution in size of the left pupil. The animal moved about spontaneously, but exhibited a distinct tendency to roll to the left. Rotatory nystagmus also was visible in both eyes. The knee-jerks were readily obtained on both sides.

On the following day equilibrium was very unsteady. Left to itself the animal sat in its cage, holding on to the wires for support. When placed on the floor, it lay prone with the limbs doubled up under it. When urged to move the body swayed much, the left limbs being raised high and planted in an ungraduated manner. The left conjunctival reflex was defective, and the rotatory nystagmus was still present. There appeared to be defect of vision towards the right, but there was no defect of common sensation.

Autopsy.—The *post-mortem* examination showed that the left occipital lobe had been removed and that the upper surface of the left cerebellar hemisphere was soft. The lesion was distinguished as an incision a short distance behind the corpora quadrigemina on the left side. After hardening in MÜLLER'S fluid, sections were cut and stained. These showed that the peduncle had been entirely divided behind the free margin of the valve of VIEUSSENS.

(2.) *Division of the Left Middle Cerebellar Peduncle.*

The steps for this operation were the same as for the superior peduncle, viz., exposure and removal of the left occipital lobe, division of the tentorium, and careful retraction of the cerebellar folia, until the anterior margin of the middle peduncle and the fifth cranial nerve were seen. The peduncle was divided by a cutting-hook from within outwards and in a direction transversely to the fibres.

Exp. 18. *Macacus rhesus*, female. February 28, 1893.

Immediately after recovery from the anæsthetic there was observed curvation of the vertebral column with the concavity to the left, and a tendency to roll to the left side, the right limbs being extended and abducted, the left flexed and adducted. Anæsthesia of the left cornea also existed, and nystagmus, which latter lasted for about a half hour after the operation.

On the following day, when the animal was placed on the floor, it lay prone and exhibited great swaying of the body and a sprawling gait on attempting spontaneous movement. There was now a tendency to fall backwards and to the left, instead of rolling to the left. The left pupil was smaller than the right, and the left cornea and the whole of the left side of the face completely anæsthetic.

During the next three days the symptoms were essentially the same and were not appreciably lessened.

On the fifth day the animal was more steady, but left to itself generally clung to some support to obviate the tendency to fall. Instead of a tendency to fall to the left, there was an inclination to fall and sometimes even to roll to the right side. At this time, the temperature was slightly raised, which was attributed to a superficial portion of the wound having not completely healed. This, however, healed by granulation in a few days.

At the end of a fortnight there was still considerable unsteadiness and swaying of the trunk, and the irregular oscillations of the left limbs were present on exertion, but there were no fine tremors. The deviation of the chin to the left continued. The left cornea and left side of the face were anæsthetic, but the cornea itself remained perfectly transparent, and free from all turbidity or ulceration.

At the end of a month the animal had practically recovered from its unsteadiness of equilibrium, but still exhibited oscillatory movements of the left arm on volitional exertion, and the movements of the left leg were awkward in progression. The deviation of the chin persisted. The anæsthesia of the cornea and face remained as before, and there was atrophy of the left temporal and masseter muscles. The cornea remained quite transparent.

From this date no material change occurred, and, as the symptoms appeared to have become stationary, the monkey was killed under an anæsthetic two months and ten days after the operation.

Autopsy.—It was found, after removal of the brain, that the incision in the middle peduncle was filled in by cicatricial tissue. The brain was accordingly placed in MÜLLER'S fluid and sections from this region were subsequently cut and stained. The nature and extent of the lesion is seen in Plate 68, figs. 2 and 3*x*.

The whole of the middle peduncle had been divided with the exception of a few of the most ventrally situated fibres. As the lesion was made where the fifth nerve issues from the side of the pons Varolii, it was involved in the cicatrix, and degeneration was traced both in its ascending and descending roots (see p. 762). Owing to some implication of the tegment of the pons, the tract from the lateral fillet was divided and degeneration was traced into the lateral column of the spinal cord (see p. 742). The brachium conjunctivum of the superior peduncle appeared also to have been slightly wounded externally.

Exp. 19. *Macacus rhesus*. September 22nd, 1893.

The operation was performed as in the preceding case.

One hour after the operation the animal, when placed on the floor, lay chiefly upon its left side; when put upon the right it at once rolled over to the left. On attempting spontaneous movements, it also rolled rapidly to the left. When a finger was placed in the palm of the left hand the monkey grasped it tightly, and by this means was able to climb on to the observer's arm and cling there with all four limbs. The chin was markedly deflected to the right shoulder, the occiput being inclined to the left. There was no deviation of the optic axes. The knee-jerks were equal and active, and there was no perceptible difference between them.

On the following day the animal showed little energy. It sat up holding on to the bars of the cage. When placed on the floor, it lay on its left side with the chin pointing to the right. It raised itself on its haunches with its legs and arms wide apart on the floor. It did this fairly well, requiring some time to get itself properly balanced. There were no oscillations or tremors, when left alone in this position. It swayed a little when it tried to turn round, apparently from lateral oscillations of the head and trunk. It was very unwilling to move, and usually lay prone; on movement it fell to the left side.

On the third day the monkey was rather more active; it walked with a slow sprawling gait, but very readily lost its balance and fell over to the left. Slight oscillations of the body were observed while sitting. The knee-jerks were well marked. The chin was slightly deflected to the right, but apparently less than before. As the monkey was on the fourth day weak and prostrate, it was killed under an anæsthetic.

Autopsy.—A good deal of effusion had occurred over the upper surface of the left lobe of the cerebellum. The middle peduncle was found to have been divided, but the incision had not entirely severed the most ventrally placed bundles of fibres. The right occipital lobe had been removed; the rest of the brain was intact.

Exp. 20. *Macacus rhesus*, female. September 20th, 1893.

One hour after the operation the animal lay prone with the left limbs flexed and the right extended and abducted. On the slightest attempt at movement it rolled over to the left, in the direction of the pointing of the chin. This was deflected to the right, the occiput being inclined to the left side. The eyes deviated to the right, but the optic axes retained their parallelism, and there was also slight nystagmus in both eyes. The pupils were equal, as also were the knee-jerks. It grasped well with the hands and feet, the grasp of the left limbs being quite as strong as that of the right. There was a slight incurvation of the whole vertebral column to the left.

On the following day the curvation of the vertebral column had disappeared, although the chin still pointed to the right shoulder. It sprawled along the floor on its belly, but there was no swaying of the body. When sitting, which it did easily, leaning on its hands spread out in front of it, there were noted fine oscillations of the head and trunk. The tendency to roll had gone. It did not use the left arm as much as the right, but it grasped equally well with both. There was no defect of sensibility in the distribution of the left fifth nerve.

The animal died on the fourth day after the operation.

Autopsy.—The middle peduncle was found to have been divided in a direction at right-angles to the course of the fibres, and in this, as in the previous experiments, the most ventrally situated fibres were not severed. The incision having been made posterior and somewhat dorsal to the roots of the fifth nerve, this structure had escaped division. The lesion was confined to the middle peduncle, the corpora quadrigemina and superior peduncle being intact.

In another experiment (Exp. 21, *Macacus rhesus*, February 7th, 1893), the left peduncle was divided by exposing the left half of the cerebellum posteriorly; and by the insertion of a cutting-hook, the peduncle was divided transversely to its fibres.

This was followed on recovery from the anæsthetic by deviation of both eyes to the right without nystagmus. The animal lay prone, but on spontaneous movement it rolled on its axis from right to left, that is towards the side of lesion. The grasps, both of the hands and feet, were forcible, and the knee-jerks were present on both sides. The animal died on the following day from the occurrence of hæmorrhage in the neighbourhood of the lesion. The left middle peduncle had been completely divided.

(3.) *Division of the Left Inferior Cerebellar Peduncle.*

Exp. 22. *Macacus rhesus*, female. April 12th, 1892.

The peduncle was destroyed in this case by the galvano-cautery.

On recovery from the anæsthesia there was incurvation of the vertebral axis to the left. The monkey lay prone with the left limbs adducted and flexed, and the right limbs extended and abducted. Attempts at movement occasioned rolling from right

to left, and apparently with a view of preventing this the animal held on tightly with the right limbs to any article it could clutch. The knee-jerks were equal and normal; there was no loss of sensibility, the animal being apparently aware of cutaneous stimulation on every part of the body.

On the following day the same incurvation of the vertebral axis to the left was noted, with tilting of the chin to the right. When placed on the floor it lay prone with the limbs sprawling and widely abducted, in which position it was able to crawl along the floor. On several occasions it was observed to roll round its axis towards the left side. It was unable to sit up without support, and when raised from its prone position, it grasped tightly with all four limbs as if from fear of falling.

No further observations were made until the ninth day, when the animal was found to be well and active, and taking food heartily. It could sit up only by holding on to some support, or by widely abducting and resting on its fore-limbs and buttocks. When startled or disturbed, it occasionally tended to fall over. It was able to progress with a sprawling gait, the limbs on the left side being irregular and ataxic in movement. It was able to climb about in a normal way. The head was still inclined as before, and slight nystagmoid movements were observed in the eyes. At the end of three weeks the animal showed much more steadiness, and could maintain its balance undisturbed, but occasionally falling when hurried. Its gait was still slightly sprawling, the movements of the left limbs only being unsteady.

At the end of two months there was still slight instability of equilibrium, as the animal fell when shaking itself; the gait was more like that of a normal monkey, though the left limbs were somewhat unsteady. The deviation of the chin to the right continued. No material alteration had occurred when the monkey was killed on August 17th, 1892, four months after the operation.

Autopsy.—The lesion of the restiform tract proper in this case is figured on Plate 69, fig. 4, *x*. From this it is seen that, in addition to the lesion of this structure, the nucleus cuneatus was also involved. The figure merely represents the most distal portion of the lesion. Sections made higher up showed that the whole extent of the corpus restiforme up to where it bends into the cerebellum was destroyed. In this case the ascending root of the fifth nerve was uninjured on the side of the lesion.

Exp. 23. *Macacus radiatus*, female. July 12th, 1892.

The peduncle was in this case divided transversely by means of a curved knife.

After recovery from the anæsthetic, the following phenomena were observed. There was incurvation of the body to the left, but no nystagmus or optic deviation. The left corneal reflex was diminished. The animal, when at rest on the floor, lay prone with the left limbs adducted and flexed, and the right limbs abducted and extended. From this position the animal on attempting to move rolled over towards the left side, and this it endeavoured to prevent by laying hold of some object of

support by its right limbs. It grasped firmly with both hands and feet, and there was no loss of sensation in the trunk or limbs.

On the following day the animal still exhibited marked rolling towards the left side.

On the third day the tendency to rolling had passed off; the position assumed on the floor was prone on the belly with the limbs sprawling, and it made no effort at progression. It was unable to sit up without holding on to some object of support. The knee-jerks were equal and readily obtained; there was no defect of sensibility except on the left cornea and left side of the face, which had been observed from the beginning.

At the end of a week the animal could walk across the floor with the belly close to the ground and the limbs sprawling. Although unsteady, it did not fall over. It was able to maintain an erect posture only by holding on to some object of support, and resisted greatly when attempts were made to detach it.

The animal continued well and in much the same condition for a fortnight, when it became ill with diarrhoea and, being prostrate, was killed under chloroform.

Autopsy.—Sections made subsequently through the site of the lesion showed that in addition to the restiform body itself, a small part of the grey matter of the floor of the fourth ventricle at the outer part, the ascending root of the auditory nerve, and the dorsal half of the ascending root of the trigeminus had been divided.

Exp. 24. *Macacus rhesus*, female. March 8th, 1892.

The operation was the same as in the preceding case.

In this instance the phenomena were not so pronounced. There was less tendency to rolling, and though the gait was sprawling, the animal was able to maintain its balance when resting on the floor with the hands placed wide apart in front of it. There were oscillatory movements of both eyes, and the left pupil was smaller than the right. There was also well-marked anæsthesia of the cornea and left side of the face. The knee-jerks were present.

On the seventh day the animal was weak, and the symptoms became intensified—inability to maintain the balance; during progression a sprawling attitude with the belly in contact with the floor; when holding on by the right limbs and using the left arm to feed itself, oscillations of the left arm were observed.

On the two following days the monkey still remained prostrate; the limbs assumed the position which they commonly did immediately after section of the restiform body, viz., flexion and adduction on the side of the lesion, extension and abduction on the opposite side. The anæsthesia of the cornea and the left side of the face remained as before. The temperature was normal, but as there was a suspicion that secondary inflammation was occurring, the animal was killed on March 18th.

Autopsy.—The restiform body was found on *post-mortem* examination to have been

divided immediately above the cuneate tubercle. The cerebellum was somewhat softened.

In a fourth case (Exp. 25, *Macacus sinicus*, March 1st, 1892), observations were only made immediately after the operation. There was flexion and adduction of the left arm and leg, abduction and extension of the right. When urged to move, the monkey tended to roll on its axis towards the left, to prevent which it clutched wildly for support with the limbs on the right side. In these struggles the left arm and leg were not used, but the grasps of the hand and foot were vigorous. There was deviation of the eyes to the left, and some clonic spasm of the left leg.

Two hours later the position of the limbs already described was less marked, but the monkey still rolled to the left side. There were oscillatory nystagmoid movements in both eyes, mainly on looking to the left. There was also detected some degree of anæsthesia of the left cornea and left side of the face. The animal died before further observations could be made. In this case also the left inferior peduncle had been divided.

Exp. 26. *Macacus rhesus*, female. November 4, 1893.

The animal recovered rapidly from the operation. On attempting to move it rolled round its axis from right to left, as many as four to six times in succession. No deviation of the optic axes was observed either during rotation or when lying quiet. The chin, however, pointed somewhat to the right shoulder, and there was marked incurvation of the vertebral column to the left. When lying undisturbed upon the floor, the left limbs were flexed and adducted, the right fully abducted and extended, but they were not maintained in this position by rigid flexion or extension, as they could be passively moved without resistance. The knee-jerks were equal and apparently normal.

On the following day the animal was fairly active, but very wild. It exhibited the same phenomena, but in a somewhat less marked degree. There was a little unsteadiness in the movements of the left arm when taking hold of an object, such as a piece of apple; but there were no marked oscillations or tremors. There was no loss of corneal sensibility in this case.

On the third day the characteristic position of the limbs was no longer assumed; although there still remained a tendency to roll to the left, vertebral incurvation to the left and deflection of the chin to the right.

The animal, which was wild and would not take food spontaneously, died upon the following day.

This experiment, which was performed for the purpose of testing some of the previous observations, has been done so recently that the brain is not, as yet, ready for minute investigation.

[Autopsy.—The restiform body had been cut a short distance in front of the

nucleus cuneatus, but the lesion did not extend to the ascending trigeminal root. In other respects the brain was normal. August, 1894.]

Remarks.—The symptoms following division of the peduncles are very similar to those occurring after removal of the lateral lobe, the chief difference being the greater tendency to roll round the longitudinal axis towards the side of lesion, whichever peduncle is cut.

The attitude immediately after section of the inferior peduncle was also a constant and characteristic one, viz., curvation of the vertebral axis with the concavity towards the side of lesion, adduction and flexion of the limbs on the side of lesion, and abduction and extension of those on the opposite side.

The direction of deviation of the chin was not constant; in the majority of the cases it was deflected to the side opposite the lesion and in the direction of the rotation round the vertebral axis, which caused the animal to roll to the side of lesion.*

In several cases, after division of the inferior peduncle, anæsthesia of the cornea on the side of lesion was observed. As will be again referred to, this was due to implication of the immediately subjacent ascending trigeminal root. In Exp. 18 (division of the middle peduncle) the trunk of the fifth nerve had been divided where it joins the pons Varolii.

DEGENERATIONS FOLLOWING DIVISION OF THE CEREBELLAR PEDUNCLES.

The degenerations following division of the cerebellar peduncles are confirmatory of those which have been already described after removal of the cerebellum itself. Special attention was, however, given in these cases to the detection of afferent as well as efferent tracts in the respective peduncles.

(1.) *The Superior Cerebellar Peduncles.*

We have already shown (*vide supra*, p. 736) that the brachium conjunctivum of the superior peduncle degenerated completely as far as the red nucleus of the opposite side after extirpation of the lateral lobe of the cerebellum, and this received confirmation from a study of the degeneration following section of the peduncle itself. The absence of any non-degenerated area in the cross-section of the brachium on the cerebral side of the lesion would indicate that this structure contains no tract centripetal to the cerebellum. But we have already (*supra*, p. 736) pointed out that the superior medullary velum which lies on the dorsal aspect of the brachium retained a normal appearance after cerebellar extirpation (Plate 64, figs. 4 and 5, *s.m.v.*). After division of the whole superior cerebellar peduncle, or after injury to the velum (as

* The impulse which causes an animal to roll towards the side of lesion may be described as a tendency to rotation round the vertebral axis towards the sound side. In this sense we should be in harmony with LUCIANI as to the direction of the rotation.

accidentally happened in Exp. 1), a tract of degeneration was traced on the cerebellar side of the lesion as far as the middle lobe.

The observations of LOEWENTHAL (31), AUERBACH (32), MOTT (33), and TOOTH (34) have shown that the antero-lateral ascending tract of GOWERS (so-called "ventral cerebellar bundle") may be followed through the medulla and pons into the medullary velum of the superior peduncle, and thence into the middle lobe of the cerebellum. In confirmation of this, we may mention that in a case of hemisection of the spinal cord, we also were able to trace a tract of degeneration in the superior peduncle, which could be followed into the inferior portion of the middle lobe.

The degeneration which we have traced into the cerebellum in the medullary velum after section of the superior peduncle corresponds in position to the tract described by these observers, which is doubtless therefore to be regarded as the upward continuation of GOWERS' tract.

(2.) *The Middle Cerebellar Peduncle.*

The degenerations following division of the middle cerebellar peduncle were essentially the same as those following extirpation of the lateral lobe, which have been described above (p. 737).

Here also the degeneration was solely efferent from the cerebellum, and consisted of partial degeneration and diminution in number and size of the superficial and deep transverse fibres of the pons on the side of the lesion, and atrophy of the nucleus pontis on the opposite side. (Plate 68, figs. 3 and 4.)

In order to ascertain the existence of a direct ponto-cerebro-cerebellar tract by way of the middle peduncle, the portion of the frontal lobe in front of the excitable area for the head and eyes, determined by preliminary electrical exploration, was extirpated on the left side.

Exp. 27. *Macacus rhesus*. June 3rd, 1893.

The animal presented no symptoms as a result of the lesion, and was killed six weeks after the operation.

Although a small area of degeneration was present in the innermost part of the crus cerebri on the side of the extirpation, there was no obvious alteration in the size of the cerebellar hemispheres, nor could we detect any signs of degeneration in the middle peduncle or transverse fibres of the pons. We purpose, however, continuing our researches on this subject.

(3.) *The Inferior Cerebellar Peduncle.*

By this is meant the external portion as already described. Section of the peduncle was followed by secondary degeneration in two directions:—

(a.) To the inferior olivary body of the opposite side.

(b.) Into the cerebellum.

(a.) It is unnecessary to recapitulate here the system which has already been described in detail (p. 738), and which has been designated, by reason of its connections and direction of degeneration, the cerebello-olivary system. The structures which undergo atrophy after division of the restiform body are, therefore, the external arcuate system of fibres on the side of lesion, and the inferior olivary body on the opposite side.

(b.) The fibres which degenerate towards the cerebellum lie in the lateral lobe external to the corpus dentatum anteriorly, and form a highly characteristic fan-shaped area of sclerosis, seen in Plate 69, fig. 5, *a.c.t.* This large tract, the *ascending cerebellar system*, as will be described subsequently (p. 756 *et seq.*), is formed by the direct cerebellar tract and those from the clavate and cuneate nuclei, and appears to end in the cortex of the lateral and middle lobes.

SERIES C. EXPERIMENTS UPON THE POSTERIOR TUBERCLES OF THE MEDULLA OBLONGATA.

(1.) *Destruction of the Left Nucleus Clavatus.*

Exp. 28. *Macacus rhesus*, male. April 5th, 1892.

This tubercle was readily exposed by trephining the occipital bone, dividing the occipito-atloid ligament and removing the arch of the atlas. It was destroyed by the galvano-caustic knife.

The monkey recovered rapidly from the operation and on attempting movement exhibited a tendency to fall backwards to either side; there was also a considerable degree of swaying of the body on exertion. On progression, the movements of the limbs were of a slightly sprawling nature. The head was retracted, the chin being deviated to the left. The knee-jerks were equal and well marked.

Special attention was directed to the state of cutaneous sensibility. Two hours after the operation clear evidence was obtained, in response to the usual tests, of the retention of tactile and painful sensibility, and the sense of localisation seemed in no wise impaired. These observations were amply confirmed upon the following day.

On the third day the slight disturbance of equilibrium previously observed had to a great extent passed off; and at the end of a week it was difficult to distinguish it from a normal monkey. It was very active, climbed readily and jumped amongst the ropes in the cage as easily as its companions. On one or two occasions, when shaking itself, it was observed to lose its balance slightly, but never fell over. It was killed six weeks after the operation.

Autopsy.—Microscopic examination of the medulla at the level of the clavate

tubercle showed that the lesion was entirely limited to this structure. The amount of destruction is indicated in Plate 68, fig. 5, *n. cl.*

In a second case (Exp. 29, *Macacus rhesus*, February 11th, 1893), both clavate tubercles were destroyed, the left to a much greater extent than the right. In this case also there was a transient tendency to fall backwards to either side. The gait was sprawling, but the animal was able to run easily across the floor and climb the lattice-work of the cage. Repeated examination failed to detect any defect of cutaneous sensibility or localisation of impressions.

At the end of a week it had nearly regained its normal equilibrium; only occasionally showing a little instability when excited or hurried. It was killed nine weeks after the operation. The lesions were found limited to the clavate nuclei. The resulting degenerations are figured on Plate 69, fig. 2.

(2.) *Destruction of the Nucleus Cuneatus.*

Exp. 30. *Macacus sinicus*. February 15th, 1893.

This nucleus was exposed in the same manner as the clavate nucleus, and destroyed by means of the galvano-cautery.

The monkey recovered rapidly from the operation. On progression there was a slight tendency to fall backwards and towards the right side, which only lasted for a few hours. The gait presented the usual slightly sprawling character. Although it was able to move about freely, it generally clung to some support when resting.

In this case also there was no evidence of any defect in the perception or localisation of tactile or painful impressions.

The symptoms passed off towards the end of a week.

The animal succumbed to diarrhoea a month after the operation.

Autopsy.—The microscopic examination showed that the cuneate tubercle had been destroyed, without any implication of the adjoining clavate tubercle.

In a second case (Exp. 22, April 12th, 1892) in addition to the complete destruction of the left cuneate tubercle, its upward prolongation into the restiform body was also destroyed.

The symptoms following this lesion have been already described (p. 749).

It is only necessary to add here that there was an entire absence of any impairment of cutaneous sensibility on either side. (Plate 69, fig. 4, X.)

DEGENERATIONS FOLLOWING LESION OF THE TUBERCLES.

The degenerations following destruction of the clavate and cuneate tubercles were traced in two directions:—

(1.) Into the restiform body.

(2.) Through the internal and middle arcuate fibre-systems to the inter-olivary layer and mesial fillet.

(1.) *The Inferior Cerebellar Peduncle or Restiform Body.*

An examination of the constitution of the restiform body by the myelination method seems to show that it is composed of several tracts, which are enumerated by BECHTEREW (17) in the order of their myelination, as follows :—

- (a.) The fibres of the direct cerebellar tract.
- (b.) Fibres from the nucleus cuneatus of the same side.
- (c.) Fibres from the nucleus lateralis of the same side.
- (d.) Superficial arcuate fibres from the nuclei of the posterior columns of the opposite side.
- (e.) The arcuate fibres from the inferior olivary body of the opposite side. These fibres myelinate during the last month of intrauterine life.

We have been able, by the degenerative method, to differentiate the following tracts in the restiform body of monkeys :—

- (a.) The cerebello-olivary system.
- (b.) The direct cerebellar tract.
- (c.) Fibres from the clavate nucleus of the same side.
- (d.) Fibres from the cuneate nucleus of the same side.

(a.) *The Cerebello-olivary System* has already been described (p. 739) and considered as the great efferent channel of the inferior peduncle.

(b.) *The direct Cerebellar Tract.*

As a result of hemisection of the spinal cord above the lumbar enlargement, we have followed this tract as a partially sclerosed area through the upper regions of the cord in the position usually assigned to it; viz., at the periphery of the cord, anterior to the posterior cornu. At the decussation of the pyramids, it lies in front of the ascending root of the fifth nerve and the tubercle of ROLANDO, but behind and external to the tract from the nucleus of the lateral fillet. (Plate 67, fig. 3, *d.c.t.*) In the lower segments of the medulla the fibres assume an oblique course, and passing external and posterior to the gelatinous substance of ROLANDO and the ascending trigeminal root, enter the lower end of the restiform body. At first the tract occupies a peripheral position, but subsequently passes towards the centre, in which position it enters the cerebellum along with the fibres from the cuneate nucleus. Passing external to the corpus dentatum, it terminates in the middle lobe of the same and also of the opposite side.*

The origin of many of the fibres of this tract from the cells of CLARKE'S vesicular

* The termination of the direct cerebellar tract in the cerebellum has been variously stated. VON MONAKOW (23), VEJAS (13), and BECHTEREW (12) traced it into the superior vermiform process of the same side, while AUERBACH (32) and BRUCE (16) have followed it to the opposite side. Our observations, which have been made by MARCHI'S method, show that it ends on both sides, but chiefly on the opposite side of the superior vermiform process.

column, originally described by KÖLLIKER, FLECHSIG, and others, has been experimentally confirmed by MOTT (37), who traced degeneration in the direct cerebellar tract after destruction of this group of cells. Although the majority of the fibres of the tract arise in this way from the lower thoracic segments of the cord, it is stated to receive accessions of fresh fibres from cells which, few in number, form the upper continuation of CLARKE'S column.

The antero-lateral ascending tract of GOWERS has been regarded by LOEWENTHAL (31) as the ventral part of the direct cerebellar tract, but the different dates at which these tracts receive their medullary sheaths,* appear to indicate a functional differentiation.

(c.) *Fibres from the Clavate Nucleus.*

This nucleus forms the superior termination of the column of GOLL, which consists largely of the direct continuations of some of the fibres of the posterior nerve roots.

Unilateral destruction of the nucleus was followed by degeneration in two directions:—

(1.) Degeneration through the restiform body of the same side into the lateral lobe of the cerebellum.

(2.) Complete degeneration of the internal system of arcuate fibres, and slight of the middle system on the same side, and in the inter-olivary layer and mesial fillet of the opposite side. (Plate 68, figs. 5 and 6, *i.a.f.* and *i.s.*)

The tract in the restiform body is of small size and occupies a dorsal position. We were able to trace it into the cerebellum lying immediately external to the tract from the vermiform process to DEITERS' nucleus. (Plate 69, fig. 5, *e.v.t.*)

We obtained no evidence of degeneration in the opposite restiform body.

These observations confirm the existence of direct fibres from the clavate nucleus to the cerebellum, as described by EDINGER (22) and BRUCE (16), working by the myelination method. Our investigations, therefore, are in harmony with those of EDINGER (22 and 38) as to the existence of an uncrossed connection between the clavate nucleus and the cerebellum.

Our observations show that the fibres of the column of GOLL pass into the post-pyramidal or clavate nucleus, thence on the one hand into the internal, and, to a lesser extent, into the middle arcuate system of fibres and opposite inter-olivary layer; and, on the other hand, into the restiform body, through which they reach the cortex of the cerebellum.

(d.) *Fibres from the Cuneate Nucleus.*

This nucleus, which consists of two portions, external and internal, characterised

* BECHTEREW ('Neurol. Centralbl.,' 1885, p. 155) puts the date of myelination of the antero-lateral ascending tract at the commencement of the eighth month of foetal life, while the direct cerebellar tract is already medullated by the fifth month (BRUCE).

by a difference in the size and shape of the nerve cells, receives the direct fibres from the posterior roots of the upper cervical region of the spinal cord.*

Destruction of this nucleus was attended by the following degenerations :—

(1.) Through the restiform body into the cerebellum of the same side.

(2.) In the middle system of arcuate fibres, and, to a small extent, of the internal arcuate fibres of the same side; and in the inter-olivary layer and mesial fillet of the opposite side.

There was no degeneration through the superficial arcuate fibres to the opposite restiform body. It is stated by BECHTEREW (35) that crossed fibres from the nucleus cuneatus are interrupted in the opposite arciform nucleus, which may account for their non-appearance in the opposite restiform body. The tract, which occupies a similar position to that from the clavate nucleus in the restiform body, could be traced through the medulla of the cerebellum towards the cortex of the lateral and middle lobes (Plate 69, fig. 5).

2. THE FILLET SYSTEMS.

We may now consider the tracts which enter into the composition of the fillet or lemniscus (Schleife).

This name has been applied to two independent tracts, the mesial and the lateral, both of which have formed the subject of our experimental investigation.

(a.) *The Mesial Fillet* (obere Schleife).

The mesial fillet has been stated by some observers to degenerate in a descending direction (VON MONAKOW (39), FLECHSIG and HÖSEL (40), HÖSEL (41), HOMÉN (42), SPITZKA (43)); by others in an ascending direction (VEJAS (13), ROSSOLYMO (44), MEYER (45), MIURA (46)); while others have described it as degenerating in both directions (MEYER (45), BRUCE (16)).

In consequence of the diversity of opinion as to the direction in which the fillet degenerates, both its origin and its termination have been variously stated by observers. Those who have observed its degeneration in a descending direction, indicate its origin in the cerebral cortex in close relation to that of the pyramidal fibres, while others look upon this region as its termination. MENDEL (47) considers that the fillet springs from the cells of the grey matter forming the wall of the third ventricle; while its origin somewhere above the level of the subthalamic region is suggested in the description given by WITKOWSKI (48), DÉJÉRINE (49), and BRUCE (16).

One point is all but universally admitted, viz., the method in which the fillet is disposed in the medulla oblongata, whether this be regarded as its origin or its termi-

* SHERRINGTON (30) has pointed out that the majority of the root fibres of the second cervical nerve enter the external cuneate nucleus.

nation. The fillet fibres forming the inter-olivary layer are continuous across the raphé as deep arcuate fibres to the clavate and cuneate nuclei of the opposite side, with the nerve cells of which they are in relation.

Some investigators have described certain other connections of the fillet, *e.g.*, with the inferior olivary body of the same side (MEYNERT (50), ROLLER (51), MENDEL (47)); with the corpus trapezoides (FREUD (52)); with the anterior ground bundles of the spinal cord (HOMÉN (42), SPITZKA (43)); with the "fasciculus solitarius" (SPITZKA (43)); and with the middle lobe of the cerebellum (MARCHI (2)). In its course towards the cerebrum, the fillet is said to receive accessions of fibres from the nuclei of the sensory cranial nerves (ROLLER), from little clumps of nerve cells scattered in its course—the "fillet flock" of ROLLER; and from the nucleus reticularis tegmenti pontis (BECHTEREW (53)).

Our own investigations have determined the following relations of the mesial fillet.

Origin.—The fibres which form the fillet arise from the clavate and internal cuneate nuclei. Unilateral destruction of these nuclei separately was followed by ascending degeneration in the fillet of the opposite side, which we traced as far as the sub-thalamic region. Each nucleus gives off from its ventral aspect a series of fibres known respectively as internal and middle arcuate fibres. As the post-pyramidal or clavate nucleus has its greatest development distal, or caudad to, the cuneate nucleus, the internal arcuate fibres arising therefrom attain their maximum development lower down in the central axis than the middle arcuate system.

We have found that the degeneration of the internal arcuate fibres resulting from destruction of the clavate nucleus occupies a more distal and ventral situation in the opposite inter-olivary layer than the degeneration of the middle arcuate fibres from the internal cuneate nucleus (Plate 68, fig. 6, and Plate 69, fig. 2). The portion of the fillet lying ventral to the inferior olivary body, and separating it from the anterior pyramid, is formed by the most distal of the internal arcuate fibres arising from the clavate nucleus. The inter-olivary layer is, therefore, composed of two sets of fibres, the distal and ventral set arising from the clavate nucleus, the proximal and dorsal from the internal cuneate nucleus of the opposite side. FLECHSIG and others have shown that the arcuate fibres from the cuneate nucleus medullate at a much earlier period than those from the clavate nucleus. These two sets of fibres eventually inter-mix to a certain extent, for, in sections through the pons Varolii, after individual destruction of these nuclei, normal fibres were observed scattered throughout the degenerated area, although those from the respective nuclei retain, to some extent, their relative ventral and dorsal position (Plate 69, figs. 3 and 5, *i.s.*).

The fibres, which degenerate after destruction of the clavate and cuneate nuclei, are not confined to the inter-olivary layer proper, but include some which lie ventrally and externally to the olive, as well as many which appear to occupy the hilum olivæ (Plate 69, fig. 2).

There was no atrophy of the cells of the corpus dentatum olivæ.

The arcuate fibres, as they pass through the *formatio reticularis grisea*, are seen to converge towards the middle line, but, as soon as the raphé is crossed, they bend at a right-angle and pass up in the long axis.

Course.—The fillet, formed in the inter-olivary layer in the manner described, was readily traced through the upper part of the medulla, at the proximal margin of which it passed amongst the fibres of the corpus trapezoides, without forming any connection with this structure. By means of the degenerative method the fillet is very sharply defined from the posterior longitudinal bundle and central tegmental tract, which are observed lying respectively dorsally and externally (Plate 69, fig. 5, *m.f.*). At the upper margin of the pons Varolii, both the shape and the position of the fillet are altered. Instead of a compact strand of fibres cut transversely in frontal sections, it forms a narrow layer of fibres cut obliquely (Plate 70, fig. 1, *m.f.*). It is said by some observers (BRUCE and others) to give fibres by the lateral fillet to the posterior corpora quadrigemina, but we have been unable to trace any such connection. The portion of the fillet lying mesial to the nucleus reticularis tegmenti pontis is continued upwards in the same relative position, but we have been unable to trace it beyond the roots of the third cranial nerve. The remainder passes towards the anterior quadrigeminal bodies. Fibres are given off to the nates and they can be traced up to, but not through, the decussation dorsal to the Sylvian aqueduct. From the fact that no degeneration could be traced across the middle plane, we assume that the fillet fibres end in the ganglia on the same side as that to which they have been traced, thus establishing a cross relation between the anterior tubercles of the corpora quadrigemina and the posterior columns of the spinal cord (Plate 70, fig. 2, *m.f.*).

The remainder of the fillet may still be traced onwards to the subthalamic region, reduced in size, lying external to the red nucleus of the tegment, but we have been unable to trace this portion beyond the outer and ventral part of the optic thalamus (Plate 70, fig. 3, *m.f.*).

We have not obtained any corroboration of a direct ascent to the cerebral cortex as held by FLECHSIG and HÖSEL (40). FLECHSIG (54) was formerly of opinion that the fillet was broken in its continuity by the intervention of cells in the optic thalamus.* This view is also confirmed by the observations of SINGER and MÜNZER (54), who found atrophy of the opposite fillet as far as the optic thalamus after destruction of the cuneate nucleus.

Inasmuch as we have found that destruction of the nuclei of the posterior columns is not followed by any defects of sensibility, we would argue that the tracts which spring from these nuclei and form the fillet are not the path of sensation proper.

[* The observations of MAHAIM ('Arch. f. Psych.,' vol. 25, p. 343) appear to confirm the view that the fillet is broken by the intervention of cells in the ventral portions of the optic thalamus,—August, 1894.]

(b.) *The Lateral Fillet* (untere Schleife).

During the course of our experiments upon the cerebellum, the lateral fillet was accidentally wounded in one instance, viz., in Exp. 5, in which the left lateral lobe was extirpated. Resulting from this lesion, as has been pointed out on p. 742, a tract of degeneration was traced through the lower portion of the pons and the medulla oblongata into the lateral column of the spinal cord, where its position and relations have been already described and figured. On examining sections from this case above the lesion, it was found that the lateral fillet had also undergone degeneration upwards as far as the posterior corpus quadrigeminum on the same side, and that the so-called nucleus of this structure chiefly on the mesial aspect was also degenerated (Plate 67, fig. 6, *p.c.q.*). A more careful examination of the lesion itself showed that in addition to the injury to the fibres of the lateral fillet, its nucleus (*nucleus lemnisci lateralis*) was also destroyed (Plate 67, fig. 6, *X.*).

In order to investigate these points more in detail, the lateral fillet was submitted to special experimentation. For this purpose it was exposed by the method employed to divide the superior cerebellar peduncle. By careful retraction of the cerebellar folia, the lateral fillet was displayed where it forms the lateral wall of the tegmentum pontis in its ascent towards the posterior corpus quadrigeminum and divided transversely.

Exp. 31. *Macacus rhesus*. April 18th, 1893.

The symptoms following this lesion were essentially the same as those following removal of the lateral lobe of the cerebellum.

After one month the animal was killed and the brain prepared for examination by MARCHI's method.

The fillet had been divided above the level of the nucleus lemnisci and degeneration was traced into the testis on the same side. No degeneration was observed to pass down into the pons or medulla.

Exp. 32. *Macacus rhesus*. June 7th, 1893.

In this case the lesion (also on the left side) was made somewhat lower and deeper, so as to destroy the nucleus lemnisci as far as possible. Examination by MARCHI's method, after the animal had lived fifteen days, revealed degeneration in two directions: upwards into the posterior corpus quadrigeminum, and downwards into the pons and medulla oblongata and lateral column of the spinal cord on the side of lesion. The tract in the pons, medulla, and cord occupied the position already described above (p. 742).

In further confirmation of these observations, we found that in Exp. 18, where the middle cerebellar peduncle was divided, the tract from the nucleus of the lateral fillet had been injured where it lies immediately mesial and ventral to the motor root and

nucleus of the fifth nerve. Consequent upon this lesion, the tract was clearly traced into the lateral column of the spinal cord. There was no upward degeneration of the lateral fillet itself, nor was the nucleus lemnisci lateralis involved in the lesion.

These observations show that from the nucleus of the lateral fillet there emerge two tracts, one passing upwards, as the lateral fillet, to the posterior corpus quadrigeminum, the other downwards through the pons Varolii and medulla oblongata into the lateral column of the spinal cord.

SERIES D.—THE RELATIONS OF THE FIFTH NERVE.

During the course of our investigations upon the middle and inferior cerebellar peduncles, there was observed, in addition to the symptoms due to the lesion of the peduncle as such, more or less anæsthesia in the region of distribution of the fifth cranial nerve on the same side; and, upon microscopic examination of the medulla oblongata and pons Varolii, degeneration of the roots of this nerve was detected.

A special series of experiments was, therefore, undertaken with the object of investigating the central connections of this nerve, including the so-called "cerebellar root" of some authors. This comprised:—

(1) Section of the sensory division of the nerve between the Gasserian ganglion and the surface of the pons Varolii (Exps. 33, 34, and 35).

(2) Intrapontine section of the motor root. This was effected in two instances during the performance of another experiment (Exps. 5 and 18).

(3) Section of the ascending root of the nerve in its course in the medulla oblongata (Exps. 23 and 24).

(4) Destruction of the dorso-lateral aspect of the medulla oblongata, involving the ascending root and the tubercle of ROLANDO (Exps. 36 to 39 inclusive).

We have reserved for future description the consideration of the symptoms following these experimental lesions, and confine ourselves here to the degenerations.

(1.) *Degenerations following Section of the Sensory Division between the Gasserian Ganglion and the Brain.*

As a result of this lesion, degeneration was traced through the stump of the nerve into the lateral region of the pons Varolii (Plate 70, fig. 4, V.). From this point it was readily followed through the lower portion of the pons, medulla oblongata, and cervical portion of the spinal cord as far as the level of the second cervical nerve-root (Plate 69, figs. 4 and 5, V. *as.*).

The bulk of the fibres of the sensory division, after passing amongst the fibres of the middle cerebellar peduncle, bend distally directly into the "ascending" root; a certain number, however, appear to pass into and terminate in the so-called sensory nucleus of the fifth (*convolutio quinti*). The root diminishes in size as it passes

towards the spinal cord. Relatively few fibres are given off from the root through the substantia gelatinosa into the reticular formation of the medulla. At the place where the gelatinous substance expands into the tubercle of ROLANDO, the root becomes flattened, so as to form a capsule of white matter on the external and anterior surface of the tubercle (Plate 70, fig. 6, *s.g.r.*). At this place the greater number of the fibres of the root bend at a right-angle and pass through the gelatinous substance into the grey matter of the posterior horn. Here they form a network of fine medullated nerve fibres, which we have found atrophied when the ascending root is sclerosed (*ibid.*, V. *as.*). This network forms the terminal arborescence of the fibres of the roots and their collaterals, but the cells of the posterior horn itself did not appear to have undergone atrophy after section of the nerve. It was not possible to trace degeneration beyond the medullated network in which the fibres appear to terminate.

To summarize the changes following section of the sensory division, there were observed:—

(a.) Degeneration and atrophy of the fibres entering the so-called sensory nucleus of the fifth nerve.

(b.) Degeneration and sclerosis of the so-called “ascending” root as far as the second cervical nerve-root.

(c.) Degeneration and atrophy of the fibres which pass from this root through the gelatinous substance into the posterior horn of grey matter.

It was specially noted that after section of this root the so-called “descending” root of the fifth nerve remained intact.

Similar changes were found following lesion of the ascending root in its intramedullary course, but only below the seat of the lesion; while, as a result of destruction of the postero-lateral aspect of the medulla (tubercle of ROLANDO), no degeneration was traced in the course of the root above the lesion.

The descending nature of the degeneration of the so-called ascending root of the fifth nerve, which we have observed, is in harmony with the observations of BECHTEREW (55) and BREGMANN (56), who likewise traced it after section of the nerve between the Gasserian ganglion and the brain. TOOTH (57) and SHERRINGTON* have also confirmed the same fact.

The general statement may be made here, that the symptoms which followed section of this root consisted of anæsthesia to all forms of sensibility in the area supplied by the fifth cranial nerve. In this respect it compared with division of a posterior spinal root.

LENHOSSEK (58) and TOOTH (57) have shown that the fibres of the ascending root of the fifth nerve are analogous to the middle group of fibres entering the spinal cord

* Reference is made by TOOTH in his paper (*Journal of Physiology*, Supplement, 1892, p. 779) to our observations, to whom they had been privately communicated. They are also referred to by SHERRINGTON (30).

by the posterior roots, which fibres bear the same relation to the substantia gelatinosa spinalis as those of the ascending root do to that of the medulla.*

(2.) *Intrapontine Section of the Motor Root.*

This was followed by atrophy of the so-called descending root, which is traceable as high as the anterior quadrigeminal bodies, and by atrophy of the vesicular cell-groups, which lie along the crescentic mesial aspect of the root in the outer portion of the Sylvian grey matter, from which the fibres of the roots are said to arise.

We have found atrophy of this root after the following lesions:—

- (a.) Destruction of the motor root in the tegment of the pons (Exps. 5 and 18).
- (b.) Section of the descending root itself where it lies under the mesial aspect of the superior cerebellar peduncle (Exps. 15 and 17).

The atrophy of the fibres of this root was not, according to our observations, a degenerative, but merely a simple atrophy.

In one case (Exp. 17), in which the changes could be noted in an early stage, the animal having died four days after the performance of the operation, the fibres of the root appeared diminished in size, and, when observed in bulk, were less well stained than those of the opposite side, but there were no signs of breaking up of the medullated sheath into globules of myeline, which is the characteristic feature of secondary degeneration.

When examined in a later stage (Exps. 5, 18), some weeks after the operation, the root, viewed as a whole, presented a very feeble staining reaction, and when examined under a high power of the microscope the nerve fibres, although small, presented a normal structure. Some fibres, also, had disappeared. In this way the spaces between the nerve fibres were considerably enlarged (Plate 70, fig. 5; Plate 68, fig. 4, *Vd.*).

The cells on the side of the lesion were shrunken and atrophied.

There is as yet no general agreement into which division of the nerve fibres of the descending root pass. MEYNERT (59), OBERSTEINER (60), MENDEL (61), and BECHTEREW (55), have stated that it joins the portio-major or sensory division, while HENLE (62), FOREL (63), PONIATOWSKY (64), BREGMANN (56), and BRUCE (16), are of opinion that it joins the portio-minor, a view to which our own observations lend support.

A connection has also been stated to exist between the cells of the substantia ferruginea and the fibres of the descending root. MENDEL (61) has observed atrophy both of the cells of the substantia ferruginea and of the fibres of the descending root in a case of old standing facial hemiatrophy. From this observation he has regarded

* According to BECHTEREW (55), the ascending trigeminal root is medullated in fetuses 25–28 cms. long, at which period all the tracts of the spinal cord are non-medullated, with the exception of the posterior root-zones and the antero-lateral ground bundles.

the descending root as trophic in function. So far as we are aware, this observation stands by itself, for HOMÉN (65), who especially examined this point in a case of facial hemiatrophy, was unable to corroborate these observations.

(3.) *The so-called Cerebellar Root of the Fifth Nerve.*

It is stated by OBERSTEINER (60), that the sensory division of the fifth gives fibres directly to the cerebellum. This has, however, been controverted by BECHTEREW (12) and PONIATOWSKY (64). The former regards the so-called cerebellar root as a strand of fibres, which passes from the superior olivary body through the ascending root to the roof nuclei of the cerebellum.

We cannot from our own observations confirm the existence of a direct cerebellar root of the trigeminal nerve. For after section of the nerve, extra or intra-pontine, we have been unable to trace any tract into the cerebellum; and, conversely, we have failed after cerebellar extirpation to detect any degeneration in the nuclei or roots of the nerve.

We have already stated on p. 740 that the "direct sensory cerebellar tract" of EDINGER is, according to our observations, an efferent tract from the middle lobe of the cerebellum to the nucleus of DEITERS.

REFERENCES.

- 1A. LUCIANI. *Il Cervelletto.* Firenze, 1891.
- 1B. RUSSELL. (1) *Brit. Med. Journ.* September 23rd, 1893, p. 680.
(2) *Proc. Roy. Soc.*, vol. 53, 1893, p. 459.
[Also *Proc. Roy. Soc.*, vol. 55, No. 331, p. 57.]
2. MARCHI. *Sull' origine e decorso dei Peduncoli Cerebellari e sui loro rapporti cogli altri Centri nervosi.* Firenze, 1891.
- 2'. MARCHI'S method described in *Rivist. Speriment. di Freniatria e di Med. Legale*, 1887, 12, 3.
3. FERRIER. *Functions of the Brain.* London, 1876.
4. MURATOFF. *Archiv f. Anat. u. Physiol.*, 1893, p. 99.
5. SINGER and MÜNZER. *Denkschrift d. Akad. d. Wissensch. Wien; Math-Natur. Klasse*, vol. 55, p. 163.
6. OBERSTEINER. *Arbeiten*, 1892, p. 130.
7. SANDMEYER. *Protocol vom X. Congress für innere Medicin.* Wiesbaden, 1891, p. 349.
8. CRAMER. *ZIEGLER'S Beiträge*, vol. 11, Hft. 1, p. 39, 1892.
9. MENDEL. *Neur. Centralbl.*, 1882, p. 241.
10. FOREL. Referred to by BRUCE; *Illustrations of the Mid- and Hind-Brain*, p. 51.

11. BECHTEREW. Archiv f. Anat. u. Physiol., 1886, p. 185.
12. BECHTEREW. Die Leitungsbahnen im Gehirn und Rückenmark, 1894, p. 135.
13. VEJAS. Archiv f. Psychiatrie, 1885, vol. 16, p. 200.
14. BECHTEREW. Neur. Centralbl., 1885, p. 121.
16. BRUCE. Illustrations of the Mid- and Hind-Brain. Edinburgh, 1892.
17. BECHTEREW. Archiv f. Anat. u. Physiol., 1886, p. 403.
18. MEYNERT. Referred to by BRUCE, *op. cit.*, p. 16.
19. GUDDEN. Neur. Centralbl., 1882, p. 455.
20. DARKSCHEWITSCH and FREUD. Neur. Centralbl., 1886, p. 121.
21. DEITERS. Untersuchungen über Gehirn und Rückenmark. Braunschweig, 1865.
22. EDINGER. Zwölf Vorlesungen ü. d. Bau. d. nervösen Centralorgane, 1892, p. 118.
23. VON MONAKOW. Archiv f. Psychiatrie, vol. 14, p. 1, 1883.
24. ONUFROWICZ. Archiv f. Psychiatrie, vol. 16, p. 711, 1885.
25. HANS HELD. Neur. Centralbl., 1890, p. 481, and Abhandlungen der math. phys. Klasse der Königl. Sächs. Gesellsch. der Wissensch., vol. 18, No. 6, 1892 (Separat-Abdruck).
26. FLECHSIG. Die Leitungsbahnen im Gehirn u. Rückenmark, 1876.
27. BECHTEREW. Die Leitungsbahnen, 1894, p. 130.
28. VON MONAKOW. Neur. Centralbl., 1885, p. 265.
29. VON MONAKOW. Neur. Centralbl., 1889, p. 550.
30. SHERRINGTON. Journal of Physiology, vol. 14, p. 255.
31. LOEWENTHAL. Rev. Médicale de la Suisse Romande, 1885.
32. AUERBACH. VIRCHOW'S Archiv, 1890, vol. 121, p. 199.
33. MOTT. Brain, part 58, 1892, p. 215.
34. TOOTH. Brain, parts 59 and 60, 1892, p. 397.
35. BECHTEREW. Die Leitungsbahnen, p. 68.
36. BECHTEREW. Die Leitungsbahnen, p. 47.
37. MOTT. Brain, 1890, p. 433.
38. EDINGER. Neur. Centralbl., 1885, p. 73.
39. VON MONAKOW. Neur. Centralbl., 1885, p. 265, also Correspondenzblatt f. Schweizer Aerzte, 1884, Nos. 6 and 7.
40. FLECHSIG and HÖSEL. Neur. Centralbl., 1890, p. 417.
41. HÖSEL. Archiv f. Psychiatrie, vol. 24, p. 452, 1892.
42. HOMÉN. VIRCHOW'S Archiv, vol. 88, p. 61, 1882.
43. SPITZKA. New York Medical Record, 1884, p. 393.
44. ROSSOLYMO. Archiv f. Psychiatrie, vol. 21, p. 897, 1890.
45. MEYER. Archiv f. Psychiatrie, vol. 13, 1882, p. 1, and vol. 17, 1886, p. 439.
46. MIURA. ZIEGLER'S Beiträge, vol. 11, part 1, p. 91, 1892.

47. MENDEL. Neur. Centralbl., 1883, p. 262.
48. WITKOWSKI. Archiv f. Psychiatrie, vol. 14, 1883, p. 410.
49. DÉJÉRINE. Archiv. d. Physiol., 1890, No. 3, p. 558.
50. MEYNERT. Referred to by BRUCE, *op. cit.*, p. 43.
51. ROLLER. Archiv f. Mikroskop. Anatomie, vol. 19, 1881, p. 340.
52. FREUD. Neur. Centralbl., 1885, p. 268.
53. BECHTEREW. Neur. Centralbl., 1885, p. 337.
- 54A. FLECHSIG. The most complete paper on the myelination of the Fillet is to be found in König. Sächs. Gesellsch. der Wissensch., May 4th, 1885. The paper is entitled "Über die Schleifenschicht." A summary of it is given in the Neur. Centralbl., 1885, p. 356, by FLECHSIG.
- 54B. SINGER and MÜNZER. Denkschrift d. K. Akad. d. Wissensch. Wien, 1890, p. 569.
55. BECHTEREW. Neur. Centralbl., 1887, p. 289.
56. BREGMANN. Jahrbuch f. Psychiatrie, vol. 11. Reference in Neur. Centralbl., 1893, p. 156.
57. TOOTH. Journ. of Physiology. Supplement, 1892, p. 773.
58. LENHOSSEK. Archiv f. Mikroskop. Anat., vol. 39, 1889, p. 157.
59. MEYNERT. Referred to by SCHWALBE, 'Lehrbuch der Neurologie,' p. 680.
60. OBERSTEINER. "Central Nervous Organs" (Dr. HILL's Translation), p. 295.
61. MENDEL. Neur. Centralbl., 1888, p. 401.
62. HENLE and } Referred to by SCHWALBE, Lehrbuch der Neurologie, p. 680.
63. FOREL. }
64. PONIATOWSKY. Jahrbuch f. Psychiatrie, vol. 11. Reference in Neur. Centralbl., 1892, p. 780.
65. HOMÉN. Neur. Centralbl., 1890, p. 385

DESCRIPTION OF THE PLATES.

(We are indebted to Mr. J. E. BARNARD for the photographs, which have in all cases been taken direct from our original sections.)

PLATE 64.

Fig. 1. A transverse section of the medulla after extirpation of the left lobe of the cerebellum, made through the lower third of the inferior olivary body, Exp. 4; enlarged 5 diameters.

r.b. Restiform body. On the side of the extirpation, this structure

is atrophied on its ventral and mesial aspects, the dorsal and external parts being normal.

V., *as.* The ascending root of the fifth nerve, divided into several portions by white canals, the result of atrophy of the external arcuate fibres.

i.o. The inferior olivary body considerably diminished in size on the side opposite the lesion. The accessory olivary bodies are similarly atrophied.

l.m.t. Lateral medullary tract.

r.f. The reticular formation is stained lighter on the side of the lesion than on the opposite side, and also shows white canals normally occupied by external arcuate fibres.

The antero-lateral region of the medulla is flattened on the side of lesion : this is also seen in fig. 2.

The posterior longitudinal bundles (*p.l.b.*) and mesial fillet (*m.f.*) are normal.

VIII., *as.* The ascending root of the auditory nerve.

IX., *as.* The ascending glossopharyngeal root.

XII., *n.* The hypoglossal nucleus.

Fig. 2 is a section through the medulla at the middle of the inferior olive from the same case, Exp. 4 ; 5 diameters.

The lettering is the same as in fig. 1.

Fig. 3. A transverse section of the medulla at the level of the inferior olivary body from Exp. 1—complete cerebellar extirpation—4 diameters.

The lettering is the same as in figs. 1 and 2, with the following addition :—

VIII. The root of the auditory nerve.

Fig. 4 represents a section made through the medulla oblongata at the level of the genu facialis from Exp. 1—complete cerebellar extirpation—4 diameters.

b.c. The brachium conjunctivum completely sclerosed on both sides.

s.m.v. Superior medullary velum. On the left-hand side of the figure the arrow points to a tract of normal fibres containing probably the upward prolongation of the antero-lateral tract of the spinal cord. The corresponding portion on the right side is sclerosed (see p. 753.)

i.v.p. The inferior vermiform process of the cerebellum.

Py. The pyramidal tracts.

s.o. The superior olivary body.

V. and VII. the fifth and seventh cranial nerves.

Fig. 5. A transverse section of the medulla from Exp. 4—removal of the lateral lobe—4 diameters.

b.c. Brachium conjunctivum sclerosed on the side of the lesion.

s.m.v. Superior medullary velum unaffected.

s.o. Superior olivary body.

m.p. Middle peduncle.

VII., *g.* Genu facialis.

V., *as.* Ascending trigeminal root.

Fig. 6 represents a transverse section through the pons Varolii from Exp. 1—complete cerebellar extirpation—5·5 diameters.

b.c. The sclerosed brachium conjunctivum in the tegment of the pons.

m.p. The middle peduncle showing sparseness of the fibres which pass amongst the bundles of pyramidal fibres (*py.*). Ventrally it presents a flattened appearance.

n.t.p. The nucleus tegmenti pontis.

p.l.b. Posterior longitudinal bundles.

m.f. Mesial fillet.

c.t.t. Central tegmental tract.

l.f. Lateral fillet.

IV. The fourth cranial nerve.

Aq.S. The aqueduct of Sylvius.

V., *d.* Descending trigeminal root.

PLATE 65.

Fig. 1. A transverse section of the pons from Exp. 4—removal of the left lateral lobe of the cerebellum. This section has been made just below the decussatio brachiorum and compares with the next (fig. 2), which has been made just above it; 3·6 diameters.

b.c. The normal brachium conjunctivum. Its position on the opposite side is characterized by an entire absence of fibres.

c.t.t. Central tegmental tract.

m.f. Mesial fillet.

m.p. Middle peduncle, of which *SS.* represents the superficial layer.

Py. The bundles of pyramidal fibres.

a.c.q. Anterior quadrigeminal bodies.

Fig. 2. A transverse section of the pons from Exp. 4. The section has been made immediately above the decussation and represents the atrophied peduncle upon the side opposite the lesion; 4·5 diameters. The lettering is the same as in Plate 65, fig. 1.

c.g.e. External geniculate body.

Fig. 3 is a section through the crura cerebri at the level of the red nuclei and roots

of the third nerve from Exp. 1—complete cerebellar extirpation—4·25 diameters.

r.n. The red nuclei, atrophied upon both sides. In addition to the atrophy of the nuclei, the brachia conjunctiva, which partly pass through them and partly lie dorso-externally (see Plate 65, fig. 4) are atrophied.

s.n. Substantia nigra.

m.f. Mesial fillet.

a.c.q. Anterior quadrigeminal bodies.

III. Nuclei and roots of the third cranial nerve.

Fig. 4 has been made through the posterior part of the optic thalamus from Exp. 5—extirpation of the left lateral lobe—2·5 diameters.

r.n. and *b.c.* The red nucleus and brachium conjunctivum are atrophied on the side opposite the lesion (left side of figure.) The latter structure is seen passing dorso-externally towards the optic thalamus.

O.th. Optic thalamus.

P.C. Posterior commissure.

m.f. Mesial fillet.

s.n. Substantia nigra.

O.tr. Optic tract.

III. The roots of the third cranial nerve.

Fig. 5 is a section through the subthalamic region from the same case as the preceding (fig. 4, Exp. 5). It represents the continuation of the brachium from the red nucleus to the optic thalamus; 2·5 diameters. The lettering is the same as in the preceding figure, with the following additions:—

g.h. Ganglion habenulæ.

f.r. Fasciculus retroflexus.

c.s. Corpus subthalamicum, or body of LUYS.

z.i. Zona incerta.

l.l. Latticed layer, or "Gitterschicht."

i.c. Internal capsule.

Fig. 6 is a section through the medulla from Exp. 7, in which the middle lobe of the cerebellum was removed. As the section has not been cut quite horizontal some structures are seen on one side which are not shown on the other; 3 diameters.

b.c. The brachium conjunctivum.

D.n. The nucleus of DEITERS (large-celled external auditory nucleus) shown only on the right side of the figure.

e.v.t. Efferent vermiform tract, which passes from the middle lobe to DEITERS' nucleus, and which is seen to have undergone sclerosis in this section (see text, p. 740).

V., *a.s.* Ascending trigeminal root.

VII., *n.* and VII. The nucleus and root of the seventh nerve.

VIII. The root of the eighth nerve on which is seen the accessory nucleus (*a.n.*).

m.f. Mesial fillet.

PLATE 66.

Fig. 1. A frontal section through the pons from Exp. 7—extirpation of the middle lobe of the cerebellum—4 diameters. The section presents a normal appearance.

p.q.c. Posterior quadrigeminal bodies.

l.f. Lateral fillet.

m.f. Mesial fillet.

b.c. Brachium conjunctivum.

V., *d.* Descending trigeminal root.

IV. Root of the fourth cranial nerve.

Py. Pyramidal tracts.

m.p. Transverse fibres of the pons.

P.l.b. Posterior longitudinal bundles.

Fig. 2. DEITERS' nucleus, magnified 40 diameters, from Exp. 5, in which the lateral lobe of the cerebellum was extirpated. In this case the fibres and cells of the nucleus present a normal appearance.

Fig. 3. DEITERS' nucleus, magnified 40 diameters, from Exp. 4—lateral lobe extirpation. The figure shows the nucleus sclerosed as a result of traumatic degeneration. The cells and network of fine medullated fibres have almost entirely disappeared.

Fig. 4. Portion of transverse section of the spinal cord at the level of the second cervical nerve from Exp. 7, showing the position of the *anterior descending tract* (*vide* text, p. 743); 40 diameters.

a.m.f. The anterior median fissure.

a.d.t. The anterior descending tract.

a.c. The anterior cornua.

a.n.r. The anterior nerve roots.

Fig. 5. A transverse section of the spinal cord at the second cervical segment, from the case of complete cerebellar extirpation (Exp. 1); 13 diameters (*vide* text p. 742).

Fig. 6. A transverse section of the spinal cord through the cervical enlargement, from a case of hemisection of the spinal cord, to show the descending degenerations resulting therefrom; 10 diameters.

c.p.t. Crossed pyramidal tract.

a.l.d.t. Antero-lateral descending tract.

PLATE 67.

Fig. 1. A transverse section of the spinal cord from the fifth dorsal segment to show the position of the tract from the lateral fillet (Exp. 18); 17 diameters.

l.f.t. The lateral fillet tract.

Fig. 2. Transverse section of the spinal cord from the second cervical segment to show the tract from the lateral fillet (Exp. 5); 10·5 diameters.

l.f.t. The lateral fillet tract.

Fig. 3. Transverse section at the level of the pyramidal decussation from the same case as fig. 2, Plate 67; 8·3 diameters. (This section has been reversed in mounting.)

l.f.t. The lateral fillet tract.

D.c.t. The direct cerebellar tract.

f.r. The reticular formation.

s.q.r. The gelatinous expansion forming the tubercle of ROLANDO.

Fig. 4. Transverse section through the medulla at the mid-olivary region from the same case as figs. 2 and 3; 4·75 diameters. The restiform body (*r.b.*) and external arcuate fibres are atrophied on the side of lesion, and the inferior olive (*i.o.*) of the opposite side, due to extirpation of the lateral lobe which was accomplished in this case (Exp. 5).

l.f.t. The lateral fillet tract is seen here occupying the dorsal portion of the lateral medullary region; the fore part of which is occupied by the antero-lateral ascending tract (*a.l.asc.*).

Fig 5. From the same case as the preceding. The section has been at the level of the corpus trapezoides; 3·2 diameters.

l.f.t. The tract from the lateral fillet is seen amongst the fibres of the corpus trapezoides (*c.t.*), immediately ventral to the nucleus of the seventh nerve (VII., *n.*).

s.o. The superior olivary body.

V., *as.* The ascending trigeminal root.

Fig. 6. From the same case as the preceding figure. This represents a frontal section through the pons at the level of the trochlear decussation and shows the lesion in the tegmentum pontis and lateral fillet; 4 diameters.

× represents the lesion of the tegmentum pontis and lateral fillet.

p.c.q. Posterior corpora quadrigemina.

IV. The decussation of the fourth cranial nerves.

b.c. Brachium conjunctivum.

l.f. Lateral fillet.

m.f. Mesial fillet.

n.t.p. Nucleus tegmenti pontis; on the side opposite the extirpation

this presents an appearance of atrophy, which is not seen on the side of lesion.

c.t.t. Central tegmental tract.

PLATE 68.

Fig. 1. Frontal section through the pons from Exp. 15; showing the extent and position of the lesion of the superior peduncle (X.); 4·4 diameters.

s.m.v. Superior medullary velum.

b.c. Brachium conjunctivum.

V., *d.* Descending trigeminal root.

V., *m.* Motor root of the fifth nerve.

p.l.b. Posterior longitudinal bundles.

Fig. 2. A frontal section through the pons and cerebellum to show the nature, extent and position of the lesion of the middle peduncle and tegmentum pontis in Exp. 18; 3·1 diameters.

× × indicates the site of the lesion; the lettering is the same as in the previous figures.

Figs. 3 and 4. Frontal sections from the same case as the preceding somewhat higher up, so as to show the changes which have taken place in the transverse fibres of the pons as a result of division of the middle peduncles; 4 diameters.

From these it is seen that the fibres have not entirely disappeared, but present a diminished staining reaction and a sparseness in the grey matter of the pons.

The lettering is the same as in fig. 1, Plate 68.

n.t.p. Nucleus tegmenti pontis.

V., *d.* Descending trigeminal root somewhat atrophied on the side of lesion, from implication of the motor root at the seat of injury (fig. 2) (see also Plate 70, fig. 5, V., *d.*).

Fig. 5. A transverse section of the medulla at the lower end of the inferior olive, showing the degeneration which follows destruction of the clavate nucleus (Exp. 28); 5·2 diameters.

x.n.cl. These letters are placed over the anterior end of the clavate nucleus.

i.a.f. Internal arcuate fibres degenerated on the side of lesion.

i.s. Inter-olivary stratum.

i.n.cu. Nucleus cuneatus internus.

e.n.cu. Nucleus cuneatus externus.

m.a.f. Middle arcuate fibres in part degenerated on side of the lesion.

i.o. Inferior olivary body.

V., as. Ascending trigeminal root.

Fig. 6. Transverse section of the medulla from the same case as the preceding, somewhat higher up; 5 diameters.

i.s. Inter-olivary layer on the side opposite the lesion.

The portion of this stratum which separates the pyramids (*py.*) from the olive is chiefly degenerated.

In all respects the lettering is the same as in the preceding figure.

XII. The hypoglossal nucleus.

PLATE 69.

Fig. 1. A transverse section from the same case as the preceding at a slightly higher level; 4 diameters.

From this it is seen that only the ventral portion of the inter-olivary stratum is degenerated, the dorsal being unaffected. Owing to the section being too deeply stained this is not so clearly seen as in the following figure (fig. 2, Plate 69), where both clavate nuclei only had been destroyed.

r.b. Restiform tract, in the dorsal portion of which is seen a small area of degeneration on the side of the lesion.

e.a.f. External arcuate fibres or cerebello-olivary system.

VIII. Root of the auditory nerve.

Fig. 2. A transverse section of the medulla oblongata at the middle of the inferior olivary body from a case in which both clavate nuclei had been destroyed (Exp. 29); 5.5 diameters.

i.s. The inter-olivary stratum degenerated mainly in its ventral portion. The deeply-stained dorsal portion being formed by the middle arcuate fibres from the cuneate nucleus.

V., as. The ascending trigeminal root. On the left-hand side of the figure this structure is sclerosed owing to the trunk of the nerve having been divided between the Gasserian ganglion and the brain. Passing through it are the cerebello-olivary fibres. This portion of the figure, therefore, is the converse of Plate 64, fig. 1, *V., as.*

VIII., *asc.* Ascending root of the auditory nerve.

IX., *asc.* Ascending root of the glossopharyngeal nerve.

Fig. 3. Frontal section through the medulla and cerebellum at the level of the eighth nerve from the same case as fig. 1, Plate 69; and figs. 5 and 6, Plate 68; 3.5 diameters.

m.f. Mesial fillet, the ventral portion only of which is completely degenerated on one side, although scattered fibres may be detected in the dorsal segment.

The lettering is the same as in the preceding figures.

b.c. Brachium conjunctivum.

c.d.c. Corpus dentatum cerebelli.

VII., *n.* Nucleus of the seventh nerve.

Fig. 4. Transverse section of the medulla from a case in which the cuneate nucleus was destroyed (Exp. 22), as well as the restiform tract; 4 diameters.

× represents the lesion of the cuneate nucleus.

i.s. The inter-olivary stratum on the side opposite the lesion presents a degenerated appearance, but in this case the degeneration is chiefly confined to the dorsal portion of the mesial fillet, the ventral part showing comparatively little affection, as it is formed, as shown in the text, p. 760, by the internal arcuate fibres from the clavate nucleus.

m.a.f. The middle arcuate fibres. These have disappeared on the side of the lesion, as also have the external arcuate fibres (*r.f.*).

Owing to the fact that the restiform body was also destroyed immediately anterior to the nucleus, the external arcuate fibres (*e.a.f.*) on the same side and the opposite inferior olive (*i.o.*) are also atrophied.

r.f. The reticular formation.

V., *asc.* The ascending trigeminal root is sclerosed on the left side, as a result of division of the nerve between the Gasserian ganglion and the surface of the pons; through it pass healthy external arcuate fibres. On the side of the lesion it is normal, and through it are seen the spaces left by the atrophied external arcuate fibres.

Fig. 5. A frontal section from the same case as the preceding at the level of the sixth nerve nuclei; 3 diameters.

The lettering is similar to the preceding.

m.f. Mesial fillet. Here the degeneration in the dorsal portion of this structure is well seen; while in the cerebellum, on the right side of the figure, a large fan-shaped sclerosed area (*a.c.t.*) formed chiefly by the direct fibres from the cuneate nucleus, is observed. Owing to the fact that the restiform body was also destroyed in this case, the sclerosed area contains the fibres from the clavate tubercle, and also the direct cerebellar tract.

e.v.t. Efferent vermiform tract, or tract to DEITERS' nucleus.

a.c.t. Ascending cerebellar system.

V., *as.* The sclerosis of the ascending trigeminal root is distinctly seen on the left side, as a result of section of the nerve between the Gasserian ganglion and the pons (see also figs. 2 and 4, Plate 69).

s.o. Superior olivary body.

c.d.c. Fore-end of the corpus dentatum cerebelli.

V. The trunk of the fifth nerve.

VII., *n.* Nucleus of the seventh nerve.

Fig. 6. A section through the pons and posterior corpora quadrigemina from a case of destruction of the clavate nucleus ; 4·3 diameters.

b.c. Brachium conjunctivum.

m.f. Mesial fillet. This presents a partially degenerated appearance throughout, owing to an intermingling of the fibres from the clavate and cuneate nuclei.

m.p. Middle cerebellar peduncle.

l.f. Lateral fillet, and *p.c.g.* posterior corpora quadrigemina.

V.d. Descending trigeminal root.

n.t.p. Nucleus tegmenti pontis.

PLATE 70.

Fig. 1. Frontal section of the upper part of the pons from Exp. 22, in which the cuneate nucleus was destroyed ; enlarged 4·5 diameters.

m.f. Mesial fillet, degenerated on the left side.

d.b.c. Decussation of the brachia.

l.f. Lateral fillet.

p.c.g. Posterior quadrigeminal bodies.

a.c.g. Anterior quadrigeminal bodies.

Fig. 2. Frontal section at the level of the anterior quadrigeminal bodies from a case in which the clavate nucleus was destroyed (Exp. 28) ; 4 diameters.

The lettering is the same as in the preceding case ; the mesial fillet is degenerated on the right side.

b.c. The brachia conjunctiva above their decussation.

c.g.e. External geniculate body.

s.n. Substantia nigra.

p.c. Pes cruris.

Fig. 3. Frontal section from the same case as the preceding ; 2·75 diameters

m.f. The mesial fillet on the left side has disappeared.

O.th. Optic thalamus.

r.n. Red nuclei.

f.r. Portion of the fasciculus retro-flexus.

Fig. 4. Frontal section through the pons and cerebellum from a case of section of the fifth nerve between the Gasserian ganglion and the brain (Exp. 33) ; enlarged 3 diameters.

V. Stump of the fifth nerve on the left side.

V., *s.n.* So-called sensory nucleus of the fifth nerve.

V., *as.* Ascending trigeminal root.

m.f. Mesial fillet degenerated on both sides from destruction of both clavate nuclei.

VII. Genu facialis.

VI. Sixth cranial nerve.

c.d.c. Corpus dentatum cerebelli.

i.v.p. Inferior vermiform process of the cerebellum.

Fig. 5. Frontal section of the pons from Exp. 5, where, in addition to the extirpation of the lateral lobe, the motor root of the fifth was involved in the lesion, which destroyed the nucleus lemnisci lateralis (fig. 4, Plate 69, ×); enlarged 4 diameters (see also Plate 68, fig. 4, V., *d.*).

V., *d.* The descending trigeminal root is atrophied on the right side of the figure.

b.c. Brachium conjunctivum, atrophied on the right side of the figure.

p.c.q. Testes.

a.c.q. Nates.

m.f. Mesial fillet.

l.f. Lateral fillet.

c.t.t. Central tegmental tract.

Fig. 6. Transverse section of the pyramidal decussation from Exp. 34, in which the fifth nerve was divided between the Gasserian ganglion and the brain; 10 diameters.

V., *as.* Ascending trigeminal root, atrophied on the left side.

s.g.r. Tubercle of ROLANDO; the fine fibres passing through are atrophied on the left side.

For further illustration of the degeneration of the ascending root, see Plate 69, figs. 2, 4, and 5, V., *as.*

PLATE 71.

Fig. 1. Photograph from a case of complete cerebellar extirpation. Exp. 1 (text, p. 724).

Fig. 2. Ditto. Exp. 2 (text, p. 725).

Fig. 3. Basal aspect of the brain from a case of removal of the lateral lobe. Exp. 4 (text, p. 727).

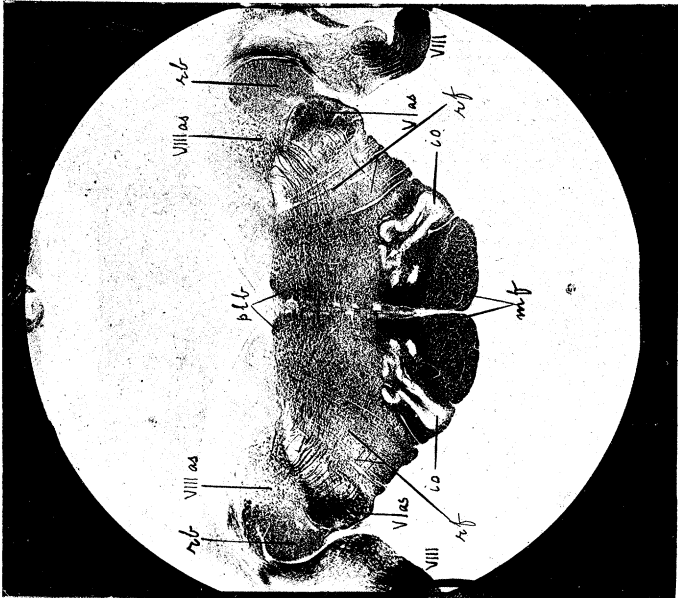
Fig. 4. The same case, showing the extent of removal of the cerebellum from behind (text, p. 727).

Fig. 5. Basal aspect of the brain from Exp. 5. Extirpation of the lateral lobe (text, p. 728).

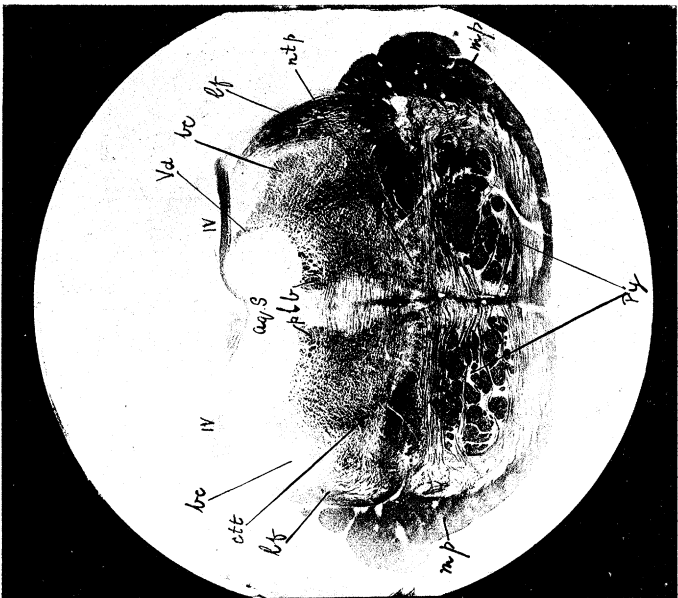
Fig. 6. Dorsal aspect of the same case (text, p. 728).

Fig. 7. Case of removal of the lateral lobe. Exp. 6 (text, p. 730).

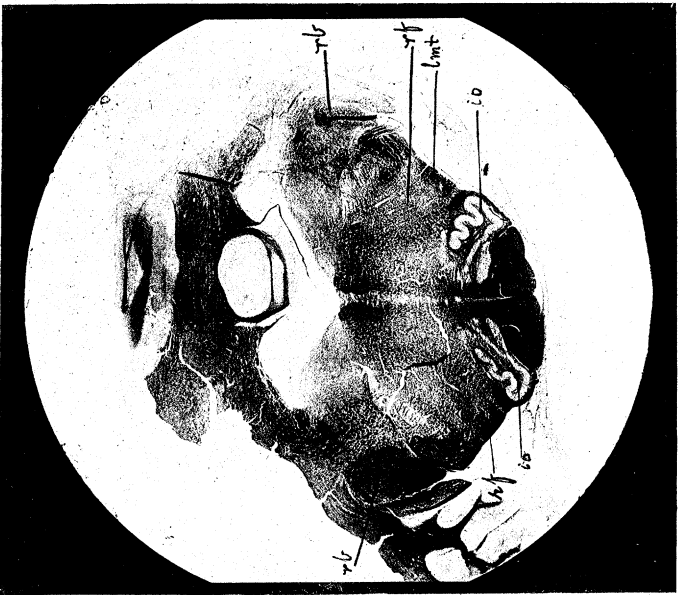
Fig. 8. Extirpation of the middle lobe. Exp. 7 (text, p. 731).



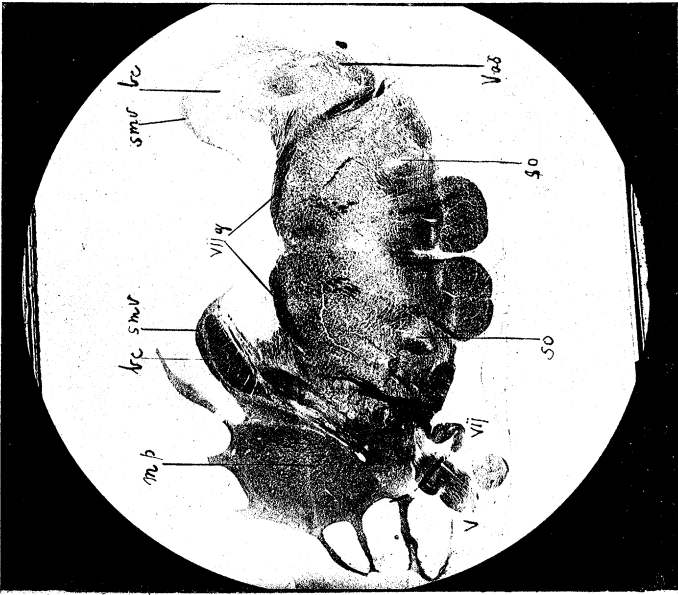
3



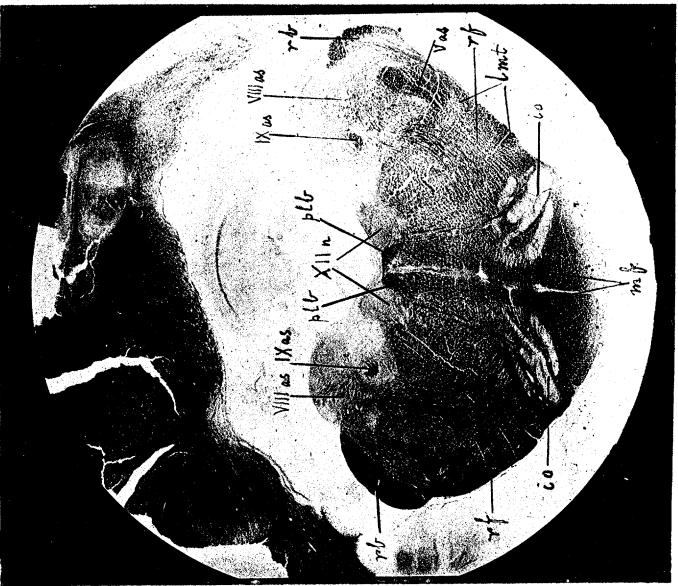
6



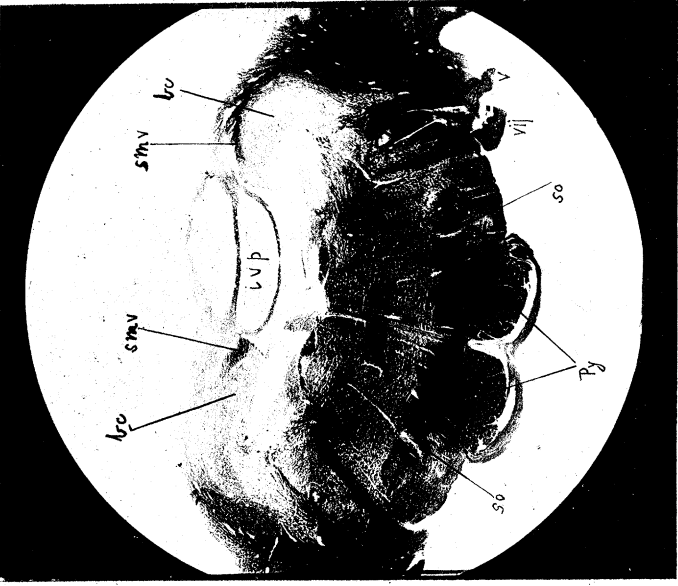
2



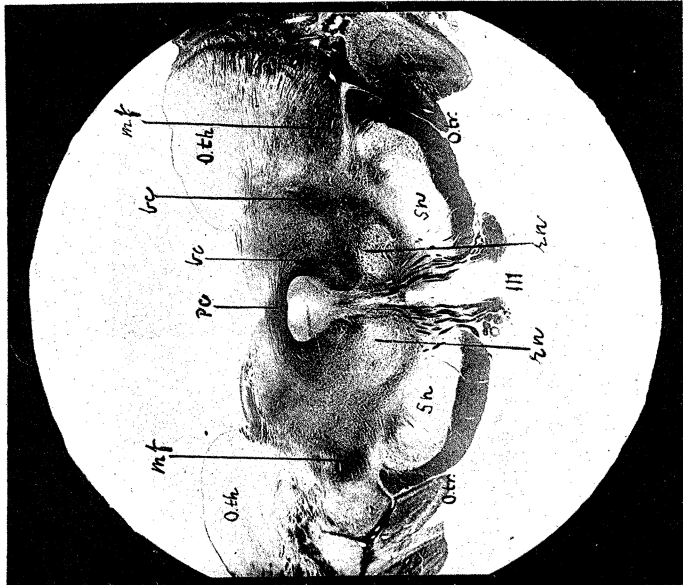
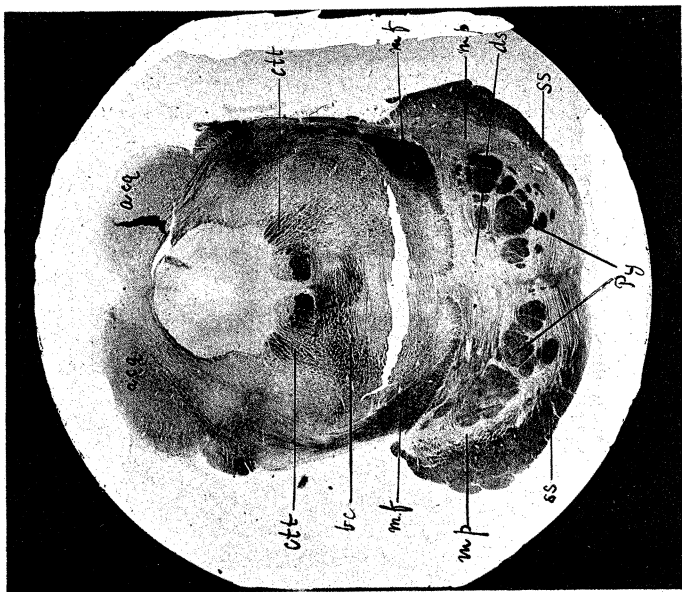
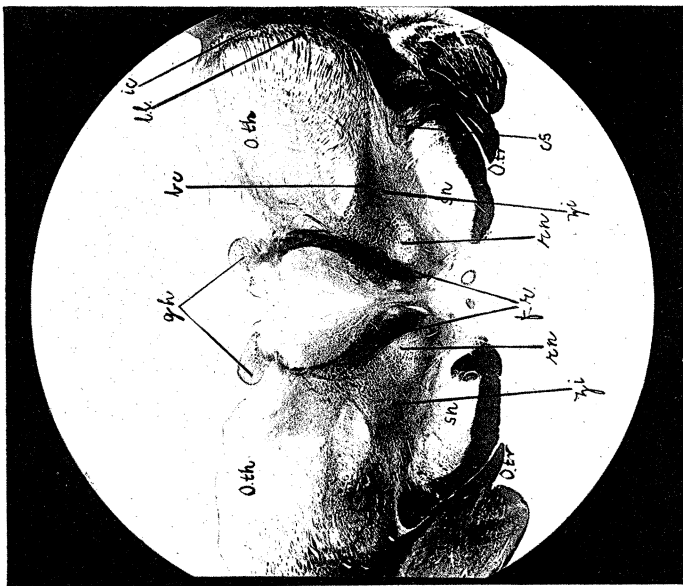
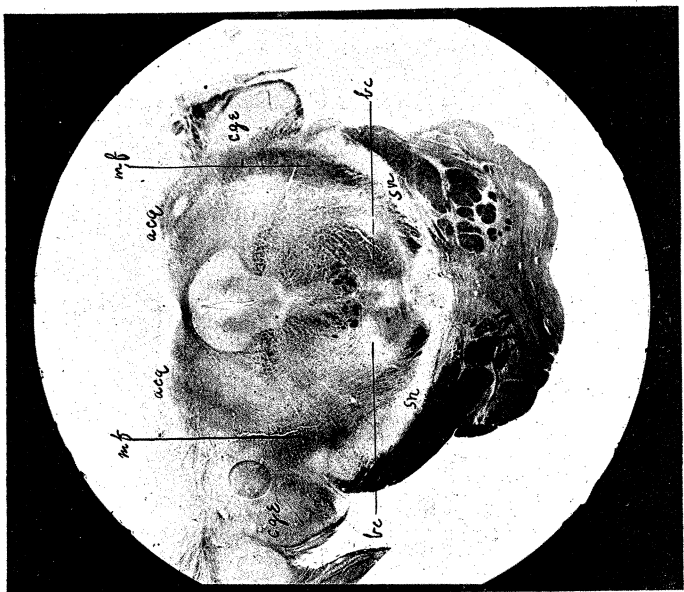
5

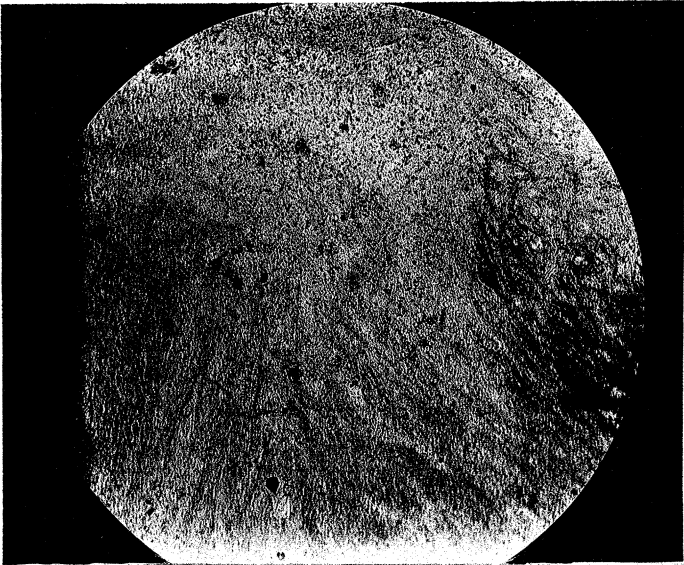


1

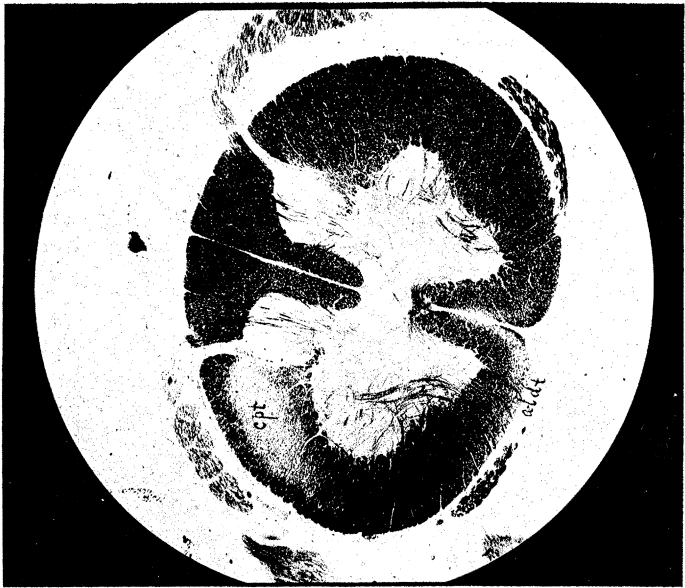

4

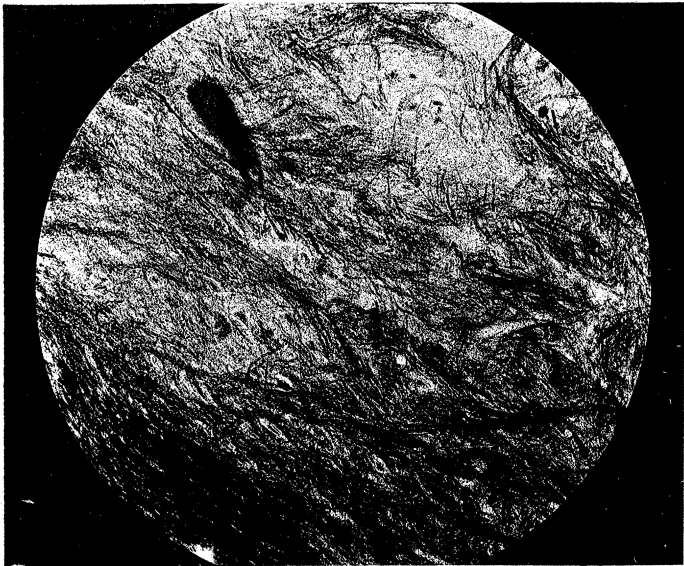




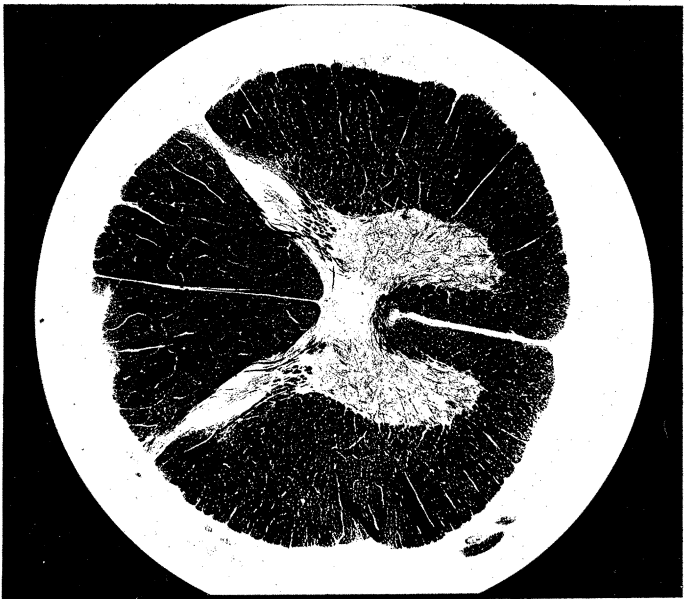3



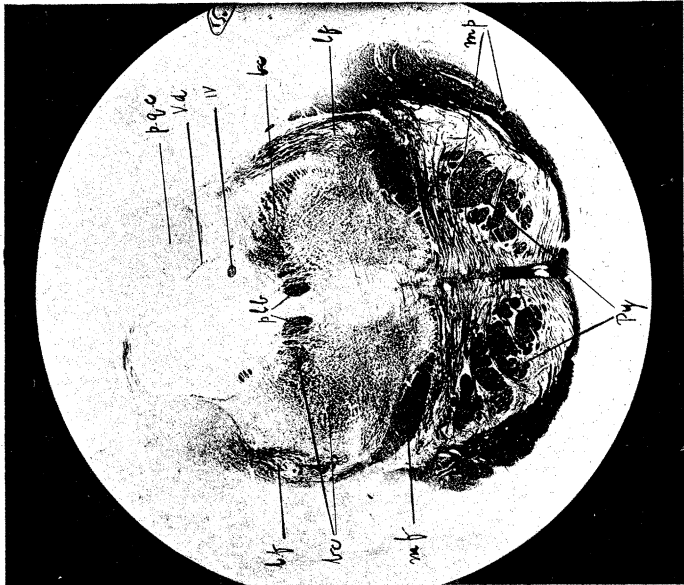
6



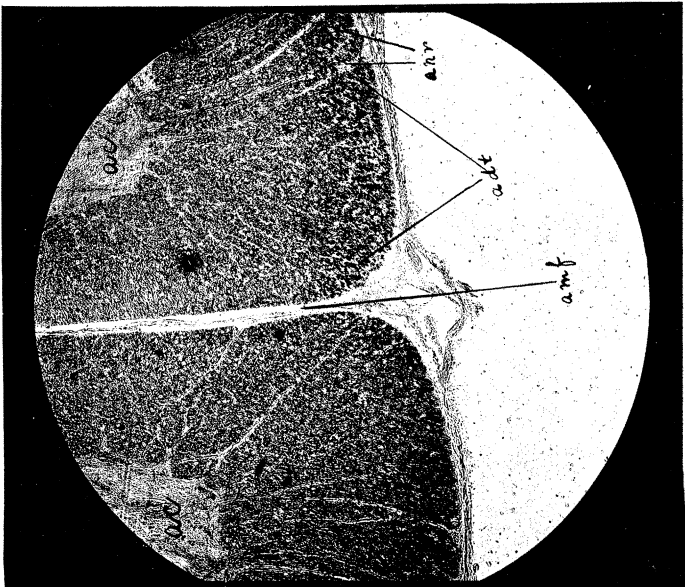
2



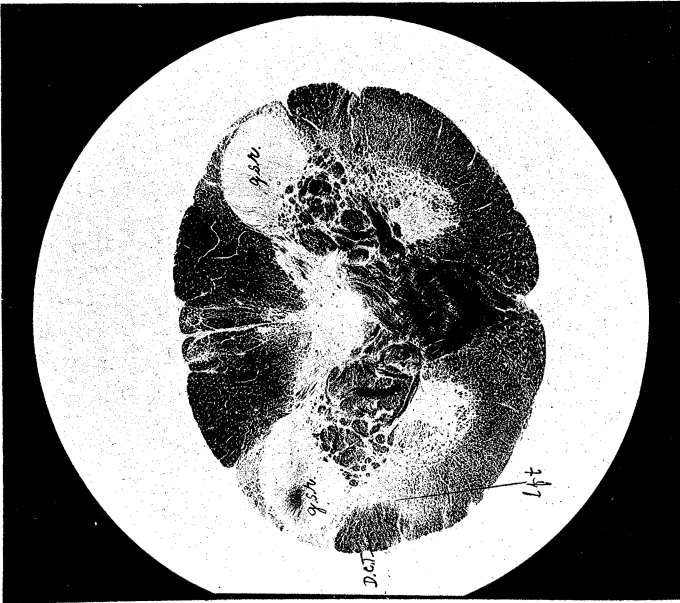
5



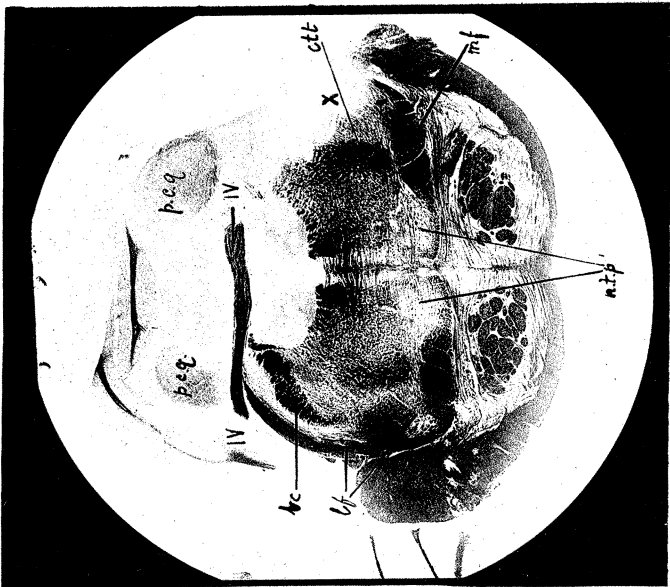
1



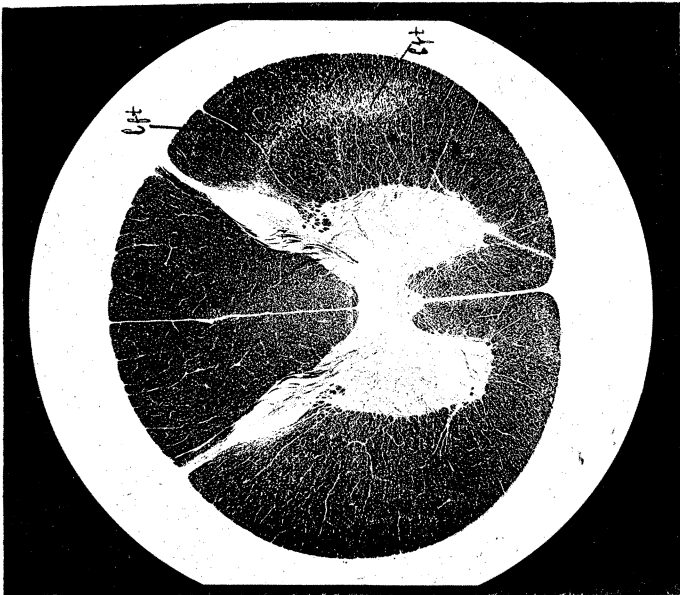
4



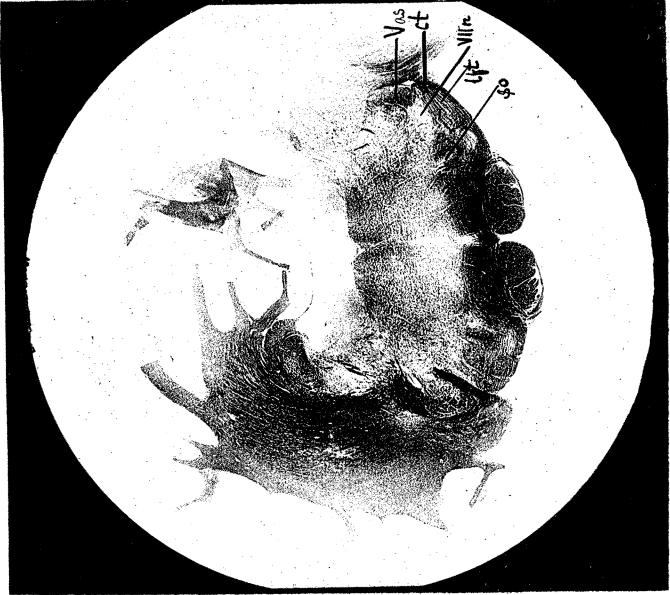
3



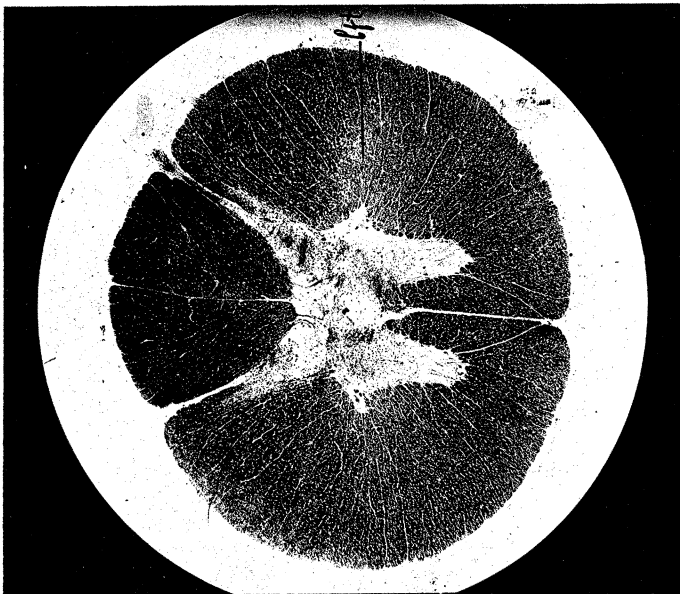
6



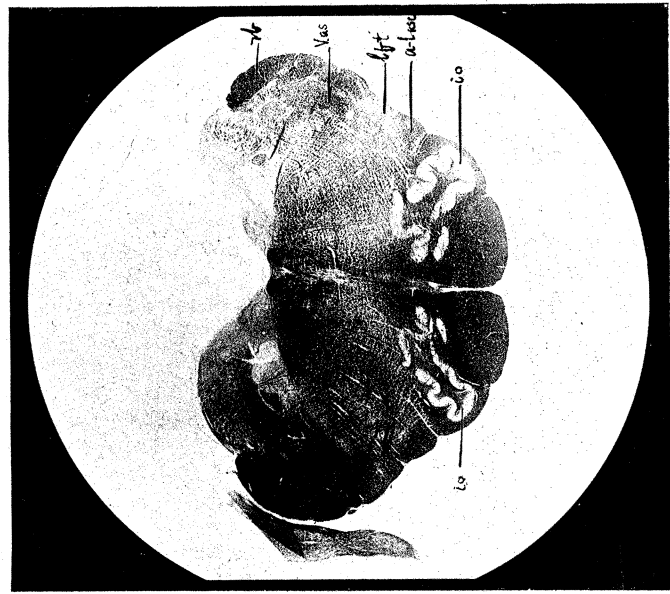
2



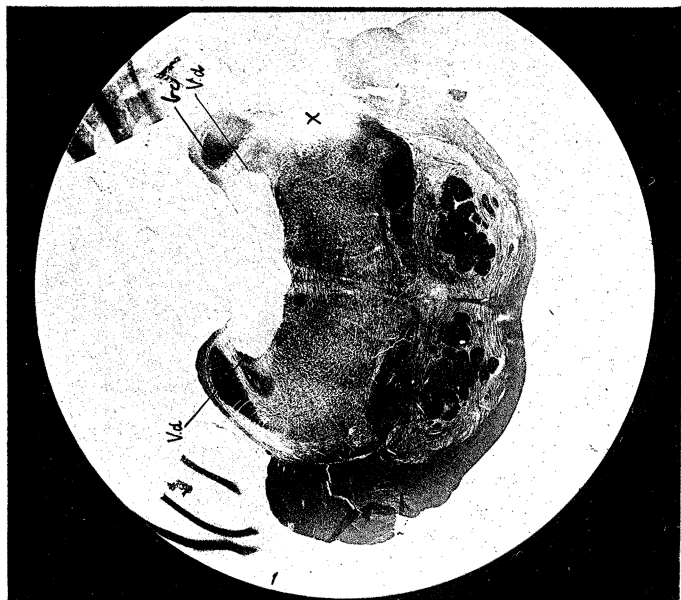5



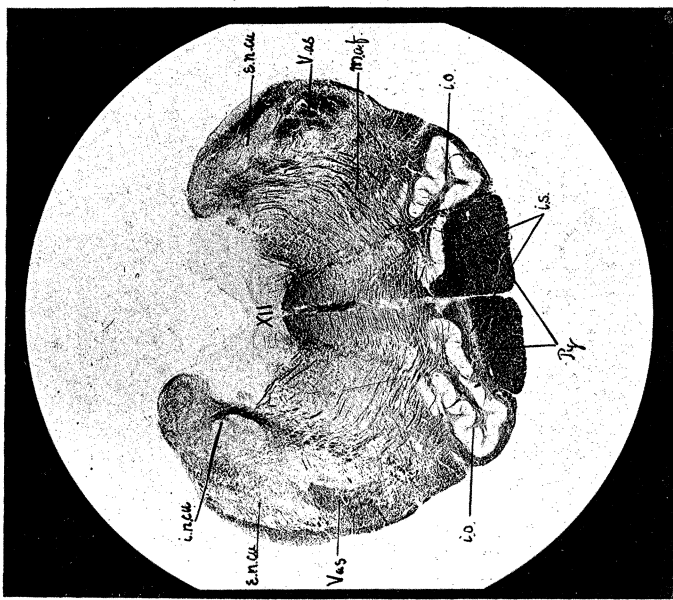
1



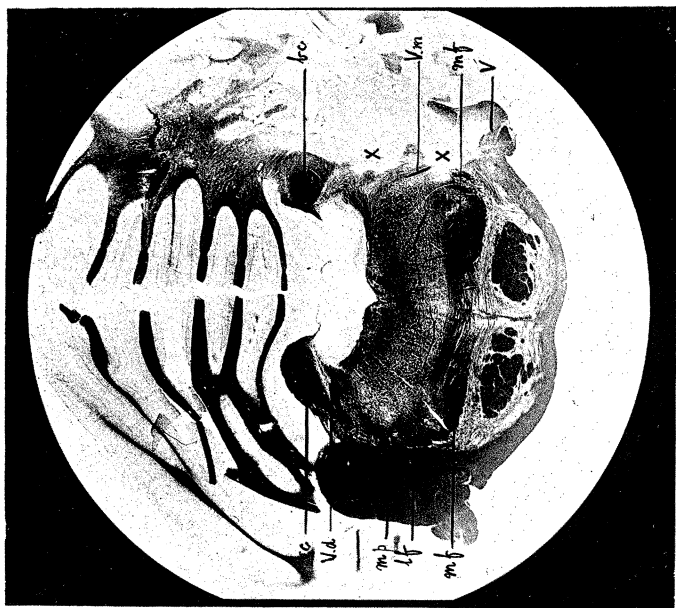
4



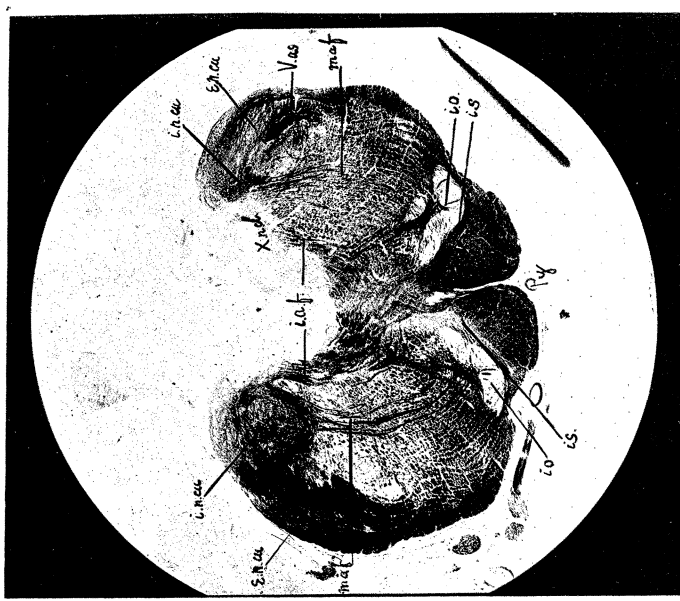
3



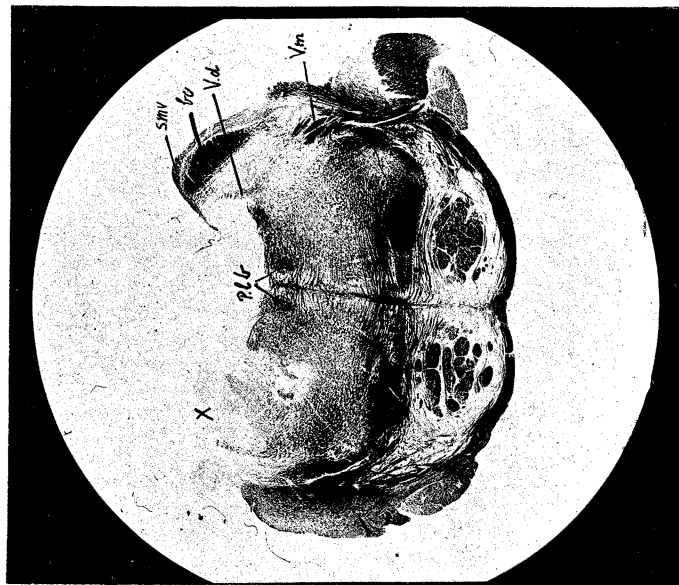
6



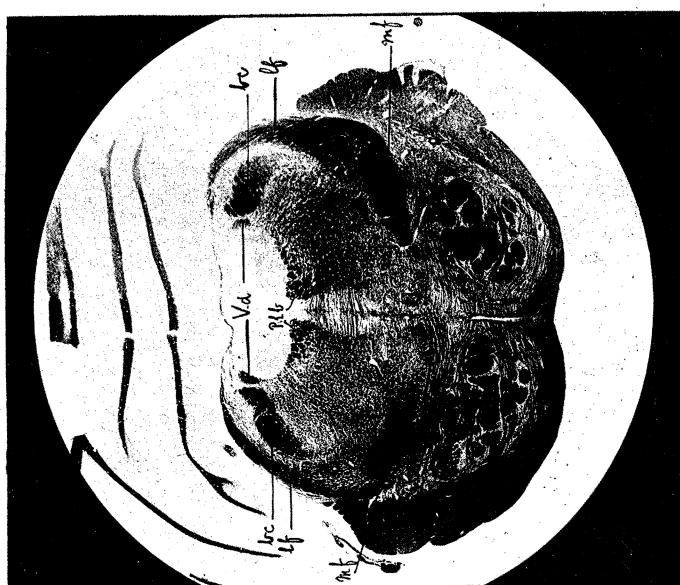
2



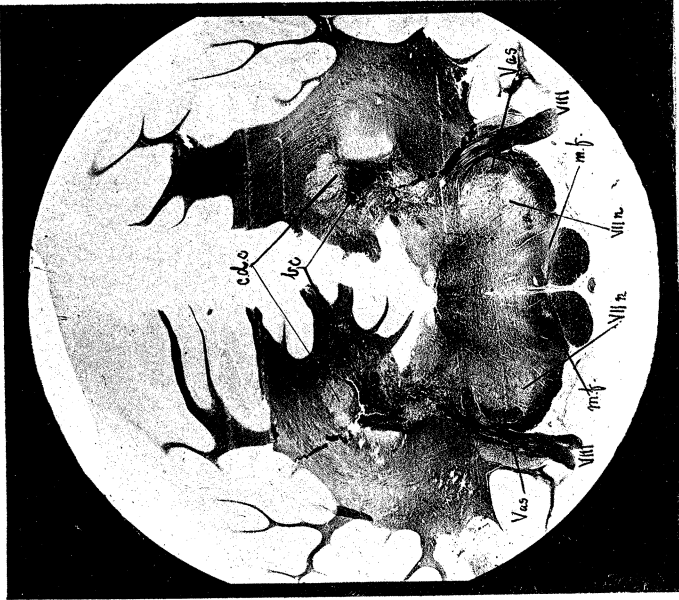
5



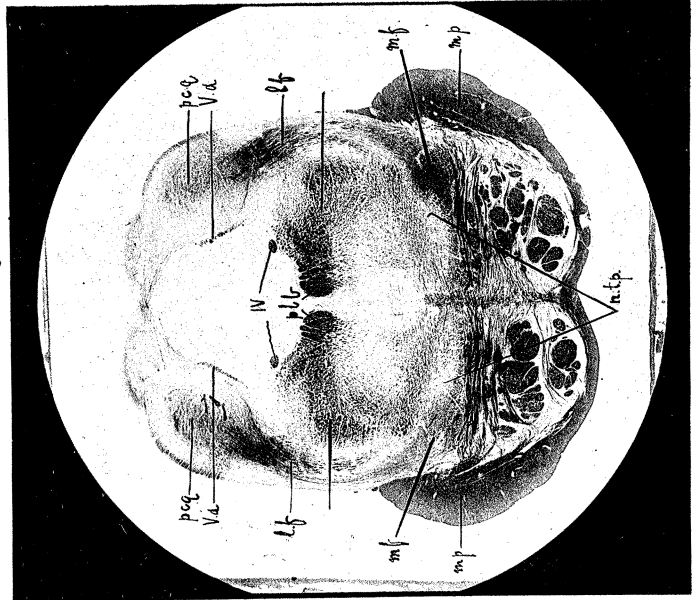
1



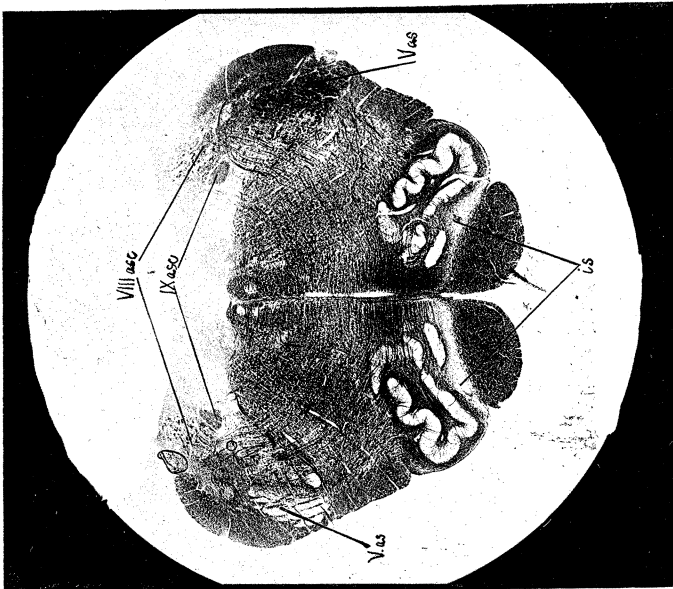
4



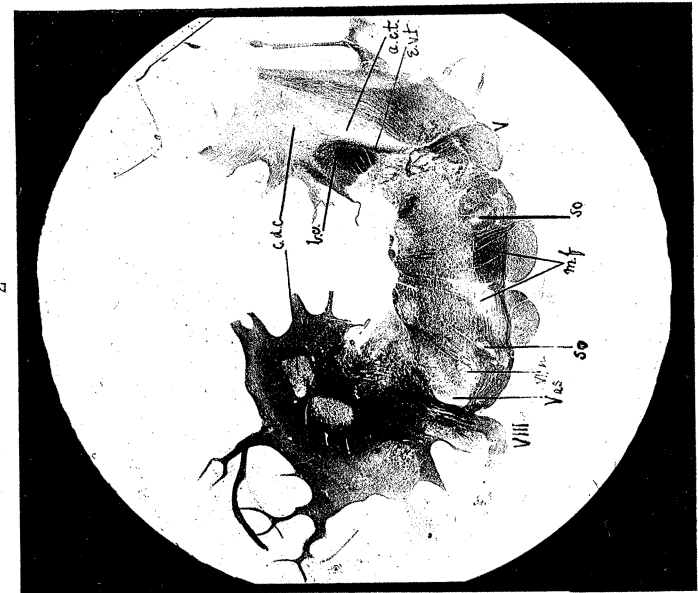
3



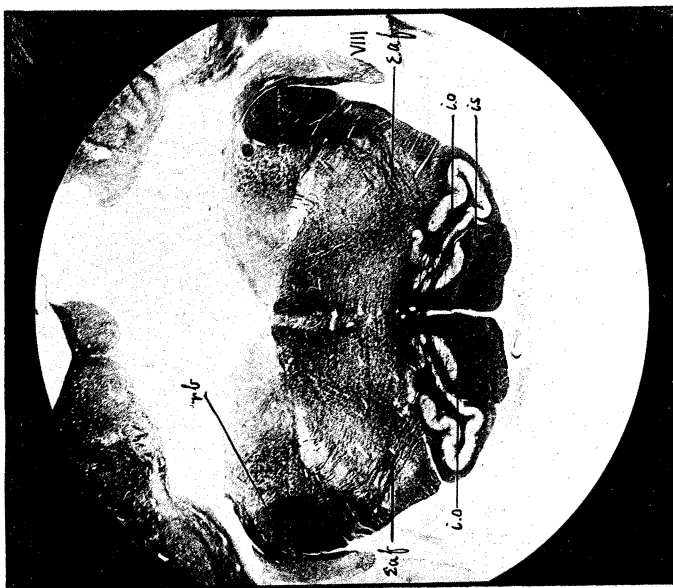
6



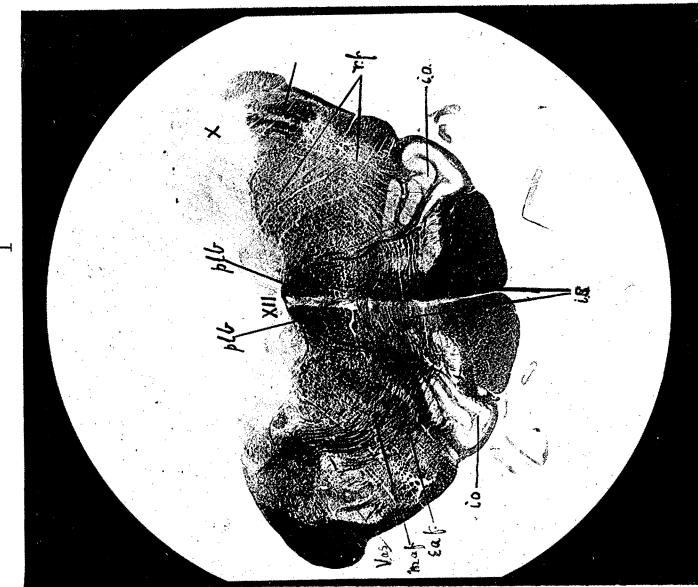
2



5




1




4

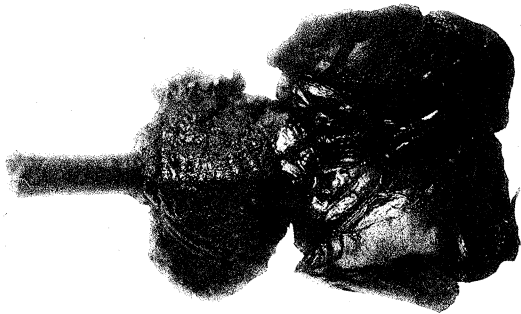




4



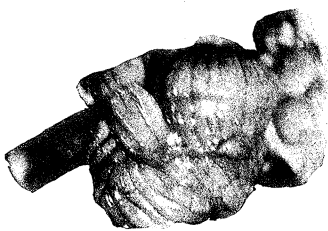
8



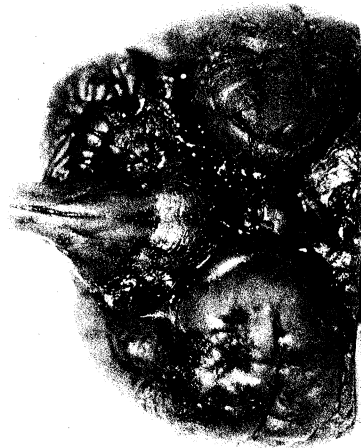3




7



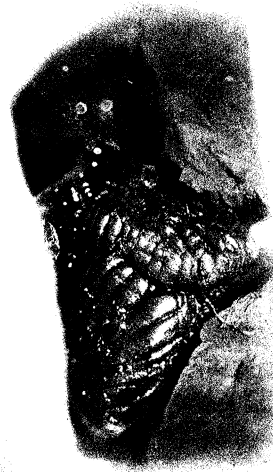2



6



1



5

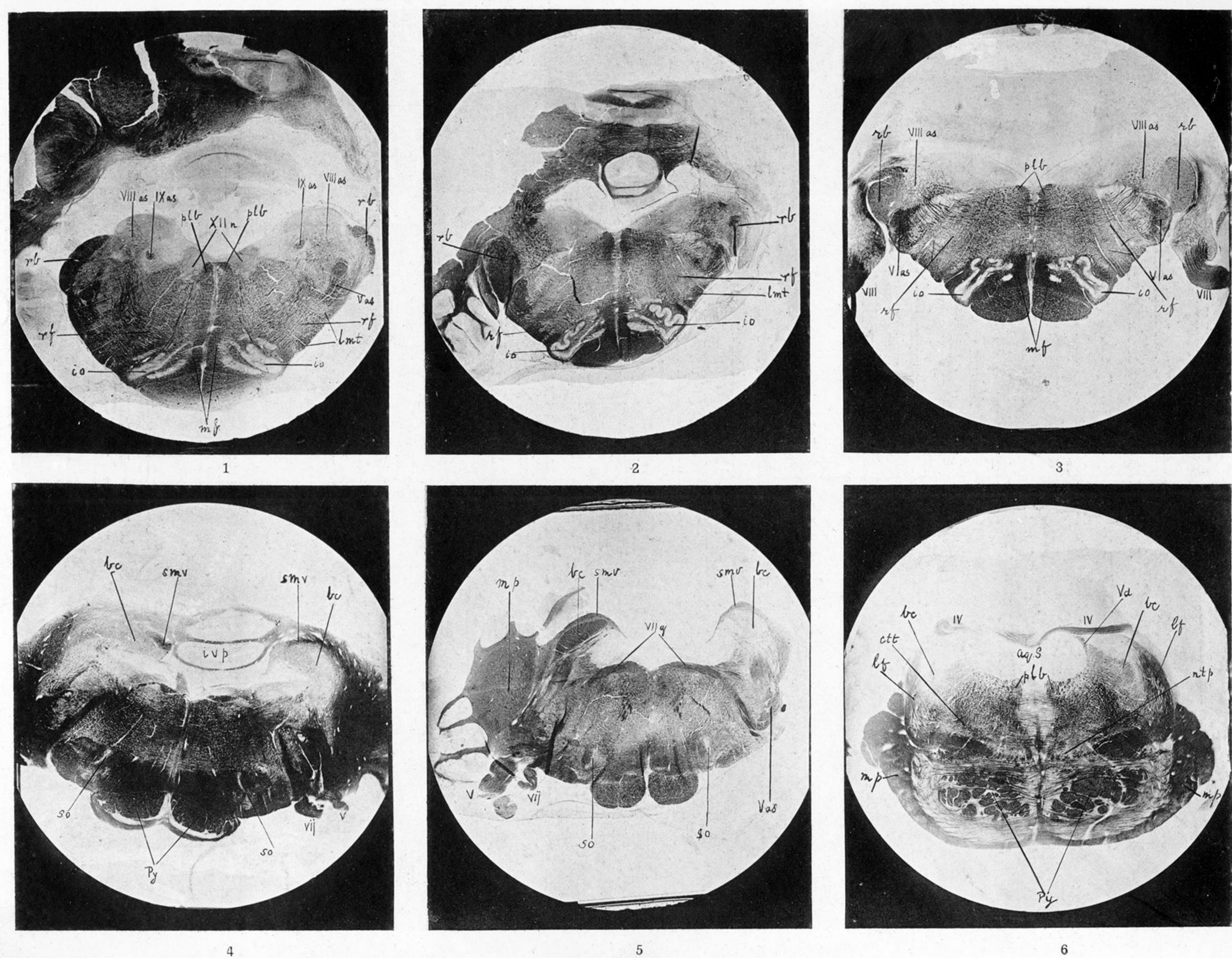


PLATE 64.

Fig. 1. A transverse section of the medulla after extirpation of the left lobe of the cerebellum, made through the lower third of the inferior olivary body, Exp. 4 ; enlarged 5 diameters.

r.b. Restiform body. On the side of the extirpation, this structure is atrophied on its ventral and mesial aspects, the dorsal and external parts being normal.

V., as. The ascending root of the fifth nerve, divided into several portions by white canals, the result of atrophy of the external arcuate fibres.

i.o. The inferior olivary body considerably diminished in size on the side opposite the lesion. The accessory olivary bodies are similarly atrophied.

l.m.t. Lateral medullary tract.

r.f. The reticular formation is stained lighter on the side of the lesion than on the opposite side, and also shows white canals normally occupied by external arcuate fibres.

The antero-lateral region of the medulla is flattened on the side of lesion : this is also seen in fig. 2.

The posterior longitudinal bundles (*p.l.b.*) and mesial fillet (*m.f.*) are normal.

VIII., as. The ascending root of the auditory nerve.

IX., as. The ascending glossopharyngeal root.

XII., n. The hypoglossal nucleus.

Fig. 2 is a section through the medulla at the middle of the inferior olive from the same case, Exp. 4 ; 5 diameters.

The lettering is the same as in fig. 1.

Fig. 3. A transverse section of the medulla at the level of the inferior olivary body from Exp. 1—complete cerebellar extirpation—4 diameters.

The lettering is the same as in figs. 1 and 2, with the following addition :—

VIII. The root of the auditory nerve.

Fig. 4 represents a section made through the medulla oblongata at the level of the genu facialis from Exp. 1—complete cerebellar extirpation—4 diameters.

b.c. The brachium conjunctivum completely sclerosed on both sides.

s.m.v. Superior medullary velum. On the left-hand side of the figure the arrow points to a tract of normal fibres containing probably the upward prolongation of the antero-lateral tract of the spinal cord. The corresponding portion on the right side is sclerosed (see p. 753.)

i.v.p. The inferior vermiform process of the cerebellum.

Py. The pyramidal tracts.

s.o. The superior olivary body.

V. and VII. the fifth and seventh cranial nerves.

Fig. 5. A transverse section of the medulla from Exp. 4—removal of the lateral lobe—4 diameters.

b.c. Brachium conjunctivum sclerosed on the side of the lesion.

s.m.v. Superior medullary velum unaffected.

s.o. Superior olivary body.

m.p. Middle peduncle.

VII., g. Genu facialis.

V., as. Ascending trigeminal root.

Fig. 6 represents a transverse section through the pons Varolii from Exp. 1—complete cerebellar extirpation—5.5 diameters.

b.c. The sclerosed brachium conjunctivum in the tegment of the pons.

m.p. The middle peduncle showing sparseness of the fibres which pass amongst the bundles of pyramidal fibres (*py.*). Ventrally it presents a flattened appearance.

n.t.p. The nucleus tegmenti pontis.

p.l.b. Posterior longitudinal bundles.

m.f. Mesial fillet.

c.t.t. Central tegmental tract.

l.f. Lateral fillet.

IV. The fourth cranial nerve.

Aq.S. The aqueduct of Sylvius.

V., d. Descending trigeminal root.

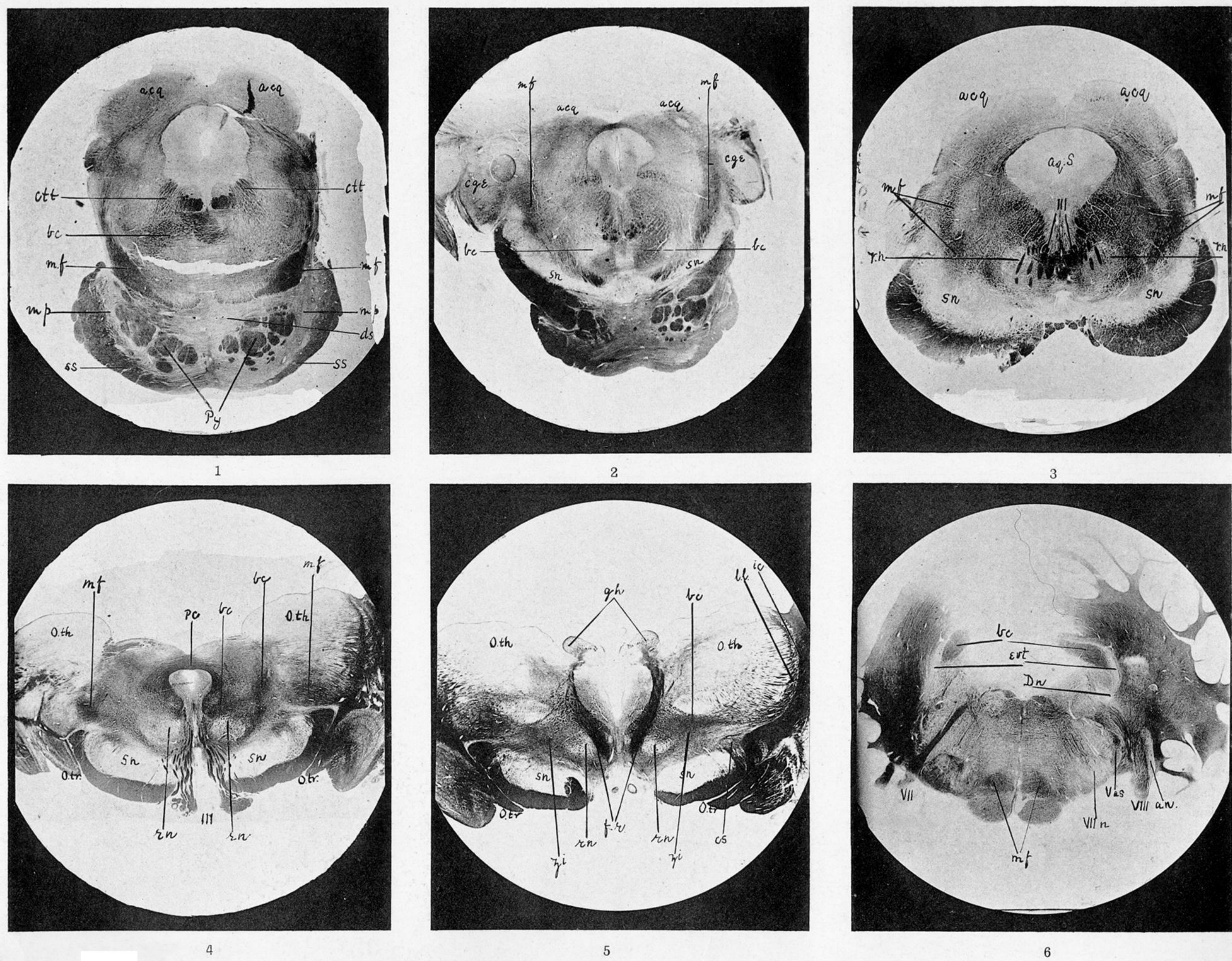


PLATE 65.

Fig. 1. A transverse section of the pons from Exp. 4—removal of the left lateral lobe of the cerebellum. This section has been made just below the decussatio brachiorum and compares with the next (fig. 2), which has been made just above it; 3·6 diameters.

b.c. The normal brachium conjunctivum. Its position on the opposite side is characterized by an entire absence of fibres.

c.t.t. Central tegmental tract.

m.f. Mesial fillet.

m.p. Middle peduncle, of which *ss.* represents the superficial layer.

Py. The bundles of pyramidal fibres.

a.c.q. Anterior quadrigeminal bodies.

Fig. 2. A transverse section of the pons from Exp. 4. The section has been made immediately above the decussation and represents the atrophied peduncle upon the side opposite the lesion; 4·5 diameters. The lettering is the same as in Plate 65, fig. 1.

c.g.e. External geniculate body.

Fig. 3 is a section through the crura cerebri at the level of the red nuclei and roots of the third nerve from Exp. 1—complete cerebellar extirpation—4·25 diameters.

r.n. The red nuclei, atrophied upon both sides. In addition to the atrophy of the nuclei, the brachia conjunctiva, which partly pass through them and partly lie dorso-externally (see Plate 65, fig. 4) are atrophied.

s.n. Substantia nigra.

m.f. Mesial fillet.

a.c.q. Anterior quadrigeminal bodies.

III. Nuclei and roots of the third cranial nerve.

Fig. 4 has been made through the posterior part of the optic thalamus from Exp. 5—extirpation of the left lateral lobe—2·5 diameters.

r.n. and *b.c.* The red nucleus and brachium conjunctivum are atrophied on the side opposite the lesion (left side of figure.) The latter structure is seen passing dorso-externally towards the optic thalamus.

O.th. Optic thalamus.

P.C. Posterior commissure.

m.f. Mesial fillet.

s.n. Substantia nigra.

O.tr. Optic tract.

III. The roots of the third cranial nerve.

Fig. 5 is a section through the subthalamic region from the same case as the preceding (fig. 4, Exp. 5). It represents the continuation of the brachium from the red nucleus to the optic thalamus; 2·5 diameters. The lettering is the same as in the preceding figure, with the following additions:—

g.h. Ganglion habenulæ.

f.r. Fasciculus retroflexus.

c.s. Corpus subthalamicum, or body of Luys.

z.i. Zona incerta.

l.l. Latticed layer, or "Gitterschicht."

i.c. Internal capsule.

Fig. 6 is a section through the medulla from Exp. 7, in which the middle lobe of the cerebellum was removed. As the section has not been cut quite horizontal some structures are seen on one side which are not shown on the other; 3 diameters.

b.c. The brachium conjunctivum.

D.n. The nucleus of DEITERS (large-celled external auditory nucleus) shown only on the right side of the figure.

e.v.t. Efferent vermiform tract, which passes from the middle lobe to DEITERS' nucleus, and which is seen to have undergone sclerosis in this section (see text, p. 740).

V., a.s. Ascending trigeminal root.

VII., n. and *VII.* The nucleus and root of the seventh nerve.

VIII. The root of the eighth nerve on which is seen the accessory nucleus (*a.n.*).

m.f. Mesial fillet.

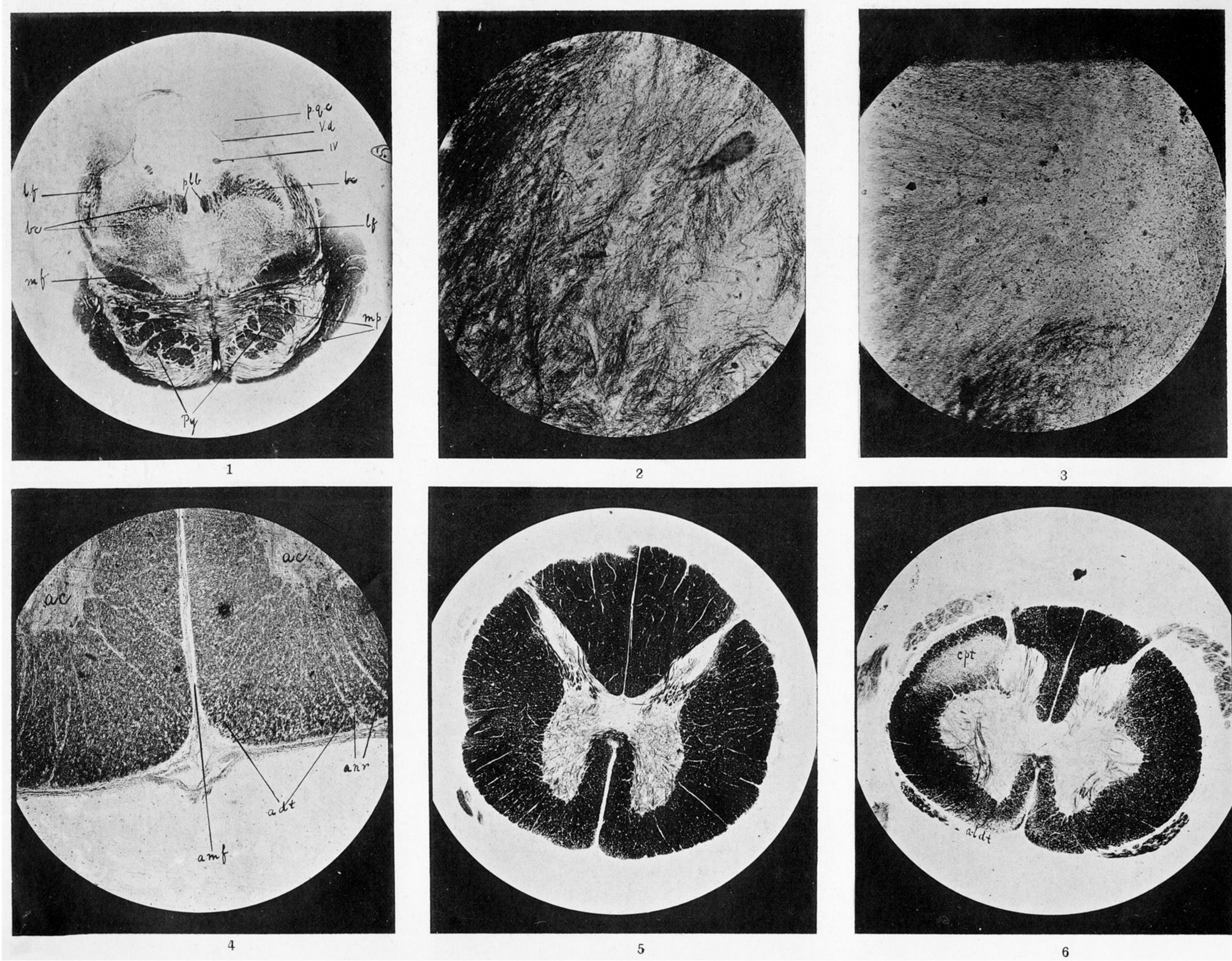


PLATE 66.

Fig. 1. A frontal section through the pons from Exp. 7—extirpation of the middle lobe of the cerebellum—4 diameters. The section presents a normal appearance.

- p.q.c.* Posterior quadrigeminal bodies.
- l.f.* Lateral fillet.
- m.f.* Mesial fillet.
- b.c.* Brachium conjunctivum.
- V., d.* Descending trigeminal root.
- IV.* Root of the fourth cranial nerve.
- Py.* Pyramidal tracts.
- m.p.* Transverse fibres of the pons.
- P.l.b.* Posterior longitudinal bundles.

Fig. 2. DEITERS' nucleus, magnified 40 diameters, from Exp. 5, in which the lateral lobe of the cerebellum was extirpated. In this case the fibres and cells of the nucleus present a normal appearance.

Fig. 3. DEITERS' nucleus, magnified 40 diameters, from Exp. 4—lateral lobe extirpation. The figure shows the nucleus sclerosed as a result of traumatic degeneration. The cells and network of fine medullated fibres have almost entirely disappeared.

Fig. 4. Portion of transverse section of the spinal cord at the level of the second cervical nerve from Exp. 7, showing the position of the *anterior descending tract* (*vide text*, p. 743); 40 diameters.

- a.m.f.* The anterior median fissure.
- a.d.t.* The anterior descending tract.
- a.c.* The anterior cornua.
- a.n.r.* The anterior nerve roots.

Fig. 5. A transverse section of the spinal cord at the second cervical segment, from the case of complete cerebellar extirpation (Exp. 1); 13 diameters (*vide text* p. 742).

Fig. 6. A transverse section of the spinal cord through the cervical enlargement, from a case of hemisection of the spinal cord, to show the descending degenerations resulting therefrom; 10 diameters.

- c.p.t.* Crossed pyramidal tract.
- a.l.d.t.* Antero-lateral descending tract.

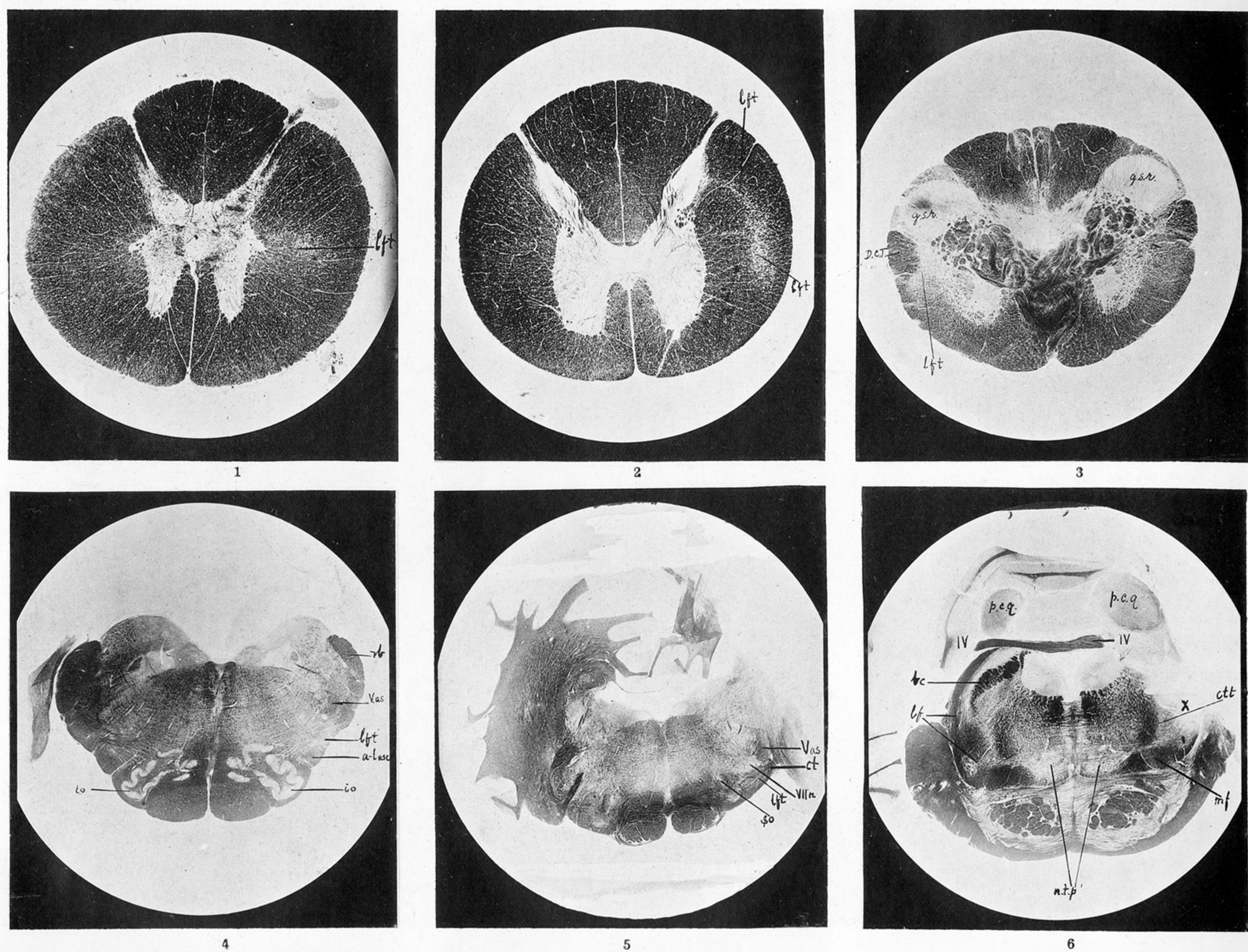


PLATE 67.

Fig. 1. A transverse section of the spinal cord from the fifth dorsal segment to show the position of the tract from the lateral fillet (Exp. 18) ; 17 diameters.

l.f.t. The lateral fillet tract.

Fig. 2. Transverse section of the spinal cord from the second cervical segment to show the tract from the lateral fillet (Exp. 5) ; 10·5 diameters.

l.f.t. The lateral fillet tract.

Fig. 3. Transverse section at the level of the pyramidal decussation from the same case as fig. 2, Plate 67 ; 8·3 diameters. (This section has been reversed in mounting.)

l.f.t. The lateral fillet tract.

D.c.t. The direct cerebellar tract.

f.r. The reticular formation.

s.q.r. The gelatinous expansion forming the tubercle of ROLANDO.

Fig. 4. Transverse section through the medulla at the mid-olivary region from the same case as figs. 2 and 3 ; 4·75 diameters. The restiform body (*r.b.*) and external arcuate fibres are atrophied on the side of lesion, and the inferior olive (*i.o.*) of the opposite side, due to extirpation of the lateral lobe which was accomplished in this case (Exp. 5).

l.f.t. The lateral fillet tract is seen here occupying the dorsal portion of the lateral medullary region ; the fore part of which is occupied by the antero-lateral ascending tract (*a.l.asc.*).

Fig 5. From the same case as the preceding. The section has been at the level of the corpus trapezoides ; 3·2 diameters.

l.f.t. The tract from the lateral fillet is seen amongst the fibres of the corpus trapezoides (*c.t.*), immediately ventral to the nucleus of the seventh nerve (VII., *n.*).

s.o. The superior olivary body.

V., as. The ascending trigeminal root.

Fig. 6. From the same case as the preceding figure. This represents a frontal section through the pons at the level of the trochlear decussation and shows the lesion in the tegmentum pontis and lateral fillet ; 4 diameters.

× represents the lesion of the tegmentum pontis and lateral fillet.

p.c.q. Posterior corpora quadrigemina.

IV. The decussation of the fourth cranial nerves.

b.c. Brachium conjunctivum.

l.f. Lateral fillet.

m.f. Mesial fillet.

n.t.p. Nucleus tegmenti pontis ; on the side opposite the extirpation this presents an appearance of atrophy, which is not seen on the side of lesion.

c.t.t. Central tegmental tract.

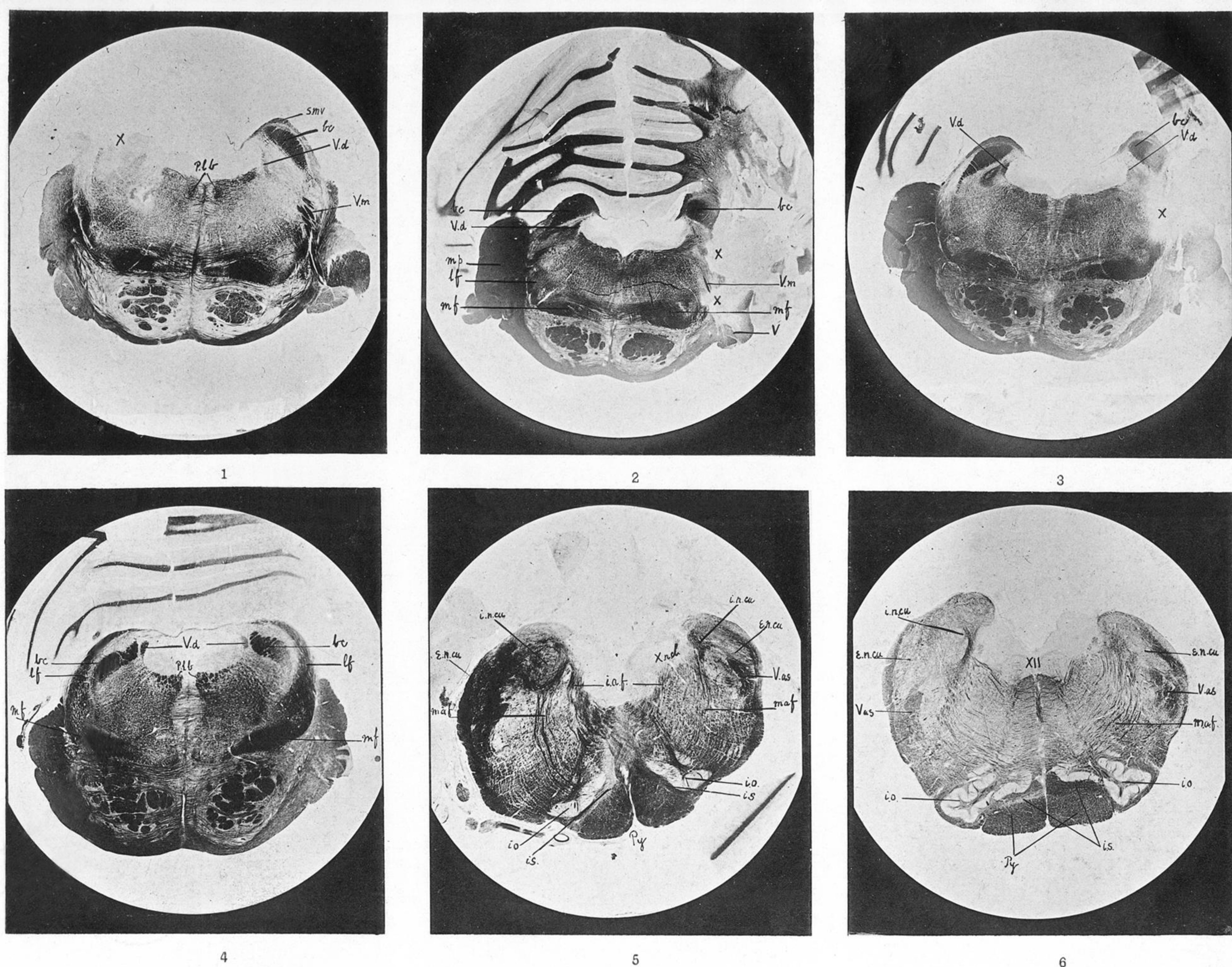


PLATE 68.

Fig. 1. Frontal section through the pons from Exp. 15; showing the extent and position of the lesion of the superior peduncle (X.); 4.4 diameters.

s.m.v. Superior medullary velum.
b.c. Brachium conjunctivum.
V., d. Descending trigeminal root.
V., m. Motor root of the fifth nerve.
p.l.b. Posterior longitudinal bundles.

Fig. 2. A frontal section through the pons and cerebellum to show the nature, extent and position of the lesion of the middle peduncle and tegmentum pontis in Exp. 18; 3.1 diameters.

× × indicates the site of the lesion; the lettering is the same as in the previous figures.

Figs. 3 and 4. Frontal sections from the same case as the preceding somewhat higher up, so as to show the changes which have taken place in the transverse fibres of the pons as a result of division of the middle peduncles; 4 diameters.

From these it is seen that the fibres have not entirely disappeared, but present a diminished staining reaction and a sparseness in the grey matter of the pons.

The lettering is the same as in fig. 1, Plate 68.

n.t.p. Nucleus tegmenti pontis.

V., d. Descending trigeminal root somewhat atrophied on the side of lesion, from implication of the motor root at the seat of injury (fig. 2) (see also Plate 70, fig. 5, *V., d.*).

Fig. 5. A transverse section of the medulla at the lower end of the inferior olive, showing the degeneration which follows destruction of the clavate nucleus (Exp. 28); 5.2 diameters.

x.n.cl. These letters are placed over the anterior end of the clavate nucleus.

i.a.f. Internal arcuate fibres degenerated on the side of lesion.

i.s. Inter-olivary stratum.

i.n.cu. Nucleus cuneatus internus.

e.n.cu. Nucleus cuneatus externus.

m.a.f. Middle arcuate fibres in part degenerated on side of the lesion.

i.o. Inferior olivary body.

V., as. Ascending trigeminal root.

Fig. 6. Transverse section of the medulla from the same case as the preceding, somewhat higher up; 5 diameters.

i.s. Inter-olivary layer on the side opposite the lesion.

The portion of this stratum which separates the pyramids (*py.*) from the olive is chiefly degenerated.

In all respects the lettering is the same as in the preceding figure.

XII. The hypoglossal nucleus.

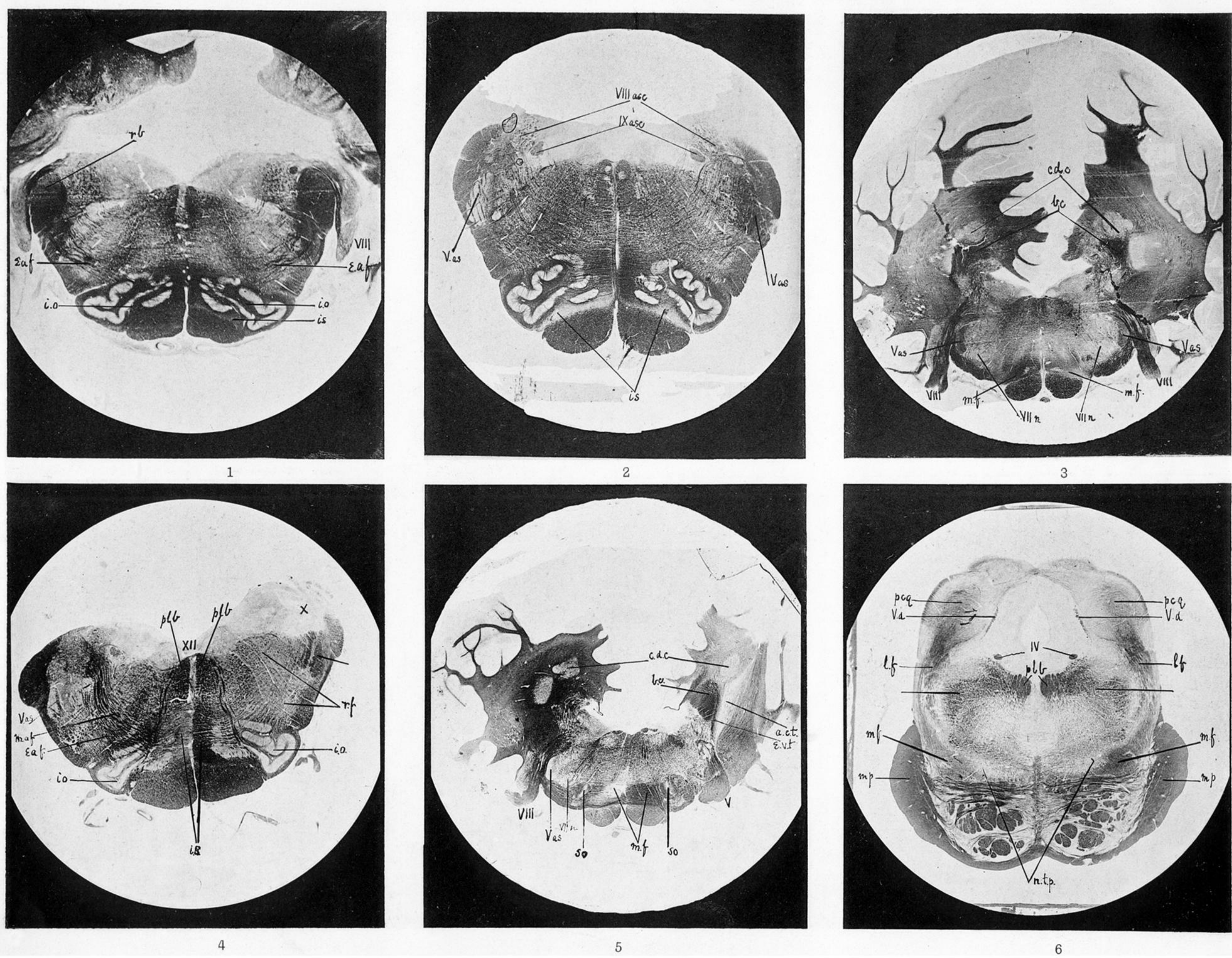


PLATE 69.

Fig. 1. A transverse section from the same case as the preceding at a slightly higher level; 4 diameters.

From this it is seen that only the ventral portion of the inter-olivary stratum is degenerated, the dorsal being unaffected. Owing to the section being too deeply stained this is not so clearly seen as in the following figure (fig. 2, Plate 69), where both clavate nuclei only had been destroyed.

r.b. Restiform tract, in the dorsal portion of which is seen a small area of degeneration on the side of the lesion.

e.a.f. External arcuate fibres or cerebello-olivary system.

VIII. Root of the auditory nerve.

Fig. 2. A transverse section of the medulla oblongata at the middle of the inferior olivary body from a case in which both clavate nuclei had been destroyed (Exp. 29); 5.5 diameters.

i.s. The inter-olivary stratum degenerated mainly in its ventral portion. The deeply-stained dorsal portion being formed by the middle arcuate fibres from the cuneate nucleus.

V., as. The ascending trigeminal root. On the left-hand side of the figure this structure is sclerosed owing to the trunk of the nerve having been divided between the Gasserian ganglion and the brain. Passing through it are the cerebello-olivary fibres. This portion of the figure, therefore, is the converse of Plate 64, fig. 1, *V., as.*

VIII., *asc.* Ascending root of the auditory nerve.

IX., *asc.* Ascending root of the glossopharyngeal nerve.

Fig. 3. Frontal section through the medulla and cerebellum at the level of the eighth nerve from the same case as fig. 1, Plate 69; and figs. 5 and 6, Plate 68; 3.5 diameters.

m.f. Mesial fillet, the ventral portion only of which is completely degenerated on one side, although scattered fibres may be detected in the dorsal segment.

The lettering is the same as in the preceding figures.

b.c. Brachium conjunctivum.

c.d.c. Corpus dentatum cerebelli.

VII., *n.* Nucleus of the seventh nerve.

Fig. 4. Transverse section of the medulla from a case in which the cuneate nucleus was destroyed (Exp. 22), as well as the restiform tract; 4 diameters.

X represents the lesion of the cuneate nucleus.

i.s. The inter-olivary stratum on the side opposite the lesion presents a degenerated appearance, but in this case the degeneration is chiefly confined to the dorsal portion of the mesial fillet, the ventral part showing comparatively little affection, as it is formed, as shown in the text, p. 760, by the internal arcuate fibres from the clavate nucleus.

m.a.f. The middle arcuate fibres. These have disappeared on the side of the lesion, as also have the external arcuate fibres (*r.f.*).

Owing to the fact that the restiform body was also destroyed immediately anterior to the nucleus, the external arcuate fibres (*e.a.f.*) on the same side and the opposite inferior olive (*i.o.*) are also atrophied.

r.f. The reticular formation.

V., asc. The ascending trigeminal root is sclerosed on the left side, as a result of division of the nerve between the Gasserian ganglion and the surface of the pons; through it pass healthy external arcuate fibres. On the side of the lesion it is normal, and through it are seen the spaces left by the atrophied external arcuate fibres.

Fig. 5. A frontal section from the same case as the preceding at the level of the sixth nerve nuclei; 3 diameters.

The lettering is similar to the preceding.

m.f. Mesial fillet. Here the degeneration in the dorsal portion of this structure is well seen; while in the cerebellum, on the right side of the figure, a large fan-shaped sclerosed area (*a.c.t.*) formed chiefly by the direct fibres from the cuneate nucleus, is observed. Owing to the fact that the restiform body was also destroyed in this case, the sclerosed area contains the fibres from the clavate tubercle, and also the direct cerebellar tract.

e.v.t. Efferent vermiform tract, or tract to DEITERS' nucleus.

a.c.t. Ascending cerebellar system.

V., as. The sclerosis of the ascending trigeminal root is distinctly seen on the left side, as a result of section of the nerve between the Gasserian ganglion and the pons (see also figs. 2 and 4, Plate 69).

s.o. Superior olivary body.

c.d.c. Fore-end of the corpus dentatum cerebelli.

V. The trunk of the fifth nerve.

VII., *n.* Nucleus of the seventh nerve.

Fig. 6. A section through the pons and posterior corpora quadrigemina from a case of destruction of the clavate nucleus; 4.3 diameters.

b.c. Brachium conjunctivum.

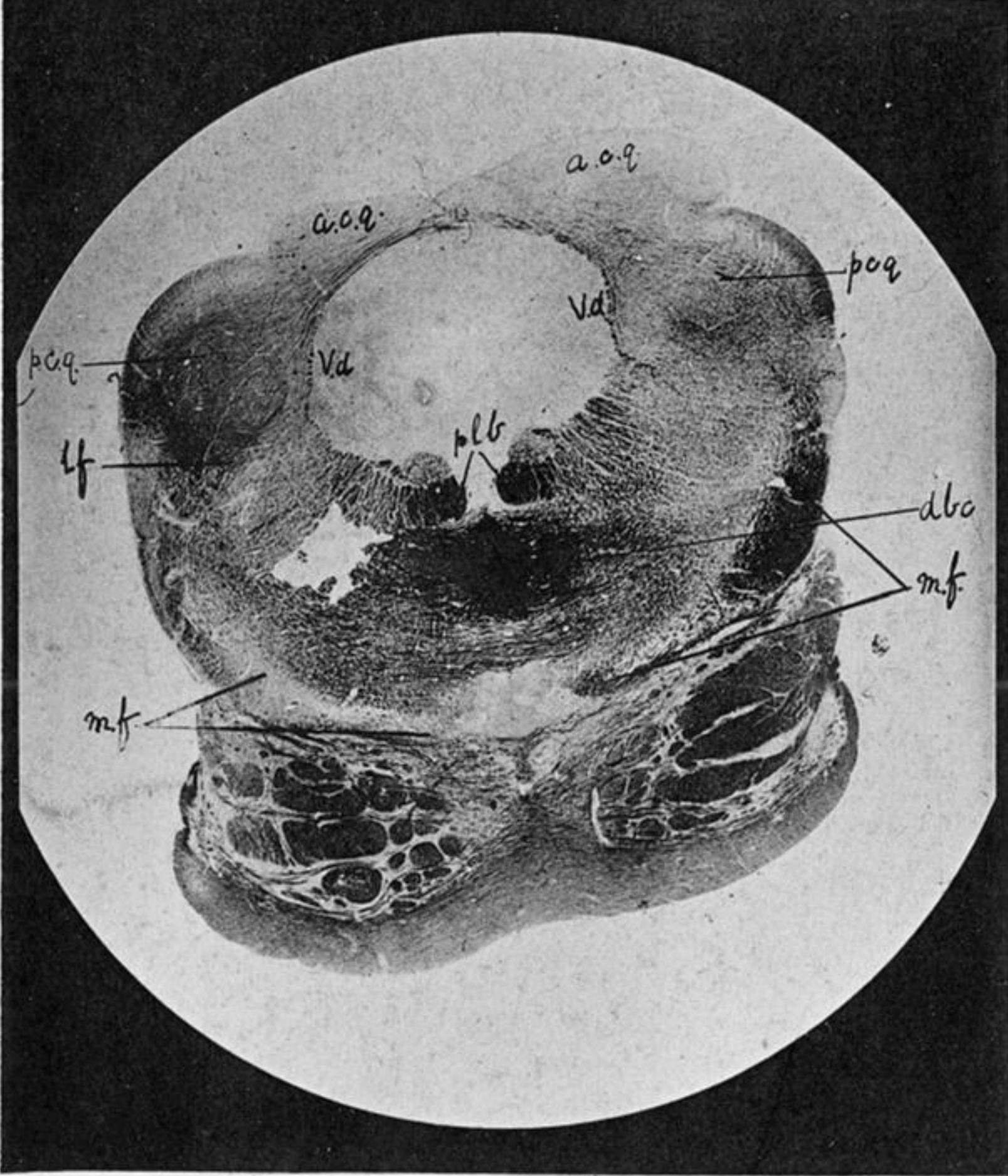
m.f. Mesial fillet. This presents a partially degenerated appearance throughout, owing to an intermingling of the fibres from the clavate and cuneate nuclei.

m.p. Middle cerebellar peduncle.

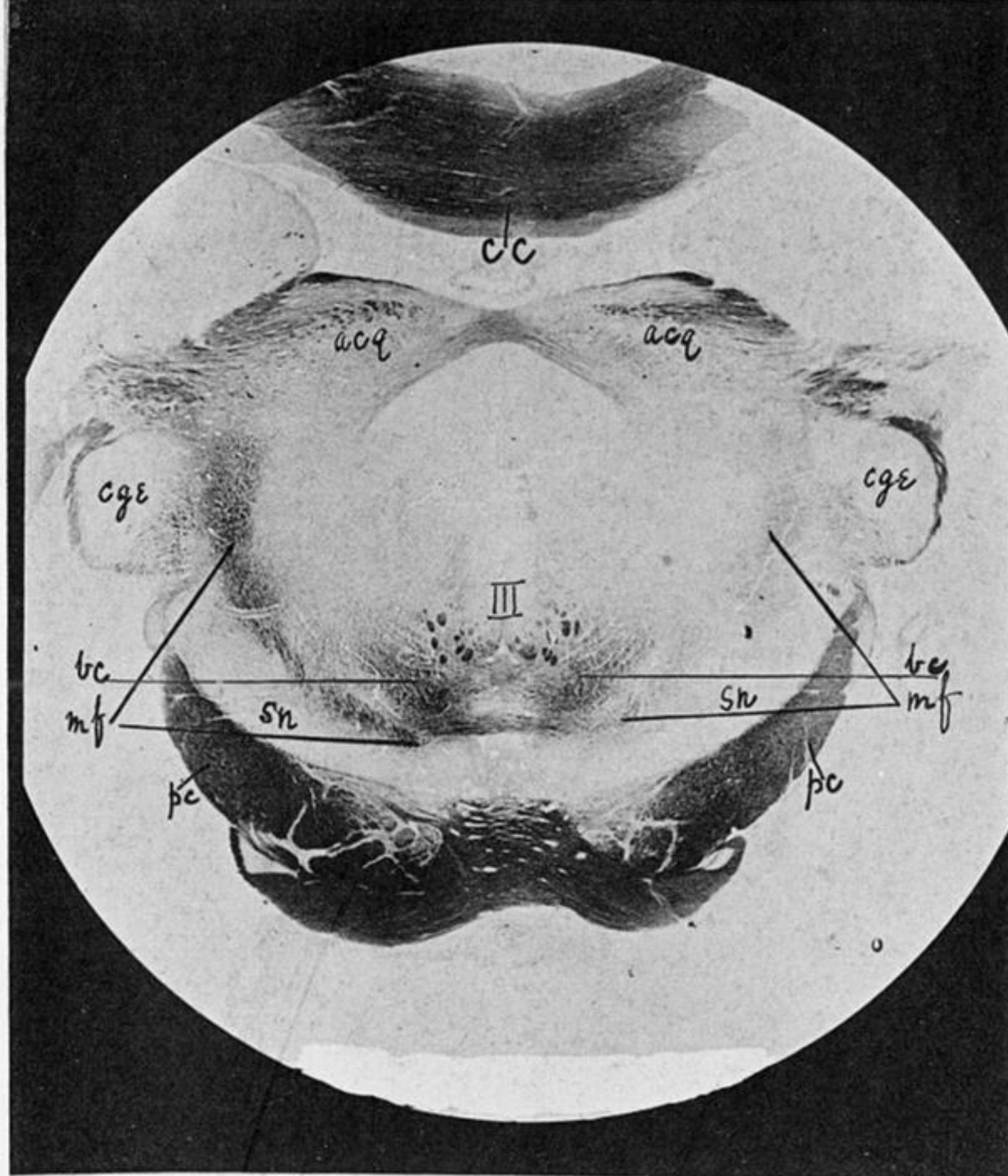
l.f. Lateral fillet, and *p.c.g.* posterior corpora quadrigemina.

V.d. Descending trigeminal root.

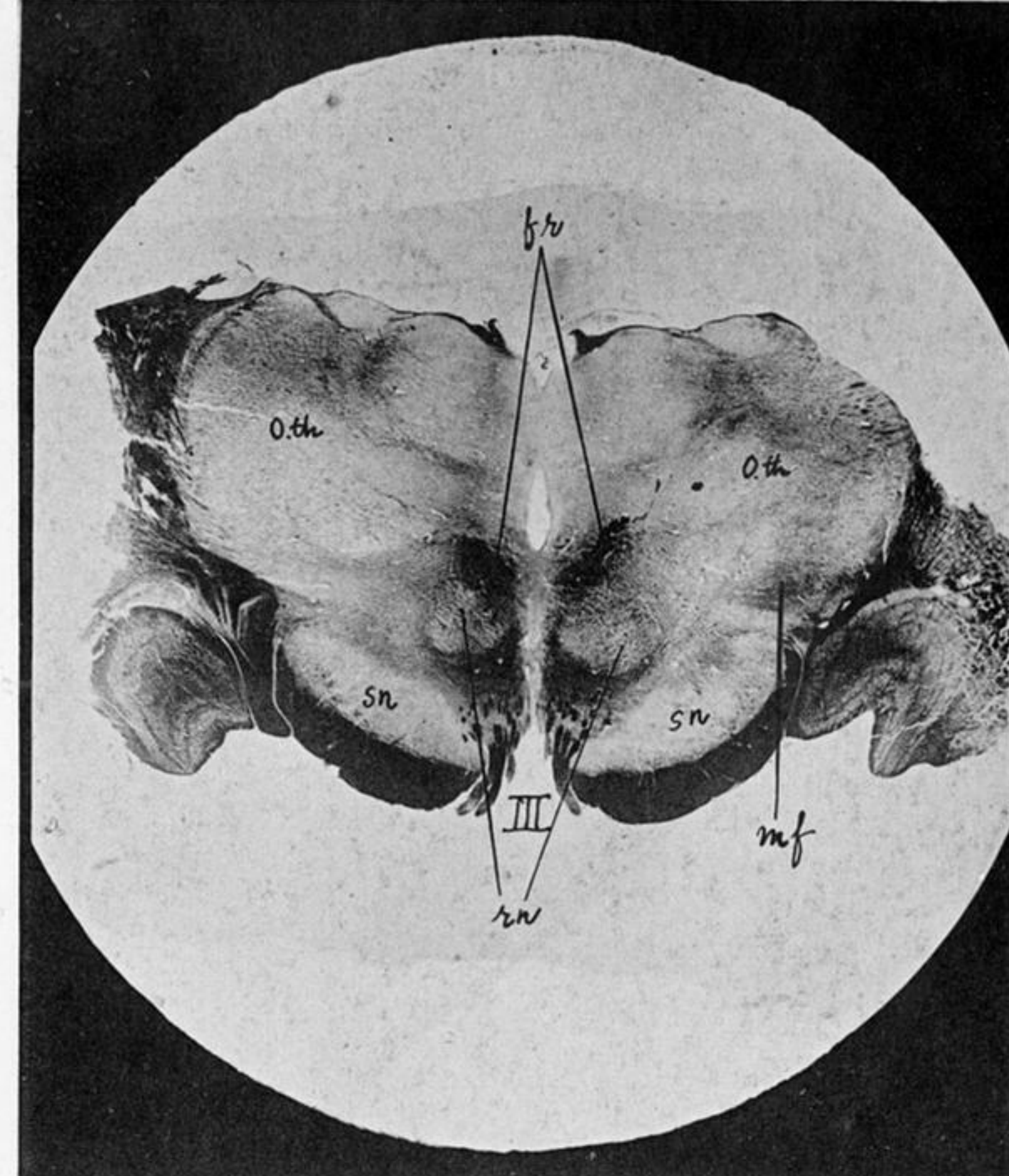
n.t.p. Nucleus tegmenti pontis.



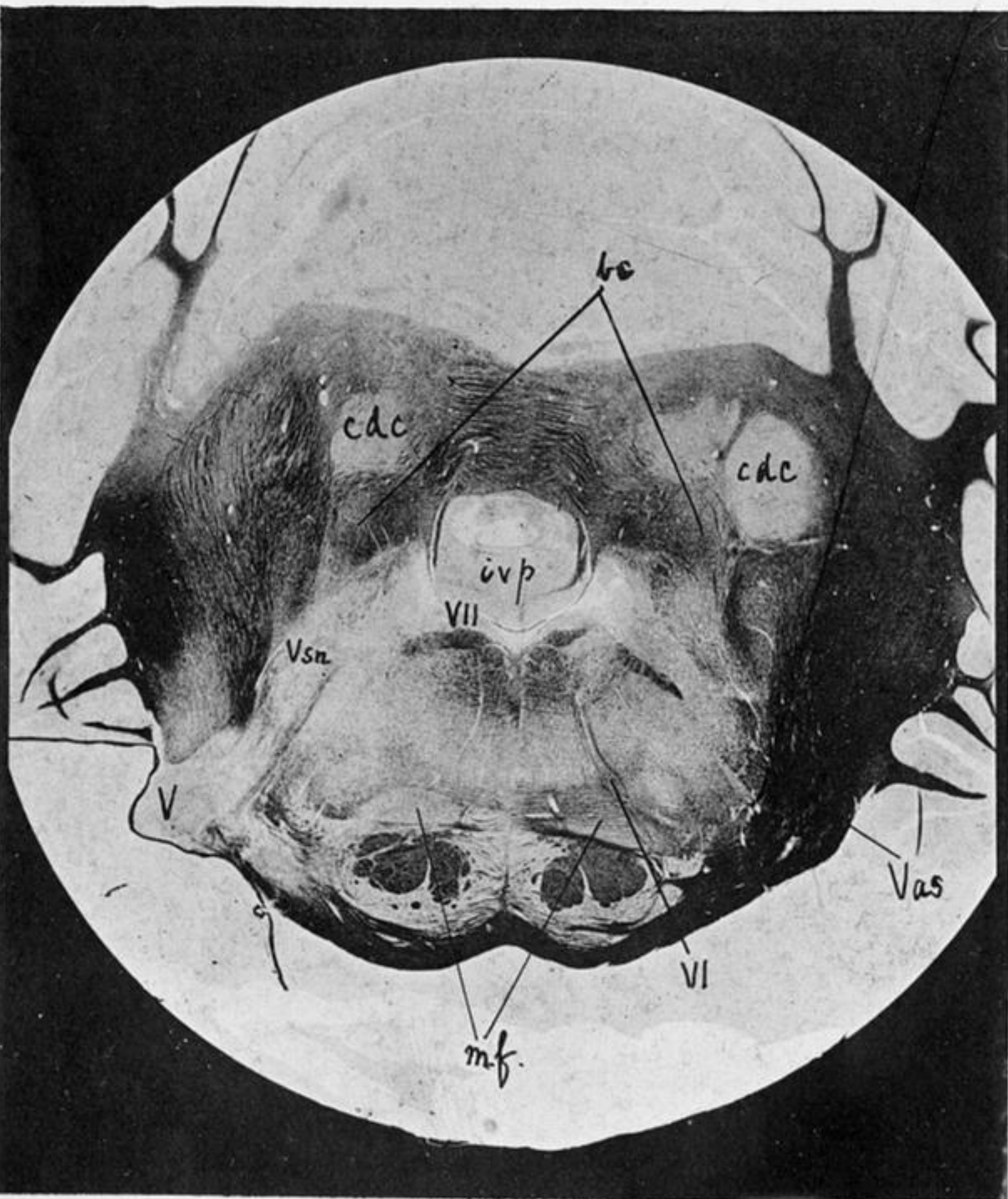
1



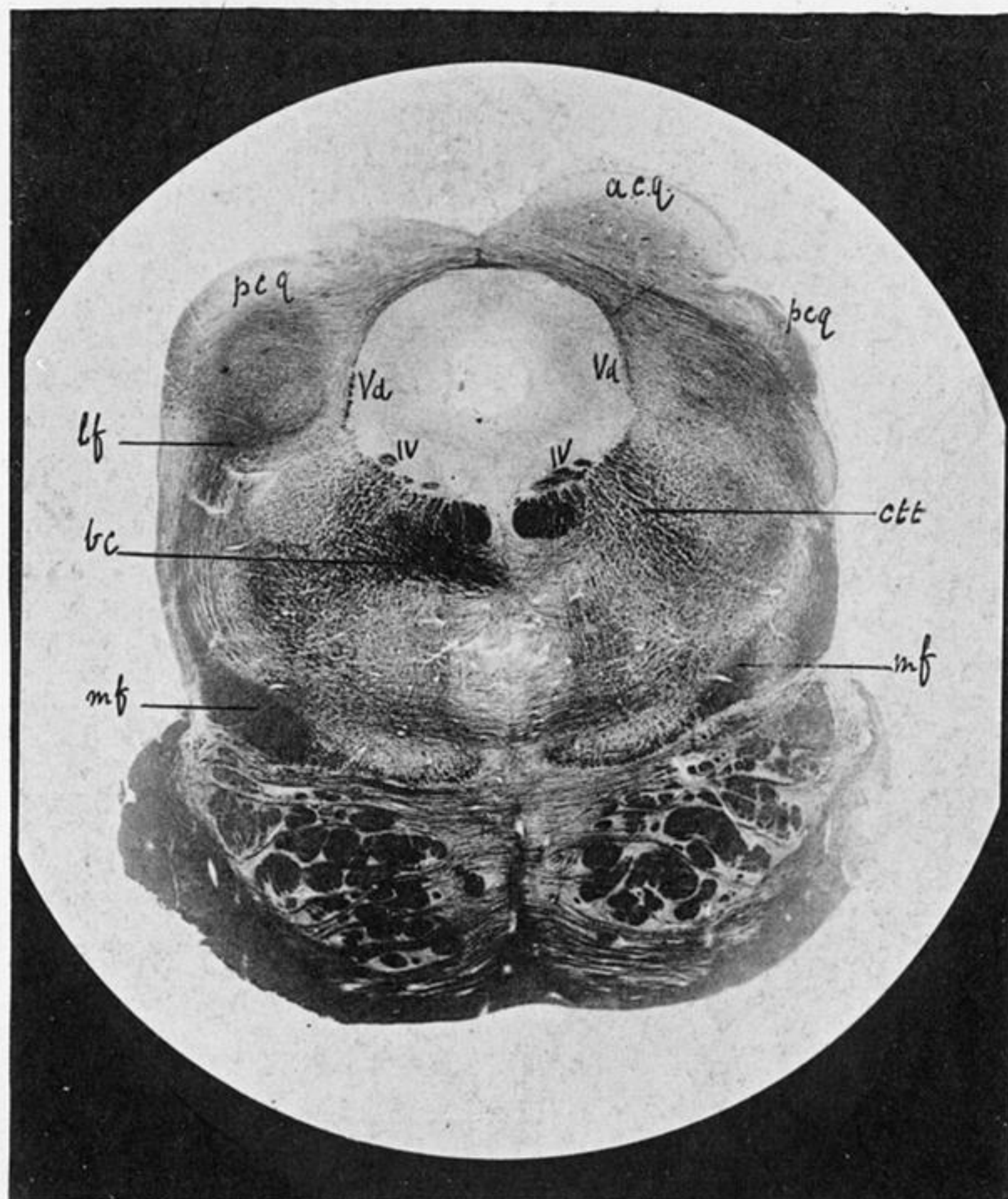
2



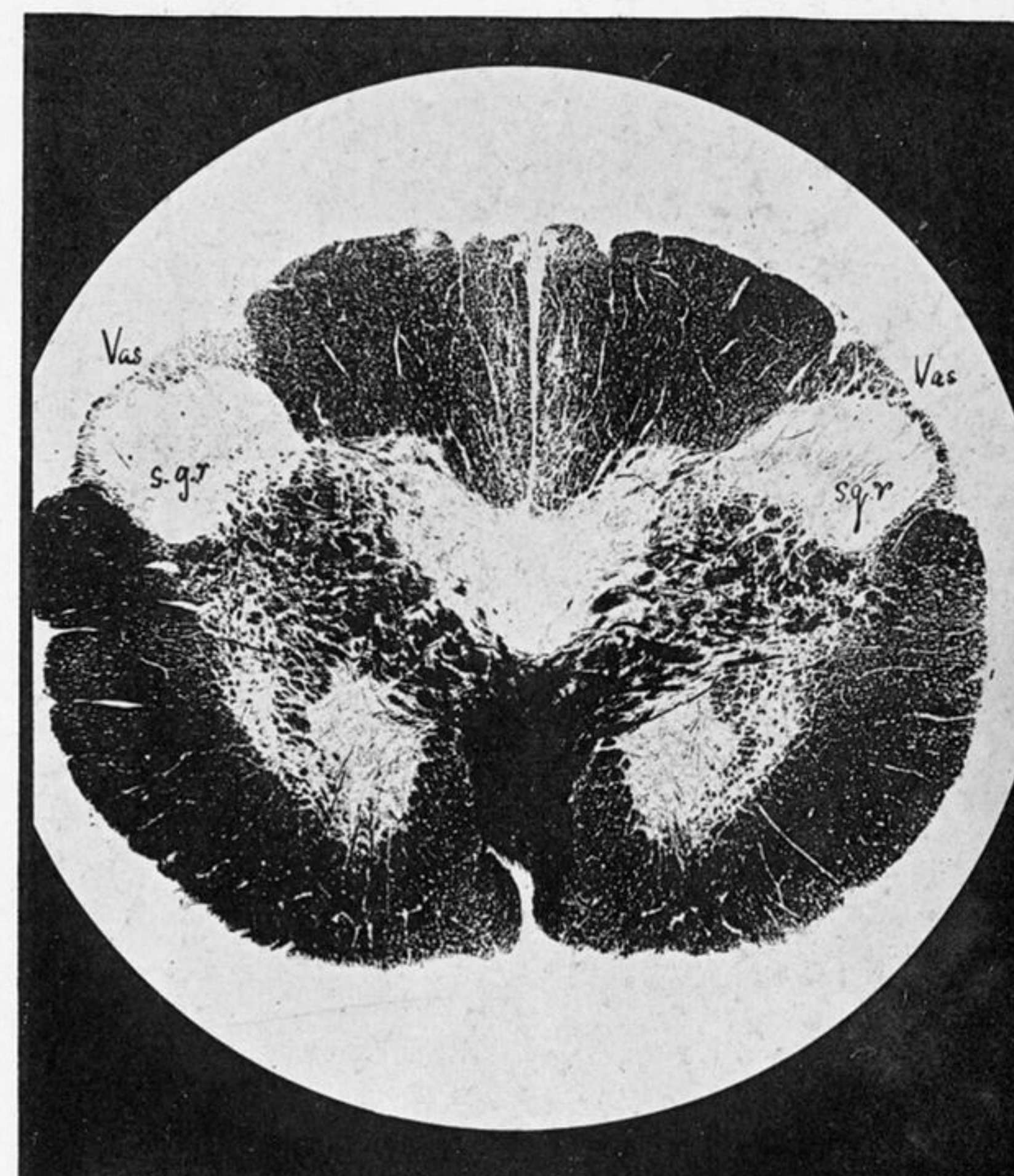3



4



5



6

PLATE 70.

Fig. 1. Frontal section of the upper part of the pons from Exp. 22, in which the cuneate nucleus was destroyed; enlarged 4.5 diameters.

m.f. Mesial fillet, degenerated on the left side.

d.b.c. Decussation of the brachia.

l.f. Lateral fillet.

p.c.q. Posterior quadrigeminal bodies.

a.c.q. Anterior quadrigeminal bodies.

Fig. 2. Frontal section at the level of the anterior quadrigeminal bodies from a case in which the clavate nucleus was destroyed (Exp. 28); 4 diameters.

The lettering is the same as in the preceding case; the mesial fillet is degenerated on the right side.

b.c. The brachia conjunctiva above their decussation.

c.g.e. External geniculate body.

s.n. Substantia nigra.

p.c. Pes crucis.

Fig. 3. Frontal section from the same case as the preceding; 2.75 diameters

m.f. The mesial fillet on the left side has disappeared.

O.th. Optic thalamus.

r.n. Red nuclei.

f.r. Portion of the fasciculus retro-flexus.

Fig. 4. Frontal section through the pons and cerebellum from a case of section of the fifth nerve between the Gasserian ganglion and the brain (Exp. 33); enlarged 3 diameters.

V. Stump of the fifth nerve on the left side.

V., s.n. So-called sensory nucleus of the fifth nerve.

V., as. Ascending trigeminal root.

m.f. Mesial fillet degenerated on both sides from destruction of both clavate nuclei.

VII. Genu facialis.

VI. Sixth cranial nerve.

c.d.c. Corpus dentatum cerebelli.

i.v.p. Inferior vermiform process of the cerebellum.

Fig. 5. Frontal section of the pons from Exp. 5, where, in addition to the extirpation of the lateral lobe, the motor root of the fifth was involved in the lesion, which destroyed the nucleus lemnisci lateralis (fig. 4, Plate 69, X); enlarged 4 diameters (see also Plate 68, fig. 4, V., d.).

V., d. The descending trigeminal root is atrophied on the right side of the figure.

b.c. Brachium conjunctivum, atrophied on the right side of the figure.

p.c.q. Testes.

a.c.q. Nates.

m.f. Mesial fillet.

l.f. Lateral fillet.

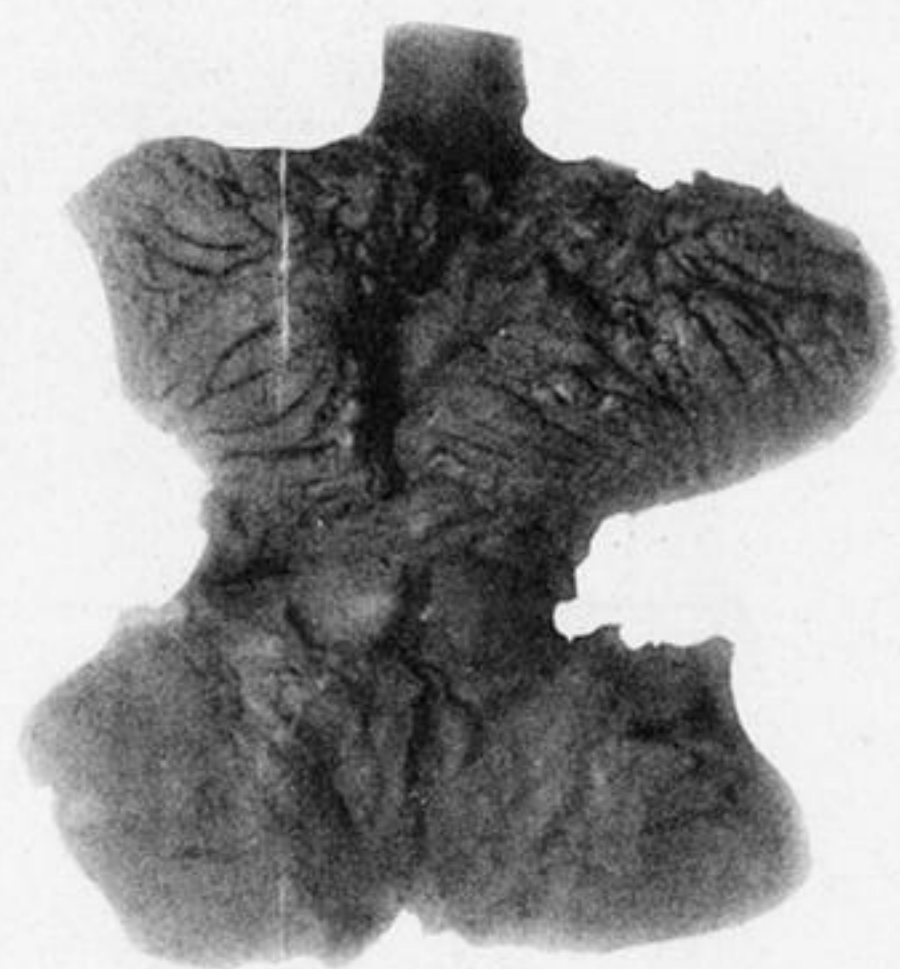c.t.t. Central tegmental tract.

Fig. 6. Transverse section of the pyramidal decussation from Exp. 34, in which the fifth nerve was divided between the Gasserian ganglion and the brain; 10 diameters.

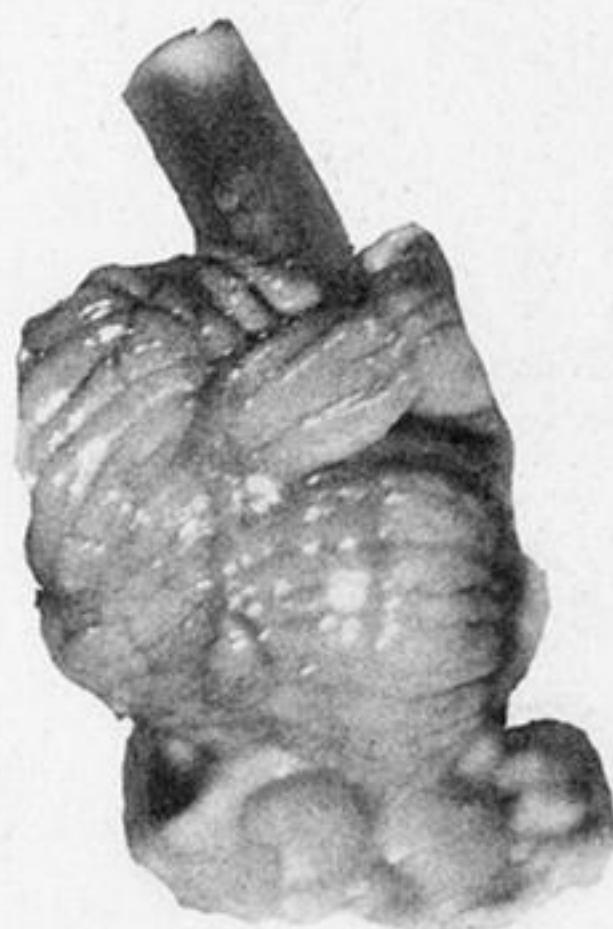
V., as. Ascending trigeminal root, atrophied on the left side.

s.g.r. Tubercle of ROLANDO; the fine fibres passing through are atrophied on the left side.

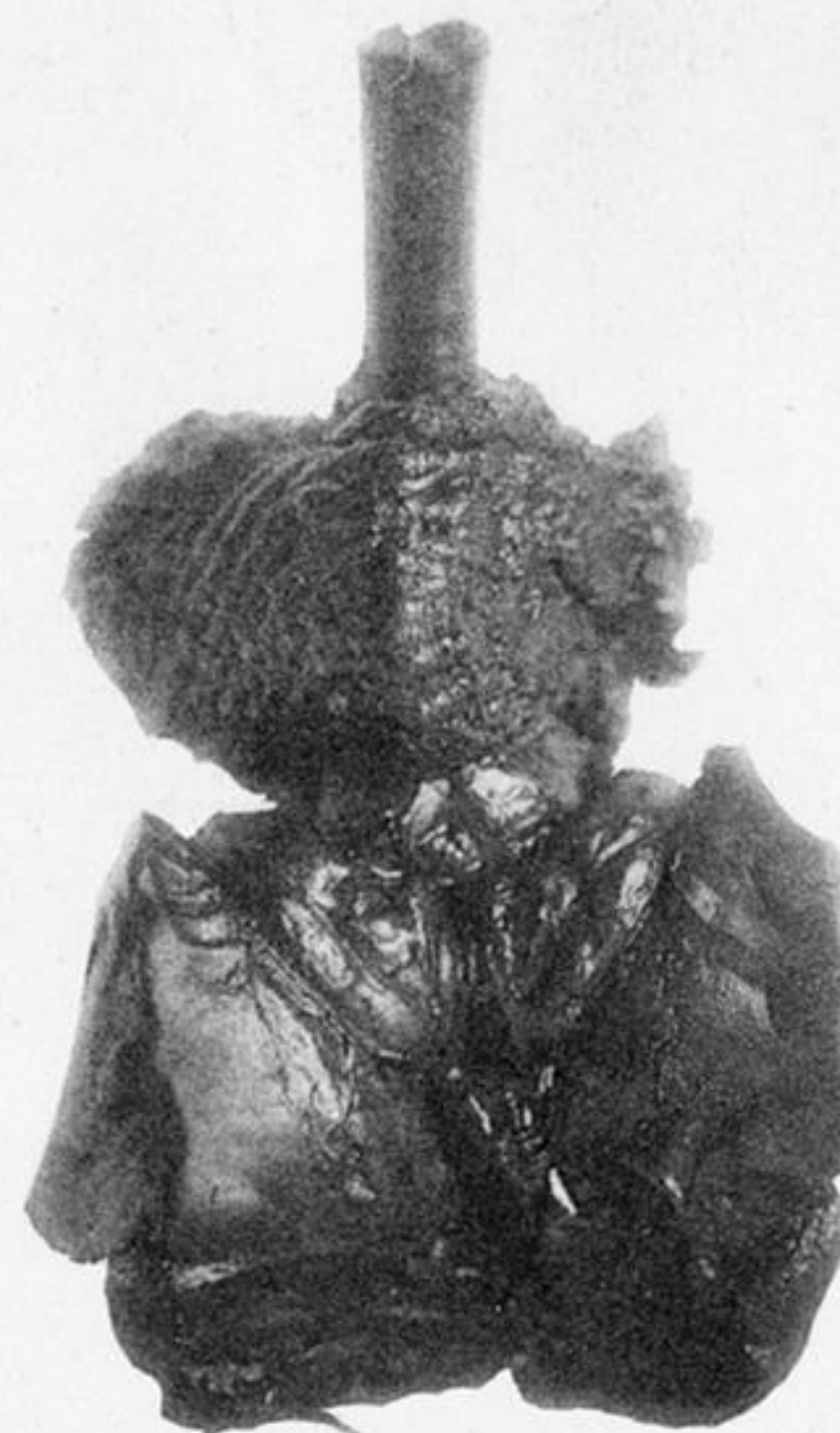
For further illustration of the degeneration of the ascending root, see Plate 69, figs. 2, 4, and 5, V., as.



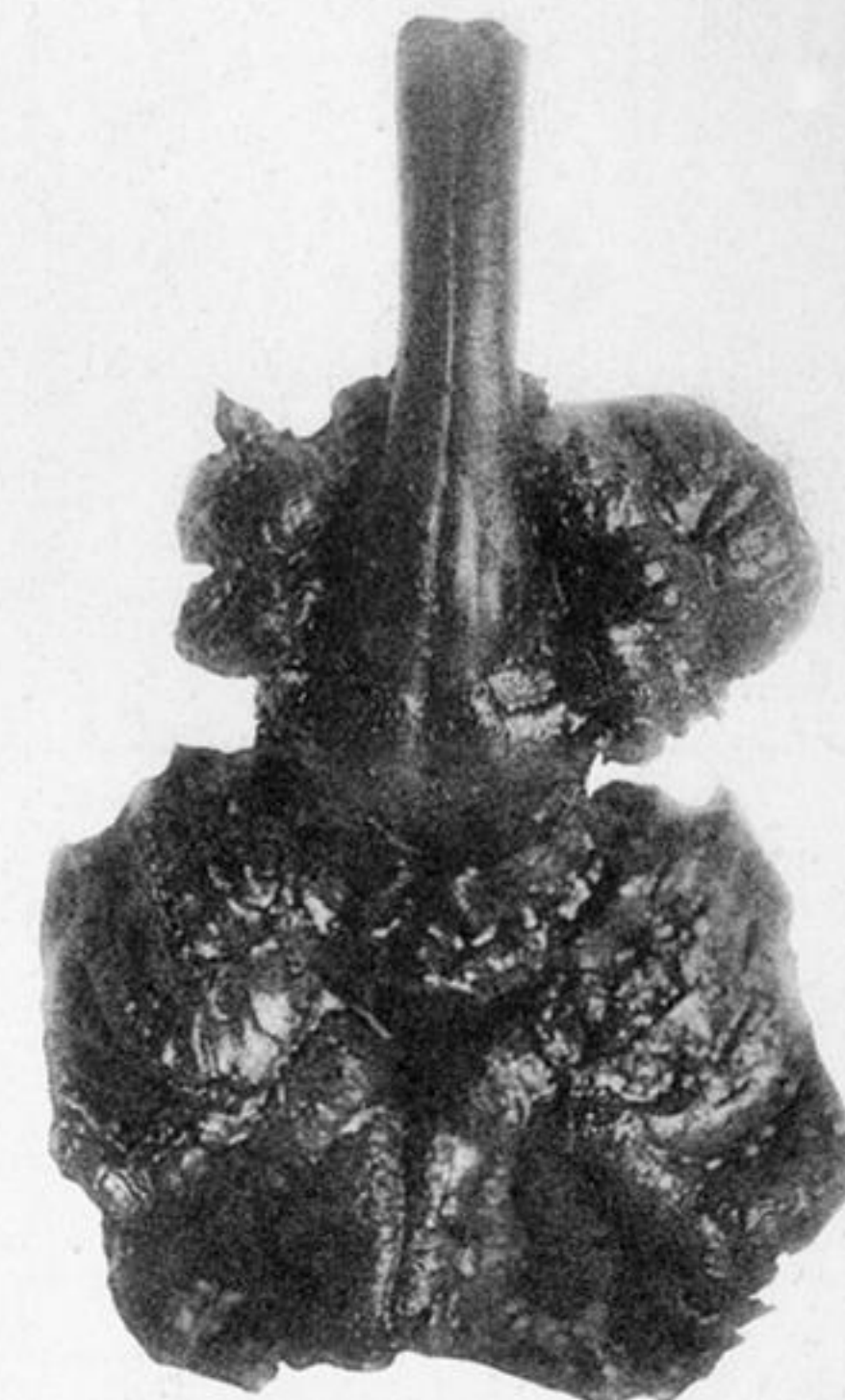1



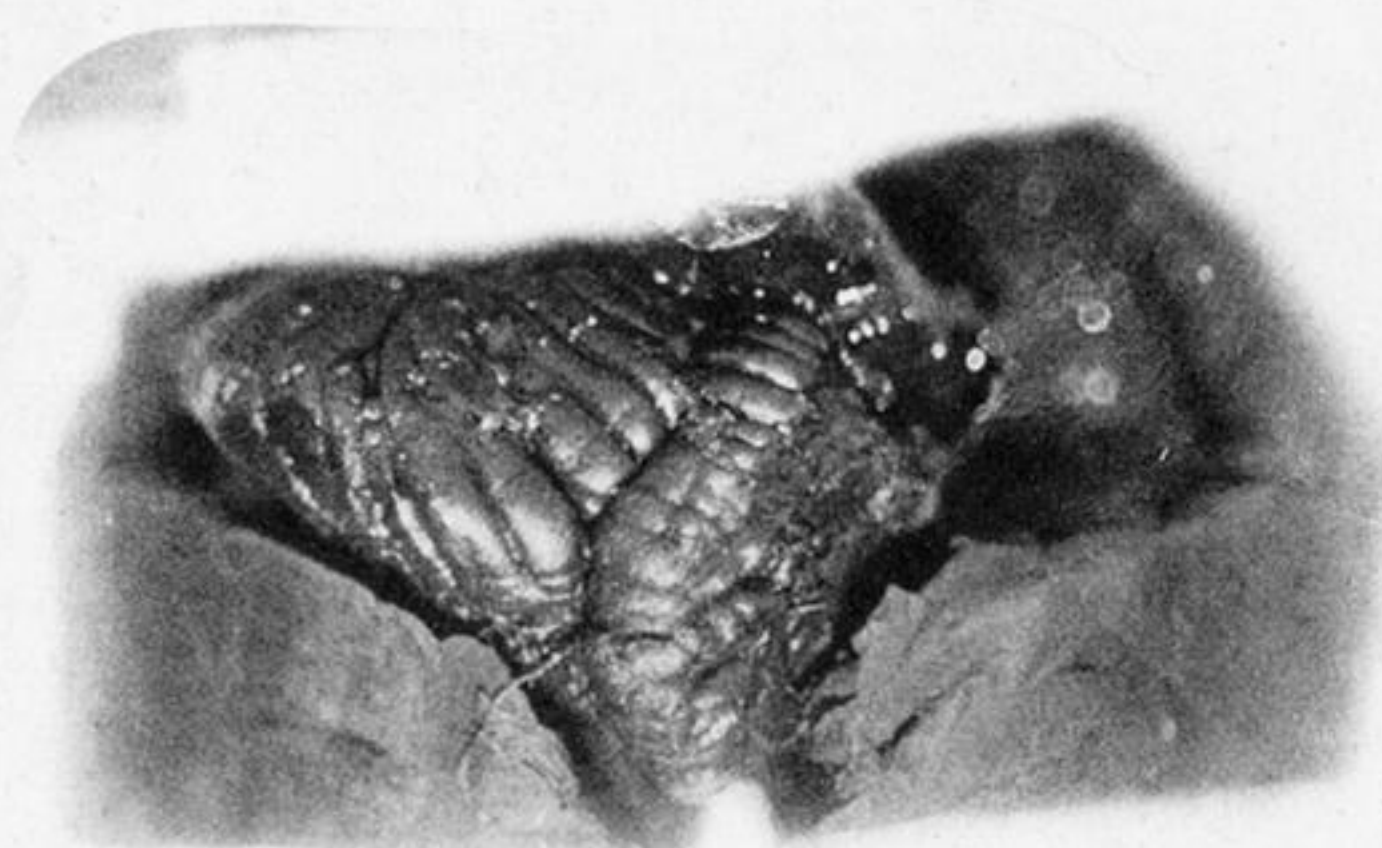
2



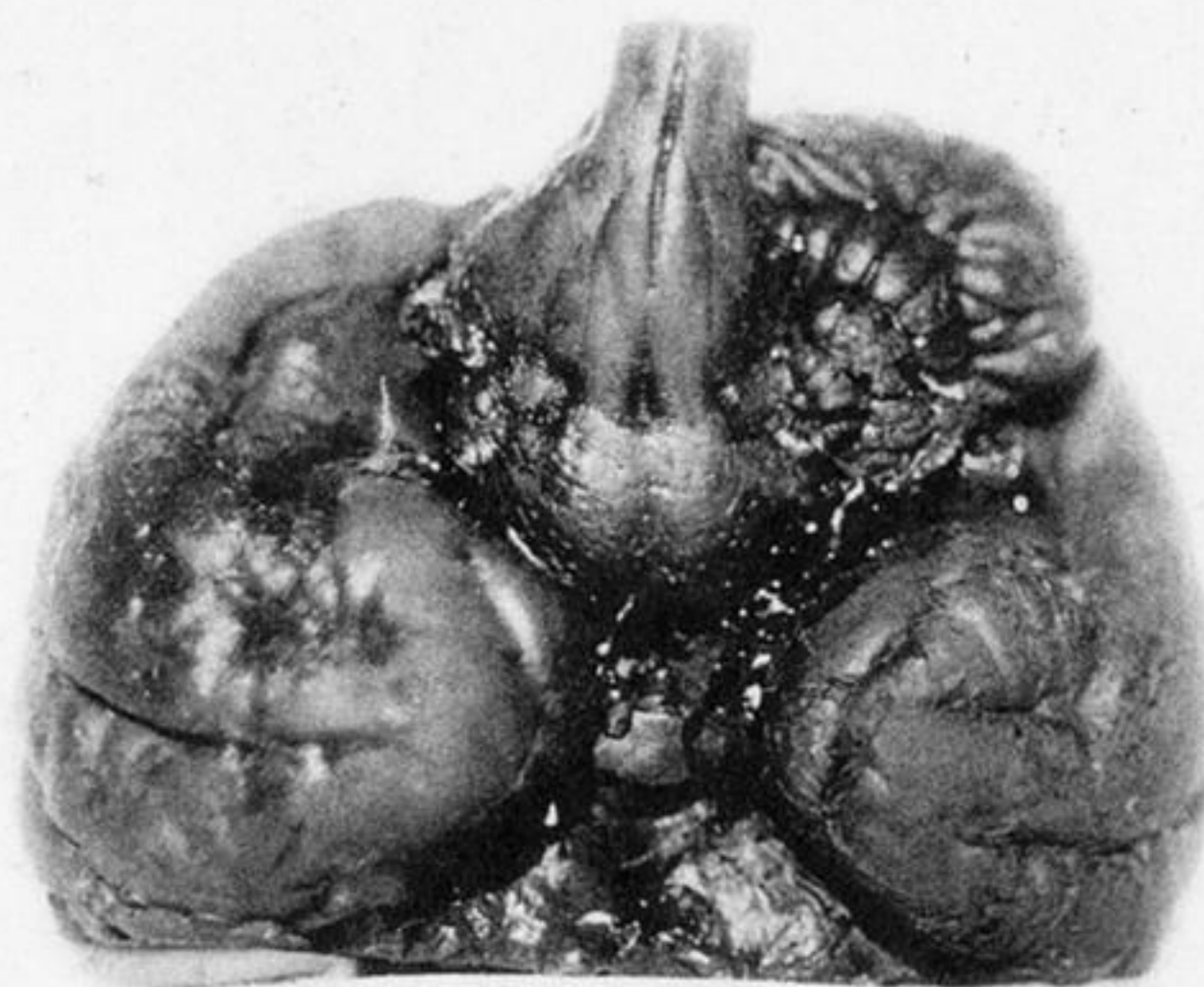
3



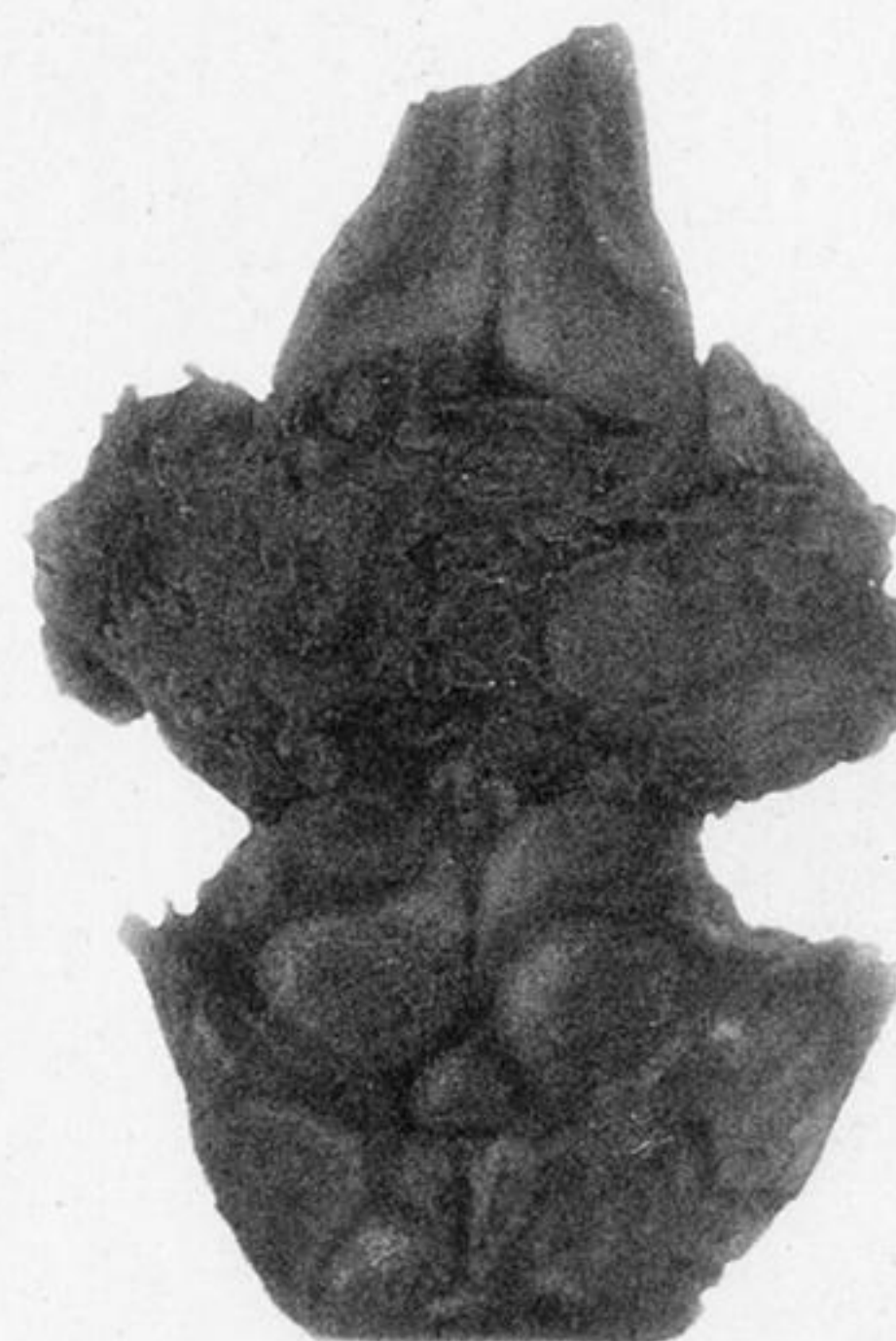4



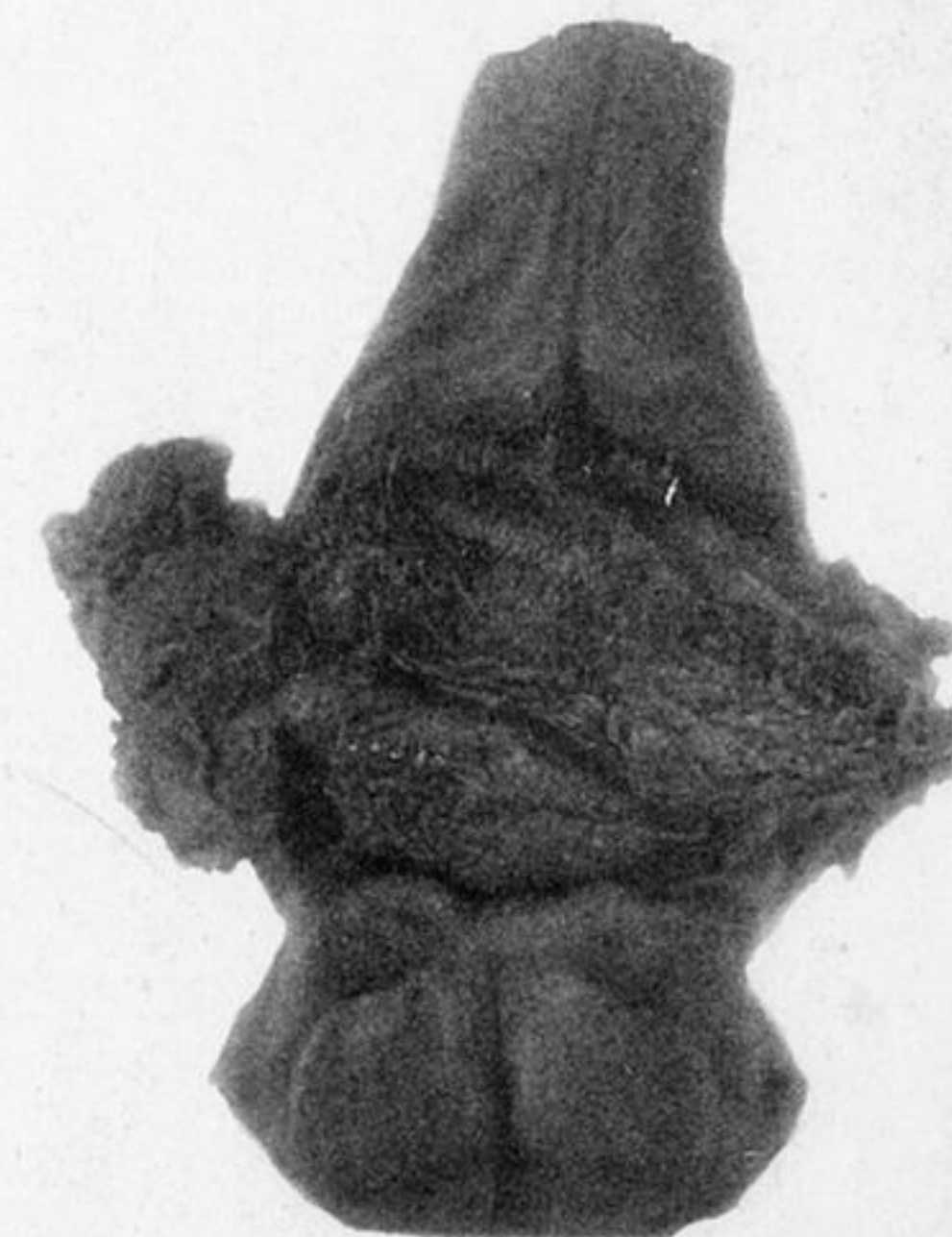5



6



7



8

PLATE 71.

Fig. 1. Photograph from a case of complete cerebellar extirpation. Exp. 1 (text, p. 724).

Fig. 2. Ditto. Exp. 2 (text, p. 725).

Fig. 3. Basal aspect of the brain from a case of removal of the lateral lobe. Exp. 4 (text, p. 727).

Fig. 4. The same case, showing the extent of removal of the cerebellum from behind (text, p. 727).

Fig. 5. Basal aspect of the brain from Exp. 5. Extirpation of the lateral lobe (text, p. 728).

Fig. 6. Dorsal aspect of the same case (text, p. 728).

Fig. 7. Case of removal of the lateral lobe. Exp. 6 (text, p. 730).

Fig. 8. Extirpation of the middle lobe. Exp. 7 (text, p. 731).