

		1.	2.	3.	4.	5.	6.	7.	8.		9.	10.	11.	1
No.	Sex.	Cleido- occipital.	Sterno- cleido- mastoid.	Omo- hyoid.	Digastric.	Trapezius.	Levator anguli scapulæ.	Serrato- vel rhombo- atloid.	Sundries.	No.	Pectoralis major.	Pectoralis minor.	Sterno- scapular.	Latis do
1.	M.	B. ....	B. double clavic. slip.	R. doub. ant. belly. L. clav. origin.	L. receives sty. hyoid.		B. double	B. ....	L. styl. hyoid L. genio-gloss. B. st. thyroid double.	1.				
2.	M.								L. scal. commu- nicating slip. L. imperfect le- vator claviculæ.	2.	B. epigastric slip.			
3.	M.	L. st. slip...				R. to 8th dor- sal spine.		L. ....		3.				
4.	M.									4.				
5.	M.	B. ....								5.				
6.	M.	B. ....	B. double clavic. origin.			B. to 9th dor- sal spine.	R. 6 slips			6.	B. fused with deltoid.			
7.	M.	B. sternal slip.						B. ....	L. levator isth. thyroid. L. cephalo- pharyngeus.	7.				
8.	M.								R. st. thy. clv. slip L. st. hy. tost. thy.	8.	B. fused with deltoid.			
9.	M.			R. clav. slip of st. thy.			R. slip from serr. mag. B. slip. fr. s. med. B. fr. serr. mag.			9.		L. to capsular ligament. B. to glenoid ligament.	B. ....	R. slip 9th in tal fa
10.	M.									10.				
11.	M.	B. ....	B. double clavic. origin.			B. cerv. & dor. portions sep.			R. stern. brut...	11.				
12.	M.									12.	B. fused with deltoid.	B. to glenoid ligament. B. to capsular ligament.	B. ....	
13.	M.	B. double	B. double clavic. origin.	L. no med. tendon.	B. ant. belly decussates.					13.				
14.	M.									14.			B. ....	
15.	M.			R. double. L. clav. orig.						15.		B. to coraco- acrom. lig.	B. ....	
16.	M.				B. double ant. belly.					16.	B. fused with deltoid.			
17.	M.									17.			B. ....	
18.	M.	B. ....								18.				
19.	F.								R. stern. brut...	19.				
20.	F.			L. clavicular origin.			B. double	L. ....		20.	B. double clavic. or.			
21.	F.									21.				
22.	F.									22.				
23.	F.	B. ....						L. ....		23.				
24.	F.									24.				
25.	F.	L. ....							B. platysma sternal slip. L. thyro-hyoid differentiated.	25.	B. epigastric slip.			
26.	F.	B. ....								26.				
27.	F.									27.				
28.	F.	B. ....								28.		B. to capsular ligament.		
29.	F.						L. fr. serr. sup. B. fr. scal. post.			29.		B. to capsular ligament. B. to capsular ligament.		L. dors epitroc
30.	F.	B. ....	B. double clavic. origin.			B. joins ster- no-mastoid.				30.			L. ....	
31.	F.									31.			B. ....	
32.	F.									32.				
33.	F.			R. clavicular origin.	L. double ant. belly.		R. slip to splen. capitis.		R. levator isth. thyroideæ.	33.		R. into clav. B. to capsular ligament.	R. ....	B. slip fascia
34.	F.									34.				
35.	F.	L. ....	L. double clavic. origin. B. double clavic. origin.			R. loop for omo-hyoid.				35.			B. ....	
36.	F.									36.			R. ....	
		14	7	6	4	5	7	5	12		7	10	10	3



1.	12.	13.	14.	15.	16.	17.	18.	19.	20.	21.	22.	23.	24.
Pro-nular.	Latissimus dorsi.	Coracobrachialis.	Biceps.	Brachialis anticus.	Anconeus epitroch.	Pronator radii teres.	Flexor sublimis <sup>1</sup> digitorum.	Flexor. profundus digitorum.	Flexor longus pollicis.	Lumbricales nanūs.	Flexor carpi radialis & F. c. r. brevis.	Palmaris longus.	Extensor carpi radialis longus & access.
		B. double ..				B. double ..		R. coron. slip to 2nd tend. B. coron. slip to 1st tend. B. coron. slip to 2nd tend.				L. double ..	L. blend with ext
					B.								L. blend with ext
					B.	B. double ..	L. slip to 1st lumbricalis.	B. radial slip to 1st tend.	B. coronoid origin. B. fusif. cor. origin. B. condyl. & cor. origins. L. coronoid origin.	L. st bipenn. 3d double. B. st & 2nd bipenniform.			B. slip o access
				B. slip to supin. long.			B. double 2nd tendon.	R. slip to 2nd lumb.	R. coronoid origin.	R. & 4 doub. L3rd doub. B. 3rd doub.		L. double ..	L. slip o access R. 2 ten
R. slip from 9th. intercostal fascia.	R. to brach. anticus. R. double ..			R. brachioradialis.				L. coron. slip to 1st tend.	L. coronoid origin. R. coronoid origin. B. coronoid origin. B. fusif. cor. origin. R. coronoid origin.			R. median belly.	R. ext. a distim. R. blend with t
			L. 3rd head.		L.		B. double coronoid origin.			R. ind bipenniform.		R. into scaphoid. R. rudimentary.	L. 2 ten
											R. slip to trapezium. R. slip to trapezium.		L. slip o access
			B. 3rd head.		B.		B. double coronoid origin.	L. coron. slip to 1st tend.	B. slip to flex. prof. L. coronoid origin. B. coronoid origin. B. coronoid origin.		L. slip to trapezium.	R. double ..	B. slip o access
										L. st, slip fr inteross. L. 3rd doub. 4h absent.		B. slip to abd. pollic. B. tendon split up.	B. slip o access
							L. 4th tendon absent. L. slip to palm. B. doub. cor. or.	B. flexor indicis.	B. coronoid origin. B. coronoid origin. B. coronoid origin.				
		L. double		L. brachio-fascialis.		B. double	B. 3 tendons...	L. coron. slip to 2nd tend.	B. coronoid origin. B. coronoid origin.			R. absent.	
		B. double. L. cor. brach. brevis. B. double	L. 3rd head. B. 3rd head. L. 3rd head.	B. double ..			L. sep. muscle to index digit.	R. coron. slip to 2nd tend. B. coron. slip to 2nd tend.	B. coronoid origin. B. coronoid origin.				
									B. coronoid origin. B. coronoid origin.				
								B. coron. slip to 2nd tend.	L. coronoid origin. R. slip to fl. profundus. R. coronoid origin.		L. brevis to ann. lig.	B. absent .. L. rudimentary.	L. slip o access R. slip o access
L. dorso-epitrochlear.	B. to internal condyle.		R. 3rd head.			L. single head	B. double coronoid origin. R. sep. dig. slip to 2nd and 5th. L. double coronoid origin.	L. coron. slip to 3rd, 4th, & 5th dig.	R. coronoid origin. L. slip to prof. B. cor. orig. B. coronoid origin. B. coronoid origin. R. coronoid origin.		L. slip to trapezium. L. brevis to os magnum. L. slip to trapezium.	R. absent. L. med. belly	R. blend with bre
B. slip to fascia.			L. 3rd head. L. 3rd head.			B. double	B. double coronoid origin. R. double coronoid origin.			B. 2nd bipenniform.		L. med. belly doub. tend.	
												L. absent ..	
	3	7	8	4	4	5	13	14	29	8	7	15	12

	24.	25.	26.	27.	28.	29.	30.	31.	32.	33.	34.	35.	36.
	Extensor carpi radi- alis longior & accessor.	Extensor intermedius.	Extensor carpi radialis brevior.	Extensor communis digitorum.	Extensor minimi digiti.	Extensor carpi ulnaris.	Extensor ossis met. pollic.	Extensor primi inter- nodii pollicis.	Extensor secundi internodii pollicis.	Extensor indicis.	Extensor pollicis et indicis.	Extensor medii digiti.	Extensor brevis manūs.
	L. blended with ext. brv.	B. fr. both	L. blended with ext. long.		B. doub. mus. slip. to 4th dig.		B. 2 tendons.						
	B. slip of accessorius.	B. fr. longior to brevior.			B. 2 tendons.		B. 2 tendons.	B. insert. with ext. secund.					
	L. slip of accessorius.	L. fr. both to 2nd metacarp.		B. differen- tiated.	B. 2 tendons.		B. 2 tendons.	L. insert. 2nd phalanx.					
	R. 2 tendons.		L. to 2nd & 3rd metac. B. to 2nd & 3rd metac.	B. med. tend. L. 3 to min. dg.	R. 2 tendons. L. absent.	B. slip. to 5th metacarpal. B. slip. to 5th digit.	B. 2 tendons.	R. blended with ossis. L. 3 tendons. R. 2 tendons.	B. 2 tendons. L. slip. fr. ext. primi.	B. 2 tendons.			B. 3 slips to 3rd & 5th dig. R. 1 slip to mid. dig.
					B. 2 tendons.		B. 2 tendons.						
	R. ext. acces. distinct.		B. to 2nd & 3rd metac.		B. 3 tendons.	R. slip to 1st to 4th dig.	R. 3 tendons.						
	R. blended with brev.	L. distinct muscle.	L. to 2nd & 3rd metac.	R. slip to pollex.	B. 2 tendons.	B. slip to 5th digit.	B. 2 tendons.	B. slip to 2nd phalan.		B. 2 tendons.	R.		
	L. 2 tendons.	L. longior to brevior.	B. to 2nd & 3rd metac. B. to 2nd & 3rd metac.	B. med. tend.	B. 2 tendons.	R. slip to 5th digit.	B. to trapez. opp. & abdr.	B. blended with ossis. R. inserted with secund.	B. 2 tendons				
							B. 2 tendons.	L. absent					
	L. slip of accessorius.	B. longior to brevior.	B. to 2nd & 3rd metac.	R. 2 tends. to 5th digit.	B. 2 tendons.		B. 3 tendons.			L. radial origin.			
	B. slip of accessorius.	R. fr. both	L. to 2d & 3d by 2 tends.	B. 2 tends. to 5th digit.	B. 2 tendons.		L. 2 tendons.	L. inserted with secund.	L. 2 tendons.			L. with in- dicator.	
		L. longior to brevior.	B. to 2d & 3d by 2 tends.		B. doub. mus. slip to 4 dig.	R. slip to 5th digit.	R. 3 tendons. L. 2 tendons.	B. slip to ext. secund.	R. 2 tendons.			R. imperfect with indic.	
					B. 2 tendons.		B. 2 tendons.	B. absent		B. 2 tendons.			
			L. to 2nd & 3rd metac.		R. 2 tendons. 1st to 4th dig.		B. 2 tendons.	B. slip to 2nd phalan.					
		L. distinct muscle.	L. to 2nd & 3rd metac.		L. 2 tendons.		L. 2 tendons.	L. absent	L. slip to 1st phalx.				B. 1 slip to mid. dig.
		L. fr. brevior to longior.			L. 2 tendons.		B. 3 tendons.	R. 2 tendons				B. with in- dicator.	B. 2 slips to 3rd & 4th dig.
				B. 5 tendons.	B. 2 tendons.		B. 2 tendons.					L. with in- dicator.	
	L. slip of accessorius.	L. fr. both.	R. to 2nd & 3rd metac.	L. slip to ext. secund.	L. 2 tendons.	B. slip to 5th digit.	B. 2 tendons.			L. 2 tendons.		B. distinct and peculiar.	
	R. slip of accessorius.	R. double			B. 2 tendons.		B. 2 tendons.	B. blended with ossis.	B. 2 tendons.			R. with in- dicator.	
		L. fr. long. to brevior.	R. slip to interosseus. R. slip to 2nd inteross.	B. index tend. separate.	B. 2 tendons.		B. 2 tendons.	B. blended with ossis. R. blended with ossis.					
	R. blended with brevior.		L. to 2nd & 3rd metac.		L. 2 tendons.	L. slip to 5th metac.	L. 2 tendons.		R. 2 tendons.				
			B. to 2nd & 3rd metac.	B. tend. mult R. slip to dor- sal fascia.	R. 3 t. 1 to 4. L. 2 tends.		B. 2 tendons.	B. 2 tendons slip to sec.	B. 2 tendons.	L. double muscle.	B.	B. distinct	R. 3 slips to 2, 3, & 4 dig.
		R. from both.	B. to 2nd & 3rd metac.		B. 3 tendons. slip to 4th dig		L. 3 tendons. R. 2 tendons.		R. 2 tendons.	B. slip from ext. med. dig.		B. with in- dicator.	
		L. long. to brv.	B. to 2nd & 3rd metac.	B. 2 tendons.	B. 2 tendons.		B. 3 tendons.		L. 2 tendons.	B.			
				L. tendons multiplied.	L. 2 tendons.		B. 2 tendons.						
	12	13	18	12	35	8	33	19	11	9	3	8	6

36.	37.	38.	39.	40.		41.	42.	43.	44.	45.	46.	47.	48.
Extensor revis manūs.	Abductor pollicis.	Abductor min. digit.	Inter- osseus.	Sundries.	No.	Pyriformis.	Gemelli.	Plantaris.	Flexor long. digitorum and Lumbr. pedis.	Flexor longus hallucis.	Extensor primi internodii hallucis.	Extensor longus digitorum.	Peroneus tertius.
					1.				B. 4th lumbr. absent.		B. double fr. propr.	B. 4 separate muscles.	B. 3 tends. 2 join ext.long.
3 slips to d & 5th dig. 1 slip to mid. dig.	B. double slip to opp.	R. 2nd head. B. double. Fl.br. absent.	B. primus volaris. B.pr. volaris. 1st dor.doub. B. pr.volaris.	L. scapulo- clavicular	2.						B. fr. extens. proprius.		
					3.			R. double muscle.					
					4.	B.insert.with obt. int.	B. superior absent.		B. slip to flex. hall. long.		B. fr. propr.		B. 2 tends.
					5.						B. fr. tibialis anticius.		R. 2 tends.
					6.						B. fr. propr.	L. tend. to 5th metat.	
1 slip to mid. dig.	B. double slip to opp.		B. pr.volaris.	B. infra- spinatus.	7.						R. fr. tibialis anticius.		R. slip to 4th inteross.
					8.				B. 3rd lumbr. double.		B. fr. propr.		L.to4th inter.
					9.				L. 4th lumbr. double.		B. fr. propr.		R. absent.
					10.						L. fr. propr.		R. 2 tends. slip to 4 inter.
		L. high double orig.			11.				R. slip to fl. brev. of 3 toe.		B. fr. tibialis anticius.		
				L. chondro- coracoid.	12.				R. slip to flex. hall. long.				
					13.						B. fr. propr.		
					14.						B. fr. propr.		
					15.	B.insert.with obt. int.					R. fr. lig.t. of ankle-joint.		B. 2 tends.
					16.						B. fr. propr.		slip to ex.br.
					17.	B.insert.with obt. int.	R. superior absent			B. no slip to flex. digit.	B. fr. propr.		B. insert.
					18.						B. fr. propr.		4th metat.
					19.	B.insert.with obt. int.	R. both abs. L. sup. abs.						R. mid.of 5th L. 4th metat.
		B. 2 tendons.			20.			L. absent			B. fr. propr.		
1 slip to mid. dig.	L. double		B. pr.volaris.	R. sup. long with rad. ext	21.	R. split					B. fr. propr.		R. absent
					22.			B. mus. slip to lig.of knee	R. slip to flex. hall. long.				
2 slips to d & 4th dig.					23.						B. fr. propr.		R. absent
					24.						B. fr. propr.		
					25.						B. fr. propr.		
					26.								
			B. pr.volaris.		27.				R. slip to flex. hall. long.	R. slip fr. flex. access.	B. fr. propr.		R. slip to 4th inteross.
					28.						B. fr. propr.		
					29.				R.tnd.to2abs. slip to flx.hal.	R. tend. to 2nd toe.	B. fr. propr.		B. 2 tends.
					30.				L. slip to flex. hall. long.		B. fr. propr.		1 to 4th int.
					31.	R. split				B. very large slip to fl.com.			
			L. pr.volaris.		32.								
3 slips to 3, & 4 dig.	B. double	R. double	B. pr.volaris.		33.						B. fr. propr.	B. slip to 2nd tend. of ext. brev.	
					34.						B. fr. propr.		B. to 4th met. slip to 5 met.
				B. depressor scapulæ. R. palmaris brev. abs.	35.						B. fr. propr.	R. 2 tends.to 5th metat.	R. slip to ext. long.
					36.						B. fr. propr.		
6	4	5	8	6		6	3	3	10	4	29	4	15

48.	49.	50.	51.	52.	53.	54.	55.	56.	
Peroneus tertius.	Peroneus brevis.	Peroneus quinti.	Extensor brevis digitorum.	Abduct. ossis metatarsi quinti.	Flexor brevis digit. pedis.	Abductor hallucis.	Opponens min. digit.	Sundries.	
3 tends. 2 n ext. long.			R. slip to 2nd toe.		B. 3 tends. 4th absent.				13
				B.					17
	B. slip to cuboid.	R. complete.	R. slip to 1st inteross.	B.					20
2 tends.		B. to 5th metatarsal.	R. 2 tends. to 2nd toe.		R. 3 tends. 4th absent.		B.	R. iliac. int. divided.	20
2 tends.				R.		R. large ins. to 2nd toe.			15
									16
slip to h inteross.		B. complete.		B.				L. 3rd head to gastroc.	25
to 4th inter.	B. slip to per. tert.	L. complete.	L. 2 tends. to 2nd toe.	L.	R. 4t. tend. abs. perfor. to 3rd				13
R. absent. 2 tends.									13
to 4 inter.									13
		R. compl. fus. mus. belly.		R.	L. fr. access. to 3 toe tend.	L. slip to 2nd toe.			24
		L. complete.		R.					15
				B.					18
		B. to 5th metatarsal.							7
		B. complete.							16
2 tends.		B. complete.		B.					16
to ex. brv.		B. complete.	B. 2 tends. to 2nd toe.	L.					20
insert. 4th metat.				L.		B. slip to 2nd toe.			14
									266
mid. of 5th 4th metat.				B.					12
				B.	B. 3 tends. 4th absent.	B. slip to 2nd toe.		B. abd. min. dig. 2 tends.	19
absent		L. complete		L.	R. 3 tends. 4th absent.		B.		15
		B. complete.	L. 2 tends. to 2nd. R. slip to 1st inter.	B.	B. 3 tends. 4th absent.			L. slip fr. add. br. to obt. ex.	17
absent									14
		B. to 5th metatarsal.							8
		R. to 5th metatarsal.							11
		B. to 5th metatarsal.							4
slip to 4th nteross.		L. to 5th metatarsal.						R. fl. brv. hall. slip. fr. tib. posticus.	16
							R.		12
2 tends. to 4th int.	B. slip to per. tert.	B. to 5th metatarsal.					B.	L. mus. slip fr. pect. to add. long.	20
							L.		16
									15
		L. complete.							12
			B. 2 tends. to 2nd toe.	R.				R. fl. long. ac- ces. fr. fib.	21
to 4th met. to 5 met. slip to xt. long.		B. complete.		L.					16
				B.					16
		B. to 5th metatarsal.	R. 2 tends. to 2nd toe.	B.			B.		18
									262
15	3	20	8	19	7	4	6	7	558

XVII. "Variations in Human Myology observed during the Winter Session of 1867-68 at King's College, London." By JOHN WOOD, F.R.C.S., Examiner in Anatomy to the University of London. Communicated by Dr. SHARPEY. Received June 10, 1868.

On giving the results of our observations in this branch of scientific inquiry, my thanks are again due to the zeal and increased experience of my assistants in the dissecting-rooms, and especially to Mr. J. B. Perrin, by whose constant labour and vigilance my work has been most materially aided. Of the 36 subjects dissected, not one has been found totally wanting in departures from the standard descriptions of the muscular system given in anatomical text-books. Some of the more common variations, which are usually mentioned by our best authors, have been included this year with a view of determining their relative frequency. Others have been comprised which seem to show the first evidences of a tendency to the more complete and striking abnormal forms.

These I have deemed of much importance in throwing light upon the origin of the more complete variations. Many of them have been found so often as materially to add to the total number of abnormalities in the Table, and also to the labour of searching out and classifying them.

With few exceptions, the *lines of variation* have been found in the same grooves as in former sessions, as will be seen by comparing the Tables. Our observations have still been confined to the muscles of the head and neck, arms and legs, not noting those of the face, back, or abdomen, except in the case of unusual eccentricity of formation. All the more important formations have been sketched by myself from the subject; and the greater part of those which have been simply noted have also been previously examined by me. The proportion of the two sexes happens this year to have been exactly equal, giving us a fair opportunity of comparing the proportionate frequency of muscular abnormalities in each. For the sake of greater convenience of reference, they have been placed separately in the Table.

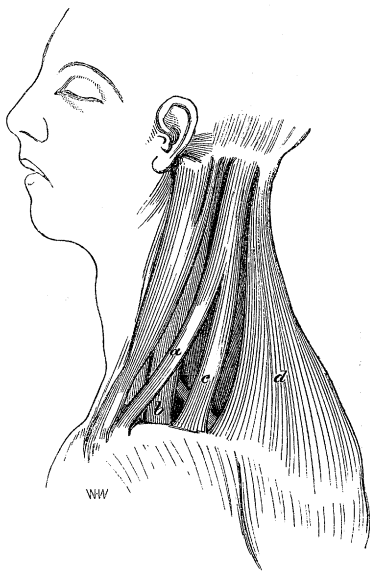
In the 36 subjects, 18 *males* and 18 *females*, we have the large number of 558 muscular variations, of which 20 were found in the *head and neck* proper, 390 in the *arms* (including those lying in the neck which act upon the upper extremity), and 148 in the *legs*. But although the absolute number of specimens found is so much greater than in former years, the *lines of variation* are not proportionably increased, amounting to 72 as compared with 61 of last year. Of these 13 were found in the *head-* and *neck-*muscles proper, 37 in the *arm*, and 22 in the *leg*—the greatest increase being in the *arm*.

In the first section of the accompanying Table will be found 20 speci-

mens affecting 13 muscles proper to the *head and neck*, and 40 others affecting 6 muscles which, acting upon the clavicle or scapula, are numbered with the muscles of the upper extremity, viz. the cleido-occipital, sterno-cleido-mastoid, omohyoid, trapezius, levator anguli scapulæ, and levator claviculæ.

1. *Cleido-occipital* (*Cephalo-humeral* of the lower animals).—Of this muscle 8 specimens have been found in the *male* subjects, all on both sides—and 6 in the *females*, two of which were on the left side only. On the left side of No. 3, male, and on both sides of No. 7, male, the curious and interesting arrangement was found which is drawn from the former subject in fig. 1. A slip of parallel muscular fibres, three-fourths of an inch wide (*a*), arising from the sternal end of the clavicle, close outside of and in connexion with the sternal origin of the sterno-mastoid, crossed superficially and obliquely the cleido-mastoid (*b*) (which was split into two parts) to join the *cleido-occipital* (*c*) about its middle. The more usual clavicular attachment of the latter muscle was broad, and connected with the centre of the clavicle directly over the posterior triangle, reaching from the origin of the cleido-mastoid as far out as the clavicular attachment of the trapezius (*d*). This arrangement gives a very complex appearance to the whole group of muscles, and strikingly resembles the formation in the Marmot, Polecat, Genette, and striped Hyæna, and, to a less extent, in the Coati. In these animals the cephalo-humeral is only connected with the trapezius close up to the occiput.

Fig. 1 (Subject No. 3).



Towards the clavicle it is continued forward, superficial to the cleido-mastoid, and joins wholly or by a separate slip with the sterno-mastoid (see Cuvier and Laurillard's plates). This resemblance to the *cephalo-humeral* of these animals tends strongly to confirm the view of the homology of the *cleido-occipital* in Man, given by the author in former papers. On the right side of the subject No. 3, the cleido-occipital was large, but presented no slip of connexion with the sterno-mastoid; but it was found on both sides of No. 7. A tendency to this formation was seen also in subject No. 21 of last year's Table.

In No. 13 the cleido-occipital was double, and distinct from both the cleido-mastoid and trapezius along its whole length. This homologue of the *cephalo-humeral* of animals was found distinct and very well marked

by Murie in his dissection of a Bushwoman (Journal of Anatomy and Physiology, No. 2, May 1867, p. 198).

2. *Sterno-cleido-mastoid*.—In 4 *male* and 3 *female* subjects out of the 36, the *clavicular* origin of this muscle was double, or divided into two portions. In all but one of these the cleido-occipital was also present.

3. *Omohyoid*.—In 2 *male* and 2 *female* subjects the *posterior belly* presented an additional or *clavicular* origin. Three were found on the left side only, and one on the right only. On the opposite side of one *male* (No. 15), a muscular slip arising from the middle of the clavicle (quasi-clavicular origin of the omohyoid) passed upwards and inwards to join the *sterno-thyroid* at its insertion, the omohyoid itself on that side being normal, with the exception of having *no* median tendon. In No. 9 the omohyoid, otherwise normal, passed through an opening between the normal origin of the *sterno-thyroid* and an abnormal slip to that muscle from the clavicle, at the junction of its middle and outer thirds. In No. 13 also, the *median tendon* of the omohyoid was wanting, a continuity of muscular fibre passing from its origin to its insertion. This is always the case in Monkeys and the lower mammalia. In a *male* subject (No. 2) the *anterior belly* was double, the superior one fusing with the *hyoglossus* and *middle constrictor* muscles, and receiving, moreover, a slip from the middle of the *sterno-thyroid* (see fig. 2 h).

Out of 70 subjects now examined by the author with a view to the abnormalities of the *omohyoid* muscle, viz. 40 *males* and 30 *females*, the *anterior belly* has been found *double* in 4 *males*, in two on both sides, and in two on the right side only. In one *male* it was *triple* on both sides. A *clavicular* origin of the *posterior belly* has been found in 2 *males* on the left side only; and in 3 *females*, of which 1 was on both sides, 1 on the right, and 1 on the left side only. The *median tendon* has been found absent in 2 *males*, in 1 on the right, and in the other on the left side only. Thus in 12 out of 70 subjects some irregularity existed in this muscle—a proportion greater than that found by Professor Turner in 373 subjects, viz. 5 or 6 per cent. (Irregularities of the Omohyoid, p. 2). A clavicular origin of the posterior belly was found in 5 subjects out of the 70, or about 7 per cent. Turner found it in 17 out of 373 subjects, *i. e.* rather more than 4 per cent. In 5 out of 70 subjects (also about 7 per cent.) the *anterior belly* was found *double* or *triple*. Turner does not mention this abnormality, but found the anterior belly blended with the *sterno-hyoid* in 4 out of the 373 cases.

4. *Digastric*.—In 3 subjects, 2 *male* (Nos. 13 & 16) and 1 *female* (No. 34), the anterior belly of this muscle was *double*, in the *males* on both sides, and in the *female* on the left side only. In No. 13 the supernumerary head decussated across the median line with its opposite fellow. This variety has been before recorded by Fleischmann (Anat. Wahrnehm. in Erlang. Abhand. Bd. i. S. 26 & 27, Taf. i. fig. i. 1810), and subsequently by Gantzer (Dissert. Anat. Musc. varietatis sistens. 1813), Scemmerring, Theile, and Henle.



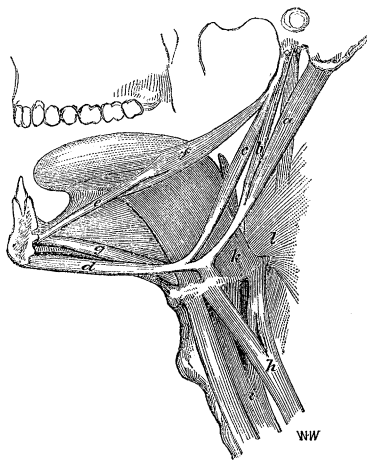
In 102 subjects examined by the author, the anterior belly of this muscle has been found *double* in 5 out of 68 *males*, of which in 2 the supernumerary belly decussated with its fellow across the median line. Out of 34 *females* it was found double once only on the left side.

In the Norway Rat (*Mus decumanus*), the anterior bellies of the digastric are completely blended together, arising without any median fissure from an arched tendinous structure connecting the two median tendons. They are also united in the *Cercopithecus sabæus*, according to Rudolphi (Heusinger's Zeitschrift, Bd. iii. S. 335), and blended so as completely to cover the mylo-hyoids in *Callithrix* and *Papio Mormon* (Cuvier and Laurillard's plates). More or less so they are found in the ruminants.

In the male subject No. 2, a combination of curious varieties led to the sketch of the adjoining figure (fig. 2), taken by the author from the dissected parts.

The posterior belly of the digastric (*a*) appeared at first sight to be a triple muscle. The two anterior muscular slips (*b* & *c*), which were implanted upon the median tendon, one behind the hyoid pulley with the true posterior belly, and the other in front of it and nearer to the anterior belly (*d*), were found on closer examination to arise from the *styloid* process, the hinder one (*b*) from the usual site of origin of the *stylohyoid* muscle, and the front one (*c*) from the tip of the process with the *stylo-glossus*. Each of these, therefore, represents the two halves of a completely split or divided *stylohyoid*, which, instead of uniting to

Fig. 2 (Subject No. 2).



be inserted into the side of the hyoid bone, are implanted separately upon the tendon of the digastric. Coexistent with this were two other abnormalities which may most conveniently be described here. One was a curious well-developed muscular slip, found only on the left side, arising as a muscle one-sixth of an inch wide (*e*), from the lower genial tubercle of the mandible outside the genio-hyoid muscle (*g*). Thence passing upward and backward over the genio-hyo-glossus and hyo-glossus muscles, it finally united its fibres with those of the *stylo-glossus* (*f*) at their insertion into the outer and back part of the tongue. This muscle, which the author has never before met with nor found recorded, is totally different from the *mylo-glossus* described in his last paper. It also differs from that mentioned under this name by Böhmer (Obs. Anat. rar. præfat. viii. note 5), as seen by Vesalius, Riolanus, and Spigelius, and considered

by Verheyneus, Haller, Douglass, and others to be that part of the *superior constrictor* which is attached to the side of the tongue, and which was at first called by Winslow the "*mylo-glossus*" (Comp. Myograph. Spec. p. 93). For the sake of distinction the author has given the name of *genio-glossus* to this remarkable slip.

On the same side of the subject was the bifurcation of the anterior belly of the omohyoid before mentioned (*h*), and also of the *sterno-thyroid* (*i*). A considerable portion of the posterior fibres of each of these muscles was split off; and the two slips, uniting together, were partly inserted into the tip of the greater horn of the hyoid bone, but chiefly blended with the fibres of the *hyo-glossus* (*k*) and *middle constrictor* (*l*) muscles.

5. *Trapezius*.—In 2 males the fibres of this muscle reached only so far down the back as the eighth and ninth dorsal spines respectively. (This deficiency has been found by the author in 4 males out of 70 subjects, viz. 40 males and 30 females.) In one (No. 11) the cervical and dorsal portions were completely separate and distinct muscles, one connected with the occipital bone and *ligamentum nuchæ*, and the other with the dorsal spinous processes,—the two joining only at their insertion into the acromion process. Something like this is the normal condition in the Mole, *Ornithorhynchus*, and Echidna, and to a less marked extent in the Agouti, according to Meckel (Anat. Comp.) and Mivart and Murie (Proceedings of the Zoological Society, June 26, 1866). It has been recorded in the human subject by Sæmmering (De Corp. Hum. Fabrica, t. iii. 1796), Fleischmann, Zagorsky, and Theile. Macalister has also found it ("Notes on Anomalies in Human Anatomy," in Proc. Royal Irish Academy, April 23rd, 1866, p. 21).

In the female (No. 31) the cervical border of the trapezius was attached to the clavicle as far inwards as the origin of the sterno-cleido-mastoid, and so covering the posterior triangle entirely. A foramen or tendinous arch, placed about the middle of the clavicle, allowed the passage of the supraclavicular nerves. This very peculiar formation has been described by Macwhinnie (London Med. Gazette, No. 948, January 30th, 1846, p. 194), and more recently figured by Gruber, of St. Petersburg (Vier Abhandlung, 1847, S. 16, 17), by Hallett (Edin. Med. and Surg. Journal, 1848, No. 174), and by Macalister. The author believes it to be a blending or fusion of the *cleido-occipital* or *cephalo-humeral* with the cervical border of the *trapezius*, of the same kind as the more common blending of the same muscle with the hinder border of the *sterno-cleido-mastoid*.

This view is further supported by the arrangement found in another female (No. 35), on the right side of whom the trapezius detached from the upper part of its cervical border a considerable muscular slip to be inserted into the clavicle, close to the cleido-mastoid. Through a tendinous arch or opening left between this slip and the lower part of the normal clavicular fibres of the trapezius the hinder belly of the omohyoid passed, along with the supraclavicular nerves, as before alluded to with

the abnormalities of that muscle. On this side of the subject no proper cleido-occipital was found; but on the other (left) side, this muscle was large, well formed, and separate, both from the trapezius and sterno-cleido-mastoid.

6. *Levator anguli scapulæ*.—The variations of this muscle have been this year recorded with a view to throw light upon the occasional occurrence in the human subject of the *levator claviculæ* described by the author in former papers.

In 2 males (Nos. 2 & 6) and 2 females (Nos. 20 & 29) this muscle was much divided, forming a distinctly double muscle, one from the two upper, and the other from the third and fourth cervical transverse processes. Such an arrangement is figured by Cuvier and Laurillard in their plate 7 of the *Anatomy of a Negro*. The upper one is there marked as the representative in Man of the "*omo-trachélien*" (*levator claviculæ*) of animals.

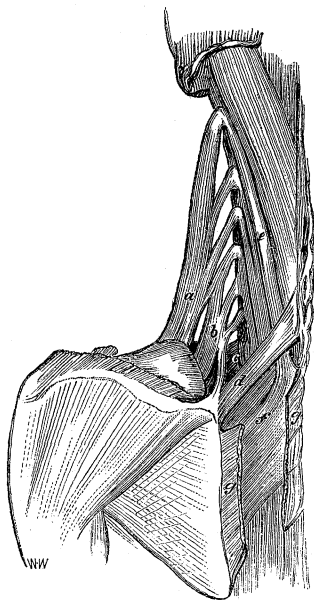
A more perfect homologue of this muscle in the human subject, however, has been recorded by Macwhinnie (*op. cit.* p. 194), and by the author in his former papers—arising from the transverse process of the atlas, and, in some, as low down as that of the third cervical vertebra, and inserted into the middle or outer third of the clavicle.

Such a muscle has been noted and described by the author in 5 male subjects out of 174 of both sexes in whom it has been carefully looked for. Macalister has also found it in a spare female (*op. cit.*). In No. 5 of the subjects noted in column 8 of the Table of the present year, a considerable and long muscular slip, arising by a tendon from the transverse process of the third cervical vertebra, was found lying superficial to the fibres of the *levator anguli scapulæ*, and inserted into the fascia placed immediately behind the clavicle and covering the axillary surface of the first digitation of the *serratus magnus* muscle. A muscle similar to this was found by Dr. Murie in the Bushwoman (*op. cit.*), and was rightly looked upon by him as an imperfect *levator claviculæ*, the insertion of which had only just failed to reach the clavicle. Kelch records that he saw, in a female subject, a triple division of the *levator anguli scapulæ*, the middle part sending off a slip to the scapulo-thoracic fascia (*Beiträge zur pathologischen Anatomie*, 1813, xxv. S. 33). Rosenmüller found a slip from the first cervical transverse process, inserted into the first digitation of the *serratus magnus* (*De nonnullis Musc. &c. Leipzig*, 1814, S. 5). These were, no doubt, specimens of the last-mentioned variety. In the male subject (No. 6) the *levator anguli scapulæ* was divided into six slips along its whole length, arising from the five upper cervical transverse processes, and all inserted into the usual place.

On the left side of a female (No. 20), the subject of fig. 3, a less extensive division of its fibres was found, combined with a double insertion, and a significant fusion of the lower portion with the *serratus magnus* and the *rhomboideus minor*. This arrangement supports and illustrates the homology first pointed out by Meckel (*Archiv*, viii. S. 585, and *Muskellehre*, Bd. ii. S.

402) between the levator anguli scapulæ of the human subject and the upper or cervical part of the serratus magnus as found in the lower animals—an homology which was disputed by no less an authority than Cuvier. The muscle arose by five digitations from the hinder tubercles of the five upper cervical transverse processes, and by a sixth from the fibres and fascia of the transversus colli muscle. Those from the three upper and part of the fourth digitations (*a*) are inserted into the usual place at the superior angle of the scapula. The two and a half lower digitations are inserted as a separate muscle (*b*) into the vertebral border of the scapula as low down as the spine, and are intimately connected by their deeper surface with the fibres of insertion of the *serratus magnus*. A muscular slip from its lower border is attached at its origin to the transversalis colli, and through it to the upper cervical transverse processes; at its insertion it is blended with that of the *rhomboideus minor* (*d*). The lower portion of the muscle may be considered as

Fig. 3 (Subject No. 20).



representing the first and second stages of that differentiation and transfer of insertion of some of the fibres of the levator anguli to the spine of the scapula which, in the *omo-trachélien* or *omo-atlanticus* of animals, attains to the acromion process, and in the *levator claviculæ* of the *Quadrupana* and Man reaches, on the same line of departure, to the clavicle. Macwhinnie records a slip of the levator anguli inserted into the spine of the scapula (*op. cit.* p. 194), a little further advance in the same direction, in the human subject.

In two other male subjects (Nos. 9 & 10), also, the levator anguli scapulæ was connected by muscular slips with the hinder surface and upper fibres of the serratus magnus. In No. 10 it also received a slip from the *scalenus medius*, and in the female (No. 29) from the *scalenus posticus* of one side, and the *serratus posticus superior* on the other. In No. 34 it gave an interdigitating slip to the *splenius capitis* high up in the neck.

7. *Rhombo-atloid*.—In 3 male and 2 female subjects was found a distinct muscle arising with the fibres of the *splenius colli* from the transverse process of the atlas, usually about half an inch wide, and forming a muscular band which was placed superficial to the serratus posticus superior, and behind the rhomboideus minor, and inserted either into the upper fibres of the tendon of origin of the *rhomboideus major* or into the verte-

bral aponeurosis of the *serratus posticus superior*. In 1 male and the 2 females it was present on the left side only. One of them was subject 20 (given in fig. 3), where the abnormal muscle (*e*) is seen to pass under the rhomboideus minor (*d*), to be inserted into the serratus tendon (*f*) under the rhomboideus major (*g*), which is divided in order to show it. In subjects 2, 3, and 23 its insertion was entirely into the serratus aponeurosis. In Nos. 7 & 20 it was also connected with the spine of the seventh cervical vertebra. It has been described by Mr. Macalister as the *rhombatloid* (*op. cit.* p. 3, pl. 5. fig. 1, *a*). In Haller's 'Disputationum Anatomicarum Selectiorum,' vol. vi. (1733) p. 589, this muscle is described by F. Walther under the name of the "*Musculus singularis splenii accessorius*," or "*Adjutor splenii*."

8. *Sundries*.—In subject 3 the *sterno-thyroid* was double—the abnormal part arising from the first rib-cartilage and costo-clavicular ligament, and joining the normal origin halfway up the neck. This abnormal slip bore much resemblance at its origin to the *costo-fascialis* described by the author in his former papers, differing only in its upper termination in the fibres of the sterno-thyroid, instead of the cervical fascia. The origin of the sterno-hyoid was placed between the two heads. In No. 4 was a muscular slip arising tendinous with the *anterior scalenus*, and inserted fleshy with the *medius*. In the male (No. 7) and the female (No. 33) well-marked specimens of the "*musculus glandulæ thyroideæ*" of Sæmmerring were found. The microscope proved satisfactorily that the structure of the formation was really muscular, and not median processes of the thyroid gland, as sometimes is the case. The slips appeared to be offsets from the inner fibres of the *thyro-hyoid* muscle, which had become attached to the gland-capsule. In the female (No. 26) the *thyro-hyoid* was divided into two distinct muscles, the inner one being the smaller, showing a tendency to the formation of the levator thyroideæ. In No. 9 the right *sterno-thyroid* was joined by a clavicular slip, round which the tendon of the omohyoid, as before described, played as through a pulley; on the other side the same muscle received a slip from the *sterno-hyoid*. The two sterno-thyroids also decussated across the median line by a considerable portion of their inner fibres. This arrangement is found in the Squirrel and some other Rodents. In No. 8 was a *cephalo-pharyngeus* muscle having the somewhat unusual origin from the spine of the sphenoid and sphenomaxillary ligament. At its insertion it blended with the lower fibres of the middle constrictor.

In the male (No. 11) and the female (No. 19) were found examples of the *sternalis brutorum* muscle. In both it was present on the right side only, and well developed. In the male it arose tendinous from the tendon of the sterno-mastoid, from the manubrium sterni  $1\frac{1}{4}$  inch below its upper border, and from the fascia covering the pectoralis major muscle 2 inches below the clavicle. Its whole length was  $3\frac{1}{2}$  inches, and it ended below in a fleshy radiating way upon the fascia covering the sheath of the rectus and external oblique. In the female it arose tendinous from the manu-

brium sterni opposite the second rib, and had no connexion with the sternomastoid. It formed a slender muscular belly,  $4\frac{1}{4}$  inches long by  $\frac{3}{8}$  of an inch wide, and ended upon the sheath of the rectus opposite the sixth rib-cartilage.

This muscle has been found by the author in 7 out of 175 subjects, in which it has been carefully looked for. This is 4 per cent. Five of the instances were in males, and 2 in females. In the males it was found, in 1 on both sides, in 3 on the right side, and in 1 on the left side only. In the females it was found in both instances on the right side only.

Professor Turner fixes the frequency of its occurrence, from observations upon 650 subjects, at about 3 per cent. He found it 9 times on both sides, 5 times on the right, and twice on the left side only; while in 5 more it was single, and crossed the median line (Journ. of Anat. and Phys. No. 2. May 1867, pp. 247, 248). Professor W. Gruber found it in 5 out of 95 subjects, in 3 on both sides, once on the right, and once on the left side only (Mem. de l'Acad. Imp. de St. Pétersbourg, L. iii. 1860).

Thirty-two columns of the Table are occupied by the remaining muscles of the *Arm*. This is six more than those of last year; the additional *lines of variation* being made up by the sterno-scapular, anconeus epitrochlearis, extensor carpi intermedius, ext. pollicis et indicis, and ext. medii digiti (which have been found so frequently as to require separation from the muscles with which they are most closely connected), and the pronator radii teres.

9. *Pectoralis major*.—In the male (No. 2) and the female (No. 25) a detached outlying slip was found on both sides at the lower border of this muscle, arising from the *epigastric aponeurosis* covering the rectus muscle, and inserted, separately from the rest of the pectoralis muscular fibres, upon the deep surface of the upper fibres of the tendon of insertion. In the male the slip was small on one side, and arose opposite to the sixth rib-cartilage; but on the other side large, and reaching as low as the seventh rib. The author looks upon the above abnormality as the homologue of the "*portion ventrale*" of Cuvier and Laurillard's plates, constituting, in most Mammalia, a large and separate portion of the pectoral group of muscles. It is also homologous with the "*costo-humeral*" of Professor Huxley, and the *chondro-epitrochlear* of Duvernoy. Meckel describes it as remarkably distinct in the Bats, drawing the wings powerfully down and inwards (Anat. Comp. vol. vi. p. 206). Zenker describes it as the "*brachio-abdominal*" muscle in the Batrachian reptiles, in whom it is frequently continuous with the rectus abdominis (Batrachomyologia. Jenæ, 1826, p. 39).

In the male (No. 13) was developed, on the left side only, a very large and well-marked example of the muscle described by the author as the "*chondro-coracoid*." It is placed in the Table among the sundries. It consisted of a separate muscle arising by two digitations, the upper from the sixth rib, and the lower from the epigastric aponeurosis covering the

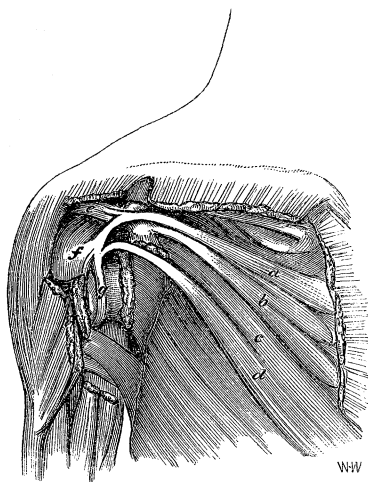
rectus, and formed a muscle 2 inches wide, while passing upwards and outwards across the axillary space, below and quite distinct from the pectorals, to be inserted by a broad tendinous expansion into the *fascia* covering the origin of the *coraco-brachialis* muscle as high up as the coracoid process. The pectoralis minor muscle was also very large and divided, and altogether the arrangement of these muscles resembled much that found in the *Felidæ* and Rodents. The *chondro-coracoid* portion forms, in the Norway Rat and Rabbit, a separate element distinct from the other pectorals. It seems to be an upward transition of the insertion of the epigastric slip above described, with which it coincides closely at its origin. In animals it is considered by some writers a part of the *panniculus carnosus*.

In 4 male subjects the clavicular fibres of the *pectoralis major* were fused with those of the *deltoid*, leaving only a small opening below for the cephalic vein. This arrangement has been recorded by Otto as an absence of the clavicular fibres of the deltoid, and by Seiler as an origin of the deltoid from the whole of the clavicle (Observ. Anat. 1808, fasc. i.). It indicates that kind of blending of the clavicular elevators of the upper arm which reaches its highest form in the lower portion of the cephalo-humeral muscle of the Carnivora and Rodents.

In the female (No. 20) the clavicular fibres of the pectoralis were split into two distinct muscles, one occupying the sternal, and the other the middle third of the bone. They were united at their insertion only.

10. *Pectoralis minor*.—In no less than 8 subjects, 4 male and 4 female, in 7 on both sides, and in 1 (male) on the left side only, a portion of the tendon of this muscle, usually the upper part, was prolonged over a pulley-like groove upon the *coracoid* process, and pierced the coraco-acromial ligament to be connected with the tendon of the supraspinatus muscle, and implanted with it into the capsular ligament of the shoulder-joint. In 2 of the males (Nos. 10 & 12) the tendon was also connected with the upper fibres of the *glenoid* ligament at its point of union with the capsular. In No. 10 the pectoralis minor was arranged in the complex manner shown in fig. 4. The fibres of the upper digitation (*a*), arising from the second rib and intercostal fascia, were joined to a roundish

Fig. 4 (Subject No. 10).



tendon which passed over the coracoid groove, gave off a slip to the coraco-acromial ligament (*e*) as it perforated it, and was implanted partly into the capsular ligament (*f*), and partly perforated it to join the fibres of the glenoid (*g*). The middle fibres (*b*), arising from the third and fourth ribs and fascia, were attached by a shorter tendon to the inner margin of the coracoid, and connected by aponeurosis to the origin of the coracoid muscles. The lower fibres (*c* & *d*), arising from the fifth rib and the adjacent intercostal and epigastric aponeuroses below the border of the pectoralis major muscle (with which they were partly blended), divided soon into two parts, of which the upper (*c*) was inserted into the fascia of the coracoid muscles (cut off short in the woodcut); while the lower (*d*) were united in a tendon which passed over these muscles, pierced the capsular ligament above the subscapularis (divided in the cut), and finally joined with the uppermost tendon to be inserted into the upper part of the glenoid ligament. A bursal opening existed at this point between the joint and the subscapular bursa. In the adjoining figure the pectoralis major, part of the deltoid, the coracoid muscles, and the subscapularis are partly removed, and the shoulder-joint opened to show the glenoid ligament.

In this curious instance the lower part of the muscular arrangement is evidently a "*chondro-coracoid*" muscle joined up to the pectoralis minor at two separate points, viz. at its origin and insertion. At its origin it coincides with the usual origin of this muscle, reaching down nearly as far as the latissimus dorsi; while at its insertion it is fused with the glenoid tendon of the pectoralis minor. Its course over the origins of the coracoid muscles quite coincides with a frequent insertion of the "*chondro-coracoid*." It resembles considerably the intermediate pectoral of the lower animals.

This remarkable insertion into the glenoid ligament goes far to corroborate the views expressed by Macalister (Journal of Anat. and Phys. No. 2. May 1867, p. 317) upon the homology of his *coraco-glenoid* ligament with the humeral tendon of the pectoralis minor.

In another male subject (No. 13) the upper fibres of the lesser pectoral passed over the coracoid process to be inserted into the *coraco-acromial ligament*. In a female (No. 32) the upper fibres of the muscle on the right side were inserted by a flat aponeurotic tendon, half an inch wide, into the lower border of the *clavicle*, forming almost a separate *sterno-clavicular* muscle.

11. *Sterno-scapular*.—In 5 males (on both sides) and in 5 females (of which 2 were on both sides, 2 on the right, and 1 on the left only) it was found that a portion of the lower fibres of the *subclavius* muscle were implanted upon the tubercle of the *coracoid* process, and were usually separated by a distinct interval from the rest of the muscle, constituting a decided formation in most of the specimens of a *sterno-scapular* muscle, first distinguished and figured by the author in his paper of 1865 (fig. 4), and compared with the muscle of that name in animals.

In the subject there figured a muscle was found, coexisting with the sterno-



scapular (marked *b* in the above-mentioned figure), which has again been met with in the male subject (No. 4) of this year's series. On the left shoulder was found a distinct band of muscular fibres, nearly an inch in width, arising just outside of, and in connexion with, the *omohyoid*, from the base of the coracoid process, and inserted into the clavicle with the outermost fibres of the *subclavius* muscle. It has been named by the author the *Scapulo-clavicular* muscle, as it seems clearly to be the homologue of the muscle described and figured by Cuvier and Laurillard, under the name of the "*scapulo-clavien*," in the Rat-mole of the Cape, and the *Didelphys marsupialis* or Sarigue (plates 216 & 195). The author has found the muscle also well marked, separate, and distinct in the Norway Rat (*Mus decumanus*), as well as in the Guineapig, and in a less distinct form in the Rabbit. The muscle is noted in the Table, in column 40, among the single specimens.

12. *Latissimus dorsi*.—In the male (No. 9) was a detached slip from the ninth intercostal fascia of the right side, which joined this muscle high up near its insertion. In the female (No. 29) was a musculo-tendinous slip, passing from the left latissimus across the axillary vessels, and inserted into the fascia covering the *biceps* muscle. It seemed to be a formation between the ordinary "*Achselbogen*" and a *dorso-epitrochlear* muscle. A similar slip, reaching only to the fascia covering the coraco-brachialis, was present on both sides in No. 32.

Out of 102 subjects, viz. 68 males and 34 females, a *dorso-epitrochlear* slip of muscular fibres has been found by the author in 5; 3 of which were males, and 2 females. In 2 of the males the slip was lost on or joined the scapular head of the *triceps* muscle. In the third male it was lost on the fascia covering the *coraco-brachialis*. All these were found in both arms. Of the 2 females, one was found on both sides, and ended on the fascia covering the *coraco-brachialis*, and the other on the left side only, and ended in the fascia covering the short head of the *biceps*. In 6 of the 102 subjects the latissimus gave off a considerable slip to the insertion of the *pectoralis major* (*Achselbogen*); 3 were in males, 2 on both sides, and 1 on the left side only; and 3 in females, 2 on both sides, and 1 on the left only. In 3 subjects the upper costal fibres of the latissimus were connected with a broad muscular slip arising with them, which, after crossing the axilla upwards and outwards, were inserted with the *pectoralis minor* into the coracoid process, or into the fascia of the coracoid muscles just below it (*chondro-coracoid*). Two of these were in males, one on the right side only (a similar slip on the left side joined the *pectoralis major*), and the other on the left only. The third was found in a female subject on the left side only.

13. *Coraco-brachialis*.—In 2 males (Nos. 1 & 10) and 3 females (Nos. 21, 23, & 24) this muscle presented an entirely double formation. The upper slip was inserted into the usual place; the lower passed down further, to be connected with the internal brachial ligament or intermus-

cular septum as far down as the ridge of the internal condyle. The musculo-cutaneous nerve usually passed between the two. The lower slip has been described by the author as a separate element, the *coraco-brachialis longus* (Journal of Anat. and Phys. No. 1. p. 49). This form of coraco-brachialis is found in the Ornithorhynchus, Echidna, and some Rodents. In the female (No. 30) this long muscle existed in the form of a distinct bundle given off from the middle of the coraco-brachialis, and ending in a long tendon which was implanted fairly upon the inner condyle, and which seemed to originate in a differentiation of the internal brachial ligament. In the female (No. 23) was found a good specimen of the muscle named by the author in the same paper the "*coraco-brachialis brevis*," or "*rotator humeri*." It arose separately from the under surface of the coracoid process near its base, and was inserted into the neck of the humerus, just below the lesser tuberosity and above the latissimus dorsi. It is found usually in the Quadrumana, coexistent with the longer form, and in the Rodents and Carnivora singly.

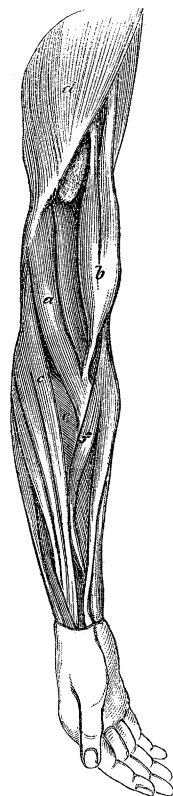
In the male (No. 9) a large coraco-brachialis gave off a considerable bundle of muscular fibres, which joined bodily those of the *brachialis anticus*. This has been before found by the author, and also by Macwhinnie (*op. cit.*) and Hyrtl (Lehrbuch, S. 863). It is significant as the homologue of the *semimembranosus* in the lower extremity, supplying the homologous origin from the coracoid (ischium) as the brachialis supplies the homologous insertion.

14. *Biceps brachii*.—In 2 males and 6 females, out of the 36 dissected this session and given in the Table, this muscle was provided with a *third* or *humeral* head. In the left arm of No. 14 a slip of muscular fibres was given off from the lower third of the *coraco-brachialis*, and joined the short head about its middle. This seems to be merely a doubled or divided short head, of which the lower portion separates from the coraco-brachialis, lower down than usual, as we frequently find in the Quadrumana. In both arms of No. 17 the muscular slip, half an inch wide, was given off from the humerus just at the insertion of the coraco-brachialis. In the 6 other instances the third head arose, in the most usual place, with the upper fibres of the *brachialis anticus*, and joined the tendon at the same point as the two normal heads. In 1 (No. 24) it was found on both sides, in 4 on the left side only, and in 1 on the right side only.

Out of 175 subjects examined by the author, a *third* or humeral head of the *biceps* was found in 14, viz. in 7 males and 7 females. In 4 others, viz. 3 males and 1 female, it was found coexistent with a *fourth* head, also arising from the humerus. In 3 of these the fourth head arose from one of the tuberosities or the borders of the bicipital groove; and in the fourth, from the outside of the humerus, between the insertion of the deltoid and the origin of the supinator longus. This gives a proportion of about 1 in 9 out of the 175 subjects, agreeing nearly with the computation of Theile, viz. 1 in 8 or 9, and not with that of Hallett, viz. 1 in 15.

In the right arm of the male (No. 10) (noted in column 15 in the Table) was found a *brachio-radialis* as a detached muscle (fig. 5, *a*) of considerable size, arising separately from the upper part of the outer condyloid ridge of the humerus and intermuscular septum, just below the deltoid (*d*) and above the supinator longus (*c*). Passing as a flat muscular band downwards, forwards, and inwards, outside the biceps (*b*), it was inserted by a flat aponeurotic tendon into the *oblique line* of the radius, close below the bicipital tuberosity, and between the insertions of the supinator brevis (*e*) and pronator radii teres (*f*). Although quite detached from other muscles, and inserted into the radius below the biceps, the homological relation of this muscle, in the situation of its origin from the humerus, to the fourth head of the biceps just alluded to (recorded in the author's paper of 1864), is clearly apparent; and it holds the same relation to that *external* humeral head of the biceps as the detached *brachio-fascialis*, described in the author's papers of 1864, 1865, and 1866, does to the *internal* humeral head of the same muscle. Meckel, quoting Pietsch (Journal de Roux, t. xxxi. p. 245), mentions an instance in which *three* humeral slips, one from the outside of the humerus (homologous with the foregoing abnormality), one from the inner side (homologous with the more common third head), and one from the short or coracoid head of the biceps, joined together to form one muscle, which was inserted into the radius by a separate tendon, behind the normal one, upon the bicipital tuberosity (Muskellehre, S. 504). He also quotes Rudolphi (in Blumenbach's Med. Bibl. Bd. i. S. 176) and Sels (Diss. Anat. Musc. Variet. sistens, 1815, p. 12) for an instance in which a muscular bundle of the size of a finger passed from the outer head of the biceps to be inserted separately into the radius. The more perfectly detached form of this abnormality is also alluded to by Theile (in Scemmering's Encyclop. Anatomique, Jourdan's Trans. 1843, p. 217), by R. Wagner (in Heusinger's Zeitschrift, Heft iii. Bd. iii. S. 345), and by Hyrtl (Lehrbuch). A case very similar to the present has been described by W. Gruber (in Müller's Archiv, 1848, S. 428) as a variety of the *brachialis anticus*, in the right arm of a very muscular male, in whose left arm was found the more common form of the third head of the biceps. It arose from the humerus, close to the outer condyloid ridge, as a thick muscle, and was inserted by a separate tendon into the radial tuberosity just below the biceps, giving off a slip of tendon to the aponeurosis of the forearm.

Fig. 5  
(Subject No. 10).



15. *Brachialis anticus*.—In both arms of the male (No. 6) some of the fibres of this muscle were directly continuous with those of the *supinator longus*, an ape-like arrangement before noticed by the author in his paper of 1866. He has found it in 6 males on both sides out of 102 subjects. It is recorded also by Macalister (*op. cit.* p. 19). Slips from this muscle to the outer part of the fascia of the forearm have been mentioned by Sæmmerring, Theile, Macwhinnie, and Hyrtl. In the female (No. 22) the *brachialis anticus* was divided into two muscles, an outer and an inner, both inserted into the coronoid process. This has been observed by the older anatomists. It resembles the arrangement in the Rabbit and Agouti.

16. *Anconeus epitrochlearis*.—In his paper read before the Royal Society in June 1866, the author mentioned and tabulated a detached muscular slip in the right elbow of a male subject, arising separately from the back part of the inner condyle of the humerus, and passing across and superficial to the ulnar nerve, and distinct both from the triceps and flexor carpi ulnaris muscles, to be inserted into the inner side of the *olecranon* process of the *ulna*. This muscle he again described and figured in his paper of last year, comparing it with a like muscle he had found in the Rabbit. During the last session this muscle has been found in 4 male subjects out of the 36—in 3 in both arms, and in 1 in the left arm only. The author has also found the muscle in his dissections of the Orang, Bonnet-Monkey, Mole, Hedgehog common Weasel, Cat, Norway Rat, Squirrel, and Ornithorhynchus. In the Mole it is particularly large and well developed, as are all the muscles of the upper arm. It is also well marked in the Norway Rat and Rabbit. In the subjects of the Table of the present year it has been very carefully looked for, with a view to determine the frequency of its occurrence, and to compare the results with those stated by Professor Gruber of St. Petersburg, in a paper published in the 'Mémoires de l'Acad. des Sciences de St. Pétersbourg,' in June 1866. This eminent observer states that he has found this muscle (*epitrochleo-anconeus*) as frequently as in 34 per cent. of subjects—in 26 out of 79 males, and in 8 out of 21 females. In 14 it was on both sides, in 12 in the right, and in 3 in the left arm only. It seems, therefore, to be more commonly found in the Slavonic than in the Anglo-Saxon races. Professor Gruber figures and minutely describes this muscle, both in the human subject and in many animals—in *Inuus nemestrinus*, *Cebus fatuellus*, *Galeopithecus*, *Myogale*, *Dasyurus viverrinus*, Arctic Bear, Lion, Cat, Hare, 3-banded Armadillo, Seal, and many others. It seems to correspond with the muscle described in the Hyrax by Mivart and Murie as a fourth head of the *triceps*, and in the Rabbit by Krause as the *anconeus quartus*. It is figured, but not distinguished from the other anconeal muscles, in Cuvier and Laurillard's plates of the Panther, Genet, Beaver, Marmot, Rat-mole, Great Anteater, Elephant, and many other animals of various genera.

17. *Pronator radii teres*.—In 2 males and 2 females this muscle was

doubled or split along nearly its whole length into a *condyloid* and *coronoid* muscle, the latter being inserted higher than, and external to, the former part. In No. 1 the coronoid origin was a rounded tendon. In the female (No. 35) the two parts were distinct throughout, and connected only by a small slip at their insertion. In No. 31 the condyloid origin of the pronator was the only one present. The occasional occurrence of a double pronator has been noticed by Albinus, Scæmmerring, Theile, and Meckel. Mr. Macalister has lately called attention to this formation as an evidence of a second or accessory embryonic germ, represented by the coronoid origin, and homologous with the tibial head of the soleus (*Journal of Anat. and Phys.* Nov. 1867). The coronoid origin is not found in the lower Mammalia, and is present only in the higher Quadrumana. It was found by the author large and well marked in the Orang, arising by a strong, broad tendon, common to it, the flexor carpi radialis, and the flexor sublimis digitorum, and giving off a slip to the separate flexor indicis, and with the median nerve passing between it and the condyloid origin. In the same animal there was no tibial origin whatever to the soleus. The coronoid head of the pronator was not found by the author in the Bonnet-Monkey. Dr. Humphry found it in the Chimpanzee disposed as in the human subject.

18. *Flexor sublimis digitorum*.—In the left arm of a male (No. 4) was an unusual fusiform muscular slip from the coronoid origin of this muscle, ending in a long tendon which, passing under the annular ligament to the palm, gave origin to the outer half of a bipenniform *first lumbricalis* muscle. The inner head of the lumbrical arose from its usual place. This abnormality was described in the arm of a negro in the author's paper of 1865, the long tendon arising in that instance from the deep fibres of the sublimis, along with a coronoid "*accessorius ad flex. long. pollicis*," and was joined in the lower part of the forearm by a muscular slip from the radius. In No. 7 the tendon to the middle digit was double. In Nos. 11 and 17, males, and in 20, 30, 32, 34, and 36, females (7 in all), the origin of the flexor sublimis from the coronoid process was twofold, viz.:—one, fleshy, from the upper part of the inner border of the process, and continuous with the fibres of the condyloid and ligamentous origins; and a second, flat, tendinous, and riband-shaped, from the lower angle of the coronoid process—the latter joining the fibres of the radial origin before these united with the rest. In all but 2 this arrangement was on both sides.

In 2 females (Nos. 19 and 22) the sublimis tendon to the little finger was absent. In the latter the perforated tendon was supplied by the fourth *lumbricalis* muscle. This arrangement forms a contrasted instance to that just mentioned, in which the first lumbricalis took origin from a tendon supplied by the sublimis. In the left arm of the female (No. 20) a musculo-tendinous slip was given off from the *sublimis* to the palmar fascia, in aid of a very feeble *palmaris longus*. Such a slip has been found by Macalister in *Cebus capucinus*. Rosenmüller has also described it in the human sub-

ject (*op. cit.* S. 6). In the opposite arm both the palmaris longus and the substitutory slip from the sublimis were wanting. In the female (No. 23) a separate digastric muscular belly was provided for the perforatus tendon of the index, while the rest of the muscle was much divided. In No. 31 a like digastric muscle gave off the perforatus tendons to both the index and little fingers. This was exactly like the instance described in the author's last paper. It has been recorded also by Meckel, and lately by Macalister. It is occasionally found in the Quadrumana.

19. *Flexor profundus digitorum*.—In no less than 4 males and 6 females out of the 36 subjects of the present year, and in 19 subjects out of a total of 102, was found the rounded, tapering, muscular slip arising with the condylo-coronoid origin of the sublimis, and joining, either by fleshy fibres or by a long tendon, some part of the *flexor profundus* or its tendons. It was observed by Gantzer, and named by him the "*accessorius ad flexorem profundum digitorum*." In two males (Nos. 2 and 9) it joined that part of the profundus which supplied the *index* finger. In No. 9 it came off from the coronoid in common with a like slip to the flexor longus pollicis. In seven subjects it joined the second tendon of the profundus, viz. that to the *middle* digit; and in one female (No. 31) it was large, and ended in a long and good-sized tendon, dividing at the wrist into separate tendinous slips to the *three* inner digits, presenting almost the appearance of an intermediate common flexor, homologous with that which constitutes the chief bulk of the combined flexor muscles in the Carnivora and other Mammalia. It was similar in many respects to the arrangement in the Negro before alluded to. The author has found the slip of connexion between the coronoid fibres of the *sublimis* and the *profundus* in the arm of the Orang-outang. It is slender, and joins that part of the profundus which becomes differentiated into a *flexor indicis* in this animal, as well as in the Gorilla and Chimpanzee. The author has also found the same slip in the *Macacus radiatus*, arising musculo-tendinous with the sublimis, and uniting just above the wrist with the combined tendons of the flexor profundus and longus pollicis, just before the tendinous slip to the thumb is given off. In *Nycticebus tardigradus*, or Slow Loris (in which animal the common flexors are still distinct as in Man and the higher Quadrumana), a slip of tendon from the sublimis unites with the profundus above the carpus, and joins also the flexor pollicis (Mivart and Murie, Proc. Zool. Soc. Feb. 1865, p. 24). Meckel also describes this in the Loris. It is also found in *Cheiromys*, according to Owen, and in *Tarsius*, as described by Burmeister, showing in these animals a more decided tendency to the more complete amalgamation and substitution found in animals lower in the scale. In the Hedgehog the author has noted its presence in a more decided form, and still more largely developed in the Guineapig, Surmulot, and Rabbit, where it assumes more of the size and importance which it possesses in the Carnivora, in whom it constitutes the chief bulk of the combined flexors.

In the left arm of a male (No. 5) a considerable slip, amounting almost to

an equal division of the tendon of the *flexor longus pollicis*, joined bodily with the *indicial* tendon of the *profundus*, just at the point of origin of the first *lumbricalis* muscle, which arose equally from both by a double penniform belly. In the right arm of the same subject, a single penniform muscle, arising from the middle third of the front surface of the radius below the flexor longus pollicis, gave off a tendon which passed under the annular ligament behind that of the flexor longus pollicis, and ended by giving origin to the outer half of a bipenniform *first lumbricalis* muscle; but it did not form any other kind of junction with the indicial tendon of the profundus. The last abnormality has been observed by Theile and Henle. It has an evident relation to that on the left arm of the same subject, although the slip does not quite reach the tendon of the profundus; and it has also a more remote one to the slip before described from the *sublimis* to the bipenniform first lumbricalis—the connexion between the two in the latter being kept up by the blending of a *coronoid accessory* muscle of the *profundus* or *flexor pollicis longus* with the slip to the *lumbricalis*. In one of last year's subjects the tendon to the bipenniform lumbricalis came directly from the belly of the flexor longus pollicis, in place of having a distinct radial muscular belly. In the male (No. 7) the profundus itself gave off a long musculo-tendinous slip to the *second* lumbricalis. In the female (No. 19) that portion of the fibres of the flexor profundus which arises from the interosseous ligament, and gives rise to the indicial tendon, formed a distinct *flexor indicis*, an areolar interval extending along its whole length and separating it from the rest of the fibres of the profundus.

20. *Flexor longus pollicis*.—In 27 out of the 36 subjects, viz. 13 males and 14 females, this muscle received a fleshy, fusiform coronoid origin, the "*musculus accessorius*" of Gantzer. Sometimes it was distinct from the coronoid fibres of the *sublimis*, but was more frequently blended with them. In both arms of the male (No. 5) the accessory muscle received an additional muscular slip from the *condyloid* fibres of the *sublimis*, the fibres of which were continuous with those of the tendon before described as passing to the first lumbricalis muscle. This coronoid or condyloid slip has been found by the author in 40 subjects out of 102, viz. in 22 out of 68 males, and in 18 out of 34 females. It would thus seem to be more common in the latter sex. In 13 of the males and 12 of the females it was present in both arms, in 4 males and 4 females in the right arm only, and in 5 males and 2 females in the left only. The condyloid origin occasionally found forms a still closer homology with the chief or condyloid origin of the combined flexors of the lower animals. In 3 subjects, viz. 1 male (No. 13) in both arms, and 2 females (in No. 28 in the right arm, and in No. 32 in the left only), the flexor longus pollicis tendon subdivided into two, the inner and smaller joining in two of them the indicial tendon of the perforans about the wrist—but in one (No. 28) having a distinct insertion into the outer part of the base of the ungual phalanx of the index finger, lying in

the sheath as a separate tendon. The former of these arrangements has been observed by the older anatomists, Fleischmann, Loschge, Gantzer, and Meckel. Both represent very closely the tendinous connexion usually existing between the long flexors of the toes as a slip from the flexor hallucis to the second, third, and sometimes the fourth tendons of the flexor communis. In his paper of 1866 (p. 235) the author described a variety in which the communicating slip passed in the opposite direction, viz. from the indicial tendon of the profundus to the flexor longus pollicis, an arrangement which is found in the Gorilla, according to Duvernoy, and in the Chimpanzee as described by Professor Wilder (Boston Journ. of Nat. Hist. vii. 364). This resembles an occasional variety in the communicating slip between the homologous tendons in the foot of the human subject.

21. *Lumbricales manûs*.—Besides the abnormal origin of the *first* lumbricalis before alluded to, there were 8 other irregularities affecting these muscles in the 36 subjects. In Nos. 5 and 10, male, and No. 36, female, the *second* lumbricalis was bipenniform in its origin from the contiguous sides of the first and second perforating tendons. In the left arm of Nos. 4 and 18, and in both arms of No. 8, all males, the *third* lumbricalis was bifurcated, with a double insertion into the extensor aponeurosis of the third and fourth digits. This was the case also in the left arm of No. 7, while in the right arm, both the *third* and *fourth* lumbricales were bifurcated and inserted into the contiguous sides of their opposing digits. In the left arm of No. 18 the *fourth* lumbricalis was absent. In the left arm of No. 17 a slip of communication was observed between the origin of the *first palmar interosseus* and the middle of the *first* lumbricalis, which thereby assumed the appearance of a bipenniform muscle, an abnormality which does not appear to have been before recorded. All these subjects but one were males; 4 were found on both sides, 3 on the left only, and 1 on the right only.

Out of 102 subjects, viz. 68 *males* and 34 *females*, examined by the author, some of the *lumbricales* of the hand have been found abnormal in 19. In 4 of these, abnormalities of two kinds occurred, making altogether 23 specimens; 15 were males and 4 only females, giving a proportion of twice as frequent in the male sex. 8 were found on both sides, 8 on the right side only, and 7 on the left only. The *second* was doubled in its insertion once only, in the left hand; and was bipenniform in its origin in two instances. The *third* was bifurcated and double at its insertion in 10 instances, in 6 on both sides, 2 in the right, and 2 in the left hand only. It was bipenniform in its origin in 2 subjects, in both hands. The *fourth* was doubled in 2 instances, 1 in the right and 1 in the left hand. In one female it supplied, in both hands, the perforatus tendon of the fifth digit. Once it was inserted into the ulnar side of the ring-digit instead of the little finger, as has been observed by Moser and Theile; and in three instances it was totally wanting—once on the right and twice on the left side. The last abnormality has been recorded by Sæmmerring and Meckel. The above figures are considerably smaller than those given by Froment (Recherch. sur plusieurs



points d'Anatomie, 1853), who found some of these muscles abnormal in 45 per cent. of subjects. The proportionate frequency of the several muscles affected, however, is much the same. He also found the *third* to be most frequently affected, as had been observed indeed by the older anatomists, Petsche, Walther, and Heister (in Haller's *Disput. Anatom. Select.*), as well as by Meckel and Theile.

22. *Flexor carpi radialis*.—In three males and two females, two of the males on the right side and the rest on the left only, the tendon of this muscle gave a slip of insertion into the trapezium before being implanted upon the base of the second metacarpal bone. This has been recorded by Albinus, Loschge, Fleischmann, Theile, and Hyrtl, and is mentioned by Henle (*Muskellehre*, S. 191).

*Flexor carpi radialis brevis seu profundus*\*.—In the left arm of a female (No. 28) was found a small specimen of the variety of abnormality described by the author under this name. It arose from the oblique line of the radius, under the origin of the flexor sublimis, by a falciform aponeurosis, with a fusiform belly  $1\frac{1}{2}$  inch long, and was inserted by a round tendon into that deep process of the annular ligament which is implanted upon the ridge of the trapezium and trapezoid, enclosing the groove for the tendon of the flexor carpi radialis. In the left arm of No. 32 (also a female) a large specimen of the same muscle existed, arising aponeurotic from the oblique line and outer border of the radius, with a fusiform belly ending in a round tendon which crossed deeply and obliquely across that of the flexor longus pollicis, close upon the wrist-joint, to be inserted in a fan-shaped way into the head of the os magnum, almost but not quite reaching to the base of the middle metacarpal bone. This specimen supplies a connecting link between the fusiform muscle attached to the annular ligament of No. 28 (which it resembled in its shape and origin) and the complete flexor of the middle metacarpal bone described by the author in former papers, which it closely resembles in its insertion. In the same hand the *flexor carpi radialis* gave off a slip to the trapezium. In both arms of No. 28 the *palmaris longus* was wanting; but in No. 32 that muscle was present

\* While this is going through the press, the author has been favoured by Professor W. Gruber, of St. Pétersburg, with the last and several back numbers of the 'Bulletin de l'Acad. Imp. des Sciences de St. Pétersbourg.' In the last he claims priority of discovery and publication in the matter of the above-named muscle, which he figured and described in three male subjects in 1859 (in tom. xvii. no. 28, of that periodical), and which he then named "*M. radio-carpeus*" and "*M. radio-carpometacarpeus*." The author takes the earliest opportunity of acknowledging this priority as regards himself. He was aware of, and has frequently referred to evidences of Professor Gruber's industry in observation, but he did not recognize his exceeding merits as a discoverer till informed of them by the pamphlets above mentioned. In the last, Professor Gruber himself refers to the publication of an instance of the "*M. radio-carpeus*" by M. Fano in the 'Bull. de la Soc. Anat. de Paris,' in November 1851, with which he himself did not become acquainted before 1859!! The grounds upon which he claims priority in face of this are not convincing; but he objects to the name given by the author, and announces that the muscle shall from henceforward be called "*M. radialis internus brevis (s. minor)*!"

and normal in the same arm, and fusiform in the opposite or right arm. In both the sex was female, and the muscle was found in the left arm only. In the 8 instances previously described by the author the sex in 7 was male; and in all, the muscle was found in the right arm only. The latter peculiarity was also present in 2 specimens, of which notes have been kindly forwarded by Mr. Macalister of Dublin, one of which was inserted into the third metacarpal and the other into the annular ligament. In a note sent to the author in March last, the same excellent observer favoured him with a description of a peculiar arrangement of the muscle which he had found in a female in the left arm only. The muscle arose by two heads, viz. the more usual one from the radius between the flexor sublimis and flexor longus pollicis, and the other, flat and aponeurotic, from the internal condyle of the humerus. These joined in a muscular belly 4 inches long, which lay deeper than that of the flexor carpi radialis, and outside of the flexor longus pollicis, and was inserted by three slips of tendon into the deep surface of the annular ligament. The *palmaris longus* was also present, and normal in this case.

23. *Palmaris longus*.—In three males (Nos. 1, 6, & 15) this muscle and its tendon were both double, in the first two in the left arm only. In the last it was found in the right arm only—the supernumerary muscle being almost median and fusiform in shape, and the tendon of insertion reaching only to the annular ligament. In both arms of a male (No. 17) its tendon was split up into several parts, all inserted into the annular ligament closer than usual to the scaphoid. In both arms of No. 16 its belly was fusiform and nearly median, and its tendon of insertion gave off a slip to the origin of the *abductor pollicis*. In the left arm of the females (Nos. 31 & 34) the muscular belly was also fusiform and median in its position. In the latter, the tendon of insertion was double. In four, all females, the *palmaris* was found entirely wanting—in No. 28 on both sides, in Nos. 20 & 31 in the right arm only, and in No. 36 in the left only. In the right hand of the last, the *palmaris brevis* was also absent. No slip of substitution was found in any of these instances. In the right arm of the male (No. 13), and in the left of the female (No. 29), the only representative of this muscle was a feeble rudimentary tendinous slip.

Out of 102 closely observed subjects, viz. 68 males and 34 females, 23 have presented abnormalities of this muscle. In 7 of these they have varied in the two arms, presenting altogether 31 instances; 6 were double muscles, and 3 double tendons; of these, in 7 males and 2 females, 1 was in both arms, 2 in the right, and no less than 6 in the left arm only. It has been altogether absent in 9 instances, and rudimentary in 2, viz. in 4 males and 7 females; of these, 4 were in both arms, 4 in the right, and 3 in the left arm only. The number of absent muscles was thus nearly double in half the total number of females, giving a proportion of 4 to 1 of frequency of absence in this sex. In 5, viz. 3 males and 2 females, the muscular belly was median or inverted, in 2 on both sides, 2 in the right arm,

and 1 in the left only. In 1 male and 1 female only was the *flexor carpi radialis brevis* present when this muscle was *absent* or rudimentary. In the left arm of one female a substitutory slip came from the *flexor sublimis digitorum*. In 3 males, in 2 on both sides, and 1 on the left only, such a slip was derived from the *flexor carpi radialis*.

24. *Extensor carpi radialis longior*.—In 2 males and 1 female, twice in the right, and once in the left arm, this muscle was entirely blended at its origin with its twin muscle the *brevior*. In the male (No. 11) the coalesced muscle gave off two tendons, which had the usual insertions of the *longior* and *brevior*. In No. 2 it gave off three tendons, the middle one being that of the muscle called by the author the *extensor intermedius*, which was inserted with the *brevior*. In the female (No. 32) there arose in the left arm, from the combined muscular belly, no less than *four* tendons, of which the inner, corresponding to that of the *brevior*, was the largest and subdivided into two (making *five* in all), the superficial one of which was inserted into the bases of the second and third metacarpals, and the deeper into that of the third only. The outermost tendon, representing the *longior*, was inserted into the base of the second metacarpal; while the two *intermediate* tendons united at the lower end of the radius, to be inserted together, on the inner side of the *longior*, into the base of the *index*-metacarpal. This *coalescence* of the fleshy bellies of the *longior* and *brevior* has been alluded to as an absence of the *extensor brevis*, with the *longior* supplying two tendons, by Meckel (Muskellehre, S. 509), quoting Albinus (Hist. Musc. p. 446), and Salzmann, and also by Macwhinnie and Henle. Theile mentions it as a union of the *longior* and *brevior* (*op. cit.* p. 226). Meckel remarks upon its resemblance to the arrangement in the lower animals, and after him Macwhinnie and Henle. The construction in the female (No. 32) somewhat resembles the formation in the Ruminants; that in the male (No. 2) finds its counterpart in the Hyæna and Brown Bear. In the right arm of No. 7, and the left of No. 12, the tendon of the *longior* was split into two, both having the normal insertion.

In the female (No. 21) the *longior* gave off a large muscular slip to join the *supinator longus* high up. This resembles the doubleheaded supinator longus found by Mivart in the *Iguana tuberculata*, the second head of which arose with the *extensor carpi radialis* (Proc. Zool. Soc. June 1867, p. 783).

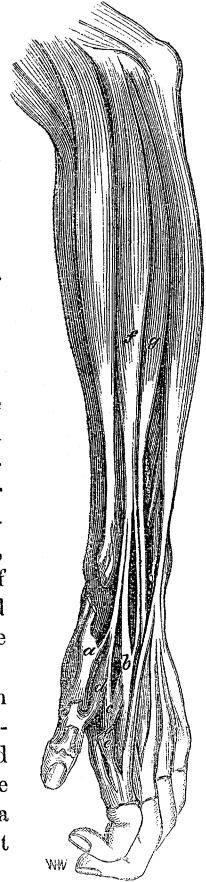
*Extensor carpi radialis accessorius*.—The above-described doubling of the tendon of the *longior* forms, apparently, the first point of transition to the abnormality found in no less than seven subjects (*viz.* Nos. 4, 6, 10, 15, & 17, males, and Nos. 27 & 29, females). In these a slip from the outer side of the tendon of the *longior* had a detached insertion into the base of the *pollex*-metacarpal and into the *first dorsal interosseous* muscle. Such slips have this session been very closely looked for as intermediate transitional forms of the muscle which has been described and figured by the author in former papers as the *extensor accessorius*. In the male (No. 4)

the insertion of this outer tendinous slip from the longior was found in both arms, and was so significant that it has been chosen as the subject of fig. 6. Leaving the outer side of the *longior* tendon and but slightly inferior to it in size, just above the radial styloid process, it crossed the depression of the "*tabatière*" under the extensor tendons of the thumb, and reached the first interosseous space. There it subdivided into two slips, the outer one of which was inserted into the inner part of the base of the *pollex-metacarpal* (*a*); and the inner, spreading out into a sort of aponeurosis, was first attached to the base of the *index-metacarpal* (*b*), and then passed into the united origins of the *abductor indicis* (*interosseus prior indicis* of Albinus) (*c*), and of an *interosseus primus volaris* of Henle (*d*). The first dorsal interosseus was entirely divided into two muscles, of which the posterior (*e*) arose from the contiguous metacarpals quite distinctly from the deeper muscle (*c*), which also arose by a bifurcated origin, one from the index-metacarpal, and the other from the slip of the *accessorius* tendon under description, in common with the *interosseus volaris*. In the figure, the dorsal portion is cut off close to its two origins to show the deeper part. In the same arm was observed an extensor-*intermedius* tendon, also leaving that of the *longior* (*f*), rather higher than the *accessorius*, and joining that of the *brevior* (*g*) at its insertion into the second and third metacarpals. The thumb-extensors are in the figure cut off close to their origins and insertions.

In this specimen we have clearly some light thrown upon the way of the formation of the anomalous *extensor accessorius*. The abnormal muscle is produced simply by lateral differentiation and displacement of the outer part of the muscle and tendon of the *longior*, a process which stops, in the specimen just described, at the tendon only.

In the left arm of the male (No. 6) a similar slip from the *longior* was inserted into the base of the *pollex-metacarpal*, and was continuous with the deep origin of the *flexor brevis pollicis*, there being no *interosseus volaris* present. In the right arm of No. 10 the same abnormal tendon was even larger than the normal one of the *longior*, and there were decided marks of a division of the muscular belly into a distinct muscle. The accessory tendon divided about an inch above its termination into an inner slip inserted into the outer tubercular projection of the base of the index-metacarpal, and an outer one which subdivided; one of the subdivisions, being inserted into the base of the *pollex-metacarpal*, gave part origin

Fig. 6  
(Subject No. 4).



to an *interosseus volaris*, the other becoming connected with the origins of the *abductor indicis* and deep head of the *flexor brevis pollicis*. On the opposite arm of the same subject, the *longior* had simply a double tendon, each part of which was inserted into the base of the index-metacarpal, one crossing under the other in a curious way. In the left arm of No. 15, and in both arms of No. 17 also, the tendon of the *longior* gave off a slip to the pollex-metacarpal. The female (No. 27) had a similar slip in the left arm, and No. 29 in the right arm. In the opposite arm of the former was a complicated arrangement of the *extensor intermedius*.

The foregoing *accessory* slips of the *extensor carpi radialis longior* would not be observed in a casual dissection of the part, the normal and abnormal parts of the tendon being closely applied to each other and divided by a mere chink. It is only by following closely the tendons to their ultimate insertion, and removing the dorsal interosseous fascia where it covers and conceals them, that the real insertion becomes apparent. Hence it appears that this abnormal slip, though now found to be not infrequently present, has never before been recorded. Macwhinnie mentions that the tendon of the *longior* is sometimes inserted partly into the dorsal fascia of the hand (*op. cit.* p. 191); and Heister (in Haller's *Disp. Anat. Select.* t. vi. p. 739) describes a *Musculus radiceus externus tricornis*, two tendons of which were inserted into the *first*, and the third into the *second* metacarpal bone. These may have been instances of the same formation.

The fully formed muscle and tendon of the *accessorius* was much more adapted to challenge attention; but after a careful and prolonged search among the works of the older anatomists (kindly placed within his reach by Professor Sharpey), the author has found that only one incomplete example has been recorded. The specimen referred to is described by G. Fleischmann (in *Abhandl. der physikalisch-medicin. Societät zu Erlangen*, 1810, Bd. i. S. 28, with a figure by Loschge, *Tafel I. fig. 2*). It was an example (found in both arms of a woman) of that variety of the muscle in which the tendon is not inserted at all into the pollex-metacarpal, but passes bodily into one of the muscular bellies of a double or divided *abductor pollicis brevis*. Such a specimen was figured by the author in his paper of 1854. The absence of any bony attachment to the pollex-metacarpal seems to have obscured the real nature of the muscle. It was called by Fleischmann "*der zweibäuchiger Abzieher des Daumens*," or "*abductor pollicis biceps*." It seems to have been the identical specimen obscurely alluded to by Meckel under that name (*Muskellehre*, S. 517), and mentioned by Cruveilhier under the head of "*abductor pollicis brevis*" as a double-headed abductor of the thumb. Henle also seems to have followed this indication of a digastric long abductor of the thumb (*Muskellehre*, S. 224).

In 175 subjects in which the author has had this muscle carefully

looked for, it has been found as a muscle and tendon, distinct from the extensor carpi radialis longior, in 6 subjects; viz. 5 *males*, in 3 in both arms, and in 2 in the right arm only, and in 1 *female*, where it was found in the left arm only. In Cuvier and Laurillard's plates of the dissection of the Common Seal (*Phoca vitulina*, pl. 19), is figured a slip of tendon from the single radial extensor of the carpus to the pollex-metacarpal, sending off a slip to join the insertion of the extensor pollicis. Humphry also describes the same slip as inserted simply into the pollex-metacarpal in that animal (Journ. of Anat. and Phys. May 1868, p. 306). In the great Anteater and Tamandua, Meckel describes a double or second supinator longus, of which the tendon of one is inserted into the ensiform bone and palmar fascia. This appears to be the homologue of the *accessorius*. The author has also found its homologue in the Ornithorhynchus and Echidna.

25. *Extensor carpi radialis intermedius*.—The muscle and tendon described by the author under this name, or its representative tendon passing between the *longior* and *brevior*, have been found this session in no less than 13 subjects. In the male (No. 11) and in the female (No. 22) it was represented by a muscular belly distinct from those of the longior and brevior, an arrangement which has been recorded by Albinus, Meckel, and Theile. In the left arm of the former subject, the muscular slip left the origin of the longior; and the tendon, after crossing between that of the longior and the radius, gave off a slip to the tendon of the brevior, and was finally inserted into the index metacarpal inside the longior. It was in the right arm of this subject that the radial extensors were blended, as before described. In the males (Nos. 2, 5, & 16) and in the females (Nos. 27 & 34), intermediate tendinous slips came off from both the longior and brevior (see fig. 7 b). A similar case is recorded by Bergman (Handschr. Notiz.) and quoted by Henle. In Nos. 2 & 5 these slips simply joined together to be inserted into the index metacarpal inside the longior. In the right arms of Nos. 16 & 27, the slips crossed each other without joining, to be inserted with the opposite longior and brevior tendons respectively. In the right arm of No. 34, two slips from the longior and one from the brevior united in a single tendon, which subdivided to be inserted with the longior and brevior respectively, as in the Ruminants. In the left arm of No. 27 the double slips united into one, which crossed under the tendon of the brevior to be inserted into the middle metacarpal bone on its *inner* or *ulnar* side. In four males (in Nos. 4 & 15 in both arms, and in 12 & 18 in the left arm only) and in two females (in the left arm of Nos. 30 & 34) the slip passed from the longior above to the insertion of the brevior below. This form of divergence has been recorded by Albinus and Scæmmerring. In another female (No. 23) the slip passed from the brevior above to the longior below,

Out of 102 subjects, viz. 68 *males* and 34 *females*, the *extensor carpi radialis intermedius* has been found complete or incomplete in 32, 19 males

and 13 females; *i. e.* a considerable majority proportionately in the latter sex. In 18 it was found in both arms; in 5 in the right; and in 9 in the left only.

26. *Extensor carpi radialis brevior*.—In 16 subjects out of the 36 of the present year, the tendon of insertion of this muscle was implanted upon the adjacent part of the base of the *second* metacarpal, as well as upon that of the *third*, its normal insertion. In two of these (Nos. 15 & 16) this insertion was made by a short but distinct slip. In all the others there was no division of the tendon at its insertion. In the right arm of the females (Nos. 29 & 30) the tendon gave off a slip from its inner side to the origin of the *third dorsal interosseous* muscle, showing a disposition to the formation of an insertion into the base of the fourth metacarpal, as recorded by Albinus (Hist. Musc. p. 446), and quoted by Macwhinnie. In the *Iguana tuberculata*, Mivart describes the single radial extensor as inserted by three tendons into the second, third, and fourth metacarpal bones. Thus, at intervals, there are found in the human arm, slips from the radial extensors to the four outer metacarpals, the extensor ulnaris providing for the fifth. In his paper in the first Number of the 'Journal of Anatomy and Physiology' (Nov. 1866), the author showed the occasional occurrence of a special *flexor* also for each of the metacarpals.

The above insertion of a slip of the brevior into the index-metacarpal is the first indication of that form of *intermedius* which passes *from* the brevior *to* the longior. The latter muscle and tendon, however, seem more prone to this fissuring or differentiation than the former.

27. *Extensor communis digitorum*.—In two subjects, abnormalities of this muscle resulted from a division of its muscular belly. In Nos. 5 & 13, males, it gave a separate belly to each tendon—as recorded by Albinus, Brugnone, and Meckel. In the female (No. 30) the indicial portion only was provided with a distinct belly,—as mentioned by Henle. In two males (Nos. 7 & 15) and three females (Nos. 24, 33, & 36) there was a multiplication of its tendons. In the female (No. 24) there were in both arms two tendons to the *middle* digit. In both arms of the male (No. 15) there were two to the *little* finger. In the left arm of the male (No. 7) there were two each to the *ring*- and *little* digits; while in the right arm were two each to the *index* and *little* fingers, and no less than *four* to the *ring*-digit. In the left arm of the female (No. 36) there were two each to the *index*, *middle*, and *ring*-fingers; while in No. 33 there were two each to the *middle* and *ring*. On the right hand of the last was a small fusiform muscle, ending in a tendon, which was implanted upon the fascia covering the first interosseous muscle. All these abnormalities find a parallel in those of the extensor longus digitorum pedis. The most noteworthy is the last, which resembles the slip given off from the tendon in the foot to one of the metatarsals, described in the author's last paper as resembling the formation in the Sloths and some Reptiles.

In the left arm of a muscular female (No. 27), a large slip of muscle

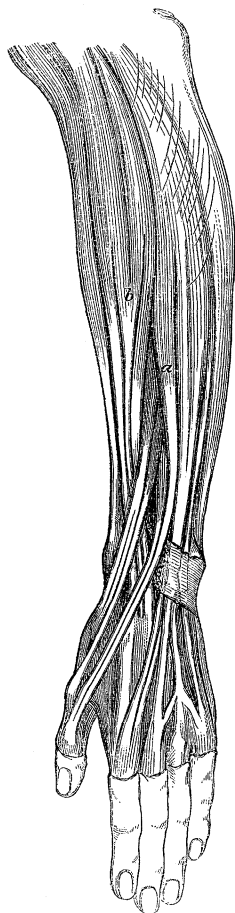
and tendon from the common extensor passed outwards, in the oblique groove of the radius, to be united with the tendon of the *extensor secundi internodii pollicis* at the base of the first phalanx (fig. 7 a). This very rare abnormality had its parallel also in the foot, in a slip from the extensor longus digitorum pedis to join the tendon of the extensor proprius hallucis, described in last year's paper. In both arms of a female (No. 25) a similar tendinous slip joined the tendon of the *indicator*. This also occasionally has its homologue in the foot in a double tendon to the *second toe*.

28. *Extensor minimi digiti*.—With only two exceptions out of the 36 subjects, this muscle presented a multiplication of its tendon; and in three instances a complete *double muscle* was present. In the latter instances, all of which were in males (Nos. 1, 14, & 17), and in both arms, the tendon of the abnormal muscle divided into two slips, one of which joined the extensor aponeurosis of the *ring-finger*. A double muscle has been found by the author in 4 males out of 68, and in 1 female out of 34, in all on both sides. In both arms of the male (No. 10) and the female (No. 34), and in the right arm of No. 32, the extensor of the little finger was provided with three tendons, one of which was furnished to the *ring-digit*. In the right arms of the male (No. 11) and the female (No. 20), and in the left arm of the male (No. 13), the muscle was provided with two tendons; one of which went also to the *ring-digit*. Thus, in 9 subjects, viz. 6 males and 3 females, out of the 18 of each sex, the *ring-digit* received a tendon from the extensor of the little finger, as well as one from the common extensor. In all the instances the latter was placed superficial to the former, constituting a close resemblance to the second or ulnar extensor muscle often met with in the lower animals.

Out of 68 males this insertion has been found in 9, and out of 34 females in 4; of these 9 (including 7 males) were found on both sides, 3 in the right, and 1 in the left arm only.

In 28 out of the 36 subjects in the Table, the tendon of the *extensor minimi* was simply doubled, *both* being inserted into the *fifth* digit. Eleven males and 8 females were so provided in both arms, 2 males and 1 female in the right arm only, and 6 females in the left arm only. This has been found to be the case altogether in 25 out of 68 males and in 18

Fig. 7  
(Subject No. 27.)





out of 34 females in 102 subjects—a proportion of 43 per cent. In 32 it was in both arms, in 4 in the right, and in 7 in the left only. It seems to be the first point of transition of a slip to the ring-finger.

In the left arm of the male (No. 7), the extensor minimi digiti was entirely *wanting*. It was, however, amply substituted by three tendons from the common extensor.

29. *Extensor carpi ulnaris*.—In 5 males and 1 female this muscle sent forward a slip of its tendon to be attached to the *extensor aponeurosis* of the *little* finger. In 2 males and 1 female this occurred in both arms, and in three males in the right arm only. In another male (No. 6) and a female (No. 31), this slip was present, but reached only as far as the head of the fifth *metacarpal* bone, into the upper border of which it was implanted.

This curious homologue of the *peroneus quinti* of the leg has been found by the author in 12 per cent. of subjects,—viz. in 10 out of 68 males (7 of which were in both arms, and 3 in the right only), and in 2 only out of 34 females (in 1 in both arms, and in the other in the left only). Thus it is  $2\frac{1}{2}$  times as common in the male sex as in the female.

30. *Extensor ossis metacarpi pollicis*.—In all the 36 subjects of the Table, except 1 male and 2 females, this muscle was provided with two or more tendons. In the 72 subjects of the Tables of the present and last year it has been found to be the case in 49. In the male subject (No. 5) the division extended to the formation, in both arms, of two *distinct muscles*, the inner one of which was inserted by a single tendon into the base of the pollex metacarpal; and the outer was provided with not less than four tendons, three of which were also inserted into the same bone, while the other gave part origin to the *opponens pollicis*. In this subject the extensor primi internodii was present, and inserted, with the secundi, into the extreme phalanx. In both arms of two males, and in the right only of three more, there were *three* tendons to the muscle, of which, in two instances, two were inserted into the metacarpal, and the third into the trapezium, or gave part origin to the *opponens* or *abductor pollicis* muscles. In one subject, one of the tendons was inserted into the metacarpal bone, trapezium, and opponens respectively; and in another, into the metacarpal, opponens, and abductor respectively. In one, the tendon of the extensor primi internodii came also from this muscle. In both arms of two females and in the left arm of a third, two of the tendons went to the metacarpal bone, and the other to the trapezium and abductor, or to the latter only. In the opposite arms of those subjects in which *three* tendons were found on one side only, there were always *two* tendons—one inserted into the metacarpal, and the other into the opponens and abductor pollicis.

In 24 subjects, viz. 9 males and 10 females on both sides, 1 male and 1 female in the right arm only, and 2 females and 1 male in the left only, the tendons of the extensor ossis metacarpi pollicis were *two* in number.

In 7 of these, both the tendons were inserted only into the metacarpal. In 14, the supernumerary one was inserted into the trapezium also. In 8 of them, slips were given also to the origin of the opponens pollicis; in 3, to that of the abductor; and in 4, to both these muscles. In two instances only, the second tendon joined the opponens or abductor without being connected with the trapezium—much resembling the slip of the *extensor carpi radialis accessorius* before described, by producing a *digastric abductor* of the thumb. The latter has apparently been confounded by anatomists with the abnormality under description. In the Orang-outang, the author found the extensor ossis metacarpi pollicis provided with a double tendon, one implanted into the trapezium and giving origin to the opponens pollicis. In most of the lower species of Monkey and Mammalia its tendon is single; its differentiation is therefore an evidence of elevation of type.

31. *Extensor primi internodii pollicis*.—In six cases the belly of this muscle was blended indistinguishably with that of the extensor ossis metacarpi pollicis. From this sprang three or more tendons, one of which was inserted into the base of the first phalanx of the thumb. Three were in males, and three in females. Three were in both arms; two in the right and one in the left only. This arrangement has been found in 4 out of 40 males, and in 4 out of 30 females.

In 5 males, 1 in both arms, 2 in the right and 2 in the left only, the tendon of this muscle was inserted entirely into the *ungual phalanx*, either in conjunction with or by the side of that of the *extensor secundi*.

In 3 males and 2 females the tendon, though having chiefly its normal insertion, sent forwards a slip to the same destination. This last arrangement has been found in 12 subjects out of 70.

In the male (No. 7) there were two slips of tendons to this muscle in the right and three in the left arm; of which two on one side, and one on the other, passed forward to join that of the *extensor secundi*.

In three subjects both muscle and tendon were entirely wanting—in the female (No. 19) in both arms, in the female (No. 22) and in the male (No. 14) in the left arm only. Also in the left arm of the female (No. 30) the tendon only (apparently from abortive development) was represented by a slip reaching from the styloid process of the radius to the base of the first phalanx of the thumb, exactly as recorded in a subject in the author's last paper. On the right arm of the same subject the tendon was very feeble, and came entirely from among those of the extensor ossis metacarpi pollicis. The muscle and tendon have been found entirely, or almost wholly wanting in 2 out of 68 males, and in 3 out of 34 females, a proportion in the latter sex of three times as many as in the former.

32. *Extensor secundi internodii pollicis*.—In 4 females and 6 females the tendon of this muscle was double, both having the normal insertion. In 2 males and 2 females it was so found in both arms, in 1 male and 3

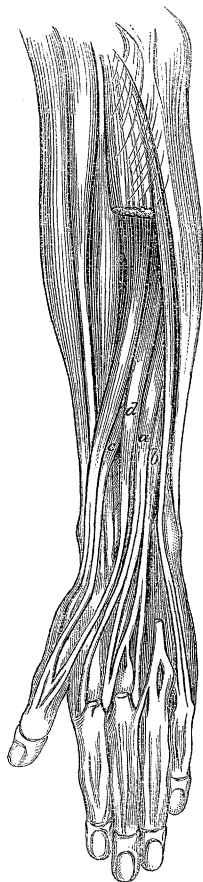
females in the right arm, and in 1 male and 1 female in the left only. In the left arm of No. 22, in which the *extensor primi* was altogether absent, the *secundi* sent off a substitutory slip to the *first* phalanx. In the left arm of No. 33, a slip from the *secundi* was given to the *first* phalanx, and one from the *primi* was sent forward to the *ungual* phalanx, forming a mutual compensation (see fig. 8, c, d).

33. *Extensor indicis*.—In the left arm of the female (No. 33), the subject of many abnormalities, this muscle was found to be quite doubled, a tendon from each going to the usual insertion. The tendon only was doubled in 3 males in both arms—and in 3 females, 1 in both arms, and 2 in the left only. In the left arm of a male (No. 15) the muscle arose from the radius, carpus, and interosseous ligament, and not at all from the ulna. In both arms of the female (No. 35) it arose in common with an *extensor medii digiti*, from which also the index received a third slip of tendon, in addition to those from the double indicator (see fig. 8 a). A double tendon or muscle to the indicator has been found in 11 out of 102 subjects, viz. :—in 6 males, on both sides ; and in 5 females—2 in both, and 3 in the left arm only.

34. *Extensor pollicis et indicis*.—In one male (No. 11), in the right arm, and in two females (No. 32 & 36), in both arms, were found the curious muscle first described by the author under this name. Arising between the *extensor secundi* and *extensor indicis*, from the hinder surface of the ulna and adjacent interosseous ligament and intermuscular septum, the muscle ends in a single tendon, which, passing in the common extensor sheath, divides on the carpus into two tendons. The inner is inserted either separately into the base of the *first phalanx*, or joins the *common extensor aponeurosis* of the index ; while the other passes outwards to join either the *extensor primi* or *secundi internodii* of the thumb. In both the females its pollex-tendon joined that of the *secundi*, while its index-tendon joined wholly the *common extensor* in one, and sent part of its fibres to the base of the first phalanx in the other.

In the right arm of the male subject (No. 11), the origin of the muscle was peculiar and differed from all the other specimens. Instead of arising from the ulna with the other muscles, it arose more superficially

Fig. 8 (Subject No. 33).



from the intermuscular septum, between the extensor communis and extensor ossis metacarpi pollicis, forming a layer intermediately placed, and appearing, at first sight, to be connected with the deep surface of the common extensor. Its pollex-insertion was with the tendon of the *secundi*; and at its indicial it joined the outermost of the tendons of a *double indicator* to be inserted into the base of the first phalanx. This origin of the muscle seems to form an intermediate link, and to connect it with the somewhat similar abnormality of the extensor communis digitorum in subject 27 (see fig. 7 a).

35. *Extensor medii digiti*.—In 2 males (1 in the right arm, and the other in the left), and in 4 females (2 in both arms, 1 in the right, and 1 in the left), this muscle was found arising in common with the *indicator*, the lower fibres of which gave off a tendon to be inserted into the base of the first phalanx of the middle digit. In 2 females, in both arms, it was found as a separate muscle arising, below the indicator, from the ulna and interosseous ligament. In the right arm of one of them (No. 28) the muscle had a peculiar origin from the intermuscular septum between the extensor communis digitorum and supinator brevis, higher and more superficial than the rest of the deep muscles. Forming a fusiform belly, it ended in a long tendon, which was inserted into the extreme or ungual phalanx of the middle finger, internal to the common extensor, crossing the fibres of insertion of the interosseus. This abnormality, again, has a resemblance to the variety of the extensor pollicis et indicis just described in the male (No. 11). In both arms of No. 33 (the subject of fig. 8) the muscle (*b*) was distinct and gave off two tendons, of which the inner was inserted into the base of the middle digit; and the outer subdivided into two slips, one to join the inner tendon of a *double indicator*, and the other to be inserted upon the *middle metacarpal* fascia. This hand showed a remarkable complexity and profusion of the special extensor muscles.

Out of 102 subjects this special *extensor* of the *middle finger* has been found 4 times in the 68 *males*, and 7 times in the 34 *females*, giving a proportionate frequency of nearly four in the latter sex to one in the former. It is a muscle constantly present in the *Quadrumana*.

36. *Extensor brevis digitorum manus*.—In 3 male and 3 female subjects, slips of muscle were found on the dorsum of the hand, arising, distinct from the dorsal interossei muscles, from the os magnum or unciform bones, and inserted into the common extensor aponeurosis of one or more digits. In the right hand of No. 3, and the left of No. 7, males, and in both hands of No. 21, a female, there was but *one* slip, which was inserted with the tendon of the second dorsal interosseus into the *middle* digit. In both hands of No. 2, male, there were *three* slips, arising respectively from without inwards from the os magnum, unciform and cuneiform bones. The outer was inserted with the second dorsal interosseus into the *middle* digit—and the two inner on each side of the *fifth* digit, with the abductor and interosseus respectively. In the female (No. 23) there were *two* slips,

in both hands, one from the os magnum to the *middle* digit, and the other from the unciform to the *ring*-digit. In the female (No. 33), the subject of the last figure, the right hand, only, showed *three* slips, arising from the dorsal aspect of the bases of the second, third, and fourth *metacarpals* and their dorsal ligaments, and inserted into the *corresponding* digits.

In 68 males this muscle has been found by the author in 7, and in 34 females in 3—giving nearly an equality in the sexes. In looking over the works of the older anatomists, the author finds that short single dorsal slips to the index or middle finger had been observed by Albinus, and described by him as the "*Musculus extensor brevis digiti indicis vel medii*" (Acad. Annot. lib. iv. cap. vi. p. 28, and tab. v. fig. 3, 1734). A single slip from the carpus to the index is described by Gantzer as an *indicator biceps* (*op. cit.* p. 14), and similar ones by Otto as an "*indicator anomalus brevis*" (Seltene Beobacht. S. 91), arising from the radius in one instance, and from the third metacarpal in another. In two other male hands the last-named anatomist found a slip from the carpus to the middle finger, which he calls the "*extensor anomalus brevis des Mittelfingers*." Sæmmerring, Petsche, and Sandifort have described slips which might be confounded with these, but which refer rather to the true *indicator* giving off an *extensor medii digiti*. In all of them, however, the slips were single, and did not form the broad flat muscle described by the author in his former papers. It is remarkable that they were all found in male subjects. The short common extensor of the digits is represented in the *Bradypus tridactylus*, in the two-toed Anteater, and in the Saurian, Chelonian, and Batrachian Reptiles, according to Meckel (Anat. Comp. vol. v. pp. 386, 388, & 391, and vol. vi. pp. 346 & 351, and Archiv, v. p. 47).

37. *Abductor pollicis*.—In 2 males and 2 females this muscle was divided into two portions, rather widely separated at their origins from the trapezium and annular ligaments respectively. In the 2 males and in 1 female this was the case in both hands, and in the other female in the left hand only. In the two males there was, in addition, a considerable muscular slip from the inner of the two to join the fibres of the *opponens pollicis* in their insertion.

38. *Abductor minimi digiti*.—In the right hand of the male (No. 2) a separate muscular head from the anterior annular ligament joined the tendon of this muscle at its insertion. In both hands of No. 3 the muscle was double, the *flexor brevis* being *absent*. In the left arm of No. 11 the muscle was arranged in two parts, viz. the normal origin, and a high origin  $2\frac{1}{2}$  inches above the wrist. The latter arose by two heads, one fleshy, from the fascia covering the *flexor carpi ulnaris*, and the other tendinous, from the tendon of the *palmaris longus*. These united above the wrist to form a fleshy muscle, larger than the normal origin, and placed external to it, which became united with it just before its insertion.

This abnormality has been found in 3 males only out of 102 subjects of both sexes examined by the author. It has been described by Sæmmerring

(*op. cit.* p. 272). It was also found by Günther and Milde (Die chirurgische Muskellehre, Taf. 30. fig. 5. 18). In the right arm of a muscular soldier Gantzer found a fleshy muscle connected with the insertion of the *abductor minimi digiti*, arising from the sheath of the *flexor-carpi-radialis* tendon, to which he gave the name of the "*accessorius ad flexorem carpi radialem*" (*op. cit.* p. 12), which was evidently a muscle of the same character as the foregoing. Macwhinnie mentions similar high origins of this muscle, arising from the tendon of the *palmaris longus*, as varieties of the last-named muscle (*op. cit.* p. 191). This abnormal upward extension of the origin of the *abductor minimi digiti* seems to correspond to the shortest of the three muscles representing the ulnar carpal extensor found in the Anteater (Meckel, Archiv, B. v. S. 45, k). In both hands of the female (No. 20) the muscle was provided with a double tendon of insertion; and in the right hand of No. 33 the whole muscle was divided into two parts.

39. *Interossei manus*.—In both hands of 4 males and 3 females, and in the left only of one other female, the "*interosseus primus volaris*" of Henle was found. In No. 4 this muscle, as before described, was connected at its origin with an *accessory* slip of the *extensor carpi radialis longior* (see fig. 6 d). It has been found in 12 out of 102 subjects, usually on both sides. In the males (Nos. 3 & 4) the *first dorsal* was separated into two muscles, the *abductor* and *interosseus prior indicis* of Albinus.

40. *Sundries*.—Besides the *scapulo-clavicular* and *chondro-coracoid* muscles described in the former part of the paper, in subjects 4 and 13, this column marks in the male (No. 7) an abnormality of the *infra-scapular* muscle, which consisted in a separate origin and distinct superficial position of the fibres derived from the spine of the scapula. In the right arm of the female (No. 21) the *supinator longus* received a large muscular slip from the *extensor carpi radialis longior*, as described with the abnormality of the latter muscle. On the right side of No. 35 two large fleshy slips from the ninth and tenth ribs, and on the left side from the eighth also, quite separate and somewhat distant from the rest of the *serratus magnus*, were inserted into the lower angle of the scapula, with the lower fibres of that muscle, which reached no lower than the seventh rib. This differentiation of the lower fibres of the *serratus* resembles the *depressor scapulæ* muscle found in the Birds. The female (No. 36) was remarkable for the very rare absence, in the right hand, of the *palmaris brevis* muscle.

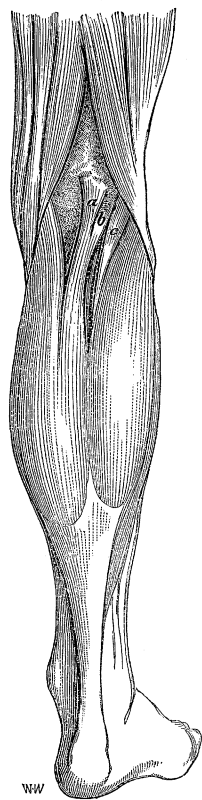
The remaining sixteen columns are occupied by the abnormal muscles of the *Leg*. The additional lines of variation are partly composed of muscles which have not been before especially regarded (such as the *pyriformis*, *gemelli*, and *opponens minimi digiti*) and partly of more numerous specimens of abnormalities presented by those which were before comprised in the column of sundries (as the *plantaris*, *peroneus brevis*, and *adductor hallucis*).

41 & 42. *Pyriformis* and *Gemelli*.—In 3 males and 1 female the tendon of the *pyriformis* was blended with that of the *obturator internus*

and inserted with it into the groove of the great trochanter. In one of these males (No. 4), and in the female (No. 19), the *superior gemellus*, which usually intervenes, was entirely absent on both sides, and in one other male (No. 17) on the right side only. In the other instances it was inserted into the common tendon. On the right side of the female (No. 19) the *inferior gemellus* was also absent. In two females the *pyriformis* muscle was divided into two parts, between which passed a portion of the great sciatic nerve. This is a frequent and striking abnormality usually noticed by anatomical writers upon the subject.

43. *Plantaris*.—In the right leg of the male (No. 3) a double muscular belly was found, both joining a single tendon rather larger than usual. In both legs of the female (No. 22) a muscular slip, nearly equal in size to the normal belly, passed from the inner side of its origin to be inserted upon the *posterior ligament of Winslow*, close to the insertion of the *semi-membranosus*-tendon, and under the inner head of the *gastrocnemius*. This curious slip appeared to be an instance of a development of muscular fibres in the substance of a tendon, similar to that unusual one which is seen in the tendon of the *peroneus quinti* (fig. 10). In its origin and direction, however, it has some resemblance to the *third head* of the *gastrocnemius* muscle found in the left leg of the male (No. 7), and marked in the Table among the sundries (col. 56). It may, perhaps, be most convenient to describe it in this place. A fleshy tapering head of muscle of considerable size arose from the middle portion of the popliteal surface of the femur just above the condyles (fig. 9, *a*). Opposite to the knee-joint it was joined on the outer side by a broad tendinous slip (*b*), arising from the posterior ligament of Winslow close to the *plantaris* muscle (*c*). The two on joining, formed a considerable bundle of muscular fibres, which, increasing slightly as it descended, joined the *inner head* of the *gastrocnemius* just before its union with the outer. This abnormality resembled in some respects that described by R. Quain (plate 80. figs. 4 & 5), in which a third head, arising from the outer femoral condyle, crossed the space between the popliteal artery and vein, and finally joined the deep surface of the outer head. Henle also describes a third head, arising from the popliteal surface of the femur, and ending in a cylindrical tendon which spread out

Fig. 9 (Subject No. 7).



and united with the point of junction of the *soleus* and *gastrocnemius* (Muskellehre). Theile also met with such a supernumerary head (*op. cit.* p. 316).

44. *Flexor longus digitorum* and *lumbricales pedis*.—In 2 males (Nos. 4 & 12) and 4 females (Nos. 22, 27, 29, & 30) the tendon of the *flexor longus digitorum* gave a considerable slip in the sole to join that of the *flexor longus hallucis*, as well as received one from it. In 1 male it was found in both feet; and in the other, as well as in 3 out of the 4 females, in the right foot only; in the remaining female it was present in the left foot only.

This slip has been especially noted only in the present year, and returns an average of about 18 per cent. Schultze of Rostock found it in 29 subjects out of 100, and usually on both sides (*Zeitschrift für wissenschaft. Zool.* xvii. 1). Nearly the same proportion was found by Turner in 50 subjects (*Edinb. Phil. Trans.* xxiv.). The slip did not in our subjects seem to be in any way compensatory for any want of size in the tendon of the flexor hallucis; for in one female (No. 22) that tendon was unusually large even before the junction. In the female (No. 27) the flexor hallucis received also a slip of reinforcement from the *flexor accessorius*. In the foot of No. 29, female, the *perforating* tendon to the second toe was derived wholly from that of the *flexor hallucis*, the common flexor supplying only the three outer toes. In the right foot of the male (No. 11) the *perforating* common flexor of the third toe gave off a slip of reinforcement to the *perforated* opposite to the base of the metatarsus.

In the male (No. 1) the *fourth lumbricalis* was absent in both feet. In the left foot of No. 9 the same muscle was double and bifurcated, and inserted into the contiguous sides of the fourth and fifth toes. In No. 8 the *third lumbricalis* was double in both feet, and inserted into the contiguous sides of the middle and fourth toes.

According to Froment (*op. cit.*), varieties in the *pedal lumbricales* are very rare. Gantzer had previously stated the same thing (*op. cit.* p. 17). In the notes of Sæmmerring, quoted by Theile, Behrends is said to have observed the absence of the *two middle* ones. Rudolph, quoted by Gantzer (*op. cit.*), found the *third* absent in the left, and the *fourth* in the right foot of a muscular male.

Out of 102 subjects examined, the *second lumbricalis pedis* was found, in one, *absent* on both sides; in one, the *third* arose from the tendon of the perforatus instead of the perforans; in another, it was double on both sides; the *fourth* was *absent* in three subjects—in one on both sides, in one in the right, and in one in the left foot only; in one the same muscle, in both feet, was *doubled*, bifurcated, and inserted into contiguous sides of the corresponding toes. This gives a proportion of only 7 per cent. of abnormalities in these muscles, contrasting widely with the frequency of irregularity of the same muscles in the hand.

45. *Flexor longus hallucis*.—In both feet of a male (No. 17) the tendon of this muscle gave no slip to that of the *common flexor*. In both feet of



a female (No. 31) the slip was, on the contrary, unusually large. In the right foot of another (No. 27) it received a considerable slip from the *flexor accessorius*, as well as from the common flexor. In a third (No. 29) it supplied the whole of the *perforating* tendon to the *second* toe, after receiving only a very small slip of fibres from the common flexor.

46. *Extensor primi internodii hallucis longus*.—In all the 18 males except two, and in 13 out of the 18 females, the base of the *first* phalanx of the *great toe* was the point of insertion of a more or less considerable slip of tendon, described by the author in former papers under the above name. In all except three it existed in both feet, in two in the right foot, and in one in the left only, exhibiting an unusual uniformity in this respect.

In 3 males (Nos. 5, 7 & 11) the tendon was derived from that of the *tibialis anticus*, leaving it a little above the ankle.

This curious parallel to the *peroneus quinti* on the outside of the foot, had been previously found by the author in five other male subjects—in four in both feet, and in one in the right only. The frequency of its occurrence is in about 8 per cent. of subjects, although this variety seems to have escaped the observation of anatomists. In the male (No. 15) the tendon existed in the right foot only, as a well-defined and strong fibrous band connected with the anterior ligament of the ankle-joint, with a distinct insertion into the first phalanx of the great toe. It was totally unconnected with any other tendon. This instance presents a curious parallel to the like occasional abortive development of the homologous tendon in the hand, viz. the *extensor primi internodii pollicis*, which has been described in these pages as having been found, in two instances, connected solely with the styloid process of the radius, close to the posterior ligament of the carpus.

In all the rest of the subjects in which this tendon was found, it was an offset of that of the *extensor proprius hallucis*, and was inserted either singly into the middle of the dorsal border of the base of the first phalanx, or joined with the innermost tendon of the *extensor brevis digitorum* in the same insertion. Sometimes it was connected separately with the lower *muscular* fibres of the proprius, which showed, by a disposition to separate from the rest, a tendency to form a *separate* muscle, such as that described by the author in his former papers, and recorded by Meckel (Archiv, Bd. v. S. 117), and mentioned by Theile and Henle (Muskellehre, S. 277). The slip of tendon from the *extensor proprius* is recorded by Sæmmerring (*op. cit.* p. 323) and by Walther (in Haller's Disp. Anat. Select. vol. vi. p. 559).

47. *Extensor longus digitorum pedis*.—In No. 1, male, this muscle divided into four separate bellies, one to each tendon. The outermost was joined by two slips from that of the *peroneus tertius*, which was split into three parts. In the left leg of the male (No. 6) a tendon of reinforcement was given off in the opposite way, viz. from the outermost of the extensor longus to the middle of the upper border of the fifth metatarsal bone. In the right leg of the female (No. 35) the same abnormality occurred in the shape of two tendons to the fifth metatarsal.

Nearly the same arrangement was found in both legs of a male last year, making a proportion of 3 in 70 subjects. It was found, according to Meckel, in the Sloths and Reptiles.

In the female (No. 33) a slip was given from the second tendon of the extensor *longus* to that of the extensor *brevis*, as found in a male in last year's series. This was noticed by Macwhinnie (*op. cit.* p. 195) joining the great-toe tendon of the *brevis*.

48. *Peroneus tertius*.—In 15 subjects, viz. 8 males and 7 females, this muscle presented abnormalities of various kinds. The most conspicuous was its entire *absence* in the right leg of one male (No. 8) and two females (Nos. 21 & 23). In the left leg of the male its tendon was very small, and was lost upon the *fourth interosseous* fascia and muscle, not reaching the metatarsus.

Out of 68 *males* this muscle has been found to be absent in 5, and out of 34 *females* in 5 also, giving a proportionate *frequency of deficiency exactly double* in the *females*. In the 5 males it was wanting in 1 on both sides, in 3 in the right, and in 1 in the left leg only. In the 5 *females* it was wanting in 1 on both sides, in 3 in the right, and in 1 in the left leg only. It would thus seem to be absent most frequently in the *right* leg. In the only instance in which the left leg only is recorded, the representative in the right leg was a mere slip from the extensor-communis-digitorum tendon, which could scarcely be called a peroneus. This muscle is uniformly *absent* in the Quadrumana and all the lower animals, and appears to subserve especially the erect position peculiar, among mammals, to the human subject.

In both legs of the male (No. 1) and in the right leg of the female (No. 35) the tendon of the *peroneus tertius* gave off slips of reinforcement to the outermost tendon of the *extensor longus digitorum*, in front of the ankle. In both legs of No. 16 a similar slip joined that of the *extensor brevis*. In 5 males and 4 females it was provided with two tendons or split. In both legs of No. 4, and in the right leg of Nos. 5 & 9 (males), both the tendons were inserted separately into the fifth metatarsal bone, one close to its base, and the other about its middle. In the right leg of Nos. 7 & 9 (males), and No. 27 (female), in the left leg of No. 8 (male), and in both legs of No. 29 (female), one of the double tendons, or a slip from a single tendon, passed forward to join the *fourth interosseous* fascia or muscle. In both legs of No. 18 (male), and in the left of No. 19 (female), the tendon of the *peroneus tertius* was implanted wholly upon the *fourth* instead of the *fifth* metatarsal bone; and in both legs of No. 34 (female) it was *mainly* inserted into the *fourth*, giving off a slip only to the fifth.

Altogether in 102 subjects these varieties of *redundancy* were found to be *half as many again* in males as in females, contrasting widely with the greater frequency of *deficiency* in females before described.

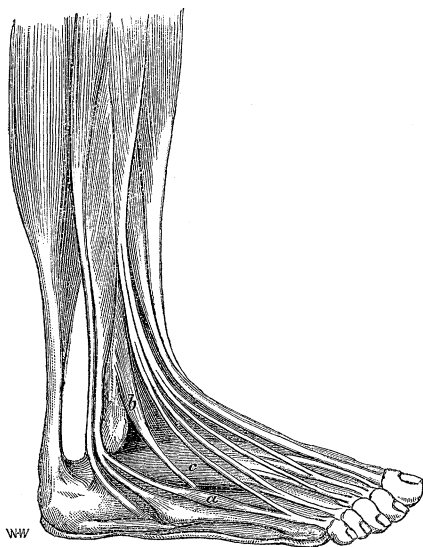
49. *Peroneus brevis*.—In the male (No. 3) the posterior fibres of this

muscle were connected with a distinct tendon, rather smaller than the normal one, which, passing in the groove and sheath of the *peroneus longus*, was implanted upon the outer margin of the *cuboid* bone behind its peroneal groove. A similar instance has been recorded by Macalister. It is of the same character as the *peroneus quartus* of Otto, which was inserted into the *calcaneum*.

The *peroneus quartus* has been found twice in 70 subjects by the author. Meckel describes it in the Kangaroo. In 1 male and 1 female the tendon of the *brevis* was found, in both legs, to give off a slip of reinforcement to that of the *tertius*.

50. *Peroneus quinti*.—This variety, constituted usually, in the human subject, by a slip of tendon from that of the *peroneus brevis*, given off below the outer ankle and joining the extensor aponeurosis of the *little toe*, was found in the male (No. 11) to have developed upon it a complete, distinct, and fusiform *muscular belly* (fig. 10 *a*), exactly like that described in the author's paper of 1864, and also by Hallett in his paper in the Edinburgh Medical and Surgical Journal of 1848. The *peroneus tertius* (*b*) was present and normal, and the tendons of the extensor *brevis digitorum* (*c*) complete.

Fig. 10 (Subject No. 11).



In 7 males—4 in both legs, 1 in the right, and 2 in the left only—the tendon of the *peroneus quinti* was complete, reaching to the extensor aponeurosis of the little toe. The same was the case in 4 females, 2 on both sides and 2 on the left only. In 2 males in both legs, and in 6 females, of which 4 were in both legs, 1 in the right, and 1 in the left only, the tendon, after parting from the *peroneus brevis* in the usual way, became spread out in front and lost upon the upper border of the *fifth metatarsal* bone about its middle—an incomplete arrangement, said by Mr. Davis to be found also in the Civet Cat (Journ. of Anat. and Physiol. May 1868, p. 217).

Out of 102 subjects, in the 68 males the complete muscle has been found once, the complete tendon in 18, and the incomplete tendon in 5, making 24 in the males. In the 34 females the complete tendon has been found in 5, and the incomplete form in 8, making 13 in the females. This gives about an equal average in the two sexes.

51. *Extensor brevis digitorum*.—In 4 *males* the tendon from this muscle to the *second* toe was found *doubled*; 1 was found on both sides, 2 in the right foot, and 1 in the left only. In 3 *females* the same arrangement occurred; in 1 in both feet, in 1 in the right, and in 1 in the left only. In 2 of the *males* (Nos. 4 & 8) the supernumerary tendon was inserted separately into the base of the first phalanx. In the rest it joined, like its fellow, the extensor aponeurosis. In the right foot of one male (No. 3) and one female (No. 22) the fibres of the muscle to the *second* toe gave a tendinous slip to the *first interosseous* muscle and fascia. This is doubtless an imperfect form of the same abnormality.

Out of 40 *males* the former arrangement has been found in 6, and the latter in 3; in 30 *females* the former was found in 3, and the latter in 1,—giving a total of 13 in 70 subjects.

52. *Abductor ossis metatarsi quinti*.—This muscle, first described and figured by the author in his paper of 1864, arising from the outer tubercle of the calcaneum, and inserted into the tubercle at the base of the fifth metatarsal bone, covered and concealed by the *abductor minimi digiti* and the insertion of the *peroneus brevis*, has been found this year in 19 subjects out of the 36, viz. in 11 out of the 18 *males* and in 8 out of the 18 *females*. Of the *males*, 5 were found in both feet, 3 in the right, and 3 in the left foot only. Of the *females*, 5 were found in both feet, 1 in the right, and 2 in the left foot only. It has been described by Professor Huxley and Mr. Flower in the foot of the Gorilla and Chimpanzee, and has been found by the author in that of the Orang-outang and Bonnet-Monkey; and also, lower in the scale, in the Cat, Hedgehog, and Squirrel he has found evidences, though less distinct, of its presence. It is figured by Strauss-Durckheim in the anatomy of the Cat. Mivart and Murie describe it in the Hyrax, and the former observer also in the *Iguana tuberculata*. In the Echidna also are fibres answering to this muscle. Meckel describes a similar muscle in the Makis, the Brown Bear, and the Coati.

Out of 63 *males* the author has found this muscle in 27, viz. in 19 in both feet, in 4 in the right, and in 4 in the left foot only; out of 34 *females* he has found it in 16, viz. in 10 in both feet, in 3 in the right, and in 3 in the left foot only,—giving a proportion of about 43 per cent. of all the subjects, and a frequency of 1 in the *male* to  $1\frac{1}{4}$  in the *female* sex.

53. *Flexor brevis digitorum pedis*.—In 3 *males* and 3 *females* (in one of the former in both feet, and in 2 in the right foot only, and in 2 of the latter in both feet, and in the other in the right foot only) the outermost tendon of this muscle to the little toe was *absent*, as in the *Quadrumana*. In some, a substitutory slip of muscle, arising from the corresponding tendon of the *perforans* or long flexor, was discovered, but often no trace of a *perforatus* tendon could be found in the digital sheath. In the right foot of the male (No. 8) a slip of tendon from the *perforans* of the middle digit became blended with the *perforatus* at the metatarso-phalangeal joint. In the same foot a well developed fusiform muscle arising from the tendon

of the *perforans* supplied the perforated tendon of the *little toe*. In the right foot of No. 11 a long slip from the *flexor-longus-digitorum* tendon joined that of the *flexor brevis* going to the middle toe—as before described with the varieties of the former muscle. In the left foot of the same subject a similar tendinous slip to the *flexor brevis* tendon of the middle toe arose from the fibres of the *accessorius*.

Out of 68 *males* the outer tendon of the *flexor brevis digitorum* has been found *absent* in 10, viz. 6 in both feet, 3 in the right, and 1 in the left only. Out of 34 *females* it has been found *absent* in 5, viz. in both feet in 4, and in 1 in the right only. This gives a proportion of 15 per cent. and an exact *equality* in the two sexes. In 4 of these, viz. 3 males and 1 female, a substitutory slip of muscle and tendon arose from the corresponding tendon of the *perforans*, as in the *Quadrumana*. In one this was connected partly with the fibres of the *accessorius*, and partly had a separate origin from the tubercle of the calcaneum.

54. *Abductor hallucis*.—A considerable slip from this muscle to the *second toe*, arising with the front fibres, and inserted into the base of the first phalanx, as first found and described by the author in his paper of last year, was seen this year in three *males* and one *female*. In one of the males and in the female it was found in both feet, in one male in the right foot, and in the third in the left foot only. A similar slip is said by Meckel to be found in the foot of the White Bear.

Out of 40 *males* this slip has been found in 5, in 2 in both feet, in 1 in the right, and in 1 in the left foot only. Out of 30 *females* it has been found in 1 only, in both feet.

55. *Opponens minimi digiti*.—This muscle, first pointed out by Henle as frequently present in the human foot, has been noted this year in 6 subjects out of 36, in 1 male and 5 females. In 4 it was found in both feet, in 1 in the right and in 1 in the left foot only. In 1 female in last year's series it was found, remarkably large, in both feet. The author has found this muscle largely developed in the Orang. In the Bonnet-Monkey it was not present. It is figured in Cuvier and Laurillard's plates as very large in the foot of the Lion and Panther.

56. *Sundries*.—Besides the three-headed gastrocnemius already described, we have in this column, in the male (No. 4), an entirely detached portion of the *iliacus internus*, arising from the middle of the iliac crest by a thin tendinous aponeurosis, forming a flat muscular slip, which was inserted into the common tendon of the *psous* and *iliacus* muscles. In both feet of the female (No. 20) the *abductor minimi digiti* was provided with two distinct tendons. In the left leg of the female (No. 22) a considerable fleshy slip from the *adductor brevis* joined the tendon of the *obturator externus*. In the right foot of the female (No. 27) the tendinous slip from the insertion of the *tibialis posticus* to the outer cuneiform bone, which usually gives part origin to the *flexor brevis hallucis*, passed wholly into that muscle without being connected with the cuneiform. In

the left leg of No. 29 a considerable muscular slip passed from the origin of the *pectineus* muscle across the deep femoral artery to join the fibres of insertion of the *adductor longus*. This slip was noted in two subjects in last year's series. It is also mentioned by Macwhinnie (*op. cit.* p. 194), and is found in some of the *Quadrumana*, *Carnivora*, and *Rodents*.

In the right leg of the female (No. 33) was found a complete specimen of the *flexor accessorius digitorum longus pedis*, arising by a single penniform belly from the lower third of the outer border of the *fibula* and the posttibial fascia, and ending in a tendon which joined that of the *flexor digitorum longus* at the point where the normal "*massa carnea Sylvi*" was connected with it.

This abnormal muscle has been found in 4 male subjects out of 68, and in 1 female out of 34. In all it arose from the lower third of the *fibula* and the *fascia* covering the *flexor longus hallucis*. In 3 of the males it was found in both legs. In the fourth male and in the female it was found in the right leg only.

On reviewing the foregoing 18 males and 18 females with reference to the Table, it will be seen, as might be expected, that the greatest absolute number of abnormalities in the vertical columns (reckoning both sides as one) is found in those muscles the variations of which have been hitherto best known to anatomists. These have been noted to ascertain simply their exact frequency.

Of supernumerary tendons of the *extensor minimi digiti* and *extensor ossis metacarpi pollicis* there are 33 instances—1 only of the males and 2 of the females, and these latter in the same individuals presenting the single insertion described in most anatomical manuals. The coronoid origin of the *flexor pollicis longus* is seen in 27 subjects, only 5 males and 4 females not possessing it. Slips of junction with the *flexor profundus digitorum* were found in 3 subjects. The *extensor primi internodii hallucis longus* is found in 29 subjects, only 2 males and 5 females not possessing it. The *peroneus quinti* tendon is found in 20 subjects, 10 in each sex. Next comes the *abductor ossis metatarsi quinti* in 19 subjects, 11 of which are males—a much larger proportion in that sex than was found in last year's series. The *extensor carpi radialis brevis* and *primi internodii pollicis* each give 18 abnormalities, 9 of which in the latter muscle were instances either of partial amalgamation or total absence, 4 in males and 5 in females. The *peroneus tertius* presents abnormalities in 15 subjects, 2 of which are instances of total deficiency, and both of them in females. This is curious when compared with the greater frequency of absence in the same sex of the *extensor primi internodii pollicis*. Both these muscles are eminently human muscles, and are never found even in the highest of the *Simiadae*. The absence of the two muscles does not, however, seem to be correlated; it is not found in the same individual in any of the cases. The *cleido-occipital*, *palmaris longus*, and *flexor profundus digitorum* come next in frequency, each in 14 subjects, and nearly

equally in the two sexes. The *extensor carpi radialis longior* (with the *accessorius*) and the *extensor communis digitorum* are found abnormal in 12 subjects, and the *extensor secundi internodii* in 11. These numbers accord, relatively and proportionately, pretty closely with their parallels in last year's series.

The *greatest number of abnormalities in each subject* is found in the *males*:—No. 7 having no less than 25 (the greatest number, it is believed, ever found in one subject), of which 17 are in the arms, and 5 only in the legs; and No. 11 having 24, of which 14 are in the arms and 6 in the legs. No. 17 has 20, of which 13 are in the arms and 7 in the legs. In all these the greatest number is found in the *arms*. But, on the other hand, we find that No. 4, having also 20 abnormalities, has 9 in the arms and 10 in the legs.

Of the *females*, No. 33 has 20 abnormalities, of which 15 are in the arms and 5 in the legs; while No. 29 has also 20, of which 11 are in the arms and 8 in the legs. In some, the proportion of the number of abnormalities in the *arms* to those in the *legs* is even greater than the above—as, for example, in the males No. 10 (in which it is 11 to 1), No. 13 (12 to 2), Nos. 2 & 6 (10 to 2), and in the females No. 31 (12 to 2), and No. 23 (10 to 2). In the male No. 1 the abnormalities in the arms and legs are equal, 6 in each; and in the female No. 21 they are also nearly equal, 8 in the arms and 7 in the legs. In only one subject, the male No. 8, is the number of abnormalities in the legs (8) greater than that in the arms (4). The smallest number of abnormalities is in No. 14 (male), viz. 5 in the arms and 2 in the legs; and in No. 26 (female), 1 proper to the head, 2 connected with the arms, and 1 in the legs.

In estimating the total number of abnormalities, both sides of the body, when alike or nearly alike, and complications affecting mutually two or more neighbouring muscles, are, for the sake of convenience, reckoned as *one* instance. 296 are found in the 18 *males*, and 262 in the 18 *females*, making a grand total of 558. Of the 296 in males, 13 are found in the muscles proper to the *head and neck*, 24 in those connected both with the *head and neck* and *arm*, 182 belonging to the *arms* only, and 77 to the *legs* only. Of the 262 in *females*, 7 are found in those proper to the *head and neck*, 16 in those connected with the *head and neck* and *arms*, 168 belonging to the *arms* only, and 71 to the *legs* only.

The proportion of those in the *arms* to those in the *legs* in the two sexes is much more nearly equal in this year's than in last year's subjects (in which the latter predominated), and amounts to about 5 in the arms to 2 in the legs. All the *lines of variation* observed in former years, except the *occipito-scapular*, *supracostalis*, and a few other less important muscles, have been noted in this year's series.

Of the 296 abnormalities found in the 18 males, 173 have been found *on both sides*, 62 on the *right side only*, and 61 on the *left side only*, making 123 *single* or *one-sided* specimens. Of the 262 found in the 18

females, 138 have been found on *both sides*, 55 on the *right side only*, and 69 on the *left side only*, making 124 *single* or *one-sided* specimens, and giving rather *fewer* on the *right* and *more* on the *left* side than in the males. In the *females*, also, it will be observed that the proportion of the abnormalities found *on both sides* to those found *on one side only* in the same sex, is much *less* than in the *males*. This is found to depend upon the smaller number found in both *arms* of the female, viz. 96 in the *females* to 125 in the *males*, while the number found in the *left arm only* of the females is 51 compared with 38 in the *males*; and that found in the right arm only of the *females* is 29, compared with 36 in the *males*. On the other hand, the number found in the *left leg only* in the *female* is but 10, in comparison with 13 in that of the *male*, and with 20 in the *right leg only* of the former sex.

The disproportion in this particular comes out still more markedly when the whole number of 102 subjects comprised in the Tables of the three last years, viz. 68 *males*, and half that number, or 34 *females*, is taken into consideration.

The number of abnormalities in the 68 *males* is 414 on *both sides*, 108 on the *right*, and 101 on the *left side only*, making 209 *one-sided* specimens. The number of abnormalities in the 34 *females* is 209 on both sides, 68 on the *right*, and 81 on the *left side only*, making 149 *one-sided* specimens.

Thus in the *females* we find a proportionate preponderance to the amount of about 45 *one-sided* specimens; and these are mainly composed of those on the *left side only*.

The total number of abnormalities in the 102 subjects is 981, of which 623 are in the 68 males, and 358 in the 34 females. The number found on *both sides* is 623, of which 414 are in the *males* and 209 in the *females*. The number found in the *right side only* is 176, of which 108 are in the *males* and 68 in the *females*. The number found on the *left side only* is 182, of which 101 are in the males and 81 in the females, making a total of 358 *one-sided* specimens.

XVIII. "On an Easy Method of measuring approximately the Intensity of Total Daylight." By ROGER J. WRIGHT, Esq. Communicated by Professor STOKES, Sec. R.S. Received May 21, 1868.

AN easy method by which the amount of light may be at any time measured and registered appears to be still wanting. I would suggest the following plan, by which I believe the desired object may be attained.

A B is a rod of solid metal, terminated by a heavy base, which keeps the rod in a perpendicular position. C D is a hollow tube, blackened inside, of such a diameter as exactly to fit and slide over A B. The extremity, B, of the rod A B is painted of a snowy white, with a jet-black spot in the centre,



[illegible]



Fig. 1 (Subject No. 3).

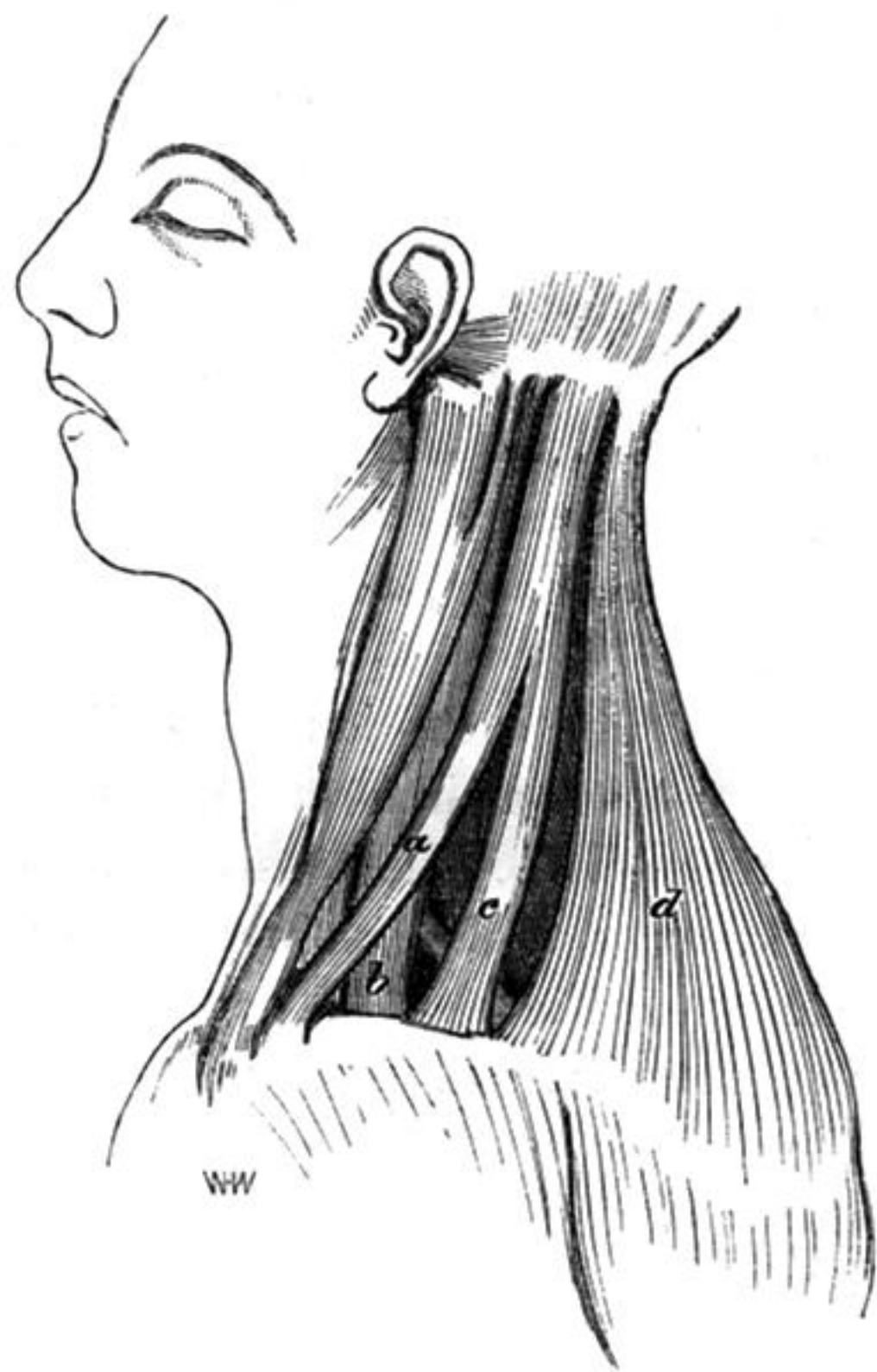


Fig. 2 (Subject No. 2).

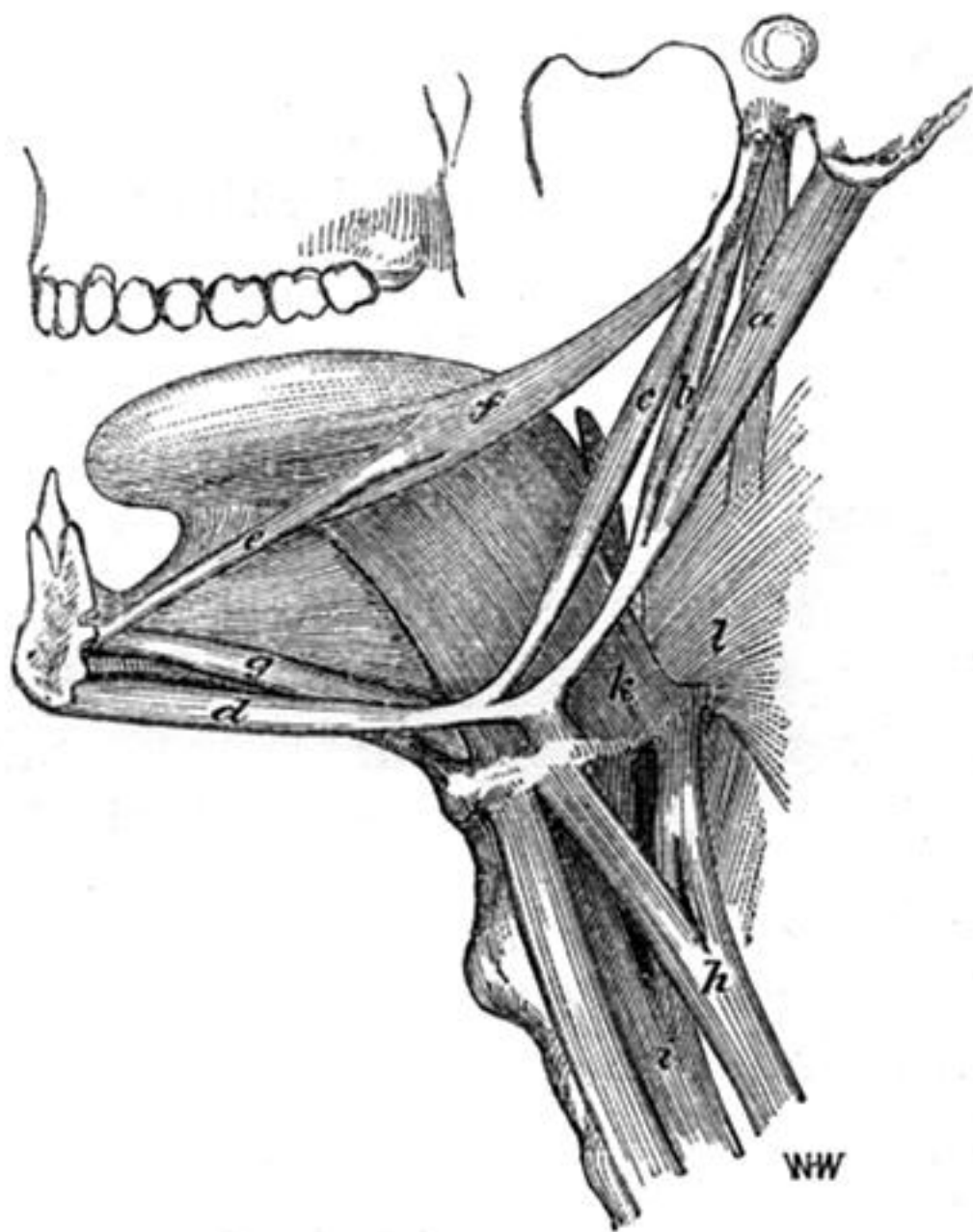


Fig. 3 (Subject No. 20).

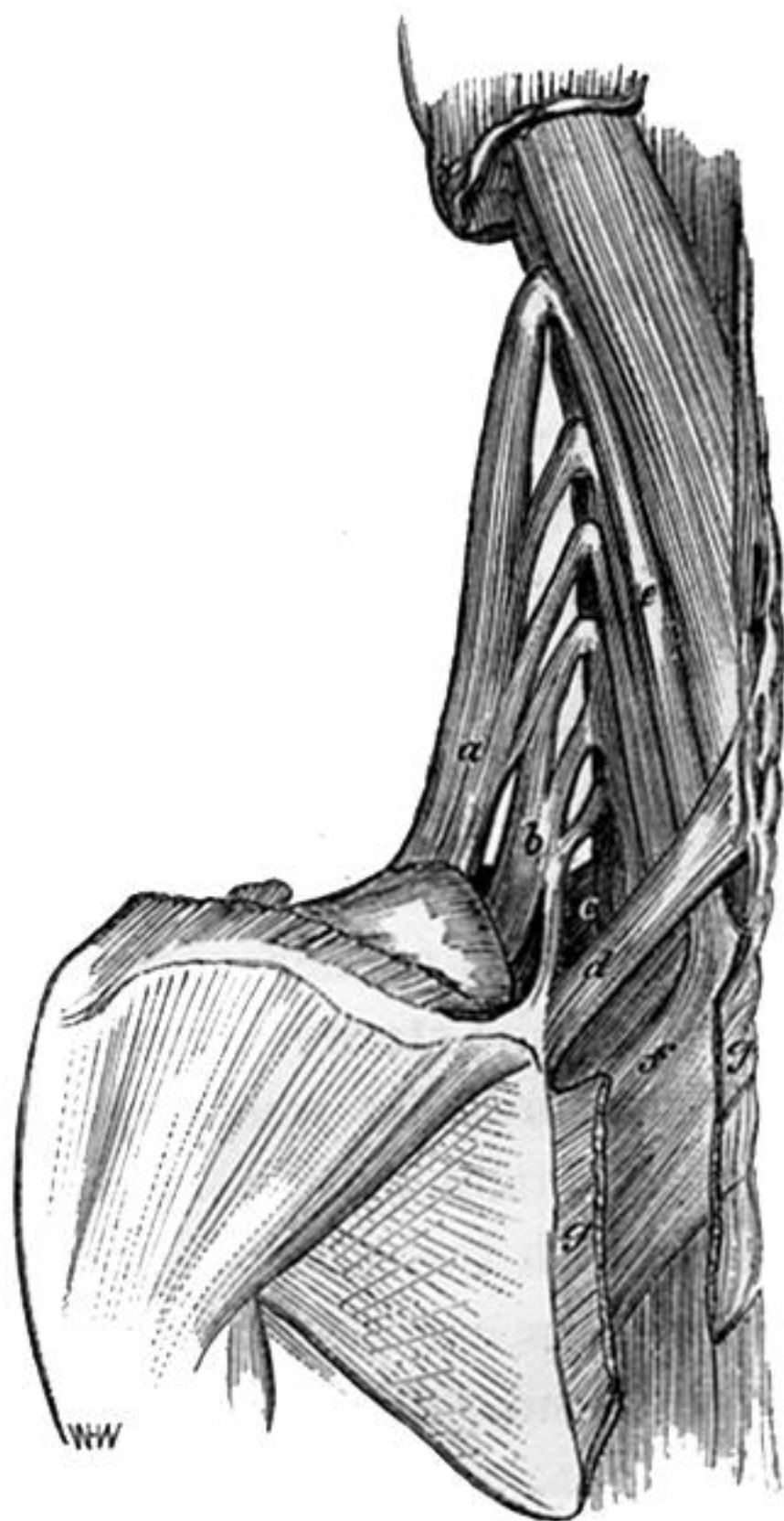


Fig. 4 (Subject No. 10).

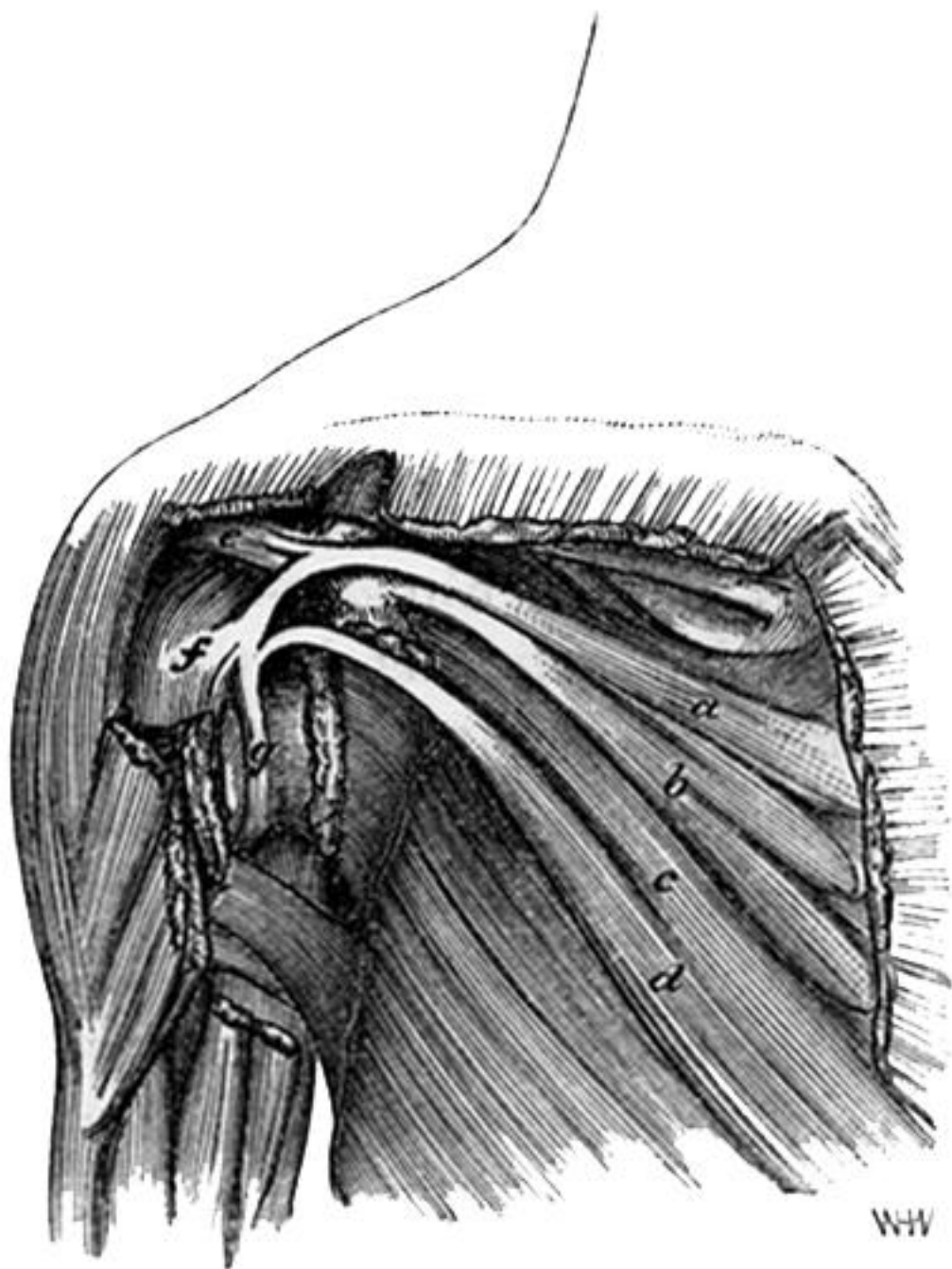


Fig. 5  
(Subject No. 10).

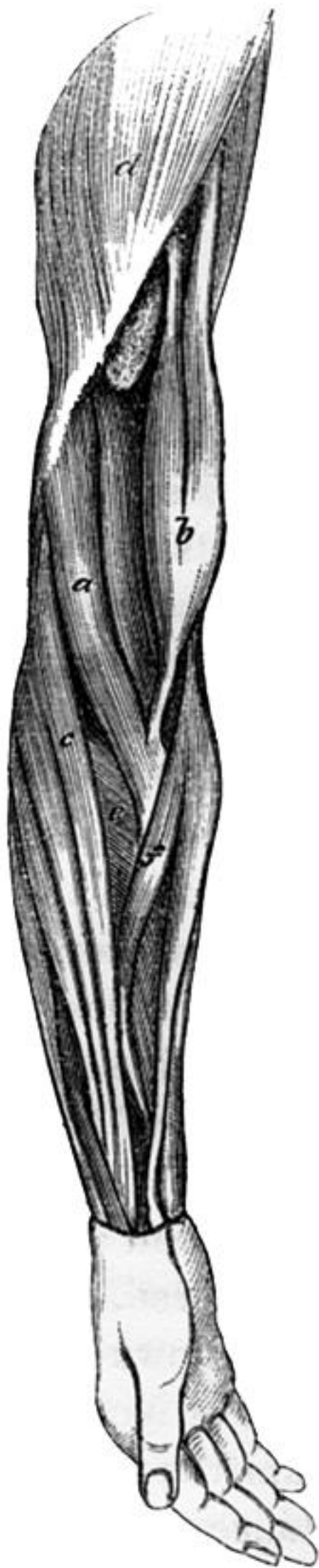

Fig. 6  
(Subject No. 4).



Fig. 7  
(Subject No. 27.)

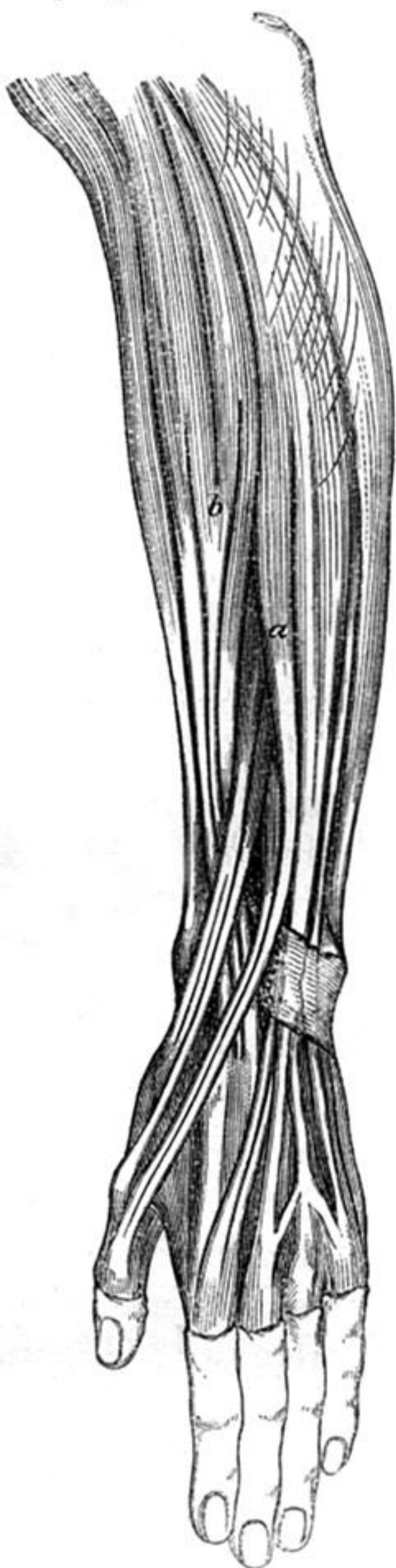



Fig. 8 (Subject No. 33).

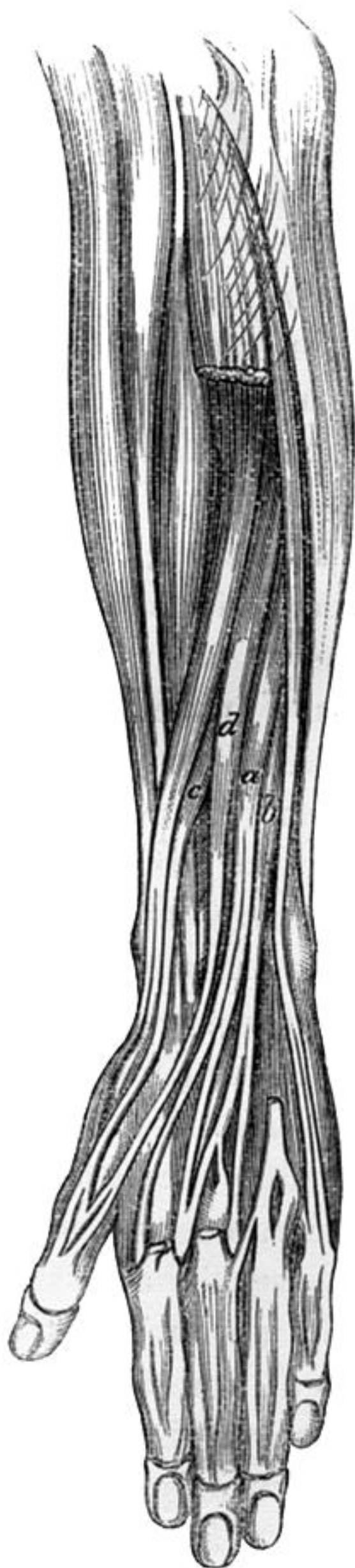


Fig. 9 (Subject No. 7).




Fig. 10 (Subject No. 11).

