

this group, appears, under artificial conditions, unable when expelled from its burrow to re-establish itself in a new home. It is, therefore, interesting to enquire what influence evokes the reconstruction of the abdominal segments, alike whether the fragment be confined within its tube or free as in a watch-glass.

On the Cytology of Malignant Growths.

By J. BRETTLAND FARMER, F.R.S., J. E. S. MOORE, A.R.C.S., and
C. E. WALKER.

(Received November 17,—Read December 7, 1905.)

[PLATES 8—12.]

In the winter of 1903 we presented to the Royal Society a preliminary account of the results of our investigations on the cytology of malignant or cancerous growths, in which we stated that we had recognised a certain type of nuclear division, known as the heterotype, to occur in the cells of these pathological tissues. Hitherto, this peculiar kind of mitosis, characterised *by a reduction to one-half of the normal number of the somatic chromosomes*, together with highly characteristic forms of their bodies themselves, had only been known to occur in connection with the so-called reduction division, that, in animals, immediately precedes the formation of the sexual elements. These reduction divisions constitute a well-known phase in the life cycle of all higher animals and plants, consisting invariably of two consecutive stages, which are distinguished as heterotype and homotype mitoses respectively. As these two mitoses constitute so well-defined a stage in the cellular life history of the higher organisms, we have proposed to emphasise this fact by the introduction of the term “maiosis,” designating the stage itself as the maiotic phase. Thus the heterotype and homotype mitosis form respectively the first and second maiotic division.

We propose, in the present paper, to deal more fully with the cytological details of malignant growths, in so far as we have been able to investigate them, and we shall endeavour briefly to point out the conclusions that we think may legitimately be drawn from them. In doing this we desire, as far as possible, to confine ourselves to a consideration of the evidence we have been able personally to obtain, and we propose to avoid a general discussion of the numerous theories as to the ætiology of the disease, and especially of those that are based on clinical experience, except in so far as our own

observations seem to throw light on those matters. We are fully aware that in pursuing such a course, we lay ourselves open to the charge of incompleteness, and of unduly neglecting the views of others. But an attempt to deal at all adequately with the vast literature that has grown up around the subject of cancer would involve a very lengthy, and probably not a correspondingly fruitful, discussion.

We further propose to confine ourselves to a consideration of carcinomata, and we do not intend to deal with sarcomata at this juncture, since we have enjoyed far fewer opportunities of examining growths of this class with anything approaching to completeness. On the other hand, we have been fortunate in securing a large number of carcinomata of very different ages, for which we are indebted to the kindness of several London Surgeons and others. We also desire especially to acknowledge our indebtedness to the Committee of the Imperial Cancer Research Fund for a grant in aid of our investigations.

We have been able to study extremely early stages in cases of cancers of the rectum, scrotum, penis, lip and tongue. A similarity in all essential features was plainly apparent in the history of the cellular evolution of each of these growths respectively. It will, therefore, be sufficient for the purpose of this paper, and it will also conduce to brevity, if we continue our account, especially to one of them, merely premising that it represents a type to which the rest really conform in all essential details of interest in the present connection. We will, therefore, select as our chief example a very early case of rectal epithelioma. This was not only a very young, but also a very actively proliferating growth, and it was preserved immediately after excision (see Plate 8, fig. 1. This is also to be compared with Plate 9, fig. 2, which illustrates a young growth of epithelioma of the penis).

For the sake of clearness it will be useful to give a short preliminary description of the mucous and subjacent layers of a healthy rectum as they appear under high magnification. The boundary of the lumen of the gut is composed of a large celled columnar epithelium, the elements of which are generally set one row deep upon the basement membrane. The latter is formed from the connective tissue and other elements of the submucous layer. All over the interior surface of the intestine the mucous epithelium is produced outwards into folds that bound correspondingly finger-like cavities, the latter forming the so-called crypts of Lieberkühn. As seen during ordinary states of activity, the epithelium is composed of elongated cells, each consisting of a mass of granular protoplasm in which a large nucleus is situated. The position of the latter in the cell is subject to individual variations. Amongst these resting cells are others in which the cytoplasm

contains masses of secretion, and these constitute elements commonly known as goblet cells. In between the cells of such a rectal epithelium are always to be seen a few wandering elements which are apparently migrating from the submucous into the mucous layer and *vice versa*. Their number is, however, very limited, and they either resemble the white corpuscles of the blood, or their nuclei exhibit a lobed appearance which seems to represent a stage of fragmentation.

In the processes of the submucous layer which interdigitate with the crypts, we find, in the first place, a kind of framework or loose scaffolding of intestinal connective tissue, between the strands and sheets of which can be seen the loops of the anastomosing rectal arteries and veins. Within and without this region, but especially in the centre of the projections of the submucosa, vast numbers of lymph bodies are always conspicuous, the central mass or core of the latter marking the termination of the irregular lymph sinuses and vessels (fig. 1, *h*).

Amongst the columnar cells of the mucous layer during states of ordinary activity we occasionally encounter nuclei in various stages of ordinary mitosis. More rarely nuclei in process of fragmentation or amitosis may be seen. Neither kind of division is frequent, and the tissue seems to be merely regenerating itself by the replacement of individual cells as fast as these disappear. Amongst the leucocytes and lymph bodies, as well as occasionally amongst the connective tissue corpuscles, division is also plainly to be discerned. The nuclei of the connective tissue elements divide mitotically, whilst in the leucocytes we meet both with true mitosis and with those peculiar forms of leucocytic fragmentation that have already been described and figured by other writers, and are generally well recognised. Wherever we light upon true mitotic figures, whether in the mucous cells, in the connective tissue elements, or in the lymph bodies, the phases of division invariably agree with the type of mitosis characteristic of the non-reproductive portions of the body. They are typically somatic or premitotic.* In every mitosis of this nature the chromosomes emerge from the resting nucleus in the form of elongated or bent rods, and in the ordinary premitotic number (32).

During the stage of the equatorial plate each of them is easily seen to be longitudinally split, the two halves passing respectively to the opposite poles of the spindle to contribute to the formation of the two daughter nuclei. Under ordinary conditions the above cytological conditions and appearances remain unchanged in the rectum.

* See Farmer and Moore, "On the Mitotic Phase (Reduction Divisions) in Animals and Plants," 'Quart. Journ. Micr. Sci.,' vol. 48.

Having completed that foregoing brief survey of the structures and changes that occur in the cells of a healthy rectum, we are in a position to consider the features that arise on the early development of a cancer in this region. In the case of the neoplasm we are especially concerned with, the area involved was very small, barely a centimetre in diameter, and this area marks the original seat of the disease. The central portions were but slightly ulcerated or broken down, whilst the margins were hardly at all raised. The essential details of the structure as shown near the edge of the growth are figured in fig. 1.

Towards the periphery of the growth the columnar cells are scarcely displaced, but they exhibit a more or less altered appearance when compared with the still healthy cells in their vicinity. There can, in fact, be traced a narrow and not very sharp line of demarcation that distinguishes the cancerous from the non-cancerous epithelial elements. A consideration of the structure of the cells in this region makes it perfectly clear that the growth has not proceeded from a more remote centre to invade the healthy mucosa, but that the cells of this layer are themselves assuming the peculiar characters of the growth. In other words we are confronted with a primary transmutation of normal and functional cells into those of cancerous tissue. The tumour was small and flat, the change visible at its margin having presumably proceeded centrifugally over the more developed central area.

Thus the growth, regarded as a whole, must be considered as having originated from a relatively large number of functional epithelial cells by a direct conversion of them into neoplastic elements. No other interpretation seems reconcilable with the facts of the case, but we may defer the theoretical conclusion involved therein for subsequent consideration.

But, notwithstanding the evidence for the marginal spread of the growth by a direct alteration of the cells in this region, when once the change has been effected in them, the cancerous cells begin on their own account to invade the deeper layers of tissue situated beneath the epithelium. This is illustrated by fig. 1, *g*. The general nature of the process of invasion is so well known as to call for no specially detailed description here. It will be noted, however, as shown in the illustration, that the ingrowing cancerous tissue long retains many of the features characteristic of the particular epithelium from which it has sprung. This is, of course, not uncommon, especially in the case of glandular tumours (fig. 1, *b*).

The marginal zone of demarcation between the diseased and healthy tissue is distinguished at its periphery by a barely perceptible increase in the size of the elements that compose it. Immediately within this outermost limit a rapid multiplication of the cells is seen to be taking place, and even in the

second or third cell from inside the margin the altered character is easily recognised (fig. 1, *b*). The cells exhibit an increase in cytoplasm, a comparative absence of secretory activity, and a peculiar and well-defined change in the appearance of the nucleolus. The alteration in this last-named structure consists in its larger size and denser appearance. Furthermore, very many nuclei are to be seen in a state of active division. Whilst some exhibit various stages of mitosis, others are clearly undergoing fragmentation or amitosis.

At this stage of the development of the tumour, the peripheral cells that are dividing mitotically show all the characters of ordinary premitotic divisions, and the normal number (32) of chromosomes can frequently be counted with certainty (figs. 5 and 10). But concomitantly with the first changes indicated in the epithelial cells at the edge of the neoplasm, a marked activity may be observed to take place on the part of the leucocytes. These bodies are seen to be in a condition of active migration and multiplication, much like that which occurs during the early stages of simple inflammation. In the subsequent stages, however, the early parallelism with inflammatory processes is lost, and there supervenes a remarkable phase in the further development of the cancerous cells. Not only do the cells of the tissue in question multiply with great rapidity, whilst the leucocytes amongst them are enormously increased in number, but the latter are seen not infrequently to force their way into the cancer cells, particularly in the so-called "giant cells," where, however, they are still to be recognised with ease and certainty (figs. 1, *x*, *d*, 11, 12, 13). This circumstance has already been noticed by others, but we have been led to attach a somewhat special importance to its occurrence. Some writers have suggested that the cancer cells are acting phagocytically upon the leucocytes, but, as a matter of fact, the further sequence of events indicates that the cancer cells are no more to be regarded as attacking the leucocytes than the latter as destroying the cancer cells. There can be no possible doubt that the leucocytes actively force their way into the elements in question. They may not seldom be observed to be in close juxtaposition with these, or in a hollowed depression, or finally they may be discovered just within the cell membrane, where they are easily recognised on account of their characteristic nuclei (fig. 11). They show no sign of disintegration—at least, in the great majority of cases—and the fact that they may persist for a considerable time without destroying the cell into which they have invaded, is proved by examples in which a leucocyte lying in the cancer cell is seen to be surrounded by several nuclei that have clearly originated by the fragmentation of the original cell nucleus, and, indeed, one of these is shown to be still dividing amitotically.

But the strongest proof of the persistence of the leucocyte under these remarkable conditions is afforded by the cases, not few in number, in which we have been able to trace the leucocyte actually dividing within the cancer cell (figs. 12, 13). Of course, it is only during the early stages that it is possible to be certain that a second dividing nucleus in a mass of protoplasm belongs to a leucocyte, and does not represent mitosis in a small nucleus that has arisen by fragmentation. But we have seen so many cases of early stages of leucocytic mitosis within the cancerous (or "precancerous") cell that it seems impossible to resist the inference that many of those frequently occurring cases in which a small nucleus is seen in the later phases of mitosis within the large nucleated cancer cell are to be attributed to this source. The nuclei of the cancer cell and leucocyte often divide simultaneously, and the two nuclear figures may also coalesce more or less intimately, and thus a commingling of leucocytic and epithelial chromosomes occurs on a spindle that becomes common to the two nuclei concerned. The cells so affected were, as already stated, usually the very large (giant) cells so characteristic at this stage of the development of the tumour, and we found that more than one leucocyte might enter and persist in a single cancer cell. In the earlier stages, of course, there is no difficulty in clearly recognising the intruding cell, since it retains its own cytoplasm and limiting membrane intact (see fig. 11), and the highly characteristic structure of the nucleus enables it to be identified even after these criteria have ceased to exist.

In the same region in which this series of events is proceeding a number of cancer cells are to be seen in various phases of mitosis, and, both in the aster and diaster of such nuclei, larger numbers of chromosomes were often encountered than are proper to normal somatic cells. These increased numbers are partly to be ascribed to the pluripolar mitosis distinguished by Hertwig and by Von Hansemann, and they result from the simultaneous mitosis of a number of nuclei lying in a common cytoplasmic mass.

But the observations recorded above indicate that, in the addition of leucocytic nuclei to those of the actual epithelial cells, we have confronted, at any rate, with one of the sources to which these excessive numbers of chromosomes (hyperchromatic nuclei of Von Hansemann) may be attributed, although a large number of the cells continue to multiply in the manner already described, it may also be seen that there exists a very considerable amount of amitosis, or direct nuclear divisions in the cells of the young parts of the tumour. There appears to be no evidence which would point to the conclusion that amitosis is in any way bound up with degeneration, or diminishing activity in those cells in which it occurs. Elements that have previously multiplied by amitosis and by fragmentation have given rise to

the highly characteristic multinucleate cells, may again assume the mitotic method of increase, and *vice versa*. A curious feature in the further division of these multinucleate cells, or syncytia as they may, perhaps, be more appropriately termed, is seen in the almost invariable circumstance that, on the resumption of mitotic activity, all the nuclei are in exactly the same phase.

This simultaneous character of the process is one which is shared by many other syncytia, *e.g.*, the myxomycetes. In these organisms, the nuclei are commonly observed not only to be dividing simultaneously over a considerable area of the plasmodium, but they also exhibit identical phases of the process at any given time. In examples of this simultaneous mitosis within the neoplastic syncytia, it often happens that the spindles of some, or even all of the dividing nuclei, become more or less intimately fused together, and in this way various forms of pluripolar mitosis are produced. Probably these pluripolar divisions owe their origin chiefly to the cause just indicated.

The figures produced are extremely variable, and it not unfrequently happens that, whilst the chromosomes belonging to the different nuclei are aggregated in the centre, the poles of three or more of the spindles involved are quite separate. In other examples the groups of chromosomes do not coalesce, but each equatorial plate is quite distinct, and lies in a plane different from that occupied by the equatorial plates of the other spindles. But when a more intimate fusion of the ends of two or more spindles takes place, it is obvious that the daughter nucleus formed in relation to such unions will receive an excessive number of chromosomes.

We would call special attention to the fact that giant cells of this character, also containing several nuclei, are present not only in the normal human testis, but also in the so-called red bone marrow, and that pluripolar mitosis may occur in such cells in a manner precisely similar to that so characteristic of cancerous tissue. The divisions of these early cancerous cells also exhibit other characters likewise encountered in the cells of the testis. Very often the daughter chromosomes do not move regularly towards the poles, but some either stray out of the direct line, or in other ways occupy unusual positions. These figures are also well known to occur in the heterotype division of some spore mother-cells of plants. In yet other examples of divisions in cancerous tissues, we have confirmed the observation of Von Hansemann that some of the chromosomes, as they are passing to the spindle poles, get ahead of their fellows, and form isolated or grouped chromatic particles that look as if they are about to be left out in the cytoplasm when the daughter nuclei become reconstituted. These figures

are also paralleled by similar occurrences that may be seen in the cells of the testis, and they are known to occur during the meiotic divisions of some plants.

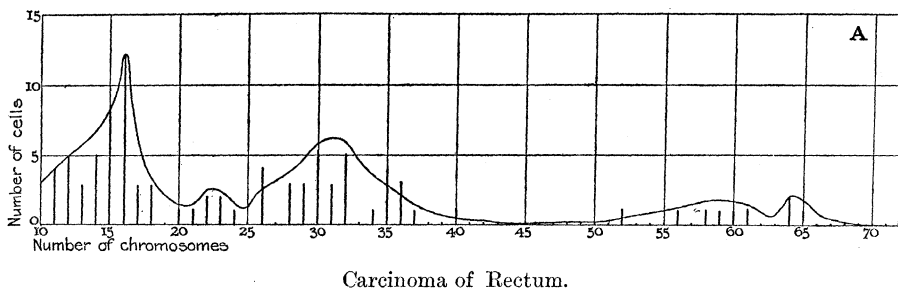
It is thus evident that hyperchromatic nuclei, that is, nuclei containing an excessive number of chromosomes, may be produced in at least two ways: firstly, by the inclusion of leucocytes, and the incorporation of the chromosomes belonging to these bodies with those of the cancer cells when mitosis sets in; secondly, through the formation, whether by amitosis or mitosis, of multinucleate syncytia, and by the subsequent confusion and mixing of the chromosomes originally belonging to two or more of the nuclei when the equatorial plate stage is reached.

These aberrant modes of division are found to proceed concurrently with the normal somatic mitoses that are going on in other cells in their immediate vicinity. It is impossible to say definitely whether there may exist any sort of alternation between the two types, though we are inclined to think that such is not the case. It is, however, important to notice that all the mitoses described above, whether they are normal in the number of chromosomes or not, agree in conforming to the somatic type of division. That is to say, no matter how many or how few the number of chromosomes involved may be, the spireme eventually divides into a number of rod-like elements, each of which splits longitudinally, and the daughter chromosomes resulting from such fusion are severally distributed between the daughter nuclei finally produced. In such typical cases this of course means that each of the two daughter nuclei receives one longitudinal moiety of such original chromosome.

But as we pass inwards from the growing edge of the tumour we encounter cells in which the nuclei exhibit important deviations from the ordinary somatic type of mitosis, and exhibit the characters otherwise met with during the heterotype division (*cf.* figs. 6, 7, 8). In the early stage of the phase of such nuclei the spireme exhibits that characteristic bunched appearance recalling the well-known contraction figure that is normally to be seen at the onset of the meiotic phase, that is in the prophase of the heterotype mitosis, in animals and plants. In addition to this, we have been able to ascertain that at about the same stage the spireme thread exhibits the longitudinal fission (fig. 6) that is highly characteristic, though perhaps not exclusively confined to the prophase of the heterotype division. The fission is especially well seen in those cases in which a marked polarisation of the spireme is apparent. But the most striking evidence of the validity of the comparison that we drew in 1903 between these particular nuclei and those of the reproductive cells during the meiotic phase of the animals and plants does not depend solely on the similar mode of evolution of the chromosomes from the resting nuclei in the "gametoid" cancerous and the true reproductive

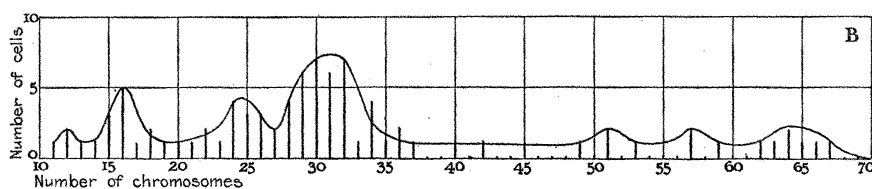
elements. The number of the chromosomes furnishes a far more important criterion. It is seen that a large number of dividing nuclei contains less than the normal complement of chromosomes. We have made a number of careful counts of the chromosomes in numerous cases of carcinoma, and always with the same result. In especial, we are indebted to Mr. L. Robinson for his assistance in this somewhat trying task. He has estimated the chromosomes in 400 dividing nuclei, taken (100 from each) near the actively growing regions of three different carcinomata originating respectively from the rectum, scrotum, penis, and in an example of deciduoma malignum.

In every case we find two well-defined maxima, one set of nuclei containing 32, the other 16, chromosomes. For purposes of comparison he has counted chromosomes of the testis of the cockroach (Curve F), so as to obtain a control indicating the probable degree of accuracy represented by the estimations in the cancer nuclei. The same two maxima are, of course, apparent, but there is a similar average error around the maxima, due to the difficulty of the actual counting, and also the chance that some of the chromosomes might be absent from the section, or that a limited degree of variation may really occur. And, having regard to the fact that in the human species the chromosomes are not easy, even under favourable conditions, to estimate very accurately, whereas in the case of the cockroach the observer encounters far less difficulty in this respect, the results may, we think, be described as satisfactory. For although, after what we have said, it is obvious that, owing to amitosis, and especially to pluripolar mitosis, a considerable extent of variations is to be anticipated, the grouping of the numbers around the maxima of 32 (somatic) and 16 (reduced) is quite unmistakeable, as is shown in the accompanying curves.

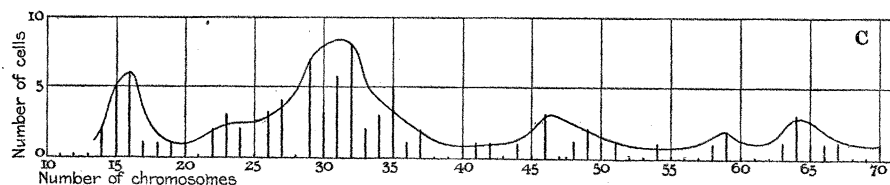


The ordinates represent the number of cells that contained any given number of chromosomes, as indicated by the abscissae.

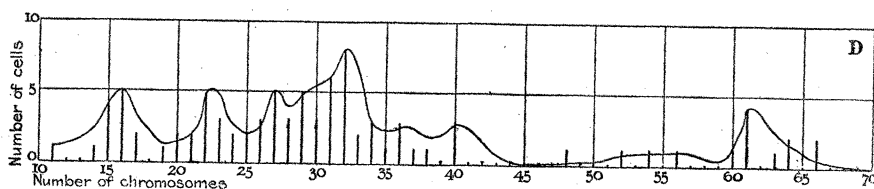
- A. Cancer of the Rectum.—The hypochromatic nuclei to the left somewhat obscure, the maximum at 16. The grouping of numbers about 24 and 64 are fairly well shown.



Epithelioma of the Scrotum.

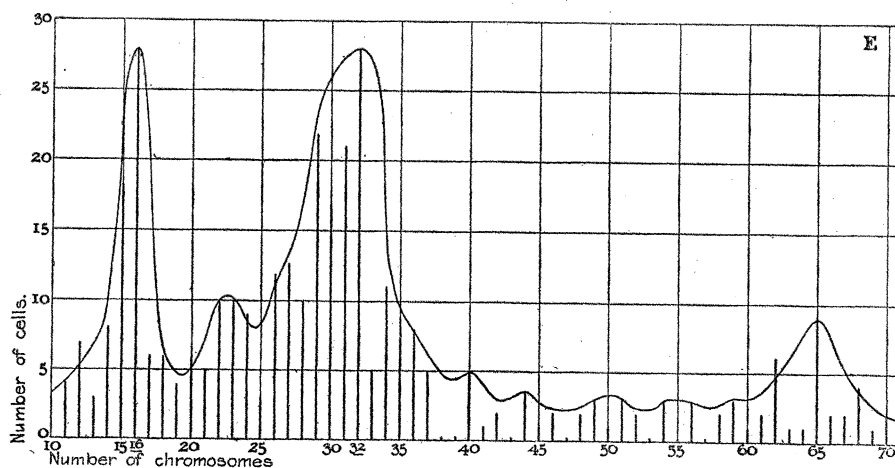


Epithelioma of the Penis.

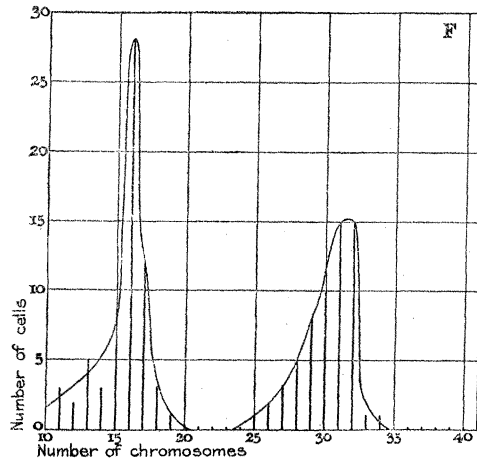


Deciduoma malignum.

- B. Epithelioma of the Scrotum. The maxima about 16, 24, and 32 are distinct, that about 64 not so clear.
- C. Epithelioma of the Penis.—The maxima in the regions of 16, 24, 32, 48, and 64 are all fairly distinct.
- D. Deciduoma malignum.—There is considerable irregularity in the nuclei in this growth, which was somewhat advanced, and deviations are therefore to be anticipated.



- E. Combined Curve drawn from the Results shown in the preceding Four Cases of Cancer, viz., carcinoma of rectum, epithelioma of scrotum and penis, and deciduoma malignum. The three maxima about 16, 32, and 64 are unmistakable.



Testis of *Periplaneta Americana*.

F. Curve obtained by countings made from dividing nuclei of the maiotic and premaiotic cells of the testis, in order to estimate the probable error in the far more difficult cases of cancer. It will be seen that there is some not inconsiderable variation about the two maxima of 16 and 32. This is due partly to underestimating the number of chromosomes actually present, and partly to the nuclei having in some cases been partly damaged in preparing the section.

We shall further consider this matter in the concluding part of the paper: at present we are mainly concerned with showing that there exists a striking resemblance between what we have termed the "gametoid" cells of cancer and the cells of normal reproductive tissues, and as we pass to the later phases of mitosis we find the same loop and barrel-shaped chromosomes present in both, and we have occasionally seen, during the diaster of a cancer nucleus, the late longitudinal fission in the daughter chromosomes as they diverge from each other, just as it occurs in the heterotype diaster of so many animals and plants. An inspection of the curves shows the relative frequency of the different numbers of chromosomes met with in the younger cancerous areas. Whilst, as already pointed out, the two maxima of 16 and 32 are unmistakeable, it is also obvious that amongst the generally irregular numbers two other groups occur with greater frequency than others. Thus, there is a distinct indication that nuclei containing about 24 chromosomes may be regarded as forming a distinct group, also that a second, though far less well-marked, series is characterised by containing about 64 (double the normal somatic number) chromosomes. It may be that the latter are related to the ingression of the leucocyte already described, but it is difficult at present to guess at the significance of the grouping of 24. There is no obvious indication that the nuclei with 48 chromosomes are specially common, and, in the absence of more direct evidence, it is useless to indulge in speculations that may prove to be devoid of all foundations.

In animals, as has already been stated, it invariably happens that, after the onset of the first meiotic (heterotype) mitosis, there ensues only one further nuclear division, commonly designated as the homotype, on account of its close general resemblance with a normal somatic mitosis. The principal point of constant difference lies in the retention in the former of the reduced number of chromosomes. The cells originating from this division give rise after a more or less complex series of changes of form and of the inter-relation of their constituent parts and the sexual cells without any further intervening nuclear divisions. In plants this is not the case. The cells issuing from the homotype mitosis always undergo one or (often) many subsequent divisions before some or all of the resulting units develop into sexual cells. It is therefore of interest to find in cancerous tissue that there is abundant evidence that the cells, the nuclei of which have undergone reduction, are capable of continued division, and, indeed, a great part of the tissue of the cancer is made up of such cells, which, in accordance with the terminology we have elsewhere employed, we may term post-meiotic, or "gametoid."

It will be seen that we differ from Von Hansemann in our explanation of these "hypochromatic" nuclei, regarding them as have arisen, not as the author just named believes, by a dropping-out of chromosomes from the spindle, or through some form of degeneration, but chiefly as the result of a process resembling, or identical with, that by which reduction is ordinarily effected in the tissues destined to give rise to the gametic cells. But we desire to definitely state that, in using the term "gametoid," we expressly differentiate between the cancerous cells and those of normal reproductive tissues. The relation existing between them, if any, is at present obscure; and, though we think the resemblances, which will be still further emphasised by facts we are about to describe, are very suggestive, we are far from holding the views which have been expressly or implicitly ascribed to us by other writers as to the identity of gametic with "gametoid" cells and tissues.

Finally, then, it is clear that there exist in the facts of pluripolar mitosis, on the one hand, and in amitosis on the other, a mechanism sufficient to explain all the irregular numbers encountered in a young cancer. But the irregularities, while masking, cannot conceal the far more frequently recurring numbers of chromosomes, whereby the reduced (halved) and, though far less frequently, the double, numbers become apparent. But the existence of the irregularities indicated above often renders extremely difficult the task of deciding to what category a particular departure from the normal somatic number is to be relegated.

There is a further body of evidence bearing on the resemblance between

cancerous and normal reproductive tissue to be derived from a study of the so-called Plimmer's bodies of cancer.*

It was shown by one of us in 1895† that, during the prophase of the first maiotic (heterotype) division of the spermatogenetic cells of mammals, the archoplasm undergoes a peculiar and definite series of metamorphoses. In ordinary somatic or premaiiotic cells, this body is seen to lie beside the nucleus as a dusky mass of protoplasm, in the centre of which are found the centrosomes. Thus, in these cells, the attraction sphere consists of the archoplasm *plus* the centrosomes (fig. 3, *b*, fig. 4, *a*).

When, however, we turn from the premaiiotic or the somatic cells to the prophase of the heterotype (first maiotic) mitosis, we find these two constituents have become separated (fig. 4, *b*). The centrosomes migrate from the centre of the archoplasm, and are eventually seen to lie outside that body, and completely detached from it (fig. 4, *c*). At the same time the archoplasm itself undergoes a change, small vesicles are developed in its substance (fig. 14), and, at the close of this particular cell-generation, both vesicles and archoplasm become merged and lost in the general cytoplasm of the daughter cells.

In the prophase of the second maiotic (homotype) mitosis the same peculiar phenomena recur, and the archoplasm and the vesicles, in like manner, become lost during the later stages of this (homotype) division. In the spermatids, which result from it, the persistent centrosomes can be readily seen to be perfectly disconnected with the new archoplasm which is differentiated in these cells. The archoplasm becomes filled with minute vesicles, as in the two preceding cases, subsequently the vesicles enlarge, and they either fuse together, as in some mammals, or one usually takes the lead and grows larger than the rest, as commonly happens in the guinea-pig and in man (fig. 15). The body thus formed was originally termed the archoplasmic vesicle in 1895‡ and it is a very conspicuous and constant feature peculiar to the sperm cells of the vertebrata, whilst it has also been encountered by various observers in animals outside that group.

When fully developed, the archoplasmic vesicle often assumes a size approximating to that of the nucleus itself, the latter being often deformed into a crescentic shape, owing to the enlargement of the vesicle that lies adjacent to it in the cell. In normal spermatids, the vesicle and its contents ultimately form the so-called "cephalic cap" of the spermatozoon (fig. 16, *a*).

* See 'Roy. Soc. Proc.,' vol. 76 B, "On the Resemblances existing between the 'Plimmer's Bodies' of Malignant Growths and certain Normal Constituents of Reproductive Cells of Animals," by J. Bretland Farmer, J. E. S. Moore, and C. E. Walker.

† Moore, 'Internat. Monatschr. f. Anat. u. Physiol.,' 1894.

‡ Moore, *loc. cit.*

Now, the "Plimmer's bodies" are well known in the cells of many cancerous growths (fig. 17), and they are most commonly met with in the young growing portions of the tumour. They appear in the form of vesicles, and consist eventually of a fairly well-defined wall, enclosing a clear space, in which is suspended a small and densely refracting granule. They appear to occur with greater frequency in cancers of a glandular or glandular-epithelial origin.*

They lie in the cytoplasm of the cancer cells, usually in close proximity to the nucleus. They vary in size from excessively minute bodies to forms as large as the nucleus itself. The special interest attaching to the Plimmer's bodies depends on the fact that they have commonly been regarded as peculiar to cancer cells, although Honda† believes that he has occasionally encountered them in inflammatory tissue. They have, in fact, been variously interpreted. Some investigators have regarded them as parasitic organisms, more or less intimately connected with the ætiology of the disease, whilst others have seen in them a differentiation of the cancerous cell itself. Borrel‡ suggested that they might represent hypertrophied centrosomes, but the observations of Benda,§ who showed that centrosomes and Plimmer's bodies coexisted in the same cell, have rightly been held to disprove the view advanced by Borrel.

When the foregoing facts are all taken into consideration, the case originally upheld by ourselves|| appears to be a strong one. We see no escape from the position that the Plimmer's bodies of cancer represent the archoplasmic vesicles that occur in the normal reproductive cells at the stages already indicated. And this forms an important link in the chain of similarities connecting cancerous tissue with the normal reproductive elements. But in this relation it is of interest to note that we have recently observed bodies, which appear to be closely similar to archoplasmic vesicles, to occur at apparently definite stages in the life history of certain leucocytes which are present in bone marrow.

General Conclusions.

To sum up the observations already recorded in this paper, it may be seen :—

* Greenough, 'Third Report of the Caroline Brewer Croft Cancer Com.,' Harv. Med. School, 1905.

† Honda, 'Virch. Arch.,' vol. 174.

‡ Borrel, 'Ann. Inst. Past.,' vol. 15.

§ Benda, 'Verh. deutsch. Gesellsch. f. Chir.,' 1902.

|| 'Roy. Soc. Proc.,' vol. 76 B, pp. 230 *et seq.*

1. That a primary growth originates in the first instance as the result of a change in the nature of a number of previously functional somatic cells.

2. That the transformation may affect a considerable number of cells, and certainly continues to operate for some time.

3. That, as the result of the change, mitotic and amitotic activity is awakened, and proceeds rapidly, with a consequent increase in the mass of affected tissue.

4. That during this increase a remarkable activity prevails amongst the leucocytes, at first resembling that seen in inflammatory processes, but finally leading to the union of at any rate some of the affected cells with one or more leucocytes.

5. That in the subsequent divisions of these cells the nucleus of the leucocyte divides simultaneously with that of the cancer cell, and their chromosomes may become mingled in cleavage figure.

6. That multinucleate cells (syncytia) may arise by mitosis or by amitosis, unaccompanied with the division of the mass of protoplasm.

7. That the resulting nuclei may divide normally and mitotically, or the nuclear figures may be more or less mingled, and hence all sorts of variations in the number of chromosomes may occur. But the mode of chromosome evolution and division follows the somatic type.

8. In addition, a form of mitosis occurs, leading to nuclei with half the number of somatic chromosomes, and the phases closely accord with those observed during the heterotype (first maiotic) mitosis of animals and plants.

9. Subsequent divisions occur, in which the reduced number of chromosomes is retained, the type of division otherwise resembling that of ordinary somatic cells. These mitoses fall into the category corresponding with the post-maiotic mitoses of plants.

10. During the maiotic and post-maiotic divisions in the cancerous cells, structures are present which have been designated as Plimmer's bodies. These are common to cancerous cells and to the reproductive cells of the testis at a particular phase in their evolution. The only other cells in which structures resembling the bodies in question have been observed are possibly those forming certain of the leucocytes in bone-marrow.

It will be evident from the above summary that the change from the healthy to a cancerous development is intimately bound up with definite change in the cells affected. The onset of the change is probably to be attributed to the operation either of new stimuli upon the body cells, or to a change in the constitution of the latter. Such an alteration might originate in a variety of ways. For example, it might be ascribed to the influence of a parasite. But we have never succeeded in tracing any such cause, and it

becomes necessary therefore to seek for some other explanation for the phenomena actually witnessed.

It is quite certain, in the first place, that we are dealing with the transformation of functional somatic cells into cancerous ones, and this, to our own minds, affords a complete refutation of the hypothesis as to the persistence of "embryonic rests," such as have been supposed by Cohnheim and his followers to account for the incidence of the disease.

We have drawn attention to the events that occur in connection with the invasion of the cells of the young growths by leucocytes, and, although we are fully aware that further investigations into the details of these processes are required before a final opinion can be expressed as to their true significance, the facts themselves are very suggestive.

Furthermore, the interest attaching to these fusions is not lessened by a study of the bone-marrow, in which the leucocytes can be most advantageously observed. For we have seen in this tissue all the abnormal types of nuclear and cellular division that are so highly characteristic of cancerous cells, and we have ascertained a fact of even greater importance, namely, that some of the nuclei of dividing marrow cells certainly possess less than the full complement (32) of somatic chromosomes. We would, further, lay emphasis on the occurrence, in the same preparations of bone-marrow, of other cells in which the process of mitosis was strictly somatic in character, both as regards the form and number of the chromosomes. But it is none the less certain that the other nuclei exhibit chromosomes of a remarkable form, elongated in the direction of the spindle, and strongly resembling those which are so characteristic of the heterotype mitoses of the testis or of a cancer.

Whilst it is obvious that further investigation on the cytology of bone-marrow is urgently needed, it is evident that, if it should ultimately prove that the cells which are derived from the results of fusion of a leucocyte with a tumour cell really represent the progenitors of the malignant elements themselves, a satisfactory explanation would be afforded not only of the striking nuclear character of the diseased tissues, but also of the invasive and destructive powers they undoubtedly possess. The destructive action of the leucocytes themselves on other cells of the body, especially during old age, is too well known, owing especially to the valuable researches of Metschnikoff, to call for further comment here.

Such a view of the case as is here tentatively suggested is not in conflict with the idea embodied in the term "gametoid" tissue, but rather forms an extension of it. We have, as already pointed out, from the first maintained the existence of a resemblance, extending to extraordinarily minute detail, between the "gametoid," cancerous, and the reproductive tissue,

which, in the case of animals, gives rise to the gametes immediately after meiosis. But it is also now certain that there exist certain striking similarities between the leucocytic and reproductive cells which are, in themselves, highly suggestive, and this is not diminished by a consideration of the earlier phylogenetic history of wandering and reproductive cells in more primitive animals, for example, in sponges.

For the present, however, and in the absence of more complete and accurate knowledge on the evolution of the leucocytes, we may close by remarking that the various peculiar characteristics of cancerous cells find their closest analogies in the cytological processes that are exhibited in the formation of the reproductive cells, and in those meiotic phenomena that so especially distinguish them.

DESCRIPTION OF PLATES.

PLATE 8.

Fig. 1.—Section of the growing edge of a young Carcinoma of the Rectum.

1 *x*, 1 *y*, 1 *z*. Enlarged parts of the same drawing. The letters *c*, *d*, *e*, correspond with those on the main figure.

a. The portion to the right represents the normal structure of the rectum; *b* the zone in which transmutation from healthy to cancerous tissue is proceeding.

c. Cell showing somatic division (see also 1 *x*).

d. Cells in this zone containing leucocytes (see also 1 *x* and 1 *y*).

e. Cell showing prophase of first meiotic (heterotype) mitosis (see also 1 *z*).

f. Cut portion of crypts, but belong to the zone of transformation.

g. Portions of the growth invading the adjacent layers.

PLATE 9.

Fig. 2.—Section through young Epithelioma of the Penis.

2 *x*, 2 *y*, 2 *z*. Enlarged parts of the same drawing. The letters *a*, *b*, *c*, *d*, correspond with those of the main figure.

a. Cells showing somatic (premeiotic) divisions.

b. Cells showing somatic division, but with excessive number of chromosomes.

c. Cell showing first meiotic (heterotype) division.

d. Cell with leucocyte in its cytoplasm.

PLATE 10.

Fig. 3.—Small Portion of the Testis of a Guinea-pig, showing (*a*) premeiotic cell dividing; (*b*) cell in prophase of first meiotic (heterotype) division. In this it will be seen that the centrosomes are at the centre of the archoplasm.

Fig. 4.—Portion of the Testis of a Guinea-pig, showing (*a*) cells with the synaptic contraction, and the normal condition of the attraction sphere; (*b*) late stage in the prophase of the first meiotic division, showing the centrosomes detached from the archoplasm; (*c*) homotype prophases showing. The same dismembered condition of the attraction spheres.

Fig. 5.—Cell from the early Cancer of the Rectum given in fig. 1, showing the somatic character of division. Compare with fig. 3, *a*.

Fig. 6.—Cell from Cancer of Rectum given in fig. 1, showing the characters of the prophase of the heterotype division. Compare with fig. 4, *a*.

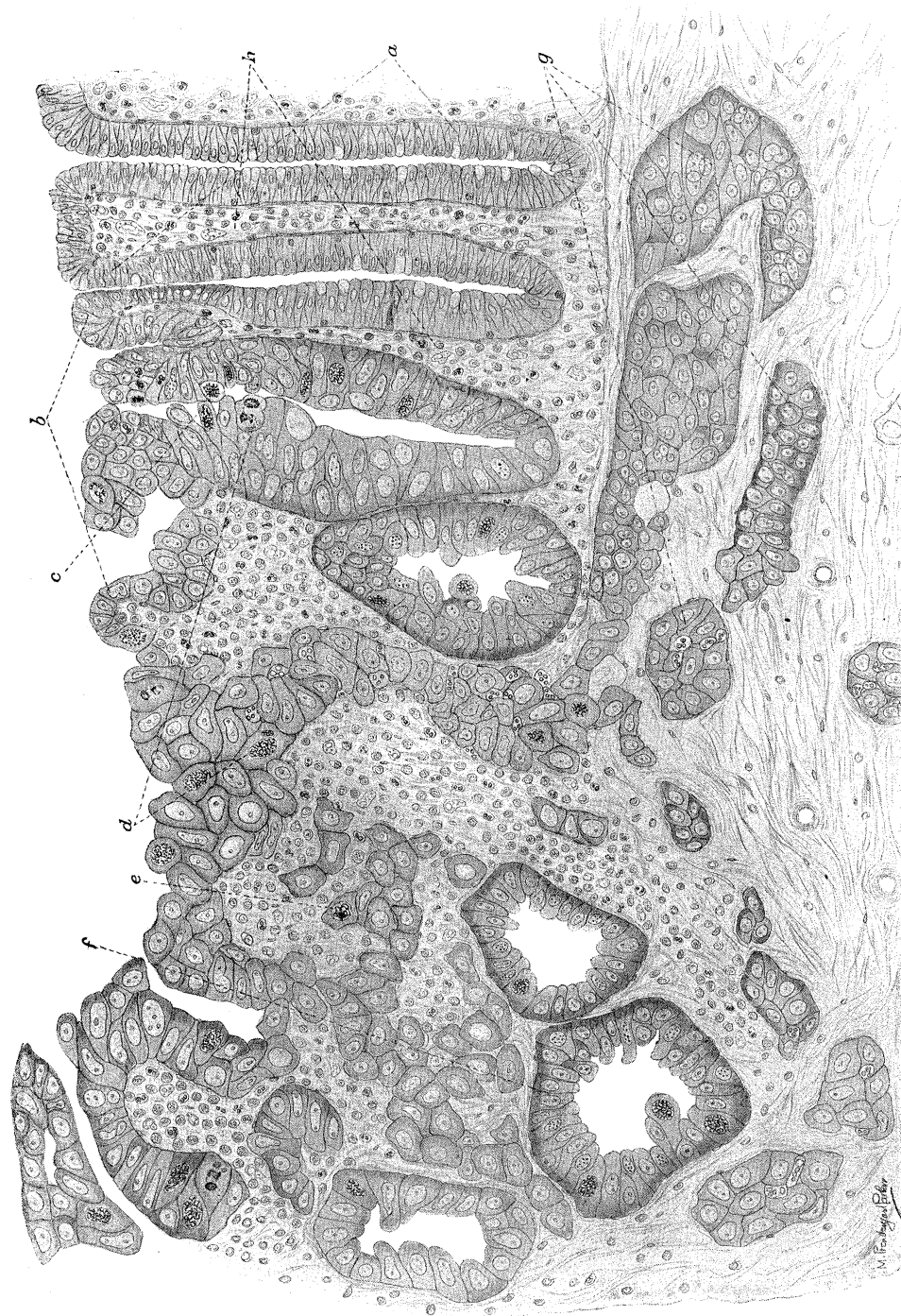
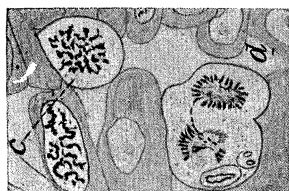
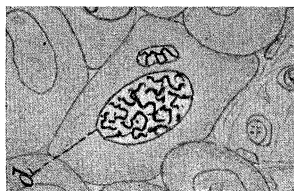


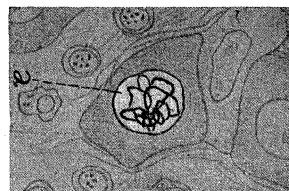
FIG. 1.



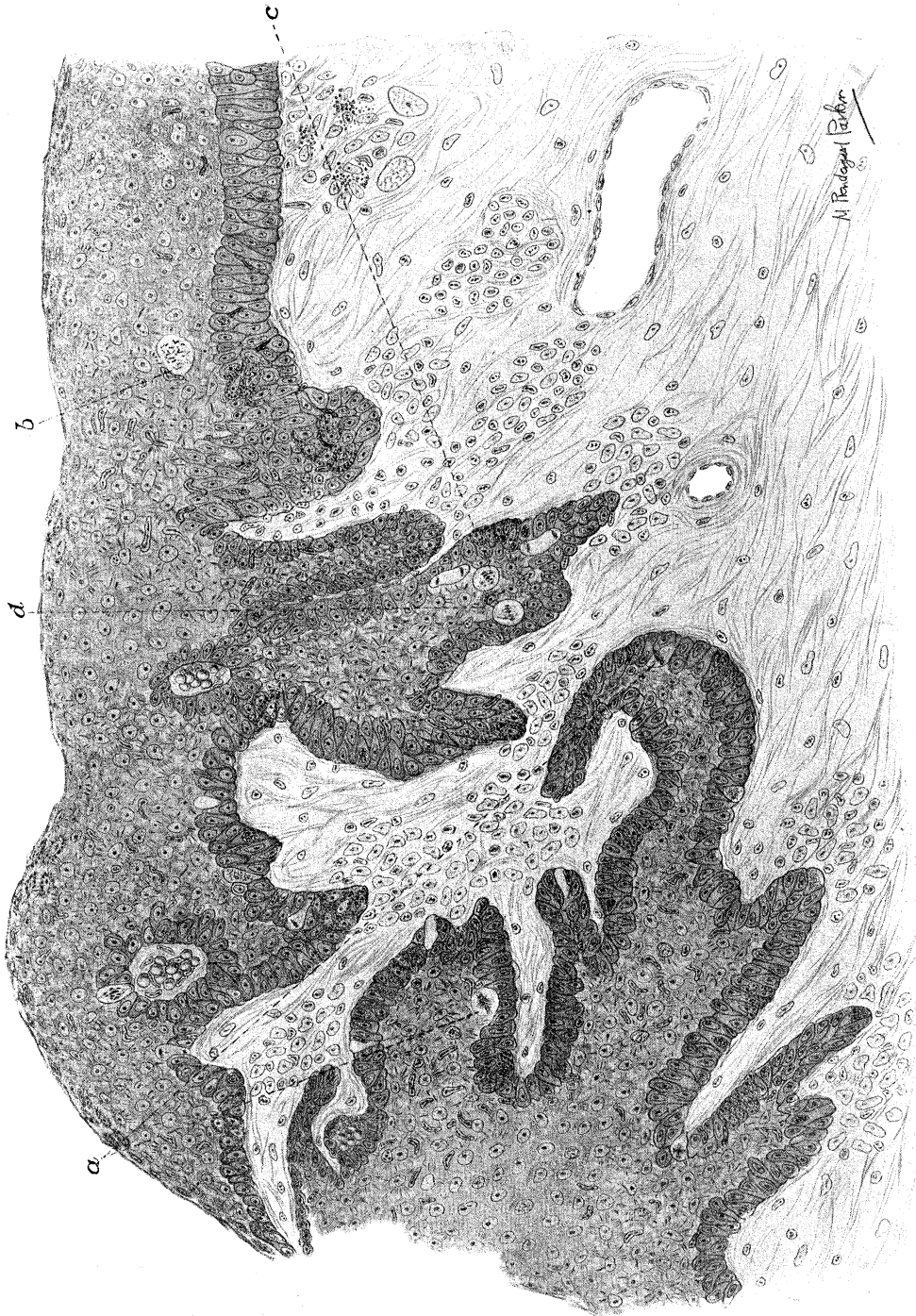
1x.



1y.

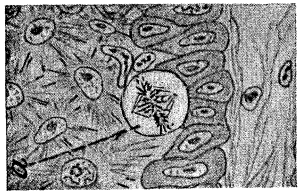


1z.

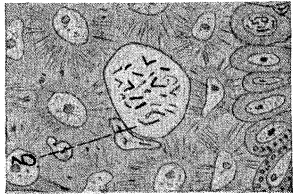


N. R. Parker

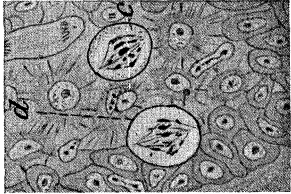
FIG. 2.



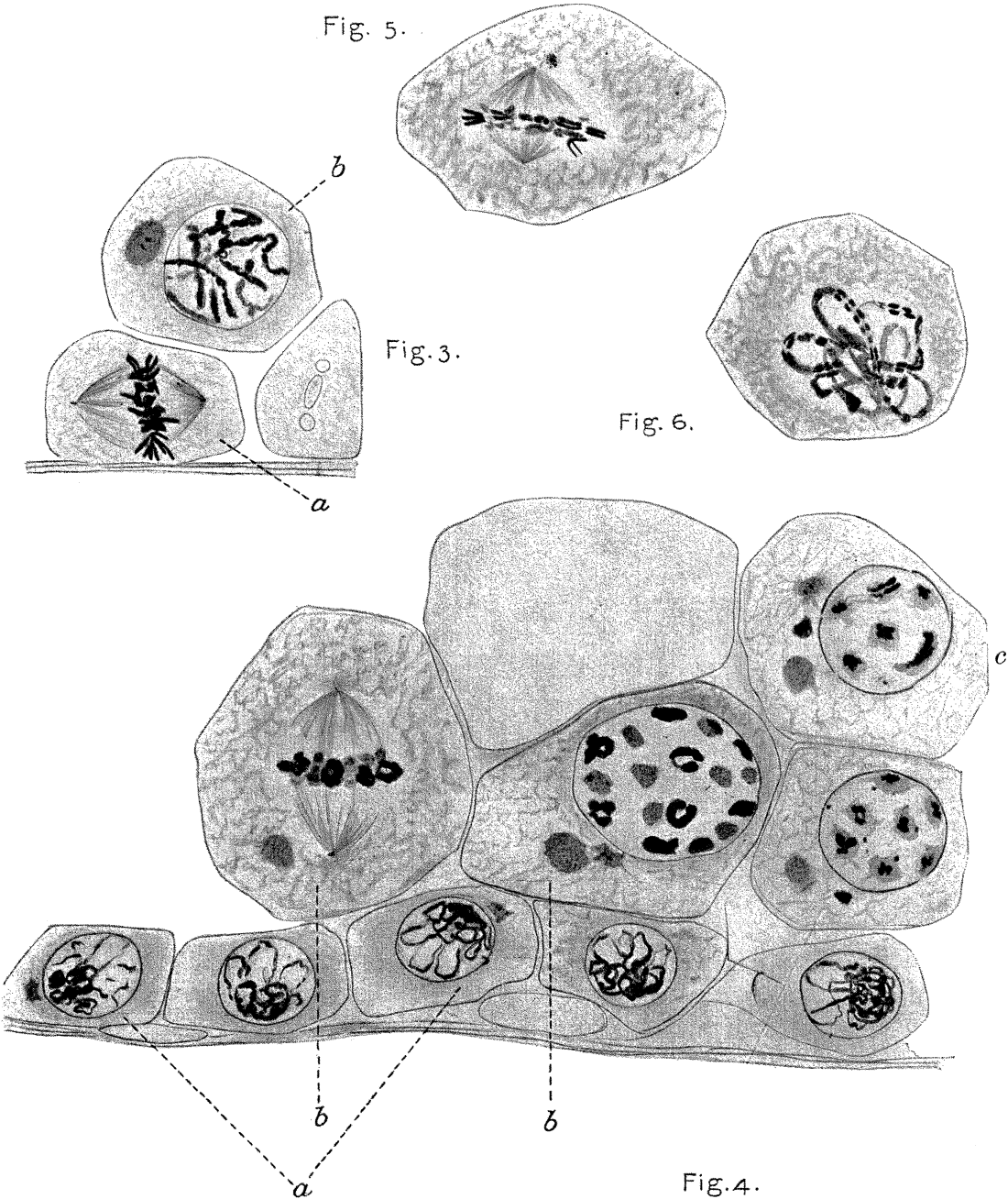
2x.



2 1/2x.



2x.



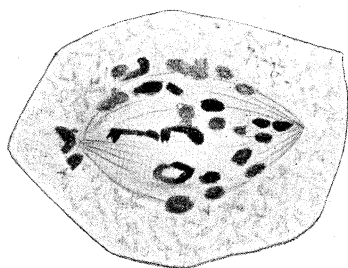


Fig. 7.

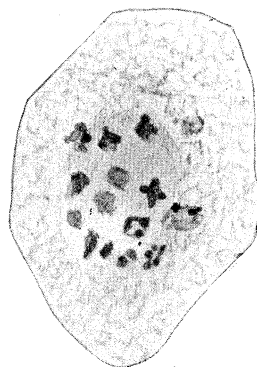


Fig. 8.

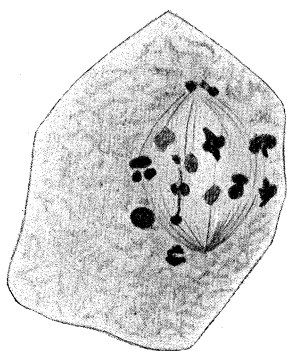


Fig. 9.

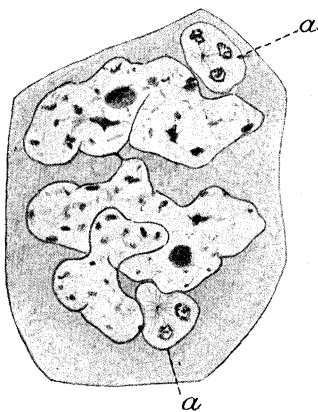


Fig. 11.

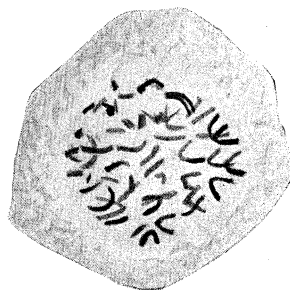


Fig. 10.

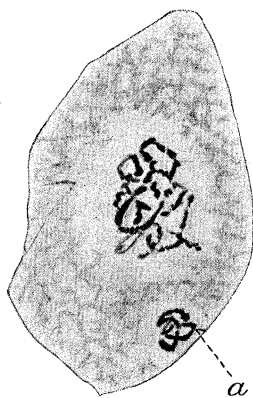


Fig. 12.

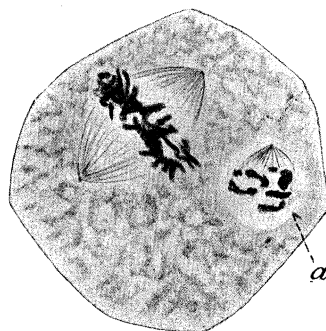


Fig. 13.

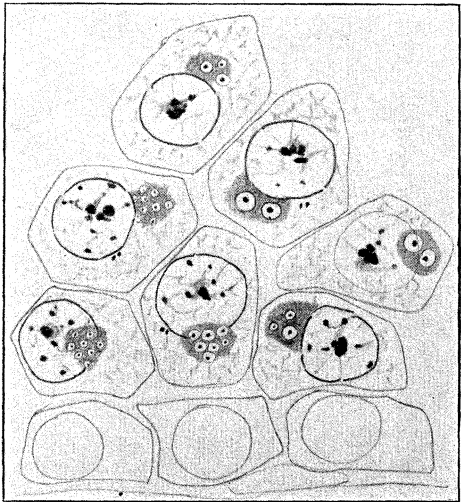


Fig. 14.

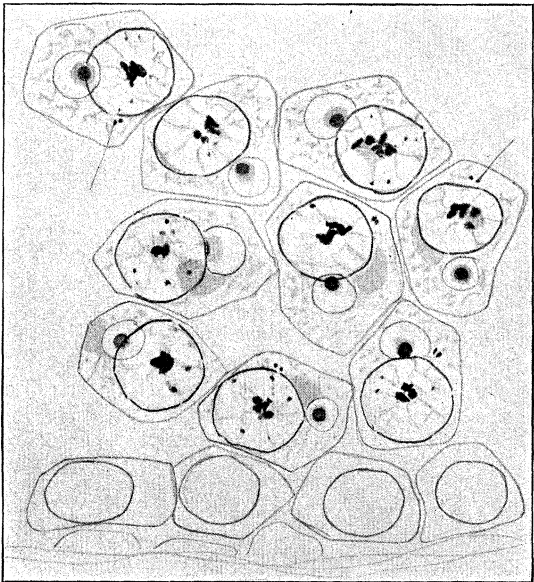


Fig 15.

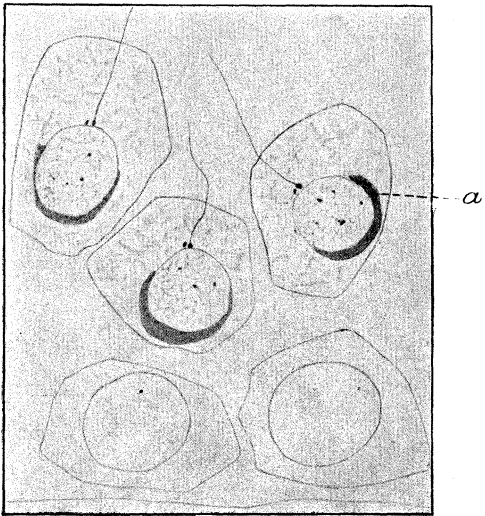


Fig. 16.

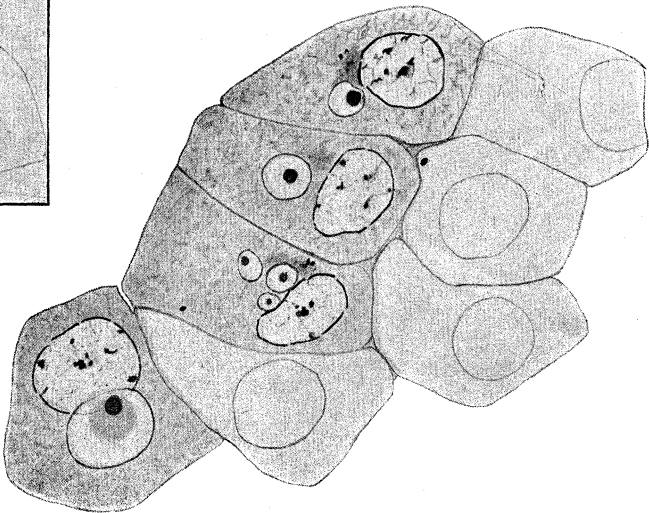


Fig. 17.

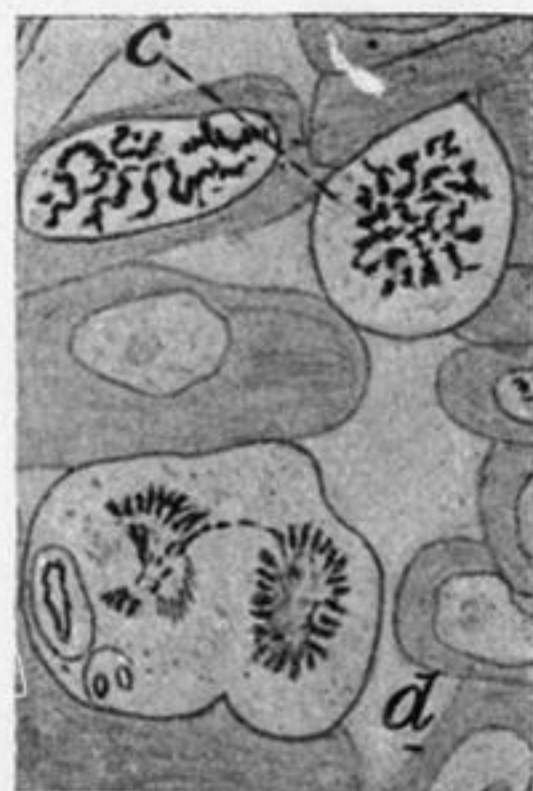PLATE 11.

- Fig. 7.—Cell from an example of Decidua malignum, showing the later phases of the heterotype mitosis.
- Fig. 8.—Similar Cell from an Epithelioma of the Tongue.
- Fig. 9.—Cell from the Testis of Man, showing the later stages of the heterotype division. Compare with figs. 7 and 8.
- Fig. 10.—Cell from a Cancer of the Rectum, showing the somatic or premaiotic character of the chromosomes and the large number of these elements.
- Fig. 11.—Cell from an early Cancer of Rectum, showing the peculiar condition of the nucleus, which suggests amitosis; also two leucocytes (α) within the cytoplasm.
- Fig. 12.—Cell from the same showing nucleus in the prophase of division, and also an intruded leucocyte (α), with its nucleus in the same phase.
- Fig. 13.—Cell from Cancer of the Rectum, showing nucleus in division, and that of intruded leucocyte (α) in a late prophase.

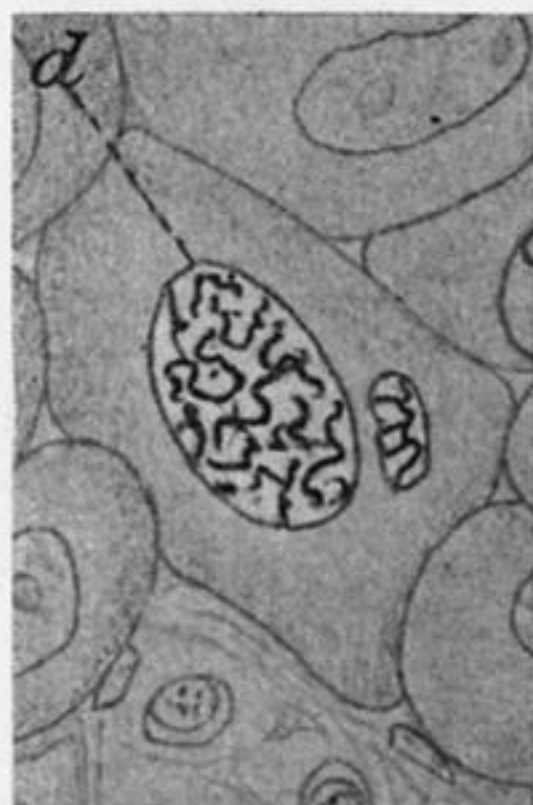PLATE 12.

- Fig. 14.—Portion of the Testis of a Guinea-pig, showing spermatids with developing archoplasmic vesicles and centrosomes.
- Fig. 15.—Portion of the Testis of a Guinea-pig, showing a later stage in the development of the archoplasmic vesicle. In this the origin of the tail of the spermatozoon is also seen, in connection with one of the centrosomes.
- Fig. 16.—Portion of the Testis of a Guinea-pig, showing the remains of the archoplasmic vesicle becoming converted into the so-called "cephalic cap" (α) of the spermatozoon.
- Fig. 17.—Cells from a Cancer of the Breast, showing Plimmer's bodies and the position of the centrosomes. Compare with figs. 13 and 14.
-

1x.



1y.



1z.

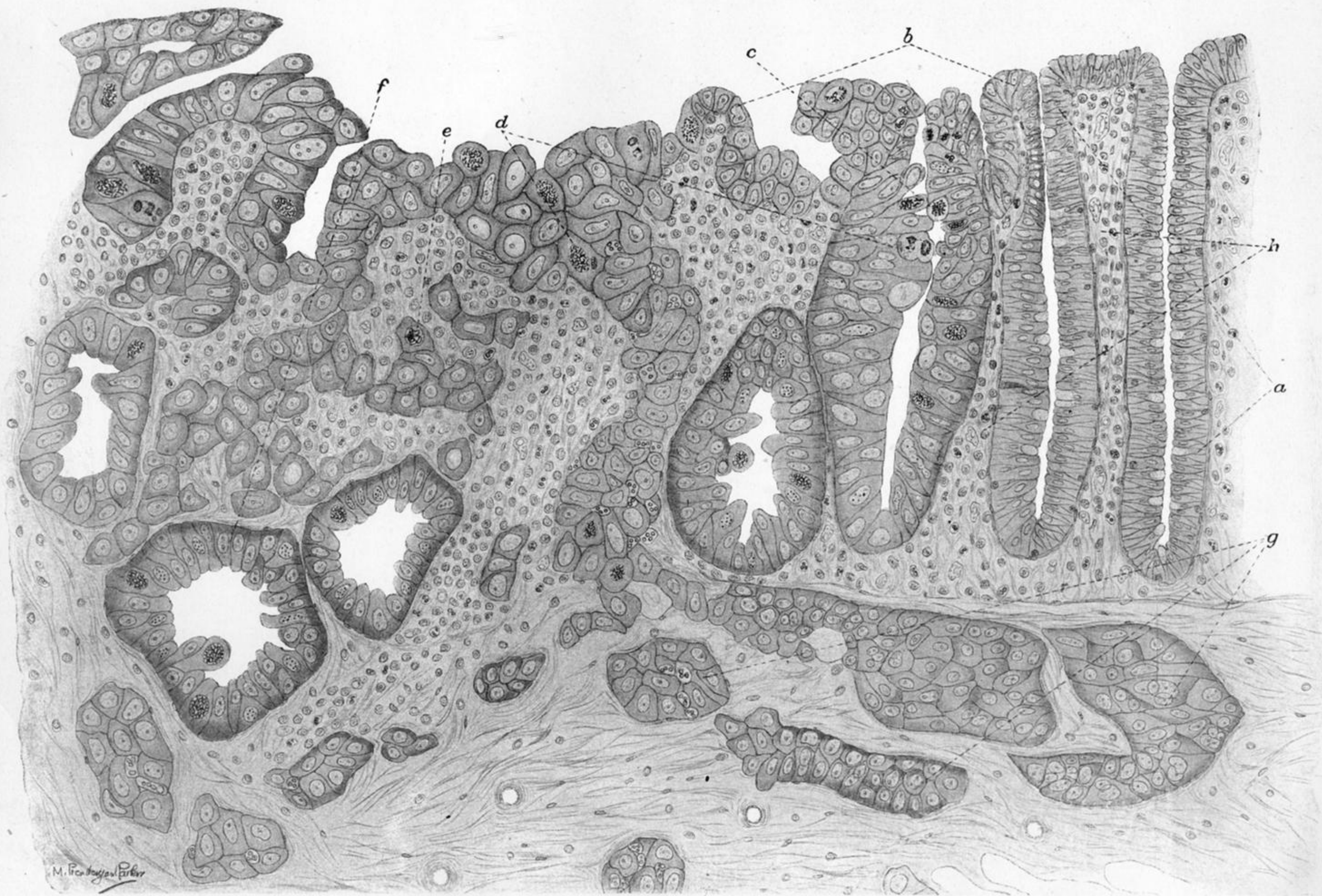
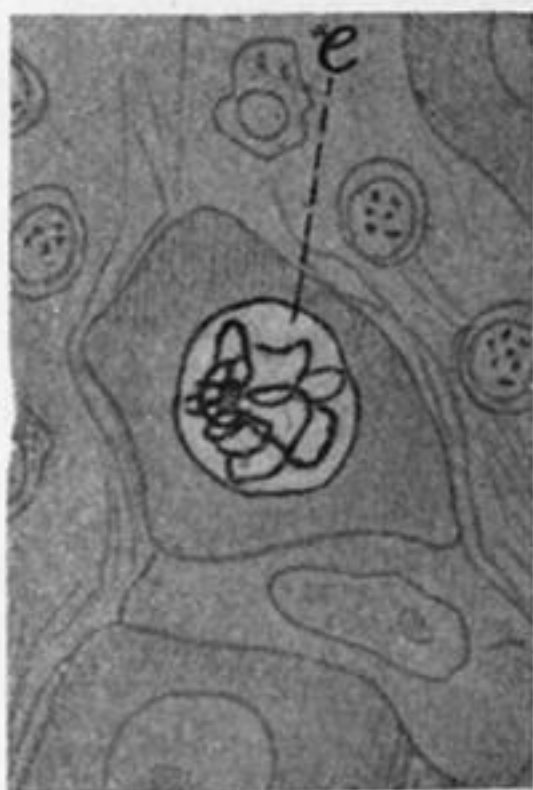
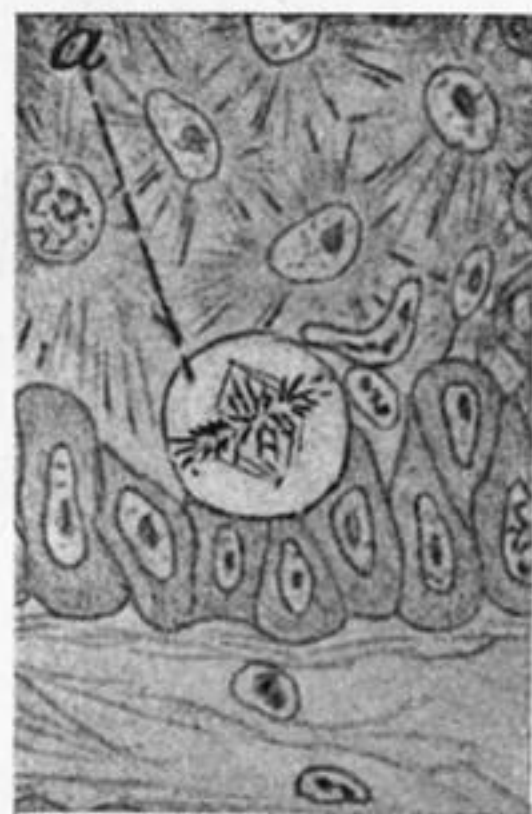
FIG. 1.

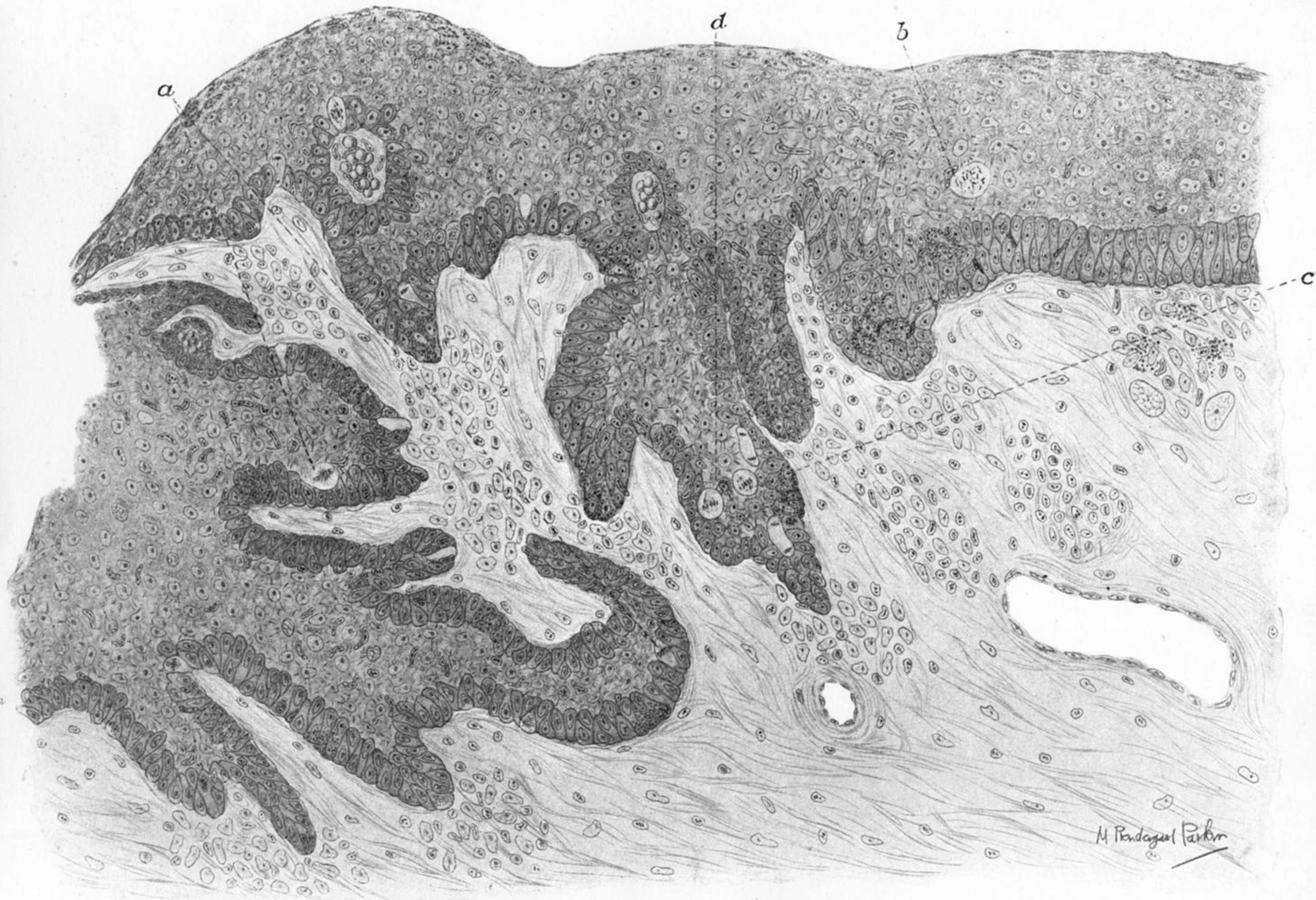
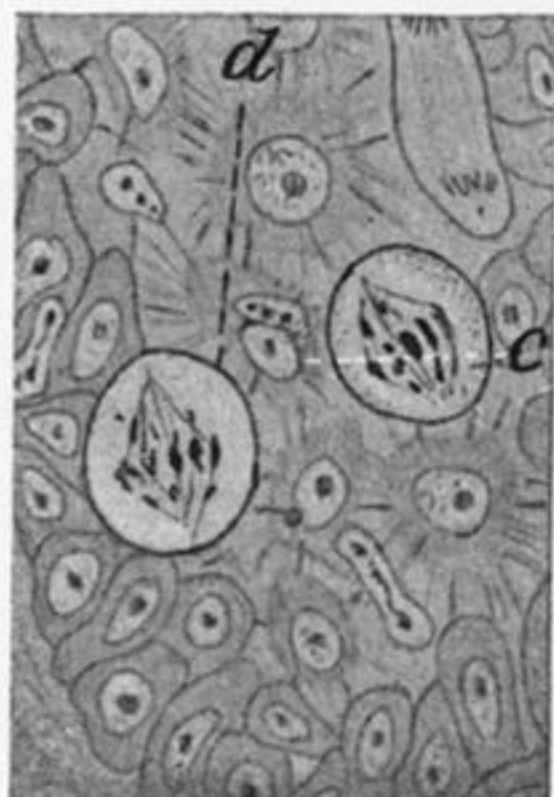
2x.



2y.



2z.



M. Pondagel Parker

FIG. 2.

Fig. 5.

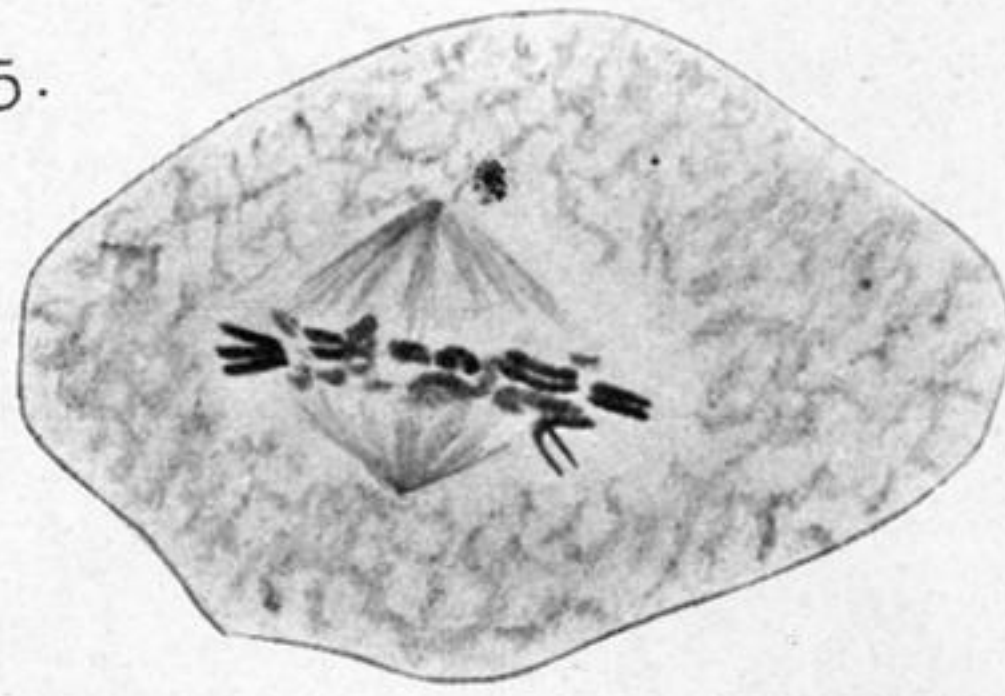


Fig. 3.

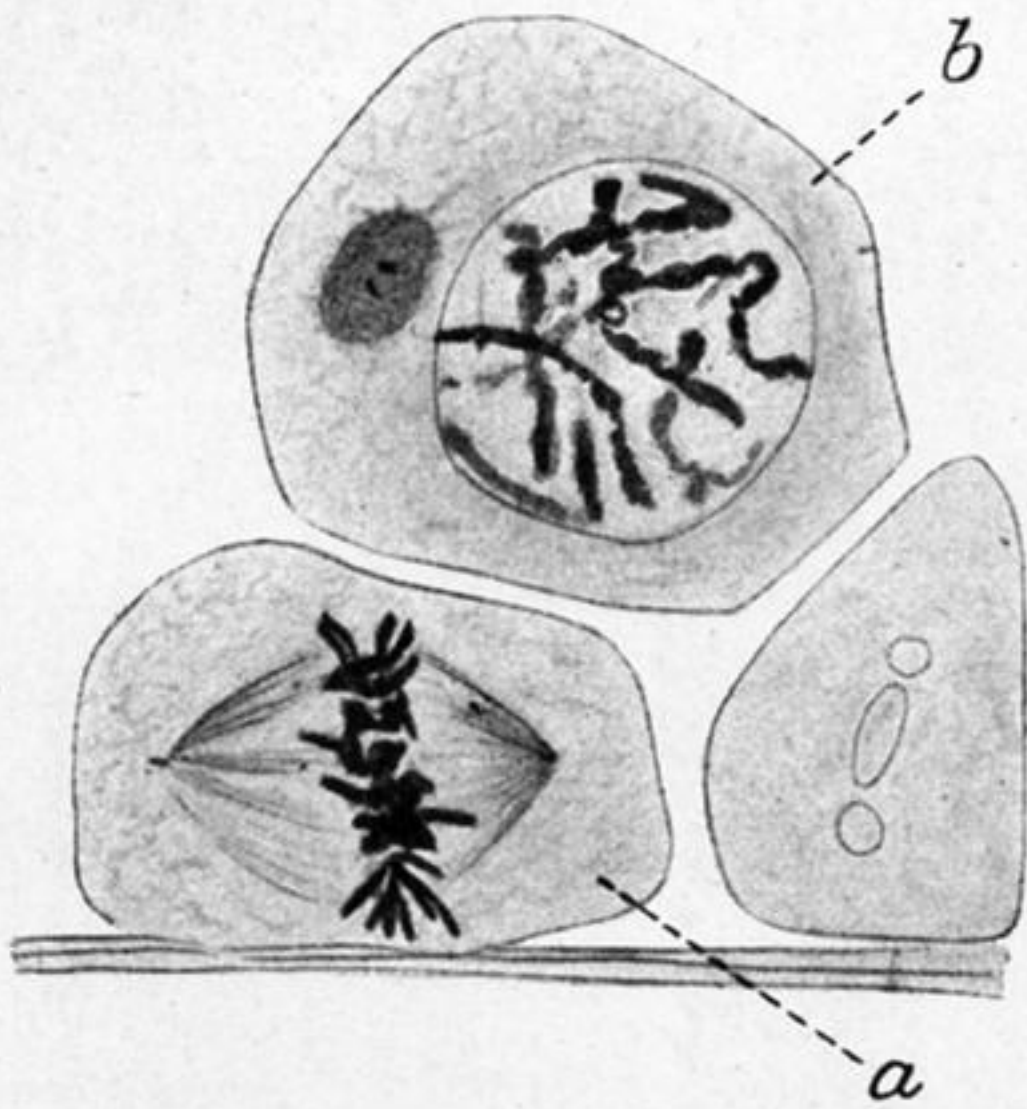


Fig. 6.

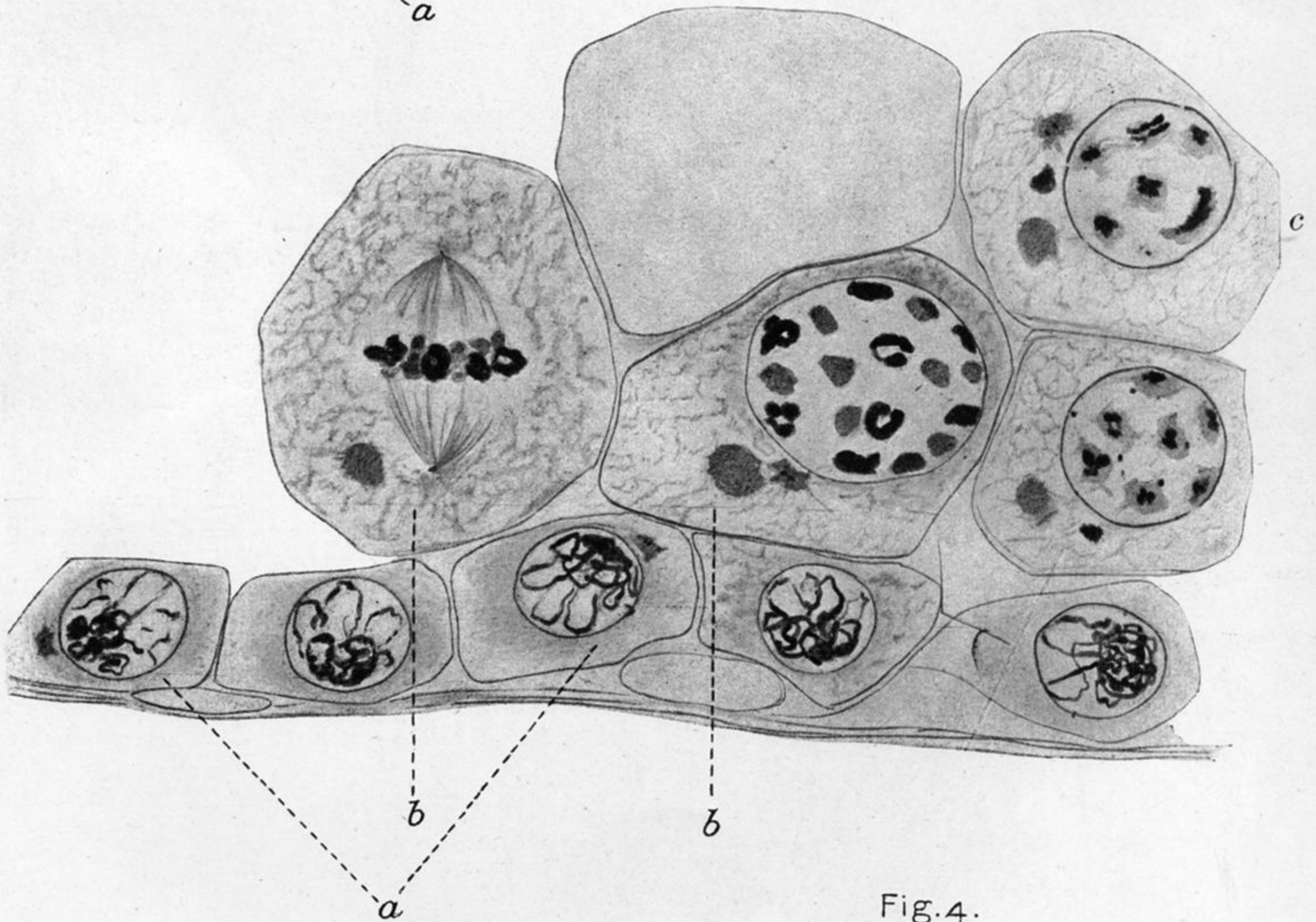
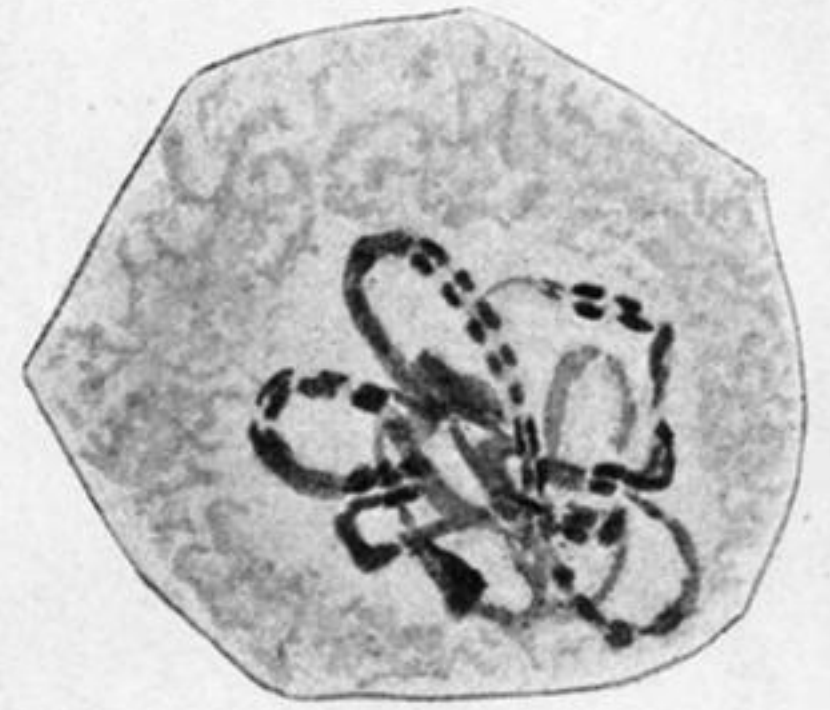


Fig. 4.

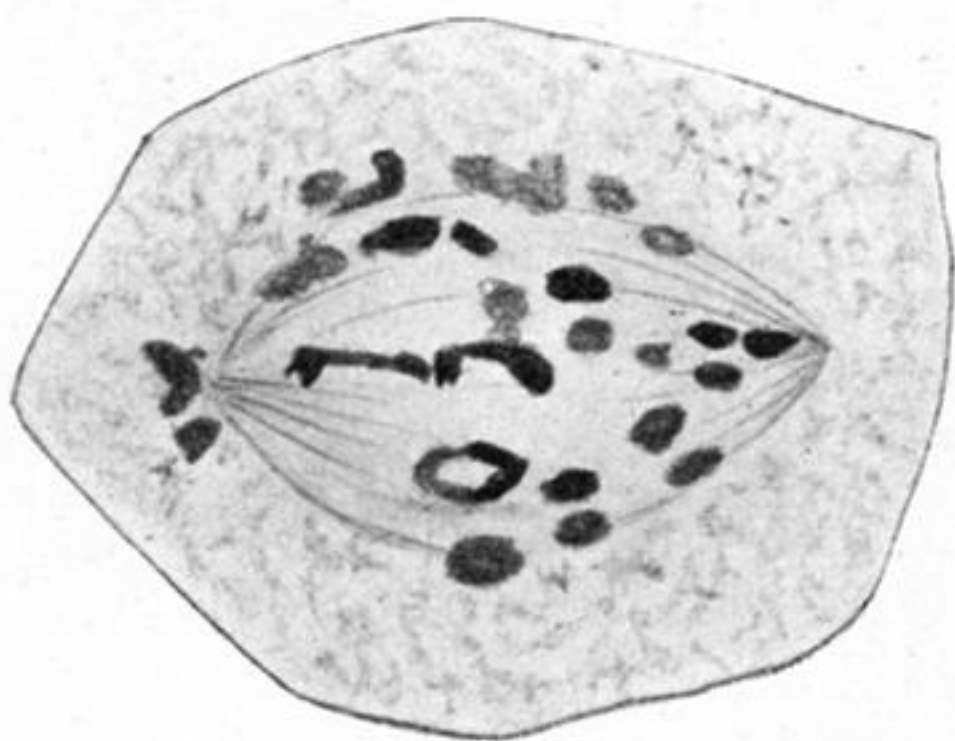

Fig. 7.

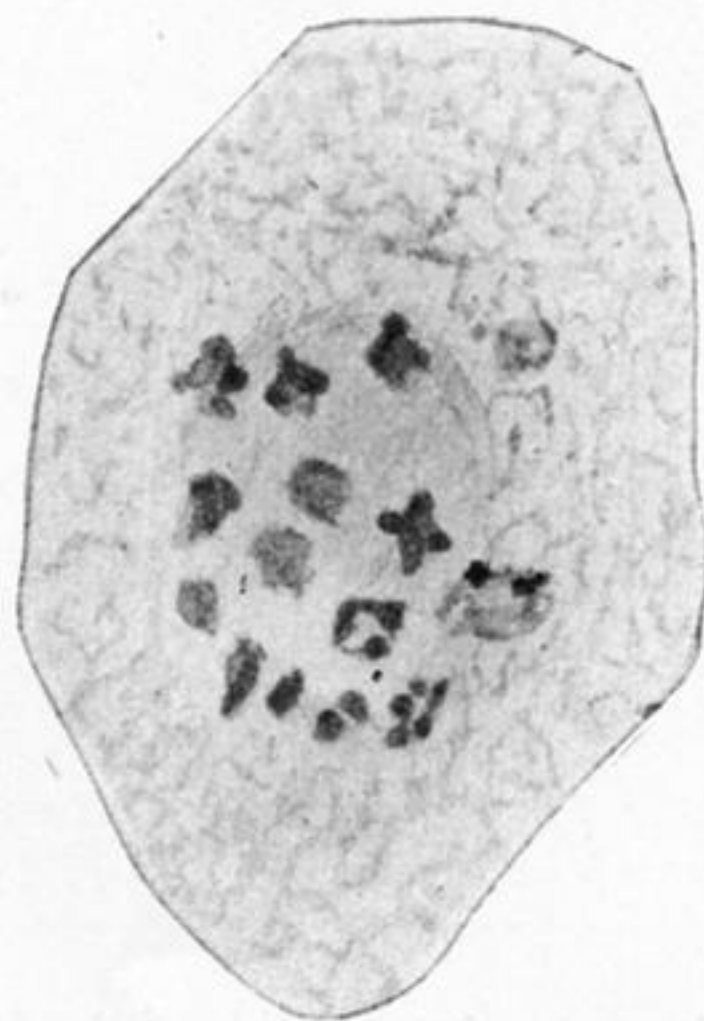


Fig. 8.

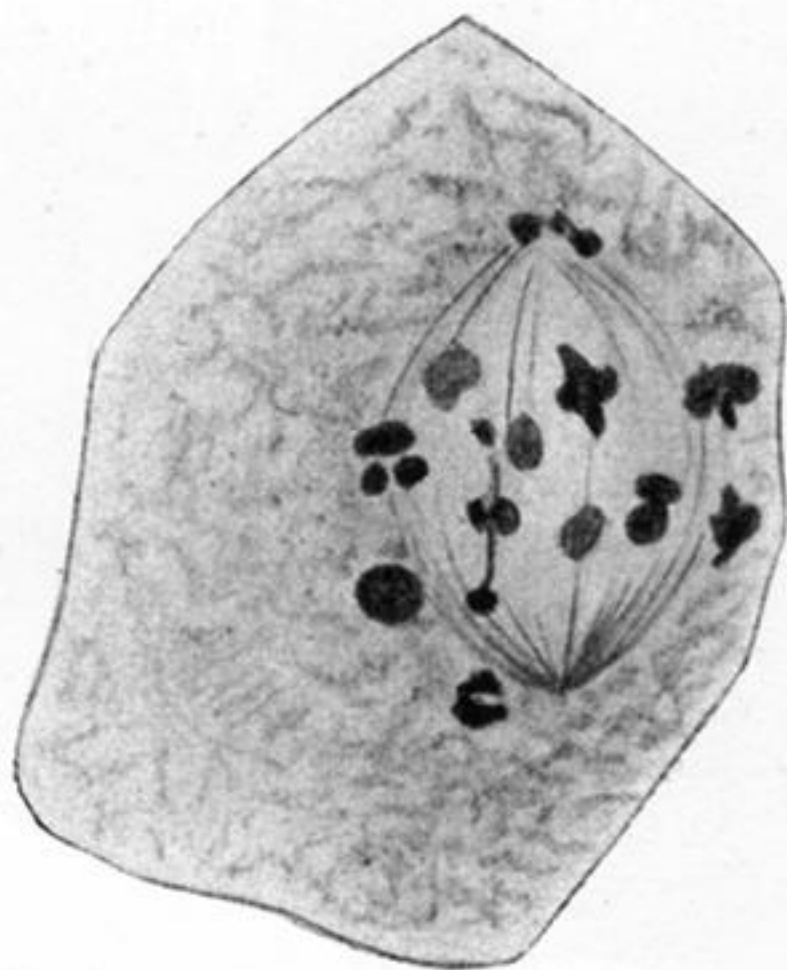


Fig. 9.

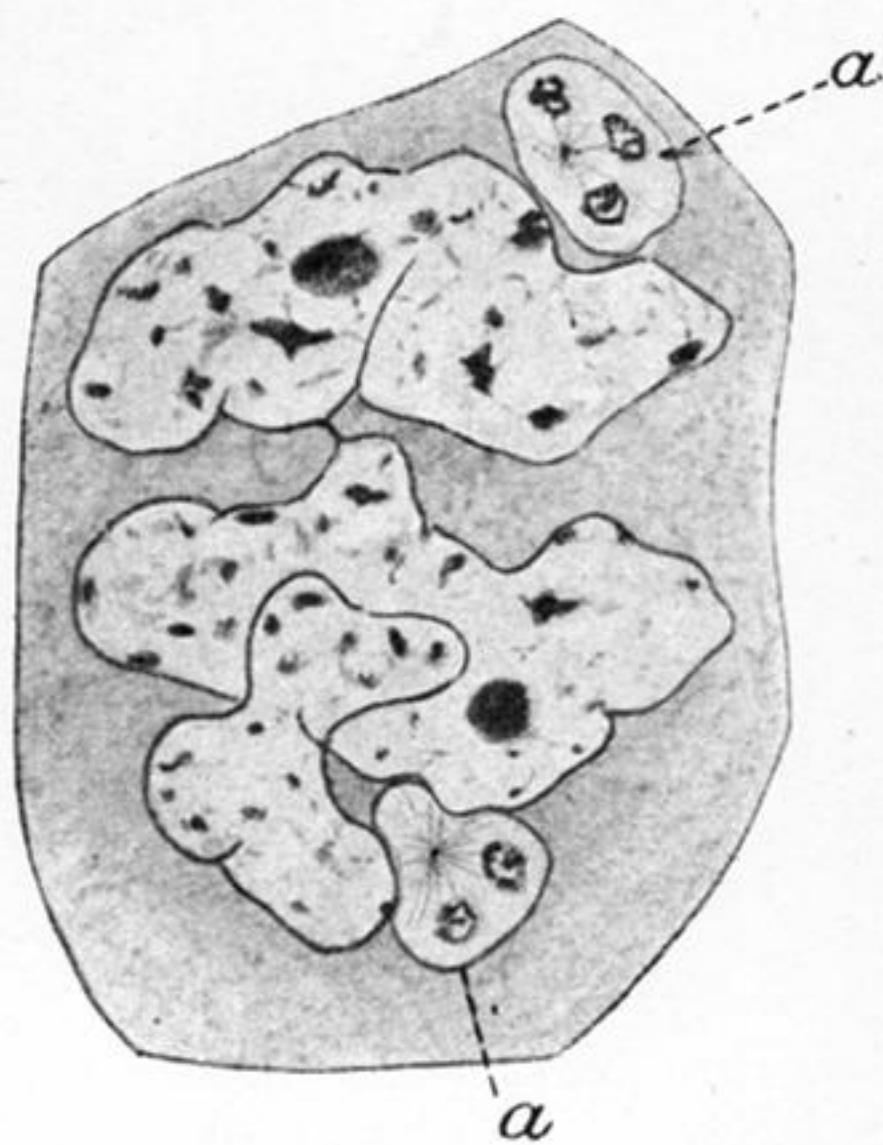


Fig. 11.

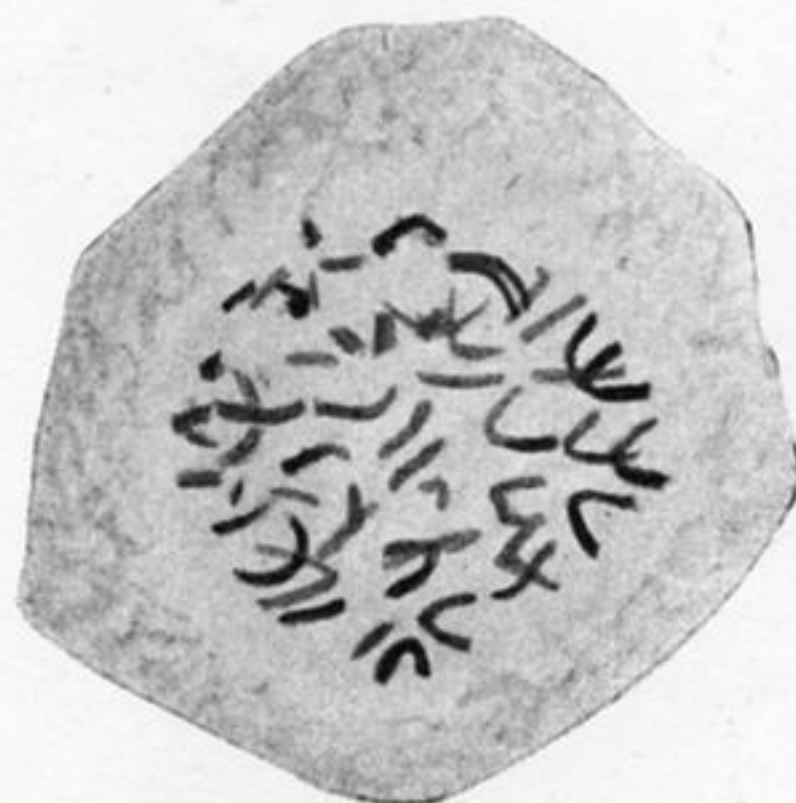


Fig. 10.

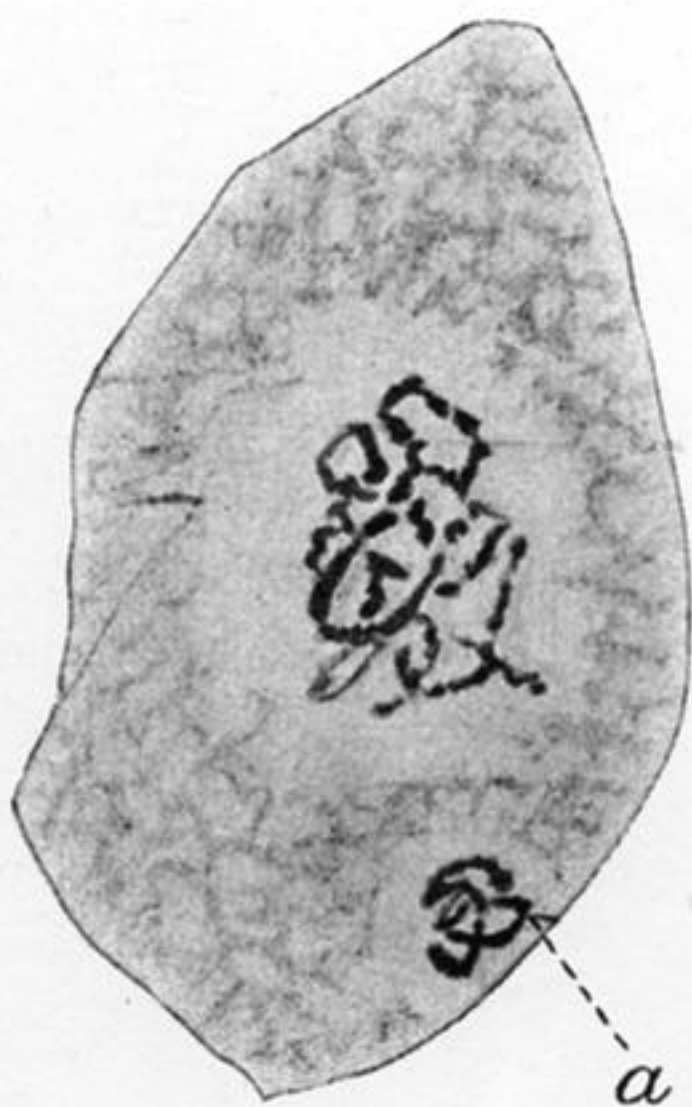


Fig. 12.

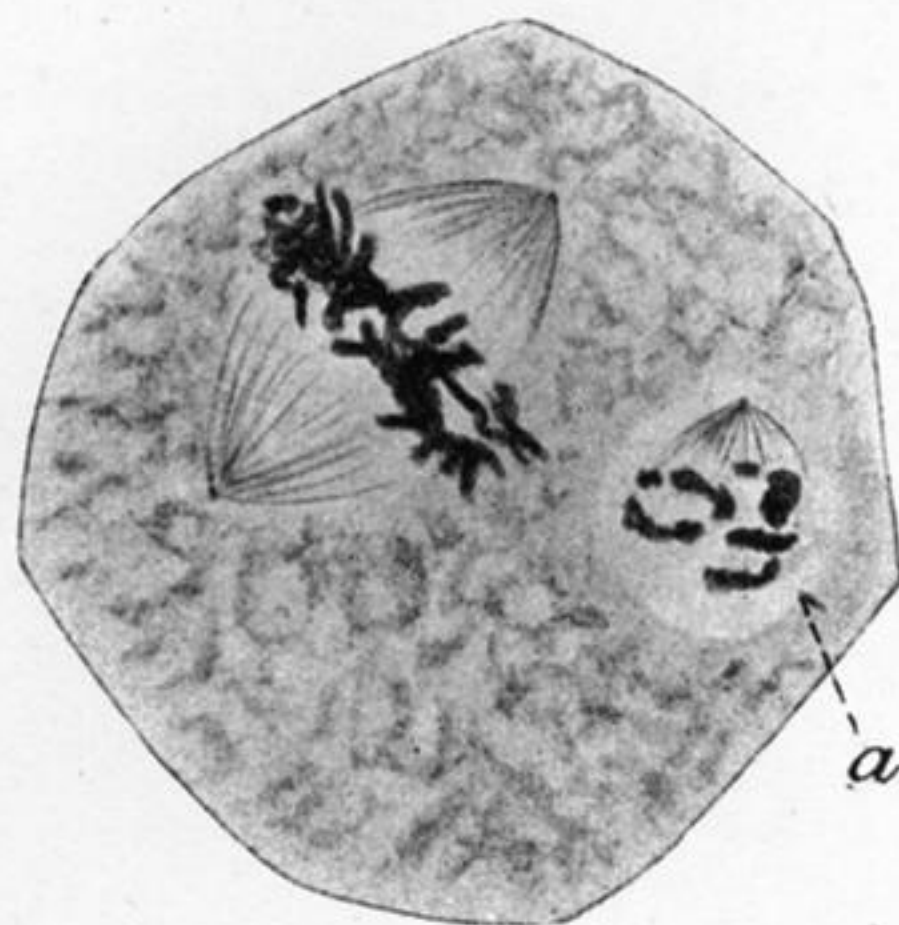


Fig. 13.

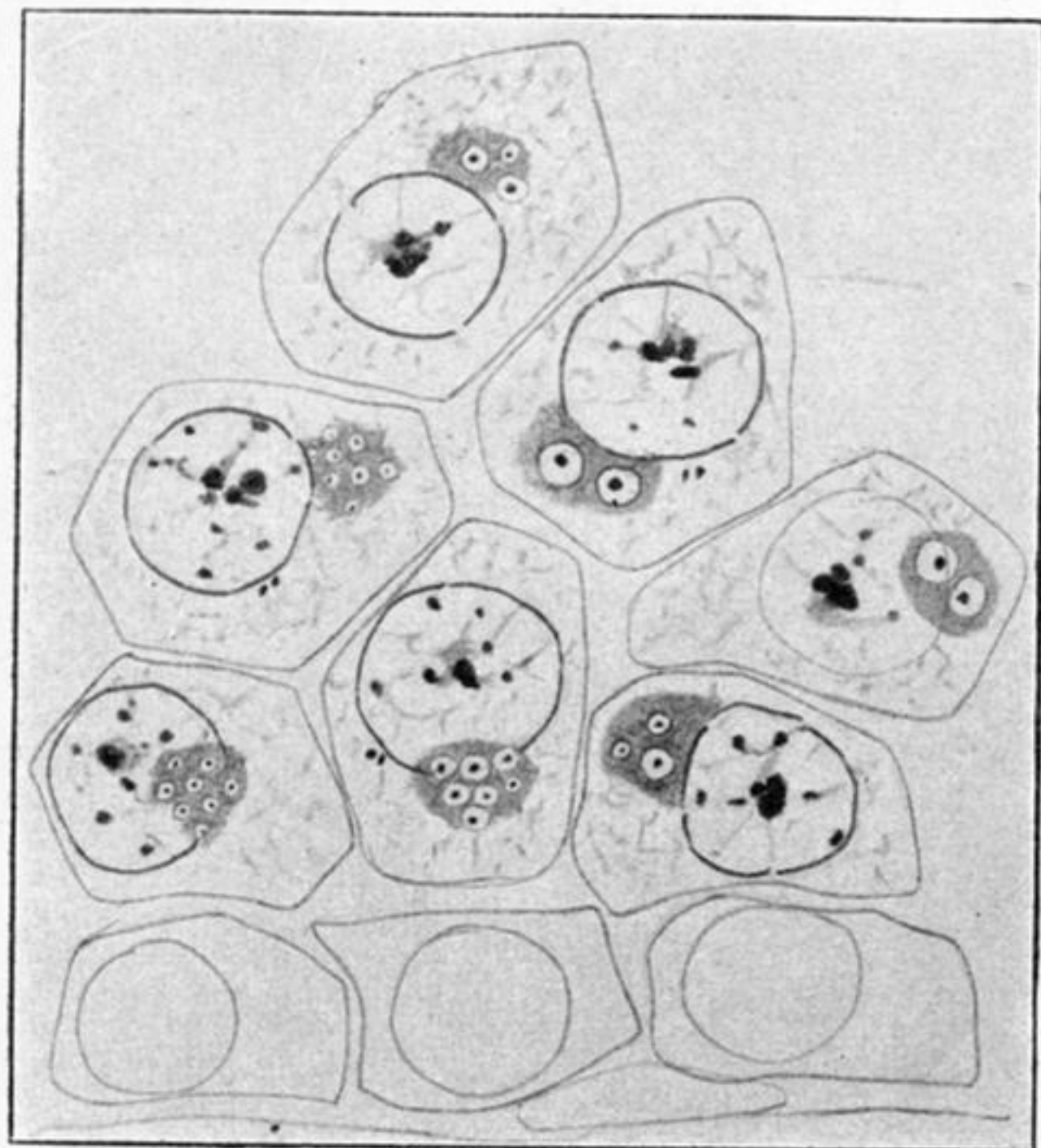


Fig. 14.

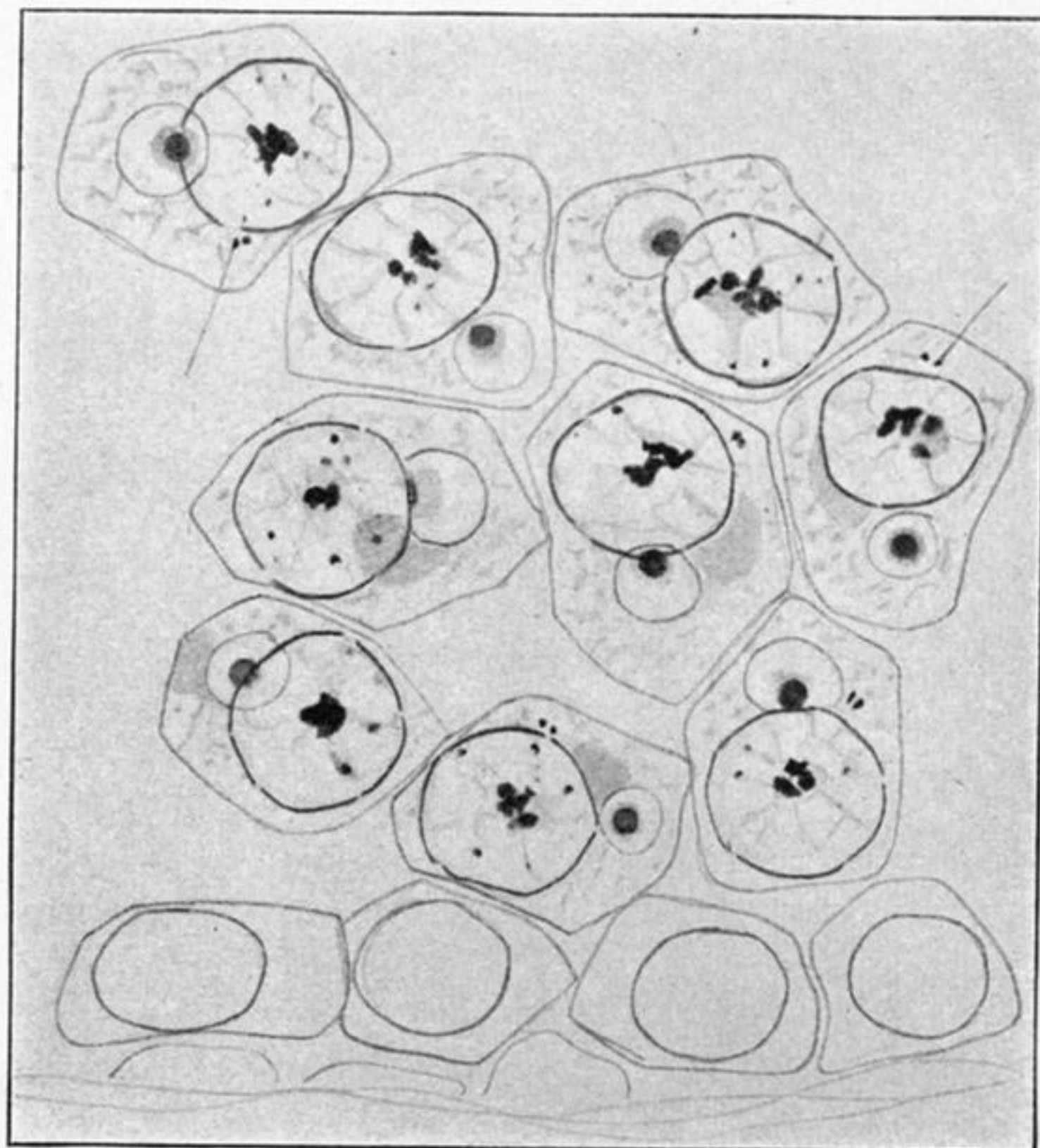


Fig 15.

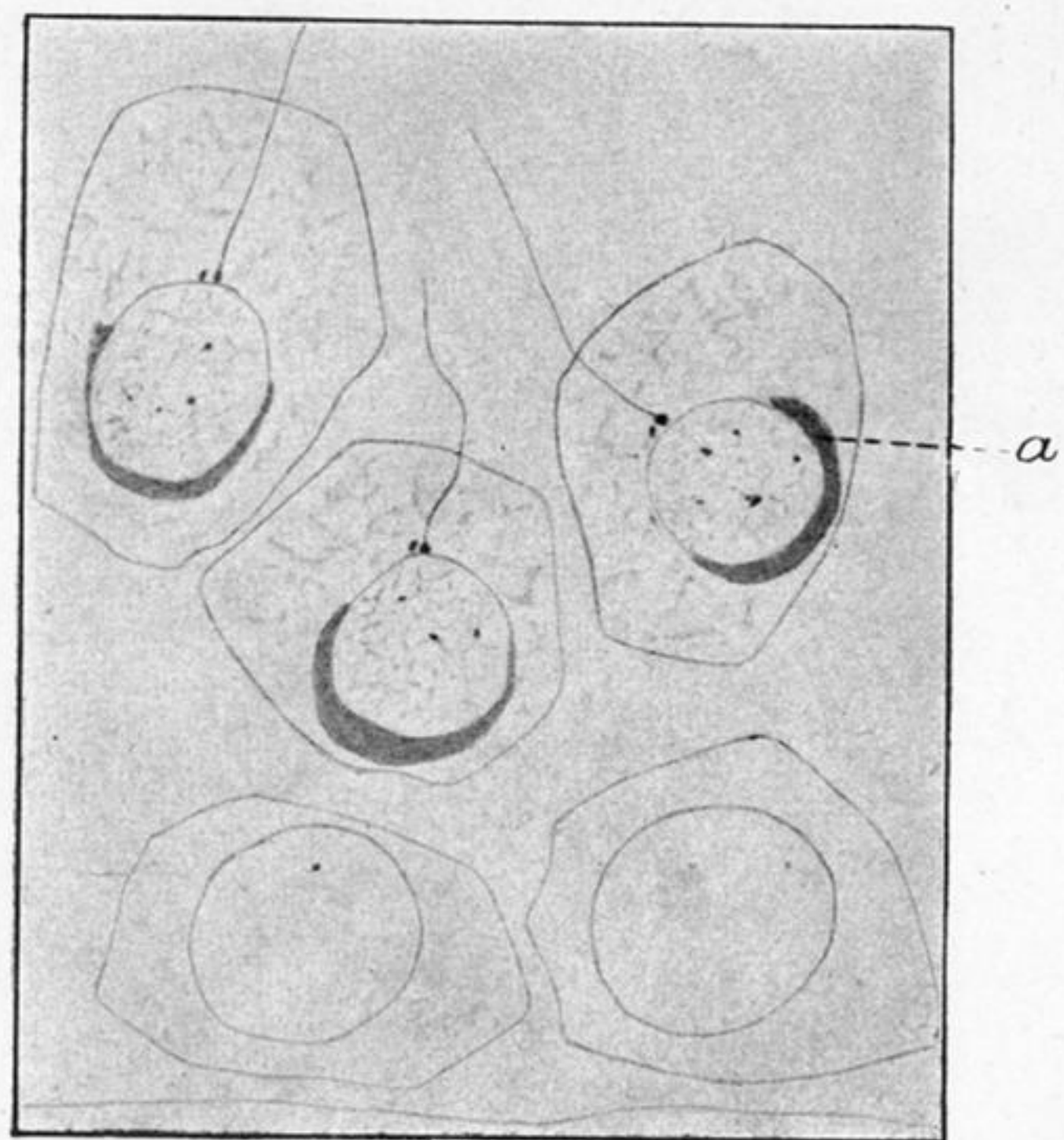


Fig. 16.

Fig. 17

