

*A Preliminary Note on the Extrusion of Granules by
Trypanosomes.*

By W. B. FRY, Captain R.A.M.C.

(Communicated by H. G. Plimmer, F.R.S. Received May 31,—Read
June 15, 1911.)

During some investigations carried out in the Wellcome Tropical Research Laboratories at the Gordon College, Khartoum, a phenomenon was noticed to occur which would seem to have some bearing on the life-history of the trypanosomata.

The observations were made whilst employing the dark ground method of illumination, and certain confirmatory evidence was obtained by using a modification of Levaditi's method of silver staining.

The trypanosome infection of animals referred to in this note was that caused by a strain known in the laboratories as Type I, *T. brucei* or *pecaudi*, a strain which our later conclusions lead us almost undoubtedly to regard as a variety of *T. brucei*.

It was found that at times during the course of an infection, certain of the trypanosomes extrude from their bodies granules which are thrown off apparently with considerable force, and then appear to possess a certain motility of their own in the blood.

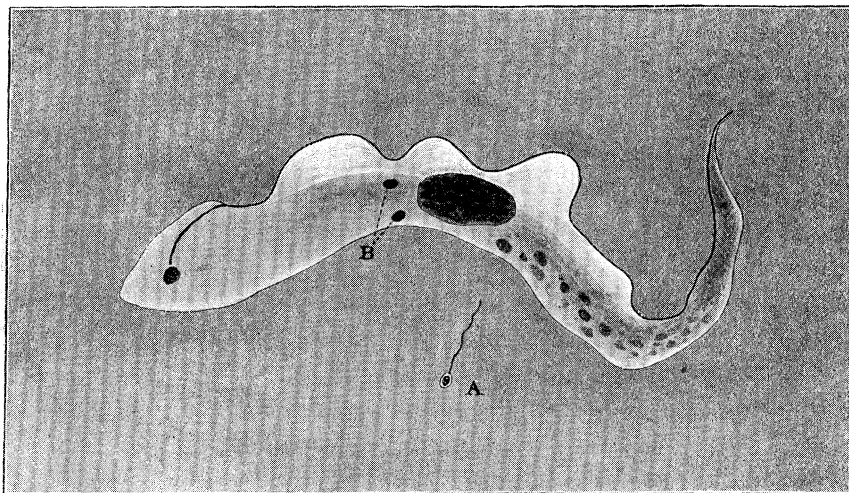
The phenomenon has been observed both naturally and after drug treatment; its occurrence has been studied principally in the Jerboa, an animal in which the disease runs a chronic course, and it is considered that the extrusion of the granules bears some relation to the periodic disappearance of the trypanosomes from the circulating blood.

The granule is irregularly spherical in shape and of an apparently constant size, estimated at about $0.5\ \mu$. At times a fine corkscrew-shaped filament was observed connected to these granules; this was seen sometimes immediately after extrusion; the length of the filament was estimated at four or five times the diameter of the granule. (See accompanying sketch.)

It is believed that similar granules have been observed in the circulating blood in which trypanosomes were not to be found. Further, that the same granules have been identified in certain organs, viz., the lung in dogs, during the course of an infection.

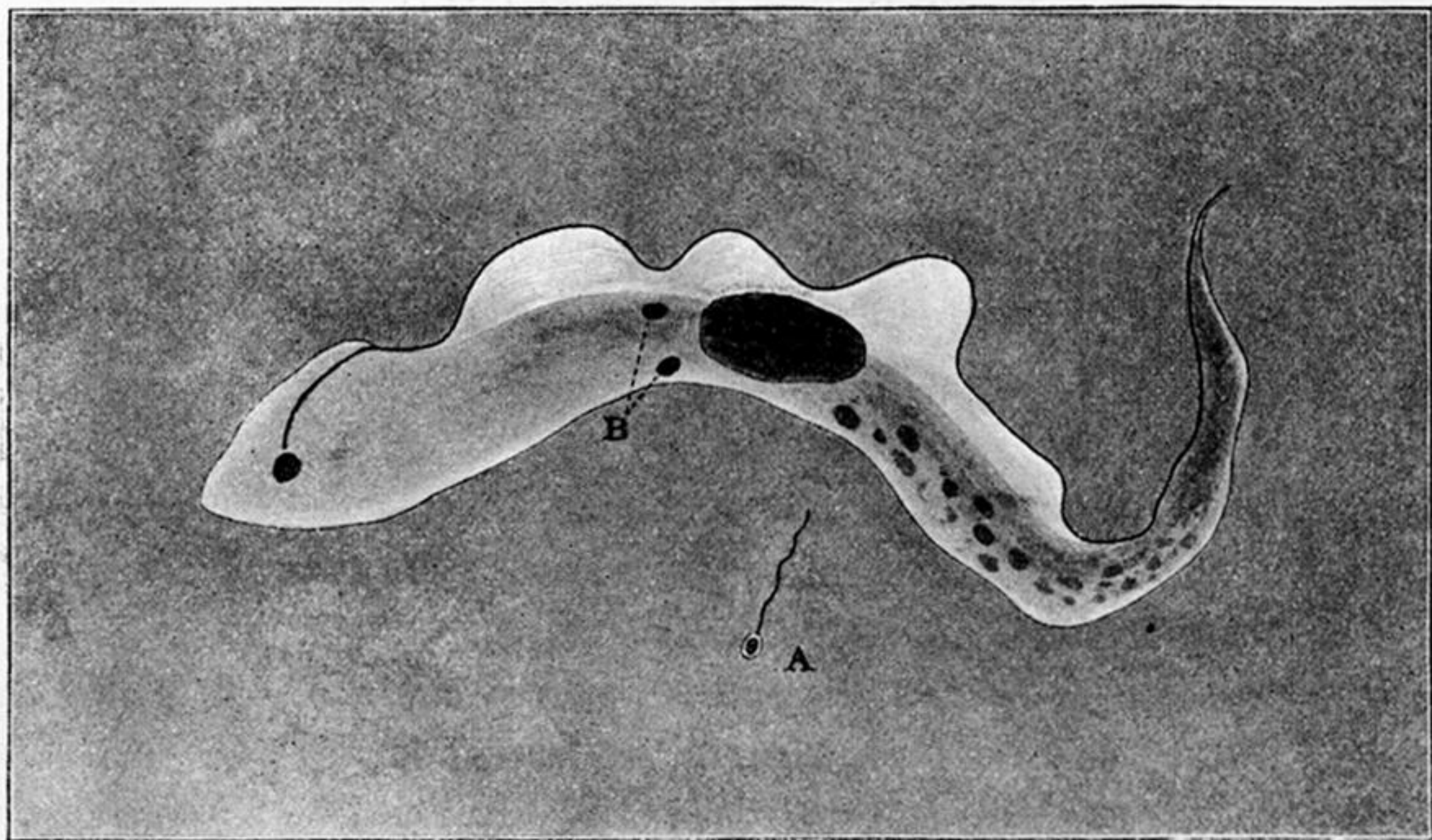
The general appearance and character of the granules were in many ways very similar to those of an extrusion granule, which was subsequently observed by Dr. Andrew Balfour in the same laboratories as occurring in the

spirochaetosis of fowls, accounts of which have already been published. As far as possible the general fallacies due to dark ground illumination were avoided.



Trypanosome and Granule, A, already flagellated, some time after extrusion, to show relative size. At B two granules are shown in the body of the trypanosome.

Further experiments as to the significance of this observation will be carried out later on in the year, but it is at present regarded as essentially of a vital and not of a degenerative nature.



Trypanosome and Granule, A, already flagellated, some time after extrusion, to show relative size. At B two granules are shown in the body of the trypanosome.