

Note on Developmental Forms of Trypanosoma brucei (pecaudi) in the Internal Organs, Axillary Glands and Bone-marrow of the Gerbil (Gerbillus pygargus).

By GEORGE BUCHANAN, Senior Laboratory Assistant, Wellcome Tropical Research Laboratories, Gordon College, Khartoum.

(Communicated by Col. Sir David Bruce, C.B., F.R.S. Received May 12,—Read June 15, 1911.)

[PLATE 3.]

The transmission and maintenance of the trypanosome strains being under my care, ample opportunities were afforded of noting the progress of the disease induced by them in experimental animals and the structural changes in the trypanosomes themselves at varying periods. But it was mainly the cultural work associated with this trypanosome that led to further investigation of these developmental forms and thereby established the observations forming the subject of this note.

On beginning the culture work, inability to recognise if certain forms met with in cultures were either developmental or degenerative phases, suggested a study of the changes which the parasite undergoes, both in the body of the gerbil after death and in citrated blood, and the comparison of these changes with the forms found in Novy and MacNeal and Nicolle's media. With this in view, a gerbil was inoculated with infected blood and chloroformed on the fifth day after injection. Cultures from the heart's blood and smears from the various organs were made, all being examined at regular intervals for comparison. Light was thereby thrown on the point in question, but, in addition to this, attention was drawn to what undoubtedly looked like trypanosome forms in the red blood corpuscles in the spleen. Some of these were identical with those figured by Chagas in his paper on *Schizotrypanum cruzi*, which appeared at the time this work was being conducted.

In order to confirm the observations made, a series of inoculations was carried out in gerbils. In the first of the series, five gerbils were employed, these receiving subcutaneous inoculation in the flanks. In each of the two later series, however, it was found necessary to use eight gerbils at least, the injection being given intraperitoneally as recommended by Chagas. The amount of infected blood in citrate inoculated into each animal was 10 minims, all the eight forming one series receiving the injection at the same time. A gerbil of the series was then chloroformed on each succeeding

day, beginning on the first day after injection. Films from the peripheral and heart's blood were taken, and smears from the lung, liver, spleen, bone-marrow and axillary glands were made, these being fixed and stained by various methods.

As both the intra-corpuscular forms and those which possibly represent encysted stages appeared in the spleen on the fifth day in the first gerbil, a careful examination of the films in the first series up to that time was made, but none of the forms seen in the original slide were recognised. In the other series, however, examination of spleen smears from gerbils chloroformed on the sixth and seventh day respectively revealed both of the forms mentioned. These were also usually obtained in subsequent independent cases on the seventh and eighth day.

Morphology and Development in the Spleen.

(a) *Intra-corpuscular*.—No definite merozoite forms as described by Chagas were ever seen entering the red cells, and the small inclusion shown in Plate 3, fig. 3, was the only appearance observed which suggested a merozoite. Speaking generally, the smallest intra-corpuscular forms met with took the shape of very small rings with two chromatin masses, and were about one-third the size of the red blood cell. Nearly all stages from this to a fairly mature trypanosome, contained within the limiting envelope of the red cell, could be traced, the intermediate stages in many cases being similar to those of *Schizotrypanum cruzi*. This fairly mature trypanosome, however, possessed neither undulating membrane nor flagellum. Some of the more mature forms were coiled up or S-shaped, every part of them being wholly within the corpuscle. These varieties were not so numerous as the complete ring forms. The blepharoplast was not recognisable in all cases, but, when present, was usually situated at the thinnest part of the ring.

(b) *Extra-corpuscular*.—Ring forms were also met with free in the plasma, and these impressed one as being possibly encysted and likewise showed a development similar to that seen in the red cell. Numerous small solid, encysted (?) forms appeared in the spleen on the fourth day in one gerbil, and these, as a rule, were also present in other animals in the bone-marrow and axillary glands on and after the sixth day. The very small types appeared as spherical masses of densely-stained blue protoplasm, the nucleus in some being indicated by a small undefined violet mass, while the blepharoplast was detached.

Round the spherical body here described there existed, as a rule, at least when development was somewhat advanced, a clear area which gave the impression that the protoplasmic mass was lying in some form of vacuoloid

space which was possibly surrounded by a limiting membrane. It was in connection with this membrane (?) that the blepharoplast was found, hence the use of the term "detached" (Plate 3, fig. 15). It was found that, as the protoplasmic mass became larger, a clear area developed within it. This increased in size, the nucleus of the mass became more distinct, and finally the blepharoplast appeared gradually to approach the mass until it became part of it. Such a movement on the part of the blepharoplast is well-nigh inconceivable unless there was originally some connection between it and the main mass of protoplasm. Such, however, I have never been able to demonstrate.

Eventually the spherical masses became ring-shaped, resembling in every respect those met with in the red cells.

These stages were always observed within the vacuoloid space, which enlarged to accommodate the requirements of the developing trypanosome. As in the red cells, forms almost mature were eventually found. These, which possessed free extremities, often assumed S shapes within a faintly defined capsule, the nucleus and blepharoplast being situated as in an ordinary trypanosome. Later observations showed that these forms were invariably found free in the plasma of the spleen, bone-marrow and axillary gland several days previous to the appearance of the intra-corpuscular forms.

Forms found in Lung Smears.

The probability of schizogony occurring in the lung as in the case of *Schizotrypanum cruzi* was borne in mind, but no definite schizonts were seen in any of the smears. Yet the forms figured by Chagas* and described by him as parasites in the lung of vertebrates preparing for schizogony were exceptionally numerous in the lung of a gerbil on the sixth day. In fact they were the only forms present in smears from the lung at that time, but no suggestion of merozoite formation was ever observed. Some forms seen resembled the so-called latent bodies of *Trypanosoma gambiense* described by Moore and Brein† and more recently by Fantham‡ as occurring both in *T. gambiense* and *T. rhodesiense* infections. Their method of formation, however, seems to be somewhat different to that described by these authors. It is, perhaps, sufficiently indicated by the cycle of events shown in Plate 3, figs. 19—32. In addition there was markedly evident the presence

* Chagas, C., "Ueber eine Neue Trypanosomiasis des Menschen," 'Memorias do Instituto Oswaldo Cruz,' August, 1908, vol. 1, No. 2.

† Moore, J. E. S., and Breinl, Anton, "The Cytology of the Trypanosomes," 'Annals Tropical Med. and Parasitol.,' July, 1907, vol. 1.

‡ Fantham, H. B., "The Life-history of *Trypanosoma gambiense* and *Trypanosoma rhodesiense* as seen in Rats and Guinea-pigs," 'Roy. Soc. Proc.,' B, 1910, vol. 83.

of individual spherical forms dividing into two, and occasionally three, separate bodies, each of which eventually assumes a trypanosome shape. As a result, large numbers of what were undoubtedly very young trypanosomes, each with a well-defined nucleus but without undulating membrane and flagellum, were present in the lung smears.

No definite intra-corpuseular or free encysted forms were ever seen in the lung or peripheral blood. The former appeared exclusively in the spleen, while the latter were found without fail in the spleen, bone-marrow and axillary glands.

The axillary gland showed an unending variety of young trypanosomes corresponding in the main to those described above in the lung, while the encysted stages were also very numerous.

A marked feature, perhaps worthy of note, was the constant presence of free chromatin granules in nearly all the smears from the second day onwards. These were apparently derived from the nuclei of disintegrating trypanosomes, and possibly represented a first stage in development.

DESCRIPTION OF PLATE 3.

Magnified 2000 diameters. Drawn with Zeiss Oc. No. 12, obj. oil imm. 2 mm., and tube length 155.

Fig. 1.—Long form with free flagellum.

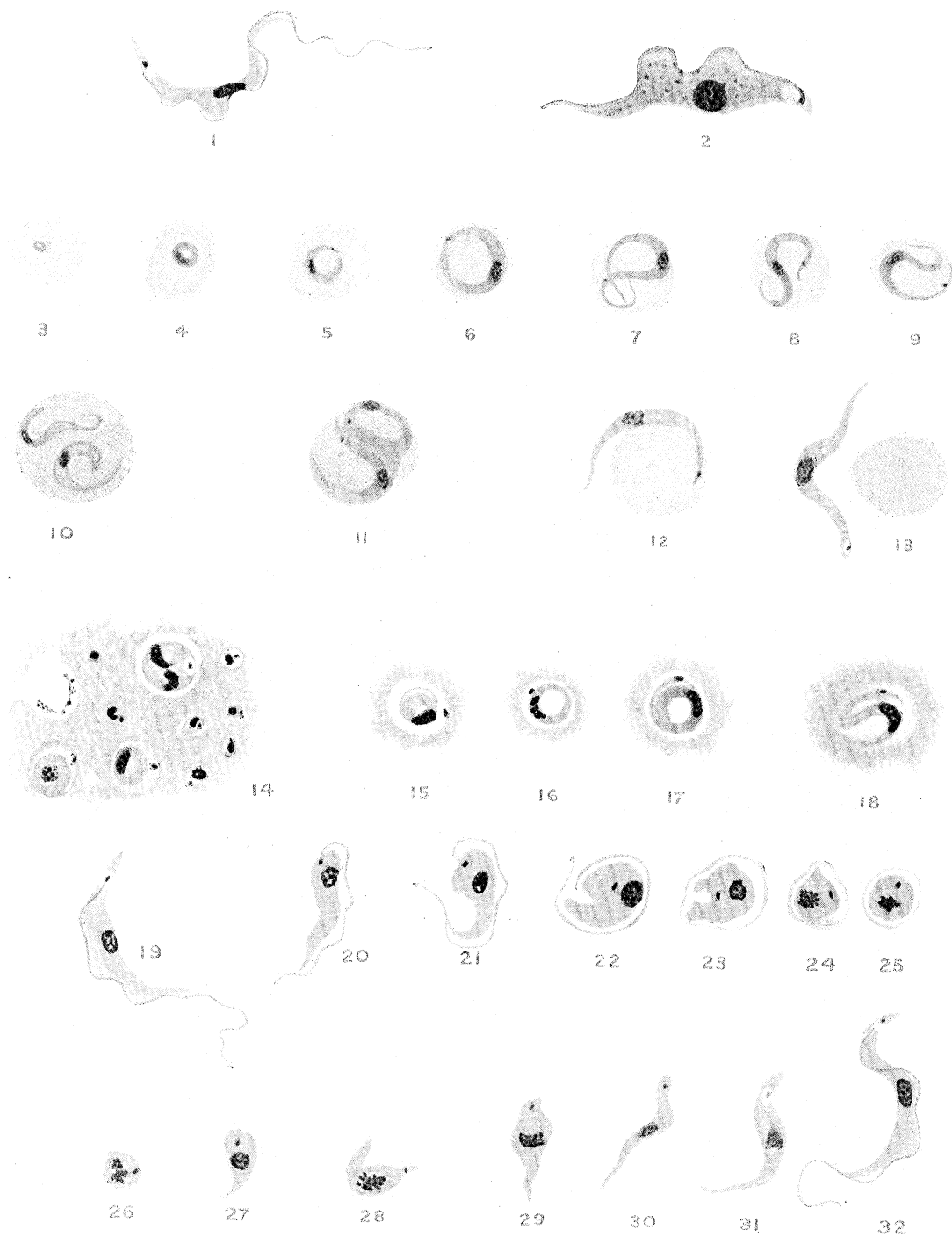
Fig. 2.—Stout granular form with very short flagellum.

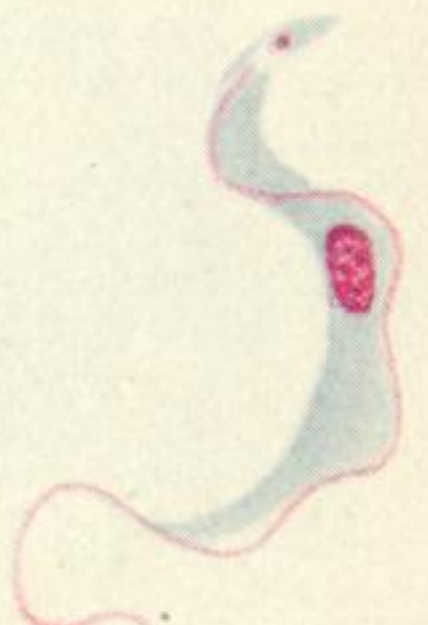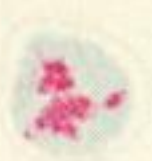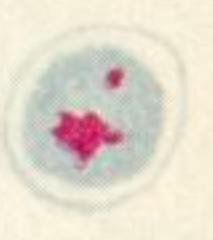
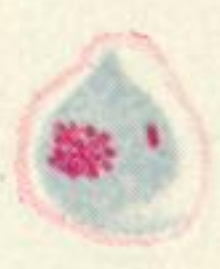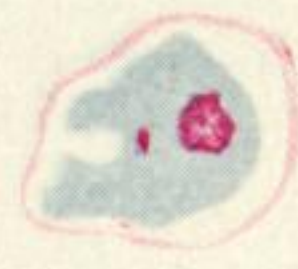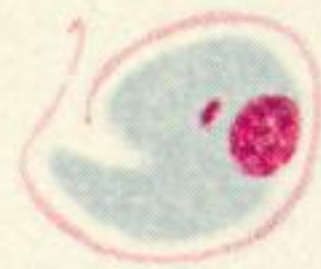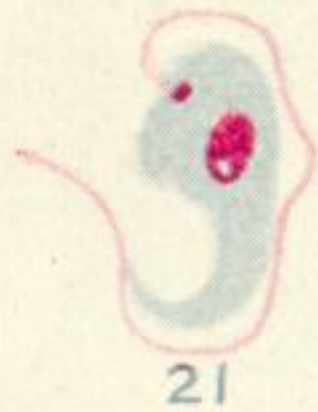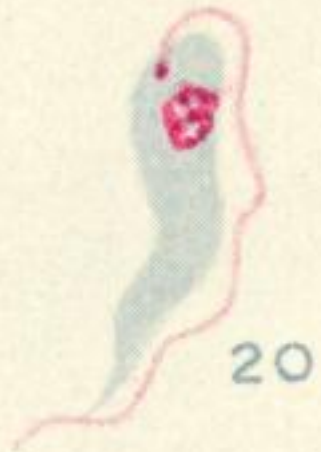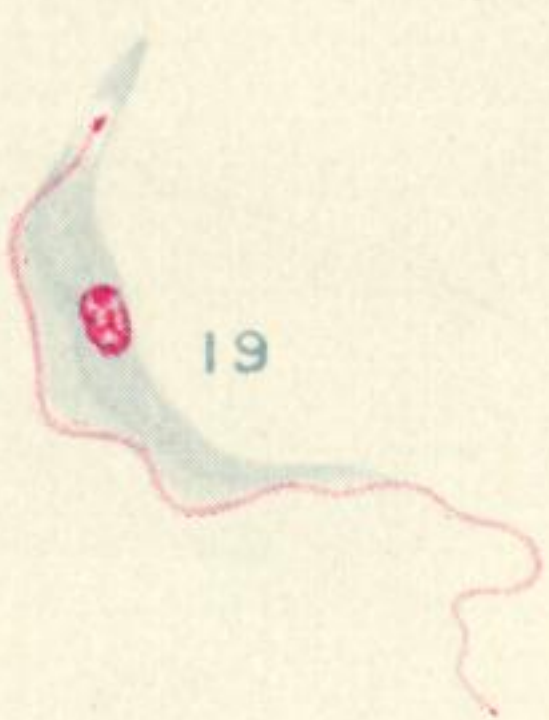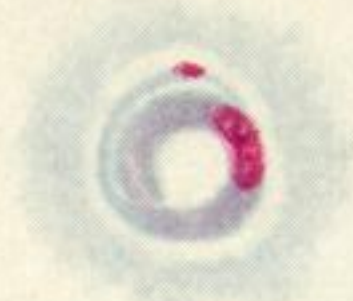
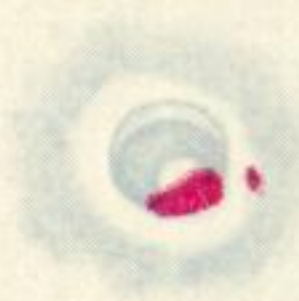
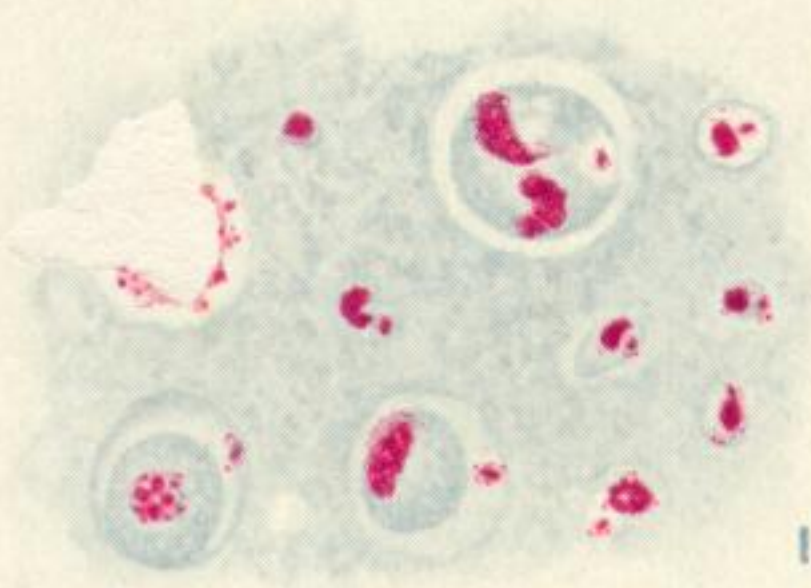
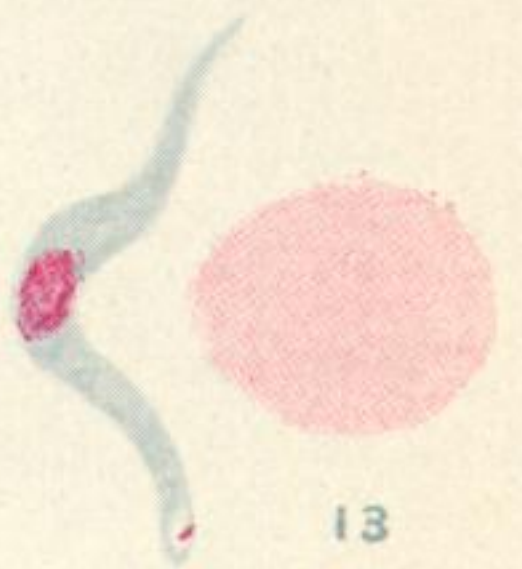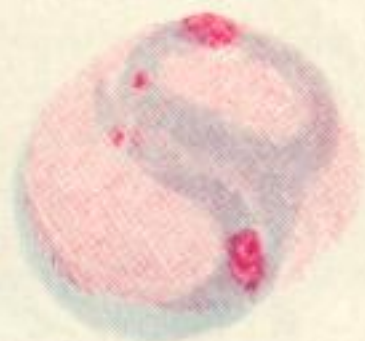
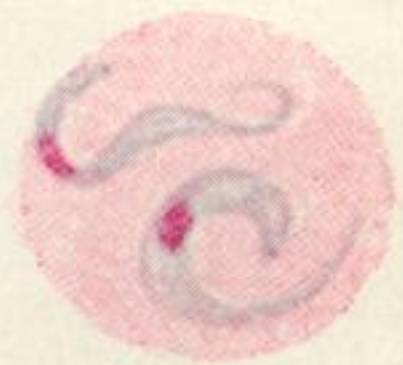
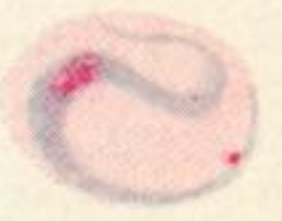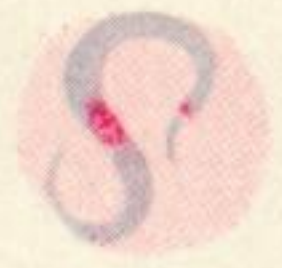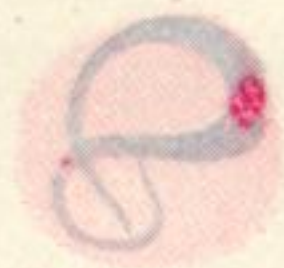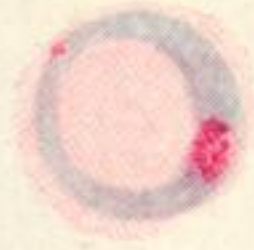
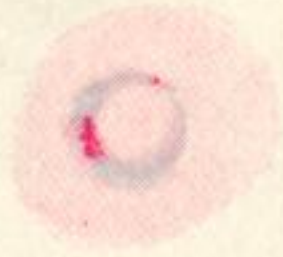
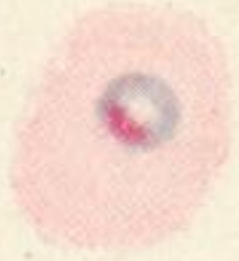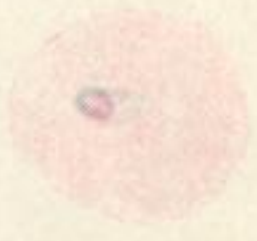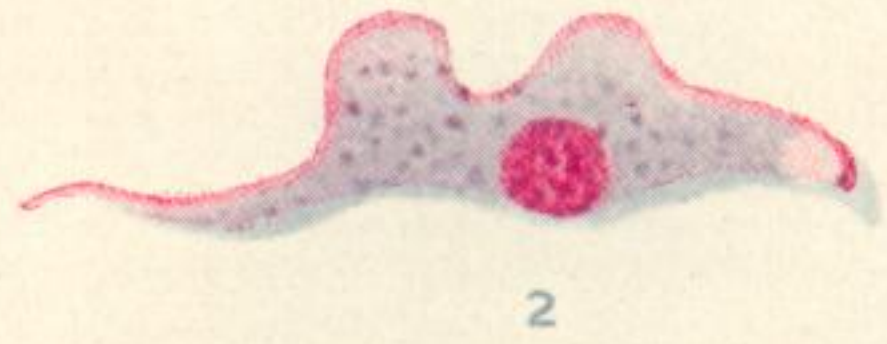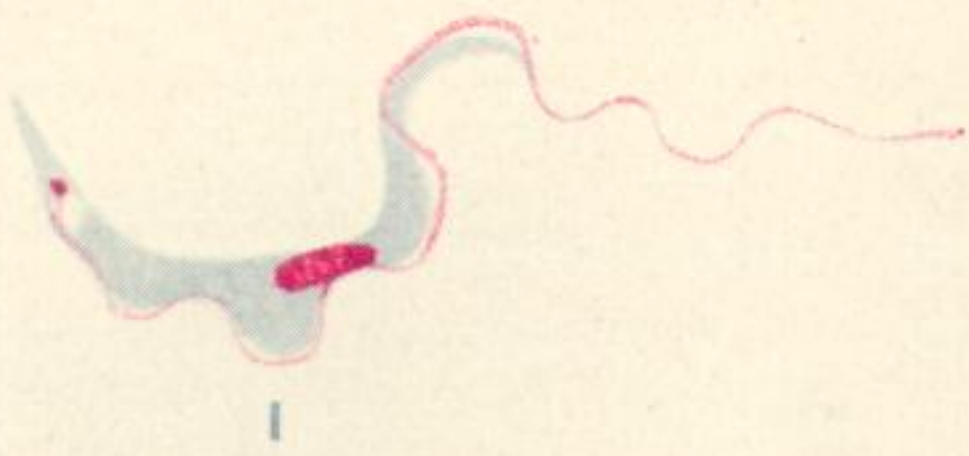Figs. 3—13.—Intra-corpuseular cycle as seen in spleen on sixth day.

Figs. 14—18.—Extra-corpuseular and apparently encysted forms in spleen, sixth day.

No. 14 shows granules and very small bodies, the former possibly representing infective granules, the latter possibly a very early stage of development.

Figs. 19—32.—Forms found in lung smear on sixth day. 19—25 show possible formation of so-called "latent body" of Moore and Breinl. 26—32, metamorphosis of latent body into trypanosome.





26

27

28

29

30

31

32